

Clinical Information for Medical Necessity Review

CMS Policy Hierarchies & Application

Guideline Definitions

GENERAL

Preface	Abdomen
Breast	Cardiac
Cardiac Implantable Devices (CID)	Chest
Head	Musculoskeletal
Neck	OB Ultrasound
Oncology	Pelvis
Peripheral Nerve Disorders (PND)	Peripheral Vascular Disease (PVD)
Spine	

PEDIATRIC

Pediatric Abdomen	Pediatric Cardiac
Pediatric Chest	Pediatric Head
Pediatric Musculoskeletal	Pediatric Neck
Pediatric and Special Populations Oncology	
Pediatric Pelvis	Pediatric Peripheral Nerve Disorders (PND)
Pediatric Peripheral Vascular Disease (PVD)	Pediatric Spine

Clinical Information to Establish Medical Necessity

eviCore applies an evidence-based approach to evaluate the most appropriate medically necessary care for each individual. This evaluation requires submission of legible medical records pertinent to the test or treatment being requested by the provider.

If the medical records provided do not provide sufficiently detailed information to understand the individual's current clinical status or cannot be read, then medical necessity for the request cannot be established and cannot be approved.

Specific elements of an individual's medical records commonly required to establish medical necessity include, but are not limited to:

- Recent virtual or in-person clinical evaluation which includes a detailed history and physical examination since the onset or change in symptoms
- Laboratory studies
- Imaging studies
- Pathology reports
- Procedure reports
- Reports from other providers participating in treatment of the relevant condition

Medicaid and Medicare Hierarchy and Application

CMS.AD.100.A
v2.0.2023

Medicaid

Medicaid Hierarchy

1. Medicaid state-specific policy
2. eviCore's evidence-based guidelines or the appropriate alternative guideline utilized by a program/health plan in place of eviCore's guidelines
3. Early and Periodic Screening, Diagnostic and Treatment (EPSDT) guidelines should also be reviewed for individuals under 21 years of age as applicable for coverage determination

Application of Medicaid Policy

The state Medicaid policy will be reviewed first to determine if the information provided is instructive to the clinical case at hand. For the purpose of this policy, sufficient clinical criteria to render a medical necessity decision is defined as the presence of a state Medicaid policy that addresses the service/procedure/test/equipment and the member condition (indication) and supplies sufficient clinically relevant detail to be instructive to the case. See the numbered items below for specific guidance:

1. State Medicaid policy addresses clinical scenario: (service/procedure/test/equipment AND member condition AND Medical Necessity criteria):
 - a. Medicaid policy will be utilized and cited for determining medical necessity
 - b. If specific medical necessity criteria are present in the state policy, but are limited or less detailed than eviCore or alternative guideline, the state policy would still be applied and cited, as this would be considered sufficient information to render a decision
2. State Medicaid policy addresses service/procedure/test/equipment, but does NOT cover member condition in question or provide specific medical necessity criteria for this indication and does not contain relevant clinical information to be instructive to the case/clinical scenario, eviCore guidelines or alternative guidelines, as appropriate, will be utilized and cited
3. State policy exists for service/procedure/test/equipment AND member condition but NO medical necessity criteria exist for this indication. The state policy would still be instructive to the case clinical scenario and Medicaid will be utilized and cited.

4. (Example: Service is requested to address a member condition and the state policy indicates that the service is indicated for this member condition without providing specific criteria regarding under which circumstances the service would be indicated for this condition. This is considered instructive, and the state policy would be applied/cited.)
5. If no clinical information is provided with a request, the above hierarchy is still applied. If there is an applicable state-specific Medicaid policy, the Medicaid policy would be utilized and cited to request clinical information/documentation. If there is no applicable state-specific Medicaid policy, eviCore guidelines or alternative guidelines, as appropriate, will be utilized and cited

Note The scope of this policy is to outline the default order in which policy sources will be used during a delegated medical necessity determination. The Medicaid hierarchy outlined here may be superseded by Plan- and State-specific Hierarchy policies, where applicable, based on eviCore client’s contracts with a state Medicaid entity.

Application and citation of policy

State Medicaid Policy exists	State Medicaid policy addresses service/procedure/test/equipment	State policy addresses member condition and/or is instructive to the case	State Medicaid Policy provides specific medical necessity criteria relevant to service and member condition	Application and Citation of Policy
Y	Y	Y	Y	State Medicaid policy applied and cited
Y	Y	Y	N	State Medicaid policy applied and cited
Y	Y	N	N	eviCore criteria applied and cited
Y	N	N	N	eviCore criteria applied and cited

Medicare Policy

CMS Coverage Hierarchy: Medicare Advantage Medical Policy Development and Application

Medicare Advantage medical policies identify the clinical criteria for determining when medical services are considered 'reasonable and necessary' (medically necessary). Medicare Advantage plans are required by CMS to provide the same medical benefits to Medicare Advantage members as original Medicare.

Medicare Advantage plans must comply with national coverage determinations (NCD), local coverage determinations (LCD), and general coverage and benefit conditions included in traditional Medicare laws. This includes criteria for determining whether an item or service is a benefit available under traditional Medicare. When coverage criteria are not fully established in Medicare statute, regulation, NCD, or LCD, Medicare Advantage organizations may create publicly accessible internal coverage criteria that are based on current evidence in widely used treatment guidelines or clinical literature.

If additional criteria are needed to interpret or supplement generalized provisions within an NCD, LCD or other Medicare coverage policy, or there is flexibility allowed in the NCD/LCD, or there is no applicable NCD, LCD, or LCA (used in concert with an LCD) available to determine medical necessity, then other evidence-based criteria may be applied.

Coverage criteria are not fully established when (42 CFR 422.101(6) (i) :

(i) Coverage criteria not fully established. Coverage criteria are not fully established when:

(A) Additional, unspecified criteria are needed to interpret or supplement general provisions in order to determine medical necessity consistently. The MA organization must demonstrate that the additional criteria provide clinical benefits that are highly likely to outweigh any clinical harms, including from delayed or decreased access to items or services;

(B) NCDs or LCDs include flexibility that explicitly allows for coverage in circumstances beyond the specific indications that are listed in an NCD or LCD; or

(C) There is an absence of any applicable Medicare statutes, regulations, NCDs or LCDs setting forth coverage criteria.

The following hierarchy is used to determine Medicare Advantage Medical Policy:

1. CMS Coverage Manuals or other CMS-Based Resource: Coverage provisions in interpretive manuals are instructions that are used to further define when and under what circumstances items or services may be covered (or not covered)
2. National Coverage Determinations (NCD)
 - a. Local Coverage Determinations (LCD)
 - b. Local Coverage Articles (LCA), when used on conjunction with LCD

3. eviCore's evidence-based guidelines or the appropriate alternative guideline utilized by a program/health plan in place of eviCore's guidelines.
 - a) Rationale supporting the adoption and use of internally developed coverage guidelines: When coverage criteria are not fully established (as defined in 42 CFR 422.101(6) (i)) in Medicare policy, an NCD, or an LCD, CMS allows a Medicare Advantage Organization (MAO) to create and use internally developed coverage criteria. See 'Coverage criteria are not fully established when (42 CFR 422.101(6) (i) above on page 3 for the full definition of 'not fully established'.
 - eviCore will exhaust all traditional Medicare policies, NCDs, and LCDs prior to using internal criteria policies. When an internally created coverage policy is utilized for a specific condition where a Medicare policy, an NCD, or LCD is not fully established, the general provisions supplemented by the internal criteria will include when the specific clinical presentation of the enrollee, for the request under review is not addressed in the Medicare coverage policy; or there are no specific coverage criteria included in a Medicare policy because the policy provides broad provisions, which may be instructive, but are not detailed enough to be used to determine the medical necessity of the request. Additionally, internal coverage policy may be used when Medicare policy includes statements within the policy that allow for coverage beyond what is written in the Medicare policy.
 - Under the guidance outlined above eviCore's evidence-based guidelines or the appropriate alternative guideline utilized by a program/health plan in place of eviCore's guidelines, eviCore may apply internally developed clinical coverage guidelines to the request under review. Each eviCore clinical coverage policy is developed following an objective, evidence-based process based on scientific evidence, generally accepted and current standards of medical practice, and authoritative clinical practice guidelines. Each coverage policy developed and used outlines clinical benefits, addresses any clinical harm, and access to services. In addition, each member's unique clinical situation is considered in conjunction with current CMS guidelines and eviCore clinical coverage policy, as applicable.

Note Where a Medicare Administrative Contractor (MAC) has adopted the Palmetto GBA MoIDX® Program's criteria for the LCDs governing molecular and genomic tests within their jurisdiction, eviCore's Laboratory Management program will follow the MoIDX criteria published by the MACs for those jurisdictions.

Medicare/Medicaid Dual Membership

Hierarchy and Application for dual eligible Medicare/Medicaid

Individuals enrolled in both Medicare and Medicaid are considered to be dually eligible. For individuals with both Medicare and Medicaid, the following hierarchy should be applied.

1. CMS Coverage Manuals

2. National Coverage Determinations (NCD)
3. Local Coverage Determinations (LCD)
4. Local Coverage Articles (LCA) – when used in conjunction with an LCD
5. Medicaid Coverage Policies (if Medicare/Medicaid (MMP) or Medicare/Medicaid Special Needs plans)
6. Evidence based clinical policies (eviCore) or the appropriate alternative guideline utilized by a program/health plan in place of eviCore's guidelines

eviCore Guideline Definitions

Definitions.A

v1.0.2024

Experimental, Investigational, or Unproven

Certain studies, treatments, procedures, or devices may be considered experimental, investigational, or unproven for **any** condition, illness, disease, injury being treated if one of the following is present:

- if there is a paucity of supporting evidence;
- if the evidence has not matured to exhibit improved health parameters;
- if clinical utility has not been demonstrated in any condition; OR
- the study, treatment, procedure, or device lacks a collective opinion of support.

Supporting evidence includes standards that are based on credible scientific evidence published in peer-reviewed medical literature (such as well conducted randomized clinical trials or cohort studies with a sample size of sufficient statistical power) generally recognized by the relevant medical community. Collective opinion of support includes physician specialty society recommendations and the views of physicians practicing in relevant clinical areas when physician specialty society recommendations are not available.

Medically Necessary

Healthcare services or supplies needed to diagnose, treat, or evaluate a condition or prevent an injury, illness, condition or disease that meets accepted standards of medicine based on evidenced-based clinical standards of care based on supporting evidence and/or collective opinion of support that is:

- Clinically appropriate in terms of type, frequency, extent, site, and duration, and considered effective for the individual's illness, injury or disease;
- Clinical utility of the technology, drug, device, treatment or procedure has been demonstrated for a diagnosis, treatment, evaluation or prevention of an illness, condition or disease based on evidence-based clinical standards of care;
- Not more costly than an alternative service or sequence of services that are at least as likely to produce equivalent therapeutic or diagnostic results as to the diagnosis or treatment of a condition;
- Not primarily for the convenience of the individual seeking medical services, health care provider, or other physicians or healthcare providers;
- Supporting evidence and/or collective opinion of support does not demonstrate that there is an alternative that is more appropriate/effective for diagnosis, treatment, or evaluation of a condition.

Supporting evidence includes standards that are based on credible scientific evidence published in peer-reviewed medical literature (such as well conducted randomized

clinical trials or cohort studies with a sample size of sufficient statistical power) generally recognized by the relevant medical community. Collective opinion of support includes physician specialty society recommendations and the views of physicians practicing in relevant clinical areas when physician specialty society recommendations are not available. Determination of medical necessity is based on specific clinical guidelines.

Not Medically Necessary

Certain studies, treatments, procedures, or devices may be considered not medically necessary if there is supporting evidence but one of the following is present:

- Not clinically appropriate in terms of type, frequency, extent, site, and duration, and/or not considered effective for the individual's illness, injury or disease;
- Clinical utility of the technology, drug, device, treatment or procedure has not been demonstrated for a diagnosis, treatment, evaluation or prevention of the specific illness, condition or disease based on evidence-based clinical standards of care;
- More costly than an alternative service or sequence of services that are at least as likely to produce equivalent therapeutic or diagnostic results as to the diagnosis or treatment of a condition;
- Primarily for the convenience of the individual seeking medical services, health care provider, or other physicians or healthcare providers;
- Supporting evidence and/or collective opinion of support demonstrates that there is an alternative that is more appropriate/effective for diagnosis, treatment, or evaluation of a condition

Supporting evidence includes standards that are based on credible scientific evidence published in peer-reviewed medical literature (such as well conducted randomized clinical trials or cohort studies with a sample size of sufficient statistical power) generally recognized by the relevant medical community. Collective opinion of support includes physician specialty society recommendations and the views of physicians practicing in relevant clinical areas when physician specialty society recommendations are not available. Determination of not medically necessary is based on specific clinical guidelines.

Special Considerations for Laboratory Testing

Laboratory-based testing is defined in terms of both the underlying technology used and, the indication for testing (i.e.: syndrome, condition, etc.),. This is due to the ubiquitous use of specific technologies in laboratory medicine.

References

1. <https://www.cigna.com/health-care-providers/coverage-and-claims/policies/medical-necessity-definitions>. Accessed 2023.04.03
2. <https://www.medicare.gov/glossary/m>. Accessed 2023.04.03
3. Per Compliance Internal policy: Clinical Certification of Services – Initial UM 0045:

- a. Experimental/Investigational: The use of a technology, drug, device, treatment, or procedure that has not been proven or recognized as having proven benefit in clinical medicine for any condition, illness, disease, or injury being treated.
- b. Medical Necessity: Refers to services or supplies for diagnosing, evaluating, treating or preventing an injury, illness, condition or disease, based on evidence-based clinical standards of care. Medically necessary services are accepted health care services and supplies provided by health care entities, appropriate to evaluation and treatment of a disease, condition, illness or injury and consistent with the applicable standard of care. Determination of medical necessity is based on specific clinical guidelines. (NCQA 2022 Standards; CMS; American College of Medical Quality)

Table of Contents

Guideline

Guideline Development (Preface-1)

Benefits, Coverage Policies, and Eligibility Issues (Preface-2)

Clinical Information (Preface-3)

Coding Issues (Preface-4)

Whole-Body Imaging (Preface-5)

References (Preface-6)

Copyright Information (Preface-7)

Trademarks (Preface-8)

Guideline Development (Preface-1)

Guideline

Guideline Development (Preface-1.1)

Guideline Development (Preface-1.1)

PRF.GG.0001.1.A

v2.0.2024

- The eviCore healthcare (eviCore) evidence-based, proprietary clinical guidelines evaluate a range of advanced imaging and procedures, including NM, US, CT, MRI, PET, Radiation Oncology, Sleep Studies, Gastrointestinal Endoscopy, as well as Cardiac, musculoskeletal and Spine interventions.
- eviCore reserves the right to change and update the guidelines. The guidelines undergo a formal review annually. eviCore's guidelines are based on current evidence supported by major national and international association and society guidelines and criteria, peer-reviewed literature, major treatises as well as, input from health plans, and practicing academic and community-based physicians.
- These guidelines are not intended to supersede or replace sound medical judgment, but instead, should facilitate the identification of the most appropriate imaging or other designated procedure given the individual's clinical condition. These guidelines are written to cover medical conditions as experienced by the majority of individuals. However, these guidelines may not be applicable in certain clinical circumstances, and physician judgment can override the guidelines.
- These guidelines provide evidence-based, clinical benefits with a focus on health care quality and patient safety.
- Clinical decisions, including treatment decisions, are the responsibility of the individual and his/her provider. Clinicians are expected to use independent medical judgment, which takes into account the clinical circumstances to determine individual management decisions.
- eviCore supports the Choosing Wisely initiative (<https://www.choosingwisely.org/>) by the American Board of Internal Medicine (ABIM) Foundation and many national physician organizations, to reduce the overuse of diagnostic tests that are low value, no value, or whose risks are greater than the benefits.

Benefits, Coverage Policies, and Eligibility Issues (Preface-2)

Guideline

Benefits, Coverage Policies, and Eligibility Issues (Preface-2.1)
References (Preface-2)

Benefits, Coverage Policies, and Eligibility Issues (Preface-2.1)

PRF.BC.0002.1.U

v2.0.2024

Medicare Coverage Policies

- See eviCore's Medicaid and Medicare Hierarchy and Application

Investigational and Experimental Studies

- See eviCore's Guideline Definitions

Clinical and Research Trials

- Similar to investigational and experimental studies, clinical trial imaging requests will be considered to determine whether they meet Health Plan coverage and eviCore's evidence-based guidelines.
- Imaging studies which are inconsistent with established clinical standards, or are requested for data collection and not used in direct clinical management are not supported.³

Legislative Mandate

- State and federal legislations may need to be considered in the review of advanced imaging requests. For example:
 - Various State and Federal Breast Density Laws
 - Texas HB 1290 Coronary Calcium CT Law

References (Preface-2)

v2.0.2024

1. Prospective Payment Systems - General Information. CMS.
[https://www.cms.gov/medicare/payment/prospective-payment-systems#:~:text=A%20Prospective%20Payment%20System%20\(PPS,on%20a%20predetermined%2C%20fixed%20amount.](https://www.cms.gov/medicare/payment/prospective-payment-systems#:~:text=A%20Prospective%20Payment%20System%20(PPS,on%20a%20predetermined%2C%20fixed%20amount.)
2. Medicare Coverage With Evidence Development: A Policy-Making Tool in Evolution. *J Oncol Pract.* 2007;3(6):296-301. doi: 10.1200/jop.0763501.
3. Coverage of Clinical Trials under the Patient Protection and Affordable Care Act; 42 U.S.C.A. § 300gg-8.

Clinical Information (Preface-3)

Guideline

Clinical Information (Preface-3.1)

References (Preface-3)

Clinical Information (Preface-3.1)

PRF.CL.0003.1.A
v2.0.2024

Clinical Documentation and Age Considerations

- eviCore guidelines use an evidence-based approach to determine the most appropriate procedure for each individual, at the most appropriate time in the diagnostic and treatment cycle. eviCore guidelines are framed by:
 - Clinical presentation of the individual, rather than the studies requested
 - Adequate clinical information that must be submitted to eviCore in order to establish medical necessity for advanced imaging or other designated procedures includes, but is not limited to the following:
 - Pertinent clinical evaluation should include a recent detailed history, physical examination²⁰ since the onset or change in symptoms, and/or laboratory and prior imaging studies.
 - Condition-specific guideline sections may describe additional clinical information which is required for a pertinent clinical evaluation.
 - The Spine and Musculoskeletal guidelines require x-ray studies from when the current episode of symptoms has started or changed; x-ray imaging does not have to be within the past 60 days.
 - Advanced imaging or other designated procedures should not be ordered prior to clinical evaluation of an individual by the physician treating the individual. This may include referral to a consultant specialist who will make further treatment decisions.
 - Other meaningful technological contact (telehealth visit, telephone or video call, electronic mail or messaging) since the onset or change in symptoms by an established individual can serve as a pertinent clinical evaluation.
 - Some conditions may require a face-to-face evaluation as discussed in the applicable condition-specific guideline sections.
 - A recent clinical evaluation may be unnecessary if the individual is undergoing a guideline-supported, scheduled follow-up imaging or other designated procedural evaluation. Exceptions due to routine surveillance indications are addressed in the applicable condition-specific guideline sections.
 - eviCore's evidence-based approach to determine the most appropriate procedure for each individual requires submission of medical records pertinent to the requested imaging or other designated procedures.
- Many conditions affecting the pediatric population are different diagnoses than those occurring in the adult population. For those diseases which occur in both pediatric and adult populations, minor differences may exist in management due to individual age, comorbidities, and differences in disease natural history between children and adults.

- Individuals who are 18 years old or younger¹⁹ should be imaged according to the Pediatric Imaging Guidelines if discussed in the condition-specific guideline sections. Any conditions not specifically discussed in the Pediatric Imaging Guidelines should be imaged according to the General Imaging Guidelines. Individuals who are >18 years old should be imaged according to the General Imaging Guidelines, except where directed otherwise by a specific guideline section.
- The terms “male” and “female” used in these guidelines refer to anatomic-specific diseases and disease predispositions associated with the individual's sex assigned at birth rather than their gender identity. It should be noted that gender identity and anatomic-specific diseases as well as disease predispositions are not always linked. As such, these guidelines should be applied to the individual's corresponding known or suspected anatomic-specific disease or disease predisposition. At eviCore, we believe that it is important to understand how all individuals, including those who are gender-diverse, choose to identify themselves. To ensure that gender-diverse individuals are treated with respect and that decisions impacting their healthcare are made correctly and with sensitivity, eviCore recognizes all individuals with the following gender marker options: Male, Female, Transgender Male, Transgender Female, “X”, and “Not Specified.”

General Imaging Information

- “Standard” or “conventional” imaging is most often performed in the initial and subsequent evaluations of malignancy. Standard or conventional imaging includes plain film, CT, MRI, or US.
 - Often, further advanced imaging is needed when initial imaging, such as ultrasound, CT, or MRI does not answer the clinical question. Uncertain, indeterminate, inconclusive, or equivocal may describe these situations.
- Appropriate use of contrast is a very important component of evidence-based advanced imaging use.
 - The appropriate levels of contrast for an examination (i.e., without contrast, with contrast, without and with contrast) is determined by the evidence-based guidance reflected in the condition-specific guideline sections.
 - If, during the performance of a non-contrast imaging study, there is the unexpected need to use contrast in order to evaluate a possible abnormality, then that is appropriate.¹

Ultrasound

- Diagnostic ultrasound uses high-frequency sound waves to evaluate soft tissue structures and vascular structures utilizing grey scale and Doppler techniques.
- Ultrasound allows for dynamic real-time imaging at the bedside.
 - Ultrasound is limited in areas where there is dense bone or other calcification.
 - Ultrasound also has a relatively limited imaging window so may be of limited value in evaluating very large abnormalities.
 - In general, ultrasound is highly operator-dependent, and proper training and experience are required to perform consistent, high-quality evaluations.

- Indications for ultrasound may include, but are not limited to, the following:
 - Obstetric and gynecologic imaging
 - Soft tissue and visceral imaging of the chest, abdomen, pelvis, and extremities
 - Brain and spine imaging when not obscured by dense bony structures
 - Vascular imaging when not obscured by dense bony structures
 - Procedural guidance when not obscured by dense bony structures
 - Initial evaluation of ill-defined soft tissue masses or fullness and differentiating adenopathy from mass or cyst. Prior to advanced imaging, ultrasound can be very beneficial in selecting the proper modality, body area, image sequences, and contrast level that will provide the most definitive information for the individual.
- More specific guidance for ultrasound usage, including exceptions to this general guidance, can be found throughout the condition-specific guidelines.

Computed Tomography (CT)

- The AMA CPT® manual does not describe nor assign any minimum or maximum number of sequences for any CT study. CT imaging protocols are often influenced by the individual's clinical situation and additional sequences are not uncommon. There are numerous CT protocols that may be performed to evaluate specific clinical questions, and this technology is constantly undergoing development.
- CT utilizes ionizing radiation to create cross-sectional and volumetric images of the body.
 - Advantages over ultrasound include a much larger field of view and faster completion time in general. Disadvantages compared to ultrasound include lack of portability and exposure to ionizing radiation.
 - Advantages over MRI include faster imaging and a more spacious scanner area limiting claustrophobia. Disadvantages compared to MRI include decreased soft tissue definition, especially with non-contrast imaging, and exposure to ionizing radiation.
- CT can be performed without, with, or without and with intravenous (IV) contrast depending on the clinical indication and body area.
 - In general, non-contrast imaging is appropriate for evaluating structures with significant tissue density differences such as lung parenchyma and bony structures, or when there is a contraindication to contrast.
 - In general, CT with contrast is the most common level of contrast and can be used when there is need for improved vascular or soft tissue resolution, including better characterization of known or suspected malignancy as well as infectious and inflammatory conditions.
 - CT without and with contrast has a limited role as the risks of doubling the ionizing radiation exposure rarely outweigh the benefits of multiphasic imaging, though there are some exceptions which include, but are not limited to, the following:
 - Characterization of a mass
 - Characterization of arterial and venous anatomy

- CT with contrast may be used to better characterize findings on a very recent (within two weeks) inconclusive non-contrast CT where the guidelines would support CT without and with contrast.
- More specific guidance for CT contrast usage, including exceptions to this general guidance, can be found throughout the condition-specific guidelines.
- Shellfish allergy:
 - It is commonly assumed that an allergy to shellfish indicates iodine allergy, and that this implies an allergy to iodinated contrast media used with CT. However, this is NOT true. Shellfish allergy is due to tropomyosins. Iodine plays no role in these allergic reactions. Allergies to shellfish do not increase the risk of reaction to iodinated contrast media any more than that of other allergens.¹
- Enteric contrast (oral or rectal) is sometimes used in abdominal imaging. There is no specific CPT[®] code which refers to enteric contrast.
- The appropriate contrast level and anatomic region in CT imaging is specific to the clinical indication, as listed in the condition-specific guideline sections.
- CT should not be used to replace MRI in an attempt to avoid sedation unless it is listed as a recommended study the appropriate condition-specific guideline.
- There are significant potential adverse effects associated with the use of iodinated contrast media. These include hypersensitivity reactions, thyroid dysfunction, and contrast-induced nephropathy (CIN). Individuals with impaired renal function are at increased risk for CIN.²
- Both contrast CT and MRI may be considered to have the same risk profile with renal failure (GFR <30 mL/min).
- The use of CT contrast should proceed with caution in pregnant and breastfeeding individuals. There is a theoretical risk of contrast toxicity to the fetal and infant thyroid. The procedure can be performed if the specific need for that contrast-enhanced procedure outweighs risk to the fetus. Breastfeeding individuals may reduce this risk by choosing to pump and discard breast milk for 12-24 hours after the contrast injection.
- CT without contrast may be appropriate if clinical criteria for CT with contrast are met AND the individual has:
 - Elevated blood urea nitrogen (BUN) and/or creatinine
 - Renal insufficiency
 - Allergies to iodinated contrast
 - Thyroid disease which could be treated with I-131
 - Diabetes
 - Very elderly
 - Urgent or emergent settings due to availability
 - Trauma
- CT is superior to other imaging modalities in certain conditions including, but not limited to, the following:
 - Screening following trauma
 - Imaging pulmonary disease

- Imaging abdominal and pelvic viscera
- Imaging of complex fractures
- Evaluation of inconclusive findings on Ultrasound or MRI, or if there is a contraindication to MRI
- More specific guidance for CT usage, including exceptions to this general guidance, can be found throughout the condition-specific guidelines.

Magnetic Resonance Imaging (MRI)

- The AMA CPT® manual does not describe nor assign any minimum or maximum number of sequences for any MRI study. MRI protocols are often influenced by the individual's clinical situation and additional sequences are not uncommon. There are numerous MRI sequences that may be performed to evaluate specific clinical questions, and this technology is constantly undergoing development.
- Magnetic Resonance Imaging (MRI) utilizes the interaction between the intrinsic radiofrequency of certain Molecules in the body (hydrogen in most cases) and a strong external magnetic field.
 - MRI is often superior for advanced imaging of soft tissues and can also define physiological processes in some instances (e.g., edema, loss of circulation [AVN], and increased vascularity [tumors]).
 - MRI does not use ionizing radiation, and even non-contrast images have much higher soft tissue definition than CT or Ultrasound.
 - MRI typically takes much longer than either CT or Ultrasound, and for some individuals may require sedation. It is also much more sensitive to individual motion that can degrade image quality than either CT or Ultrasound.
- MRI Breast and MRI Chest are not interchangeable, as they focus detailed sequences on different adjacent body parts.
- MRI may be utilized either as the primary advanced imaging modality, or when further definition is needed based on CT or ultrasound imaging.
- Most orthopedic and dental implants are not magnetic. These include hip and knee replacements; plates, screws, and rods used to treat fractures; and cavity fillings. Yet, all of these metal implants can distort the MRI image if near the part of the body being scanned.
 - Other implants, however, may have contraindications to MRI. These include the following:
 - Pacemakers
 - ICD or heart valves
 - Metal implants in the brain
 - Metal implants in the eyes or ears
 - Infusion catheters and bullets or shrapnel
 - CT can therefore be an alternative study to MRI in these scenarios.
- The contrast level and anatomic region in MRI imaging is specific to the clinical indication, as listed in the specific guideline sections.

- MRI utilizing Xenon Xe 129 for contrast is considered investigational and experimental at this time. MRI with or with and without contrast in these guidelines refers to MRI utilizing gadolinium for contrast.
- MRI is commonly performed without, without and with contrast.
 - Non-contrast imaging offers excellent tissue definition.
 - Imaging without and with contrast is commonly used when needed to better characterize tissue perfusion and vascularization.
 - Most contrast is gadolinium based and causes T2 brightening of the vascular and extracellular spaces.
 - Some specialized gadolinium and non-gadolinium contrast agents are available, and most commonly used for characterizing liver lesions.
 - MRI with contrast only is rarely appropriate and is usually used to better characterize findings on a recent inconclusive non-contrast MRI, commonly called a completion study.
 - MRI contrast is contraindicated in pregnant individuals .
 - More specific guidance for MRI contrast usage, including exceptions to this general guidance, can be found throughout the condition-specific guidelines.
- MRI may be preferred in individuals with renal failure and in individuals allergic to intravenous CT contrast.
 - Both contrast CT and MRI may be considered to have the same risk profile with renal failure (GFR <30 mL/min).²
 - Gadolinium can cause Nephrogenic Systemic Fibrosis (NSF). The greater the exposure to gadolinium in individuals with a low GFR (especially if on dialysis), the greater the chance of individuals developing NSF.
 - Multiple studies have demonstrated potential for gadolinium deposition following the use of gadolinium-based contrast agents (GBCAs) for MRI studies.^{3,4,5,6,7} The U.S. Food and Drug Administration (FDA) has noted that there is currently no evidence to suggest that gadolinium retention in the brain is harmful and restricting gadolinium-based contrast agents (GBCAs) use is not warranted at this time. It has been recommended that GBCA use should be limited to circumstances in which additional information provided by the contrast agent is necessary and the necessity of repetitive MRIs with GBCAs should be assessed.⁸
- A CT may be approved in place of an MRI when clinical criteria are met for MRI AND there is a contraindication to having an MRI (pacemaker, ICD, insulin pump, neurostimulator, etc.).
 - When replacing MRI with CT, contrast level matching should occur as follows:
 - MRI without contrast → CT without contrast
 - MRI without and with contrast → CT with contrast or CT without and with contrast
- The following situations may impact the appropriateness for MRI and or MR contrast:
 - Caution should be taken in the use of gadolinium in individuals with renal failure.

- The use of gadolinium contrast agents is contraindicated during pregnancy unless the specific need for that procedure outweighs risk to the fetus.
- MRI can be performed for non-ferromagnetic body metals (i.e., titanium), although some imaging facilities will consider it contraindicated if recent surgery, regardless of the metal type.
- MRI should not be used as a replacement for CT for the sole reason of avoidance of ionizing radiation when MRI is not supported in the condition-based guidelines, since it does not solve the problem of overutilization.
- MRI is superior to other imaging modalities in certain conditions including, but not limited to, the following:
 - Imaging the brain and spinal cord
 - Characterizing visceral and musculoskeletal soft tissue masses
 - Evaluating musculoskeletal soft tissues including ligaments and tendons
 - Evaluating inconclusive findings on ultrasound or CT
 - Individuals who are pregnant or have high radiation sensitivity
 - Suspicion, diagnosis, or surveillance of infections
- More specific guidance for MRI usage, including exceptions to this general guidance, can be found throughout the condition-specific guidelines.

Positron Emission Tomography (PET)

- PET is a nuclear medicine study that uses a positron emitting radiotracer to create cross-sectional and volumetric images based on tissue metabolism.
- Conventional imaging (frequently CT, sometimes MRI or bone scan) of the affected area(s) drives much of initial and restaging and surveillance imaging for malignancy and other chronic conditions. PET is not indicated for surveillance imaging unless specifically stated in the condition-specific guideline sections.
- PET/MRI is generally not supported, see **PET-MRI (Preface-5.3)**.
- PET is rarely performed as a single modality, but is typically performed as a combined PET/CT.
 - The unbundling of PET/CT into separate PET and diagnostic CT CPT® codes is not supported, because PET/CT is done as a single study.
- PET/CT lacks the tissue definition of CT or MRI, but is fairly specific for metabolic activity based on the radiotracer used.
- Indications for PET/CT may include the following:
 - Oncologic Imaging for evaluation of tumor metabolic activity
 - Cardiac Imaging for evaluation of myocardial metabolic activity
 - Brain Imaging for evaluation of metabolic activity for procedural planning
- More specific guidance for PET usage, including exceptions to this general guidance, can be found throughout the condition-specific guidelines.

Overutilization of Advanced Imaging

- A number of recent reports describe overutilization in many areas of advanced imaging and other procedures, which may include the following:

- High-level testing without consideration of less invasive, lower cost options which may adequately address the clinical question at hand
- Excessive radiation and costs with unnecessary testing
- Defensive medical practice
- CT without and with contrast (so called “double contrast studies”) requests, which have few current indications
- MRI requested in place of CT to avoid radiation without considering the primary indication for imaging
- Adult CT settings and protocols used for smaller people and children
- Unnecessary imaging procedures when the same or similar studies have already been conducted
- A review of the imaging or other relevant procedural histories of all individuals presenting for studies has been recognized as one of the more important processes that can be significantly improved. By recognizing that a duplicate or questionably indicated examination has been ordered for individuals, it may be possible to avoid exposing them to unnecessary risks.^{9,10} To avoid these unnecessary risks, the precautions below should be considered:
 - The results of initial diagnostic tests or radiologic studies to narrow the differential diagnosis should be obtained prior to performing further tests or radiologic studies.
 - The clinical history should include a potential indication such as a known or suspected abnormality involving the body part for which the imaging study is being requested. These potential indications are addressed in greater detail within the applicable guidelines.
 - The results of the requested imaging procedures should be expected to have an impact on individual management or treatment decisions.
 - Repeat imaging studies are not generally necessary unless there is evidence of disease progression, recurrence of disease, and/or the repeat imaging will affect an individual’s clinical management.
- Pre-operative imaging/pre-surgical planning imaging/pre-procedure imaging is considered not medically necessary if the surgery/procedure is not considered medically necessary. Once the procedure has been approved or if the procedure does not require prior authorization, the appropriate pre-procedural imaging may be approved.

References (Preface-3)

v2.0.2024

1. Bettmann MA. Frequently Asked Questions: Iodinated Contrast Agents. *RadioGraphics*. 2004;24(suppl_1):S3-S10. doi: 10.1148/rg.24si045519.
2. Andreucci M, Solomon R, Tasanarong A. Side Effects of Radiographic Contrast Media: Pathogenesis, Risk Factors, and Prevention. *BioMed Res Int*. 2014;2014:1-20. doi: 10.1155/2014/741018.
3. McDonald RJ, McDonald JS, Kallmes DF, et al. Intracranial Gadolinium Deposition after Contrast-enhanced MR Imaging. *Radiology*. 2015;275(3):772-782. doi: 10.1148/radiol.15150025.
4. Kanda T, Ishii K, Kawaguchi H, Kitajima K, Takenaka D. High Signal Intensity in the Dentate Nucleus and Globus Pallidus on Unenhanced T1-weighted MR Images: Relationship with Increasing Cumulative Dose of a Gadolinium-based Contrast Material. *Radiology*. 2014;270(3):834-841. doi: 10.1148/radiol.13131669.
5. Olchow C, Cebulski K, Łasecki M, et al. The presence of the gadolinium-based contrast agent depositions in the brain and symptoms of gadolinium neurotoxicity - A systematic review. Mohapatra S, ed. *PLOS ONE*. 2017;12(2):e0171704. doi: 10.1371/journal.pone.0171704.
6. Ramalho J, Castillo M, AlObaidy M, et al. High Signal Intensity in Globus Pallidus and Dentate Nucleus on Unenhanced T1-weighted MR Images: Evaluation of Two Linear Gadolinium-based Contrast Agents. *Radiology*. 2015;276(3):836-844. doi:10.1148/radiol.2015150872.
7. Radbruch A, Weberling LD, Kieslich PJ, et al. Intraindividual Analysis of Signal Intensity Changes in the Dentate Nucleus After Consecutive Serial Applications of Linear and Macrocyclic Gadolinium-Based Contrast Agents. *Invest Radiol*. 2016;51(11):683-690. doi: 10.1097/rli.0000000000000308.
8. FDA Warns That Gadolinium-Based Contrast Agents (GBCAs) Are Retained in the Body; Requires New Class Warnings. <https://www.fda.gov/media/109825/download>.
9. Amis ES, Butler PF, Applegate KE, et al. American College of Radiology White Paper on Radiation Dose in Medicine. *J Am Coll Radiol*. 2007;4(5):272-284. doi: 10.1016/j.jacr.2007.03.002.
10. Powell AC, Long JW, Kren EM, Gupta AK, Levin DC. Evaluation of a Program for Improving Advanced Imaging Interpretation. *J Patient Saf*. 2019;15(1):69-75. doi: 10.1097/PTS.000000000000034.5.
11. FDA. White Paper: Initiative to Reduce Unnecessary Radiation Exposure from Medical Imaging. Page Last Updated: 06/14/2019. <https://www.fda.gov/Radiation-EmittingProducts/RadiationSafety/RadiationDoseReduction/ucm199994.htm>.
12. Update on FDA approach to safety issue of gadolinium retention after administration of gadolinium-based contrast agents. <https://www.fda.gov/media/116492/download>.
13. Blumfield E, Swenson DW, Iyer RS, Stanescu AL. Gadolinium-based contrast agents — review of recent literature on magnetic resonance imaging signal intensity changes and tissue deposits, with emphasis on pediatric patients. *Pediatr Radiol*. 2019;49(4):448-457. doi: 10.1007/s00247-018-4304-8.
14. American College of Radiology. ACR – SPR – SRU Parameter for the Performing and Interpreting Diagnostic Ultrasound Examinations. Revised 2017. (Resolution 32). Available at: <https://www.acr.org/-/media/ACR/Files/Practice-Parameters/US-Perf-Interpret.pdf>.
15. American College of Radiology. ACR–SPR Practice Parameter for Performing FDG-PET/CT in Oncology. Revised 2021. (Resolution 20). Available at: <https://www.acr.org/-/media/ACR/Files/Practice-Parameters/FDG-PET-CT.pdf>.
16. American College of Radiology. ACR PRACTICE Practice Parameter for Performing and Interpreting Magnetic Resonance Imaging (MRI). Revised 2017. (Resolution 10). Available at: <https://www.acr.org/-/media/ACR/Files/Practice-Parameters/MR-Perf-Interpret.pdf>.
17. American College of Radiology. ACR Practice Parameter for Performing and Interpreting Diagnostic Computed Tomography (CT). Revised 2017. (Resolution 22). Available at: <https://www.acr.org/-/media/ACR/Files/Practice-Parameters/CT-Perf-Interpret.pdf>.
18. Lohrke J, Frenzel T, Endrikat J, et al. 25 Years of Contrast-Enhanced MRI: Developments, Current Challenges and Future Perspectives. *Adv Ther*. 2016;33(1):1-28. doi: 10.1007/s12325-015-0275-4.
19. Implementation Guide: Medicaid State Plan Eligibility Eligibility Groups Mandatory Coverage Infants and Children under Age 19. Available at: <https://www.hhs.gov/guidance/document/implementation-guide-medicaid-state-plan-eligibility-eligibility-groups-aeu-mandatory-2>.
20. History and Physicals - Understanding the Requirements. Available at: <https://www.jointcommission.org/standards/standard-faqs/hospital-and-hospital-clinics/provision-of-care-treatment-and-services-pc/000002272/>.
21. Mammarrappallil JG, Rankine L, Wild JM, Driehuis B. New Developments in Imaging Idiopathic Pulmonary Fibrosis With Hyperpolarized Xenon Magnetic Resonance Imaging. *J Thorac Imaging*. 2019;34(2):136-150. doi: 10.1097/rti.0000000000000392.
22. Wang JM, Robertson SH, Wang Z, et al. Using hyperpolarized 129Xe MRI to quantify regional gas transfer in idiopathic pulmonary fibrosis. *Thorax*. 2017;73(1):21-28. doi: 10.1136/thoraxjnl-2017-210070.

Coding Issues (Preface-4)

Guideline

- 3D Rendering (Preface-4.1)
- CT-, MR-, or Ultrasound-Guided Procedures (Preface-4.2)
- Unlisted Procedures/Therapy Treatment Planning (Preface-4.3)
- Unilateral Versus Bilateral Breast MRI (Preface-4.4)
- CPT® 76380 Limited or Follow-up CT (Preface-4.5)
- SPECT/CT Imaging (Preface-4.6)
- CPT® 76140 Interpretation of an Outside Study (Preface-4.7)
- Quantitative MR Analysis of Tissue Composition (Preface-4.8)
- HCPCS Codes (Preface-4.9)
- References (Preface-4)

3D Rendering (Preface-4.1)

PRF.CD.0004.1.U

v2.0.2024

CPT® 76376 and CPT® 76377:

- Both codes require concurrent supervision of the image post-processing 3D manipulation of the volumetric data set and image rendering.
 - Concurrent supervision is defined as active physician participation in and monitoring of the reconstruction process including design of the anatomic region that is to be reconstructed; determination of the tissue types and actual structures to be displayed (e.g., bone, organs, and vessels); determination of the images or cine loops that are to be archived; and monitoring and adjustment of the 3D work product. The American College of Radiology (ACR) recommends that it is best to document the physician's supervision or participation in the 3D reconstruction of images.
- These two codes differ in the need for and use of an independent workstation for post-processing.
 - CPT® 76376 reports procedures not requiring image post-processing on an independent workstation.
 - CPT® 76377 reports procedures that require image post-processing on an independent workstation.
- These 3D rendering codes should not be used for 2D reformatting.
- Two-dimensional reconstruction (e.g., reformatting an axial scan into the coronal plane) is now included in all cross-sectional imaging base codes and is not separately reimbursable.
- The codes used to report 3D rendering for ultrasound and echocardiography are also used to report the 3D post processing work on CT, MRI, and other tomographic modalities.
- Providers may be required to obtain prior authorization on these 3D codes even if prior authorization is not required for the echocardiography and/or ultrasound procedure codes. It may appear that eviCore pre-authorizes echocardiography and/or ultrasound when, in fact, it may only be the 3D code that needs the prior authorization.
- CPT® codes for 3D rendering should not be billed in conjunction with computer-aided detection (CAD), MRA, CTA, nuclear medicine SPECT studies, PET, PET/CT, Mammogram, MRI Breast, US Breast, CT Colonography (virtual colonoscopy), Cardiac MRI, Cardiac CT, or Coronary CTA studies.
- CPT® 76377 (3D rendering requiring image post-processing on an independent workstation) or CPT® 76376 (3D rendering not requiring image post-processing on an independent workstation) can be considered in the following clinical scenarios:
 - Bony conditions:
 - Evaluation of congenital skull abnormalities in newborns, infants, and toddlers (usually for pre-operative planning)

- Complex fractures (comminuted or displaced)/dislocations of any joint (for pre-operative planning when conventional imaging is insufficient)
- Spine fractures, pelvic/acetabulum fractures, intra-articular fractures (for pre-operative planning when conventional imaging is insufficient)
- Pre-operative planning for other complex surgical cases
- Complex facial fractures
- Pre-operative planning for other complex surgical cases
- Cerebral angiography
- Pelvis conditions:
 - Uterine intra-cavitary lesion when initial US is equivocal: See **Abnormal Uterine Bleeding (AUB) (PV-2.1)** and **Leiomyoma/Uterine Fibroids (PV-12.1)** in the Pelvis Imaging Guidelines.
 - Hydrosalpinxes or peritoneal cysts when initial US is indeterminate: See **Complex Adnexal Masses (PV-5.3)** in the Pelvis Imaging Guidelines.
 - Lost IUD (inability to feel or see IUD string) with initial US: See **Intrauterine Device (PV-10.1)** in the Pelvis Imaging Guidelines.
 - Uterine anomalies with initial US: See **Uterine Anomalies (PV-14.1)** in the Pelvis Imaging Guidelines.
 - Infertility: See **Initial Infertility Evaluation, Female (PV-9.1)** in the Pelvis Imaging Guidelines.
- Abdomen conditions:
 - CT Urogram: See **Hematuria and Hydronephrosis (AB-39)** in the Abdomen Imaging Guidelines.
 - MRCP: See **MR Cholangiopancreatography (MRCP) (AB-27)** in the Abdomen Imaging Guidelines.

CT-, MR-, or Ultrasound-Guided Procedures (Preface-4.2)

PRF.CD.0004.2.A

v2.0.2024

- CT-, MR-, and Ultrasound-guidance procedure codes contain all of the imaging necessary to guide a needle or catheter. It is inappropriate to routinely bill a diagnostic procedure code in conjunction with a guidance procedure code.
- Imaging studies performed as part of a CT-, MR-, or Ultrasound-guided procedure should be reported using the CPT® codes in the following table:

TABLE: Imaging Guidance Procedure Codes

CPT®	Description
19085	Biopsy, breast, with placement of breast localization device(s), when performed, and imaging of the biopsy specimen, when performed, percutaneous; first lesion, including MR guidance
19086	Biopsy, breast, with placement of breast localization device(s), when performed, and imaging of the biopsy specimen, when performed, percutaneous; each additional lesion, including MR guidance
75989	Imaging guidance for percutaneous drainage with placement of catheter (all modalities)
76942	Ultrasonic guidance for needle placement
77011	CT guidance for stereotactic localization
77012	CT guidance for needle placement
77013	CT guidance for, and monitoring of parenchymal tissue ablation
77021	MR guidance for needle placement
77022	MR guidance for, and monitoring of parenchymal tissue ablation

CPT® 19085 and CPT® 19086

- The proper way to bill an MRI-guided breast biopsy is CPT® 19085 (Biopsy, breast, with placement of breast localization device(s), when performed, and imaging of the biopsy specimen, when performed, percutaneous; first lesion, including MR guidance). Additional lesions should be billed using CPT® 19086.
 - CPT® 77021 (MR guidance for needle placement) is not an appropriate code for a breast biopsy.

CPT® 75989

- This code is used to report imaging guidance for a percutaneous drainage procedure in which a catheter is left in place.

- This code can be used to report whether the drainage catheter is placed under fluoroscopy, Ultrasound-, CT-, or MR-guidance modality.

CPT® 77011

- A stereotactic CT localization scan is frequently obtained prior to sinus surgery. The dataset is then loaded into the navigational workstation in the operating room for use during the surgical procedure. The information provides exact positioning of surgical instruments with regard to the individual's 3D CT images.³
- In most cases, the pre-operative CT is a technical-only service that does not require interpretation by a radiologist.
 - The imaging facility should report CPT® 77011 when performing a scan not requiring interpretation by a radiologist.
 - If a diagnostic scan is performed and interpreted by a radiologist, the appropriate diagnostic CT code (e.g., CPT® 70486) should be used.
 - It is not appropriate to report both CPT® 70486 and CPT® 77011 for the same CT stereotactic localization imaging session.
 - 3D Rendering (CPT® 76376 or CPT® 76377) should not be reported in conjunction with CPT® 77011 (or CPT® 70486 if used). The procedure inherently generates a 3D dataset.

CPT® 77012 (CT) and CPT® 77021 (MR)

- These codes are used to report imaging guidance for needle placement during biopsy, aspiration, and other percutaneous procedures.
- They represent the radiological supervision and interpretation of the procedure and are often billed in conjunction with surgical procedure codes.
 - For example, CPT® 77012 is reported when CT guidance is used to place the needle for a conventional arthrogram.
 - Only codes representing percutaneous surgical procedures should be billed with CPT® 77012 and CPT® 77021. It is inappropriate to use with surgical codes for open, excisional, or incisional procedures.
 - **CPT® 77021** (MR guidance for needle placement) is not an appropriate code for breast biopsy.
 - CPT® 19085 would be appropriate for the first breast biopsy site and CPT® 19086 would be appropriate for additional concurrent biopsies.

CPT® 77013 (CT) and CPT® 77022 (MR)

- These codes include the initial guidance to direct a needle electrode to the tumor(s), monitoring for needle electrode repositioning within the lesion, and as necessary for multiple ablations to coagulate the lesion and confirmation of satisfactory coagulative necrosis of the lesion(s) and comparison to pre-ablation images.
 - **NOTE:** CPT® 77013 should only be used for non-bone ablation procedures.
 - CPT® 20982 includes CT guidance for bone tumor ablations.

- Only codes representing percutaneous surgical procedures should be billed with CPT® 77013 and CPT® 77022. It is inappropriate to use with surgical codes for open, excisional, or incisional procedures.
- CPT® 77012 and CPT® 77021 (as well as guidance codes CPT® 76942 [US] and CPT® 77002 - CPT® 77003 [fluoroscopy]) describe radiologic guidance by different modalities.
 - Only one unit of any of these codes should be reported per individual encounter (date of service). The unit of service is considered to be the individual encounter, not the number of lesions, aspirations, biopsies, injections, or localizations.

Unlisted Procedures/Therapy Treatment Planning (Preface-4.3)

PRF.CD.0004.3.U

v2.0.2024

CPT [®]	Description
78999	Unlisted procedure, diagnostic nuclear medicine
76498	Unlisted MR procedure (e.g., diagnostic or interventional)
76497	Unlisted CT procedure (e.g., diagnostic or interventional)

- These unlisted codes should be reported whenever a diagnostic or interventional CT or MR study is performed in which an appropriate anatomic site-specific code is not available.
 - A Category III code that describes the procedure performed must be reported rather than an unlisted code if one is available.
- CPT[®] 76497 or CPT[®] 76498 (Unlisted CT or MRI procedure) can be considered in the following clinical scenarios:
 - Studies done for navigation and planning for neurosurgical procedures (i.e. Stealth or Brain Lab Imaging)^{1,2}
 - Custom joint arthroplasty planning (not as an alternative recommendation): See **Osteoarthritis (MS-12.1)** in the Musculoskeletal Imaging Guidelines.
 - Any procedure/surgical planning if thinner cuts or different positional acquisition (than those on the completed diagnostic study) are needed. These could include navigational bronchoscopy. See **Navigational Bronchoscopy (CH-1.7)** in the Chest Imaging Guidelines

Therapy Treatment Planning

- Radiation Therapy Treatment Planning: See **Unlisted Procedure Codes in Oncology (ONC-1.5)** In the Oncology Imaging Guidelines

Unilateral Versus Bilateral Breast MRI (Preface-4.4)

PRF.CD.0004.4.A

v2.0.2024

- Diagnostic MRI of both breasts should be coded as CPT® 77049 regardless of whether both breasts are imaged simultaneously or whether unilateral breast MRI is performed in two separate imaging sessions.

CPT® 76380 Limited or Follow-up CT (Preface-4.5)

PRF.CD.0004.5.A

v2.0.2024

- CPT® 76380 describes a limited or follow-up CT scan. The code is used to report any CT scan, for any given area of the body, in which the work of a full diagnostic code is not performed.
- Common examples include, but are not limited to, the following:
 - Limited sinus CT imaging protocol
 - Limited or follow-up slices through a known pulmonary nodule
 - Limited slices to assess a non-healing fracture (such as the clavicle)
- Limited CT (CPT® 76380) is not indicated for treatment planning purposes. See **Unlisted Procedure Codes in Oncology (ONC-1.5)** in the Oncology Imaging Guidelines.
- It is inappropriate to report CPT® 76380, in conjunction with other diagnostic CT codes, to cover ‘extra slices’ in certain imaging protocols.
 - There is no specific number of sequences or slices defined in any CT CPT® code definition.
 - The AMA, in *CPT® 2019*, does not describe nor assign any minimum or maximum number of sequences or slices for any CT study.
 - A few additional slices or sequences are not uncommon.
 - CT imaging protocols are often influenced by the individual's clinical situation. Sometimes the protocols require more time and sometimes less.

SPECT/CT Imaging (Preface-4.6)

PRF.CD.0004.6.A

v2.0.2024

- SPECT/CT involves SPECT (Single Photon Emission Computed Tomography) nuclear medicine imaging and CT for optimizing location, accuracy, and attenuation correction and combines functional and anatomic information.
 - Common studies using this modality include ^{123}I - or ^{131}I - Metaiodobenzylguanidine (MIBG) and octreotide scintigraphy for neuroendocrine tumors.
- Hybrid Nuclear/CT scan can be reported as CPT[®] 78830 (single area and single day), CPT[®] 78831 (2 or more days), or CPT[®] 78832 (2 areas with one day and 2 day study).
- CPT[®] 78072 became effective January 1, 2013 for SPECT/CT parathyroid nuclear imaging.

CPT® 76140 Interpretation of an Outside Study (Preface-4.7)

PRF.CD.0004.7.U

v2.0.2024

- It is inappropriate to use diagnostic imaging codes for interpretation of a previously performed exam that was completed at another facility.
 - If the outside exam is being used for comparison with a current exam, the diagnostic code for the current examination includes comparison to the prior study.⁴
 - CPT® 76140 is the appropriate code to use for an exam which was completed elsewhere and a secondary interpretation of the images is requested.⁵
 - Medicare does not reimburse CPT® 76140 and their coverage policies take precedence over eviCore's guidelines.

Quantitative MR Analysis of Tissue Composition (Preface-4.8)

PRF.CD.0004.8.A

v2.0.2024

- Category III CPT® codes for quantitative analysis of multiparametric-MR (mp-MRI) data with and without an associated diagnostic MRI have been established. Quantitative mp-MRI uses software to analyze tissue physiology of visceral organs and other anatomic structures non-invasively. At present, these procedures are primarily being used in clinical trials and there is no widely recommended indications in clinical practice. As such, these procedures are considered to be investigational and experimental for coverage purposes.
 - CPT® 0648T (without diagnostic MRI) and CPT® 0649T (with diagnostic MRI) refer to data analysis with and without associate imaging of a single organ, with its most common use being LiverMultiScan (LMS).
 - See **Fatty Liver (AB-29.2)** in the Abdomen Imaging Guidelines.
 - CPT® 0697T (without diagnostic MRI) and CPT® 0698T (with diagnostic MRI) refer to data analysis with and without associate imaging of a multiple organs, with its most common use being CoverScan.

HCPCS Codes (Preface-4.9)

PRF.CD.0004.9.A
v2.0.2024

- Healthcare Common Procedure Coding System (HCPCS) codes are utilized by some hospitals in favor of the typical Level-III CPT® codes. These codes are typically 4 digits preceded by a C or S.⁶
 - Many of these codes have similar code descriptions to Level-III CPT® codes (i.e., C8931 – MRA with dye, Spinal Canal; and, CPT® 72159 – MRA Spinal Canal).
 - If cases are submitted with HCPCS codes with similar code descriptions to the typical Level-III CPT® codes, those procedures should be managed in the same manner as the typical CPT® codes.
 - Medicare does not support approval of "S" HCPCS codes.
 - HCPCS code management is discussed further in the applicable guideline sections.
- Requests for many Healthcare Common Procedure Coding System (HCPCS) codes, including non-specific codes such as S8042 (Magnetic resonance imaging [MRI], low-field), should be redirected to a more appropriate and specific CPT® code. Exceptions are noted in the applicable guideline sections.

References (Preface-4)

v2.0.2024

1. Society of Nuclear Medicine and Molecular Imaging Coding Corner. Available at: <http://www.snmmi.org/ClinicalPractice/CodingCornerPT.aspx?ItemNumber=1786>.
2. Intraoperative MR. Brainlab. Available at: <https://www.brainlab.com/surgery-products/overview-neurosurgery-products/intraoperative-mr/>
3. Experience the Advanced 3D Sinus Surgery Planning with Scopis Building Blocks planning software. Scopis Planning. Available at: <http://planning.scopis.com/>.
4. ACR Radiology Coding Source™ March-April 2007 Q and A. Available at: <https://www.acr.org/Advocacy-and-Economics/Coding-Source/ACR-Radiology-Coding-Source-March-April-2007-Q-and-A>.
5. Chung CY, Alson MD, Duszak R, Degnan AJ. From imaging to reimbursement: what the pediatric radiologist needs to know about health care payers, documentation, coding and billing. *Pediatr Radiol*. 2018;48(7):904-914. doi: 10.1007/s00247-018-4104-1.
6. HCPCS - General Information from CMS.gov. Available at: www.cms.gov/medicare/coding/medhcpcsgeninfo.

Whole-Body Imaging (Preface-5)

Guideline

- Whole Body CT Imaging (Preface-5.1)
- Whole-Body MR Imaging (Preface-5.2)
- PET-MRI (Preface-5.3)
- References (Preface-5)

Whole Body CT Imaging (Preface-5.1)

PRF.WB.0005.1.U

v2.0.2024

- Whole-body CT or LifeScan (CT Brain, Chest, Abdomen, and Pelvis) for screening of asymptomatic individuals is not a covered benefit. The performance of whole-body screening CT examinations in healthy individuals does not meet any of the current validity criteria for screening studies and there is no clear documentation of benefit versus radiation risk.
- Whole-body low-dose CT is supported for oncologic staging in Multiple Myeloma. See **Multiple Myeloma and Plasmacytomas (ONC-25)** in the Oncology Imaging Guidelines.

Whole-Body MR Imaging (Preface-5.2)

PRF.WB.0005.2.A

v2.0.2024

- Whole-body MRI (WBMRI) is, with the exception of select cancer predisposition syndromes and autoimmune conditions discussed below, generally not supported at this time due to lack of standardization in imaging technique and lack of evidence that WBMRI improves outcome for any individual disease state.
 - While WBMRI has the benefit of whole-body imaging and lack of radiation exposure, substantial variation still exists in the number of images, type of sequences (STIR vs. diffusion weighting, for example), and contrast agent(s) used.
- Coding considerations:
 - There are no established CPT® or HCPCS codes for reporting WBMRI.
 - WBMRI is at present only reportable using CPT® 76498. All other methods of reporting whole-body MRI are inappropriate including the following:
 - Separate diagnostic MRI codes for multiple individual body parts
 - MRI Bone Marrow Supply (CPT® 77084)
- Disease-specific considerations:
 - Cancer screening:
 - Interval WBMRI is recommended for cancer screening in individuals with select cancer predisposition syndromes. Otherwise, WBMRI has not been shown to improve outcomes for cancer screening.
 - For additional information, see **Li-Fraumeni Syndrome (LFS) (PEDONC-2.2)**, **Hereditary Paraganglioma-Pheochromocytoma (HPP) Syndromes (PEDONC-2.13)**, or **Constitutional Mismatch Repair Deficiency (CMMRD or Turcot Syndrome) (PEDONC-2.15)** in the Pediatric Oncology Imaging Guidelines.
 - Cancer staging and restaging:
 - While the feasibility of WBMRI has been established, data remain conflicting on whether WBMRI is of equivalent diagnostic accuracy compared with standard imaging modalities such as CT, scintigraphy, and PET imaging. Evidence has not been published establishing WBMRI as a standard evaluation for any type of cancer.
 - Autoimmune disease:
 - WBMRI can be approved in some situations for individuals with chronic recurrent multifocal osteomyelitis.
 - For additional information, see **Chronic Recurrent Multifocal Osteomyelitis (PEDMS-10.2)** in the Pediatric Musculoskeletal Imaging Guidelines.

PET-MRI (Preface-5.3)

PRF.WB.0005.3.A

v2.0.2024

- PET-MRI is generally not supported for a vast majority of oncologic and neurologic conditions due to lack of standardization in imaging technique and interpretation. However, it may be appropriate in select circumstances when the following criteria are met:
 - The individual meets condition-specific guidelines for PET-MRI OR
 - The individual meets ALL of the following:
 - The individual is a pediatric patient or being treated under a pediatric guideline and treatment plan AND
 - The individual meets guideline criteria for PET-CT, AND
 - PET-CT is not available at the treating institution, AND
 - The provider requests PET-MRI in lieu of PET-CT
- When the above criteria are met, PET-MRI may be reported using the code combination of PET Whole-Body (CPT[®] 78813) and MRI Unlisted (CPT[®] 76498). All other methods of reporting PET-MRI are inappropriate.
 - When clinically appropriate, diagnostic MRI codes may be indicated at the same time as the PET-MRI code combination.
- For more information, see **PET Imaging in Pediatric Oncology (PEDONC-1.4)** in the Pediatric Oncology Imaging Guidelines, and **PET Brain Imaging (PEDHD-2.3)** and **Special Imaging Studies in Evaluation for Epilepsy Surgery (PEDHD-6.3)** in the Pediatric Head Imaging Guidelines.

References (Preface-5)

v2.0.2024

1. Villani A, Tabori U, Schiffman J, et al. Biochemical and imaging surveillance in germline TP53 mutation carriers with Li-Fraumeni syndrome: a prospective observational study. *Lancet Oncol.* 2011;12(6):559-567. doi: 10.1016/S1470-2045(11)70119-X.
2. Siegel MJ, Acharyya S, Hoffer FA, et al. Whole-Body MR Imaging for Staging of Malignant Tumors in Pediatric Patients: Results of the American College of Radiology Imaging Network 6660 Trial. *Radiology.* 2013;266(2):599-609. doi: 10.1148/radiol.12112531.
3. Antoch G. Whole-Body Dual-Modality PET/CT and Whole-Body MRI for Tumor Staging in Oncology. *JAMA.* 2003;290(24):3199. doi: 10.1001/jama.290.24.3199.
4. Lauenstein TC, Semelka RC. Emerging techniques: Whole-body screening and staging with MRI. *J Magn Reson Imaging.* 2006;24(3):489-498. doi: 10.1002/jmri.20666.
5. Khanna G, Sato TSP, Ferguson P. Imaging of Chronic Recurrent Multifocal Osteomyelitis. *RadioGraphics.* 2009;29(4):1159-1177. doi: 10.1148/rg.294085244.
6. Ferguson PJ, Sandu M. Current Understanding of the Pathogenesis and Management of Chronic Recurrent Multifocal Osteomyelitis. *Curr Rheumatol Rep.* 2012;14(2):130-141. doi: 10.1007/s11926-012-0239-5.
7. National Comprehensive Cancer Network® (NCCN®). NCCN Clinical Practice Guidelines in Oncology (NCCN Guidelines®): Genetic/Familial High Risk Assessment: Breast, Ovarian, and Pancreatic. Version 3.2023. February 13, 2023. Referenced with permission from the NCCN Clinical Practice Guidelines in Oncology (NCCN Guidelines®) for Genetic/Familial High-Risk Assessment: Breast, Ovarian, and Pancreatic V.3.2023. ©National Comprehensive Cancer Network, Inc. 2023. All rights reserved. Accessed July 10, 2023. The NCCN Guidelines® and illustrations herein may not be reproduced in any form for any purpose without the express written permission of the NCCN. To view the most recent and complete version of the NCCN Guidelines® go online to NCCN.org.

References (Preface-6)

Guideline

References (Preface-6.1)

References (Preface-6.1)

PRF.RF.0006.1.A
v2.0.2024

- Complete reference citations for the journal articles are embedded within the body of the guidelines and/or may be found on the Reference pages at the end of some guideline sections.
- The website addresses for certain references are included in the body of the guidelines but are not hyperlinked to the actual website.
- The website address for the American College of Radiology (ACR) Appropriateness Criteria® is <http://www.acr.org>.

Copyright Information (Preface-7)

Guideline

Copyright Information (Preface-7.1)

Copyright Information (Preface-7.1)

PRF.CI.0007.1.A
v2.0.2024

- ©2024 eviCore healthcare. All rights reserved. No part of these materials may be changed, reproduced, or transmitted in any form or by any means, electronic or mechanical, including photocopying or recording, or in any information storage or retrieval system, without the prior express written permission of eviCore.

Trademarks (Preface-8)

Guideline

Trademarks (Preface-8.1)

Trademarks (Preface-8.1)

PRF.TM.0008.1.A
v2.0.2024

- **CPT® (Current Procedural Terminology)** is a registered trademark of the American Medical Association (AMA). **CPT®** five digit codes, nomenclature, and other data are copyright 2023 American Medical Association. All Rights Reserved. No fee schedules, basic units, relative values, or related listings are included in the **CPT®** book. AMA does not directly or indirectly practice medicine or dispense medical services. AMA assumes no liability for the data contained herein or not contained herein.

Table of Contents

Guideline

- General Guidelines (AB-1)
- Abdominal Pain (AB-2)
- Abdominal Sepsis (Suspected Abdominal Abscess) (AB-3)
- Flank Pain, Rule Out or Known Renal/Ureteral Stone (AB-4)
- Gastroenteritis/Enterocolitis (AB-5)
- Mesenteric/Colonic Ischemia (AB-6)
- Post-Operative Pain Within 60 Days Following Abdominal Surgery –
Abdominal Procedure (AB-7)
- Abdominal Lymphadenopathy (AB-8)
- Bariatric Surgery and Percutaneous Gastrostomy (AB-9)
- Blunt Abdominal Trauma (AB-10)
- Gaucher Disease and Hemochromatosis (AB-11)
- Hernias (AB-12)
- Abdominal Mass (AB-13)
- Lower Extremity Edema (AB-14)
- Zollinger-Ellison Syndrome (ZES-Gastrinoma) (AB-15)
- Adrenal Cortical Lesions (AB-16)
- Abdominal Aortic Aneurysm (AAA), Iliac Artery Aneurysm (IAA), and
Visceral Artery Aneurysms Follow-Up of Known Aneurysms and Pre-Op
Evaluation (AB-17)
- Abdominal Aortic Aneurysm (AAA) and Iliac Artery Aneurysm (IAA)-Post
Endovascular or Open Aortic Repair (AB-18)
- Aortic Dissection and Imaging for Other Aortic Conditions (AB-19)
- Bowel Obstruction, Gastroparesis, and Bloating (AB-20)
- Diarrhea, Constipation, and Irritable Bowel (AB-21)
- GI Bleeding (AB-22)
- Inflammatory Bowel Disease (AB-23)
- Celiac Disease (Sprue) (AB-24)
- CT Colonography (CTC) (AB-25)
- Cirrhosis and Liver Screening for Hepatocellular Carcinoma (HCC);
Ascites and Portal Hypertension (AB-26)
- MR Cholangiopancreatography (MRCP) (AB-27)
- Gallbladder (AB-28)
- Liver Lesion Characterization (AB-29)
- Abnormal Liver Chemistries (AB-30)

- Pancreatic Lesion (AB-31)
- Pancreatic Pseudocysts (AB-32)
- Pancreatitis (AB-33)
- Spleen (AB-34)
- Indeterminate Renal Lesion (AB-35)
- Renal Failure (AB-36)
- Renovascular Hypertension (AB-37)
- Polycystic Kidney Disease (AB-38)
- Hematuria and Hydronephrosis (AB-39)
- Urinary Tract Infection (UTI) (AB-40)
- Patent Urachus (AB-41)
- Transplant (AB-42)
- Hepatic and Abdominal Arteries (AB-43)
- Suspected Neuroendocrine Tumors of the Abdomen (AB-44)
- Liver Elastography (AB-45)
- Hiccups (AB-46)
- Retroperitoneal Fibrosis (AB-47)
- Fistulae (AB-48)

General Guidelines (AB-1)

Guideline

Abbreviations for Abdomen Imaging Guidelines

General Guidelines (AB-1.0)

Overview (AB-1.1)

CT Imaging (AB-1.2)

MR Imaging (AB-1.3)

MR Enterography and Enteroclysis Coding Notes (AB-1.4)

Ultrasound (AB-1.5)

Abdominal Ultrasound (AB-1.6)

Retroperitoneal Ultrasound (AB-1.7)

CT-, MR-, Ultrasound-guided Procedures (AB-1.8)

Contrast-Enhanced Ultrasound (AB-1.9)

Quantitative MRI (AB-1.10)

RADCAT Grading System (AB-1.11)

Pregnancy Considerations for Imaging (AB-1.12)

References (AB-1)

Abbreviations for Abdomen Imaging Guidelines

AB.GG.Abbreviations.A

v1.0.2024

Abbreviations for Abdomen Imaging Guidelines	
AAA	abdominal aortic aneurysm
AASLD	American Association for the Study of Liver Diseases
ACE	angiotensin-converting enzyme
ACG	American College of Gastroenterology
ACR	American College of Radiology
ACTH	adrenocorticotrophic hormone
AFP	alpha-fetoprotein
AGA	American Gastroenterological Association
ALT	alanine aminotransferase
ASGE	American Society for Gastrointestinal Endoscopy
AST	aspartate aminotransferase
AUA	American Urological Association
BEIR	Biological Effects of Ionizing Radiation
BUN	blood urea nitrogen
CAG	Canadian Association of Gastroenterology
CNS	central nervous system
CT	computed tomography
CTA	computed tomography angiography
CTC	computed tomography colonography (aka: virtual colonoscopy)
DVT	deep vein thrombosis
ERCP	endoscopic retrograde cholangiopancreatography
EUS	endoscopic ultrasound
FNH	focal nodular hyperplasia
GFR	glomerular filtration rate

Abbreviations for Abdomen Imaging Guidelines	
GGT	gamma glutamyltransferase
GI	gastrointestinal
HCC	hepatocellular carcinoma
HCPCS	Healthcare Common Procedural Coding System (commonly pronounced: "hix pix")
HU	Hounsfield units
IAA	iliac artery aneurysm
IV	intravenous
KUB	kidneys, ureters, bladder (plain frontal supine abdominal radiograph)
LFT	liver function tests
MRCP	magnetic resonance cholangiopancreatography
MRA	magnetic resonance angiography
MRI	magnetic resonance imaging
mSv	millisievert
NAFLD	nonalcoholic fatty liver disease
PA	posteroanterior projection
PET	positron emission tomography
RAS	renal artery stenosis
RBC	red blood cell
SBFT	small bowel follow through
SPECT	single photon emission computed tomography
VC	virtual colonoscopy (CT colonography)
PFT	pulmonary function tests
WBC	white blood cell
ZES	Zollinger-Ellison Syndrome

General Guidelines (AB-1.0)

AB.GG.0001.0.A

v1.0.2024

- A current clinical evaluation (within 60 days) is required before advanced imaging can be considered. The clinical evaluation must include a history relevant to the current complaint and physical examination, and may include appropriate laboratory studies, and non-advanced imaging modalities such as plain x-ray or ultrasound. Other meaningful contact (telephone call, electronic mail or messaging) by an established individual can substitute for a face-to-face clinical evaluation.

Red Flag Findings

- The following signs and symptoms can be indicative of more serious conditions. Documentation of abdominal pain along with ANY of the following warrants exclusion from prerequisites to advanced imaging:
 - History of malignancy with a likelihood or propensity to metastasize to abdomen
 - Fever (≥ 101 degrees Fahrenheit)
 - Elevated WBC $> 10,000$, or above the upper limit of normal for the particular lab reporting the result
 - Low WBC (absolute neutrophil count < 1000)
 - Palpable mass of clinical concern and/or without benign features
 - GI bleeding, overt or occult, not obviously hemorrhoidal
 - Abdominal tenderness documented as moderate or severe
 - Peritoneal signs, such as guarding or rebound tenderness
 - Suspected complication of bariatric surgery
 - Notation by the ordering provider that the individual has a "surgical abdomen"
 - Age ≥ 60 years with unintentional weight loss of ≥ 10 lbs. or $\geq 5\%$ of body weight over 6 months or less
- See the condition-specific sections for when the above list of exclusionary criteria apply and lead directly to advanced imaging.

Experimental, Investigational, and/or Unproven Techniques

- Certain studies, treatments, procedures, or devices may be considered experimental, investigational, or unproven for **any** condition, illness, disease, or injury being treated if one of the following is present:
 - If there is a paucity of supporting evidence;
 - If the evidence has not matured to exhibit improved health parameters;
 - If clinical utility has not been demonstrated in any condition OR
 - The study, treatment, procedure, or device lacks a collective opinion of support.

- Supporting evidence includes standards that are based on credible scientific evidence published in peer-reviewed medical literature (such as well conducted randomized clinical trials or cohort studies with a sample size of sufficient statistical power) generally recognized by the relevant medical community. Collective opinion of support includes physician specialty society recommendations and the views of physicians practicing in relevant clinical areas when physician specialty society recommendations are not available.

Imaging Recommended Per Drug Manufacturer

- When follow up imaging for the purposes of monitoring or screening is recommended in the package insert for a particular drug therapy or medication, that imaging may be indicated.

Complications Related to COVID-19

- Please refer to the appropriate condition-specific guideline relevant to the presenting signs or symptoms in individuals with potential sequelae of COVID-19.
 - Examples include:
 - For suspected acute mesenteric ischemia, see: **Mesenteric Ischemia (AB-6.1)**
 - For suspected renal failure, see: **Renal Failure (AB-36.1)**
 - For left upper quadrant pain and suspected infarct, see: **Left Upper Quadrant (LUQ) Pain (AB-2.4)**

Pre-operative Radiologic Imaging

- Please refer to the appropriate condition-specific guideline relevant to the clinical condition for pre-operative imaging indications (e.g., **Percutaneous Gastrostomy (AB-9.2)**)
- If imaging is requested by the operating surgeon to support planned surgery, the imaging may be approved.
- Radiologic therapeutic intervention is addressed elsewhere in this Guideline
 - Radiologic management of lower GI bleeding, see: **Small Bowel Bleeding Suspected (AB-22.2)**
 - Radiologic management of mesenteric ischemia, see: **Mesenteric/Colonic Ischemia (AB-6.1)**
 - Radiologic management of portal hypertension, see: **Portal Hypertension (AB-26.3)**

3D Rendering

- CPT® 76377 (3D rendering requiring image post-processing on an independent workstation) or CPT® 76376 (3D rendering not requiring image post-processing on an independent workstation) can be considered in the following clinical scenarios:
 - Preoperative planning for complex surgical cases
 - CT Urogram (See: **Hematuria and Hydronephrosis (AB-39)**)
 - MRCP (See: **MR Cholangiopancreatography (MRCP) (AB-27)**)
- CPT® codes for 3D rendering should not be billed in conjunction with computer-aided detection (CAD), MRA, CTA, nuclear medicine SPECT studies, PET, PET/CT, or CT Colonography (virtual colonoscopy).

Overview (AB-1.1)

AB.GG.0001.1.A
v1.0.2024

- GI Specialist evaluations can be helpful, particularly in determining mesenteric/colonic ischemia, diarrhea/constipation, irritable bowel syndrome (IBS), or need for MRCP.
- Abdominal imaging begins at the diaphragm and extends to the umbilicus or iliac crest.
- Pelvic imaging begins at the iliac crest and extends to the pubis.
- Clinical concerns at the dividing line can be providers' choice (abdomen and pelvis; abdomen or pelvis).

CT Imaging (AB-1.2)

AB.GG.0001.2.A

v1.0.2024

- CT imaging is a more generalized modality. CT Abdomen is usually performed with contrast (CPT® 74160):
 - Oral contrast has no relation to the IV contrast administered. Coding for contrast only refers to IV contrast. There is no coding for oral contrast.
 - Exceptions are noted in these guidelines, and include:
 - CT Abdomen with contrast (CPT® 74160) or without and with contrast (CPT® 74170) with suspicion of a solid organ lesion (liver, kidney, pancreas, spleen).
 - Please refer to the specific guideline for the lesion in question for specific guidance.
 - CT Abdomen without contrast (CPT® 74150) or CT Abdomen and Pelvis without contrast (CPT® 74176) if there is renal insufficiency/failure, or a documented allergy to contrast. It can also be considered for diabetics or the very elderly.
 - CT Abdomen and Pelvis without and with contrast (CPT® 74178 – CT Urogram) for certain urologic conditions (e.g. hematuria)
 - Shellfish allergy:
 - It is commonly assumed that an allergy to shellfish infers iodine allergy, and that this implies an allergy to CT iodinated contrast media. However, this is NOT true. Shellfish allergy is due to tropomyosins. Iodine plays no role in these allergic reactions. Allergies to shellfish do not increase the risk of reaction to IV contrast any more than that of other allergens.
 - CT Abdomen and Pelvis, usually with contrast (CPT® 74177), should be considered when signs or symptoms are generalized, or involve a lower quadrant of the abdomen.
 - CT Enterography (CPT® 74177) combines CT imaging with large volumes of ingested neutral bowel contrast material to allow visualization of the small bowel.
 - CT Enteroclysis
 - A tube is placed through the nose or mouth and advanced into the duodenum or jejunum. Bowel contrast material is infused through the tube and CT imaging is performed either with or without intravenous contrast.
 - CT Enteroclysis is used to allow visualization of the small bowel wall and lumen. CT Enteroclysis may allow better or more consistent distention of the small bowel than CT Enterography.
 - Report by assigning: CPT® 74176 or CPT® 74177
 - Triple-phase CT
 - 3 phases of a triple-phase CT are:

- 1) Hepatic arterial phase,
- 2) Portal venous phase, and
- 3) Washout or delayed acquisitions phase.
- It should be noted that, in general, a pre-contrast or non-contrast CT is usually not needed in a standard triple-phase CT, except in those individuals previously treated with locoregional embolic or ablative therapies. Other specific instances in which a prior noncontrast CT may be indicated for the evaluation of liver lesions are noted in **Liver Lesion Characterization (AB-29.1)**.
- CT Colonography (CTC)
 - There are 3 CPT® codes for CTC:
 - CPT® 74263: Screening CTC (only used for screening procedures)
 - CPT® 74261: CTC without contrast
 - CPT® 74262: CTC with contrast
 - See: **CT Colonography (CTC) (AB-25)** for further indications for these procedures

MR Imaging (AB-1.3)

AB.GG.0001.3.A
v1.0.2024

- MRI may be preferred as a more targeted study in cases of renal failure, in individuals allergic to intravenous CT contrast, and as noted in these guidelines.
 - MRI Abdomen with contrast only is essentially never performed. If contrast is indicated, MRI Abdomen without and with contrast (CPT® 74183) should be performed.
 - For pregnant women ultrasound or MRI without contrast should be used to avoid radiation exposure. The use of gadolinium contrast agents is limited during pregnancy, as gadolinium contrast agents cross the placenta and enter the amniotic fluid with unknown long-term effects on the fetus.
 - See: **Pregnancy Considerations for Imaging (AB-1.12)** for additional discussion of this issue
- MR Elastography (CPT® 76391) replaces MRI Abdomen (CPT® 74183 or CPT® 74181) for requests for MR Elastography liver (See: **Liver Elastography (AB-45)**)

MR Enterography and Enteroclysis Coding Notes (AB-1.4)

AB.GG.0001.4.U

v1.0.2024

- MR Enterography or Enteroclysis is reported in one of two ways:
 - MRI Abdomen without and with contrast (CPT® 74183), or
 - MRI Abdomen without and with contrast (CPT® 74183) and MRI Pelvis with and without contrast (CPT® 72197)

Ultrasound (AB-1.5)

AB.GG.0001.5.A

v1.0.2024

- Ultrasound, also called sonography, uses high frequency sounds waves to image body structures.
 - The routine use of 3D and 4D rendering, (post-processing), in conjunction with ultrasound is considered investigational.
 - All ultrasound studies require permanently recorded images either stored on film or in a Picture Archiving and Communication System (PACS).
 - The use of a hand-held or any Doppler device that does not create a hard-copy output is considered part of the physical examination and is not separately billable. This exclusion includes devices that produce a record that does not permit analysis of bi-directional vascular flow.
- Duplex scan describes an ultrasonic scanning procedure for characterizing the pattern and direction of blood flow in arteries and veins with the production of real-time images integrating B-mode 2D vascular structures, Doppler spectral analysis, and color flow Doppler imaging.
 - The minimal use of color Doppler alone, when performed for anatomical structure identification during a standard ultrasound procedure, is not separately reimbursable.

Abdominal Ultrasound (AB-1.6)

AB.GG.0001.6.A

v1.0.2024

- Complete abdominal ultrasound (CPT® 76700) includes all of the following required elements:
 - Liver, gallbladder, common bile duct, pancreas, spleen, kidneys, upper abdominal aorta, and inferior vena cava.
 - If a particular structure or organ cannot be visualized, the report should document the reason.
- Limited abdominal ultrasound (CPT® 76705) is without all of these required elements and can refer to a specific study of a single organ, a limited area of the abdomen, or a follow-up study.
 - Further, CPT® 76705 should:
 - Be assigned to report follow-up studies once a complete abdominal ultrasound (CPT® 76700) has been performed; and
 - Be assigned to report ultrasonic evaluation of diaphragmatic motion; and
 - Be reported only once per individual imaging session; and
 - Not be reported with CPT® 76700 for the same individual for the same imaging session.

Retroperitoneal Ultrasound (AB-1.7)

AB.GG.0001.7.A

v1.0.2024

- Complete retroperitoneal ultrasound (CPT® 76770) includes all of the following required elements:
 - Kidneys, lymph nodes, abdominal aorta, common iliac artery origins, inferior vena cava.
 - For urinary tract indications, a complete study can consist of kidneys and bladder.
- Limited retroperitoneal ultrasound (CPT® 76775) studies are without all of these required elements and can refer to a specific study of a single organ, a limited area of the abdomen, or a follow-up study.
 - Further, CPT® 76775 should:
 - Be assigned to report follow-up studies once a complete retroperitoneal ultrasound (CPT® 76770) has been performed; and
 - Be reported only once per individual imaging session; and
 - Not be reported with CPT® 76770 for the same individual for the same imaging session.

CT-, MR-, Ultrasound-guided Procedures (AB-1.8)

AB.GG.0001.8.A

v1.0.2024

See: **CT-, MR-, or Ultrasound-Guided Procedures (Preface-4.2)** in the Preface
Imaging Guidelines

Contrast-Enhanced Ultrasound (AB-1.9)

AB.GG.0001.9.A

v1.0.2024

Ultrasound with contrast (CEUS, CPT® 76978, CPT® 76979) is an emerging technology that may be as good, if not better, than CT or MRI in certain circumstances. Abdominal Imaging Guidelines address its use as appropriate. CPT® 76978 refers to the initial imaging of the first lesion, and CPT® 76979 refers to additional lesions that are imaged subsequently.

Quantitative MRI (AB-1.10)

AB.GG.0001.10.A

v1.0.2024

- Quantitative MR analysis of tissue composition (CPT® 0648T, 0649T, 0697T and 0698T)
 - These CPT codes are investigational and experimental for coverage purposes.
 - See: **Quantitative MR Analysis of Tissue Composition (Preface-4.8)** and **Fatty Liver (AB-29.2)** for further discussion of these modalities.

RADCAT Grading System (AB-1.11)

AB.GG.0001.11.A

v1.0.2024

- The RADCAT (Radiology Report Categorization) Grading System was developed in order to communicate to ordering physicians (most commonly in the ER setting), the relative urgency of a radiologic finding. It is not related to the LI-RADs reporting system, nor does it necessarily imply the need for follow-up imaging, as opposed to clinical follow-up. The rating system is as follows:
 - RADCAT 1: Normal Result
 - RADCAT 2: Routine Result
 - RADCAT 3: Result with recommendation for non-urgent routine follow-up
 - RADCAT 4: Priority Result
 - RADCAT 5: Critical Result

Pregnancy Considerations for Imaging (AB-1.12)

AB.GG.0001.12.A

v1.0.2024

The American College of Obstetricians and Gynecologists has issued guidelines with regards to imaging during pregnancy and lactation. Their recommendations are as follows:¹⁵

- Ultrasonography and magnetic resonance imaging (MRI) are not associated with risk and are the imaging techniques of choice for the pregnant patient, but they should be used prudently and only when use is expected to answer a relevant clinical question or otherwise provide medical benefit to the patient.
- With few exceptions, radiation exposure through radiography, computed tomography (CT) scan, or nuclear medicine imaging techniques is at a dose much lower than the exposure associated with fetal harm.
 - If these techniques are necessary in addition to ultrasound or MRI or are more readily available for the diagnosis in question, they should not be withheld from a pregnant patient.
- The use of gadolinium contrast with MRI should be limited; it may be used as a contrast agent in a pregnant patient only if it significantly improves diagnostic performance and is expected to improve fetal or maternal outcome.
- With regards to iodinated IV contrast media, “it is generally recommended that contrast only be used if absolutely required to obtain additional diagnostic information that will affect the care of the fetus or woman during pregnancy”.

References (AB-1)

v1.0.2024

1. Faerber EN, Benator RM, Browne LP, et al. ACR–SPR Practice Parameter For The Safe And Optimal Performance Of Fetal Magnetic Resonance Imaging (MRI) American College of Radiology. Published 2014.
2. ACR Practice Guideline for Imaging Pregnant or Potentially Pregnant Adolescents and Women with Ionizing Radiation. American College of Radiology. Published 2014.
3. Runyon BA. Management of adult patients with ascites due to cirrhosis: An update. *Hepatology*. 2009;49(6):2087-2107.(revised 2012).
4. Berzigotti A, Ashkenazi E, Reverter E, et al. Non-Invasive Diagnostic and Prognostic Evaluation of Liver Cirrhosis and Portal Hypertension. *Disease Markers*. 2011;31(3):129-138.
5. Choi J-Y, Lee J-M, Sirlin CB. CT and MR Imaging Diagnosis and Staging of Hepatocellular Carcinoma: Part II. Extracellular Agents, Hepatobiliary Agents, and Ancillary Imaging Features. *Radiology*. 2014;273(1):30-50. doi:10.1148/radiol.14132362.
6. Chiorean L, Tana C, Braden B, et al. Advantages and Limitations of Focal Liver Lesion Assessment with Ultrasound Contrast Agents: Comments on the European Federation of Societies for Ultrasound in Medicine and Biology (EFSUMB) Guidelines. *Medical Principles and Practice*. 2016;25(5):399-407. doi:10.1159/000447670.
7. Claudon M, Dietrich C, Choi B, et al. Guidelines and Good Clinical Practice Recommendations for Contrast Enhanced Ultrasound (CEUS) in the Liver – Update 2012. *Ultraschall in der Medizin - European Journal of Ultrasound*. 2012;34(01):11-29. doi:10.1055/s-0032-1325499.
8. Beyer L, Wassermann F, Pregler B, et al. Characterization of Focal Liver Lesions using CEUS and MRI with Liver-Specific Contrast Media: Experience of a Single Radiologic Center. *Ultraschall in der Medizin - European Journal of Ultrasound*. 2017;38(06):619-625. doi:10.1055/s-0043-105264.
9. Trillaud H, Bruel J-M, Valette P-J, et al. Characterization of focal liver lesions with SonoVue®-enhanced sonography: International multicenter-study in comparison to CT and MRI. *World Journal of Gastroenterology*. 2009;15(30):3748. doi:10.3748/wjg.15.3748.
10. Marrero JA, Kulik LM, Sirlin CB, et al. Diagnosis, Staging, and Management of Hepatocellular Carcinoma: 2018 Practice Guidance by the American Association for the Study of Liver Diseases. *Hepatology*. 2018;68(2):723-750. doi:10.1002/hep.29913.
11. Baig, Mudassar. "Shellfish Allergy and Relation to Iodinated Contrast Media: United Kingdom Survey." *World Journal of Cardiology* 6, no. 3 (2014): 107-111. doi:10.4330/wjc.v6.i3.107.
12. Schabelman, Esteban, and Michael Witting. "The Relationship of Radiocontrast, Iodine, and Seafood Allergies: A Medical Myth Exposed." *The Journal of Emergency Medicine* 39, no. 5 (2010): 701-07. doi:10.1016/j.jemermed.2009.10.014.
13. Beckett, Katrina R., Andrew K. Moriarity, and Jessica M. Langer. "Safe Use of Contrast Media: What the Radiologist Needs to Know." *RadioGraphics* 35, no. 6 (2015): 1738-750. doi:10.1148/rg.2015150033.
14. Swenson DW, Baird GL, Portelli DC, Mainiero MB, Movson JS. Pilot study of a new comprehensive radiology report categorization (RADCAT) system in the emergency department. *Emergency Radiology*. 2017;25(2):139-145. doi:10.1007/s10140-017-1565-8.
15. Guidelines for diagnostic imaging during pregnancy and lactation. Committee Opinion No. 723. American College of Obstetricians and Gynecologists. *Obstet Gynecol*. 2017;130:e210–6.
16. Longo SA, Moore RC, Canzoneri BJ, Robichaux A. Gastrointestinal conditions during pregnancy. *Clin. Colon Rectal Surg*. 2010;23(2):80-89. doi:10.1055/s-0030-1254294.
17. Aslanian HR, Lee JH, Canto MI. AGA clinical practice update on pancreas cancer screening in high risk individuals: expert review. *Gastroenterology*. 2020;159(1):358-362. doi:10.1053/j.gastro.2020.03.088.
18. National Institute for Health and Care Excellence (NICE). Upper gastrointestinal tract cancers. In: Suspected cancer: recognition and referral. 2015. <https://www.nice.org.uk/guidance/ng12/chapter/Recommendations-organised-by-site-of-cancer#upper-gastrointestinal-tract-cancers>.
19. Baluch, A., Shewayish, S. (2019). Neutropenic Fever. In: Velez, A., Lamarche, J., Greene, J. (eds) *Infections in Neutropenic Cancer Patients*. Springer, Cham. https://doi.org/10.1007/978-3-030-21859-1_8.

Abdominal Pain (AB-2)

Guideline

- Acute/Persistent (Non-Chronic) Lower Abdominal Pain (AB-2.2)
- Right Upper Quadrant Pain Including Suspected Gallbladder Disease (AB-2.3)
- Left Upper Quadrant (LUQ) Pain (AB-2.4)
- Epigastric Pain and Dyspepsia (AB-2.5)
- Chronic Abdominal Pain (AB-2.6)
- Non-operative Treatment of Acute Appendicitis (AB-2.7)
- Non-chronic Nonspecific Abdominal Pain with No Localizing Findings (AB-2.8)
- References (AB-2)

Acute/Persistent (Non-Chronic) Lower Abdominal Pain (AB-2.2)

AB.AP.0002.2.A

v1.0.2024

- The presence of any red flag findings per **General Guidelines (AB-1.0)** precludes adjudication based on any other criteria.
- Left Lower Abdominal Pain (including suspected diverticulitis) <6 months duration
 - CT Abdomen and Pelvis with contrast is indicated if ANY of the following are present:
 - Age ≥65
 - The presence of LLQ tenderness specifically noted on physical examination, and diverticulitis is specified as a diagnostic consideration
 - Immunocompromised individual (e.g., on immunosuppressive therapy, history of HIV)
 - If prior abdominal and pelvic US has been performed and demonstrates a need for additional imaging OR if they do not explain the source of pain
 - CBC, Basic Metabolic Panel, C-Reactive Protein or other inflammatory marker, Pregnancy Test, and Urinalysis have been performed
 - Note: All the specific laboratory studies listed are not required, but there should be some studies performed relating to the current episode in order to help direct imaging appropriately.
 - For follow-up imaging of acute diverticulitis if symptoms or elevated WBC persists despite treatment
 - For follow-up of complicated diverticulitis, including confirmed abscess, fistulae, free fluid, or perforation (See: **Abdominal Sepsis/Suspected Abdominal Sepsis (AB-3)**).
 - For follow-up of diverticulitis treated with radiologic intervention (e.g. drainage procedure)
 - Note: Per ASCRS, colonic endoscopic evaluation is recommended to confirm the diagnosis after resolution of acute diverticulitis to exclude malignancy, especially when initial CT scan supports abscess, shouldering, or shelf-like appearance of a presumed inflammatory mass, obstruction, mesenteric or retroperitoneal adenopathy.
 - Pregnant individuals
 - US Abdomen and/or Pelvis should be considered initially to avoid ionizing radiation.
 - MRI Abdomen and MRI Pelvis without contrast if US is nondiagnostic. (See: **Pregnancy Considerations for Imaging (AB-1.12)**)
- Right Lower Abdominal Pain (including suspected appendicitis)
 - CT Abdomen and Pelvis with or without contrast is indicated if ANY of the following are present:

- Age ≥65
- For Alvarado Score of ≥4
- For AIR (Appendicitis Inflammatory Response Score) of ≥5
- Immunocompromised individual (e.g., on immunosuppressive therapy, history of HIV)
- US of the abdomen and pelvis has been performed and is nondiagnostic or negative or indicates a need for further advanced imaging
- CBC or CRP (or other inflammatory marker such as ESR or fecal calprotectin) have been performed related to this episode
- Pregnant individuals
 - Abdominal US and/or Pelvic US initial imaging
 - MRI Abdomen and Pelvis without contrast if initial US is nondiagnostic.
 - See above statement regarding CT and contrast during pregnancy.
- For Chronic lower abdominal pain (≥6 months), see: **Chronic Abdominal Pain (AB-2.6)**
- For follow-up imaging for conservatively treated acute appendicitis, see: **Non-Operative Treatment of Acute Appendicitis (AB-2.7)**.
- For Rectal Pain (Proctalgia) see: **Pelvic Pain/Dyspareunia (PV-11.1), Female, Proctalgia Syndromes and Male Pelvic Disorders, Proctalgia Syndromes (PV-19.1)**.
- For pain described as pelvic, see: **Pelvic Pain/Dyspareunia (PV-11.1)** or other appropriate sections based on likely etiology.

CPT® Codes for Acute/Persistent (Non-Chronic) Lower Abdominal Pain (AB-2.2)

CPT® 74150	CT Abdomen without contrast	CPT® 76700	Ultrasound, complete Abdomen
CPT® 74160	CT Abdomen with contrast	CPT® 76705	Ultrasound, limited Abdomen
CPT® 74176	CT Abdomen and Pelvis without contrast	CPT® 76830	Ultrasound, Transvaginal
CPT® 74177	CT Abdomen and Pelvis with contrast	CPT® 76856	Ultrasound, complete Pelvis
CPT® 74181	MRI Abdomen without contrast	CPT® 72195	MRI Pelvis without contrast
CPT® 74183	MRI Abdomen without and with contrast	CPT® 72197	MRI Pelvis without and with contrast

Background and Supporting Information

- The Alvarado Score for appendicitis risk is comprised of the following parameters with points assigned based on their presence, as follows:

Migration of pain	1 point
Anorexia	1 point
Nausea/vomiting	1 point
Right lower quadrant tenderness	2 points
Rebound pain	1 point
Temperature > 99.1	1 point
WBC > 10,000	2 points
PMNs ≥ 75%	1 point

- Low Risk: <4
- Moderate Risk: 4-7
- High Risk: ≥8
- Appendicitis Inflammatory Response Score (AIR)

Vomiting	1 point
Right iliac fossa pain	1 point
Rebound tenderness	Light – 1 point Medium – 2 points Strong – 3 points
Febrile (temperature ≥ 101.3)	1 point
PMNs	70-84% - 1 point ≥85% - 2 points
WBC	10-14.9 – 1 point ≥15 – 2 points
CRP	10-49 – 1 point >50 – 2 points

- Low Probability: 0-4
- Mild Probability: 5-8
- High Probability: 9-12

Right Upper Quadrant Pain Including Suspected Gallbladder Disease (AB-2.3)

AB.AP.0002.3.A

v1.0.2024

- The presence of any red flag findings per **General Guidelines (AB-1.0)** precludes adjudication based on any other criteria.
- For Pregnant Women, see: **Pregnancy Considerations for Imaging (AB-1.12)**
- For all others:
 - Abdominal ultrasound (complete or limited) is the initial diagnostic test
 - CT Abdomen with contrast, or MRCP/MRI (MRI Abdomen without or without and with contrast) if ultrasound is equivocal or nondiagnostic.
- Hepatobiliary System Imaging (HIDA) with OR without pharmacologic intervention (CPT® 78226 or CPT® 78227) can be considered:
 - If there is right upper quadrant pain or epigastric pain and there is a suspicion of gallbladder disease, with a normal, or equivocal or non-diagnostic recent ultrasound, CT, or MRI
 - NOTE: If findings on US suggest acute cholecystitis in a symptomatic individual (presence of gallstones with gallbladder wall thickening, Murphy's sign, and peri-cholecystic fluid) then a HIDA scan is generally not needed.
 - If the HIDA without pharmacologic intervention (CPT® 78226) is initially performed and is normal or inconclusive, the site can convert the study to HIDA with pharmacologic intervention (CPT® 78227). The member will not need to return for a second study with injection of a pharmaceutical.
 - Suspected bile leak after trauma or surgery
 - Monitoring of liver regeneration
 - Assessment of liver transplant
 - Assessment of choledochal cyst
 - Pre-operative assessment prior to partial hepatectomy
 - Chronic acalculous cholecystitis, biliary dyskinesia, functional gallbladder disease, or sphincter of Oddi dysfunction can be imaged with a HIDA with or without pharmacologic intervention (CPT® 78226 or CPT® 78227)

Left Upper Quadrant (LUQ) Pain (AB-2.4)

AB.AP.0002.4.A

v1.0.2024

- The presence of any red flag findings per **General Guidelines (AB-1.0)** precludes adjudication based on any other criteria.
- Most common causes which may be more specifically evaluated:
 - Splenic etiologies:
 - Suspected trauma, or splenomegaly
 - See: **Spleen (AB-34)**
 - Suspected infarct or abscess (severe pain and tenderness, fever, history of atrial fibrillation)
 - CT Abdomen without and with contrast or with contrast (CPT® 74170 or CPT® 74160)
 - Pancreatic etiologies:
 - Suspected pancreatitis
 - See: **Acute Pancreatitis (AB-33.1)**
 - Renal etiologies
 - Suspected nephrolithiasis
 - See: **Suspected Renal/Ureteral Stone (AB-4.1)**
 - Suspected pyelonephritis or abscess
 - See: **Upper (Pyelonephritis) (AB-40.1)**
 - Suspected small or large bowel etiologies (e.g., ischemia, obstruction, volvulus, diverticulitis)
 - CT Abdomen (CPT® 74160) or CT Abdomen and Pelvis (CPT® 74177)
 - Gastric etiologies
 - If there is concern for peptic ulcer disease, or if the complaint is dyspepsia, without any signs or symptoms suggesting possible perforation or penetration, endoscopy would be the best study for assessing these potential conditions. See: **EGD-1** in the EGD guidelines
 - If there is concern for a more urgent gastric problem, such as perforation, then a CT Abdomen (CPT® 74160) or CT Abdomen and Pelvis (CPT® 74177) can be approved.
 - Suspected aortic dissection
 - See: **Aortic Dissection and Other Aortic Conditions (PVD-6.7)** in the Peripheral Vascular Disease Imaging Guidelines
 - Unknown etiology, simply reported as LUQ pain

- Prior to advanced imaging, an adequate history and physical examination, with lab work to include: CBC, chemistry profile including electrolytes, BUN, creatinine, LFTs (ALT, AST, alkaline phosphatase and bilirubin) lipase, amylase, and urinalysis, should be performed with the intention of trying to establish a potential etiology.
 - All the specific laboratory studies listed are not required, but there should be some studies performed relating to the current episode in order to help direct imaging appropriately.
- CT Abdomen (CPT® 74160) or CT Abdomen and Pelvis (CPT® 74177) is indicated for ANY of the following:
 - History and physical examination and lab studies are negative or inconclusive for establishing a potential etiology

Background and Supporting Information

- LUQ pain is more difficult to categorize with regard to imaging as there are many potential etiologies, which might be better evaluated with different imaging procedures.

Epigastric Pain and Dyspepsia (AB-2.5)

AB.AP.0002.5.A

v1.0.2024

- The presence of any red flag findings per **General Guidelines (AB-1.0)** precludes adjudication based on any other criteria.

Epigastric Pain or Dyspepsia Without Additional Signs or Symptoms

- Epigastric pain or dyspepsia (dyspepsia is defined by the ACG and CAG as predominant epigastric pain lasting at least one month and can be associated with any upper gastrointestinal symptoms such as epigastric fullness, nausea, vomiting, or heartburn) without any red flag findings:
 - Ultrasound Abdomen (CPT® 76700 or CPT® 76705) to assess for biliary/pancreatic disease is the initial study
 - CT Abdomen (CPT® 74160) or MRI Abdomen (CPT® 74183), or MRCP (CPT® 74181 or CPT® 74183), may be appropriate to evaluate positive findings on ultrasound. The use of these advanced imaging procedures to evaluate the ultrasound findings may be specifically addressed in the dedicated guideline.
 - CT Abdomen (CPT® 74160), or MRI Abdomen (CPT® 74183) for persistent symptoms after a negative or inconclusive upper gastrointestinal endoscopy and ultrasound as well as ONE of the following:
 - Test and treat for Helicobacter pylori (H. pylori) and a trial of acid suppression with a proton pump inhibitor (PPI) for 4–8 weeks if eradication is successful, but symptoms do not resolve OR
 - An empiric trial of acid suppression with a PPI for 4–8 weeks.
- NOTE: See imaging for pregnant women **Pregnancy Considerations for Imaging (AB-1.12)**
- For suspicion of superior mesenteric artery syndrome, see: **Superior Mesenteric Artery (SMA) Syndrome (AB-20.4)**

Special Considerations for Suspicion of Pancreatic Cancer

- CT Abdomen with contrast (CPT® 74160), CT Abdomen and Pelvis with contrast (CPT® 74177), or MRI Abdomen without and with contrast (CPT® 74183) is appropriate for suspicion of pancreatic cancer in individuals aged ≥ 60 years with weight loss and any ONE of the following:
 - Diarrhea
 - Back pain
 - Abdominal pain
 - Nausea

- Vomiting
- Constipation
- New onset diabetes
- Abnormal lab results raising the possibility of pancreatic cancer (e.g., elevated CA-19-9, GGTP, alkaline phosphatase, or bilirubin)
- Nondiagnostic or negative prior US
- If none of the above signs or symptoms applies, follow criteria for epigastric pain and dyspepsia
- See also: **Pancreatic Cancer – Suspected/Diagnosis (ONC-13.2)** in the Oncology Imaging Guidelines

Chronic Abdominal Pain (AB-2.6)

AB.AP.0002.6.A

v1.0.2024

- The presence of any red flag findings per **General Guidelines (AB-1.0)** precludes adjudication based on any other criteria.
- Evaluation of Chronic Abdominal Pain (defined as continuous or intermittent symptoms >6 months)
 - Epigastric Pain and Dyspepsia
 - See: **Epigastric Pain and Dyspepsia (AB-2.5)**
 - Right Upper Quadrant Pain
 - See: **Right Upper Quadrant Pain Including Suspected Gallbladder Disease (AB-2.3)**
 - Left Upper Quadrant Pain
 - See: **Left Upper Quadrant (LUQ) Pain (AB-2.4)**
 - Nonspecific, generalized, or lower abdominal pain
 - CT Abdomen with contrast (CPT® 74160) or CT Abdomen and Pelvis with contrast (CPT® 74177) as requested (include pelvis for lower abdominal complaints or findings) for the following:
 - Initial laboratory assessment (see below) is negative or does not provide specific causes for more directed workup (for example, colonoscopy or EGD if iron deficiency anemia is found, or CT Urogram if urinalysis shows hematuria)
 - CBC with differential, chemistry profile including electrolytes, glucose, creatinine, BUN and liver chemistries, ESR, urinalysis, amylase and lipase (for generalized or upper abdominal complaints), thyroid function tests, and serology testing for celiac (if celiac is suspected)

Non-operative Treatment of Acute Appendicitis (AB-2.7)

AB.AP.0002.7.A

v1.0.2024

- Recurrent symptoms or routine post-treatment follow-up, if requested:
 - One-time CT Abdomen and Pelvis with contrast (CPT® 74177)
(Note: Non-operative treatment of acute appendicitis is increasingly utilized. There is an approximately 2% chance of a pathologic finding not initially identified prior to treatment (e.g. Crohn's Disease or an appendiceal neoplasm such as a carcinoid). In view of this, some authors suggest a follow-up imaging study in asymptomatic patients, post-antibiotic treatment.)

Non-chronic Nonspecific Abdominal Pain with No Localizing Findings (AB-2.8)

AB.AP.0002.8.A

v1.0.2024

- The presence of any red flag findings per **General Guidelines (AB-1.0)** precludes adjudication based on any other criteria.
- Nonspecific abdominal pain can have multiple etiologies and be a diagnostic dilemma. Often, the history, physical examination, and laboratory data can guide subsequent workup in individuals presenting with abdominal pain (e.g. RUQ pain would lead to US for the evaluation of cholecystitis). If, despite an initial history and physical examination the clinical suspicion cannot be localized, and there is no specific indication of a significant concern for serious pathology, then further workup and appropriate imaging may be directed by the results of initial lab studies or the results of non-advanced imaging relevant to and ordered for the evaluation of the current complaint being investigated.
- When possible, please use the more specific guideline, depending on clinical presentation and the differential diagnosis offered by the provider:
 - **Right Upper Quadrant Pain including Suspected Gallbladder Disease (AB-2.3)**
 - **Left Upper Quadrant (LUQ) Pain (AB-2.4)**
 - **Epigastric Pain and Dyspepsia (AB-2.5)**
 - **Chronic Abdominal Pain (AB-2.6)**
 - **Flank Pain, Rule Out or Known Renal/Ureteral Stone (AB-4)**
 - **Gastroenteritis (AB-5.1)**
 - **Mesenteric Ischemia (AB-6.1) and Colonic Ischemia (AB-6.2)**
 - **Post-Operative Pain With-in 60 Days Following Abdominal Surgery – Abdominal Procedure (AB-7)**
 - **Bowel Obstruction (AB-20.1) and Gastroparesis (AB-20.2)**
 - **Diarrhea, Constipation, and Irritable Bowel (AB-21)**
 - **Inflammatory Bowel Disease Rule Out Crohn’s Disease or Ulcerative Colitis (AB-23)**
 - **Pancreatitis (AB-33)**
- Evaluation of Nonspecific Abdominal Pain:
 - US Abdomen and/or Pelvis OR
 - CT Abdomen and Pelvis with contrast:
 - Preliminary labs such as CBC, electrolytes, lipase or amylase, urinalysis, ESR or CRP, or LFT's are unrevealing or do not point to a specific etiology

that would otherwise direct more appropriate imaging (such as findings suggestive of pancreatitis or biliary tract disease)

- Note: All the specific laboratory studies listed are not required, but there should be some studies performed relating to the current episode in order to help direct imaging appropriately. (Note: Pregnancy test should be performed prior to CT in all appropriate reproductive age females)
- If a prior US Abdomen and/or Pelvis performed for the current complaint is unrevealing or does not explain the pain
- Special Populations:
 - Pregnant women:
 - US Abdomen and/or Transvaginal and/or complete Pelvis as the initial study
 - MRI Abdomen and/or Pelvis without contrast if US is equivocal

References (AB-2)

v1.0.2024

1. Cartwright S and Knudsen M. Evaluation of Acute Abdominal Pain in Adults. *Am Fam Physician*. 2008 Apr 1;77(7):971-978.
2. Moayyedi PM, Lacy BE, Andrews CN, et al. ACG and CAG Clinical Guideline: Management of Dyspepsia. *Am J Gastroenterol*.
3. Fashier J and Gitu A. Diagnosis and Treatment of Peptic Ulcer Disease and H. pylori infection. *Am Fam Physician* 2015 Feb 15;91(4):236-242.
4. Talley NJ, Vakil N, and the Practice Parameters Committee of the American College of Gastroenterology. Guidelines for the management of dyspepsia. *American Journal of Gastroenterology*, 2005; 100:2324–2337.
5. ACR Appropriateness Criteria® left lower quadrant pain — suspected diverticulitis *The American College of Radiology*. Revised 2014. National Guideline Clearinghouse.
6. Yarmish GM, Smith MP, Rosen MP, et al. Expert Panel on Gastrointestinal Imaging. ACR Appropriateness Criteria® right upper quadrant pain. *J Am Coll Radiol*. 2014;11(3):316–32.
7. Continuing Medical Education: July 2017: ACG and CAG Clinical Guideline: Management of Dyspepsia. *The American Journal of Gastroenterology*. 2017;112(7):987-987. doi:10.1038/ajg.2017.190.
8. Ringel-Kulka, Tamar, et. al. Evaluation of Chronic Abdominal Pain in Adults. Nov 28, 2018. Epocrates (Content by British Medical Journal).
9. Charles, G, Chery, M, King Channell, M. Chronic Abdominal Pain: Tips for the Primary Care Provider. *Osteopathic Family Physician*; Jan/Feb, 2019.11(1).
10. Mendelson R. Diagnostic tests: Imaging for chronic abdominal pain in adults. *Australian Prescriber*. 2015;38(2):49-54. doi:10.18773/austprescr.2015.019.
11. Sakorafas GH. Interval routine appendectomy following conservative treatment of acute appendicitis: Is it really needed. *World Journal of Gastrointestinal Surgery*. 2012;4(4):83. doi:10.4240/wjgs.v4.i4.83.
12. Talan DA, Saltzman DJ, Deugarte DA, Moran GJ. Methods of conservative antibiotic treatment of acute uncomplicated appendicitis. *Journal of Trauma and Acute Care Surgery*. 2019;86(4):722-736. doi:10.1097/ta.0000000000002137.
13. Jang T, Chauhan V, Cundiff C, Kaji AH. Assessment of emergency physician–performed ultrasound in evaluating nonspecific abdominal pain. *The American Journal of Emergency Medicine*. 2014;32(5):457-460. doi:10.1016/j.ajem.2014.01.004.
14. Gans SL, Pols MA, Stoker J, Boermeester MA. Guideline for the Diagnostic Pathway in Patients with Acute Abdominal Pain. *Digestive Surgery*. 2015;32(1):23-31. doi:10.1159/000371583.
15. Lameris W, Randen AV, Es HWV, et al. Imaging strategies for detection of urgent conditions in patients with acute abdominal pain: diagnostic accuracy study. *Bmj*. 2009;338(jun26 2). doi:10.1136/bmj.b2431.
16. American College of Radiology. ACR Appropriateness Criteria. Acute Nonlocalized Abdominal Pain. 2018.
17. DiSaverio S, Podda M, De Simone B, et. al. Diagnosis and treatment of acute appendicitis: 2020 update of the WSES (World Society of Emergency Surgery) Jerusalem guidelines. *World J Emerg Surg*. 2020;15:27. doi:10.1186/s13017-020-00306-3.
18. Garcia EM, Camacho MA, Karolyi DR, et. al. ACR Appropriateness Criteria® right lower quadrant pain – suspected appendicitis. *J Am Coll Radiol*. 2018;15(11S):S373-S387. doi:10.1016/j.jacr.2018.09.033.
19. Longo SA, Moore RC, Canzoneri BJ, Robichaux A. Gastrointestinal conditions during pregnancy. *Clin Colon Rectal Surg*. 2010; 23(2):80-89. doi:10.1055/s-0030-1254294.
20. Guidelines for diagnostic imaging during pregnancy and lactation. Committee Opinion No. 723. American College of Obstetricians and Gynecologists. *Obstet Gynecol*. 2017;130:e210–6.
21. Von-Mühlén B, Franzon O, Beduschi MG, Krüel N, Lupselo D. AIR score assessment for acute appendicitis. *Arg Bras Cir Dig*. 2015;28(3):171-173. doi:10.1590/S0102-672020150003000006.
22. Snyder MJ, Guthrie M, Cagle S. Acute appendicitis: efficient diagnosis and management. *Am Fam Physician*. 2018;98(1):25-33.
23. Hall J, Hardiman K, Lee S, et. al. The American Society of Colon and Rectal Surgeons clinical practice guidelines for the treatment of left-sided colonic diverticulitis. *Dis Colon Rectum*. 2020;63:728-747. doi:10.1097/DCR.0000000000001679.
24. Wilkins T, Embry K, George R. Diagnosis and management of acute diverticulitis. *Am Fam Physician*. 2013;87(9):612-620.
25. Schultz JK, Azhar N, Binda GA, et. al. European Society of Coloproctology: guidelines for the management of diverticular disease of the colon. *Colorectal Disease*. 2020;22(2):5-28. doi:10.1111/codi.15140.
26. Strate LL, Morris AM. Epidemiology, pathophysiology, and treatment of diverticulitis. *Gastroenterology*. 2019;156:1282-1298. doi:10.1053/j.gastro.2018.12.033.

27. Schreyer AG, Layer G. S2K guidelines for diverticular disease and diverticulitis: diagnosis, classification, and therapy for the radiologist. *Rofo*. 2015;187(8):676-84. doi:10.1055/s-0034-1399526.28.
28. Aslanian HR, Lee JH, Canto MI. AGA clinical practice update on pancreas cancer screening in high risk individuals: expert review. *Gastroenterology*. 2020;159(1):358-362. doi:10.1053/j.gastro.2020.03.088.29.
29. National Institute for Health and Care Excellence (NICE). Upper gastrointestinal tract cancers. In: Suspected cancer: recognition and referral. 2015. <https://www.nice.org.uk/guidance/ng12/chapter/Recommendations-organised-by-site-of-cancer#upper-gastrointestinal-tract-cancers>

Abdominal Sepsis (Suspected Abdominal Abscess) (AB-3)

Guideline

Abdominal Sepsis (AB-3.1)

Reference (AB-3)

Abdominal Sepsis (AB-3.1)

AB.AS.0003.1.A

v1.0.2024

- CT Abdomen, or CT Pelvis, or CT Abdomen and Pelvis with contrast (CPT® 74160, or CPT® 72193, or CPT® 74177) for abdominal symptoms associated with fever and/or elevated white blood cell count.¹
- CT Abdomen and Pelvis with contrast (CPT® 74177) interval imaging as requested for intraperitoneal abscess.
- Serial Ultrasound (CPT® 76705) or CT Abdomen, CT Pelvis, or CT Abdomen and Pelvis with contrast (CPT® 74160, or CPT® 72193, or CPT® 74177) studies may be performed for follow-up of known abnormal fluid collections, especially following catheter drainage. The interval can be days, weeks, or months based on the clinical course of the individual.

Reference (AB-3)

v1.0.2024

1. ACR Appropriateness Criteria® Acute (nonlocalized) Abdominal Pain and Fever or Suspected Abdominal Abscess. American College of Radiology, Published 2012. Rev. 2018.

Flank Pain, Rule Out or Known Renal/Ureteral Stone (AB-4)

Guideline

Ultrasound (AB-4.0)

Suspected Renal/Ureteral Stone(s) (AB-4.1)

Observation of Known Renal/Ureteral Stone(s) (AB-4.2)

Follow-Up of Treated Renal/Ureteral Stone (AB-4.3)

Annual Surveillance (AB-4.4)

Nuclear Kidney Imaging (AB-4.5)

References (AB-4)

Ultrasound (AB-4.0)

AB.US.0004.0.A

v1.0.2024

- Retroperitoneal ultrasound (CPT® 76770 or CPT® 76775) can be used in place of CT Abdomen and Pelvis at any of the initial or follow-up indications, if requested by Provider.

Suspected Renal/Ureteral Stone(s) (AB-4.1)

AB.US.0004.1.A

v1.0.2024

- CT Abdomen and Pelvis without contrast (CPT® 74176) is indicated for ANY of the following:
 - Suspected renal/ureteral stone with symptoms in non-pregnant adults (flank pain/renal colic)^{1,2}
 - Suspected staghorn calculi^{12,13,14}
- CT Abdomen and Pelvis without contrast (CPT® 74176) or CT Urogram (CPT® 74178) is indicated for the following:
 - Suspicion renal/ureteral stones (flank pain/renal colic) with hematuria
- Ultrasound (CPT® 76770 or CPT® 76775) or MRI Abdomen and Pelvis without contrast (CPT® 74181 and CPT® 72195) is indicated for the following:
 - Suspected renal/ureteral stone in pregnant women (flank pain/renal colic)^{3,4}
 - The use of gadolinium contrast agents is contraindicated during pregnancy unless the specific need for that procedure outweighs risk to the fetus.
- Suspected renal/ureteral stone in children (flank pain/renal colic)
 - See: **Flank Pain, Renal Stone (PEDAB-4)** in the Pediatric Abdomen Imaging Guidelines

Observation of Known Renal/Ureteral Stone(s) (AB-4.2)

AB.US.0004.2.A

v1.0.2024

- Radiopaque Stones
 - Initial follow-up imaging:
 - Retroperitoneal ultrasound (CPT® 76770 or CPT® 76775) and KUB X-ray
 - Subsequent follow-up imaging:
 - If initial follow-up ultrasound and KUB are negative, and there is no hematuria and individual is asymptomatic:
 - See: **Annual Surveillance (AB-4.4)**
 - If initial follow-up ultrasound and KUB demonstrates hydronephrosis, retained stone, or if the individual has persistent hematuria, or is symptomatic:
 - CT Abdomen and Pelvis without contrast (CPT® 74176)
- Non-radiopaque Stones (i.e. radiolucent)
 - Initial follow-up imaging:
 - CT Abdomen and Pelvis without contrast (CPT® 74176)
 - Subsequent follow-up imaging:
 - If CT is negative:
 - See: **Annual Surveillance (AB-4.4)**
 - If CT demonstrates a retained stone, hydronephrosis, or if the individual is being evaluated for surgery:
 - Further imaging can be considered on an individual basis
- ANY of the following are indicated for surgical/procedural evaluation of staghorn calculi:^{12,13,14}
 - CT Abdomen and Pelvis (contrast as requested)
 - 3-D reconstruction (CPT® 76377 or CPT® 76376)
 - Nuclear kidney imaging (CPT® 78707, CPT® 78708, or CPT® 78709) when there is concern for a poorly functioning kidney

Background and Supporting Information

- Radiopaque versus radiolucent stones on plain radiograph:
 - Radiopaque
 - Calcium-based stones (70-80%)
 - Struvite stones (triple phosphate) (usually opaque but variable – 15-20%)
 - Radiolucent
 - Uric acid (5-10%)

- Cystine (1-3%)
- Medication stones (e.g. indinavir) (1%)

Follow-Up of Treated Renal/Ureteral Stone (AB-4.3)

AB.US.0004.3.A

v1.0.2024

- Post-shock wave lithotripsy (SWL):
 - Retroperitoneal ultrasound (CPT® 76770 or CPT® 76775) is the appropriate initial follow-up imaging.
 - Retroperitoneal ultrasound (CPT® 76770 or CPT® 76775) and/or CT Abdomen and Pelvis (contrast as requested) may be indicated for:
 - Individuals who are symptomatic
 - Individuals with hydronephrosis
 - Individuals who have residual fragments
 - Individuals treated by SWL who have passed fragments, are asymptomatic and without hydronephrosis can be followed according to **Annual Surveillance (AB-4.4)**.
- Post-medical expulsive therapy (MET):
 - Retroperitoneal ultrasound for individuals treated by MET who have passed a stone and are symptomatic.
 - CT Abdomen and Pelvis (contrast as requested) if hydronephrosis is demonstrated with ultrasound.
 - Individuals treated by MET who have passed a stone and are asymptomatic can be followed according to **Annual Surveillance (AB-4.4)**.
- Post-ureteroscopic extraction with an intact stone:
 - Retroperitoneal ultrasound for individuals without symptoms
 - CT Abdomen and Pelvis with contrast (CPT® 74177) for individuals with symptoms or hydronephrosis demonstrated on ultrasound
 - Individuals without symptoms or without hydronephrosis demonstrated on ultrasound can be followed according to **Annual Surveillance (AB-4.4)**.
- Post-ureteroscopic extraction requiring fragmentation of the stone(s):
 - Retroperitoneal ultrasound for individuals without symptoms
 - CT Abdomen and Pelvis without contrast (CPT® 74176) for individuals without symptoms, but hydronephrosis demonstrated on ultrasound
 - Individuals without symptoms or without hydronephrosis demonstrated on ultrasound can be followed according to **Annual Surveillance (AB-4.4)**.
 - Retroperitoneal ultrasound and KUB for individuals with symptoms and a radiopaque stone
 - CT Abdomen and Pelvis without contrast (CPT® 74176) for individuals with symptoms and a non-radiopaque stone
- Post-surgical/procedural treatment of staghorn calculi:

- CT Abdomen and Pelvis without contrast (CPT® 74176)^{12,13,14}
- Retroperitoneal ultrasound and/or CT Abdomen and Pelvis (contrast as requested) may be indicated for individuals with persistent symptoms and/or hydronephrosis.

Annual Surveillance (AB-4.4)

AB.US.0004.4.A

v1.0.2024

- Annual surveillance for stable individuals who have a history of stones may be indicated to assess for stone growth or formation of new stones:
 - Plain X-ray (KUB) should be performed for individuals with radiopaque stones
 - Retroperitoneal ultrasound (CPT® 76770 or CPT® 76775) is the preferred modality for individuals with non-radiopaque stones

Nuclear Kidney Imaging (AB-4.5)

AB.US.0004.5.A

v1.0.2024

- Nuclear kidney imaging (CPT® 78707, CPT® 78708, or CPT® 78709) can be considered for evaluation of any of the following:^{5,6}
 - Recurrent flank pain when CT and ultrasound are non-diagnostic.
 - Prior imaging (CT or ultrasound) shows hydronephrosis and to determine if this truly obstructive in nature.

References (AB-4)

v1.0.2024

1. Fulgham PF, Assimos DG, Pearle MS, et al. Clinical Effectiveness Protocols for Imaging in the Management of Ureteral Calculous Disease: AUA Technology Assessment. *The Journal of Urology*. 2013;189(4):1203-1213.
2. Dubinsky TJ, Sadro CT. Acute Onset Flank Pain—Suspicion of Stone Disease. *Ultrasound Quarterly*. 2012;28(3):239-240.
3. Faerber EN, Benator RM, Browne LP, et al. ACR–SPR Practice Parameter for the Safe and Optimal Performance of Fetal Magnetic Resonance Imaging (MRI). *American College of Radiology*. (Revised 2015).
4. Faerber EN, Abramson SJ, Benator RM, et al. ACR Practice Guideline for Imaging Pregnant or Potentially Pregnant Adolescents and Women with Ionizing Radiation. *American College of Radiology*. (Revised 2013).
5. Banks KP, Green ED, Brown RKJ, et al. ACR–SPR Practice Guideline for the Performance of Renal Scintigraphy. (Revised 2017). *American College of Radiology*.
6. Remer EM, Papanicolaou N, Casalino DD, et al. American College of Radiology Appropriateness Criteria – Renal Failure. *American College of Radiology*. (Revised 2013).
7. Pearle MS, Godfarb DS, Assimos DG. Medical management of kidney stones: AUA guideline. *American Urological Association (AUA)*. 2019.
8. Assimos D, Krambeck A, Miller NL, et al. Surgical Management of Stones: American Urological Association/Endourological Society Guideline, PART I. *Journal of Urology*. 2016;196(4):1153-1160. doi:10.1016/j.juro.2016.05.090.
9. Assimos D, Krambeck A, Miller NL, et al. Surgical Management of Stones: American Urological Association/Endourological Society Guideline, PART II. *Journal of Urology*. 2016;196(4):1161-1169. doi:10.1016/j.juro.2016.05.091.
10. Cheng PM, Moin P, Dunn MD, Boswell WD, Duddalwar VA. What the radiologist needs to know about urolithiasis: part 1 – pathogenesis, types, assessment, and variant anatomy. *AJR Am J Roentgenol*. 2012;198(6):W540-7. doi:10.2214/AJR.10.7285.
11. Gupta K, Feiertag N, Gottlieb J, et al. Imaging after ureteroscopy: practice patterns, patient adherence and impact on subsequent management in an urban academic hospital system. *Urology*. 2023;171:49-56. doi:10.1016/j.urology.2022.08.056.
12. Sharbaugh A, Morgan Nikonow T, Kunkel G, Semins MJ. Contemporary best practice in the management of staghorn calculi. *Ther Adv Urol*. 2019;11:1756287219847099. doi:10.1177/1756287219847099.
13. Marien T, Miller NL. Treatment of the infected stone. *Urol Clin North Am*. 2015;42:459–472. doi:10.1016/j.ucl.2015.05.009.
14. Flannigan R, Choy WH, Chew B, Lange D. Renal struvite stones—pathogenesis, microbiology, and management strategies. *Nat Rev Urol*. 2014;11:333-341. doi:10.1038/nrurol.2014.99.

Gastroenteritis/ Enterocolitis (AB-5)

Guideline

Gastroenteritis/Enterocolitis (AB-5.1)

References (AB-5)

Gastroenteritis/Enterocolitis (AB-5.1)

AB.GE.0005.1.A

v1.0.2024

- The presence of any red flag findings per **General Guidelines (AB-1.0)** precludes adjudication based on any other criteria.
- CT Abdomen and Pelvis with contrast (CPT® 74177) if:
 - Acute abdomen suggesting bowel obstruction, toxic megacolon (abdominal swelling, fever, tachycardia, elevated white blood cell count), or perforation
 - Bloody stools
 - Immunocompromised
 - Previous gastric bypass
- For suspected ischemic enterocolitis, see: **Mesenteric Ischemia (AB-6.1)** or **Colonic Ischemia (Including Ischemic Colitis) (AB-6.2)**

Background and Supporting Information

Gastroenteritis is a nonspecific term which denotes a constellation of symptoms including, to a varying degree, nausea, vomiting, diarrhea, and abdominal pain. It is usually caused by infectious agents such as norovirus. The broad differential of such symptoms evades establishing a guideline to evaluate gastroenteritis, as a specific entity, from an imaging standpoint.

References (AB-5)

v1.0.2024

1. Scorza K, Williams A, Phillips D, et al. Evaluation of Nausea and Vomiting. *American Family Physician*. 2007; 76(1):76-84. Vol. 92, No. 11.
2. DuPont HI, Practice Parameters of the American College of Gastroenterology. Guideline on acute infectious diarrhea in adults. *The American Journal of Gastroenterology*. 1997; 92:1962-1975.

Mesenteric/Colonic Ischemia (AB-6)

Guideline

Mesenteric Ischemia (AB-6.1)

Colonic Ischemia (Including Ischemic Colitis) (AB-6.2)

References (AB-6)

Mesenteric Ischemia (AB-6.1)

AB.MI.0006.1.A

v1.0.2024

- Suspicion of acute mesenteric ischemia, ONE of the following:
 - CTA Abdominal and/or Pelvic (Mesenteric) (CPT® 74174, or CPT® 74175, or CPT® 72191) (preferable), **or**
 - MRA Abdominal and/or Pelvic (CPT® 72198 and/or CPT® 74185), **or**
 - CT Abdomen and Pelvis with contrast (CPT® 74177).
- Post-procedure surveillance imaging following invasive treatment for mesenteric ischemia (celiac, superior mesenteric, and inferior mesenteric angioplasty with or without stenting, or mesenteric artery bypass grafting):
 - Baseline Duplex ultrasound (CPT® 93975 or CPT® 93976) within 1 month of the procedure
 - Duplex ultrasound (CPT® 93975 or CPT® 93976) at 6 months, 12 months, 18 months, and then annually thereafter
 - CT Abdomen or Abdomen and Pelvis with contrast (CPT® 74160 and CPT® 74177) or CTA Abdomen or Abdomen and Pelvis (CPT® 74174 or CPT® 74175) or MRA Abdomen (CPT® 74185) and if requested, MRA Pelvis (CPT® 72198):
 - For symptoms suggesting recurrent ischemia OR
 - In the absence of symptoms, following a Duplex Ultrasound if, on the Duplex study:
 - Celiac axis:
 - PSV >370 cm/s or a substantial increase from the post-treatment baseline PSV (substantial increase has not been defined) or demonstration of restenosis ≥70%
 - Superior mesenteric artery:
 - PSV >420 cm/s, or a substantial increase from the post-treatment baseline PSV (substantial increase has not been defined) or demonstration of restenosis of ≥70%
 - Inferior mesenteric artery:
 - Substantial increase from the post treatment baseline PSV (substantial increase has not been defined).

Background and Supporting Information

- Typical presentation of mesenteric ischemia is based on severe abdominal pain out of proportion to findings on physical exam, usually in individuals with underlying risk factors including cardiovascular disease, atrial fibrillation, hypertension, etc.

Colonic Ischemia (Including Ischemic Colitis) (AB-6.2)

AB.MI.0006.2.A

v1.0.2024

- CT Abdomen and Pelvis with contrast (CPT® 74177) is considered the first imaging modality in order to assess the distribution and phase of the colitis, and it can be performed if abdominal pain **and**:
 - Rectal bleeding; **or**
 - Moderate or severe tenderness; **or**
 - Fever (≥ 101 degrees); **or**
 - Guarding, rebound tenderness, or other peritoneal signs; **or**
 - Elevated WBC as per the testing laboratory's range
- Repeat imaging for asymptomatic or improving individuals, including routine post-operative imaging, is generally not needed.
- CTA Abdomen (CPT® 74175) or CTA Abdomen and Pelvis (CPT® 74174) or MRA Abdomen (CPT® 74185) and if requested, MRA Pelvis (CPT® 72198) can be performed for suspicion of right sided or pancolonic ischemia (as suggested on the initial CT Abdomen and Pelvis or by history/physical examination)

Background and Supporting Information

- Suspicion of colonic ischemia based on sudden cramping abdominal pain accompanied by urgency to defecate and passage of bright red blood, maroon blood, or bloody diarrhea, with risk factors including cardiovascular disease, diabetes mellitus, kidney disease, previous abdominal surgery, use of constipating medications, COPD, and atrial fibrillation.
- As noted in the ACG Clinical Guideline:
 - “In contrast to AMI (*acute mesenteric ischemia*) in which conventional mesenteric angiography or CTA plays an essential role, vascular imaging studies are not indicated in most patients with suspected CI (*colonic ischemia*) because by the time of presentation, colon blood flow has usually returned to normal and the observed changes are not from ongoing ischemia but rather reflect the ischemic insult with or without reperfusion injury”

References (AB-6)

v1.0.2024

1. Fidelman N, Funaki BS, Ray CE, et al. Expert Panel on Interventional Radiology. ACR Appropriateness Criteria® radiologic management of mesenteric ischemia. American College of Radiology (ACR); 2011 (Revised 2016).
2. Menke J. Diagnostic Accuracy Of Multidetector CT In Acute Mesenteric Ischemia: Systematic Review And Meta-Analysis. *Radiology*. 2010; 256: 93-101.
3. Olivia IB, Davarpanah AH, Rybicki FJ, et al. AI ACR Appropriateness Criteria- Imaging of Mesenteric Ischemia 2018. The American College of Radiology.
4. Brandt LJ, Feuerstadt P, Longstreth GF, et al. Epidemiology, Risk Factors, Patterns of Presentation, Diagnosis, and Management of Colonic Ischemia. *American College of Gastroenterology*. 2015; 110: 18-44.
5. Bala M, Kashuk J, Moore EE, et al. Acute mesenteric ischemia: guidelines of the World Society of Emergency Surgery. *World Journal of Emergency Surgery*. 2017;12(1). doi:10.1186/s13017-017-0150-5.
6. Zierler RE, Jordan WD, Lal BK, et al. The Society for Vascular Surgery practice guidelines on follow-up after vascular surgery arterial procedures. *Journal of Vascular Surgery*. 2018;68(1):256-284. doi:10.1016/j.jvs.2018.04.018.
7. Peck MA, Conrad MF, Kwolek CJ, Lamuraglia GM, Paruchuri V, Cambria RP. Intermediate-term outcomes of endovascular treatment for symptomatic chronic mesenteric ischemia. *Journal of Vascular Surgery*. 2010;51(1). doi:10.1016/j.jvs.2009.06.064.
8. Cai W, Li X, Shu C, et al. Comparison of Clinical Outcomes of Endovascular Versus Open Revascularization for Chronic Mesenteric Ischemia: A Meta-analysis. *Annals of Vascular Surgery*. 2015;29(5):934-940. doi:10.1016/j.avsg.2015.01.010.
9. Alahdab F, Arwani R, Pasha AK, et al. A systematic review and meta-analysis of endovascular versus open surgical revascularization for chronic mesenteric ischemia. *Journal of Vascular Surgery*. 2018;67(5):1598-1605. doi:10.1016/j.jvs.2017.12.046.

Post-Operative Pain Within 60 Days Following Abdominal Surgery – Abdominal Procedure (AB-7)

Guideline

Post-Op Pain and/or Complication Within 60 Days (AB-7.1)

References (AB-7)

Post-Op Pain and/or Complication Within 60 Days (AB-7.1)

AB.OP.0007.1.A

v1.0.2024

- CT Abdomen and/or Pelvis with contrast (CPT® 74177, or CPT® 74160, or CPT® 72193) can be performed for suspected postoperative/post procedure complications (For example: bowel obstruction, abscess, anastomotic leak, or post-endoscopic complication).
- Beyond 60 days postoperatively, see: **Abdominal Pain (AB-2)**
- See: **Liver Transplant, Post-Transplant Imaging (AB-42.3)** for post-transplant indications and imaging

References (AB-7)

v1.0.2024

1. ACR Appropriateness Criteria® acute (nonlocalized) abdominal pain and fever or suspected abdominal abscess. American College of Radiology. Published 2012. Rev. 2018.

Abdominal Lymphadenopathy (AB-8)

Guideline

Abdominal Lymphadenopathy (AB-8.1)

Inguinal Lymphadenopathy (AB-8.2)

Sclerosing Mesenteritis and Mesenteric Panniculitis (AB-8.3)

References (AB-8)

Abdominal Lymphadenopathy (AB-8.1)

AB.AL.0008.1.A

v1.0.2024

- History of malignancy
 - Refer to oncology guidelines specific for that known malignancy
 - Biopsy may be considered
- Clinical or lab findings suggesting a lymphoproliferative disorder:
 - Biopsy
 - PET/CT (CPT® 78815) may be considered prior to biopsy in order to determine a more favorable site for biopsy, when a prior biopsy was nondiagnostic, or a relatively inaccessible site is contemplated which would require invasive surgical intervention for biopsy attempt.

Clinical note: Due to its relative lack of specificity as well as higher cost, PET is a less efficient alternative to biopsy.
- If clinical, laboratory findings, biopsy, or PET suggest benign etiology, and no history of malignancy:
 - CT Abdomen and Pelvis (CPT® 74177) at 3 months for follow-up.
 - If no changes at 3 months, 2 additional follow-up scans (at 6 months and one year) can be approved.
 - If no changes by one year, the finding can be considered benign. No further imaging.
- If a follow-up CT demonstrates a concerning change, biopsy should be performed. If biopsy is inconclusive, PET/CT (CPT® 78815) can be approved

Inguinal Lymphadenopathy (AB-8.2)

AB.AL.0008.2.A
v1.0.2024

There is no evidence-based support for advanced imaging of clinically evidenced inguinal lymphadenopathy without biopsy. Advanced imaging should be directed by results of biopsy. If biopsy results are negative or benign, then no advanced imaging is indicated.

If biopsy is positive for malignancy, advanced imaging is guided by sections specific to the histological diagnosis:

- High suspicion of lymphoma: See **Non-Hodgkin Lymphomas (ONC-27)** and **Hodgkin Lymphoma (ONC-28)** in the Oncology Imaging Guidelines
- Prior history of malignancy: See **Metastatic Cancer, Carcinoma of Unknown Primary Site, and Other Types of Cancer (ONC-31)** in the Oncology Imaging Guidelines

Background and Supporting Information

- Localized inguinal lymphadenopathy should prompt:
 - Search for adjacent extremity injury or infection
 - 3 to 4 weeks of observation if clinical picture is benign
 - Excisional or image guided core needle biopsy under ultrasound or CT guidance of most abnormal lymph node if condition persists or malignancy suspected
- Generalized inguinal lymphadenopathy should prompt:
 - Diagnostic work-up, including serological tests, for systemic diseases and
 - Excisional or image guided core needle biopsy under ultrasound or CT guidance of most abnormal lymph node if condition persists or malignancy suspected.

Sclerosing Mesenteritis and Mesenteric Panniculitis (AB-8.3)

AB.AL.0008.3.A

v1.0.2024

- For new or worsening clinical symptoms, or if not previously performed:
 - CT Abdomen and Pelvis without and with contrast (CPT® 74178)
- Requests for follow-up imaging in asymptomatic individuals or for sequential imaging to monitor for the development of malignancy:
 - Further imaging in these scenarios is not supported in the absence of worsening or new clinical symptoms.
- PET imaging is not indicated for the evaluation of Sclerosing Mesenteritis or Mesenteric Panniculitis

Background and Supporting Information

- Sclerosing mesenteritis and mesenteric panniculitis are rare, incompletely understood entities that are characterized by an idiopathic inflammatory condition of the mesentery, with radiologic findings including:
 - Fatty mass lesion in the small intestinal mesentery
 - “Halo” (fat ring) surrounding lymph nodes or vessels
 - Lymph nodes in the fatty mass
 - A “pseudocapsule”
 - “Misty” mesentery
 - Calcifications from fat necrosis
- Sclerosing mesenteritis may represent a spectrum of diseases (retractile mesenteritis, mesenteric panniculitis, and mesenteric lipodystrophy), or may be stages of one disease with progression.
- The chronic inflammation may result in fibrosis with a mass effect and can involve the gut (causing obstruction), the mesenteric vessels, and other intra-abdominal or retroperitoneal organs. The etiology is uncertain, but may be secondary to trauma (previous abdominal surgery), an autoimmune process, ischemia, infection, and possibly may represent a paraneoplastic syndrome secondary to a malignancy, though this is controversial.
- There is an increased prevalence of malignancy in individuals with sclerosing mesenteritis, and this has resulted in requests for sequential imaging in stable or asymptomatic individuals. In addition, requests may be made to assess the clinical response in those undergoing active treatment.
- However, studies have reported that the data on potentially developing a subsequent malignancy is inconclusive and thus “it does not seem justified to subject patients with MP, especially those in whom other associations such as abdomino-pelvic surgery may explain the MP findings, to multiple follow-up CT

scans with the aim of detecting a future malignancy”¹. This recommendation is supported by other authors.^{2,3,4,5}

- In addition, there is no correlation between radiologic and clinical findings, and management decisions are guided by the severity and type of symptoms. Thus, sequential radiologic imaging to assess treatment response is not recommended.²

References (AB-8)

v1.0.2024

1. Nyberg L, Björk J, Björkdahl P, Ekberg O, Sjöberg K, Vigren L. Sclerosing mesenteritis and mesenteric panniculitis – clinical experience and radiological features. *BMC Gastroenterology*. 2017;17(1). doi:10.1186/s12876-017-0632-7.
2. Akram S, Pardi DS, Schaffner JA, Smyrk TC. Sclerosing Mesenteritis: Clinical Features, Treatment, and Outcome in Ninety-Two Patients. *Clinical Gastroenterology and Hepatology*. 2007;5(5):589-596. doi:10.1016/j.cgh.2007.02.032.
3. Green MS, Chhabra R, Goyal H. Sclerosing mesenteritis: a comprehensive clinical review. *Annals of Translational Medicine*. 2018;6(17):336-336. doi:10.21037/atm.2018.07.01.
4. Catlow J, Twemlow M, Lee T. PWE-141 Should we reimaging mesenteric panniculitis? *Small Bowel*. 2017. doi:10.1136/gutjnl-2017-314472.386.
5. Halligan S, Plumb A, Taylor S. Mesenteric panniculitis: systematic review of cross-sectional imaging findings and risk of subsequent malignancy. *European Radiology*. 2016;26(12):4531-4537. doi:10.1007/s00330-016-4298-2.
6. Protin-Catteau L, Thiéfin G, Barbe C, Jolly D, Soyer P, Hoeffel C. Mesenteric panniculitis: review of consecutive abdominal MDCT examinations with a matched-pair analysis. *Acta Radiologica*. 2016;57(12):1438-1444. doi:10.1177/0284185116629829.
7. Bazemore AW and Smucker DR. Lymphadenopathy and malignancy. *American Family* 2002, 66(1), 2103-2111.
8. Heller M, Harisinghani M, Neitlich J, et al. Managing Incidental Findings on Abdominal and Pelvic CT and MRI, Part 3: White Paper of the ACR Incidental Findings Committee II on Splenic and Nodal Findings. *American College of Radiology*, Volume 10, Issue 11, Pages 833-839, November 2013.
9. Gaddey HL, Riegel AM. Unexplained Lymphadenopathy: Evaluation and Differential Diagnosis. *American Family Physician*. 2016 Dec 1;94(11):896-903.

Bariatric Surgery and Percutaneous Gastrostomy (AB-9)

Guideline

Bariatric Surgery (AB-9.1)

Percutaneous Gastrostomy (AB-9.2)

References (AB-9)

Bariatric Surgery (AB-9.1)

AB.BS.0009.1.A

v1.0.2024

- Pre-operative Assessment:
 - Abdominal ultrasound (CPT® 76700 or CPT® 76705) to assess the liver and gallbladder
- Post-operative complications:
 - CT Abdomen and Pelvis with contrast (CPT® 74177) or CT Abdomen with contrast (CPT® 74160) may be used for individuals who have had weight loss surgery and present with suspected complications including:
 - Weight loss failure
 - Heartburn
 - Nausea or vomiting
 - Abdominal pain
 - Fever
 - Abdominal distension
 - Suspected hernia
- Note: Internal hernias in patients who have had Roux-en-Y gastric bypasses may have intermittent and relatively mild abdominal symptoms which require immediate evaluation with CT imaging.
- See: **Post-Operative Pain Within 60 Days Following Abdominal Surgery – Abdominal Procedure (AB-7)**

Background and Supporting Information

- Bariatric procedures include gastric banding, gastric bypass, sleeve gastrectomy, and biliopancreatic diversion procedures.
- Though abdominal pain in post-operative bariatric patients may be gallbladder-induced and an ultrasound would be helpful for this diagnosis, the complications of bariatric surgery can become quickly life-threatening, and so any request for CT imaging in the post-operative bariatric individual should not be delayed with recommendations for ultrasound, even if the examination does not indicate any signs or symptoms of more serious or complicated disease.

Percutaneous Gastrostomy (AB-9.2)

AB.BS.0009.2.A

v1.0.2024

- Percutaneous Endoscopic Gastrostomy (PEG)
 - CT or MRI is generally not needed pre-operatively for PEG placement.
 - CT Abdomen with or without contrast (CPT® 74160 or 74150):
 - For pre-operative assessment in the presence of:
 - Abdominal wall defects such as an open abdomen
 - The presence of “ostomy” sites or drain tubes
 - Abdominal surgical scars or prior major abdominal surgery (e.g. laparotomy, laparoscopy)
 - Known situs inversus
 - Known paraesophageal hernia
 - Previous endoscopic attempt did not achieve adequate transillumination through the abdominal wall or compression and a suitable site for PEG placement could not be determined.
 - Percutaneous Gastrostomy via Interventional Radiologist using CT guidance
 - A pre-operative CT Abdomen with or without contrast (CPT® 74150, 74160) may be appropriate for complicated cases in which a safe window cannot be determined via fluoroscopy. See above indications for CT prior to endoscopic gastrostomy tube placement for pre-operative indications.
 - Suspected complication of an endoscopically or IR-placed gastrostomy or jejunostomy tube:
 - CT Abdomen with or without contrast (CPT® 74150, 74160) or CT Abdomen and Pelvis with or without contrast (CPT® 74176 or 74177)

Background and Supporting Information

- A percutaneous endoscopic gastrostomy utilizes endoscopic guidance in order to place the feeding tube.
- The optimal site for gastrostomy placement is determined by illuminating the abdominal wall from the stomach using the scope and simultaneously indenting the wall with the finger, and visualizing that indentation endoscopically.
 - Routine CT prior to this is generally not needed.
 - A recent study⁵ retrospectively compared complication rates between patients who underwent a pre-procedure CT vs. those that did not, and found no difference in the rate of bleeding events, need for operative intervention, and accidental tube dislodgement.
 - One patient in the non-CT group had an injury due to the tube being placed through the colon, but in that case there was failure of transillumination through the abdominal wall.

- The authors concluded, “routine CT to evaluate for unfavorable anatomy such as overlying liver or transverse colon prior to PEG tube placement does not result in a reduced complication rate. Safe site selection utilizing the correct technique of transillumination of the abdominal wall and visualization of the indentation of the operator’s finger is essential for safe PEG tube placement.”

References (AB-9)

v1.0.2024

1. Gaetke-Udager K, Wasnik A, Kaza R, et al. A Guide To Imaging In Bariatric Surgery. *Emergency Radiology*, June 2014; 21(3):309-319.
2. Levine MS and Carucci LR. Imaging of Bariatric Surgery: Normal Anatomy and Postoperative Complications. *Radiology*. 2014;270(2):327-341.
3. Varghese JC and Roy-Choudhury SH. Radiological imaging of the GI tract after bariatric surgery. *Gastrointestinal Endoscopy*. 2009;70(6):1176-1181.
4. Schneider R, Lazaridis I, Kraljević M, Beglinger C, Wölnerhanssen B, Peterli R. The impact of preoperative investigations on the management of bariatric patients; results of a cohort of more than 1200 cases. *Surgery for Obesity and Related Diseases*. 2018;14(5):693-699. doi:10.1016/j.soard.2018.01.009.
5. Miskimins RJ, Glenn JM, Kamy C, Paffett CL, Arshad S, Auyang ED. Routine CT Prior to PEG tube placement does not reduce complication rates. Poster presented at SAGES 2017 Annual Meeting.
6. Itkin M, DeLegge MH, Fang JC, et. al. Multidisciplinary practical guidelines for gastrointestinal access for enteral nutrition and decompression from the Society of Interventional Radiology and American Gastroenterological Association Institute, with endorsement by Canadian Interventional Radiological Association and Cardiovascular and Interventional Radiological Society of Europe. *AGA*. 2011;131:742-765. doi:10.1053/j.gastro.2011.06.001.
7. Jain R, Maple JT, Anderson MA, et. al. The role of endoscopy in enteral feeding. *Gastrointest Endosc*. 2011;74(1)7-12. doi:10.1016/j.gie.2010.10.021.
8. Arvanitakis M, Gkolfakis P, Despott EJ, et. al. Endoscopic management of enteral tubes in adult patients - part 1: definitions and indications. *Endoscopy*. 2021;53:81-92. doi:10.1055/a-1303-7449.
9. Arvanitakis M, Gkolfakis P, Despott EJ, et. al. Endoscopic management of enteral tubes in adult patients - part 2: peri- and post-procedural management. *Endoscopy*. 2021;53:178-195. doi:10.1055/a-1331-8080.

Blunt Abdominal Trauma (AB-10)

Guideline

Blunt Abdominal Trauma (AB-10.1)

References (AB-10)

Blunt Abdominal Trauma (AB-10.1)

AB.BA.0010.1.A

v1.0.2024

- Abdominal and/or Pelvic ultrasound (CPT® 76700 and/or CPT® 76856) can be approved for the evaluation of blunt abdominal trauma when requested.
- CT Abdomen and/or Pelvis with contrast (CPT® 74160, or CPT® 72193, or CPT® 74177):
 - High probability intra-abdominal injury
 - Abdominal pain or tenderness
 - Pelvic or femur fracture
 - Lower rib fracture
 - Costal margin tenderness or evidence of thoracic wall trauma
 - Diminished breath sounds
 - Vomiting
 - Pneumothorax
 - Hematocrit <30%
 - Hematuria
 - Elevated AST
 - Non-examinable individual (intoxicated, less than fully conscious, Glasgow Coma Scale Score <13, etc.)
 - Evidence of abdominal wall trauma or seat-belt sign
 - If ultrasound demonstrates any definitive abnormalities or inconclusive results

References (AB-10)

v1.0.2024

1. ACR Appropriateness Criteria® blunt abdominal trauma Clinical Practice Guidelines. Guideline Central.
2. Soto JA and Anderson SW. Multidetector CT of Blunt Abdominal Trauma. *Radiology*. 2012;265(3):678-693.
3. Nishijima DK, Simel DL, Wisner DH, et al. Does this adult patient have a blunt intra-abdominal injury? *JAMA* 2012; 307:1517.
4. Washington State Department of Health Office of Community Health Systems: Trauma Clinical Guideline. May 2017. <https://www.doh.wa.gov/Portals/1/Documents/Pubs/530168.pdf>.
5. Jansen JO, Yule SR, Loudon MA. Investigation of blunt abdominal trauma. *Bmj*. 2008;336(7650):938-942. doi:10.1136/bmj.39534.686192.80.
6. Diercks DB, Mehrotra A, Nazarian DJ, Promes SB, Decker WW, Fesmire FM. Clinical Policy: Critical Issues in the Evaluation of Adult Patients Presenting to the Emergency Department With Acute Blunt Abdominal Trauma. *Annals of Emergency Medicine*. 2011;57(4):387-404. doi:10.1016/j.annemergmed.2011.01.013.

Gaucher Disease and Hemochromatosis (AB-11)

Guideline

Gaucher Disease (AB-11.1)

Hereditary (Primary) Hemochromatosis (HH) and Other Iron Storage
Diseases (AB-11.2)

References (AB-11)

Gaucher Disease (AB-11.1)

AB.GD.0011.1.A

v1.0.2024

- See: **Gaucher Disease (Storage Disorders) (PN-6.3)** in the Peripheral Nerve Disorders (PND) Imaging Guidelines

Hereditary (Primary) Hemochromatosis (HH) and Other Iron Storage Diseases (AB-11.2)

AB.GD.0011.2.A

v1.0.2024

- MRI Abdomen without contrast (CPT® 74181) for iron quantification
 - If transferrin iron saturation (TS) $\geq 45\%$ OR Elevated serum ferritin (males >300 ng/ml, females >200 ng/ml)

AND

- Genetic studies for hemochromatosis have been performed and results are ANY of the following:
 - Negative for hemochromatosis
 - C282Y/H63D compound heterozygote
 - C282Y heterozygote
 - Non-C282Y homozygote

Note:

- For C282Y/C282Y homozygote, iron quantification generally not indicated. Workup is as follows:

- If serum ferritin >1000 ug/L or elevated liver enzymes:
- Liver biopsy for fibrosis staging and rule out concurrent liver disease
- If serum ferritin <1000 ug/L and normal liver enzymes:

Therapeutic phlebotomy

(Note: Studies indicate that measurements of hepatic iron concentration by MRI may be more useful in ruling out than diagnosing clinically significant iron overload. MRI can distinguish between primary and secondary iron overload based on iron uptake in the reticuloendothelial system.)

- For the evaluation of suspected hepatic iron overload in chronic transfusional states (e.g., sickle cell disease, thalassemia, oncology patients, bone marrow failure, and stem cell transplant individuals):
 - MRI Abdomen without contrast (CPT® 74181) for iron quantification can be performed annually
- See: **Transfusion-Associated (Secondary) Hemochromatosis (PEDAB-18.2)** in the Pediatric Abdomen Imaging Guidelines regarding transfusion-associated hepatic iron deposition.
- If clinical, biopsy, or radiological findings suggest advanced fibrosis or cirrhosis and HCC surveillance is requested, then follow HCC Screening Guidelines – See: **Chronic Liver Disease, Cirrhosis and Screening for HCC (AB-26.1)**.
- Role of MR Elastography (CPT® 76391):

- The role of MR Elastography to assess the degree of fibrosis in the setting of hemochromatosis is not yet clearly defined and thus not currently approvable.
- One of the main limitations of MR Elastography is that artifact from excess iron deposition degrades signal intensity in MRE sequences, leading to technical failure of elastography and a decrease in MRE's diagnostic reliability. The latest ACG Clinical Guideline (2019) indicates that MRI for the purpose of estimating hepatic iron concentration is appropriate in the circumstances described above. However, "if there is a concomitant need to stage hepatic fibrosis, then liver biopsy is the preferred method."¹⁴ The ACG diagnostic algorithm for the workup of hemochromatosis does not include MR Elastography at any stage, including the evaluation for the presence, absence, or degree of fibrosis.

Background and Supporting Information

- An elevated serum ferritin >1000 mcg/l is associated with an increased risk of cirrhosis and mortality in C282 homozygotes, while a serum ferritin <1000 mcg/l is associated with a very low likelihood of cirrhosis.
- The role of serial MRI for monitoring hepatic iron concentration in hemochromatosis has not been defined. Treatment is phlebotomy and results are monitored by serum ferritin.

References (AB-11)

v1.0.2024

1. Zoller H and Henninger B. Pathogenesis, Diagnosis, and Treatment of Hemochromatosis. *Digestive Diseases*. 2016;34:364-373.
2. Weinreb NJ, Aggio MC, Andersson HC, et al. Gaucher disease type 1: revised recommendations on evaluations and monitoring for adult patients. *Seminars in Hematology*, 2004, 41(4 Suppl 5), 15-22.
3. Taouli B, Ehman RL, Reeder SB. Advanced MRI Methods for Assessment of Chronic Liver Disease. *American Journal of Roentgenology*. 2009;193(1):14-27.
4. Penugonda N. Cardiac MRI in Infiltrative Disorders: A Concise Review. *Current Cardiology Reviews*, 2010, 6(2), 134-136.
5. Chavhan GB, Babyn PS, Thomas B, et al. Principles, Techniques, and Applications of T2*-based MR Imaging and Its Special Applications. *RadioGraphics*. 2009;29(5):1433-1449.
6. Bacon BR, Adams PC, Kowdley KV, et al. Diagnosis and management of hemochromatosis: 2011 Practice Guideline by the American Association for the Study of Liver Diseases. *Hepatology*. 2011;54(1):328-343.
7. Sarigianni M, Liakos A, Vlachaki E, et al. Exam 1: Accuracy of Magnetic Resonance Imaging in Diagnosis of Liver Iron Overload: A Systematic Review and Meta-analysis. *Clinical Gastroenterology and Hepatology*. 2015;13(1). Accessed October 19, 2017. [http://www.cghjournal.org/article/S1542-3565\(14\)00928-8/fulltext](http://www.cghjournal.org/article/S1542-3565(14)00928-8/fulltext).
8. Zoller H, and Henninger B. Pathogenesis, Diagnosis, and Treatment of Hemochromatosis: *Dig Dis* 2016;34:364-373.
9. Kanwar P, Kowdley KV. Diagnosis and treatment of hereditary hemochromatosis: an update. *Expert Review of Gastroenterology & Hepatology*. 2013;7(6):517-530. doi:10.1586/17474124.2013.816114.
10. EASL clinical practice guidelines for HFE hemochromatosis. *Journal of Hepatology*. 2010;53(1):3-22. doi:10.1016/j.jhep.2010.03.001.
11. Bacon BR, Adams PC, Kowdley KV, Powell LW, Tavill AS. Diagnosis and management of hemochromatosis: 2011 Practice Guideline by the American Association for the Study of Liver Diseases. *Hepatology*. 2011;54(1):328-343. doi:10.1002/hep.24330.
12. Initial TS% > 45% Hemochromatosis Diagnosis Algorithm. http://www.irondisorders.org/Websites/idi/files/Content/863362/HHC_Both_April_16_2017.pdf.
13. Kowdley KV, Brown KE, Ahn J, Sundaram V. ACG Clinical Guideline. Hereditary Hemochromatosis. *The American Journal of Gastroenterology*. 2019;1. doi:10.14309/ajg.0000000000000315.
14. Degnan AJ, Ho-Fung VM, Ahrens-Nicklas RC, et al. Imaging of non-neuronopathic Gaucher disease: recent advances in quantitative imaging and comprehensive assessment of disease involvement. *Insights into Imaging*. 2019;10(1). doi:10.1186/s13244-019-0743-5.
15. Wagner M, Corcuera-Solano I, Lo G, et al. Technical Failure of MR Elastography Examinations of the Liver: Experience from a Large Single-Center Study. *Radiology*. 2017;284(2):401-412. doi:10.1148/radiol.2016160863.
16. Ghazizadeh HM, Kröner PT, Stancampiano FF, et al. Hepatic iron overload identified by magnetic resonance imaging-based T2* is a predictor of non-diagnostic elastography. *Quantitative Imaging in Medicine and Surgery*. 2019;9(6):921-927. doi:10.21037/qims.2019.05.13.
17. Yin M, Glaser KJ, Talwalkar JA, Chen J, Manduca A, Ehman RL. Hepatic MR Elastography: Clinical Performance in a Series of 1377 Consecutive Examinations. *Radiology*. 2016;278(1):114-124. doi:10.1148/radiol.2015142141.
18. Fitzsimons EJ, Cullis JO, Thomas DW, Tsochatzis E, Griffiths WJH. Diagnosis and therapy of genetic haemochromatosis (review and 2017 update). *British Journal of Haematology*. 2018;181(3):293-303. doi:10.1111/bjh.15164.

Hernias (AB-12)

Guideline

Inguinal or Femoral Hernia, or Indeterminate Groin Pain (AB-12.1)

Spigelian, Ventral, Umbilical, or Incisional Hernia (AB-12.2)

Hiatal Hernia (AB-12.3)

References (AB-12)

Inguinal or Femoral Hernia, or Indeterminate Groin Pain (AB-12.1)

AB.IH.0012.1.A

v1.0.2024

- Clinical examination alone is usually sufficient for confirming the diagnosis of an evident groin hernia
- If musculoskeletal ailments such as osteitis pubis or athletic pubalgia are in the differential, see: **Pelvis (MS-23)** in the Musculoskeletal Imaging Guidelines.
- Ultrasound, pelvic limited (CPT® 76857) or pelvic complete (CPT® 76856) is the initial imaging study if:
 - Vague groin swelling with diagnostic uncertainty
 - Poor localization of swelling (as might be seen with a small hernia and prominent overlying fat)
 - Intermittent swelling not present on examination
 - Other/indeterminate groin complaints without swelling
- If ultrasound is indeterminate or non-diagnostic, ONE of the following:
 - CT Pelvis with contrast (CPT® 72193) or without contrast (CPT® 72192)
 - MRI Pelvis without contrast (CPT® 72195) or with and without contrast (CPT® 72197)
- For suspected incarceration or strangulation (initial ultrasound is not required):
 - CT Pelvis with contrast (CPT® 72193) or without contrast (CPT® 72192)
- For chronic post-surgical groin pain (after hernia repair):
 - Pelvic ultrasound (CPT® 76856 or CPT® 76857) or US-guided nerve block
 - CT Pelvis with contrast (CPT® 72193) or without contrast (CPT® 72192) or MRI Pelvis without contrast (CPT® 72195) or without and with contrast (CPT® 72197) can be approved if either ultrasound or ultrasound-guided nerve block is indeterminate or non-diagnostic, to assess for other, non-neuropathic causes.

Spigelian, Ventral, Umbilical, or Incisional Hernia (AB-12.2)

AB.IH.0012.2.A

v1.0.2024

- Known or suspected primary or recurrent Spigelian hernia (anterior abdominal wall hernia through the semilunar line), ventral hernia, umbilical, or incisional hernia:
 - CT Abdomen without or with contrast (if at or above the umbilicus) (CPT® 74150 or CPT® 74160) **or**
 - CT Pelvis without or with contrast (if below the umbilicus) (CPT® 72192 or CPT® 72193) **or**
 - CT Abdomen and Pelvis without or with contrast (if above and below the umbilicus, or indeterminate) (CPT® 74176 or CPT® 74177)

Hiatal Hernia (AB-12.3)

AB.IH.0012.3.A

v1.0.2024

- CT Chest and/or Abdomen with contrast (CPT® 71260 and/or CPT® 74160) to evaluate ANY of the following:
 - GI specialist or surgeon or any provider in consultation with one of these specialists request for treatment/pre-operative planning.
 - Suspected complication of primary disease or surgery.

Background and Supporting Information

- Some complications might include suspicion of a gastric volvulus (torsion) within the chest cavity, vomiting, chest pain, and difficulty in swallowing

References (AB-12)

v1.0.2024

1. Yaghmai V, Yee J, Cash B, Expert Panel on Gastrointestinal Imaging. ACR Appropriateness Criteria® palpable abdominal mass. American College of Radiology. Published 2014.
2. LeBlanc KE, LeBlanc LL, LeBlanc KA. Inguinal hernias: Diagnosis and Management. *Am Fam Physician*, 2013;87(12):844-848.
3. Hartman S, Leyendecker JR, Friedman B, et al., Expert Panel on Urologic Imaging. ACR Appropriateness Criteria® acute onset of scrotal pain -- without trauma, without antecedent mass. Reston (VA): American College of Radiology (ACR); Last review date, 2014.
4. International guidelines for groin hernia management. *Hernia*. 2018;22(1):1-165. doi:10.1007/s10029-017-1668-x.
5. Murphy KP, Oconnor OJ, Maher MM. Adult Abdominal Hernias. *American Journal of Roentgenology*. 2014;202(6). doi:10.2214/ajr.13.12071.
6. Peters JH. SAGES guidelines for the management of hiatal hernia. *Surgical Endoscopy*. 2013;27(12):4407-4408. doi:10.1007/s00464-013-3212-0.

Abdominal Mass (AB-13)

Guideline

Abdominal Wall Mass (AB-13.1)

Indeterminate Intra-Abdominal Mass (AB-13.2)

Abnormal Findings on Endoscopy/Colonoscopy (AB-13.3)

References (AB-13)

Abdominal Wall Mass (AB-13.1)

AB.AM.0013.1.A

v1.0.2024

- Abdominal ultrasound and/or Pelvic ultrasound (CPT® 76700 or CPT® 76705 and/or CPT® 76856) is the initial imaging study to assess an abdominal wall or subcutaneous mass.
- MRI Abdomen without and with contrast (CPT® 74183) or CT Abdomen with contrast (CPT® 74160) to assess a suspected malignant or indeterminate mass detected on ultrasound (Pelvic imaging can be included depending on the location of the mass).

Indeterminate Intra-Abdominal Mass (AB-13.2)

AB.AM.0013.2.A

v1.0.2024

- Palpable abdominal mass on physical examination:
 - CT Abdomen with contrast (CPT® 74160) if above the umbilicus
 - CT Abdomen and Pelvis with contrast (CPT® 74177) if extending below the umbilicus
 - CT Pelvis with contrast (CPT® 72193) if involving the pelvis
 - Abdominal ultrasound (CPT® 76700) and/or Pelvis ultrasound (CPT® 76856) may be approved in lieu of CT, if requested
- Indeterminate findings on a prior CT or ultrasound:
 - MRI Abdomen without and with contrast (CPT® 74183)
 - MRI Pelvis without and with contrast (CPT® 72197) may be approved to evaluate if the mass extends below the umbilicus or involves the pelvis
 - Specific lesions mentioned within the Abdomen Imaging Guidelines should be imaged according to those specific sections (e.g., liver lesion, pancreatic cyst, etc.)
- For a pulsatile abdominal mass, suspected aortic aneurysm: See: **Abdominal Aortic Aneurysm (AAA) (PVD-6.3)** in the Peripheral Vascular Disease (PVD) Imaging Guidelines
- For females with a suspected adnexal mass or fibroid: See: **Adnexal Mass/Ovarian Cysts (PV-5)** or **Leiomyomata/Uterine Fibroids (PV-12)** in the Pelvis Imaging Guidelines.
- Pregnant individual:
 - Abdominal and/or Pelvic and/or Transvaginal ultrasound (CPT® 76700 and/or CPT® 76856 and/or CPT® 76830) is appropriate for initial imaging.

Abnormal Findings on Endoscopy/Colonoscopy (AB-13.3)

AB.AM.0013.3.A

v1.0.2024

- Submucosal colonic lesions above the rectum or unexplained colonic extrinsic compression above the rectum:
 - CT Abdomen and Pelvis with contrast (CPT® 74177)
- Colonic Mucosal Mass or Polypoid Lesion above the rectum:
 - If pathology shows invasive cancer OR if colonoscopic findings describe a fungating, ulcerated, bleeding, irregular, circumferential (partial or complete) mass (i.e., findings that suggest a colonic malignancy based on the endoscopic appearance):
 - CT Abdomen and Pelvis with contrast (CPT® 74177), and if requested, CT Chest with contrast (CPT® 71260) (See: **Colorectal Cancer – Initial Work-up/Staging (ONC-16.2)** in the Oncology Imaging Guidelines)
 - If the lesion is in the distal sigmoid:
 - MRI Pelvis without and with contrast (CPT® 72197) if requested can also be performed
 - Pre-operative planning for the surgical (not endoscopic) removal of a polypoid lesion:
 - CT Abdomen and Pelvis with contrast (CPT® 74177)
- Submucosal gastric lesions:
 - CT Abdomen with contrast (CPT® 74160) or CT Abdomen and Pelvis with contrast (CPT® 74177)
 - If endoscopic ultrasound with or without fine-needle aspiration (which is the preferred initial imaging modality to further characterize a gastric submucosal lesion detected on endoscopy) cannot be performed, is indeterminate, or if the findings of the endoscopic ultrasound indicate a need for further imaging.
- Gastric extrinsic compression:
 - CT Abdomen with contrast (CPT® 74160) or CT Abdomen and Pelvis with contrast (CPT® 74177)
- Submucosal rectal lesions or unexplained extrinsic compression in the rectum:
 - MRI Pelvis without and with contrast (CPT® 72197), or, if requested, MRI Pelvis without contrast (CPT® 72195)
 - If rectal endoscopic ultrasound, which is the preferred initial imaging study, cannot be performed (e.g. anal stricture, or severe inflammatory process prohibiting passage of probe, etc.), is indeterminate, or, if based on endoscopic ultrasound findings, additional imaging is needed for further characterization
- Rectal Mucosal Mass or Polypoid Lesion:

- If pathology shows invasive cancer OR if colonoscopic findings describe a fungating, ulcerated, bleeding, irregular, circumferential (partial or complete) mass (i.e., findings that suggest a colonic malignancy based on the endoscopic appearance):
 - CT Abdomen and Pelvis with contrast (CPT® 74177) and if requested, CT Chest with contrast (CPT® 71260)
 - MRI Pelvis without and with contrast (CPT® 72197) or without contrast (CPT® 72195) in addition to the above
- Pre-operative planning for the surgical (not endoscopic) removal of a polypoid lesion:
 - CT Abdomen and Pelvis with contrast (CPT® 74177)
- For further imaging of a documented colonic or rectal malignancy: See **Colorectal Cancer – Initial Work-up/Staging (ONC-16.2)** in the Oncology Imaging Guidelines
- For further imaging of a suspected Gastrointestinal Stromal Tumor (GIST): See **Gastrointestinal Stromal Tumor (GIST) (ONC-12.5)** in the Oncology Imaging Guidelines
- For further imaging of gastric cancer: See **Gastric Cancer - Initial Work-up/Staging (ONC-14.9)** in the Oncology Imaging Guidelines

References (AB-13)

v1.0.2024

1. Lakkaraju A, Sinha R, Garikipati Ret al. Ultrasound for initial evaluation and triage of clinically suspicious soft-tissue masses. *ClinRadiol*, 2009; 64: 615-621.
2. Gaskin CM, Helms CA. Lipomas, Lipoma Variants, and Well-Differentiated Liposarcomas (Atypical Lipomas): Results of MRI Evaluations of 126 Consecutive Fatty Masses. *American Journal of Roentgenology*. 2004;182(3):733-739.
3. Einarsdottir H, Söderlund V, Larsson O, et al. 110 Subfascial Lipomatous Tumors. *Acta Radiologica*. 1999;40(6):603-609.
4. Zoga AC, Weissman BN, Kransdorf MJ, et al. ACR Appropriateness Criteria: Soft Tissue Masses. American College of Radiology, 2012.
5. ACR Appropriateness Criteria. Palpable Abdominal Mass-Suspected Neoplasm. Revised 2019.
6. Evans JA, Chandrasekhara V, Chathadi KV, et al. The role of endoscopy in the management of premalignant and malignant conditions of the stomach. *Gastrointestinal Endoscopy*. 2015;82(1):1-8. doi:10.1016/j.gie.2015.03.1967.
7. Faulx AL, Kothari S, Acosta RD, et al. The role of endoscopy in subepithelial lesions of the GI tract. *Gastrointestinal Endoscopy*. 2017;85(6):1117-1132. doi:10.1016/j.gie.2017.02.022.
8. Benson AB, Venook AP, Al-Hawary MM, et al. National Comprehensive Cancer Network (NCCN) Guidelines Version 2.2021, January 21, 2021. Colon cancer, available at: https://www.nccn.org/professionals/physician_gls/pdf/colon.pdf. Referenced with permission from the NCCN Clinical Practice Guidelines in Oncology (NCCN Guidelines™) for Colon cancer V2.2021,1/21/2021. ©2021 National Comprehensive Cancer Network, Inc. All rights reserved. The NCCN Guidelines™ and illustrations herein may not be reproduced in any form for any purpose without the express written permission of the NCCN. To view the most recent and complete version of the NCCN Guidelines™, go online to NCCN.org.
9. Benson AB, Venook AP, Al-Hawary MM, et al. National Comprehensive Cancer Network (NCCN) Guidelines Version 1.2021, December 22, 2020. Rectal cancer, available at: https://www.nccn.org/professionals/physician_gls/pdf/rectal.pdf. Referenced with permission from the NCCN Clinical Practice Guidelines in Oncology (NCCN Guidelines™) for Rectal cancer V1.2021, 12/22/2020. ©2020 National Comprehensive Cancer Network, Inc. All rights reserved. The NCCN Guidelines™ and illustrations herein may not be reproduced in any form for any purpose without the express written permission of the NCCN. To view the most recent and complete version of the NCCN Guidelines™, go online to NCCN.org.
10. Rex DK, Hassan C, Bourke MJ. The colonoscopist's guide to the vocabulary of colorectal neoplasia: histology, morphology, and management. *Gastrointestinal Endoscopy*. 2017;86(2):253-263. doi:10.1016/j.gie.2017.03.1546
11. Emmanuel A, Gulati S, Ortenzi M, Burt M, Hayee B, Haji A. Radiological staging investigations before endoscopic resection of large colorectal lesions: significant burden with no benefit. *Gut*. 2018;67(Suppl 1). doi:10.1136/gutjnl-2018-bsgabstracts.94.

Lower Extremity Edema (AB-14)

Guideline

Lower Extremity Edema (AB-14)

Lower Extremity Edema (AB-14)

AB.14.A
v1.0.2024

See: **Acute Limb Swelling (PVD-12)** and **Chronic Limb Swelling Due to Venous Insufficiency/Venous Stasis Changes/Varicose Veins (PVD-13)** in the Peripheral Vascular Disease Imaging Guidelines.

Zollinger-Ellison Syndrome (ZES- Gastrinoma) (AB-15)

Guideline

Zollinger-Ellison Syndrome (ZES-Gastrinoma) (AB-15.1)

Zollinger-Ellison Syndrome (ZES- Gastrinoma) (AB-15.1)

AB.15.1.A

v1.0.2024

- See: **Neuroendocrine Cancers and Adrenal Tumors (ONC-15)** in the Oncology Imaging Guidelines

Adrenal Cortical Lesions (AB-16)

Guideline

Adrenal Cortical Lesions (AB-16)

Asymptomatic Adrenal Cortical Lesions (AB-16.1)

References (AB-16.1)

Adrenal Hormone Excess/Symptomatic Adrenal Lesions (AB-16.2)

References (AB-16.2)

Adrenal Insufficiency (AB-16.3)

References (AB-16.3)

Adrenal Nuclear Imaging (AB-16.4)

References (AB-16.4)

Adrenal Cortical Lesions (AB-16)

AB.AC.0016.A
v1.0.2024

Procedure Code	Description
CPT® 74150	CT Abdomen without contrast
CPT® 74160	CT Abdomen with contrast
CPT® 74170	CT Abdomen without and with contrast
CPT® 74181	MRI Abdomen without contrast
CPT® 74183	MRI Abdomen without and with contrast
CPT® 78812	PET, Skull Base to Mid-Thigh
CPT® 78815	PET/CT, Skull Base to Mid-Thigh

Asymptomatic Adrenal Cortical Lesions (AB-16.1)

AB.AC.0016.1.A

v1.0.2024

Overall Considerations

- US is not a prerequisite study for advanced imaging in the evaluation of any adrenal abnormality
- The following recommendations are for asymptomatic individuals
 - Symptomatic refers to signs or symptoms of hormonal excess or abnormal adrenal hormone levels.
 - For symptomatic individuals, see: **Symptomatic Adrenal Cortical Lesions (AB-16.2)**
- Abdominal pain may be present in large or rapidly expanding adrenal tumors due to mass effect or hemorrhage.
 - If the source of abdominal pain is suspected to be an incidental adrenal mass and initial imaging was indeterminate, immediate reimaging with a dedicated adrenal protocol study (see 3 imaging modalities below) is reasonable irrespective of the size of the mass.
 - See: **Abdominal Pain (AB-2)** in the Abdomen Imaging Guidelines for imaging recommendations if abdominal pain is unrelated to the adrenal mass
- The three imaging modalities that can be used for definitive benign characterization of an adrenal mass are:
 - CT Abdomen without contrast (CPT® 74150)
 - CT Abdomen without and with contrast (CPT® 74170)
 - CS-MRI (chemical shift MRI, CPT® 74181)
- The following list represents definitively benign characteristics of the adrenal gland. This list applies wherever "benign characteristics" are mentioned in the table below:
 - ≤ 10 HFU on CT
 - $\geq 60\%$ absolute washout or $\geq 40\%$ relative washout on CT abdomen without and with contrast with calculated washout (adrenal protocol CT, CPT® 74170)
 - An important exception to the washout rule: Non-adenomatous adrenal masses that may show elevated washout on adrenal protocol CT but are not benign include:
 - Adrenal metastasis from hypervascular tumors (e.g. RCC and HCC)
 - Pheochromocytoma
 - Adrenocortical carcinoma
 - Clinical suspicion should be used in these cases to guide further investigation

- Decreased signal on Chemical Shift MRI (CS-MRI, CPT® 74181)
- Cyst (if imaging was completed with and without contrast and "no enhancement"-defined as <10HFU change between unenhanced and enhanced/contrasted CT)
- Adrenal myelolipoma (macroscopic fat)
- If definitively benign diagnosis cannot be made during follow up imaging using dedicated CT adrenal protocol (If <60% absolute washout or <40% relative washout) or lack of signal drop out on MRI chemical shift:
 - Additional imaging is indicated at 6-12 months from initial follow up OR
 - Consider resection for possible primary adrenocortical carcinoma after biochemical evaluation and exclusion of pheochromocytoma.
 - For individuals who are poor surgical candidates, if ordered by or in consultation with an endocrinologist, endocrine surgeon, or urologist:
 - Imaging as requested
- CT Abdomen without and with contrast (CPT® 74170) may be approved in place of any below recommended CT Abdomen without contrast for the following:
 - Facility protocol is to cease imaging if adrenal mass is found to have HFU<10 on initial non-contrasted images
- MRI Abdomen without contrast (CPT® 74181) is indicated in place of CT for the following:
 - Clips that cause artifacts when using CT
 - Allergy to CT contrast
 - Individuals in whom radiation exposure should be limited (children, pregnant individuals, individuals with known germline mutations, and individuals with recent excessive radiation exposure)
- CS MRI may not detect the intracellular lipid in an adrenal mass if HFU is 30 HU or more on CT without contrast. CS MRI is less effective than CT without and with contrast with calculated washout for adenomas with unenhanced attenuation of more than 20 HU
- Below imaging can be applied to bilateral adrenal masses, with each lesion addressed separately.

Mass Characteristics and Appropriate Imaging

Mass Details	Imaging Study
<ul style="list-style-type: none"> • Asymptomatic AND • Incidentally found on US, CT, or MRI of area OTHER than the abdomen or if seen only on US of the abdomen AND • Any size AND • No history of cancer 	<ul style="list-style-type: none"> • CT Abdomen without contrast (CPT® 74150)
<ul style="list-style-type: none"> • Asymptomatic AND • Incidentally found on CT Chest without contrast, entirely imaged, and fully characterized as indeterminate by HFU score AND • >2 cm AND • No history of cancer 	<ul style="list-style-type: none"> • CT Abdomen without and with contrast (CPT® 74170) in lieu of above recommended CT Abdomen without contrast
<ul style="list-style-type: none"> • Asymptomatic AND • Incidentally found on CT or MRI of the Abdomen or Abdomen and Pelvis AND • <1 cm in short axis AND • No history of cancer 	<ul style="list-style-type: none"> • No further imaging indicated <ul style="list-style-type: none"> • It is uncertain as to whether subcentimeter nodularity or adrenal thickening qualifies as an adrenal mass on radiology reports
<ul style="list-style-type: none"> • Asymptomatic AND • Incidentally found on CT or MRI of the Abdomen or Abdomen and Pelvis AND • No prior imaging for comparison AND • Diagnostic with benign imaging characteristics AND • ≥1 cm AND • No history of cancer 	<ul style="list-style-type: none"> • No further imaging, regardless of size <ul style="list-style-type: none"> • The risk of malignancy in a mass with diagnostically benign findings on imaging is extremely low^{1, 3, 7, 8}

Mass Details	Imaging Study
<ul style="list-style-type: none"> Asymptomatic AND 1 cm to 2 cm AND Incidentally detected and indeterminate on any CT or MRI Abdomen or Abdomen and Pelvis AND No prior imaging for comparison AND No history of cancer 	<ul style="list-style-type: none"> Reimaging indicated at 12 months from the initial indeterminate study, as follows: <ul style="list-style-type: none"> CT Abdomen without and with contrast (CPT® 74170 - adrenal protocol), CT Abdomen without contrast (CPT® 74150), or CS-MRI (chemical shift MRI, CPT® 74181) No further imaging is indicated after initial 12 month study if ANY of the following: <ul style="list-style-type: none"> Definitively benign characteristics Stable in size (change <8mm) over >1 year (likely benign adenoma)^{1, 7, 8}
<ul style="list-style-type: none"> Asymptomatic AND >2 cm to <4 cm AND Incidentally detected and indeterminate on any CT or MRI Abdomen or Abdomen and Pelvis AND No prior imaging for comparison AND No history of cancer 	<ul style="list-style-type: none"> Reimaging indicated immediately after initial indeterminate study, as follows: <ul style="list-style-type: none"> CT Abdomen without and with contrast (CPT® 74170 - adrenal protocol), or CS-MRI (chemical shift MRI, CPT® 74181) No further imaging is indicated after initial 12 month study if ANY of the following: <ul style="list-style-type: none"> Definitively benign characteristics Stable in size (change <8mm) over >1 year (likely benign adenoma)^{1, 7, 8}
<ul style="list-style-type: none"> Asymptomatic AND ≥4 cm AND Incidentally detected and indeterminate on any CT or MRI Abdomen or Abdomen and Pelvis AND No prior imaging for comparison AND No history of cancer 	<ul style="list-style-type: none"> Reimaging indicated immediately after initial indeterminate study, as follows: <ul style="list-style-type: none"> CT Abdomen without and with contrast (CPT® 74170) or chemical shift MRI (CPT® 74181) Consider resection for possible primary adrenocortical carcinoma See: Adrenocortical Carcinoma (ONC-15.13) in the Oncology Imaging Guidelines

Mass Details	Imaging Study
<ul style="list-style-type: none"> History of cancer with a likelihood or propensity to metastasize to the adrenal gland or abdomen Incidentally detected and indeterminate on any CT or MRI Abdomen or Abdomen and Pelvis 	<ul style="list-style-type: none"> See: Adrenal Gland Metastases (ONC-31.4) in the Oncology Imaging Guidelines
<ul style="list-style-type: none"> Known adrenal mass with benign characteristics, but newly symptomatic or new hormonal excess 	<ul style="list-style-type: none"> Repeat imaging per Adrenal Hormone Excess/Symptomatic Adrenal Lesions (AB-16.2)

Background and Supporting Information

Benign Adenoma Imaging Characteristics		
	Findings consistent with Adenoma:	Indeterminate for Adenoma:
CT Abdomen without contrast	≤10 Hounsfield Units	>10 Hounsfield Units
CT Abdomen WWO with calculated washout	≥60% absolute washout or ≥40% relative washout	<60% absolute washout <40% relative washout
Chemical Shift MRI	Signal drop out	Lack of signal drop out

- Endocrine guidelines recommend biochemical evaluation in all incidental adrenal lesions (with the exception of myelolipomas and cysts), however laboratory results are NOT required for imaging in an asymptomatic individual.
- Most benign adenomas, which account for up to 75% of adrenal incidentalomas, are lipid rich and thus easily characterized because they measure 10HFU or less on CT without contrast. CT Abdomen without and with contrast with calculated washout and chemical shift MRI help identify lipid poor adenomas which are the next most common group. Masses which remain indeterminate include pheochromocytomas (up to 7%) and primary adrenal cancers or metastases to the adrenal glands (approximately 4%).
- Adrenal masses are often found incidentally on CT scans performed WITH contrast to evaluate abdominal symptoms. While CT scans performed with contrast only may report the HFU of an adrenal mass, most benign adenomas are labeled

"indeterminate" originally because non-contrasted HFU and HFU after washout cannot be measured or calculated.

- An "Adrenal Protocol CT" measures pre-contrast HFU of an adrenal mass as well as the HFU during "wash out" of contrast medium after 60 to 90 seconds [early] and 10 to 15 minutes [delayed]. Benign adenomas show more rapid and efficient contrast washout as compared to malignant adrenal masses.
- When an adrenal mass shows avid enhancement on CT scan (>110 – 120 HU), a pheochromocytoma should be considered.
- In addition to the imaging features in the grid which are considered "diagnostic" of a benign adrenal mass, other radiographic characteristics "suggestive" of a benignity include: smooth/round shape, homogeneous content, lack of calcification/hemorrhage/necrosis, growth rate <1cm/year, lack of FDG avidity on PET, <4cm
- Radiographic characteristics "suggestive" of malignancy include: irregular margins/shape, heterogeneous content, presence of calcification/hemorrhage/necrosis, growth rate >1cm/year, presence of FDG avidity on PET, >4-6cm
- Malignancies most likely to metastasize to the adrenal glands include lung cancer, gastrointestinal cancer, melanoma, and renal-cell carcinoma.

References (AB-16.1)

v1.0.2024

1. Vaidya A, Hamrahian A, Bancos I, Fleseriu M, Ghayee HK. The evaluation of incidentally discovered adrenal masses. *Endocr Pract.* 2019;25(2):178-192.
2. Corwin MT, Remer EM. Adrenal Washout CT: Point-Not Useful for Characterizing Incidentally Discovered Adrenal Nodules. *AJR Am J Roentgenol.* 2021;216(5):1166-1167.
3. Kebebew E. Adrenal Incidentaloma. *N Engl J Med.* 2021;384(16):1542-1551.
4. Grajewski KG, Caoili EM. Adrenal Washout CT: Counterpoint-Remains a Valuable Tool for Radiologists Characterizing Indeterminate Nodules. *AJR Am J Roentgenol.* 2021;216(5):1168-1169.
5. Kiseljak-Vassiliades K, Bancos I, Hamrahian A, et al. American Association of Clinical Endocrinology Disease State Clinical Review on the Evaluation and Management of Adrenocortical Carcinoma in an Adult: a Practical Approach. *Endocr Pract.* 2020;26(11):1366-1383.
6. Zeiger MA, Thompson GB, Duh QY, et al. The American Association of Clinical Endocrinologists and American Association of Endocrine Surgeons medical guidelines for the management of adrenal incidentalomas. *Endocr Pract.* 2009;15 Suppl 1:1-20.
7. Mayo-Smith WW, Song JH, Boland GL, et al. Management of Incidental Adrenal Masses: A White Paper of the ACR Incidental Findings Committee. *J Am Coll Radiol.* 2017;14(8):1038-1044.
8. Expert Panel on Urological Imaging, Mody RN, Remer EM, et al. ACR Appropriateness Criteria® Adrenal Mass Evaluation: 2021 Update. *J Am Coll Radiol.* 2021;18(11S):S251-S267.

Adrenal Hormone Excess/Symptomatic Adrenal Lesions (AB-16.2)

AB.AC.0016.2.A
v1.0.2024

Overall Considerations

- Prior to advanced imaging, adrenal hormone excess must be clinically suspected, and then biochemically confirmed via testing listed in the table below
 - The following imaging recommendations can also be followed in asymptomatic individuals with an adrenal incidentaloma who are found to have abnormalities at initial hormonal evaluation.
- For severe hormone elevation or rapidly progressing symptoms for which adrenocortical carcinoma is suspected, see: **Adrenocortical Carcinoma (ONC-15.13)** in the Oncology Imaging Guidelines.

Condition and Indicated Imaging

Condition	Signs/Symptoms (not required to be documented for imaging)	Laboratory requirements PRIOR TO initial adrenal imaging	Indicated Imaging
<ul style="list-style-type: none"> Suspected cortisol excess (adrenal Cushing's Syndrome) 	<ul style="list-style-type: none"> Weight gain Hyperglycemia/diabetes Low bone mineral density/fractures Hyperpigmented Striae Lipodystrophy ("buffalo hump") 	<ul style="list-style-type: none"> ACTH low/suppressed <p>AND</p> <ul style="list-style-type: none"> Cortisol elevation documented by any of the following: <ul style="list-style-type: none"> Elevated AM cortisol following overnight 1mg dexamethasone suppression (cortisol >1.8 mcg/dL) Elevated late night salivary cortisol Elevated urine free cortisol 	<ul style="list-style-type: none"> CT Abdomen without contrast (CPT® 74150) <ul style="list-style-type: none"> If CT Abdomen without contrast shows an indeterminate adrenal mass, the following is indicated immediately: <ul style="list-style-type: none"> CT Abdomen without and with contrast adrenal protocol (CPT® 74170) OR MRI Abdomen without contrast chemical shift (CPT® 74181)

Condition	Signs/Symptoms (not required to be documented for imaging)	Laboratory requirements PRIOR TO initial adrenal imaging	Indicated Imaging
<ul style="list-style-type: none"> Suspected adrenal hyperandrogenism/virilizing adrenal tumor 	<ul style="list-style-type: none"> Hirsutism Virilization (voice deepening, clitoromegaly) 	<ul style="list-style-type: none"> Elevated serum DHEAS AND/OR Elevated testosterone 	<ul style="list-style-type: none"> CT Abdomen without contrast (CPT® 74150) <ul style="list-style-type: none"> If CT Abdomen without contrast shows an indeterminate mass, the following is indicated immediately: <ul style="list-style-type: none"> CT Abdomen without and with contrast adrenal protocol (CPT® 74170) OR MRI Abdomen without contrast chemical shift (CPT® 74181) In individuals with an elevated testosterone level and an ovarian etiology is suspected, see: <u>Polycystic Ovary Syndrome (PV-8.1)</u> in the Pelvis Imaging Guidelines and <u>Ovarian Cancer-Suspected/Diagnosis (ONC-21.2)</u> in the Oncology Imaging Guidelines.

Condition	Signs/Symptoms (not required to be documented for imaging)	Laboratory requirements PRIOR TO initial adrenal imaging	Indicated Imaging
<ul style="list-style-type: none"> Suspected feminizing adrenal tumor 	<ul style="list-style-type: none"> Gynecomastia Testicular atrophy 	<ul style="list-style-type: none"> Elevated serum estradiol <p>AND</p> <ul style="list-style-type: none"> Non-elevated serum LH <p>AND</p> <ul style="list-style-type: none"> No testicular mass seen on dedicated imaging 	<ul style="list-style-type: none"> CT Abdomen without contrast (CPT® 74150) If CT Abdomen without contrast shows an indeterminate adrenal mass, the following is indicated immediately: <ul style="list-style-type: none"> CT Abdomen without and with contrast adrenal protocol (CPT® 74170) OR MRI Abdomen without contrast chemical shift (CPT® 74181)

Condition	Signs/Symptoms (not required to be documented for imaging)	Laboratory requirements PRIOR TO initial adrenal imaging	Indicated Imaging
<ul style="list-style-type: none"> Suspected primary aldosteronism (Conn's Syndrome) 	<ul style="list-style-type: none"> HTN Hypokalemia 	<ul style="list-style-type: none"> Serum aldosterone >15-20ng/dL in the setting of suppressed renin* and spontaneous hypokalemia (K<3.5mEq/L) <p>OR</p> <ul style="list-style-type: none"> Confirmatory testing** showing lack of aldosterone suppression. (See <u>Background and Supporting Information</u> on renin* levels and confirmatory testing**) 	<ul style="list-style-type: none"> CT Abdomen without contrast (CPT® 74150) <ul style="list-style-type: none"> If CT Abdomen without contrast shows an indeterminate adrenal mass, the following is indicated immediately: <ul style="list-style-type: none"> CT Abdomen without and with contrast adrenal protocol (CPT® 74170) OR MRI Abdomen without contrast chemical shift (CPT® 74181)

Condition	Signs/Symptoms (not required to be documented for imaging)	Laboratory requirements PRIOR TO initial adrenal imaging	Indicated Imaging
<ul style="list-style-type: none"> Suspected pheochromocytoma/ paraganglioma 	<ul style="list-style-type: none"> HTN Palpitations Tremor Pallor Flushing Hyperadrenergic spells 	<ul style="list-style-type: none"> Elevated plasma free metanephrines OR Elevated urinary fractionated metanephrines 	<ul style="list-style-type: none"> CT Abdomen and Pelvis without and with contrast (CPT® 74178), CT Abdomen and Pelvis with contrast (CPT® 74177), or MRI Abdomen (CPT® 74183) and Pelvis (CPT® 72197) without and with contrast See also: <u>Adrenal Nuclear Imaging (AB-16.4)</u> and <u>Adrenal Tumors (ONC-15.10)</u> in the Oncology Imaging Guidelines and <u>Hereditary Paraganglioma-Pheochromocytoma Syndromes (PEDONC-2.13)</u> in the Pediatric and Special Populations Oncology Imaging Guidelines
<ul style="list-style-type: none"> Suspected adrenocortical carcinoma 	<ul style="list-style-type: none"> Rapidly progressive symptoms Elevation of multiple adrenal hormones 	<ul style="list-style-type: none"> NA 	<ul style="list-style-type: none"> See: <u>Adrenocortical Carcinoma (ONC-15.13)</u> in the Oncology Imaging Guidelines

Condition	Signs/Symptoms (not required to be documented for imaging)	Laboratory requirements PRIOR TO initial adrenal imaging	Indicated Imaging
<ul style="list-style-type: none"> Confirmed adrenal hormone excess <p>AND</p> <ul style="list-style-type: none"> Requested for surgical planning <p>AND</p> <ul style="list-style-type: none"> Requested by or in consultation with an Endocrinologist, endocrine surgeon, or Urologist 	<p>NA</p>	<p>NA</p>	<ul style="list-style-type: none"> Repeat imaging as requested

Background and Supporting Information

- Surgery is the management of choice for patients with virilizing adrenal tumors, feminizing adrenal tumors, pheochromocytoma/PGL and suspected adrenocortical carcinoma due to an increased risk of malignancy and/or comorbidity. Adrenal masses that secrete excess cortisol (adrenal Cushing's syndrome) or aldosterone (primary hyperaldosteronism/Conn's syndrome) are rarely malignant; however, surgery is also definitive management.

Suspected cortisol excess (adrenal Cushing's syndrome)

- Low or suppressed ACTH levels (<10 pg/mL) are consistent with an adrenal source.
- DHEAS levels are also low in adrenal Cushing's syndrome.
- The diagnosis of Cushing's syndrome can be delayed for years due to the insidious nature of clinical presentation and the complexity of diagnostic testing.

Suspected adrenal hyperandrogenism/virilizing adrenal tumor

- Testosterone is produced by both the ovary (primary source) and adrenal gland while DHEA and DHEAS are produced almost exclusively by the adrenal gland.

- The magnitude of the androgen level is of poor predictive value for tumors, although a very high testosterone (adult-male range) or DHEAS level ($>700 \mu\text{g/dL}$) is suggestive.

Suspected feminizing adrenal tumor

- Adrenal tumors, mainly carcinomas (extremely rare, 0.5–2.0 per million), can secrete both estrogens and high amounts of adrenal androgens, which aromatize to estrogens. In this case, gynecomastia is usually of recent onset, progresses rapidly and testicular atrophy can also be seen.
- Common causes of excessive endogenous estrogens should be excluded prior to adrenal imaging. These include increased secretion from testis (Leydig cell or Sertoli cell tumors, stimulation of normal Leydig cells by LH or hCG) and increased aromatization of androgens to estrogens (aging, obesity, alcoholic cirrhosis, hyperthyroidism, drugs, hCG-secreting tumors, aromatase excess syndrome).

Suspected primary aldosteronism (Conn's syndrome)

- A positive screen for primary aldosteronism is an aldosterone level $>15\text{-}20\text{ng/dL}$ in the setting of suppressed renin* (plasma renin activity $<0.6\text{-}1.0\text{ng/mL/hour}$ or plasma renin concentration $<5\text{-}8.2 \text{ mU/L}$) and spontaneous hypokalemia ($\text{K} < 3.5\text{mEq/L}$).
- The most common dynamic confirmatory tests include the oral sodium suppression test, the seated intravenous saline suppression test, the fludrocortisone suppression test, and the captopril challenge test and results that indicate a "positive" result are unique to the each test. For example, if oral sodium loading is used, a 24-hour urine aldosterone excretion of more than 12 mg in the setting of 24-hour urine sodium excretion of more than 200 mEq is diagnostic of primary aldosteronism (and values of more than 10 mg/24 hours are strongly suggestive).
- Primary hyperaldosteronism may be managed medically with mineralocorticoid receptor antagonists (spironolactone and eplerenone) in cases of bilateral adrenal disease or poor surgical candidacy. If there has been no recent adrenal imaging, reimaging can be considered in cases of diagnostic uncertainty or poor response to medical therapy.

Suspected pheochromocytoma/paraganglioma

- A pheochromocytoma (85% of chromaffin tumors) arises from the chromaffin cells in the adrenal medulla and commonly produces one or more of the following catecholamines: epinephrine, norepinephrine and dopamine.
- A paraganglioma (15-20% of chromaffin tumors) arises from the extra-adrenal chromaffin cells of the sympathetic paravertebral ganglia of the thorax, abdomen and pelvis (catecholamine producing) or the parasympathetic ganglia along the

glossopharyngeal and vagal nerves in the neck and base of skull (not catecholamine producing).

- Cases of pheochromocytoma/paraganglioma can be sporadic but 1/3 are hereditary and due to germ-line mutations that may increase malignant potential.

Suspected adrenocortical carcinoma

- Adrenocortical carcinoma may be suspected radiographically or clinically. Approximately 60% of patients present with evidence of adrenal steroid hormone excess, with or without virilization. Hormonally inactive ACCs typically produce symptoms related to tumor burden, including abdominal pain, back pain, early satiety, and weight loss.
- See: **Adrenocortical Carcinoma (ONC-15.13)**

References (AB-16.2)

v1.0.2024

1. Fleseriu M, Auchus R, Bancos I, et al. Consensus on diagnosis and management of Cushing's disease: a guideline update. *Lancet Diabetes Endocrinol*. 2021;9(12):847-875. doi:10.1016/S2213-8587(21)00235-7
2. Vaidya A, Hamrahian A, Bancos I, Fleseriu M, Ghayee HK. The evaluation of incidentally discovered adrenal masses. *Endocr Pract*. 2019;25(2):178-192.
3. Nieman LK, Biller BM, Findling JW, et al. Treatment of Cushing's Syndrome: An Endocrine Society Clinical Practice Guideline. *J Clin Endocrinol Metab*. 2015;100(8):2807-2831.
4. Goodman NF, Cobin RH, Futterweit W, et al. American association of clinical endocrinologists, american college of endocrinology, and androgen excess and pcos society disease state clinical review: guide to the best practices in the evaluation and treatment of polycystic ovary syndrome--part 1. *Endocr Pract*. 2015;21(11):1291-1300.
5. Fassnacht M, Arlt W, Bancos I, et al. Management of adrenal incidentalomas: European Society of Endocrinology Clinical Practice Guideline in collaboration with the European Network for the Study of Adrenal Tumors. *Eur J Endocrinol*. 2016;175(2):G1-G34.
6. Martin KA, Anderson RR, Chang RJ, et al. Evaluation and Treatment of Hirsutism in Premenopausal Women: An Endocrine Society Clinical Practice Guideline. *J Clin Endocrinol Metab*. 2018;103(4):1233-1257.
7. Shah MH, Goldner WS, Benson AB, et al. Neuroendocrine and Adrenal Tumors, Version 2.2021, NCCN Clinical Practice Guidelines in Oncology. *J Natl Compr Canc Netw*. 2021;19(7):839-868. Published 2021 Jul 28.
8. Carlson HE. Approach to the patient with gynecomastia. *J Clin Endocrinol Metab*. 2011;96(1):15-21.
9. Kanakis GA, Nordkap L, Bang AK, et al. EAA clinical practice guidelines-gynecomastia evaluation and management. *Andrology*. 2019;7(6):778-793.
10. Funder JW, Carey RM, Mantero F, et al. The Management of Primary Aldosteronism: Case Detection, Diagnosis, and Treatment: An Endocrine Society Clinical Practice Guideline. *J Clin Endocrinol Metab*. 2016;101(5):1889-1916.
11. Vaidya A, Carey RM. Evolution of the Primary Aldosteronism Syndrome: Updating the Approach [published correction appears in *J Clin Endocrinol Metab*. 2021 Jan 1;106(1):e414]. *J Clin Endocrinol Metab*. 2020;105(12):3771-3783.
12. Hundemer GL, Vaidya A. Primary Aldosteronism Diagnosis and Management: A Clinical Approach. *Endocrinol Metab Clin North Am*. 2019;48(4):681-700.
13. Lenders JW, Duh QY, Eisenhofer G, et al. Pheochromocytoma and paraganglioma: an endocrine society clinical practice guideline. *J Clin Endocrinol Metab*. 2014;99(6):1915-1942.

Adrenal Insufficiency (AB-16.3)

AB.AC.0016.3.A

v1.0.2024

- CT Abdomen (contrast as requested), or MRI Abdomen (contrast as requested) if CT is contraindicated, if the cause of primary adrenal insufficiency is unclear.
- Imaging is NOT indicated if clinical presentation and labs are consistent with any of the following:
 - Primary autoimmune destruction of the adrenal cortex (Addison's disease)
 - Congenital adrenal hyperplasia
 - Adrenoleukodystrophy

Background and Supporting Information

- Imaging can detect infiltrative disease, adrenal hemorrhage, infections, and malignant tumors which may be the cause of adrenal dysfunction

References (AB-16.3)

v1.0.2024

1. Bornstein SR, Allolio B, Aert W, et al. Diagnosis and Treatment of Primary Adrenal Insufficiency: An Endocrine Society Clinical Practice Guideline. *J Clin Endocrinol Metab.* 2016;101(2):364-389.

Adrenal Nuclear Imaging (AB-16.4)

AB.AC.0016.4.A

v1.0.2024

Nuclear medicine imaging can assist in the evaluation of adrenal masses not adequately characterized by CT or MRI.

- Evaluation of SUSPECTED pheochromocytoma or paraganglioma:
 - MIBG (Any ONE of the following codes can be approved: CPT® 78801, CPT® 78802, or CPT® 78804
 - Any ONE of the following codes may also be approved, individual or in combination with CPT® 78801, 78802, 78804: SPECT studies (CPT® 78803 or CPT® 78831), or hybrid SPECT/CT studies (CPT® 78830 or CPT® 78832)
 - Octreotide scans can be approved in place of MIBG scans (with the same CPT codes) as requested in rare clinical circumstances including head and neck paragangliomas
- For PET/CT indications and for cases of KNOWN pheochromocytoma or paraganglioma, see: **Adrenal Tumors (ONC-15.10-15.12)** in the Oncology Imaging Guidelines
- Evaluation of SUSPECTED neuroblastoma, ganglioneuroblastoma, or ganglioneuromas:
 - MIBG (Any ONE of the following codes can be approved: CPT® 78801, CPT® 78802, or CPT® 78804)
 - Any ONE of the following codes may also be approved, individual or in combination with CPT® 78801, 78802, 78804: SPECT studies (CPT® 78803 or CPT® 78831), or hybrid SPECT/CT studies (CPT® 78830 or CPT® 78832)
- For KNOWN neuroblastoma, ganglioneuroblastoma, or ganglioneuroma, see **Neuroblastoma (PEDONC-6)** in the Pediatric and Special Populations Oncology Imaging Guidelines
- Adrenal Nuclear Imaging of the cortex and/or medulla (single site, planar imaging of the adrenal gland only) (CPT® 78075) includes the adrenal scintigraphy scans for 131I-iodocholesterol (NP-59) as well as MIBG (Iodine i-123 iobenguane and Iodine i-131 iobenguane sulfate) scans
 - 131I-iodocholesterol (NP-59) scans for adrenal cortex imaging can be useful in cases of suspected hyperaldosteronism and adrenal Cushing's, however NP-59 is not readily available for use in the United States
 - MIBG (Iodine i-123 iobenguane and Iodine i-131 iobenguane sulfate) scans for adrenal medulla imaging can be helpful in cases of known pheochromocytoma or neuroblastoma
 - CPT® 78075 is insufficient for the initial evaluation of a suspected pheochromocytoma, paraganglioma or neuroblastoma as this study does not evaluate extra-adrenal sites of disease, but can be considered in rare circumstances

- SPECT and SPECT/CT codes as listed above for MIBG can be added to CPT® 78075 as requested
- History of multiple endocrine neoplasia syndromes: See **Multiple Endocrine Neoplasias (MEN) (PEDONC-2.8)** in the Pediatric and Special Populations Oncology Imaging Guidelines.
- History of Neurofibromatosis: there is insufficient evidence to support routine imaging of adult patients with Neurofibromatosis in asymptomatic patients. See: **Adrenal Hormone Excess/Symptomatic Adrenal Lesions (AB-16.2)** if there is concern for pheochromocytoma. Labs would be required before imaging as stated in guideline.
- History of von Hippel-Lindau disease: See **Von Hippel-Lindau Syndrome (VHL) (PEDONC-2.10)** in the Pediatric and Special Populations Oncology Imaging Guidelines.

References (AB-16.4)

v1.0.2024

1. Taïeb D, Timmers HJ, Hindié E, et al. EANM 2012 guidelines for radionuclide imaging of pheochromocytoma and paraganglioma. *Eur J Nucl Med Mol Imaging*. 2012;39(12):1977-1995.
2. Carrasquillo JA, Chen CC, Jha A, et al. Imaging of Pheochromocytoma and Paraganglioma. *J Nucl Med*. 2021;62(8):1033-1042.
3. Arnold DT, Reed JB, Burt K. Evaluation and management of the incidental adrenal mass. *Proc (Bayl Univ Med Cent)*. 2003;16(1):7-12 .

Abdominal Aortic Aneurysm (AAA), Iliac Artery Aneurysm (IAA), and Visceral Artery Aneurysms Follow-Up of Known Aneurysms and Pre-Op Evaluation (AB-17)

Guideline

Abdominal Aortic Aneurysm (AAA) (AB-17.1)

Iliac Artery Aneurysm (IAA) (AB-17.2)

Visceral Artery Aneurysm (AB-17.3)

Abdominal Aortic Aneurysm (AAA) (AB-17.1)

AB.17.1.A

v1.0.2024

- See: **Abdominal Aortic Aneurysm (AAA) (PVD-6.3)** in the Peripheral Vascular Disease Imaging Guidelines

Iliac Artery Aneurysm (IAA) (AB-17.2)

AB.17.2.A

v1.0.2024

- See: **Iliac Artery Aneurysm (IAA) (PVD-6.4)** in the Peripheral Vascular Disease Imaging Guidelines

Visceral Artery Aneurysm (AB-17.3)

AB.17.3.A

v1.0.2024

- See: **Visceral Artery Aneurysm (PVD-6.5)** in the Peripheral Vascular Disease Imaging Guidelines

Abdominal Aortic Aneurysm (AAA) and Iliac Artery Aneurysm (IAA)-Post Endovascular or Open Aortic Repair (AB-18)

Guideline

AAA, IAA, Post Endovascular or Open Aortic Repair (AB-18.1)

AAA, IAA, Post Endovascular or Open Aortic Repair (AB-18.1)

AB.18.1.A

v1.0.2024

- See: **Post Aortic Endovascular/Open Surgery Surveillance Studies (PVD-6.8)** in the Peripheral Vascular Disease Imaging Guidelines

Aortic Dissection and Imaging for Other Aortic Conditions (AB-19)

Guideline

Aortic Dissection and Other Aortic Conditions (AB-19.1)

Imaging for Other Aortic Conditions (AB-19.2)

Aortic Dissection and Other Aortic Conditions (AB-19.1)

AB.19.1.A

v1.0.2024

- See: **Aortic Imaging** in the Peripheral Vascular Disease Imaging Guidelines

Imaging for Other Aortic Conditions (AB-19.2)

AB.19.2.A

v1.0.2024

- See: **Aortic Imaging** in the Peripheral Vascular Disease Imaging Guidelines

Bowel Obstruction, Gastroparesis, and Bloating (AB-20)

Guideline

Bowel Obstruction (AB-20.1)

Gastroparesis and Dumping Syndrome (AB-20.2)

Nausea and Vomiting as the Primary Symptom (AB-20.3)

Superior Mesenteric Artery (SMA) Syndrome (AB-20.4)

Bloating, Gas, and Distention (AB-20.5)

References (AB-20)

Bowel Obstruction (AB-20.1)

AB.BO.0020.1.A
v1.0.2024

- Suspected bowel obstruction:
 - CT Abdomen and Pelvis with contrast (CPT® 74177)
 - Pediatric individuals:
 - MRI Abdomen and Pelvis without and with contrast (CPT® 74183 and CPT® 72197) can be approved if requested
 - Pregnant individuals:
 - MRI Abdomen and Pelvis without contrast (CPT® 74181 and CPT® 72195)
 - If the etiology or level of suspected intermittent or low-grade small bowel obstruction remains undetermined and additional imaging is needed after CT Abdomen and Pelvis:
 - CT Enteroclysis (CPT® 74176 or CPT® 74177) or
 - CT Enterography (CPT® 74177) or
 - MR Enteroclysis (CPT® 74183 and CPT® 72197) or
 - MR Enterography (CPT® 74183 and CPT® 72197)
- If there is a suspected small bowel tumor as a cause of the small bowel obstruction (including a history of no prior abdominal or pelvic surgery, no known hernia and/or concomitant obscure GI bleeding):
 - CT Enterography (CPT® 74177)
- Small bowel obstruction suspected to be secondary to Crohn's Disease:
 - See: **IBD (Crohn's Disease or Ulcerative Colitis) (AB-23.1)** and **Known IBD (AB-23.2)**
- Bariatric surgery patients, see: **Bariatric Surgery (AB-9.1)**

Background and Supporting Information

- Complete or high-grade obstruction can be defined as no fluid or gas passing beyond the site of obstruction. In incomplete or partial obstruction (low-grade), some fluid or gas passes beyond the point of obstruction. However, a plain film is not required prior to advanced imaging for suspicion of either high- or low- grade obstruction.

Gastroparesis and Dumping Syndrome (AB-20.2)

AB.BO.0020.2.A

v1.0.2024

Gastroparesis

- Gastric Emptying Study (CPT® 78264) for suspicion of delayed gastric emptying and ONE of the following:
 - Nausea, or vomiting of old food ingested several hours earlier
 - Bloating
 - Early satiety, or postprandial fullness
 - Recurrent aspiration
 - Unexplained poor glucose control in diabetes
 - Gastroesophageal reflux refractory to medical management
 - Non-ulcer dyspepsia
 - Retained gastric contents on endoscopy
- Gastric emptying study with small bowel transit (CPT® 78265) can be used in the evaluation of suspected abnormalities in both total and regional times for gastrointestinal transit in small bowel.
- Gastric emptying study with small bowel and colon transit (CPT® 78266) can be used in the evaluation of suspected abnormalities in both total and regional time for gastrointestinal transit to the colon.

Dumping Syndrome

- Gastric Emptying Study (CPT® 78264) to evaluate signs or symptoms of dumping syndrome is not indicated
- Dumping syndrome is a common complication of gastric and bariatric surgery in which changes in anatomy and innervation promote a rapid emptying of gastric contents into the small bowel. This triggers a series of physiologic responses. “Early dumping”, occurring within the first hour after a meal is characterized by abdominal pain, bloating, gassiness, nausea, vomiting, and diarrhea as well as vasomotor symptoms such as flushing, sweatiness, tachycardia, and hypotension). “Late dumping” symptoms occurring between 1 and 3 hours after meals are usually related to hypoglycemia (e.g., weakness, confusion, syncope).
- Dumping syndrome is usually a clinical diagnosis and the recommended diagnostic testing is an oral glucose tolerance test.
- Evidence-based guidelines have recently concluded that gastric emptying tests have low sensitivity and specificity for dumping syndrome, and that a gastric emptying test showing rapid emptying rate would not be used to confirm a diagnosis of dumping syndrome. Rapid emptying can occur in other conditions, and it has been demonstrated that the initial rapid emptying in dumping may produce symptoms such as nausea, which then delays gastric emptying, such that the

results of a gastric emptying study are in the normal range. Because of these limitations, recent guidelines have concluded that "...gastric emptying testing seems to be of low utility in diagnosing dumping syndrome".¹⁸

Note: If both a solid-phase and a liquid-phase gastric emptying imaging study are performed on the same day by any protocol, CPT® 78264 may not be reported with two units, only 1 unit. However, if a solid-phase study is performed, and then on a later date a liquid-phase study is performed, one unit of CPT® 78264 may be reported for each date of service. This occurrence should be rare, however, as there are dual-phase imaging protocols that should be employed if both are known to be needed prior to the start of the first study.

Nausea and Vomiting as the Primary Symptom (AB-20.3)

AB.BO.0020.3.A

v1.0.2024

- The presence of any red flag findings per **General Guidelines (AB-1.0)** precludes adjudication based on any other criteria
- Nausea and vomiting as the Primary Symptom
 - An initial assessment should be performed prior to imaging requests. The initial assessment should include a history with a delineation of the duration, frequency, and severity of symptoms, including a description of their characteristics and any associated symptoms. The purpose of the initial assessment is to define whether the symptom complex suggests a central (neurologic), endocrine (e.g. pregnancy, thyroid disorder), iatrogenic (chemotherapy/medication-induced), obstructive (e.g., low-grade small bowel obstruction), or a mucosal (gastritis, peptic ulcer disease) etiology. Diagnostic testing for nausea and vomiting should be targeted at finding the etiology suggested by a thorough history and physical examination. In the absence of more complicated or serious disease, if the cause is not obvious or suggestive from the history and physical, laboratory data including a CBC, chemistry profile, and, in a reproductive-age female, pregnancy testing, should be performed prior to advanced radiographic imaging. Imaging is based on the findings of the initial evaluation as follows:
 - CT Abdomen and Pelvis with contrast (CPT® 74177) for ANY of the following:
 - If the initial assessment does not suggest a specific cause
 - If the evaluation proves unproductive
 - Symptoms suggesting mucosal disease (e.g. GERD, suspicion of ulcer disease):
 - EGD prior to advanced imaging
 - If nausea and vomiting remains unexplained despite workup and CT Abdomen and Pelvis is negative:
 - Gastric emptying study (CPT® 78264)
 - Symptoms suggesting an intracranial etiology (vertigo/nystagmus, associated headache, or neurogenic vomiting suggested by a positional nature and/or associated with other neurologic signs and symptoms):
 - See: **Headache (HD-11)** , **Dizziness, Vertigo and Syncope (HD-23)** , or other Head Imaging Guidelines depending on the predominant neurologic presentation
 - See: **General Guidelines – Other Imaging Situations (HD-1.7)** in the Head Imaging Guidelines for persistent, unexplained nausea and vomiting, when GI evaluation is negative.

- Nausea and vomiting associated with RUQ pain and suspicion of gallbladder disease, see: **Right Upper Quadrant Pain including Suspected Gallbladder Disease (AB-2.3)**
- Nausea and vomiting associated with dyspeptic symptoms, or epigastric pain, see: **Epigastric Pain and Dyspepsia (AB-2.5)**

Superior Mesenteric Artery (SMA) Syndrome (AB-20.4)

AB.BO.0020.4.A

v1.0.2024

- CTA Abdomen (CPT® 74175) or MRA Abdomen (CPT® 74185) are indicated for clinical suspicion of SMA syndrome and ANY of the following:
 - Risk factors or radiographic/EGD findings as noted below:
 - Recent significant weight loss which leads to a loss of retroperitoneal fat
 - Presence of a severe debilitating illness such as malignancy, malabsorption syndromes, AIDS, trauma, and burns.
 - History of corrective spine surgery for scoliosis
 - Anorexia Nervosa
 - Abdominal surgery
 - Congenital short ligament of Treitz
 - Radiologic findings or history suggestive of duodenal obstruction
 - Failure to diagnose either persistent nausea and vomiting despite the workup outlined in **Nausea and Vomiting as the Primary Symptom (AB-20.3)**

Background and Supporting Information

- SMA syndrome is a rare cause of duodenal obstruction in which there is a decrease in the aortomesenteric angle with resulting compression of the duodenum by the SMA.
- The typical clinical scenario includes an episode of weight loss followed by chronic food intolerance with nausea and vomiting, further weight loss, and epigastric pain, and can be relieved by lying prone or in the left lateral decubitus position.
- The diagnosis can be suspected with barium studies demonstrating delayed passage of contrast beyond the duodenum, dilatation of the first and second portions of the duodenum, anti-peristaltic flow of barium proximal to the obstruction, and relief of obstruction when placed in the prone, knee-chest, or left lateral position, or with an upper endoscopy revealing pulsatile extrinsic compression of the duodenum, or plain films suggesting duodenal obstruction.

Bloating, Gas, and Distention (AB-20.5)

AB.BO.0020.5.A

v1.0.2024

- For bloating as the primary symptom, present for at least 3 months, see: **Irritable Bowel Syndrome (AB-21.4)**
- For documented suspicion of bowel obstruction (e.g., patients with prior abdominal surgery, previous history of SBO, known adhesions, history of Crohn's Disease, etc.) see: **Bowel Obstruction (AB-20.1)**.
- If associated with constipation, see: **Constipation (AB-21.3)**
- If associated with dyspeptic symptoms, see: **Epigastric Pain/Dyspepsia (AB-2.5)**
- CT Abdomen and Pelvis with contrast (CPT® 74177) if any of the following is present:
 - History of malignancy with a likelihood or propensity to metastasize to abdomen
 - Fever (≥ 101 degrees Fahrenheit)
 - Elevated WBC $> 10,000$, or above the upper limit of normal for the particular lab reporting the result
 - Low WBC (absolute neutrophil count < 1000)
 - Palpable mass of clinical concern and/or without benign features
 - GI bleeding, overt or occult, not obviously hemorrhoidal
 - Abdominal tenderness documented as moderate or severe
 - Peritoneal signs, such as guarding or rebound tenderness
 - Suspected complication of bariatric surgery
 - Notation by the ordering provider that the patient has a "surgical abdomen"
 - Age > 60 years with unintentional weight loss of ≥ 10 lbs. or $\geq 5\%$ of body weight over 6 months or less, without an identifiable reason

Background and Supporting Information

Bloating and distension are among the most common gastrointestinal complaints, and appears in 96% of patients with IBS, and 20-30% of the general population. Bloating is the subjective perception of increased abdominal pressure. Distension is the objective finding of increased abdominal girth.

References (AB-20)

v1.0.2024

1. Expert Panel on Gastrointestinal Imaging. ACR Appropriateness Criteria® suspected small-bowel obstruction. American College of Radiology (ACR); 2013
2. Donohoe KJ, Maurer AH, Ziessman HA. Society of Nuclear Medicine Procedure Guideline for Gastric Emptying and Motility, Version 2.0. Society of Nuclear Medicine and Molecular Imaging. Published June 6, 2004.
3. Parkman HP, Hasler WL, RS Fisher. American Gastroenterological Association Medical Position Statement: diagnosis and treatment of gastroparesis. *Gastroenterology*, 2004; 127:1589-1591
4. Abell TL, Camilleri M, Donohoe KJ, et al. Consensus recommendations for gastric emptying scintigraphy: A joint report of the American Neurogastroenterology and Motility Society and the Society of Nuclear Medicine, *Am J Gastroenterol*, 2008; 103:753-763.
5. Sarnelli G, Caenepeel P, Geypens B, et al. Symptoms associated with impaired gastric emptying of solids and liquids in Functional dyspepsia, *Am J Gastroenterol*, 2003; 98:783-788.
6. Parkman HP, Hasler WL, RS Fisher. American Gastroenterological Association technical review on the diagnosis and treatment of gastroparesis, *Gastroenterology*, 2004; 127:1592-1622.
7. Lawal A, Barboi A, Krasnow A, et al. Rapid gastric emptying is more common than gastroparesis in individuals with autonomic dysfunction, *Am J Gastroenterol*, 2007; 102:618-623.
8. Chial HJ, Camilleri M, Williams DE, et al. Rumination Syndrome in Children and Adolescents: Diagnosis, Treatment, and Prognosis, *Pediatrics*, 2003;111(1):158-62
9. Paulson EK, Thompson WM. Review of Small-Bowel Obstruction: The Diagnosis and When to Worry. *Radiology*. 2015;275(2):332-342. doi:10.1148/radiol.15131519.
10. Mullan CP, Siewert B, Eisenberg RL. Small Bowel Obstruction. *American Journal of Roentgenology*. 2012;198(2). doi:10.2214/ajr.10.4998.
11. American Gastroenterological Association medical position statement: Nausea and vomiting. *Gastroenterology*. 2001;120(1):261-262. doi:10.1053/gast.2001.20515.
12. Scorza K, Williams A, Phillips JD, Shaw J. Evaluation of Nausea and Vomiting, *American Family Physician*, 2007; 76(1)76-84.
13. Quigley EM, Hasler WL, Parkman HP. AGA technical review on nausea and vomiting. *Gastroenterology*. 2001;120(1):263-286. doi:10.1053/gast.2001.20516.
14. Baluch, A., Shewayish, S. (2019). Neutropenic Fever. In: Velez, A., Lamarche, J., Greene, J. (eds) *Infections in Neutropenic Cancer Patients*. Springer, Cham. https://doi.org/10.1007/978-3-030-21859-1_8.
15. Sinagra E, Raimondo D, Albano D, et al. Superior Mesenteric Artery Syndrome: Clinical, Endoscopic, and Radiological Findings. *Gastroenterology Research and Practice*. 2018;2018:1-7. doi:10.1155/2018/1937416.
16. Zaraket V, Deeb L. Wilkies Syndrome or Superior Mesenteric Artery Syndrome: Fact or Fantasy. *Case Reports in Gastroenterology*. 2015;9(2):194-199. doi:10.1159/000431307.
17. Merrett ND, Wilson RB, Cosman P, Biankin AV. Superior Mesenteric Artery Syndrome: Diagnosis and Treatment Strategies. *Journal of Gastrointestinal Surgery*. 2008;13(2):287-292. doi:10.1007/s11605-008-0695-4.
18. Foley A, Burgell R, Barrett JS, Gibson PR. Management strategies for abdominal bloating and distension. *Gastroenterol Hepatol*. 2014;10(9):531-571.
19. Scarpellini E, Arts J, Karamanolis G, et. al. International consensus on the diagnosis and management of dumping syndrome. *Nat Rev Endocrinol*. 2020;16:448-466. doi:10.1038/s41574-020-0357-5.
20. Lacy BE, Cangemi D, Vazquez-Roque M. Management of chronic abdominal distension and bloating. *Clin Gastroenterol Hepatol*. 2021;19(2):219-231.e.1. doi:10.1016/j.cgh.2020.03.056.

Diarrhea, Constipation, and Irritable Bowel (AB-21)

Guideline

Acute and Persistent Diarrhea (Up to 30 Days) (AB-21.1)

Chronic Diarrhea (More than 30 Days) (AB-21.2)

Constipation (AB-21.3)

Irritable Bowel Syndrome (AB-21.4)

References (AB-21)

Acute and Persistent Diarrhea (Up to 30 Days) (AB-21.1)

AB.DC.0021.1.A

v1.0.2024

- The presence of any red flag findings per **General Guidelines (AB-1.0)** precludes adjudication based on any other criteria.
- Routine advanced imaging is not supported for acute, or persistent (up to 30 days) uncomplicated, including infectious diarrhea.
- Travel and dysenteric (including bloody) diarrhea should undergo biological assessment and antimicrobial treatment.^{9,10,11}
- CT Abdomen and Pelvis with contrast (CPT® 74177) can be used if:
 - Suspected ischemia (See: **Mesenteric Ischemia (AB-6.1)** and **Colonic Ischemia (AB-6.2)**)
 - Older (>50) individuals with significant abdominal pain
 - Previous gastric bypass
 - Immunocompromised
 - Obstruction, toxic megacolon, or perforation suspected

Chronic Diarrhea (More than 30 Days) (AB-21.2)

AB.DC.0021.2.A

v1.0.2024

- Basic lab work including routine CBC, chemistries, as well as stool tests for pathogens.
- CT Abdomen with contrast (CPT® 74160), CT Abdomen and Pelvis with contrast (CPT® 74177), CT Enterography (CPT® 74177), or MR Enterography (CPT® 74183 or CPT® 74183 and CPT® 72197), can be approved if all of the following have been performed:
 - Colonoscopy has been performed and is nondiagnostic or suggestive of inflammatory bowel disease
 - Fecal calprotectin or fecal lactoferrin
 - Testing for giardia antigen or PCR for giardia
 - Testing for celiac disease with serum IgA tissue transglutaminase (tTG)
- See: **IBD (Crohn's Disease or Ulcerative Colitis) (AB-23.1)** for concerns regarding inflammatory bowel disease.

Constipation (AB-21.3)

AB.DC.0021.3.U

v1.0.2024

- The presence of any red flag findings per **General Guidelines (AB-1.0)** precludes adjudication based on any other criteria
- CT Abdomen and Pelvis with contrast (CPT® 74177) if:
 - Concern for obstruction
- MRI (MRI Pelvis without contrast CPT® 72195) for Defecography is considered investigational/experimental by UHC.

Background and Supporting Information

- The work-up and treatment of constipation usually proceeds with a history and physical followed by empiric medication or dietary trials.
 - In general, a colonoscopy is performed prior to advanced imaging in an individual presenting with chronic constipation if the alarm symptoms of blood in the stool, anemia, or weight loss are present.

Irritable Bowel Syndrome (AB-21.4)

AB.DC.0021.4.A

v1.0.2024

- The presence of any red flag findings per **General Guidelines (AB-1.0)** precludes adjudication based on any other criteria.
- Advanced imaging in the absence of alarm symptoms has a very low yield, but can be considered in the following circumstances:
 - CT Abdomen (CPT® 74160) or CT Abdomen and Pelvis (CPT® 74177) can be considered in the following circumstances:
 - Presence of any of the following alarm symptoms:
 - Weight loss
 - Frequent nocturnal awakenings due to gastrointestinal symptoms
 - Fever
 - Blood in the stool or iron deficiency anemia (See: **GI Bleeding (AB-22)** for appropriateness of imaging in this circumstance)
 - New onset and progressive symptoms
 - Onset of symptoms after age 50
 - Family history of colon cancer or inflammatory bowel disease
 - Findings of an abdominal mass
 - Presence of lymphadenopathy
 - Fecal calprotectin $\geq 50\text{ug/g}$ or fecal lactoferrin $\geq 4.0\text{ug/g}$ or CRP >0.5 in individuals with diarrhea-predominance
 - Celiac testing should also be performed in individuals with diarrhea-predominance IBS, and if positive see: **Celiac Disease (AB-24.1)** for imaging guidance. (See background and supporting information in **IBD (Crohn's Disease or Ulcerative Colitis) (AB-23.1)**)

Background and Supporting Information

- Irritable bowel syndrome is characterized by abdominal pain associated with altered bowel habits, abdominal distention, and bloating. It is important to understand that IBS is a positive diagnosis, not a diagnosis of exclusion. ACG guidelines (2021) strongly suggest that IBS be assessed with a “positive diagnostic strategy as compared to a diagnostic strategy of exclusion”. Subtypes include IBS-C (constipation-predominant), IBS-D (diarrhea-predominant), IBS-M (mixed), and unclassified IBS. Rome IV Criteria for the diagnosis of irritable bowel syndrome are:
 - Recurrent abdominal pain, on average ≥ 1 d/wk in the past 3 months, related to ≥ 2 of the following:
 - Defecation
 - Change in stool frequency
 - Change in stool appearance (form)

References (AB-21)

v1.0.2024

1. O'Connor OJ, McSweeney SE, McWilliams S, et al. Role of radiologic imaging in irritable bowel syndrome: Evidence-based review. *Radiology*. 2012;262(2):485-494.
2. Riddle MS, Dupont HL, Connor BA. ACG Clinical Guideline: Diagnosis, Treatment, and Prevention of Acute Diarrheal Infections in Adults. *The American Journal of Gastroenterology*. 2016;111(5):602-622.
3. Bharucha A. Exam 3: American Gastroenterological Association Technical Review on Constipation. *Gastroenterology*. 2013;144(1).
4. van Iersel JJ, Jonkers F, Verheijen PM et al. (2017), Comparison of dynamic magnetic resonance defaecography with rectal contrast and conventional defaecography for posterior pelvic floor compartment prolapse. *Colorectal Dis*. 19: O46–O53.
5. Wald A, Bharucha AE, Limketkai B, et.al. ACG clinical guidelines: management of benign anorectal disorders. *Am. J. Gastroenterol*. 2021;116(10):1987-2008. doi:10.14309/ajg.0000000000001507.
6. Menees SB, Powell C, Kurlander J, Goel A, Chey WD. A meta-analysis of the utility of c-reactive protein, erythrocyte sedimentation rate, fecal calprotectin and fecal lactoferrin to exclude inflammatory bowel disease in adults with IBS. *The American Journal of Gastroenterology*. 2015;110(3):444-454. doi:10.1038/ajg.2015.
7. Sultan S, Malhotra A. Irritable Bowel Syndrome. *Annals of Internal Medicine*. 2017;166(11). doi:10.7326/aitc201706060.
8. An Evidence-Based Position Statement on the Management of Irritable Bowel Syndrome. *The American Journal of Gastroenterology*. 2008;104(S1). doi:10.1038/ajg.2008.122.
9. O'Connor OJ, Mcsweeney SE, Mcwilliams S, et al. Role of radiologic imaging in Irritable Bowel Syndrome: evidence-based review. *Radiology*. 2012;262(2):485-494. doi:10.1148/radiol.11110423.
10. Ford AC, Moayyedi P, Lacy BE, et al. American College of Gastroenterology monograph on the management of Irritable Bowel Syndrome and chronic idiopathic constipation. *The American Journal of Gastroenterology*. 2014;109(S1). doi:10.1038/ajg.2014.187.
11. Foley A, Burgell R, Barrett JS, Gibson PR. Management strategies for abdominal bloating and distension. *Gastroenterol Hepatol (NY)*. 2014;10(9):561-571.
12. Smalley W, Falck-Ytter C, Carrasco-Labra A, Wani S, Lytvyn L, Falck-Ytter Y. AGA clinical practice guidelines on the laboratory evaluation of functional diarrhea and diarrhea-predominant Irritable Bowel Syndrome in adults (IBS-D). *Gastroenterology*. 2019;157(3):851-854. doi:10.1053/j.gastro.2019.07.004.
13. Lacy BE, Pimentel M, Brenner DM, et. al. ACG clinical guideline: management of Irritable Bowel Syndrome. *Am J Gastroenterol*. 2021;116(1):17-44. doi:10.14309/ajg.0000000000001036.
14. Bharucha AD, Dorn SD, Lembo A, Pressman A. American Gastroenterological Association medical position statement on constipation. *Gastroenterology*. 2013;144:211-217. doi:10.1053/j.gastro.2012.10.029.

GI Bleeding (AB-22)

Guideline

GI Bleeding (AB-22.1)

Small Bowel Bleeding Suspected (AB-22.2)

References (AB-22)

GI Bleeding (AB-22.1)

AB.GI.0022.1.A

v1.0.2024

- Endoscopy for upper GI bleeding as initial evaluation
- Colonoscopy for lower GI bleeding as initial evaluation
- CTA Abdomen (CPT® 74175) or CTA Abdomen and Pelvis (CPT® 74174) or CT Abdomen and Pelvis with contrast (CPT® 74177):
 - If colonoscopy cannot be performed in an individual with GI bleeding
 - Active bleeding and if endoscopy is negative
 - If conventional angiography is being considered
 - If surgery is being considered
 - GI bleeding and moderate to severe abdominal pain and/or tenderness
 - GI bleeding and hemodynamic instability (shock)
 - If there is concern for an aorto-enteric fistula (known or suspected aortic aneurysm, history of any type of aortic aneurysm repair).
- Meckel's scan (CPT® 78290) can be approved if bleeding is suspected from a Meckel's diverticulum.
- Gastrointestinal Bleeding Scintigraphy (CPT® 78278) can be considered if there is brisk active bleeding with negative endoscopy
- For TIPS placement, see: **Portal Hypertension (AB-26.3)**

Small Bowel Bleeding Suspected (AB-22.2)

AB.GI.0022.2.A

v1.0.2024

- If small bowel bleeding is suspected as the source of bleeding, and if upper and lower endoscopies are negative:
 - Video capsule endoscopy (VCE) is performed prior to advanced imaging.
 - VCE is not required prior to advanced imaging if small bowel obstruction or stricture of the gastrointestinal tract is suspected, if there is dysphagia, or in individuals with implantable devices such as pacemakers or defibrillators.
 - CT Enterography (CPT® 74177) if upper and lower endoscopy are negative and if VCE is negative. If there is a contraindication to CT Enterography, MR Enterography (CPT® 74183 or CPT® 74183 and CPT® 72197) may be performed.
 - Note: Providers occasionally request a CT or MR Enterography prior to the administration of a VCE, in order to assess whether there is pathology that might impede passage of the capsule and cause retention. This is not supported as a routine procedure prior to VCE. It should be noted that a patency capsule is available, and that this may identify patients at higher risk of retention. However, guidance from the consensus group of the American College of Gastroenterology recommends that in individuals with obstructive symptomatology, imaging (MR Enterography or CT Enterography) should be performed prior to VCE. This group would also include high risk individuals with a known history of Crohn's Disease, known history of strictures or other obstruction, history of previous pelvic or abdominal radiation, or suspected tumor.
- Iron Deficiency Anemia
 - If the bleeding is determined to be non-gastrointestinal (e.g. hematuria or vaginal bleeding), refer to the appropriate guideline for these conditions.
 - If the source is determined to be gastrointestinal:
 - Upper endoscopy and colonoscopy should be performed, unless contraindicated.
 - Small bowel video capsule endoscopy is next, if endoscopies are negative (unless contraindicated).
 - CT Abdomen and Pelvis with contrast (CPT® 74177), CT Enterography (CPT® 74177), or MR Enterography (CPT® 74183 or CPT® 74183 and CPT® 72197) (if CT Enterography is contraindicated) can be performed, if small bowel video capsule endoscopy is negative, or for further evaluation of abnormal video capsule findings. CT Enterography should be considered the test of choice given the lack of motion artifact and its superior spatial resolution.

References (AB-22)

v1.0.2024

1. ACR Appropriateness Criteria®. Radiologic Management of Upper Gastrointestinal Bleeding, 2016.
2. Laing CJ, Tobias T, Rosenblum DI, Banker WL, et al. Acute gastrointestinal bleeding: emerging role of multidetector CT angiography and review of current imaging Techniques. *Radiographics*. 2007;27:1055-1070.
3. American Gastroenterological Association Medical Position Statement: Evaluation And Management Of Occult And Obscure Gastrointestinal Bleeding. *Gastroenterology*, 2000;118(1):197-200.
4. Barkun AN, Bardou M, Kuipers EJ, et al. International Consensus Recommendations on the Management of Individuals with Nonvariceal Upper Gastrointestinal Bleeding. *Ann Intern Med*. 2010 Jan 19;152(2):101-13.
5. Wilkins T, Khan N, Nabh A, et al. Diagnosis and Management of Upper Gastrointestinal Bleeding. *Am Fam Physician*. 2012 Mar 1;85(5):469-76.
6. Strate LL, Gralnek IM. ACG Clinical Guideline. Management of Individuals with Acute Lower Gastrointestinal Bleeding. *Amer. J. Gastroenterol*. Advance Online Publication 1 March 2016.
7. Gerson I, et al. ACG Clinical Guideline: Diagnosis and Management of Small Bowel Bleeding. *Amer J Gastroenterol*. 2015;110:1265-1287.
8. Laine L, Jensen D. Management of Individuals with Ulcer Bleeding. *Am J. Gastroenterol* 2012;107:345-360.
9. Garcia-Tsao G, et al. Prevention and Management of Gastroesophageal Varices and Variceal Hemorrhage in Cirrhosis. *Amer J Gastroenterol*. 2007;102:2086-2102.
10. Short M and Domagalski J, Iron deficiency Anemia: Evaluation and Management. *Am. Fam. Physician*. 2013 Jan 15;87(2):98-104.
11. Garcia-Lopez S, Bermejo F. A guide to diagnosis of iron deficiency and iron deficiency anemia in Digestive Diseases. *World Journal of Gastroenterology*. 2009 Oct 7; 5(37):4638-4643.
12. Ghosh S. Investigating Iron Deficiency Anemia without Clinical Evidence of Gastrointestinal Blood Loss. *Canadian Journal of Gastroenterology*. 2012;26(10):686-686.
13. American Gastroenterological Association Medical Position Statement: Evaluation and management of occult and obscure gastrointestinal bleeding. *Gastroenterology*. 2000;118:197-200.
14. Raju GS, Gerson L, Das A, et al. American Gastroenterological Association (AGA) Institute medical position statement on obscure gastrointestinal bleeding. *Gastroenterology*. 2007;133:1694-1696.
15. Zuckerman GR, Prakash C, Askin MP, et al. AGA Technical review on the evaluation and management of occult and obscure gastrointestinal bleeding. *Gastroenterology*, 2000; 118:201-221.
16. Enns RA, Hookey L, Armstrong D, et al. Clinical Practice Guidelines for the Use of Video Capsule Endoscopy. *Gastroenterology*. 2017;152(3):497-514. doi:10.1053/j.gastro.2016.12.032.
17. Flemming J, Cameron S. Small bowel capsule endoscopy. *Medicine*. 2018;97(14). doi:10.1097/md.00000000000010148.
18. Technology status evaluation report on wireless capsule endoscopy. *Gastrointestinal Endoscopy*. 2014;79(5):805-815.

Inflammatory Bowel Disease (AB-23)

Guideline

IBD (Crohn's Disease or Ulcerative Colitis) (AB-23.1)

Known IBD (AB-23.2)

Perirectal/Perianal Disease (AB-23.3)

Primary Sclerosing Cholangitis (PSC) (AB-23.4)

References (AB-23)

IBD (Crohn's Disease or Ulcerative Colitis) (AB-23.1)

AB.IB.0023.1.A

v1.0.2024

- Suspected Crohn's Disease or Ulcerative Colitis
 - CT Abdomen and Pelvis with contrast (CPT® 74177) or CT Enterography (CPT® 74177) or MR Enterography (CPT® 74183 or CPT® 74183 and CPT® 72197) for ANY of the following:
 - History of malignancy with a likelihood or propensity to metastasize to abdomen
 - Fever (≥ 101 degrees Fahrenheit)
 - Elevated WBC $> 10,000$, or above the upper limit of normal for the particular lab reporting the result
 - Palpable mass of clinical concern and/or without benign features
 - GI bleeding, overt or occult, not obviously hemorrhoidal
 - Abdominal tenderness documented as moderate or severe
 - Peritoneal signs, such as guarding or rebound tenderness
 - Suspected complication of bariatric surgery
 - Notation by the ordering provider that the patient has a "surgical abdomen"
 - Age > 60 years with unintentional weight loss of ≥ 10 lbs. or $\geq 5\%$ of body weight over 6 months or less, without an identifiable reason
 - Chronic diarrhea without the above signs or symptoms, see: **Diarrhea, Constipation, and Irritable Bowel (AB-21)**
 - CT Enterography (CPT® 74177) or MR Enterography (CPT® 74183 or CPT® 74183 and CPT® 72197) if none of the above signs or symptoms are present and request is for the evaluation of chronic abdominal pain associated with diarrhea due to a concern for inflammatory bowel disease if:
 - There is a positive family history of inflammatory bowel disease, **OR**
 - There are endoscopy or colonoscopy findings suggestive of inflammatory bowel disease, **OR**
 - Elevated inflammatory markers (fecal lactoferrin ≥ 4.0 ug/g, CRP > 0.5 mg/dL, or fecal calprotectin ≥ 50 ug/g), **OR**
 - Diagnosis is still in doubt after colonoscopy and evaluation of inflammatory markers, and Crohn's disease is suspected
 - CT Abdomen and Pelvis with or without contrast (CPT® 74177 or CPT® 74176) can be performed prior to endoscopy if requested by or in consultation with the provider who will be performing the endoscopy.
- NOTE: Serologic markers

Serologic and genetic markers are currently under investigation with regards to their value in diagnosing inflammatory bowel disease, and are sometimes used as a

screening test for IBD in which other examinations are negative. At the current time they are not considered suitable as a screening test for inflammatory bowel disease in patients with GI symptoms, and the routine use of serologic or genetic markers for the diagnosis of IBD is not indicated. Thus, an isolated positive marker result in a patient without any other findings to suggest IBD, especially in the presence of negative inflammatory markers and endoscopic examinations, is not, in and of itself, an indication for advanced imaging.

- Note: Serologic markers include anti-glycan antibodies, such as ASCA, ACCA, ALCA, AMCA, Anti-L, Anti-C, Anti-OmpC, Anti-Is, Anti-Cbir, pANCA, PAB, GAB

Background and Supporting Information

Studies have demonstrated the negative predictive value of a low fecal calprotectin and CRP with regards to inflammatory bowel disease. Chey, et al. in a meta-analysis demonstrated that a fecal calprotectin $<40\text{mcg/g}$ or a CRP $\leq 0.5\text{ mg/dl}$ effectively excludes inflammatory bowel disease in patients with IBS. Katsinelos, et al. reviewed wireless capsule endoscopy results in patients with abdominal pain and diarrhea. The diagnostic yield of capsule endoscopy in patients with abdominal pain and diarrhea with positive inflammatory markers was 90.1%, and 0% in patients with abdominal pain and diarrhea with negative inflammatory markers. This led the Canadian Association of Gastroenterology to recommend against the use of capsule endoscopy in persons with chronic abdominal pain or diarrhea as their only symptoms and no evidence of biomarkers associated with Crohn's Disease, stating "CE (capsule endoscopy) is not warranted in most patients who present with chronic abdominal pain in the absence of positive tests for inflammatory markers or abnormal findings on endoscopy or imaging".

Known IBD (AB-23.2)

AB.IB.0023.2.A

v1.0.2024

- CT Abdomen and Pelvis (CPT® 74177), CT Enterography (CPT® 74177), or MR Enterography (CPT® 74183 or CPT® 74183 and CPT® 72197) for known Crohn's Disease or Ulcerative Colitis and ANY of the following:
 - Suspected complications including abscess, perforation, fistula, or obstruction
 - Monitoring response to therapy
 - To determine change in treatment
- MR Enterography is the test of choice for the follow up of young patients with IBD given the lack of ionizing radiation and the need for lifetime follow up in many patients.

Perirectal/Perianal Disease (AB-23.3)

AB.IB.0023.3.A

v1.0.2024

This section is applicable to individuals with Crohn's disease. See: **Fistula in Ano (PV-21.1)** and **Perirectal Abscess (PV-21.2)** in the Pelvis Imaging Guidelines for non-Crohn's related perirectal and/or perianal fistulae

- Perirectal/Perianal Fistula:
 - MRI Pelvis without and with contrast (CPT® 72197)
 - Endoscopic ultrasound is preferential to CT in this setting
 - CT Pelvis with contrast (CPT® 72193) is an inferior study in this setting, and should be used when MRI or Endoscopic ultrasound cannot be performed.
- Perirectal/Perianal Abscess:
 - MRI Pelvis without and with contrast (CPT® 72197)
 - CT Pelvis with contrast (CPT® 72193) is inferior but can be approved as an alternative if desired.

Primary Sclerosing Cholangitis (PSC) (AB-23.4)

AB.IB.0023.4.A

v1.0.2024

- Primary Sclerosing Cholangitis:
 - MRCP can be considered to assess for PSC in those:
 - With IBD and any elevated liver study (including alkaline phosphatase, GGTP, bilirubin, AST, or ALT).
 - Without IBD, but with persistent cholestatic liver tests. (See: **Abnormal Liver Chemistries (AB-30)**)
 - Ultrasound or MRI/MRCP can be done as surveillance for cholangiocarcinoma in individuals with PSC every 6 months.

Background and Supporting Information

Primary sclerosing cholangitis (PSC) is a chronic liver and biliary tract disease that can result in stricturing and fibrosis of the intra- and extra- hepatic biliary ducts, as well as end-stage liver disease. It is most often associated with inflammatory bowel disease. Biliary obstruction can occur anywhere along the biliary tree, resulting in cholangitis, and there is a high risk of the development of cholangiocarcinoma, which must be strongly considered in individuals with PSC and a dominant stricture, as well as an increased risk of gallbladder polyps and other malignancies. As such, imaging plays an important role in the diagnosis and follow-up of PSC.^{6,7,8}

See: **Chronic Liver Disease, Cirrhosis and Screening for HCC (AB-26.1)**

Background and Supporting Information PSC (Primary Sclerosing Cholangitis) vs PBC (Primary Biliary Cholangitis)

References (AB-23)

v1.0.2024

1. Lichtenstein GR, Loftus EV, Isaacs KL, Regueiro MD, Gerson LB, Sands BE. ACG Clinical Guideline: Management of Crohn's Disease in Adults. *American Journal of Gastroenterology*. 2018;113(4):481-517. doi:10.1038/ajg.2018.27.
2. Hara AK, Leighton JA, Heigh RI, et al. Crohn Disease of the Small Bowel: Preliminary Comparison among CT Enterography, Capsule Endoscopy, Small-Bowel Follow-through, and Ileoscopy | *Radiology*.
3. Lin MF and Narra V. Developing role of magnetic resonance imaging in Crohn's disease. *Current Opinion in Gastroenterology*. 2008, 24(2):135-140.
4. Expert Panel on Gastrointestinal Imaging. ACR Appropriateness Criteria® Crohn disease. American College of Radiology (ACR); Reviewed 2014.
5. Linder KD et al. ACG Clinical Guideline: Primary Sclerosing Cholangitis. *Amer J Gastroenterol*. 2015;110:646-659.
6. Razumilava, N. et al. Cancer Surveillance in individuals with primary sclerosing cholangitis. *Hepatology*. 2011;54: 842-1852.
7. Chapman R, Fevery J, Kallou A, et al. Diagnosis and Management of Primary Sclerosing Cholangitis. *Hepatology*. 2010;51(2).
8. Katsinelos P, Fasoulas K, Beltsis A, et al. Diagnostic yield and clinical impact of wireless capsule endoscopy in patients with chronic abdominal pain with or without diarrhea: A Greek multicenter study. *European Journal of Internal Medicine*. 2011;22(5). doi:10.1016/j.ejim.2011.06.012.
9. Enns RA, Hookey L, Armstrong D, et al. Clinical Practice Guidelines for the Use of Video Capsule Endoscopy. *Gastroenterology*. 2017;152(3):497-514. doi:10.1053/j.gastro.2016.12.032.
10. Menees SB, Powell C, Kurlander J, Goel A, Chey WD. A Meta-Analysis of the Utility of C-Reactive Protein, Erythrocyte Sedimentation Rate, Fecal Calprotectin and Fecal Lactoferrin to Exclude Inflammatory Bowel Disease in Adults With IBS. *The American Journal of Gastroenterology*. 2015;110(3):444-454. doi:10.1038/ajg.2015.6.
11. Ziech M, Felt-Bersma R, Stoker J. Imaging of Perianal Fistulas. *Clinical Gastroenterology and Hepatology*. 2009;7(10):1037-1045. doi:10.1016/j.cgh.2009.06.030.
12. Berman L. Utility of magnetic resonance imaging in anorectal disease. *World Journal of Gastroenterology*. 2007;13(23):3153. doi:10.3748/wjg.v13.i23.3153.
13. Vogel JD, Johnson EK, Morris AM, et al. Clinical Practice Guideline for the Management of Anorectal Abscess, Fistula-in-Ano, and Rectovaginal Fistula. *Diseases of the Colon & Rectum*. 2016;59(12):1117-1133. doi:10.1097/dcr.0000000000000733.
14. Long MD, Sands BE. What Is the Role of the Inflammatory Bowel Disease Panel in Diagnosis and Treatment? *Clinical Gastroenterology and Hepatology*. 2018;16(5):618-620. doi:10.1016/j.cgh.2018.02.010
15. Magro F, Gionchetti P, Eliakim R, et al. Third European Evidence-based Consensus on Diagnosis and Management of Ulcerative Colitis. Part 1: Definitions, Diagnosis, Extra-intestinal Manifestations, Pregnancy, Cancer Surveillance, Surgery, and Ileo-anal Pouch Disorders. *Journal of Crohn's and Colitis*. 2017;11(6):649-670. doi:10.1093/ecco-jcc/jjx008.
16. Rubin DT, Ananthakrishnan AN, Siegel CA, Sauer BG, Long MD. ACG Clinical Guideline. Ulcerative Colitis in Adults. *The American Journal of Gastroenterology*. 2019;114(3):384-413. doi:10.14309/ajg.0000000000000152.
17. Smalley W, Falck-Ytter C, Carrasco-Labra A, Wani S, Lytvyn L, Falck-Ytter Y. AGA clinical practice guidelines on the laboratory evaluation of functional diarrhea and diarrhea-predominant Irritable Bowel Syndrome in adults (IBS-D). *Gastroenterology*. 2019;157(3):851-854. doi:10.1053/j.gastro.2019.07.004.

Celiac Disease (Sprue) (AB-24)

Guideline

Celiac Disease (AB-24.1)

References (AB-24)

Celiac Disease (AB-24.1)

AB.CD.0024.1.A

v1.0.2024

- CT Abdomen and Pelvis with contrast (CPT® 74177), CT Enteroclysis (CPT® 74176 or CPT® 74177), or CT Enterography (CPT® 74177) is appropriate for:
 - One time study after initial, confirmed diagnosis of celiac disease.
 - Confirmed celiac disease and new or continued symptoms (e.g., bloating, diarrhea, abdominal pain, weight loss, distention, evidence of malabsorption, anemia) despite adherence to 6 months of a gluten free diet

Background and Supporting Information

- Celiac is an autoimmune disease in which the villi of the small intestine are damaged from eating gluten (found in wheat, barley, and rye).
- Complications of celiac disease include ulcerative jejunitis, lymphoma, and small intestinal adenocarcinoma.
- Diagnosis is made by blood testing¹:
 - Anti-tissue transglutaminase antibody [anti-tTG], anti-endomysium antibody (EMA), total IgA count, CBC to detect anemia, ESR, C-reactive protein, complete metabolic panel, vitamin D, E, B12 levels.
- Endoscopy with biopsy of the small bowel is performed to confirm the diagnosis of celiac disease if anti-tTG and/or EMA tests are positive.
- Capsule endoscopy may be used to confirm diagnosis of celiac disease in individuals with positive serology and negative biopsy, or when there is contraindication to biopsy or EGD. See: **Celiac Disease (CAPEND-2)** in the Capsule Endoscopy guidelines.

References (AB-24)

v1.0.2024

1. Rubio-Tapia A, Hill ID, Kelly CP, Calderwood AH, Murray JA. ACG Clinical Guidelines: Diagnosis and Management of Celiac Disease. *The American Journal of Gastroenterology*. 2013;108(5):656-676.
2. Weyenberg SJV, Mulder CJ, Waesberghe JHTV. Small Bowel Imaging in Celiac Disease. *Digestive Diseases*. 2015;33(2):252-259. doi:10.1159/000369516.
3. Radmard AR, Taheri APH, Nik ES, et al. MR enterography in nonresponsive adult celiac disease: Correlation with endoscopic, pathologic, serologic, and genetic features. *Journal of Magnetic Resonance Imaging*. 2017;46(4):1096-1106. doi:10.1002/jmri.25646.
4. Elsayes KM, Al-Hawary MM, Jagdish J, Ganesh HS, Platt JF. CT Enterography: Principles, Trends, and Interpretation of Findings. *RadioGraphics*. 2010;30(7):1955-1970. doi:10.1148/rg.307105052.

CT Colonography (CTC) (AB-25)

Guideline

CTC (AB-25.1)

References (AB-25)

CTC (AB-25.1)

AB.CT.0025.1.U

v1.0.2024

Note: A screening CTC (CPT[®] 74263) can ONLY be used for an individual who is a candidate for average risk screening as defined below. It cannot be used for any other indication. If the request for a CTC is for any other reason than average risk screening, please refer to diagnostic CTC indications. A diagnostic CTC would be the appropriate code, if approvable, for any other reason than average risk screening. This would include surveillance for a history of colon polyps, the evaluation of a change in bowel habits, abdominal pain, bleeding, etc. Please refer to the definition below of an average-risk individual, as well as the circumstances for which a diagnostic CTC is appropriate.

- Screening CTC (CPT[®] 74263) for colorectal cancer is NOT indicated if:
 - FIT-DNA (multi-targeted stool DNA test) within the last 3 years, OR
 - Colonoscopy within the last 10 years
- Screening CTC (CPT[®] 74263) can be approved every 5 years for colorectal cancer^{1,2,3} for:
 - Average-risk individuals ages 45 to 75
 - Average risk is defined as:
 - No previously diagnosed colorectal cancer, or colonic adenomas, or inflammatory bowel disease involving the colon
 - Individuals between 76 to 85 if there is no history of a previously negative colonoscopy or CTC, or, if in the opinion of the provider, the benefits of screening outweigh the risks.
 - Individuals with a SINGLE first-degree relative diagnosed at age >60 years with colorectal cancer or an advanced adenoma can be screened with CTC beginning at age 40.
 - If there are 2 or more first degree relatives at any age with CRC or an advanced adenoma, or a first degree relative <60, the individual should be screened via colonoscopy, not CTC.
- Diagnostic CTC without contrast (CPT[®] 74261) can be approved for:
 - Failed conventional colonoscopy (e.g. due to a known colonic lesion, structural abnormality, or technical difficulty), and/or
 - Conventional colonoscopy is medically contraindicated. Contraindications may include:⁴
 - Coagulopathy
 - Intolerance to sedation
 - Elderly ≥80 years of age
 - Recent (within the last 60 days) myocardial infarction (MI)
- Diagnostic CTC with contrast (CPT[®] 74262) can be approved if:

- There is a known obstructing colorectal malignancy so that staging prior to surgery can be performed, if desired.
- There is a clearly stated indication for IV contrast to evaluate extra-colonic organs. When performed in this setting, a CTC with contrast will substitute for a CT Abdomen and Pelvis such that an additional CT Abdomen and Pelvis would generally not be needed.
- MRI Colonography: Currently, no published society-endorsed guideline with respect to colorectal cancer screening lists MRI Colonography as an alternative screening study. As such, requests for MRI Colonography would be considered investigational at this time. There is no specific CPT assigned for this procedure. It is sometimes requested as an MRI Abdomen and MRI Pelvis.

Background and Supporting Information

CT Colonography is routinely performed without contrast, and IV contrast is not needed in most cases

References (AB-25)

v1.0.2024

1. Lin JS, Piper MA, Perdue LA, et al. Screening for Colorectal Cancer. *JAMA*, 2016;315(23):2576. doi:10.1001/jama.2016.3332.
2. Yee J, Kim DH, Rosen MP, et al. ACR Appropriateness Criteria® Colorectal cancer screening. Last review date: 2018.
3. Rex DK, Boland CR, Dominitz JA, et al. Colorectal Cancer Screening: Recommendations for Physicians and Patients From the U.S. Multi-Society Task Force on Colorectal Cancer. *Gastroenterology*. 2017;153(1):307-323. doi:10.1053/j.gastro.2017.05.013.
4. Yau TY, Alkandari L, Haaland B, Low W, Tan CH. Is intravenous contrast necessary for detection of clinically significant extracolonic findings in patients undergoing CT colonography? *The British Journal of Radiology*. 2014;87(1036):20130667. doi:10.1259/bjr.20130667.
5. Spada C, Stoker J, Alarcon O, et al. Clinical indications for computed tomographic colonography: European Society of Gastrointestinal Endoscopy (ESGE) and European Society of Gastrointestinal and Abdominal Radiology (ESGAR) Guideline. *Endoscopy*. 2014;46(10):897-915. doi:10.1055/s-0034-1378092.
6. ACR-SAR-SCBT-MR: Practice Parameter for the Performance of Computed Tomography (CT) Colonography in Adults. 2014.
7. Scalise P, Mantarro A, Pancrazi F, Neri E. Computed tomography colonography for the practicing radiologist: A review of current recommendations on methodology and clinical indications. *World Journal of Radiology*. 2016;8(5):472. doi:10.4329/wjr.v8.i5.472.
8. U.S. Preventative Services Task Force. Colorectal cancer: screening. Draft recommendation statement. October 27, 2020. <https://uspreventiveservicestaskforce.org/uspstf/draft-recommendation/colorectal-cancer-screening3#fullrecommendationstart>.
9. Wolf AMD, Fontham ETH, Church TR, et al. Colorectal cancer screening for average-risk adults: 2018 guideline update from the American Cancer Society. *CA*. 2018;68(4):250-281. doi:10.3322/caac.21457.
10. Shaukat A, Kahi CJ, Burke CA, Rabeneck L, Sauer BG, Rex D. ACG clinical guidelines: colorectal cancer screening 2021. *Am J Gastroenterol*. 2021;116(3):458-479. doi:10.14309/ajg.0000000000001122.

Cirrhosis and Liver Screening for Hepatocellular Carcinoma (HCC); Ascites and Portal Hypertension (AB-26)

Guideline

Chronic Liver Disease, Cirrhosis and Screening for HCC (AB-26.1)

Ascites (AB-26.2)

Portal Hypertension (AB-26.3)

Monitoring After Fontan Procedure (AB-26.4)

References (AB-26)

Chronic Liver Disease, Cirrhosis and Screening for HCC (AB-26.1)

AB.CL.0026.1.A

v1.0.2024

- Note: for HCC surveillance in Budd-Chiari Syndrome/Hepatic Vein Thrombosis, see: **Hepatic Arteries and Veins (AB-43.1)**
- Ultrasound (CPT® 76700 or CPT® 76705) every 6 months for HCC screening is appropriate in the following circumstances:
 - All individuals, regardless of etiology, with cirrhosis or advanced fibrosis (e.g., Fibrosis Score F3 or greater on an elastography study, or results of a lab study such as FIB-4 or a biopsy indicative of severe activity or advanced fibrosis). See below for any exceptions.
 - All individuals with Hepatitis B, regardless of the presence of cirrhosis or advanced fibrosis.
 - See: **Hepatic Arteries and Veins (AB-43.1)** for individuals with Chronic Budd-Chiari Syndrome (BCS).
 - See: **Monitoring After Fontan Procedure (AB-26.4)** for individuals who have undergone the FONTAN procedure.
 - The presence of liver disease in the absence of advanced fibrosis or cirrhosis, with the exception for those circumstances indicated above, is not an indication for screening. This would include, for example, NAFLD (Non-alcoholic fatty liver disease), the presence of which is not an indication for screening in the absence of either advanced fibrosis or cirrhosis.
 - HCC screening may also be indicated in the use of medications or treatments which increase risk of HCC. See: **General Guidelines (AB-1.0)** for additional information.
- If liver nodule is identified on screening:
 - Less than 1cm
 - Repeat US in 3 months, then every 3 to 6 months.
 - If stable for 2 years, then return to US every 6 months
 - Greater than or equal to 1cm
 - Multiphase CT Liver (either CPT® 74160 or CPT® 74170) or MRI Abdomen (CPT® 74183) should be performed.
 - If negative, return to routine surveillance via US in 6 months.
 - If Li-RADS NC (non-categorizable): repeat the same study or an alternative diagnostic imaging ≤3 months. (Note: non-categorizable refers to a technical problem with the study, such as image omission or severe degradation)
 - If Li-RADS 1 (definitely benign): Return to routine surveillance via US in 6 months.

- If Li-RADS 2 (probably benign): CT or MRI in 6 months can be approved (US requests are approvable if desired). If unchanged, return to routine surveillance via US.
- If Li-RADS 3 (intermediate): CT or MRI in 3-6 months, and can be repeated every 6 months 2 more times, for a total of 18 months from the initial finding. If no change by 18 months, return to US surveillance every 6 months.
- If Li-RADS 4 (probable HCC): Repeat or alternative imaging in ≤ 3 months. If HCC confirmed: See: **Upper GI Cancers (ONC-14)** in the Oncology Imaging Guidelines.
- If Li-RADS 5 (HCC confirmed): See: **Upper GI Cancers (ONC-14)** in the Oncology Imaging Guidelines.
- If Li-RADS M (Malignant, not definitely HCC): Repeat or alternative imaging in ≤ 3 months, and follow appropriate Oncology guidelines upon diagnosis.
- Exceptions to the above algorithms:
 - Advanced imaging for surveillance may be substituted for US in the following circumstances:
 - Obesity (BMI >35)
 - Marked parenchymal heterogeneity noted on US.
 - Other specifically noted technical limitations of US such as obscuration by intestinal gas, chest wall deformity, etc.
 - For individuals on the Liver Transplant list: See: **Liver Transplant, Pre-Transplant (AB-42.1)**
- Alpha-fetoprotein ≥ 20 ng/mL: Multiphasic CT or MRI Abdomen:
 - Further imaging should follow the above algorithm, depending on the findings of the CT or MRI.
 - If the initial CT or MRI does not reveal a lesion, but the AFP increases on subsequent testing, additional advanced imaging by CT or MRI may be approved.
- Contrast-Enhanced Ultrasound (CEUS)
 - Further studies are needed to assess the value of CEUS in this setting, and it should be considered investigational and experimental at this time.

Background and Supporting Information

When performed for liver lesion evaluation, a multiphase CT protocol may include non-contrast imaging as well as arterial, portal venous, and delayed-phase post-contrast imaging. However, these protocols do not always require non-contrast imaging which may not provide additional information in many scenarios. Therefore, a multiphase CT for liver lesion evaluation can be requested as CPT[®] 74160 (CT Abdomen with contrast) or CPT[®] 74170 (CT Abdomen without and with contrast).

The American Association for the Study of Liver Diseases (AASLD) revised its guidelines with respect to surveillance for HCC in patients with cirrhosis in 2018. The recommended algorithm now includes either US alone or US with serum AFP every 6 months. It should be noted that “modification of this surveillance strategy based on the etiology of liver diseases or risk stratification models cannot be recommended at this time.”¹

In addition, the AASLD also issued a subsequent Practice Guidance in 2018 and this document forms the basis of eviCore’s guidelines. The AASLD has adopted the Li-RADS classification of liver lesions with respect to HCC surveillance imaging for patients with advanced liver disease, and follow-up imaging protocols are based on this system. In view of this, the Li-RADS classification now informs imaging protocols used by eviCore.

Note: PSC (Primary Sclerosing Cholangitis) vs. PBC (Primary Biliary Cholangitis)

These 2 entities sound similar, and both are cholestatic, but they are different diseases, and as such have different monitoring requirements.

PSC is an idiopathic cholestatic disease characterized by chronic inflammation, progressive fibrosis, and stricturing of the *medium and large-sized* extra-hepatic or intra-hepatic bile ducts. Segmental bile duct dilation proximal to areas of stricturing creates the characteristic beaded appearance on a cholangiogram, such as MRCP. This may progress and eventually lead to cirrhosis as well. It is most commonly associated with inflammatory bowel disease. From a surveillance standpoint, PSC may be complicated by disease-associated malignancies, including cholangiocarcinoma, hepatocellular carcinoma, and pancreatic cancer. Thus, follow-up imaging in this setting is generally via MRCP +/- MRI Abdomen (CPT® 74181 or CPT® 74183) – See: **Primary Sclerosing Cholangitis (PSC) (AB-23.4)**.

PBC is a complex, chronic, and slowly progressive autoimmune liver disease that predominately affects women, and is characterized by cholestatic liver biochemistries as well as the presence of AMA (Anti-Mitochondrial Antibodies), and results in T-lymphocyte-mediated destruction of *small* intrahepatic bile ducts. This may ultimately lead to cirrhosis, and thus an increased risk of hepatocellular carcinoma. Because of this, surveillance via US screening protocols for HCC are followed in PBC.

It may be necessary, when the diagnosis of PBC is uncertain, for an MRCP to be performed in order to distinguish between PBC and PSC. However, MRI or MRCP is not used for serial monitoring for PBC, once the diagnosis is established. This is in contradistinction to PSC, in which MRCP is used to surveil for cholangiocarcinoma, as discussed above.

Ascites (AB-26.2)

AB.CL.0026.2.A

v1.0.2024

- Abdominal ultrasound (CPT® 76700 or CPT® 76705) and/or Doppler (CPT® 93975) with diagnostic paracentesis required for all initial evaluations of ascites to determine the need for further or advanced imaging.
- Further advanced imaging is determined by the nature of etiology of the ascites (e.g., portal hypertension secondary to cirrhosis, malignancy such as ovarian or pancreatic, heart failure, etc.).
- Peritoneal-venous shunt patency study (CPT® 78291) is considered for evaluation of shunt patency and function in an individual with ascites

Background and Supporting Information

- Guidance from the American Association for the Study of Liver Diseases (2021) indicates that the initial evaluation of patients with ascites should include a medical history, physical examination, abdominal US with Doppler, lab studies including CBC, Liver function tests, serum and urine electrolytes and paracentesis with ascitic fluid analysis, which then guides further management. They specifically note that "A diagnostic paracentesis should be performed in all patients with new-onset ascites that is accessible for sampling".

Portal Hypertension (AB-26.3)

AB.CL.0026.3.A

v1.0.2024

- For noninvasive abdominal imaging:
 - Abdominal US (CPT[®] 76700 or CPT[®] 76705) (including Duplex Doppler US [CPT[®] 93975] of the liver and upper abdomen) is required for all initial evaluations to assist in determining the cause (pre-hepatic [e.g. portal vein thrombosis, extrinsic compression from a tumor], intrahepatic [e.g. cirrhosis], and post-hepatic [e.g. hepatic vein thrombosis]). US is very accurate for detecting portal vein or hepatic vein thrombosis.
- For additional imaging indications, see: **Hepatic Arteries and Veins (AB-43.1)**
- TIPS (transjugular intrahepatic portosystemic shunt)
 - See: **Hepatic Arteries and Veins (AB-43.1)**
- Certain requests are made for advanced imaging to evaluate an individual with cirrhosis for the presence of esophageal varices. In general, and in the absence of a contraindication, endoscopy should be performed in individuals to assess for the presence of varices.

Background and Supporting Information

- Most cases of portal hypertension are caused by cirrhosis, and the most feared complication is that of esophageal variceal hemorrhage. Causes of portal hypertension can be divided into prehepatic (e.g. portal vein thrombosis, extrinsic compression from a tumor), intrahepatic (e.g. cirrhosis) and post-hepatic (e.g. hepatic vein thrombosis) causes. The differentiation of some of these causes may require work-up which includes measurement of the hepatic venous pressure gradient (HVPG) which is considered the gold standard for the evaluation of portal hypertension.
- The gold standard for the assessment of portal hypertension is the Hepatic Venous Pressure Gradient (HVPV [pressure gradient between portal vein and the inferior vena cava]), which is an invasive test.

Monitoring After Fontan Procedure (AB-26.4)

AB.CL.0026.4.A

v1.0.2024

- Abdominal ultrasound (CPT® 76700 or CPT® 76705) and Doppler (CPT® 93975) every 6 months or per institution protocol
- MR Elastography (CPT® 76391) every 6 months
- If any sized lesions are detected on ultrasound:
 - MRI Abdomen without contrast, or without and with contrast (CPT® 74181 or CPT® 74183) with follow-up timeframes as requested
- If advanced fibrosis or cirrhosis is detected on any imaging modality:
 - HCC monitoring every 6 months after advanced fibrosis or cirrhosis is detected with MRI Abdomen without contrast, or without and with contrast (CPT® 74181 or CPT® 74183) is indicated
- CT Abdomen and Pelvis with contrast, CT Abdomen with contrast, or other elastography techniques (i.e., Fibroscan) can be used to assess and monitor individuals with contraindications to MRI (e.g., pacemaker devices, etc.)

Background and Supporting Information

- Individuals with single-ventricle physiology who have undergone the Fontan Procedure which redirects venous blood flow to the pulmonary circulation invariably develop liver complications, which can include the development of nodules and cirrhosis secondary to the altered vascular anatomy, and thus are at risk for hepatocellular carcinoma. In addition, the congestive hepatopathy associated with the Fontan procedure makes differentiation of focal liver lesions from congestive changes more challenging than other cirrhotic conditions. Thus, most institutions use MRI rather than US for monitoring in the setting of cirrhosis. In addition, the evaluation for HCC is challenging due to the vascular changes associated with the Fontan procedure, because the typical HCC pattern of delayed venous-phase contrast washout may not be appreciated within the background congestive hepatopathy. Thus, biopsy is usually required. Also, distinguishing dysplastic lesions from true HCC based on LiRADS criteria is very challenging as well. There are no current society endorsed guidelines, and institutions may vary in the monitoring of chronic liver disease in this patient population. The above algorithm represents an accepted approach and is consistent with the consensus from the Fontan-Associated Liver Disease proceedings from the American College of Cardiology Shareholders Meeting (2015) as well as the consensus of a multidisciplinary group of American Society of Transplantation members (2020).

References (AB-26)

v1.0.2024

1. Heimbach JK, Kulik LM, Finn RS, et al. AASLD guidelines for the treatment of hepatocellular carcinoma. *Hepatology*. 2017;67(1):358-380. doi:10.1002/hep.29086.
2. Benson AB, D'Angelica MI, Abbot D, et al. National Comprehensive Cancer Network (NCCN) Guidelines Version 2.2018 – June 7, 2018. Hepatobiliary Cancers, available at: https://www.nccn.org/professionals/physician_gls/pdf/hepatobiliary.pdf. Referenced with permission from the NCCN Clinical Practice Guidelines in Oncology (NCCN Guidelines™) for Hepatobiliary Cancers, V 2.2018 – June 7, 2018. © 2018 National Comprehensive Cancer Network, Inc. All rights reserved. The NCCN Guidelines™ and illustrations herein may not be reproduced in any form for any purpose without the express written permission of the NCCN. To view the most recent and complete version of the NCCN Guidelines™, go online to NCCN.org.
3. Ascites SR, Katz J. Portal Hypertension Imaging: Practice Essentials, Radiography, Computed Tomography. Published June 9, 2017.
4. Khanna R, Sarin SK. Non-cirrhotic portal hypertension – Diagnosis and management. *Journal of Hepatology*. 2014;60(2):421-441.
5. Marrero JA, Kulik LM, Sirlin CB, et al. Diagnosis, Staging, and Management of Hepatocellular Carcinoma: 2018 Practice Guidance by the American Association for the Study of Liver Diseases. *Hepatology*. 2018;68(2):723-750. doi:10.1002/hep.29913.
6. Diamond T, Ovchinsky N. Fontan-associated liver disease: Monitoring progression of liver fibrosis. *Clinical Liver Disease*. 2018;11(1):1-5. doi:10.1002/cld.681.
7. Daniels CJ, Bradley EA, Landzberg MJ, et al. Fontan-Associated Liver Disease. *Journal of the American College of Cardiology*. 2017;70(25):3173-3194. doi:10.1016/j.jacc.2017.10.045.
8. Munsterman ID, Duijnhouwer AL, Kendall TJ, et al. The clinical spectrum of Fontan-associated liver disease: results from a prospective multimodality screening cohort. *European Heart Journal*. 2018;40(13):1057-1068. doi:10.1093/eurheartj/ehy620.
9. Lindor KD, Bowlus CL, Boyer J, Levy C, Mayo M. Primary Biliary Cholangitis: 2018 Practice Guidance from the American Association for the Study of Liver Diseases. *Hepatology*. June 2018. doi:10.1002/hep.30145.
10. Primary Biliary Cirrhosis and Primary Sclerosing Cholangitis: a Review Featuring a Womens Health Perspective. *Journal of Clinical and Translational Hepatology*. 2014;2(4). doi:10.14218/jcth.2014.00024.
11. European Association for the Study of the Liver. EASL clinical practice guidelines on the management of ascites, spontaneous bacterial peritonitis, and hepatorenal syndrome in cirrhosis. *J Hepatol*. 2010;53(3):397-417. doi:10.1016/j.jhep.2010.05.004.
12. Aithal GP, Palaniyappan N, China L, et. al. Guidelines on the management of ascites in cirrhosis. *Gut*. 2020;Epub ahead of print;1-21. doi:10.1136/gutjnl-2020-321790.
13. Oey RC, van Buuren HR, de Man RA. The diagnostic work-up in patients with ascites: current guidelines and future prospects. *Neth J Med*. 2016;74(8):330-335.
14. Emamaullee J, Zaidi AN, Schiano T, et. al. Fontan-associated liver disease. Screening, management and transplant considerations. *Circulation*. 2020;142:519-604.
15. Biggins SW, Anglei P, Garcia-Tsao G, et. al. Diagnosis, evaluation, and management of ascites, spontaneous bacterial peritonitis and hepatorenal syndrome: 2021 practice guidance by the American Association for the Study of Liver Diseases. *Hepatology*. 2021;74(2):1014-1048.
16. Hemgenix. Package insert. CSL Behring LLC; 2022. <https://www.fda.gov/media/163467/download>.
17. Chavhan GB, Yoo S, Lam CZ, Khanna G. Abdominal imaging of children and young adults with Fontan circulation: pathophysiology and surveillance. *American Journal of Roentgenology*. 2021;217(1):207-217. doi:10.2214/AJR.20.23404.

MR

Cholangiopancreatography (MRCP) (AB-27)

Guideline

MRCP (AB-27.1)

References (AB-27)

MRCP (AB-27.1)

AB.MR.0027.1.A

v1.0.2024

- MRCP (Magnetic Resonance Cholangio Pancreatography) is a non-invasive imaging procedure, which is used to visualize the biliary and pancreatic ductal system. It is used most often in the following circumstances:
 - Suspected gallstone pancreatitis (See: **Pancreatitis (AB-33)**)
 - Suspected biliary pain (See: **Right Upper Quadrant Pain (AB-2.3)** including Suspected Gallbladder Disease and **Epigastric Pain and Dyspepsia (AB-2.5)**)
 - Pancreatic cyst and pseudocyst evaluation (See: **Pancreatic Lesion (AB-31)**, and **Pancreatitis (AB-33)**)
 - Evaluation of abnormal liver chemistries (See: **Abnormal Liver Chemistries (AB-30.1)**)
 - Evaluation of the pancreas secondary to abdominal trauma with suspected duct injury or pseudocyst
 - Recurrent pancreatitis of unknown etiology (See: **Pancreatitis (AB-33)**)
 - Evaluation and follow-up of Primary Sclerosing Cholangitis (See: **Primary Sclerosing Cholangitis (PSC) (AB-23.4)**)
 - Evaluation of jaundice (See: **Abnormal Liver Chemistries (AB-30.1)**)
 - Evaluation of congenital anomalies of the cystic and hepatic ducts
 - Post-surgical biliary anatomy and complications (See: **Liver Transplant, Post-Transplant Imaging (AB-42.3)**)
 - For the further evaluation of abnormal ultrasound or CT findings of dilated pancreatic duct, enlargement, or fullness of the pancreas.
- Code assignment for MRCP
 - In general, there is no specific CPT code to describe MRCP. To report an MRCP, one of the MRI Abdomen codes should be selected, depending on contrast needs (CPT® 74181, CPT® 74182, or CPT® 74183).
 - There is a Level II HCPCS code for MRCP, S8037, used by some insurers. However this code (and any other code beginning with the letter “S”) is not payable by Medicare.
 - Reporting or billing a *second* MRI code to represent the “MRCP portion” of the study is not supported. When this occurs, it is usually seen as two simultaneous MRI requests, an MRI Abdomen without and with contrast (CPT® 74183) AND an additional MRI Abdomen without contrast (CPT® 74181). This second MRI code, as noted, is not supported. Both the primary MRI Abdomen AND the MRCP portion of the study are covered by the single MRI Abdomen code (CPT® 74183).
 - Requests for 3D rendering (either CPT® 76376 or CPT® 76377) are approvable, if requested, in addition to the primary MRI Abdomen code (CPT® 74181, CPT® 74182, or CPT® 74183).

References (AB-27)

v1.0.2024

1. Faerber EN, Benator RM, Browne LP, et al. American College of Radiology. ACR practice guideline for the performance of magnetic resonance imaging (MRI) of the abdomen. Reston (VA): American College of Radiology (ACR); 2010 (revised 2015).
2. Kaltenthaler EC, Walters SJ, Chilcott J, et al. MRCP compared to diagnostic ERCP for diagnosis when biliary obstruction is suspected: a systematic review. *BMC Medical Imaging*. 2006;6(1).
3. Griffin N, Charles-Edwards G, Grant LA. Magnetic resonance cholangiopancreatography: the ABC of MRCP. *Insights into Imaging*. 2011;3(1):11-21. doi:10.1007/s13244-011-0129-9.

Gallbladder (AB-28)

Guideline

Gallbladder (AB-28.1)

References (AB-28)

Gallbladder (AB-28.1)

AB.GP.0028.1.A
v1.0.2024

- Findings on ultrasound or EUS suspicious for malignancy:
 - CT Abdomen with or without and with contrast (CPT® 74160 or CPT® 74170)
- Findings on ultrasound inconclusive for adenomyomatosis:
 - Contrast-Enhanced US (CEUS, CPT® 76978, CPT® 76979)
 - If US and CEUS are inconclusive for adenomyomatosis:
 - MRI Abdomen without and with contrast (CPT® 74183)
- For confirmed gallbladder malignancy:
 - See **Gallbladder and Biliary Tumors - Initial Work-up/Staging (ONC-14.6)** in the Oncology Imaging Guidelines

Gallbladder Polyps

- Individuals at increased risk for gallbladder malignancy (if surgery not chosen):
 - Age >50
 - Primary Sclerosing Cholangitis
 - Indian ethnicity
 - Sessile polyp or gallbladder wall thickening >4mm
- Increased risk for gallbladder malignancy:
 - Polyp <6 mm
 - Ultrasound at 6 months, then yearly for 5 years
 - Polyp 6-9 mm (If cholecystectomy is not chosen)
 - Ultrasound at 6 months, then yearly for 5 years
- No increased risk for gallbladder malignancy:
 - Polyp <6 mm
 - Ultrasound at 1, 3, and 5 years
 - Polyp 6-9 mm
 - Ultrasound at 6 months, and then yearly for 5 years
- Gallbladder polyp ≥10 mm:
 - Surgery recommended. If surgery not performed, follow guidelines for increased risk of gallbladder malignancy as noted above.
- Alternative Imaging:
 - Endoscopic ultrasound (EUS) may provide additional information in the diagnosis of gallbladder polyps. There is insufficient data that advanced imaging (CT or MRI) should be used ahead of conventional ultrasound in the investigation of gallbladder polyps.¹

References (AB-28)

v1.0.2024

1. Wiles R, Thoeni RF, Barbu ST, et al. Management and follow-up of gallbladder polyps. *European Radiology*. 2017;27(9):3856-3866. doi:10.1007/s00330-017-4742-y.
2. Andrén-Sandberg Å. Diagnosis and Management of Gallbladder Polyps. *North American Journal of Medical Sciences*. 2012;4(5):203. doi:10.4103/1947-2714.95897.
3. Mccain RS, Diamond A, Jones C, Coleman HG. Current practices and future prospects for the management of gallbladder polyps: A topical review. *World Journal of Gastroenterology*. 2018;24(26):2844-2852. doi:10.3748/wjg.v24.i26.2844.
4. Anderson MA, Appalaneni V, Ben-Menachem T, et al. The role of endoscopy in the evaluation and treatment of patients with biliary neoplasia. *Gastrointestinal Endoscopy*. 2013;77(2):167-174. doi:10.1016/j.gie.2012.09.029.
5. Bonatti M, Vezzali N, Lombardo F, et al. Gallbladder adenomyomatosis: imaging findings, tricks and pitfalls. *Insights Imaging*. 2017;8(2):243-253. doi:1007/s13244-017-0544-7.
6. Golse N, Lewin M, Rode A, Sebagh M, Mabrut J-Y. Gallbladder adenomyomatosis: diagnosis and management. *J Visc Surg*. 2017;154(5):345-353. doi:10.1016/j.jviscsurg.2017.06.004.

Liver Lesion Characterization (AB-29)

Guideline

Liver Lesion Characterization (AB-29.1)

Fatty Liver (Non-Alcoholic Fatty Liver Disease – NAFLD) (AB-29.2)

Polycystic Liver Disease (AB-29.3)

Isolated or Incidental Hepatomegaly (AB-29.4)

References (AB-29)

Liver Lesion Characterization (AB-29.1)

AB.LL.0029.1.A

v1.0.2024

Note: Advanced imaging approvals in this section refers to MRI Abdomen without and with contrast (CPT® 74183), CT Abdomen with contrast (CPT® 74160), CT Abdomen without and with contrast (CPT® 74170) and Contrast-Enhanced Ultrasound (CPT® 76978-initial lesion, CPT® 76979-additional lesions). In the following section, if only CT Abdomen with contrast (CPT® 74160) is noted as the appropriate study, it is because the American College of Radiology has determined that a prior without contrast study does not provide any added benefit. It should also be noted that a standard “triple-phase CT” liver does not involve a prior without contrast study (See: [CT Imaging \(AB-1.2\)](#))

- **Low-risk** individuals defined as:
 - No known primary malignancy
 - No hepatic dysfunction (abnormal liver tests)
 - No known underlying chronic liver disease
 - No history of alcoholism, sclerosing cholangitis, choledochal cysts, hemochromatosis, or anabolic steroid use²
- High-risk individual would have one or more of the above conditions.
- Liver Lesion discovered on US:
 - Indeterminate Liver Lesion ≥1cm on initial imaging
 - No suspicion or evidence of extrahepatic malignancy or underlying liver disease
 - MRI Abdomen without and with contrast (CPT® 74183) or CT Abdomen with contrast (CPT® 74160) or Contrast-Enhanced US (CEUS, CPT® 76978, CPT® 76979)
 - Known history of an extrahepatic malignancy:
 - MRI Abdomen without and with contrast (CPT® 74183) or CT Abdomen with contrast or without and with contrast (CPT® 74160 or CPT® 74170)
 - Known history of chronic liver disease:
 - See: [Chronic Liver Disease, Cirrhosis, and Screening for HCC \(AB-26.1\)](#)
 - Indeterminate Liver Lesion <1cm on initial imaging
 - Known underlying chronic liver disease
 - See: [Chronic Liver Disease, Cirrhosis, and Screening for HCC \(AB-26.1\)](#)
 - Known history of an extrahepatic malignancy:

- MRI Abdomen without and with contrast (CPT® 74183) is the preferred study
- Contrast-Enhanced US (CPT® 76978, CPT® 76979) is appropriate
- CT Abdomen is generally not the appropriate study in this scenario. In most circumstances, the resolution of CT does not allow for definitive characterization of lesions <1cm.
- Liver Lesion discovered on CT (non-contrast or single-contrast) or non-contrast MRI
 - Indeterminate, ≥1cm on initial imaging:
 - No suspicion or evidence of extrahepatic malignancy or underlying liver disease
 - Multiphase CT Abdomen with contrast (CPT® 74160), MRI Abdomen without and with contrast (CPT® 74183), or CEUS (CPT® 76978 and/or CPT® 76979)
 - Known history of an extrahepatic malignancy:
 - MRI Abdomen without and with contrast (CPT® 74183), CT Abdomen with contrast or without and with contrast (CPT® 74160 or CPT® 74170), or CEUS (CPT® 76978 or CPT® 76979)
 - Known chronic liver disease:
 - See: **Chronic Liver Disease, Cirrhosis, and Screening for HCC (AB-26.1)**
 - Indeterminate liver lesion <1cm on initial imaging:
 - Known history of an extrahepatic malignancy:
 - MRI Abdomen without and with contrast (CPT® 74183), Multiphase CT Abdomen (CPT® 74160), or CEUS (CPT® 76978 and/or CPT® 76979)
 - Known chronic liver disease:
 - See: **Chronic Liver Disease, Cirrhosis, and Screening for HCC (AB-26.1)**
- Additional scenarios and follow-up imaging for an Indeterminate lesion²:
 - Indeterminate lesion <1cm on US, CT, or MRI, **low-risk** individual (See above “Low-Risk individuals”) and no suspicious imaging features noted on the study
 - No further imaging
 - Indeterminate lesion <1cm in high-risk individuals on US, CT, or unenhanced MRI (See above ‘High Risk’) not specifically dealt with in the above guidelines:
 - MRI Abdomen without and with contrast (CPT® 74183)
 - If, after MRI, the lesion remains indeterminate or not fully characterized
 - See: **Liver Metastases (ONC-31.2)** or malignancy-specific guidelines in the Oncology Imaging Guidelines
 - If **biopsy cannot be performed**, follow-up MRI can be obtained in 3-6 months. Additional imaging in this setting can be considered on an individual basis. This timeframe would also apply if the lesion is

- indeterminate and an MRI with Eovist is requested for further evaluation in this setting.
- Most lesions $\geq 1\text{cm}$ can be categorized by MRI or histology. For lesions which have been categorized, regardless of size, see below.
 - For the imaging of specific focal liver lesions:
 - Suspected hepatic adenoma³:
 - MRI is considered the best technique for characterization. Follow-up imaging can be CT Abdomen (CPT[®] 74160 or CPT[®] 74170) or MRI Abdomen (CPT[®] 74183) every 6 months for 2 years, and then annually, to establish any growth patterns and assess for malignant transformation.
 - Hepatic Hemangioma (if not completely characterized on initial CT without a liver protocol):³
 - Multiphase CT Abdomen (CPT[®] 74160 or CPT[®] 74170) or MRI Abdomen (CPT[®] 74183)
 - Additional follow-up imaging is not required if the advanced imaging study demonstrates classic features of hemangioma with the following exception:
 - Giant hemangiomas ($>4\text{cm}$) can be followed by limited abdominal US in 6-12 months. If no change in size, no further follow-up is indicated, unless it becomes symptomatic.
 - See below for pre-operative considerations
 - Focal Nodular Hyperplasia (FNH)³:
 - MRI Abdomen (CPT[®] 74183) or CT Abdomen (CPT[®] 74160 or CPT[®] 74170) to confirm a diagnosis of FNH. The use of Eovist contrast is often diagnostic in differentiating FNH from other lesions seen on MRI or CT.
 - Additional follow-up is annual US for 2 to 3 years in women diagnosed with FNH who are continuing to use oral contraceptives. Follow-up with CT (CPT[®] 74160 or CPT[®] 74170) or MRI (CPT[®] 74183) can be done if the lesion is not adequately visualized on US.
 - Hepatic cysts³:
 - Asymptomatic, simple cysts do not require additional follow-up.
 - For complicated cysts (US shows internal septations, fenestrations, calcifications, irregular walls, as well as the presence of daughter cysts):
 - CT Abdomen (CPT[®] 74160 or CPT[®] 74170) or MRI Abdomen (CPT[®] 74183) can be performed
 - Additional indications for advanced imaging (MRI Abdomen or CT Abdomen):
 - If documented that a percutaneous liver biopsy is to be considered if imaging is atypical or inconclusive.¹
 - Fatty liver on US with a focal liver lesion.
 - **If there is a technical limitation to US (e.g. marked heterogeneity, or other specifically noted technical limitations of US such as obscuration by intestinal gas, chest wall deformity, etc.)⁵

- For suspected liver metastases, see: **Liver Metastases (ONC-31.2)** in the Oncology Imaging Guidelines
- Preoperative studies for individuals with large hemangiomas or adenomas considered for resection:
 - MRA Abdomen (CPT® 74185) or CTA Abdomen (CPT® 74175) can be considered
- For Indeterminate Lesions ≥ 1 cm in categories for which defined guidelines do not exist (i.e., underlying chronic liver disease, **Chronic Liver Disease, Cirrhosis, and Screening for HCC (AB-26.1)**, underlying malignancy, **Liver Metastases (ONC-31.2)** or the specific malignancy in the Oncology Imaging Guidelines, hepatic adenoma, etc.) a biopsy should be considered when the findings from advanced imaging are inconclusive. In clinical situations when a biopsy cannot be performed (such as a medical contraindication or a liver transplant candidate due to the risk of needle-tract seeding), or is inconclusive, a short-term surveillance MRI can be performed in 3-4 months to monitor lesion stability.
- This can be repeated every 6 months, as necessary in this scenario.¹ This timeframe would also apply if an MRI with Eovist is requested for short-term follow-up of an indeterminate lesion imaged on MRI Abdomen without and with contrast performed with other contrast, such as gadolinium. An exception would be if the differential is between FNH vs. hepatic adenoma or other benign lesions. FNH follow-up is yearly, and hepatic adenoma would require a 6 month follow-up study; if the differential of the lesion is between FNH and hepatic adenoma, then the follow-up study should be 6 months.
- Nuclear Medicine imaging of the Liver (CPT® 78201, CPT® 78202, CPT® 78803, CPT® 78215, CPT® 78216, or CPT® 78830) are rarely performed, but can be considered when US, CT, and MRI are unavailable or contraindicated for:
 - Evaluation of liver mass, trauma, or suspected focal nodular hyperplasia (FNH)
 - Differentiation of hepatic hemangioma from FNH
 - Diffuse hepatic disease or elevated liver function tests

Fatty Liver (Non-Alcoholic Fatty Liver Disease – NAFLD) (AB-29.2)

AB.LL.0029.2.A

v1.0.2024

- Non-Alcoholic Fatty Liver Disease
 - Fatty liver incidentally discovered on imaging (US/CT/MRI) or suspected:
 - Magnetic Resonance Elastography (MRE) (CPT® 76391)
 - See: **Liver Elastography (AB-45)** for MRE indications
 - Magnetic Resonance-Protein Density Fat Fraction (MRI-PDFF, usually requested as CPT® 74181 or 74183), MR Spectroscopy (MR-S, CPT® 76390), and the multiparametric MRI referred to as Liver Multiscan (LMS, Category III CPT® code 0648T or 0649T) for evaluation of fatty liver disease:
 - With regards to the above procedures, their main current utility is in assessing response to therapy in clinical trials. Their role in clinical practice, or with what frequency one would image, has not been defined. In view of this, they are considered investigational at this time.
 - HCC Screening for Fatty Liver with cirrhosis or advanced fibrosis:
 - See: **Chronic Liver Disease, Cirrhosis, and Screening for HCC AB-26.1)**
 - MRI or CT for the further evaluation of incidentally discovered fatty liver on US, in the absence of a specific finding needing further characterization such as a nodule, is generally not indicated. See: **Liver Lesion Characterization and Additional Indications for Advanced Imaging AB-29.1**. In addition, the finding of fatty liver alone on CT with contrast does not require MRI for confirmation.
 - Requests for imaging studies to screen individuals at high-risk for NAFLD (e.g., diabetes or obesity) or for screening family members of individuals with NAFLD is not approvable at this time.⁴

Polycystic Liver Disease (AB-29.3)

AB.LL.0029.3.A

v1.0.2024

- Polycystic Liver Disease
 - Defined as >20 cysts, or the presence of cysts occupying $\frac{1}{2}$ the volume of the hepatic parenchyma
 - Most commonly seen as an extra-renal manifestation of Autosomal Dominant Polycystic Kidney Disease, though may occur as Autosomal Dominant Polycystic Liver Disease.
 - Imaging:
 - For prognostication purposes MRI Abdomen (CPT® 74183) or CT Abdomen (CPT® 74160 or CPT® 74170) can be performed initially to assess liver volume.
 - At this time, there is no evidence that the asymptomatic patient requires surveillance imaging or monitoring.
 - Suspected complications such as cyst rupture or hemorrhage (manifested by acute pain in the upper abdomen):
 - MRI Abdomen (CPT® 74183) or CT Abdomen (CPT® 74160 or CPT® 74170)

Isolated or Incidental Hepatomegaly (AB-29.4)

AB.LL.0029.4.A

v1.0.2024

- Initial imaging of hepatomegaly discovered or suspected on physical examination:
 - US Abdomen (CPT® 76700 or CPT® 76705) and Duplex (CPT® 93975 or CPT® 93976)
- Further evaluation of abnormalities on initial ultrasound that require further characterization:
 - Refer to specific guidelines for the abnormality detected on US
 - Fatty liver, see: **Fatty Liver (Non-Alcoholic Fatty Liver Disease - NAFLD) (AB-29.2)**
 - Hepatic lesion, see: **Liver Lesion Characterization (AB-29.1)**
- Hepatomegaly discovered on ultrasound and no indeterminate abnormalities:
 - Medical workup, including lab studies such as liver tests, and history and physical should be performed to assess for suspected underlying disease (e.g. infiltrative disease such as amyloid, lymphoma, etc.)
 - Lab abnormalities and/or symptoms of a specific disease process should follow imaging studies outlined in the guideline for that disease process
 - Advanced imaging in the absence of symptoms or lab abnormalities indicative of an underlying disorder is not indicated

Background and Supporting Information

As noted by the AASLD "...imaging tests, such as ultrasound, computed tomography (CT), and MR, do not reliably reflect the spectrum of liver histology in patients with NAFLD." In addition, "MR imaging, either by spectroscopy or by proton density fat fraction is an excellent noninvasive modality for quantifying hepatic fat and is being widely used in NAFLD clinical trials.....However, the utility of noninvasively quantifying HS (hepatic steatosis) in patients with NAFLD in routine clinical care is limited".⁴

- Hints for liver lesion imaging:
 - Imaging accuracy:
 - A non-contrast CT is less sensitive than ultrasound
 - A non-contrast MRI is better than a non-contrast CT, but inadequate to define the etiology of a lesion
 - Triple-phase scanning is essential in characterizing a liver lesion
- How to interpret the radiologist's descriptors:
 - Hemangioma:
 - Hyperechoic
 - Peripheral nodular enhancement

- Fills in from the periphery (nodular centripetal fill-in on venous and delayed phases)
- Focal nodular hyperplasia:
 - Homogenous enhancement
 - Washout. No delayed rim enhancement
 - Central scar (with fibrous-appearing septae radiating from the scar)
 - MRI specifics:
 - Homogenous on T1
 - Scar hyperintense on T2
 - Uniformly hyperintense with contrast
- Hepatic adenoma:
 - Irregular enhancement
 - Fat-containing
 - Washout
 - Central hemorrhage
 - No rim enhancement
 - No central scar
 - MRI specifics: Hyperintense signal on T1 and T2-weighted imaging with intra-lesional lipid
- Hepatocellular carcinoma:
 - HCC's are hypervascular and receive 100% of their blood supply from the hepatic artery, whereas the liver parenchyma receives 30% from the hepatic artery and 70% from the portal vein, and this discrepancy can be exploited during imaging.
 - Dynamic imaging via MRI and CT follows tumor density with time after IV contrast bolus.
 - During the early arterial phase: HCC appears brighter than surrounding liver (hyperintense) due to hepatic arterial supply.
 - May have a necrotic central region
 - Washes out rapidly
 - Delayed post-contrast phase: rim enhancement (a "tumor capsule")
- Focal fat (pseudo-mass)
 - Area with sharply demarcated borders
 - Absence of mass effect of surrounding architecture
 - Vessels can course through the region
 - No rim enhancement
 - No central scar

References (AB-29)

v1.0.2024

1. Lalani T, Rosen MP, Blake MA, Baker ME, et al. Expert Panel on Gastrointestinal Imaging. ACR Appropriateness Criteria® liver lesion -- initial characterization. American College of Radiology (ACR), 2014.
2. Gore RM, Pickhardt PJ, Morteale KJ, et al. Management of Incidental Liver Lesions on CT: A White Paper of the ACR Incidental Findings Committee. *Journal of the American College of Radiology*. 2017;14(11):1429-1437. doi:10.1016/j.jacr.2017.07.018.
3. Marrero JA, Ahn J, Reddy KR. ACG Clinical Guideline: The Diagnosis and Management of Focal Liver Lesions. *The American Journal of Gastroenterology*. 2014;109(9):1328-1347. doi:10.1038/ajg.2014.213.
4. Chalasani N, Younossi Z, Lavine JE, et al. The diagnosis and management of nonalcoholic fatty liver disease: Practice guidance from the American Association for the Study of Liver Diseases. *Hepatology*. 2017;67(1):328-357. doi:10.1002/hep.29367.
5. Heimbach JK, Kulik LM, Finn RS, et al. AASLD guidelines for the treatment of hepatocellular carcinoma. *Hepatology*. 2017;67(1):358-380. doi:10.1002/hep.29086.
6. Albrecht T. Dynamic Vascular Pattern of Focal Liver Lesions with Contrast-Enhanced Ultrasound: Latest Results with SonoVue. *Contrast-Enhanced Ultrasound in Clinical Practice*:1-22. doi:10.1007/988-470-0357-1_1.
7. Nolsøe CP, Lorentzen T. International guidelines for contrast-enhanced ultrasonography: ultrasound imaging in the new millennium. *Ultrasonography*. 2016;35(2):89-103. doi:10.14366/usg.15057.
8. Greenbaum LD. Foreword to Guidelines and Good Clinical Practice Recommendations for Contrast Enhanced Ultrasound (CEUS) in the Liver – Update 2012. *Ultrasound in Medicine & Biology*. 2013;39(2):186. doi:10.1016/j.ultrasmedbio.2012.09.021.
9. Chalasani N, Younossi Z, Lavine JE, et al. The Diagnosis and Management of Non-alcoholic Fatty Liver Disease: Practice Guideline by the American Gastroenterological Association, American Association for the Study of Liver Diseases, and American College of Gastroenterology. *Gastroenterology*. 2012;142(7):1592-1609. doi:10.1053/j.gastro.2012.04.001.
10. Chandok N. Polycystic liver disease: a clinical review. *Annals of Hepatology*. 2012;11(6):819-826. doi:10.1016/s1665-2681(19)31406-1.
11. Cnossen WR, Drenth JP. Polycystic liver disease: an overview of pathogenesis, clinical manifestations and management. *Orphanet Journal of Rare Diseases*. 2014;9(1):69. doi:10.1186/1750-1172-9-69.
12. Aerts RMV, Laarschot LFVD, Banales JM, Drenth JP. Clinical management of polycystic liver disease. *Journal of Hepatology*. 2018;68(4):827-837. doi:10.1016/j.jhep.2017.11.024.
13. Schiffman, Mitchell. Director, Liver Institute of Virginia. Assessment of Liver Masses. Presentation at 2019 American College of Gastroenterology Hepatology School and Eastern Regional Postgraduate Course. Washington, DC, June 7-9, 2019.
14. Aytaman, Ayse. Hepatocellular Carcinoma. Presentation at 2019 American College of Gastroenterology Hepatology School and Eastern Regional Postgraduate Course. Washington, DC, June 7-9, 2019.
15. Singal, Amit. Approach to Liver Lesions: Abnormal Sonogram, Please Evaluate. Medical Director, Liver Tumor Program, UT Southwestern Medical College. Presentation at 2019 American College of Gastroenterology Hepatology School and Eastern Regional Postgraduate Course. Washington, DC, June 7-9, 2019.
16. Bell, Daniel. Et. al. Hepatocellular Carcinoma *Radiopedia*
17. Marrero JA, Kulik LM, Sirlin CB, et al. Diagnosis, Staging, and Management of Hepatocellular Carcinoma: 2018 Practice Guidance by the American Association for the Study of Liver Diseases. *Hepatology*. 2018;68(2):723-750. doi:10.1002/hep.29913.
18. Castera L, Friedrich-Rust M, Loomba R. Noninvasive Assessment of Liver Disease in Patients With Nonalcoholic Fatty Liver Disease. *Gastroenterology*. 2019;156(5). doi:10.1053/j.gastro.2018.12.036
19. Chartampilas E. Imaging of nonalcoholic fatty liver disease and its clinical utility. *Hormones*. 2018;17(1):69-81. doi:10.1007/s42000-018-0012-x
20. EASL–EASD–EASO Clinical Practice Guidelines for the management of non-alcoholic fatty liver disease. *Journal of Hepatology*. 2016;64(6):1388-1402. doi:10.1016/j.jhep.2015.11.004
21. Caussy C, Reeder SB, Sirlin CB, Loomba R. Noninvasive, Quantitative Assessment of Liver Fat by MRI-PDF as an Endpoint in NASH Trials. *Hepatology*. 2018;68(2):763-772. doi:10.1002/hep.29797
22. American College of Radiology ACR Appropriateness Criteria® Liver Lesion-Initial Characterization Revised 2020. <https://acsearch.acr.org/docs/69472/Narrative/>.
23. National Institute for Health and Care Excellence (NICE-UK). Liver Multiscan for Liver Diagnosis. Medtech Innovation Briefing 26April2019.
24. Breiman R, Beck J, Korobkin M, et al. Volume determinations using computed tomography. <AJR Am J Roentgenol>. 1982;138:329–33.

25. McNeal G, Maynard W, Branch R, et al. Liver volume measurements and three-dimensional display from MR images. <*Radiology*>. 1988;169:851–4.
26. Heymsfield S, Fulenwider T, Nordlinger B, et al. Accurate measurement of liver, kidney, and spleen volume and mass by computerized axial tomography. <*Ann Intern Med*>. 1979;90:185–7.
27. Gosink B, Leymaster C. Ultrasonic determination of hepatomegaly. <*J Clin Ultrasound*>. 1981;9:37–44.
28. Kratzer W, Fritz V, Mason RA, et al. Factors affecting liver size: a sonographic survey of 2080 subjects. <*J Ultrasound Med*>. 2003;22:1155.
29. Kudo M. Riedel's lobe of the liver and its clinical implication. <*Intern Med*>. 2000;39:87.
30. Loloi J, Patel A, McDevitt P, et al. How Strongly Do Physical Examination Estimates and Ultrasonographic Measurements of Liver Size Correlate? A Prospective Study. <*Am J Med*>. 2019;32:103.
31. Karlo C, Reiner CS, Stolzmann P, et al. CT- and MRI-based volumetry of resected liver specimen: comparison to intraoperative volume and weight measurements and calculation of conversion factors. <*Eur J Radiol*>. 2010;75:e107.
32. Farragher SW, Jara H, Chang KJ, et al. Liver and spleen volumetry with quantitative MR imaging and dual-space clustering segmentation. <*Radiology*>. 2005;237:322.

Abnormal Liver Chemistries (AB-30)

Guideline

Abnormal Liver Chemistries (AB-30.1)

References (AB-30)

Abnormal Liver Chemistries (AB-30.1)

AB.LC.0030.1.A

v1.0.2024

- The major patterns of elevation which affect work-up are:
 - Hepatocellular (AST and ALT disproportionately elevated to ALKP)
 - Cholestatic (ALKP elevated disproportionately to AST and ALT)
 - Mixed pattern (ALKP, AST, and ALT all elevated)
 - Isolated hyperbilirubinemia (elevated bilirubin and normal ALKP, ALT and AST)
 - “R” Ratio
 - “R” Ratio: The so-called “R” ratio can be used to determine whether a pattern of multiple elevated liver chemistries is predominately cholestatic or hepatocellular in origin
 - $R = (\text{ALT} / \text{Upper limit of normal (ULN)}) / (\text{ALKP} / \text{ULN ALKP})$
 - If the “R” ratio:
 - >5 = hepatocellular
 - <2 = cholestatic
 - 2-5 = mixed pattern
 - For hepatocellular, use AST or ALT elevation guidelines
 - For cholestatic, use ALKP elevation guidelines
 - Use ULN for ALT as noted below, and ULN for alkphos based on the individual lab report
- For elevated AST and/or ALT (>33 IU/l for males, >25 IU/l for females) and other LFTs are normal:
 - <2X normal:
 - Repeat lab after 3 weeks and discontinuation of medications associated with elevated LFTs (such as statins, niacin, sulfa, rifampin, tetracycline, estrogen) if applicable.
 - If LFTs remain elevated: Abdominal US (CPT® 76700 or CPT® 76705)
 - 2 to 15X normal:
 - Abdominal US (CPT® 76700 or CPT® 76705)
 - >15X normal:
 - Abdominal US with Doppler (CPT® 76700 or CPT® 76705 and CPT® 93975)
- CT Abdomen with contrast (CPT® 74160) may be approved if the above studies do not explain the cause of the elevated transaminases AND the following labs have been performed and are inconclusive:
 - HAV IgG, HBsAg, HBcAb, HBsAb, HCV Ab, iron panel (may include ferritin, serum iron, iron-binding capacity, or transferrin saturation).

- Additional labs, which may be useful, but not required, are: serum ceruloplasmin, anti-nuclear antibody (ANA), anti-smooth muscle antibody (ASMA), lipid profile, prothrombin time, creatine kinase (CK)
- If the findings suggest chronic liver disease, see: **Chronic Liver Disease, Cirrhosis and Screening for HCC (AB-26.1)**
- If the findings suggest hemochromatosis, see: **Hereditary (Primary) Hemochromatosis (HH) and Other Iron Storage Diseases (AB-11.2)**
- Elevated alkaline phosphatase level (or GGT), and other LFTs are normal
 - Etiology of elevated ALKP should be determined prior to imaging.
 - If isolated ALKP elevation, GGT should be obtained for confirmation of hepatic etiology, prior to imaging. If ALKP is elevated with other LFTs, no confirmatory test is necessary.
 - For confirmed hepatic etiology of elevated ALKP, Abdominal or RUQ ultrasound (CPT® 76700 or CPT® 76705)
 - If dilated biliary ducts on US: MRCP
 - If no dilated biliary ducts: anti-mitochondrial antibody (AMA) should be checked prior to advanced imaging.
 - If AMA is negative, and ALKP >2X ULN: MRCP
 - If AMA is negative, and ALKP 1 to 2X ULN: observe for 6 months, if ALKP remains elevated: MRCP
 - CT Abdomen with contrast (CPT® 74160) if the above studies are unrevealing or individual cannot undergo MRCP.
 - Isolated elevated bilirubin (no other LFTs elevated).
 - An isolated elevated bilirubin should be fractionated into direct (conjugated) and indirect (unconjugated) levels.
 - No advanced imaging if elevation is unconjugated, and no other LFT elevations
 - RUQ ultrasound if elevation is conjugated
 - MRCP if biliary ducts dilated
 - Check AMA prior to advanced imaging if biliary ducts not dilated
 - MRCP or liver biopsy can be considered if negative and elevation persists or is unexplained
 - CT Abdomen with contrast (CPT® 74160) if the above studies are unremarkable or the individual cannot undergo MRCP.
 - For individuals with elevated LFTs and suspicion of sclerosing cholangitis, such as those with IBD, see: **Primary Sclerosing Cholangitis (PSC) (AB-23.4)**.
 - For individuals with elevated LFTs and history of underlying malignancy, please refer to the specific oncology guidelines, when appropriate.
 - Requests for additional advanced imaging (CT, MRI, etc.) are based on the prior imaging results, as appropriate to the finding (for example, if a lesion is identified that needs further characterization, refer to liver lesion imaging as per **Liver Lesion Characterization (AB-29.1)**).

- Clinical jaundice, no known predisposing condition
 - Abdominal ultrasound (CPT® 76700 or CPT® 76705)
 - For further imaging, follow guideline for elevated bilirubin
- Clinical jaundice, suspected mechanical obstruction based on clinical condition or laboratory values (e.g., known choledocholithiasis, acute and chronic pancreatitis, suspected stricture from a recent invasive procedure, previous biliary surgery, suspected tumor), or US findings suggesting mechanical biliary obstruction, non-diagnostic or technically limited US (e.g., large amounts of intestinal gas, obesity with BMI >35):
 - CT Abdomen with contrast (CPT® 74160) or
 - MRI and/or MRCP (CPT® 74183 or CPT® 74181)

Background and Supporting Information

- The standard laboratory tests commonly referred to as “LFTs” include bilirubin, alkaline phosphatase (alkphos or ALKP), aspartate transaminase (AST), alanine transaminase (ALT), and gamma-glutamyl transferase (GGT).

References (AB-30)

v1.0.2024

1. Kwo, Paul, et al. ACG Clinical Guideline: Evaluation of Abnormal Liver Chemistries. *Am J Gastroenterol* 2017; 112:18-35.
2. O'Shea RS, Dasarathy S, McCullough AJ. ACG practice guidelines: alcoholic liver disease. *American Journal of Gastroenterology*. 2010;105:14-32.
3. American College of Radiology ACR Appropriateness Criteria® Jaundice, Revised 2018.
4. EASL Clinical Practice Guidelines: Management of cholestatic liver diseases. *Journal of Hepatology*. 2009;51(2):237-267. doi:10.1016/j.jhep.2009.04.009.
5. Fargo, MV, et al. Evaluation of Jaundice in Adults. *Am Fam Physician*, 2017;95(3):164-68.
6. Aronsohn A, Gondal B. A Systematic Approach to Patients with Jaundice. *Seminars in Interventional Radiology*. 2016;33(04):253-258. doi:10.1055/s-0036-1592331.

Pancreatic Lesion (AB-31)

Guideline

Pancreatic Cystic Lesions (AB-31.1)

Incidental Pancreatic Mass or Suspected Metastatic Disease to Pancreas (AB-31.2)

References (AB-31)

Pancreatic Cystic Lesions (AB-31.1)

AB.PC.0031.1.A

v1.0.2024

Screening studies for pancreatic cancer can be considered in those who are considered high risk in the following guideline: **Pancreatic Cancer (ONC-13)** in the Oncology Imaging Guidelines.

- Note:
 - Individuals who are not medically fit for surgery should not undergo further surveillance of incidentally found pancreatic cysts, irrespective of size.
 - Surveillance should be discontinued if an individual is no longer a surgical candidate. However, follow-up imaging can be performed if requested for a symptomatic cyst (such as the development of jaundice secondary to cyst), in which palliative treatment might be available.
- This guideline applies to the following pancreatic cystic lesions:
 - Intraductal papillary mucinous neoplasms (IPMN)
 - Mucinous cystic neoplasms (MCN)
 - Serous Cystadenomas (SCA)
 - Solid-pseudopapillary neoplasms (SPN)
- Pancreatic Cyst seen on Imaging-Initial Management:
 - MRI Abdomen (CPT[®] 74183) and/or MRCP are the tests of choice for initial evaluation.
 - Both MRI Abdomen and MRCP may be performed, but only one CPT[®] 74183 should be used, not two.
 - CT Pancreatic protocol (CPT[®] 74160) or EUS are alternatives in patients who are unable to undergo MRI.
 - Indeterminate cysts may benefit from a second imaging modality or EUS prior to proceeding with surveillance. MRI/MRCP can be approved to better characterize the lesion, without reference to the timeframe for follow-up imaging, if a previous US or CT Abdomen has been performed.
 - Radiographic diagnosis of a non-neoplastic cyst or classic features of a serous cystadenoma
 - No further imaging
 - If any of the following are present the individual should proceed to EUS + FNA and depending on findings, surgical consultation:
 - Main duct >5mm
 - Cyst ≥3cm
 - Change in main duct caliber with upstream atrophy
 - If EUS does not reveal findings of main duct involvement, patulous ampulla, cytology with high-grade dysplasia or pancreatic malignancy, or a mural nodule, then follow up MRI should be performed in 6 months.

- Pancreatic Cyst Follow up Imaging
 - If high risk features (See below High Risk Considerations and Features) are not present, then the next follow-up imaging proceeds as follows:
 - Cyst <1cm: MRI in 2 years
 - Cyst 1-<2cm: MRI in 1 year
 - Cyst 2-3cm: if cyst is not clearly an IPMN or MCN then proceed with EUS. If it is an IPMN or MCN, then MRI at 6-12 months.
 - If the cyst is determined to be a serous cystadenoma, then no further evaluation unless symptomatic.
 - Additional Surveillance for a presumed IPMN or MCN (imaging from time of presentation):
 - (Note: MRCP or MRI/MRCP is the preferred modality for surveillance due to non-invasiveness, lack of radiation, and improved delineation of the main pancreatic duct. In addition, since the timeframes for surveillance imaging are based on the size of the cyst as well as characteristics such as the presence or absence of high-risk features, it is necessary to have an adequate description of these findings from the previous imaging study, either by inclusion of the previous imaging report, or an adequate description of the findings. Finally, the date of the previous study is needed so that the appropriate timing for the next study can be determined.)
 - Cyst <1cm
 - MRI every 2 years for 4 years.
 - If stable after 4 years consider lengthening of interval imaging.
 - If increase in cyst size, then MRI or EUS in 6 months.
 - If stable, repeat again in 1 year and if stable return to MRI every 2 years.
 - Cyst 1-<2cm
 - MRI yearly for 3 years
 - If stable for 3 years, then change to MRI every 2 years for 4 years
 - If stable after the additional 4 years, consider lengthening of interval for surveillance.
 - If increase in cyst size, repeat MRI in 6 months. If stable, repeat MRI in 1 year and if remains stable, resume original surveillance schedule.
 - Cyst 2-<3cm
 - MRI every 6-12 months for 3 years
 - If stable after 3 years, change to MRI every year for 4 years
 - If remains stable, consider lengthening of surveillance interval
 - Cyst ≥3cm
 - MRI alternating with EUS every 6 months for 3 years
 - If stable for 3 years, increase interval to MRI alternating with EUS yearly for 4 years.
 - If remains stable, consider lengthening of surveillance interval.
 - If increase in cyst size, EUS + FNA

- Additional considerations
 - Individuals with asymptomatic cysts that are diagnosed as pseudocysts on initial imaging and clinical history, or are determined to be serous cystadenomas, do not require further evaluation.
 - High-Risk Considerations and Features
 - Individuals with IPMNs or MCNs with new onset or worsening diabetes
 - Rapid increase in cyst size (>3mm/year) during surveillance may have an increased risk of malignancy and should undergo a short-interval MRI or EUS.
 - Additional high-risk features which may prompt early evaluation are:
 - Jaundice secondary to the cyst
 - Acute pancreatitis secondary to the cyst
 - Significantly elevated CA 19-9
 - Presence of a mural nodule or solid component either within the cyst or in the pancreatic parenchyma
 - Dilation of the main pancreatic duct >5mm
 - Focal dilation of the pancreatic duct concerning for main duct IPMN or an obstructing lesion
 - IPMNs or MCNs measuring ≥3cm in diameter
 - Presence of high-grade dysplasia or pancreatic cancer on cytology. In this circumstance, imaging should be at the discretion of the provider.
- Post-op surveillance
 - Surgically resected serous cystadenomas, pseudocyst, or other benign cyst:
 - No additional imaging after resection
 - Surgically resected mucinous cystic neoplasms (MCNs) without an associated pancreatic malignancy (can have low, intermediate, or high-grade dysplasia):
 - No additional post-op surveillance
 - Surgically resected MCNs with invasive cancer:
 - Standard surveillance-based pancreatic cancer guidelines (See: **Pancreatic Cancer-Surveillance/Follow-up (ONC-13.5)** in the Oncology Imaging Guidelines) for 5 years. No surveillance required after 5 years.
 - Surgically resected IPMNs
 - IPMN with cancer
 - Pancreatic cancer surveillance guidelines (See: **Pancreatic Cancer-Surveillance/Follow-up (ONC-13.5)** in the Oncology Imaging Guidelines)
 - IPMN with high-grade dysplasia
 - MRI Abdomen (CPT® 74183) or EUS every 6 months
 - IPMN with low- or intermediate-grade dysplasia
 - MRI Abdomen (CPT® 74183) every 2 years

- Surgically resected solid-pseudopapillary neoplasm with negative margins:
 - MRI Abdomen (CPT® 74183) yearly for 5 years.
- See: **MR Cholangiopancreatography (MRCP) (AB-27)** for coding guidelines for MRCP.

Incidental Pancreatic Mass or Suspected Metastatic Disease to Pancreas (AB-31.2)

AB.PC.0031.2.A

v1.0.2024

- CT Abdomen with contrast with dual phase imaging (CPT® 74160), or MRI Abdomen without and with contrast (CPT® 74183).
- Note: A pancreatic protocol CT involves scan acquisition during a parenchymal and portal venous phase, each of which are post-contrast administration.

References (AB-31)

v1.0.2024

1. Vege SS, Ziring B, Jain R, et al. and the Clinical Guidelines Committee Guideline American Gastroenterological Association Institute guideline on the diagnosis and management of asymptomatic neoplastic pancreatic cysts. *Gastroenterol.* 2015 Apr;148(4):819-822.
2. Elta GH, Enestvedt BK, Sauer BG, Lennon AM. ACG Clinical Guideline: Diagnosis and Management of Pancreatic Cysts. *The American Journal of Gastroenterology.* 2018;113(4):464-479. doi:10.1038/ajg.2018.14.
3. Tempero MA, Malafa MP, Al-Hawary M, et al. National Comprehensive Cancer Network (NCCN) Guidelines Version 1.2020 – November 26, 2019. Pancreatic adenocarcinoma, available at: https://www.nccn.org/professionals/physician_gls/pdf/pancreatic.pdf. Referenced with permission from the NCCN Clinical Practice Guidelines in Oncology (NCCN Guidelines™) for Pancreatic adenocarcinoma V 1.2020 – November 26, 2019. © 2019 National Comprehensive Cancer Network, Inc. All rights reserved. The NCCN Guidelines™ and illustrations herein may not be reproduced in any form for any purpose without the express written permission of the NCCN. To view the most recent and complete version of the NCCN Guidelines™, go online to NCCN.org.
4. American College of Radiology ACR Appropriateness Criteria® Staging of Pancreatic Ductal Adenocarcinoma. New 2017. <https://acsearch.acr.org/docs/3099847/Narrative/>.

Pancreatic Pseudocysts (AB-32)

Guideline

Pancreatic Pseudocysts (AB-32.1)

Pancreatic Pseudocysts (AB-32.1)

AB.32.1.A
v1.0.2024

See: **Acute Pancreatitis (AB-33.1)** or **Chronic Pancreatitis (AB-33.2)**

Pancreatitis (AB-33)

Guideline

Acute Pancreatitis (AB-33.1)

Chronic Pancreatitis (AB-33.2)

Exocrine Pancreatic Insufficiency (AB-33.3)

Asymptomatic Elevation of Pancreatic Enzymes (AB-33.4)

References (AB-33)

Acute Pancreatitis (AB-33.1)

AB.PX.0033.1.A

v1.0.2024

- Knowledge base:
 - Acute pancreatitis (2 of 3 of the following criteria):
 - Characteristic abdominal pain (typically epigastric or left upper quadrant pain with radiation to the back, chest, or flank)
 - Amylase or lipase >3 times the upper limit of normal
 - Radiographic evidence of pancreatitis on cross-sectional imaging
 - Early Phase takes place in the first week
 - Goals of imaging:¹
 - Establish the correct diagnosis or provide an alternative diagnosis
 - Establish the etiology
 - Stage the morphologic severity
 - Assess for complications in patients who deteriorate or fail to improve
 - Late phase can last weeks to months thereafter
 - Goals of imaging:¹
 - Monitor established pancreatic collections
 - Delineate the presence of symptomatic and asymptomatic complications
 - Guide interventional procedures
 - Etiologies of pancreatitis:
 - Gallstones and alcohol account for 75-80% of all causes¹
 - Hypercalcemia, hypertriglyceridemia, medications, a benign or malignant obstruction, pancreatic mass, genetic causes (hereditary pancreatitis), autoimmune pancreatitis (IgG4), infectious etiologies, ischemia secondary to vascular disease, anatomic abnormalities (e.g., pancreas divisum), physiologic abnormalities (Sphincter of Oddi dysfunction), idiopathic causes.
 - Complications:
 - Early Phase:²
 - Generally manifests as a systemic inflammatory response
 - In the first week, imaging findings correlate poorly with clinical severity¹
 - Advanced imaging is most useful when performed 5-7 days after admission, when local complications have developed and pancreatic necrosis can be clearly defined.
 - IEP = acute interstitial edematous pancreatitis
 - Necrotizing Pancreatitis
 - Late Phase:²
 - APFC (Acute peripancreatic fluid collection) occurs during the first 4 weeks. If it does not resolve within 4 weeks, it can become organized and

- develop into a pseudocyst, which contains only fluid with no nonliquefied components
- Walled-off necrosis (sequelae of necrotizing pancreatitis): inhomogenous nonliquefied components, encapsulated with a wall
- Note: Most cases of pancreatitis are mild. More severe cases are usually hospitalized and imaging performed in that setting is generally not managed by eviCore. The majority of imaging requests are for the initial evaluation of suspected pancreatitis in individuals with epigastric pain, and then the follow-up imaging of discharged individuals with respect to complications experienced during the hospitalization, to further elucidate the etiology of the pancreatitis if this was not previously established, or to evaluate continued post-discharge symptoms.
- The presence of any red flag findings per **General Guidelines (AB-1.0)** precludes adjudication based on any other criteria.
- Imaging:
 - Initial imaging for suspicion of pancreatitis (typical symptoms, <48 to 72 hours, first-time presentation)³
 - Abdominal ultrasound (CPT® 76700 or CPT® 76705)
 - Purpose is to establish the presence/absence of gallstones and biliary ductal dilation.
 - Doppler ultrasound (CPT® 93975) can be approved to assess vasculature, if requested
 - If ultrasound or CT is performed and is nondiagnostic due to technical limitation (obesity, overlying gas, etc.):
 - MRI/MRCP (CPT® 74183 or CPT® 74181)
 - CT Abdomen and Pelvis with contrast (CPT® 74177) or CT Abdomen with contrast (CPT® 74160) if ultrasound is nondiagnostic and MRI/MRCP cannot be performed.
 - In suspected acute biliary pancreatitis and/or cholangitis (dilated ducts or choledocholithiasis on ultrasound, elevated liver chemistries with a negative ultrasound, suspicion of cholangitis (classic triad is RUQ pain, fever, and jaundice))⁴
 - MRI/MRCP (CPT® 74183 or CPT® 74181)
 - Initial imaging with atypical signs and symptoms when diagnoses other than pancreatitis are being considered (e.g., bowel perforation, bowel ischemia):
 - CT Abdomen and Pelvis with contrast (CPT® 74177) or CT Abdomen with contrast (CPT® 74160)
 - MRI/MRCP* (CPT® 74181 or CPT® 74183) can be considered for pregnant patients (non-contrast), or those with renal insufficiency (without or without and with depending on request)
 - Follow-up imaging (late phase and thereafter):
 - Continued or worsening symptoms:

- CT Abdomen and Pelvis with contrast (CPT® 74177), CT Abdomen with contrast (CPT® 74160) or MRI and/or MRCP (CPT® 74183 or CPT® 74181)
- Follow-up of known pancreatic or peri-pancreatic fluid collections (including pseudocysts), to follow-up symptomatic collections, or for interventional planning:
 - MRI/MRCP (CPT® 74183 or CPT® 74181) or CT Abdomen and Pelvis (CPT® 74177)
 - Note: If requested, CT Abdomen with contrast (CPT® 74160) or Abdominal ultrasound (CPT® 76705 or CPT® 76700) can be approved (Note: Frequency or intervals for additional follow-up is not defined and depends on clinical circumstances, response to therapy, etc.)
 - If, despite initial imaging, the etiology of the pancreatitis is still in doubt:
 - MRI/MRCP (CPT® 74183 or CPT® 74181) or CT Abdomen and Pelvis with (CPT® 74177)
 - Note: If requested, CT Abdomen with contrast (CPT® 74160) can be approved.
- Acute recurrent pancreatitis
 - Abdominal ultrasound (CPT® 76705 or CPT® 76700)
 - MRI/MRCP (CPT® 74183 or CPT® 74181)
 - CT Abdomen and Pelvis with contrast (CPT® 74177)
 - See: **Chronic Pancreatitis (AB-33.2)**

Background and Supporting Information

- *NOTE: While MRI/MRCP will give better evaluation of the pancreatic parenchyma as well as biliary and pancreatic ducts, it does NOT provide coverage and adequate evaluation of the bowel to assess alternative diagnoses such as bowel ischemia or perforation.

Chronic Pancreatitis (AB-33.2)

AB.PX.0033.2.A

v1.0.2024

- If chronic pancreatitis is suspected:
 - Initial imaging:
 - CT Abdomen with contrast or without and with contrast (CPT® 74160 or CPT® 74170) or MRI Abdomen without and with contrast (CPT® 74183)
 - If diagnostic criteria are met (pancreatic calcification in combination with pancreatic atrophy and/or dilated pancreatic duct):
 - No further imaging indicated (See below regarding worsening symptoms)
 - If initial CT is inconclusive or nondiagnostic of chronic pancreatitis:
 - MRI/MRCP with secretin enhancement (CPT® 74183 or CPT® 74181)
 - If MRI/MRCP are inconclusive or nondiagnostic of chronic pancreatitis:
 - Endoscopic ultrasound (EUS) is the appropriate next imaging study
 - If EUS is inconclusive, pancreatic function testing and/or ERCP can be performed
 - Note: If abdominal ultrasound is requested at any stage for evaluation of chronic pancreatitis, this can be approved in lieu of advanced imaging
 - If initial imaging fails to confirm chronic pancreatitis, but the clinical suspicion remains, the above testing can be repeated in 6 months.
- Known chronic pancreatitis with worsening symptoms or pain
 - CT Abdomen with or without and with contrast (CPT® 74160 or CPT® 74170), MRI/MRCP (CPT® 74183 or CPT® 74181) or Abdominal ultrasound (CPT® 76700 or CPT® 76705) can be approved
 - Note: Possible etiologies of worsening pain include:
 - Peptic ulcer disease
 - GI cancers
 - Pseudocysts
 - Duodenal or common bile duct obstruction
 - Pancreatic duct stone or strictures
 - Inflammatory masses at the head of the pancreas
- For pre-surgical planning or post-surgical evaluation for treatment of complications of chronic pancreatitis
 - CT Abdomen with or without and with contrast (CPT® 74160 or CPT® 74170), or MRI/MRCP (CPT® 74183 or CPT® 74181) or Abdominal ultrasound (CPT® 76700 or CPT® 76705)
- Routine screening for pancreatic cancer in chronic pancreatitis
 - As noted in the American College of Gastroenterology Clinical Guideline for Chronic Pancreatitis (2020)¹⁴ “There is a lack of evidence to suggest that

performing screening examinations on patients with CP (chronic pancreatitis) to detect malignancy is beneficial....Although the overall prevalence of pancreatic malignancy is increased in patients with CP, there are no RCTs (randomized controlled trials), systematic reviews, or meta-analyses to support screening this patient population for pancreatic malignancy.” As such, the ACG Guideline concludes “At this time there is no definitive benefit to screen patients with CP for pancreatic ductal adenocarcinoma. This is based on the invasive and costly nature of testing, the inherent difficulty in screening given the structural changes of CP, and the inability to alter in many cases the natural history of the disease even if malignancy is detected at an early stage.”

- Therefore, routine surveillance to monitor for the occurrence of pancreatic cancer in individuals with chronic pancreatitis is not supported at this time. For other indications for imaging in chronic pancreatitis, see the above. For pancreatic cancer screening guidelines in inherited syndromes, including hereditary pancreatitis, see: **Screening Studies for Pancreatic Cancer (ONC-13.1)** in the Oncology Imaging Guidelines

Background and Supporting Information

- Clinical signs of chronic pancreatitis include history of alcohol use, abdominal pain, weight loss, steatorrhea, malabsorption, recurrent pancreatitis, fatty food intolerance, low fecal elastase.

Exocrine Pancreatic Insufficiency (AB-33.3)

AB.PX.0033.3.A

v1.0.2024

- The presence of any red flag findings per **General Guidelines (AB-1.0)** precludes adjudication based on any other criteria.
- Pancreatic Insufficiency
 - The initial evaluation for pancreatic insufficiency should include one of the following laboratory results:
 - Elevation in fecal fat
 - Fecal elastase <200 mcg/g
 - Serum trypsinogen <20ng/mL
 - CT Abdomen with (CPT® 74160) or without and with contrast (CPT® 74170) or MRI/MRCP (CPT® 74183 or 74181) for the evaluation of suspected pancreatic insufficiency:
 - For suspected pancreatic insufficiency with any one of the above laboratory findings
 - For suspected pancreatic insufficiency due to known chronic pancreatitis, see: **Chronic Pancreatitis (AB-33.2)**
 - For suspected pancreatic insufficiency due to known cystic fibrosis, see: **(PEDAB-16)** and **(PEDCH-5.1)**
 - For suspected pancreatic cancer, see: **Pancreatic Cancer – Suspected/Diagnosis (ONC-13.2)**

Background and Supporting Information

- Exocrine pancreatic insufficiency (EPI) reflects reduced pancreatic enzymes with resulting maldigestion/malabsorption. When intraduodenal levels of lipase fall below 5-10% of normal output, individuals may manifest with abdominal pain, bloating/cramping, flatulence, and progressive steatorrhea.

Asymptomatic Elevation of Pancreatic Enzymes (AB-33.4)

AB.PX.0033.4.A

v1.0.2024

- If there is the incidental elevation of amylase or lipase:
 - If isolated amylase elevation, prior to imaging, the source of the elevation should be confirmed as pancreatic by the performance of amylase isoenzymes demonstrating that the source is not salivary, or the absence of macroamylase should be ascertained by blood test.
 - If the lipase is elevated alone or in combination with an elevated amylase, or If the amylase is confirmed as pancreatic in origin:
 - Abdominal Ultrasound can be performed initially
 - If US is inconclusive, nondiagnostic, or the elevated pancreatic enzymes persist:
 - MRI/MRCP can be performed (CPT® 74183). Note: It is best performed as a secretin-stimulation test in this setting.
 - Note: CT Abdomen (pancreatic protocol, CPT® 74160) can be performed if there is a contraindication to MRI.
 - If the pancreatic enzyme elevation persists at one year, either of the above studies can be repeated

References (AB-33)

v1.0.2024

1. Imaging Assessment of Etiology and Severity of Acute Pancreatitis. The Pancreapedia: Exocrine Pancreas Knowledge Base. doi:10.3998/panc.2016.31.
2. Foster BR, Jensen KK, Bakis G, Shaaban AM, Coakley FV. Revised Atlanta Classification for Acute Pancreatitis: A Pictorial Essay—Erratum. *RadioGraphics*. 2019;39(3):912-912. doi:10.1148/rg.2019194003.
3. ACR Appropriateness Criteria: Acute Pancreatitis. Rev. 2019.
4. Greenberg JA, Hsu J, Bawazeer M, et al. Clinical practice guideline: management of acute pancreatitis. *Canadian Journal of Surgery*. 2016;59(2):128-140. doi:10.1503/cjs.015015.
5. Testoni PA. Acute recurrent pancreatitis: Etiopathogenesis, diagnosis and treatment. *World Journal of Gastroenterology*. 2014;20(45):16891. doi:10.3748/wjg.v20.i45.16891.
6. Pan G, Wan MH, Xie K-L, et al. Classification and Management of Pancreatic Pseudocysts. *Medicine*. 2015;94(24). doi:10.1097/md.0000000000000960.
7. Oconnor OJ, Buckley JM, Maher MM. Imaging of the Complications of Acute Pancreatitis. *American Journal of Roentgenology*. 2011;197(3). doi:10.2214/ajr.10.4339.
8. Conwell DL, Lee LS, Yadav D, et al. American Pancreatic Association Practice Guidelines in Chronic Pancreatitis. *Pancreas*. 2014;43(8):1143-1162. doi:10.1097/mpa.0000000000000237.
9. Löhr JM, Dominguez-Munoz E, Rosendahl J, et al. United European Gastroenterology evidence-based guidelines for the diagnosis and therapy of chronic pancreatitis (HaPanEU). *United European Gastroenterology Journal*. 2017;5(2):153-199. doi:10.1177/2050640616684695.
10. Forsmark CE. Management of Chronic Pancreatitis. *Gastroenterology*. 2013;144(6). doi:10.1053/j.gastro.2013.02.008.
11. Duggan SN, Chonchubhair HMN, Lawal O, O'Connor DB, Conlon KC. Chronic pancreatitis: A diagnostic dilemma. *World Journal of Gastroenterology*. 2016;22(7):2304-2313. doi:10.3748/wjg.v22.i7.2304.
12. Conwell DL, Wu BU. Chronic Pancreatitis: Making the Diagnosis. *Clinical Gastroenterology and Hepatology*. 2012;10(10):1088-1095. doi:10.1016/j.cgh.2012.05.015.
13. Gardner TB, Adler DG, Forsmark CE, Sauer BG, Taylor JR, Whitcomb DC. ACG Clinical Guideline: Chronic Pancreatitis. *The American Journal of Gastroenterology*. 2020;115(3):322-339. doi:10.14309/ajg.0000000000000535
14. Capurso G, Traini M, Piciucchi M, Signoretti M, Arcidiacono PG. Exocrine pancreatic insufficiency: prevalence, diagnosis, and management. *Clin Exp Gastroenterol*. 2019;12:129-39. doi:10.2147/CEG.S168266.
15. Forsmark CE. Diagnosis and management of exocrine pancreatic insufficiency. *Curr Treat Options Gastroenterol*. 2018;16(3):306-315. doi:10.1007/s11938-018-0186-y.
16. Singh VK, Yadav D, Garg PK. Diagnosis and management of chronic pancreatitis: a review. *JAMA*. 2019;322(4):2422-34. doi:10.1001/jama.2019.19411.
17. Durie P, Baillargeon J-D, Bouchard S, Donnellan F, Zepeda-Gomez S, Teshima C. Diagnosis and management of pancreatic exocrine insufficiency (PEI) in primary care: consensus guidance of a Canadian expert panel. *Curr Med Res Opin*. 2018;34(1):25-33. doi:10.1080/03007995.2017.1389704.
18. Lohr J, Oliver M, Frulloni L. Synopsis of recent guidelines on pancreatic exocrine insufficiency. *United European Gastroenterol J*. 2013;1(2):79-83. doi:10.1177/2050640613476500.
19. Gonoï W, Hayashi TY, Hayashi N, Abe O. Association between chronic asymptomatic pancreatic hyperenzynemia and pancreatic ductal anomalies: a magnetic resonance cholangiopancreatography study. *Abdom Radiol (NY)*. 2019;44(2):2494-2500. doi:10.1007/s00261-019-02004-4.
20. Mariani A. Chronic asymptomatic pancreatic hyperenzynemia: is it a benign anomaly or a disease? *JOP: Journal of the Pancreas*. 2010;11(2):95-8. doi:10.6092/1590-8577/3840.

Spleen (AB-34)

Guideline

Spleen (AB-34.1)

Trauma – Spleen (AB-34.2)

References (AB-34)

Spleen (AB-34.1)

AB.SP.0034.1.A

v1.0.2024

- Incidental splenic findings on US:
 - CT Abdomen (CPT® 74170) or MRI Abdomen (CPT® 74183) can be obtained.
- Incidental splenic findings on CT or MRI:
 - Imaging is diagnostic of a benign lesion (simple cyst, hemangioma) or characteristics are benign-appearing (homogeneous, low attenuation, no enhancement, smooth margins):
 - No follow-up imaging.
 - Imaging characteristics are not diagnostic:
 - Prior imaging available:
 - One year stability: no follow up imaging
 - Lack of stability: consider MRI if not done, biopsy, or PET/CT (CPT® 78815).
 - No prior imaging:
 - No known malignancy:
 - Suspicious imaging features: (suggesting possible malignancy)
 - MRI Abdomen (CPT® 74183) if not already done or biopsy
 - If MRI still inconclusive and biopsy is not feasible then PET/CT (CPT® 78815) can be considered
 - Indeterminate imaging features: (equivocal but not suspicious for malignancy)
 - Follow up MRI Abdomen (CPT® 74183) in 6 and 12 months.
 - Known malignancy:
 - <1 cm: follow up MRI Abdomen (CPT® 74183) in 6 and 12 months.
 - ≥1 cm: consider MRI Abdomen (CPT® 74183) if not done, biopsy
 - If MRI still inconclusive and biopsy is not feasible then PET/CT (CPT® 78815) can be considered
 - (See diagnosis-specific in the **Oncology Imaging Guidelines**).
 - Clinically detected splenomegaly
 - Abdominal US (CPT® 76700 or CPT® 76705) should be the first imaging study to evaluate splenic size.
 - If splenomegaly is confirmed, the following evaluation is indicated prior to advanced imaging:
 - CBC, evaluation of the peripheral blood smear, LFTs, UA, chest x-ray, HIV testing.

- CT Abdomen without and with contrast or with (CPT® 74170 or CPT® 74160) can be performed if the etiology of the splenomegaly remains unexplained.
- MRI Abdomen (CPT® 74183) can be considered for pregnant patients, or individuals with iodinated contrast allergy.
- Nuclear medicine imaging of the liver/spleen (CPT® 78201, CPT® 78202, CPT® 78803, CPT® 78215, CPT® 78216, or CPT® 78830) is rarely performed, but can be considered if CT and MRI are contraindicated, as well as for evaluation of an accessory spleen.

Background and Supporting Information

Our current guidelines are consistent with ACR recommendations for the follow-up of incidental splenic masses. It is noteworthy, however, that a recent study from Beth Israel Deaconess Medical Center in which the authors retrospectively reviewed 379 patients who were found to have an incidental splenic mass on CT found that in patients without a history of malignancy, constitutional symptoms of fever or weight loss, or left upper quadrant or epigastric pain (205/379) there were 2 incidences of malignancy. However, in both of these cases the splenic masses were neither isolated nor indeterminate findings as the CTs demonstrated disease in other locations. An isolated splenic malignancy (which can occur but is very rare) was found only in 2 patients and both of these had constitutional symptoms. Thus, the authors claim that “the isolated and incidentally found splenic mass is of unlikely clinical significance, regardless of its appearance”, They concluded that “in patients with an incidental splenic mass identified at imaging and with the absence of a history of malignancy, fever, weight loss, or pain in the left upper quadrant or epigastrium, such masses are highly likely to be benign regardless of their appearance. Additional imaging or follow-up is not warranted, even if the mass does not show the appearance of simple cyst. Further work-up is only needed if the splenic mass is seen in conjunction with other findings worrisome for malignancy”. These authors challenge the use of the ACR guidelines.

Trauma – Spleen (AB-34.2)

AB.SP.0034.2.A

v1.0.2024

- Ultrasound Abdomen (CPT® 76700 or CPT® 76705) and Pelvis (CPT® 76856 or CPT® 76857) or CT^{3,4,5} Abdomen and Pelvis without and with contrast (CPT® 74178) or with contrast (CPT® 74177) for ANY of the following:
 - Blunt abdominal trauma with suspected splenic rupture, or
 - Suspected post-procedural injury, or
 - Individuals with penetrating trauma to the left upper quadrant. See: **Blunt Abdominal Trauma (AB-10)**

Background and Supporting Information

Splenomegaly is usually the result of systemic disease, and diagnostic studies are directed toward identifying the causative disease. Complete blood count with differential, LFT's, and peripheral blood smear examination are often performed prior to considering advanced imaging. There is no evidence-based data to support performing serial CT or MRI to follow individuals with incidental splenic lesions.

References (AB-34)

v1.0.2024

1. Heller M et. al. Managing Incidental Findings on Abdominal and Pelvic CT and MRI, Part 3. Journal of the American College of Radiology, Vol. 10, Issue 11, Pages 833-839, Nov. 2013.
2. Thut D et. al. A diagnostic approach to splenic lesions. Appl. Radiology 2017; 46 (2): 7-22(B)
3. Saboo SS, Krajewski KM, O'Regan KN, et al. Spleen in haematological malignancies: spectrum of imaging findings. *British Journal of Radiology*. 2012;85:81-92 2012.
4. Benter T, Klühs L, Teichgräber U. Sonography of the spleen. *J Ultrasound Med*. 2011;30:1281-93.
5. Killeen KL, Shanmuganathan K, Boyd-Kranis R, et al. CT findings after embolization for blunt splenic trauma. *J Vasc Interv Radiol*. Feb 2001;12(2):209-14.
6. Naulet P, Wassel J, Gervaise A, et al. Evaluation of the value of abdominopelvic acquisition without contrast injection when performing a whole body CT scan in a patient who may have multiple trauma. *Diagn Interv Imaging*. 2013;94(4):410-7.
7. Boscak AR, Shanmuganathan K, Mirvis SE, et al. Optimizing trauma multidetector CT protocol for blunt splenic injury: need for arterial and portal venous phase scans. *Radiology*. 2013;268(1):79-88.
8. Royal HD, Brown ML, Drum DE. Society of Nuclear Medicine Procedure guideline for hepatic and splenic imaging 3.0, version 3.0, approved July 20, 2003.
9. Siewert B, Millo NZ, Sahi K, et al. The Incidental Splenic Mass at CT: Does It Need Further Work-up? An Observational Study. *Radiology*. 2018;287(1):156-166. doi:10.1148/radiol.2017170293.

Indeterminate Renal Lesion (AB-35)

Guideline

Indeterminate Renal Lesion – General Information (AB-35.0)

Indeterminate Renal Lesion (AB-35.1)

Pre-operative Assessment (AB-35.2)

References (AB-35)

Indeterminate Renal Lesion – General Information (AB-35.0)

AB.RL.0035.0.A

v1.0.2024

For acute flank pain, rule out renal stone, see: [Flank Pain, Rule Out or Known Renal/Ureteral Stone \(AB-4\)](#)

Indeterminate Renal Lesion (AB-35.1)

RL.AB.0035.1.A
v1.0.2024

- Incidental Renal Mass on Ultrasound
 - If categorized as simple cyst or Bosniak I or II, no further imaging
 - Otherwise, CT Abdomen without and with contrast (CPT® 74170), MRI Abdomen without and with contrast (CPT® 74183), or Contrast-Enhanced Ultrasound (CPT® 76978 for one lesion, and CPT® 76979 if there are additional lesions).
- CT Abdomen without and with contrast (CPT® 74170) or MRI Abdomen without and with contrast (CPT® 74183) can be approved for further characterization if the original study reveals incomplete visualization of a renal lesion (for example, if only partially visualized on a CT Chest).
- Incidental Renal Mass on Non-Contrast CT
 - If characterized as heterogeneous (thick or irregular wall, mural nodule, septa or calcification):
 - Considered indeterminate. MRI Abdomen without and with contrast (CPT® 74183) or CT Abdomen without and with contrast (CPT® 74170)
 - If characterized as homogeneous (thin or imperceptible wall, NO mural nodule, septa or calcification):
 - 10 to 20 HU (Hounsfield units)
 - Likely benign, not fully characterized: no further work-up
 - 21 to 69 HU
 - Indeterminate: MRI or CT Abdomen without and with contrast (CPT® 74183 or CPT® 74170)
 - ≥70 HU
 - Hemorrhagic or proteinaceous cyst, unlikely to be neoplastic: no further work-up
 - If characterized as TSTC (too small to characterize) and homogeneous:
 - If labelled likely benign cyst, not fully characterized:
 - No further work-up
 - If labelled inconclusive based on subjective evaluation:
 - Considered indeterminate. MRI Abdomen without and with contrast (CPT® 74183) (preferred) or CT Abdomen without and with contrast (CPT® 74170) within 6-12 months
- Incidental Renal Mass on Contrast-Enhanced CT
 - If characterized as heterogeneous: thick or irregular wall, mural nodule, septa or calcification:
 - Considered indeterminate. MRI Abdomen without and with contrast (CPT® 74183) or CT Abdomen without and with contrast (CPT® 74170)

- If characterized as homogeneous: thin or imperceptible wall, NO mural nodule, septa or calcification:
 - 10 to 20 HU
 - No further work-up
 - >20 HU (solid or complicated cystic mass)
 - Considered indeterminate. MRI Abdomen without and with contrast (CPT® 74183) or CT Abdomen without and with contrast (CPT® 74170)
- If characterized as TSTC, homogeneous:
 - If labelled likely benign cyst, not fully characterized:
 - No further work-up
 - If labelled inconclusive based on subjective evaluation:
 - Considered indeterminate. MRI Abdomen without and with contrast (CPT® 74183) (preferred), or CT Abdomen without and with contrast (CPT® 74170) within 6-12 months
- Incidental cystic renal mass on CT or MRI without and with contrast (completely characterized, and does NOT contain fat)
 - Bosniak I (benign simple) or II (minimally complicated)
 - No further work-up
 - Bosniak IIF
 - CT Abdomen without and with contrast (CPT® 74170) or MRI Abdomen without and with contrast (CPT® 74183) at 6 and 12 months, then yearly for 5 years
 - If no changes for 5 years, cyst is considered benign and of no clinical significance
 - Bosniak III or IV should be referred for additional management or if chosen, active surveillance see: **Surveillance (ONC-17.4)** in the Oncology Imaging Guidelines
- Incidental solid renal mass or incidental mass too small to characterize evaluated on CT or MRI without and with contrast and does NOT contain fat
 - TSTC
 - If labelled likely benign cyst:
 - No further work-up
 - If labelled inconclusive based on subjective evaluation:
 - MRI Abdomen without and with contrast (CPT® 74183) (preferred), or CT Abdomen without and with contrast (CPT® 74170) within 6 months
 - If solid mass <1.0cm
 - MRI Abdomen without and with contrast (CPT® 74183) (preferred), or CT Abdomen without and with contrast (CPT® 74170) beginning at 6-12 months, then yearly for 5 years
 - If stable at 5 years (average growth ≤3mm per year): No further work-up

- If mass shows growth (≥ 4 mm per year) or morphologic change: refer for management, consider renal biopsy. If biopsy is technically challenging or relatively contraindicated, a T2 weighted image MRI Abdomen without and with contrast (CPT[®] 74183) can be performed
- Solid mass 1.0-4.0cm:
 - Considered a small renal neoplasm: refer for management, consider biopsy. If biopsy is technically challenging or relatively contraindicated, a T2 weighted imaging MRI Abdomen without and with contrast (CPT[®] 74183) can be performed. If active surveillance chosen due to limited life expectancy or co-morbidities, see: **Surveillance (ONC-17.4)** in the Oncology Imaging Guidelines
- Solid renal mass >4.0 cm
 - Considered a renal neoplasm: refer for management, or biopsy. If biopsy is technically challenging or relatively contraindicated, a T2 weighted image MRI Abdomen without and with contrast (CPT[®] 74183) can be performed. If active surveillance chosen due to limited life expectancy or co-morbidities, see: **Surveillance (ONC-17.4)** in the Oncology Imaging Guidelines
- Incidental renal mass containing fat (contains a region of interest measuring <-10 HU on CT)
 - No calcification angiomyolipoma (AML)
 - Solitary and without documentation of growth:
 - <4 cm: no further work-up
 - If no prior imaging study for comparison, one follow-up MRI Abdomen (CPT[®] 74183) or CT Abdomen (CPT[®] 74170) can be repeated in 6-12 months to assess for any growth.
 - ≥ 4 cm, and considered an AML with potential for clinical symptoms: refer for management.
 - Multiple lesions or growth documented based on old studies:
 - Refer for management. If active surveillance chosen due to limited life expectancy or co-morbidities, see: **Surveillance (ONC-17.4)** in the Oncology Imaging Guidelines.
 - With calcification (suspected renal cell carcinoma):
 - CT Abdomen without and with contrast (CPT[®] 74170) or MRI Abdomen without and with contrast (CPT[®] 74183) if only a non-contrast CT has been performed. If active surveillance chosen due to limited life expectancy or co-morbidities, see: **Surveillance (ONC-17.4)** in the Oncology Imaging Guidelines.
- Active Surveillance: For all Active Surveillance indications, see: **Surveillance (ONC-17.4)** in the Oncology Imaging Guidelines

NOTE: PET/CT or PET/MRI are not recommended because their role evaluating the incidental renal mass is limited.¹

Bosniak Classification:

I- Benign simple cyst with a hairline thin wall without septa, calcification, or solid component. Homogeneous near-water attenuation density (10 to 20 HU) without enhancement.

II- Benign minimally complicated cyst that may contain a few hairline thin septa that may have “perceived” but not measurable enhancement. Fine calcification or a segment of slightly thickened calcification may be present in the wall or septa. Also, a well-marginated nonenhancing homogeneous mass <3cm with density above simple fluid attenuation (hyperdense cyst).

IIF- Usually benign complicated renal cyst with multiple hairline thin septa or minimal smooth thickening of the wall or septa. Wall or septa may contain thick and nodular calcification and may have “perceived” but not measurable enhancement. Also, a well-marginated intrarenal nonenhancing mass >3cm with density above simple fluid.

III -Indeterminate complicated cystic renal mass with thickened irregular walls or septa that have measurable enhancement.

IV-Malignant cystic renal mass with enhancing soft tissue components (cystic renal cell carcinoma).

From the Journal of the American College of Radiology¹

Pre-operative Assessment (AB-35.2)

RL.AB.0035.2.A

v1.0.2024

- Pre-operative assessment for robotic kidney surgery
 - If not previously performed:
 - CT Abdomen without and with contrast (CPT® 74170) OR
 - MRI Abdomen without and with contrast (CPT® 74183)
 - CTA Abdomen (CPT® 74175) or CTA Abdomen and Pelvis (CPT® 74174) OR
 - MRA Abdomen (CPT® 74185), or MRA Abdomen and Pelvis (CPT® 74185 and CPT® 72198)

References (AB-35)

v1.0.2024

1. Herts BR, Silverman SG, Hindman NM, et al. Management of the Incidental Renal Mass on CT: A White Paper of the ACR Incidental Findings Committee. *Journal of the American College of Radiology*. 2018;15(2):264-273. doi:10.1016/j.jacr.2017.04.028.
2. Finelli A, Ismaila N, Russo P. Management of Small Renal Masses: American Society of Clinical Oncology Clinical Practice Guideline Summary. *Journal of Oncology Practice*. 2017;13(4):276-278. doi:10.1200/jop.2016.019620.
3. Campbell S, Uzzo RG, Allaf ME, et al. Renal Mass and Localized Renal Cancer: AUA Guideline. *The Journal of Urology*. 2017;198(3):520-529. doi:10.1016/j.juro.2017.04.100.
4. Zhao PT, Richstone L, Kavoussi LR. Laparoscopic partial nephrectomy. *International Journal of Surgery*. 2016;36:548-553. doi:10.1016/j.ijssu.2016.04.028.
5. Lane BR, Campbell SC, Gill IS. 10-Year Oncologic Outcomes After Laparoscopic and Open Partial Nephrectomy. *Journal of Urology*. 2013;190(1):44-49. doi:10.1016/j.juro.2012.12.102.
6. Barr RG, Peterson C, Hindi A. Evaluation of Indeterminate Renal Masses with Contrast-enhanced US: A Diagnostic Performance Study. *Radiology*. 2014;271(1):133-142. doi:10.1148/radiol.13130161.
7. Nicolau C, Buñesch L, Paño B, et al. Prospective evaluation of CT indeterminate renal masses using US and contrast-enhanced ultrasound. *Abdominal Imaging*. 2014;40(3):542-551. doi:10.1007/s00261-014-0237-3.
8. Zarzour JG, Lockhart ME, West J, et al. Contrast-Enhanced Ultrasound Classification of Previously Indeterminate Renal Lesions. *Journal of Ultrasound in Medicine*. 2017;36(9):1819-1827. doi:10.1002/jum.14208.

Renal Failure (AB-36)

Guideline

Renal Failure (AB-36.1)

References (AB-36)

Renal Failure (AB-36.1)

AB.RF.0036.1.A

v1.0.2024

- Ultrasound kidney and bladder (CPT® 76770 or CPT® 76775), preferably with Doppler (CPT® 93975 or CPT® 93976), is the preferred imaging study for the evaluation of acute or chronic renal failure¹.
- MRA Abdomen (CPT® 74185) can be utilized when there is suspected¹:
 - Renal vein/caval thrombosis
 - Renal artery stenosis as cause of renal failure
 - MRA with contrast may be contraindicated in severe renal failure or patients on dialysis due to the risk of gadolinium agents in causing nephrogenic systemic sclerosis.
- CT Abdomen without contrast (CPT® 74150) is not needed except to rule out ureteral obstruction or retroperitoneal mass.¹
- Nuclear renal imaging (CPT® 78701, CPT® 78707, CPT® 78708, CPT® 78709) can be considered for ANY of the following:^{3,4}
 - Renal transplant follow-up
 - Kidney salvage vs. nephrectomy surgical decisions
 - Acute renal failure with no evidence of obstruction on recent ultrasound.
 - Chronic renal failure to estimate prognosis for recovery.
- Nuclear medicine studies of the kidney (CPT® 78700 or CPT® 78701) can be considered for evaluation of the following anatomic renal anomalies:³
 - Suspected horseshoe kidney
 - Suspected solitary or ectopic kidney

References (AB-36)

v1.0.2024

1. Papnicolaou N, Francis IR, Casalino DD, Arellano RS, et al. Expert Panel on Urologic Imaging. ACR Appropriateness Criteria® renal failure. American College of Radiology (ACR); 2008.
2. National Kidney Foundation. KDOQI Clinical Practice Guidelines for Chronic Kidney Disease: Evaluation, Classification, and Stratification. 2012. *Am J Kidney Disease*, 2002;39(2 Supp 1):S1-S266.
3. Kim C, Becker M, Grant F, et al., ACR–SPR Practice Guideline for the Performance of Renal Scintigraphy. Revised 2017. The American College of Radiology.
4. Expert Panel on Urologic Imaging. American College of Radiology Appropriateness Criteria – Renal Failure.

Renovascular Hypertension (AB-37)

Guideline

Renovascular Hypertension (AB-37.1)

Renovascular Hypertension (AB-37.1)

AB.37.1.A

v1.0.2024

- See: **Renovascular Hypertension/Renal Artery Stenosis (PVD-6.6)** in the Peripheral Vascular Disease Imaging Guidelines

Polycystic Kidney Disease (AB-38)

Guideline

Polycystic Kidney Disease (AB-38.1)

References (AB-38)

Polycystic Kidney Disease (AB-38.1)

AB.PK.0038.1.A

v1.0.2024

- Retroperitoneal ultrasound¹ (CPT[®] 76770 or CPT[®] 76775) can be performed for:
 - Suspected polycystic kidney disease
 - Screening individuals at risk for autosomal dominant polycystic disease (ADPKD)
 - In the absence of any clinical change, follow-up screening is not indicated if a screening ultrasound was performed at age 40 or later and was negative for any cysts (The negative predictive value of an ultrasound in this age group is 100% for both PKD1 and PKD2, if no cysts are identified.).
 - If an initial ultrasound is negative for any cysts, a follow-up ultrasound can be performed at the discretion of the ordering provider for individuals <40 years of age.
- MRI Abdomen without contrast (CPT[®] 74181) can be performed:
 - If a cystic renal lesion is detected in an individual at-risk of PKD, for prognostic purposes
 - For volume averaging (Total Kidney Volume – TKV) prior to treatment for PKD (Jynarque, tolvaptan)
 - Optimal follow-up imaging intervals in this setting have not yet been established. Requests for follow-up imaging can be considered on a case-by-case basis.

Background and Supporting Information

- Ultrasound is very effective in establishing a diagnosis of ADPKD, though may miss early small cysts. However, the negative predictive value in the various age groups of a negative ultrasound is as follows:
 - ≥40: 100% for PKD1 and PKD2
 - 30-39: 100% for PKD1 and 96.8% for PKD2
 - 5-29: 99.1% for PKD1 and 83.5% for PKD2
- In addition, the preferable advanced imaging study is MRI Abdomen without contrast (CPT[®] 74181). This is because of the increased risk of gadolinium-induced nephrogenic fibrosis in individuals with PKD.

References (AB-38)

v1.0.2024

1. Chapman AB, Devuyst O, Eckardt K-U, et al. Autosomal-dominant polycystic kidney disease (ADPKD): executive summary from a Kidney Disease: Improving Global Outcomes (KDIGO) Controversies Conference. *Kidney International*. 2015;88(1):17-27. doi:10.1038/ki.2015.59.
2. Belibi FA, Edelstein CL. Unified Ultrasonographic Diagnostic Criteria for Polycystic Kidney Disease. *Journal of the American Society of Nephrology*. 2008;20(1):6-8. doi:10.1681/asn.2008111164.
3. Chebib FT, Torres VE. Autosomal Dominant Polycystic Kidney Disease: Core Curriculum 2016. *American Journal of Kidney Diseases*. 2016;67(5):792-810. doi:10.1053/j.ajkd.2015.07.037.
4. Gastel MDAV, Messchendorp AL, Kappert P, et al. T1 vs. T2 weighted magnetic resonance imaging to assess total kidney volume in patients with autosomal dominant polycystic kidney disease. *Abdominal Radiology*. 2017;43(5):1215-1222. doi:10.1007/s00261-017-1285-2.
5. Alam A, Dahl NK, Lipschutz JH, et al. Total Kidney Volume in Autosomal Dominant Polycystic Kidney Disease: A Biomarker of Disease Progression and Therapeutic Efficacy. *American Journal of Kidney Diseases*. 2015;66(4):564-576. doi:10.1053/j.ajkd.2015.01.030.

Hematuria and Hydronephrosis (AB-39)

Guideline

Hematuria with Urinary Tract Infection (UTI) (AB-39.1)

Asymptomatic Hematuria (AB-39.2)

Hematuria and Flank Pain (Suspicion for Renal/ureteral Stones) (AB-39.3)

Hydronephrosis of Unexplained or Indeterminate Cause (AB-39.4)

References (AB-39)

Hematuria with Urinary Tract Infection (UTI) (AB-39.1)

AB.HH.0039.1.A

v1.0.2024

- Individuals suspected to have a UTI as the etiology of microscopic hematuria should be treated for the UTI and should then undergo repeat urinalysis to confirm resolution of the hematuria. If the hematuria persists following treatment, proceed with the risk-based evaluation as per **Asymptomatic Hematuria (AB-39.2)**.
- Also see: **Urinary Tract Infection (UTI) (AB-40)** for additional imaging considerations

Background and Supporting Information

- Signs and symptoms of UTI: urinary frequency, burning on urination, urgency, dysuria, positive urine leukocyte esterase, presence of WBCs in the urine, fever, elevated WBC as per the testing laboratory's range

Asymptomatic Hematuria (AB-39.2)

AB.HH.0039.2.A

v1.0.2024

- Microscopic hematuria is defined as ≥ 3 red blood cells per high power field. Hematuria is NOT defined as a positive dipstick. A positive dipstick should prompt a microscopic examination. A positive dipstick is not considered as defining microhematuria.
- Prior to imaging, individuals should be stratified into low, intermediate, or high risk, based on the following criteria⁷
 - Low risk (individual meets ALL criteria listed)
 - Women <50 years of age or Men <40 years of age
 - Never smoker or <10 pack years
 - 3-10 RBC/HPF on a single urinalysis
 - No additional risk factors for urothelial cancer:
 - Irritative lower urinary tract symptoms
 - Prior pelvic radiation therapy
 - Prior cyclophosphamide/ifosfamide chemotherapy
 - Family history of urothelial cancer or Lynch Syndrome
 - Occupational exposures to benzene chemicals or aromatic amines (e.g. rubber, petrochemicals, dyes)
 - Chronic indwelling foreign body in the urinary tract
 - Intermediate risk (individual meets any one of these criteria)
 - Women age 50-59 years, Men age 40-59 years
 - 10-30 pack years of smoking
 - 11-25 RBC/HPF on a single urinalysis
 - Low-risk individual with no prior evaluation and 3-10 RBC/HPF on repeat urinalysis
 - Any one of the Additional risk factors for urothelial cancer (see above)
 - High-risk (individual meets any one of these criteria)
 - Women or Men ≥ 60 years
 - >30 pack-years of smoking
 - >25 RBC/HPF on a single urinalysis
 - History of gross hematuria
- Low- or intermediate-risk individuals:
 - Renal ultrasound (combined with cystoscopy)
 - Note: Low-risk individuals may opt for observation with repeat urinalysis within 6 months. If no imaging was performed initially, and follow-up urinalysis reveals persistent hematuria with 3-10 RBC/HPF the individual may be imaged according to Intermediate-Risk criteria. If >10 RBC/HPF, they should be imaged according to High-risk guidelines.

- High-risk individuals
 - CT Urogram (CPT® 74178) (3D imaging is appropriate if requested)
 - If CT is contraindicated, MR Urography may be performed (CPT® 74183 and 72197)
 - If both CT and MR are contraindicated due to contrast, non-contrast CT urography or renal ultrasound should be performed. See also:
Pregnancy Considerations for Imaging (AB-1.12).
- Persistent microscopic hematuria if previously evaluated by renal ultrasound
 - Imaging as per High-risk individuals above
- Hematuria in individuals with inherited risk factors for renal cortical tumors
 - Renal ultrasound or
 - CT Abdomen without and with contrast (CPT® 74170) or
 - MRI Abdomen without and with contrast (CPT® 74183)
 - Note: Inherited risk factors include:
 - Von-Hippel-Lindau
 - Birt-Hogg-Dube
 - Hereditary Papillary RCC
 - Hereditary Leiomyomatosis Renal Cell Cancer
 - Tuberous Sclerosis
- Follow-up
 - Individuals with a negative hematuria evaluation who undergo repeat urinalysis
 - If repeat urinalysis is negative:
 - No further workup
 - If repeat urinalysis demonstrates persistent hematuria
 - Repeat imaging as requested (Renal Ultrasound or CT urography)
- NOTE: 3-D Reconstruction enhances a CT Urogram. Requests for 3-D reconstruction (CPT® 76377 or 76376) for a CT Urogram can be approved.

Hematuria and Flank Pain (Suspicion for Renal/ureteral Stones) (AB-39.3)

AB.HH.0039.3.A

v1.0.2024

- CT Abdomen and Pelvis without contrast (CPT® 74176) or CT Urogram (CPT® 74178)
- NOTE:
 - 3-D Reconstruction enhances a CT Urogram. Requests for 3-D reconstruction (CPT® 76377 or CPT® 76376) for a CT Urogram can be approved.
 - US abdomen or retroperitoneum can be performed in lieu of a CT for any of the above indications

Hydronephrosis of Unexplained or Indeterminate Cause^{3, 4} (AB-39.4)

AB.HH.0039.4.A

v1.0.2024

- CT Urogram (CPT® 74178)
- NOTE:
 - 3-D Reconstruction enhances a CT Urogram. Requests for 3-D reconstruction (CPT® 76377 or CPT® 76376) for a CT Urogram can be approved.
 - US abdomen or retroperitoneum can be performed in lieu of a CT for any of the above indications
- Patients with known uncomplicated hydronephrosis, neurogenic bladder, myelomeningocele (open spinal dysraphism), or spina bifida can have follow-up/surveillance imaging with Retroperitoneal Ultrasound (CPT® 76770) every 6 to 12 months

References (AB-39)

v1.0.2024

1. Ramchandani P, Kisler T, Francis IR, Casalino DD, et al. Expert Panel on Urologic Imaging. ACR Appropriateness Criteria® hematuria. American College of Radiology (ACR); 2014.
2. Cohen RA, Brown RS. Microscopic hematuria. *New England Journal of Medicine*, 2003; 348:2330-2338.
3. Kolbeck K, Ray C Jr, Lorenz J, et al. Expert Panel on Interventional Radiology. ACR Appropriateness Criteria® radiologic management of urinary tract obstruction. American College of Radiology (ACR); 2013.
4. Expert Panel on Urologic Imaging. ACR Appropriateness Criteria® acute onset flank pain - suspicion of stone disease (urolithiasis). American College of Radiology (ACR), 2015:11.
5. Raman SP, Horton KM, Fishman EK. MDCT Evaluation of Ureteral Tumors: Advantages of 3D Reconstruction and Volume Visualization. *American Journal of Roentgenology*. 2013;201(6):1239-1247. doi:10.2214/ajr.13.10880.
6. Coplen D. Diagnosis, Evaluation and Follow-Up of Asymptomatic Microhematuria (AMH) in Adults: AUA Guideline. *Yearbook of Urology*. 2013;2013:1-2. Reviewed and Validity Confirmed 2016 doi:10.1016/j.yuro.2013.07.019.
7. Georgieva MV, Wheeler SB, Erim D, et al. Comparison of the Harms, Advantages, and Costs Associated With Alternative Guidelines for the Evaluation of Hematuria. *JAMA Internal Medicine*. 2019;179(10):1352. doi:10.1001/jamainternmed.2019.2280.
8. Barocas D, Boorjian S, Alvarez R, et. al. Microhematuria: AUA/SUFU guideline. *J Urol*. 2020;204:778.

Urinary Tract Infection (UTI) (AB-40)

Guideline

Urinary Tract Infection (AB-40.0)

Upper (Pyelonephritis) (AB-40.1)

Lower (AB-40.2)

References (AB-40)

Urinary Tract Infection (AB-40.0)

AB.UT.0040.0.A
v1.0.2024

These guidelines refer to UTI without Hematuria.

For UTI with Hematuria, see: **Hematuria and Hydronephrosis (AB-39)**

Upper (Pyelonephritis) (AB-40.1)

AB.UT.0040.1.A

v1.0.2024

- CT Abdomen and Pelvis without and with contrast (CPT® 74178) or CT Abdomen and Pelvis with contrast (CPT® 74177) if¹:
 - Suspected complicated: diabetes, immune-compromised, history of stones, prior renal surgery, or fever ≥ 101 F (≥ 38.5 C).
 - Not responding to therapy after 3 days.
 - Recurrent pyelonephritis (at least 1 prior pyelonephritis).
 - Males with first time UTI, or recurrent UTI without etiology.
- MRI Abdomen without or with and without contrast (CPT® 74181 or CPT® 74183)
 - Elevated creatinine
- Pregnant women should be evaluated initially by renal ultrasound² (CPT® 76770 or CPT® 76775) and if further imaging is necessary, MRI Abdomen and Pelvis³ without contrast (CPT® 74181 and CPT® 72195).

Lower (AB-40.2)

AB.UT.0040.2.A

v1.0.2024

- CT Abdomen and Pelvis without and with contrast (CPT® 74178) if³:
 - Suspected complicated: diabetes or immunocompromised or history of stones or prior renal surgery, or fever ≥ 101 F (≥ 38.5 C).
 - Not responding to therapy after 3 days.
 - Males with first time UTI or recurrent UTI without etiology.
 - Recurrent UTI ≥ 3 per year.
 - Recommendation by or in consultation with a urologist or specialist.
- MRI Abdomen and MRI Pelvis without or with and without contrast (CPT® 74181 and CPT® 72195 or CPT® 74183 and CPT® 72197) can be approved if requested when ALL of the following apply:
 - Criteria (as above) for CT Abdomen and Pelvis without and with contrast are met and
 - Elevated creatinine
- See: **Periurethral Cysts and Urethral Diverticula (PV-13)** in the Pelvis Imaging Guidelines

References (AB-40)

v1.0.2024

1. Expert Panel on Urologic Imaging. ACR Appropriateness Criteria® acute pyelonephritis. American College of Radiology (ACR); 2012.
2. Delzell JE, Lefevre ML. Urinary tract infections during pregnancy. *American Family Physician*, 2000;61(3):713-720.
3. Lazarus E, Casalino DD, Remer EM, Arellano RS, et al. Expert Panel on Urologic Imaging. ACR Appropriateness Criteria® recurrent lower urinary tract infection in women. American College of Radiology (ACR); 2014.
4. Davis R, Jones JS, Barocas DA, et al. Diagnosis, Evaluation and Follow-Up of Asymptomatic Microhematuria (AMH) in Adults: AUA Guideline. *Journal of Urology*. 2012;188(6s):2473-2481. doi:10.1016/j.juro.2012.09.078.
5. Silverman SG, Leyendecker JR, Amis ES. What Is the Current Role of CT Urography and MR Urography in the Evaluation of the Urinary Tract? *Radiology*. 2009;250(2):309-323. doi:10.1148/radiol.2502080534.
6. Hooton TM. Uncomplicated Urinary Tract Infection. *New England Journal of Medicine*. 2012;366(11):1028-1037. doi:10.1056/nejmcp1104429.
7. Suskind AM, Saigal CS, Hanley JM, Lai J, Setodji CM, Clemens JQ. Incidence and Management of Uncomplicated Recurrent Urinary Tract Infections in a National Sample of Women in the United States. *Urology*. 2016;90:50-55. doi:10.1016/j.urology.2015.11.051.
8. Gupta K, Hooton TM, Naber KG, et al. International Clinical Practice Guidelines for the Treatment of Acute Uncomplicated Cystitis and Pyelonephritis in Women: A 2010 Update by the Infectious Diseases Society of America and the European Society for Microbiology and Infectious Diseases. *Clinical Infectious Diseases*. 2011;52(5). doi:10.1093/cid/ciq257.
9. Anger J, Lee U, Ackerman AL, et al. Recurrent Uncomplicated Urinary Tract Infections in Women: AUA/CUA/SUFU Guideline. *Journal of Urology*. 2019;202(2):282-289. doi:10.1097/ju.000000000000296.

Patent Urachus (AB-41)

Guideline

Patent Urachus (AB-41.1)

Patent Urachus (AB-41.1)

AB.41.1.A
v1.0.2024

See: **Patent Urachus (PV-23.1)** in the Pelvis Imaging Guidelines

Transplant (AB-42)

Guideline

Liver Transplant, Pre-Transplant (AB-42.1)

Liver Transplant, Living Donor Pre-Transplant Imaging (Donor Imaging) (AB-42.2)

Liver Transplant, Post-Transplant Imaging (AB-42.3)

Post-Transplant Lymphoproliferative Disorder (PTLD) (AB-42.4)

Kidney Transplant, Pre-Transplant Imaging Studies (AB-42.5)

Kidney Transplant, Post-Transplant (AB-42.6)

Heart Transplant (AB-42.7)

References (AB-42)

Liver Transplant, Pre-Transplant (AB-42.1)

AB.TX.0042.1.A

v1.0.2024

- Individuals **WITHOUT hepatocellular carcinoma (HCC)** referred to a transplant center for liver transplant evaluation can undergo advanced imaging as follows:
 - Per the transplant institution's protocol, OR
 - Per the studies and intervals listed below:

Imaging Study	Interval	Comments
Both of the following US studies: <ul style="list-style-type: none"> • Abdominal US (CPT® 76700 or CPT® 76705) and • Doppler (CPT® 93975) 	<ul style="list-style-type: none"> • Every 6 months 	
ONE of the following abdomen/pelvis advanced imaging studies: <ul style="list-style-type: none"> • CT Abdomen (CPT® 74160 or CPT® 74170) • MRI Abdomen (CPT® 74183) 	<ul style="list-style-type: none"> • Annually <ul style="list-style-type: none"> • Individuals with known cholangiocarcinoma may have more frequent repeat of studies at left per institution's protocol 	
Additional abdomen/pelvis advanced imaging, for individuals on the transplant list with known Primary Sclerosing Cholangitis (PSC): <ul style="list-style-type: none"> • MRCP (See: MRCP (AB-27.1) for acceptable CPT® codes) 	<ul style="list-style-type: none"> • Per the transplant institution's protocol 	

Imaging Study	Interval	Comments
<ul style="list-style-type: none"> CT Chest with or without contrast (CPT® 71260 or CPT® 71250) 	<ul style="list-style-type: none"> One-time <ul style="list-style-type: none"> Individuals with known cholangiocarcinoma may have more frequent repeat of studies at left per institution's protocol 	<ul style="list-style-type: none"> Repeat studies based on clinical indications per <u>Chest Imaging Guidelines</u>
<p>ONE of the following:</p> <ul style="list-style-type: none"> MRI Bone Marrow Blood Supply (CPT® 77084) or Bone scan (CPT® 78306) 	<ul style="list-style-type: none"> One-time 	
<p>Echocardiography with ONE of the following:</p> <ul style="list-style-type: none"> CPT® 93306 (preferred) CPT® 93307 CPT® 93308 	<ul style="list-style-type: none"> Annually 	<p>See: <u>CD-2.1</u>, <u>CD-2.2</u> for descriptions of CPTs or further indications</p>
<p>CT Coronary angiography (CCTA) (CPT® 75574)</p>	<ul style="list-style-type: none"> Annually 	<p>See: <u>CD-4.1</u>, <u>CD-4.3</u>, <u>CD-4.4</u> for descriptions of CPTs or further indications</p>
<p>Stress imaging in place of but not in addition to CT Coronary angiography (CCTA) - ONE of the following:</p> <ul style="list-style-type: none"> CPT® 93350 CPT® 93351 CPT® 78452 CPT® 75563 CPT® 78492 CPT® 78431 	<ul style="list-style-type: none"> Annually 	<p>See: <u>CD-1.6</u>, <u>CD-2.6</u>, <u>CD-3.1</u>, <u>CD-5.1</u>, <u>CD-6.1</u>, <u>CD-6.2</u> for descriptions of CPTs or further indications</p>

Imaging Study	Interval	Comments
<p>For individuals with systemic amyloidosis:</p> <ul style="list-style-type: none"> • Cardiac MRI – ONE of the following: <ul style="list-style-type: none"> • CPT® 75557 • CPT® 75561 • If Cardiac MRI is contraindicated or indeterminate, ONE of the following SPECT studies may be performed: <ul style="list-style-type: none"> • CPT® 78803 • CPT® 78830 	<ul style="list-style-type: none"> • One-time 	<p>See: <u>CD-5.1</u>, <u>CD-5.2</u>, <u>CD-3.7</u>, <u>CD-3.8</u> for descriptions of CPTs or further indications</p>
<p>If required to further assess CAD seen on a recent CCTA that is of uncertain physiologic significance, CT-FFR (Noninvasive estimated coronary fractional flow reserve derived from coronary computed tomography angiography) with ONE of the following:</p> <ul style="list-style-type: none"> • CPT® 0501T • One or more of the following: CPT® 0502T, 0503T, or 0504T 	<ul style="list-style-type: none"> • One-time 	<p>See: <u>CD-4.1</u>, <u>CD-4.5</u> for descriptions of CPTs or further indications</p>

Imaging Study	Interval	Comments
<p>In place of CT Coronary angiography or stress imaging for initial pre-transplant evaluation, OR If CT Coronary angiography and/or CT-FFR or stress imaging is abnormal WITH addition of right heart catheterization if requested for evaluation of pulmonary hypertension:</p> <ul style="list-style-type: none"> • Left heart catheterization or left and right heart catheterization with ONE of the following: <ul style="list-style-type: none"> • CPT® 93458 • CPT® 93454 • CPT® 93460 • CPT® 93456 • Or if prior CABG, with ONE of the following: <ul style="list-style-type: none"> • CPT® 93459 • CPT® 93455 • CPT® 93461 • CPT® 93457 	<ul style="list-style-type: none"> • One-time 	<p>Repeat studies as per CD-7.1, CD-7.3.5, CD-7.4.2, CD-7.5 for descriptions of CPTs or further indications</p>
<p>ONE of the following, for vascular evaluation in anticipation of transplant:</p> <ul style="list-style-type: none"> • CTA (CPT® 74175) • MRA Abdomen (CPT® 74185) 	<ul style="list-style-type: none"> • One-time 	

Imaging Study	Interval	Comments
<p>ANY of the following may be performed immediately prior to transplant:</p> <ul style="list-style-type: none"> Abdominal US (CPT® 76700 or CPT® 76705) AND Doppler (CPT® 93975) CT Abdomen (CPT® 74160 or CPT® 74170) OR MRI Abdomen (CPT® 74183) CT Abdomen and Pelvis (CPT® 74177) or CT Pelvis (CPT® 72193) CTA (CPT® 74175) OR MRA Abdomen (CPT® 74185) 	<ul style="list-style-type: none"> Once, immediately prior to transplant 	

- Individuals **WITH hepatocellular carcinoma (HCC)** referred to a transplant center for liver transplant evaluation can undergo advanced imaging as follows:
 - Per the transplant institution's protocol, OR
 - Per the studies and intervals listed below:

Imaging Study	Interval	Comments
<p>Both of the following US studies:</p> <ul style="list-style-type: none"> Abdominal US (CPT® 76700 or CPT® 76705) and Doppler (CPT® 93975) 	<ul style="list-style-type: none"> Every 6 months 	
<p>ONE of the following abdomen/pelvis advanced imaging studies:</p> <ul style="list-style-type: none"> CT Abdomen (CPT® 74160 or CPT® 74170) MRI Abdomen (CPT® 74183) 	<ul style="list-style-type: none"> Every 3 months <ul style="list-style-type: none"> Can be approved at interval as requested according to the transplant center's protocol for waitlisted individuals under active locoregional therapy to control tumor growth (i.e., tumor ablation) 	

Imaging Study	Interval	Comments
<ul style="list-style-type: none"> CT Chest with contrast (CPT® 71260) 	<ul style="list-style-type: none"> Every 6 months <ul style="list-style-type: none"> Can be approved at interval as requested according to the transplant center’s protocol for waitlisted individuals under active locoregional therapy to control tumor growth (i.e., tumor ablation) 	
<ul style="list-style-type: none"> Bone Scan (CPT® 78306) 	<ul style="list-style-type: none"> Every 6 months 	
Echocardiography with ONE of the following: <ul style="list-style-type: none"> CPT® 93306 (preferred) CPT® 93307 CPT® 93308 	<ul style="list-style-type: none"> Annually 	See: CD-2.1 , CD-2.2 for descriptions of CPTs or further indications
CT Coronary angiography (CCTA) (CPT® 75574)	<ul style="list-style-type: none"> Once in 3 years 	See: CD-4.1 , CD-4.3 , CD-4.4 for descriptions of CPTs or further indications
Stress imaging in place of but not in addition to CT Coronary angiography (CCTA) - ONE of the following: <ul style="list-style-type: none"> CPT® 93350 CPT® 93351 CPT® 78452 CPT® 75563 CPT® 78492 CPT® 78431 	<ul style="list-style-type: none"> Annually 	See: CD-1.6 , CD-2.6 , CD-3.1 , CD-5.1 , CD-6.1 , CD-6.2 for descriptions of CPTs or further indications

Imaging Study	Interval	Comments
<p>For individuals with systemic amyloidosis:</p> <ul style="list-style-type: none"> • Cardiac MRI – ONE of the following: <ul style="list-style-type: none"> • CPT® 75557 • CPT® 75561 • If Cardiac MRI is contraindicated or indeterminate, ONE of the following SPECT studies may be performed: <ul style="list-style-type: none"> • CPT® 78803 • CPT® 78830 	<ul style="list-style-type: none"> • One-time 	<p>See: <u>CD-5.1</u>, <u>CD-5.2</u>, <u>CD-3.7</u>, <u>CD-3.8</u> for descriptions of CPTs or further indications</p>
<p>If required to further assess CAD seen on a recent CCTA that is of uncertain physiologic significance, CT-FFR (Noninvasive estimated coronary fractional flow reserve derived from coronary computed tomography angiography) with ONE of the following:</p> <ul style="list-style-type: none"> • CPT® 0501T • One or more of the following: CPT® 0502T, 0503T, or 0504T 	<ul style="list-style-type: none"> • One-time 	<p>See: <u>CD-4.1</u>, <u>CD-4.5</u> for descriptions of CPTs or further indications</p>

Imaging Study	Interval	Comments
<p>In place of CT Coronary angiography or stress imaging for initial pre-transplant evaluation, OR If CT Coronary angiography and/or CT-FFR or stress imaging is abnormal WITH addition of right heart catheterization if requested for evaluation of pulmonary hypertension:</p> <ul style="list-style-type: none"> • Left heart catheterization or left and right heart catheterization with ONE of the following: <ul style="list-style-type: none"> • CPT® 93458 • CPT® 93454 • CPT® 93460 • CPT® 93456 • Or if prior CABG, with ONE of the following: <ul style="list-style-type: none"> • CPT® 93459 • CPT® 93455 • CPT® 93461 • CPT® 93457 	<ul style="list-style-type: none"> • One-time 	<p>Repeat studies as per <u>CD-7.1</u>, <u>CD-7.3.5</u>, <u>CD-7.4.2</u>, <u>CD-7.5</u></p>

Imaging Study	Interval	Comments
<p>ANY of the following may be performed immediately prior to transplant:</p> <ul style="list-style-type: none">• Abdominal US (CPT® 76700 or CPT® 76705) AND Doppler (CPT® 93975)• CT Abdomen (CPT® 74160 or CPT® 74170) OR MRI Abdomen (CPT® 74183)• CT Abdomen and Pelvis (CPT® 74177) or CT Pelvis (CPT® 72193)• CTA (CPT® 74175) OR MRA Abdomen (CPT® 74185)• MRI Bone Marrow Blood Supply (CPT® 77084)	<ul style="list-style-type: none">• Once, immediately prior to transplant	

Liver Transplant, Living Donor Pre-Transplant Imaging (Donor Imaging) (AB-42.2)

AB.TX.0042.2.A

v1.0.2024

- CT Abdomen or MRI Abdomen (CPT® 74160, or CPT® 74170, or CPT® 74183) to assess liver anatomy and volumetrics.
- MRCP to assess biliary anatomy (See: **MRCP (AB-27.1)** for proper coding)
- CTA or MRA Abdomen (CPT® 74175 or CPT® 74185) to assess vascular anatomy

Liver Transplant, Post-Transplant Imaging (AB-42.3)

AB.TX.0042.3.A

v1.0.2024

- Cardiac Imaging:
 - See: **Transplant Patients (CD-1.6)** in the Cardiac Imaging Guidelines
- Suspected post-operative complications:
 - Vascular thrombosis (suspected hepatic artery thrombosis)
 - Doppler ultrasound (CPT® 93975)
 - CTA or MRA Abdomen (CPT® 74175 or CPT® 74185)
 - Suspicion of biliary anastomotic strictures:
 - MRCP (See: **MRCP (AB-27.1)** for appropriate CPT codes)
 - Vascular imaging as above for vascular thrombosis may also be requested and approved for this indication
 - Other suspected post-operative complications (e.g., infection, etc.)
 - Imaging as requested by the transplant institution or team
- Transplant individuals without prior HCC or cholangiocarcinoma:
 - Routine post-transplant imaging is not indicated.
 - If cirrhosis develops post-transplant:
 - See: **Cirrhosis and Liver Screening for Hepatocellular Carcinoma (HCC) (AB-26.1)**, **Ascites (AB-26.2)**, and **Portal Hypertension (AB-26.3)** for HCC screening guidelines.
 - Fibrosis assessment post-liver transplant:
 - Transient elastography (CPT® 91200), which is the most studied modality in this setting.
- Surveillance after transplant for HCC:
 - Based on RETREAT score
 - 0 points: No additional screening needed
 - 1-3 points: CT or MRI Abdomen (CPT® 74160, or CPT® 74170, or CPT® 74183) and CT Chest (CPT® 71260 or CPT® 71250) every 6 months for 2 years.
 - 4 points: CT or MRI Abdomen (CPT® 74160, or CPT® 74170, or CPT® 74183) and CT Chest (CPT® 71260 or CPT® 71250) every 6 months for 5 years
 - ≥5 points: CT or MRI Abdomen (CPT® 74160, or CPT® 74170, or CPT® 74183) and CT Chest (CPT® 71260 or CPT® 71250) every 3 months for 2 years, then every 6 months between the 2nd and 5th years.
- If there is a suspicion of recurrent tumor based on clinical findings and/or sequentially increasing AFP:

- CT Abdomen (CPT® 74160 or CPT® 74170) or MRI Abdomen (CPT® 74183)
- Imaging after transplant for primary sclerosing cholangitis (PSC):
 - Suspected recurrence of PSC;
 - MRCP (See: **MRCP (AB-27.1)** for proper coding)
- Imaging after transplant for cholangiocarcinoma:
 - Liver ultrasound (CPT® 76705 or CPT® 76700) or MRI Abdomen and MRCP (CPT® 74183) every 6 months for 5 years post-transplantation.
 - CT Chest (CPT® 71250 or CPT® 71260) every 6 months for 5 years post-transplantation

Background and Supporting Information

Consensus guidelines regarding post-transplant surveillance imaging have not yet been established. There have been recent attempts to establish evidence-based guidelines, including the development of the RETREAT score, validated recently in a study conducted at University of California, San Francisco, Mayo Clinic-Rochester, and Mayo Clinic-Jacksonville. This scoring system has been adopted for use by UCSF and guides post-transplant imaging for individuals who have undergone transplant for HCC.

The RETREAT score is a protocol used to estimate the risk of tumor recurrence after liver transplantation in patients who have been transplanted for the treatment of hepatocellular carcinoma. It is comprised of three factors which are assessed before and after transplant. Points are assigned based on criteria which include the alpha-fetoprotein level before liver transplantation, the presence or absence of microvascular invasion, and the sum of the diameter of the largest viable tumor and the number of viable nodules on pathologic examination of the explant liver. The RETREAT score is calculated as follows:

Risk Factor	Score
Alpha-fetoprotein level before LT	
0-20	0
21-99	1
100-999	2
≥1000	3
Microvascular invasion present	2
Sum of the diameter of the largest viable tumor and the number of viable nodules	
0	0

Risk Factor	Score
1.1-4.9	1
5.0-9.9	2
≥10	3

Post-Transplant Lymphoproliferative Disorder (PTLD) (AB-42.4)

AB.TX.0042.4.A

v1.0.2024

- CT Chest/Abdomen/Pelvis with contrast (CPT® 71260 and CPT® 74177) for known or suspected PTLD.
- Additional evaluation of suspected PTLD is the same as the evaluation of lymphoma. See: **Diffuse Large B Cell Lymphoma (DLBCL) (ONC-27.2)** in the Oncology Imaging Guidelines for further recommendations
- There is insufficient evidence to support the routine use of imaging to screen for PTLD.

Background and Supporting Information

- Post-transplant lymphoproliferative disease (PTLD) is a major complication of solid organ transplantation and the spectrum ranges from benign hyperplasia to malignant lymphoma. It has an incidence of 1-20%, and is usually related to Epstein-Barr virus infection in the setting of immunosuppression.

Kidney Transplant, Pre-Transplant Imaging Studies (AB-42.5)

AB.TX.0042.5.A

v1.0.2024

Pre-Transplant Evaluation (Per Institution Protocol)

- Individuals referred to a transplant center for kidney or kidney-pancreas transplant evaluation can undergo advanced imaging as follows:
 - Per the transplant institution's protocol, OR
 - Per the studies and intervals listed below:

Imaging Study	Interval	Comments
ONE of the following abdomen/pelvis imaging studies: <ul style="list-style-type: none"> • CT Abdomen and Pelvis without contrast (CPT® 74176) • CT Abdomen and Pelvis with contrast (CPT® 74177) • CTA Abdomen (CPT® 74175) • CTA Abdomen and Pelvis (CPT® 74174) • CTA Pelvis (CPT® 72191) 	One-time	
ONE of the following echocardiography studies: <ul style="list-style-type: none"> • CPT® 93306 (preferred) • CPT® 93307 • CPT® 93308 	Annual	See also: <u>Transthoracic Echocardiography (TTE) - Indications/initial evaluation (CD-2.2)</u> for descriptions of CPTs or further indications

Imaging Study	Interval	Comments
<p>ONE of the following stress imaging studies:</p> <ul style="list-style-type: none"> • CPT® 93350 • CPT® 93351 • CPT® 78452 • CPT® 75563 • CPT® 78492 • CPT® 78431 	<p>Annual</p>	<p>See also: <u>Transplant (CD-1.6), Stress Echocardiography (Stress Echo) (CD-2.7), Myocardial Perfusion Imaging (MPI) - Coding (CD-3.1), Cardiac MRI - Coding (CD-5.1), Cardiac PET - Coding (CD-6.1), Cardiac PET - Perfusion - Indications (CD-6.2)</u> for descriptions of CPTs or further indications</p>

Additional Pre-Transplant Evaluation (Per Indication)

Individuals referred to a transplant center for kidney or kidney-pancreas transplant evaluation can undergo the following additional advanced imaging when the listed indications are met:

Indication	Imaging Study	Interval	Comments
<ul style="list-style-type: none"> 20 pack-year history of smoking 	ONE of the following: <ul style="list-style-type: none"> CT Chest without contrast (CPT® 71250) CT Chest with contrast (CPT® 71260) 	One-time	For lung cancer screening with Low Dose Computed Tomography (LDCT), see: <u>U.S. Preventative Services Task Force: Lung Cancer Screening (Commercial and Medicaid) (CH-33.1)</u> or <u>National Coverage Determination (NCD) for Lung Cancer Screening with Low Dose Computed Tomography (LDCT) (210.14) (CH-33.2)</u> for Low-Dose CT Chest without contrast
<ul style="list-style-type: none"> Autosomal dominant polycystic kidney disease 	ONE of the following: <ul style="list-style-type: none"> MRA Head (CPT® 70544, 70545, or 70546) CTA Head (CPT® 70496) 	One-time	Repeat imaging as per <u>Intracranial Aneurysms (HD-12.1)</u>
<ul style="list-style-type: none"> History of stroke, or History of TIA, or Carotid bruit on exam 	ONE of the following: <ul style="list-style-type: none"> Carotid duplex bilateral study (CPT® 93880 or CPT® 73882) 	One-time	Repeat imaging as per <u>Initial Imaging (PVD-3.1)</u>

Indication	Imaging Study	Interval	Comments
<ul style="list-style-type: none"> Presence of systemic amyloidosis 	ONE of the following cardiac MRI studies: <ul style="list-style-type: none"> CPT® 75557 CPT® 75561 	One-time	See also: <u>Cardiac MRI - Coding (CD-5.1)</u> , <u>Cardiac MRI - Indications (excluding Stress MRI) (CD-5.2)</u> for descriptions of CPTs or further indications
BOTH of the following: <ul style="list-style-type: none"> Presence of systemic amyloidosis AND Cardiac MRI is either contraindicated or indeterminate 	ONE of the following nuclear medicine studies: <ul style="list-style-type: none"> CPT® 78803 CPT® 78830 	One-time	See also: <u>Myocardial Tc-99m Pyrophosphate Imaging (CD-3.7)</u> , <u>Cardiac Amyloidosis (CD-3.8)</u> or descriptions of CPTs or further indications
<ul style="list-style-type: none"> In place of stress imaging for initial pre-transplant evaluation, or Stress imaging is positive for ischemia 	ONE of the following heart catheterization: <ul style="list-style-type: none"> CPT® 93458 CPT® 93454 If prior CABG: <ul style="list-style-type: none"> CPT® 93459 CPT® 93455 	One-time	Repeat imaging as per <u>Diagnostic Heart Catheterization - Code Sets (CD-7.1)</u> and <u>Evaluation of structural heart disease (CD-7.3.5)</u>

Kidney Donor Nephrectomy or Pre-Transplant Nephrectomy

Indication	Imaging Study	Comments
<ul style="list-style-type: none"> Individuals being evaluated for living kidney donation, or Individual is planning removal of one or both kidneys 	ONE of the following: <ul style="list-style-type: none"> CTA Abdomen (CPT® 74175) MRA Abdomen (CPT® 74185) MRI Abdomen without and with contrast (CPT® 74183) 	For CTA and MRA, 3D rendering is included with the original study

Kidney Transplant, Post-Transplant (AB-42.6)

AB.TX.0042.6.A

v1.0.2024

- Ultrasound of transplanted kidney:
 - Current ultrasound imaging protocols of the transplanted kidney commonly include a Doppler study and are coded as CPT® 76776.
 - Do not report non-invasive vascular codes CPT® 93975 and CPT® 93976 in conjunction with CPT® 76776.
 - Ultrasound of the transplanted kidney performed without duplex Doppler should be reported as a limited retroperitoneal ultrasound (CPT® 76775).

Heart Transplant (AB-42.7)

AB.TX.0042.7.A

v1.0.2024

- See: **Transplant Patients (CD-1.6)** in the Cardiac Imaging Guidelines

References (AB-42)

v1.0.2024

1. Carruso S, Miraglia R, et al. Imaging in liver transplantation. *World Journal of Gastroenterology*. 2009;15(6):675-683.
2. Pomfret E, Washburn K, Wald C, et al. Report of a national conference on liver allocation in patients with hepatocellular carcinoma in the United States. *Liver Transplant*. 2010;16(3):262-78.
3. Sahani D, Mehta A, Blake M, et al. Preoperative hepatic vascular evaluation with CT and MR angiography: implications for surgery. *RadioGraphics*. 2004;24:1367-1380. 2017.
4. Cincinnati Children's Hospital Medical Center. Evidence based clinical practice guideline for management of EBV-associated post-transplant lymphoproliferative disease (PTLD) in solid organ transplant.
5. Liu, D. et al. Evidence-Based Surveillance Imaging Schedule After Liver Transplantation for Hepatocellular Carcinoma Recurrence. *Transplantation* 2017. Jan;101(1): 107-111
6. Lucey, Michael, et al. Long-Term Management of the Successful Adult Liver Transplant: 2012 Practice Guideline by AASLD and the American Society of Transplantation.
7. Mehta N, Heimbach J, Harnois DM, et al. Validation of a Risk Estimation of Tumor Recurrence After Transplant (RETREAT) Score for Hepatocellular Carcinoma Recurrence After Liver Transplant. *JAMA Oncology*. 2017;3(4):493. doi:10.1001/jamaoncol.2016.5116.
8. Filgueira NA. Hepatocellular carcinoma recurrence after liver transplantation: Risk factors, screening and clinical presentation. *World Journal of Hepatology*. 2019;11(3):261-272. doi:10.4254/wjh.v11.i3.261.
9. Xu M, Doyle MM, Banan B, et al. Neoadjuvant Locoregional Therapy and Recurrent Hepatocellular Carcinoma after Liver Transplantation. *Journal of the American College of Surgeons*. 2017;225(1):28-40. doi:10.1016/j.jamcollsurg.2017.03.015.
10. Cai L, Yeh BM, Westphalen AC, Roberts JP, Wang ZJ. Adult living donor liver imaging. *Diagnostic and Interventional Radiology*. 2016;22(3):207-214. doi:10.5152/dir.2016.15323.
11. Liu D, Chan ACY, Fong DYT, Lo C-M, Khong P-L. Evidence-Based Surveillance Imaging Schedule After Liver Transplantation for Hepatocellular Carcinoma Recurrence. *Transplantation*. 2017;101(1):107-111. doi:10.1097/tp.0000000000001513.
12. Bajer L, Slavcev A, Macinga P, et al. Risk of recurrence of primary sclerosing cholangitis after liver transplantation is associated with de novo inflammatory bowel disease. *World Journal of Gastroenterology*. 2018;24(43):4939-4949. doi:10.3748/wjg.v24.i43.4939.
13. Ligeti K, Müller LP, Müller-Tidow C, Weber T. Risk factors, diagnosis, and management of posttransplant lymphoproliferative disorder: improving patient outcomes with a multidisciplinary treatment approach. *Transplant Research and Risk Management*. 2017;Volume 9:1-14. doi:10.2147/trrm.s84744.
14. Aghayev A, Gupta S, Dabiri BE, Steigner ML. Vascular imaging in renal donors. *Cardiovascular Diagnosis and Therapy*. 2019;9(S1). doi:10.21037/cdt.2018.11.02.
15. Sawinski D, Locke JE. Evaluation of Kidney Donors: Core Curriculum 2018. *American Journal of Kidney Diseases*. 2018;71(5):737-747. doi:10.1053/j.ajkd.2017.10.018.
16. Kidney Disease: Improving Global Outcomes (KDIGO) Kidney Transplant Candidate Work Group. KDIGO Clinical Practice Guideline on the Evaluation and Management of Candidates for Kidney Transplantation. *Transplantation*. 2020;104: S1 – S103.
17. Cheng XS, VanWagner LB, Costa SP, et al. Emerging evidence on coronary heart disease screening in kidney and liver transplantation candidates: a scientific statement from the American Heart Association. *Circulation*. 2022;146:e299–e324. doi.org/10.1161/CIR.0000000000001104.
18. Kumamaru KK, Kondo T, Kumamaru H, et al. Repeat coronary computed tomographic angiography in patients with a prior scan excluding significant stenosis. *Circ Cardiovasc Imaging*. 2014;7:788-795. doi.org/10.1161/CIRCIMAGING.113.001549.
19. VanWagner LB, Harinstein ME, Runo JR, et al. Multidisciplinary approach to cardiac and pulmonary vascular disease risk assessment in liver transplantation: An evaluation of the evidence and consensus recommendations. *Am J Transplant*. 2018;18:30–42. doi.org/10.1111/ajt.14531.
20. Löffler AI, Gonzalez JA, Sundararaman SK, et al. Coronary computed tomography angiography demonstrates a high burden of coronary artery disease despite low-risk nuclear studies in pre-liver transplant evaluation. *Liver Transplantation*. 2020; 26(11):1398–1408. doi.org/10.1002/lt.25869.

Hepatic and Abdominal Arteries (AB-43)

Guideline

Hepatic Arteries and Veins (AB-43.1)

Abdominal Veins Other than Hepatic and Portal Veins (AB-43.2)

Renal Vein Thrombosis (AB-43.3)

References (AB-43)

Hepatic Arteries and Veins (AB-43.1)

AB.HA.0043.1.A

v1.0.2024

- Portal Vein Thrombosis (PVT):
 - Doppler US (CPT® 93975) is the initial noninvasive modality for the diagnosis of Portal Vein Thrombosis
 - CT Abdomen with contrast (CPT® 74160 or 74170 – 4 phase CT), MRI Abdomen without and with contrast (CPT® 74183) or CTA Abdomen (CPT® 74175)
 - To assess the extension of thrombus into the mesenteric veins when Doppler US (or other imaging, such as abdominal US) is positive for PVT
 - To exclude tumor thrombus among individuals with cirrhosis who develop new portal and/or mesenteric vein thrombosis
 - For continued concern for PVT (for example in an individual with a hypercoagulable state or abdominal malignancy) if Doppler US is negative or inconclusive
 - To assess for development of intestinal ischemia among individuals with known portal and/or mesenteric vein thrombosis (MVT) (e.g., development of fever, rebound, leukocytosis, elevated serum lactate levels):
 - In lieu of the above imaging modalities, if requested: CT Abdomen and Pelvis with contrast (CPT® 74177)
 - For suspicion of portal hypertensive or portal cavernoma cholangiopathy in individuals with known PVT or MVT (cholestatic liver chemistry profile (See **Abnormal Liver Chemistries (AB-30.1)**), known portal cavernoma, extrahepatic biliary abnormalities on imaging):
 - MRCP (CPT® 74183 or CPT® 74181)

(Note: Portosystemic collaterals in the region surrounding the common bile duct in individuals with chronic PVT can be associated with common bile duct obstruction.)

- For routine follow-up of PVT:
 - US/Doppler every 6 months. If these are reported as not providing adequate visualization, CT Abdomen (CPT® 74160), MRI Abdomen (CPT® 74183), or CTA Abdomen (CPT® 74175), can be performed.
- For follow-up of PVT being treated with anticoagulation:
 - US/Doppler, CT Abdomen (CPT® 74160), MRI Abdomen (CPT® 74183), or CTA Abdomen (CPT® 74175) in 3-6 months.
 - Further follow-up every 6 months with US/Doppler unless these are reported as not providing adequate visualization, in which case any of the above studies can be approved.
- TIPS (transjugular intrahepatic portosystemic shunt)
 - Pre-procedure evaluation:

- Abdominal US, including Doppler (CPT® 76700 and/or CPT® 93975), Multiphase CT Abdomen (CPT® 74160 or CPT® 74170), Multiphase CTA Abdomen (CPT® 74175), Multiphase MRA Abdomen (CPT® 74185), or MRI Abdomen liver protocol (CPT® 74183)
- Echocardiogram (CPT® 93306) (see: **Transthoracic Echocardiography (TTE) – Indications/Initial Evaluation (CD-2.2)**)
- For routine follow-up to monitor stent patency:
 - US with Doppler (CPT® 93975) 7-14 days after shunt creation, and then at 3 months, 6 months, and then every 6 months thereafter.
 - Note: If requested earlier than the above intervals because of a clinical deterioration or suspicion of stent occlusion, the Doppler can be approved.
- If Doppler imaging is indeterminate or if there is a negative Doppler with clinical signs of worsening portal hypertension:
 - Multiphase CT Abdomen (CPT® 74160 or CPT® 74170), Multiphase CTA Abdomen (CPT® 74175), Multiphase MRA Abdomen (CPT® 74185), or MRI Abdomen liver protocol (CPT® 74183)
- Echocardiogram (CPT® 93306) is indicated for the following:
 - One time post-procedure for routine follow up
 - Any time post-procedure:
 - For new signs or symptoms
 - For concern for new or worsening pulmonary hypertension
 - See also: **Frequency of Echocardiography Testing (CD-2.3)** in the Cardiac Imaging Guidelines
- Budd-Chiari Syndrome
 - Primary Budd-Chiari Syndrome (BCS) is due to thrombotic obstruction of the hepatic venous outflow tract, and Secondary BCS is caused by malignant tumors or extrinsic compression of the hepatic vein. Guidelines refer to Primary BCS.
 - LI-RADS assessment should not be applied to individuals <18 years old or those with cirrhosis from congenital hepatic fibrosis or secondary to vascular disorders (e.g., Budd-Chiari syndrome, chronic portal vein occlusion, cardiac congestion, hereditary hemorrhagic telangiectasia).
 - Doppler US (CPT® 93975) is the initial diagnostic test for the evaluation of BCS.
 - CT Abdomen with contrast (CPT® 74160), or MRI Abdomen without and with contrast (CPT® 74183) or CTA Abdomen (CPT® 74175)
 - To assess thrombus extension
 - Rule out tumor thrombus
 - Assess response to anticoagulation therapy
 - If there is high suspicion of BCS despite a negative or inconclusive Doppler US

- To additionally assess indeterminate hepatic nodules detected on the prior US (any of the above studies or CT Abdomen without and with contrast CPT® 74170)
- For pre-operative evaluation of anticipated interventional vascular therapies or TIPS:
 - Abdominal US, including Doppler (CPT® 76700 and/or CPT® 93975), Multiphase CT Abdomen (CPT® 74160 or CPT® 74170), Multiphase CTA Abdomen (CPT® 74175), Multiphase MRA Abdomen (CPT® 74185), or MRI Abdomen liver protocol (CPT® 74183)
- For HCC Surveillance in patients with chronic BCS:
 - Abdominal US (CPT® 76700 or CPT® 76705) and serum alpha-fetoprotein every 6 months
 - Triphasic CT Abdomen (CPT® 74160 or CPT® 74170), or MRI Abdomen (CPT® 74183) for the evaluation of hepatic nodules seen on US or AFP ≥15 ng/ml.
 - The LiRADS reporting system does not apply to HCC surveillance in this population, due to the vascular origin of many of the hepatic imaging abnormalities.
- Hereditary Hemorrhagic Telangiectasia (HHT)
 - Note: The liver may be involved in individuals with HHT, and artery-to-vein or vein-to-vein shunting may occur resulting in liver vascular malformations (LVMs).
 - Screening the liver for LVMs is not indicated. As per recent ACG Guidelines⁶ “There is no evidence to suggest that making a diagnosis in an asymptomatic patient has clinical benefits or prevents death”.
 - For symptoms suggestive of LVMs (including an audible bruit or palpable thrill over the hepatic region on physical examination, abnormal liver tests) or for the development of signs or symptoms of heart failure, biliary ischemia, hepatic encephalopathy, mesenteric ischemia, or portal hypertension:
 - CT Abdomen (CPT® 74160), CTA Abdomen (CPT® 74175), MRI Abdomen with and without (CPT® 74183), MRCP (CPT® 74183), or MRA Abdomen (CPT® 74185)
- CTA Abdomen and Pelvis (CPT® 74174), or CTA Abdomen (CPT® 74175) or MRA Abdomen (CPT® 74185) additional indications:
 - Evaluation of portal and hepatic veins prior to or following surgical intervention for the treatment of portal hypertension (See: **Portal Hypertension (AB-26.3)**)
 - Evaluation of hepatic vasculature prior to and following embolization procedure (See: **Hepatocellular Carcinoma (HCC) – Restaging/Recurrence (ONC-14.4)** and **Hepatocellular Carcinoma (HCC) – Surveillance/Follow-up (ONC-14.5)** and **Liver Metastases (ONC-31.2)** in the Oncology Imaging Guideline)
 - Evaluation of hepatic vasculature prior to planned hepatectomy (See: **Liver Transplant, Pre-Transplant (AB-42.1)**)

- Evaluation of liver donor (See: Liver Transplant, **Living Donor Pre-Transplant Imaging (Donor Imaging) (AB-42.2)** for specific guidance)
- Hepatic arterial aneurysms:
 - See: **Visceral Artery Aneurysm (PVD-6.5)** in the Peripheral Vascular Disease Imaging Guidelines

Background and Supporting Information

Primary Budd-Chiari Syndrome is due to thrombotic occlusion of the hepatic venous outflow tract. Most individuals have an underlying prothrombotic condition such as a myeloproliferative disease, an inherited thrombophilia (e.g. Factor V Leiden), a systemic disease such as vasculitis, or hormonal factors, such as recent oral contraceptive use. Secondary Budd-Chiari Syndrome is caused by malignant tumors or extrinsic compression of the hepatic veins.

Abdominal Veins Other than Hepatic and Portal Veins (AB-43.2)

AB.HA.0043.2.A

v1.0.2024

- CTA Abdomen and Pelvis (CPT® 74174), or CTA Abdomen (CPT® 74175) or MRA Abdomen (CPT® 74185) if ONE of the following:
 - Nephrotic syndrome
 - Renal vein thrombosis
 - Mesenteric vein thrombosis
- Suspicion of iliac vein thrombus when a lower extremity duplex or abdominal duplex is inconclusive or equivocal, see: **Acute Deep Venous Thrombosis (DVT) (PVD 12.2)**
- Suspicion of inferior vena cava thrombus when a lower extremity duplex or abdominal duplex is inconclusive or equivocal, see: **Acute Deep Venous Thrombosis (DVT) (PVD 12.2)**

Renal Vein Thrombosis (AB-43.3)

AB.HA.0043.3.A
v1.0.2024

- MRA Abdomen (CPT® 74185) if ONE of the following:
 - Nephrotic syndrome
 - Proteinuria – 3 grams or more in 24 hours
 - Lupus nephritis
 - Hypercoagulable state, ONE of the following:
 - Antiphospholipid antibodies
 - Behçet's syndrome
 - Protein C deficiency
 - Protein S deficiency

References (AB-43)

v1.0.2024

1. American College of Radiology (ACR), North American Society for Cardiovascular Imaging (NASCI), Society for Pediatric Radiology (SPR). ACR-NASCI-SPR practice guideline for the performance of pediatric and adult body magnetic resonance angiography (MRA). *Am Coll Radiol*. Revised 2015.
2. Nghiem HV, Winter TC III, Mountford MC, et al. Evaluation of the portal venous system before liver transplantation: value of phase-contrast MR angiography. *AJR*. 1995;164:871-878.
3. American Association for the Study of Liver Disease (AASLD). AASLD practice guidelines: the role of transjugular intrahepatic portosystemic shunt (TIPS) in the management of portal hypertension. *Hepatology*. 2010;51:1-16.
4. Lee SS, Kim TK, Byun JH, et al. Hepatic arteries in potential donors for living related liver transplantation: evaluation with multi-detector row CT angiography. *Radiology*. 2003; 227:391-399.
5. Simonetto DA, Singal AK, Garcia-Tsao G, Caldwell SH, Ahn J, Kamath PS. ACG Clinical Guideline. *The American Journal of Gastroenterology*. 2020;115(1):18-40. doi:10.14309/ajg.0000000000000486.
6. Boyer TD, Haskal ZJ. The role of transjugular intrahepatic portosystemic shunt (TIPS) in the management of portal hypertension: Update 2009. *Hepatology*. 2009;51(1):306-306. doi:10.1002/hep.23383.
7. Kapoor B, Sands M, Copelan A. Transjugular Intrahepatic Portosystemic Shunt: Indications, Contraindications, and Patient Work-Up. *Seminars in Interventional Radiology*. 2014;31(03):235-242. doi:10.1055/s-0034-1382790.
8. Dariushnia SR, Haskal ZJ, Midia M, et al. Quality Improvement Guidelines for Transjugular Intrahepatic Portosystemic Shunts. *Journal of Vascular and Interventional Radiology*. 2016;27(1):1-7. doi:10.1016/j.jvir.2015.09.018.
9. Margini C, Berzigotti A. Portal vein thrombosis: the role of imaging in the clinical setting. *Dig Liver Dis*. 2017;49(2):113-120. doi:10.1016/j.dld.2016.11.013.
10. Northup PG, Garcia-Pagan JC, Garcia-Tsao G, et al. Vascular liver disorders, portal vein thrombosis, and procedural bleeding in patients with liver disease: 2020 practice guidance by the American Association for the Study of Liver Diseases. *Hepatology*. 2020;73(1):366-413. doi:10.1002/hep.31646.
11. Humbert M, Kovacs G, Hoeper MM, et al. 2022 ESC/ERS guidelines for the diagnosis and treatment of pulmonary hypertension. *European Respiratory Journal*. 2022;61(3). doi:10.1183/13993003.00879-2022.
12. Boike JR, Thornburg BG, Asrani SK, et al. North American practice-based recommendations for transjugular intrahepatic portosystemic shunts in portal hypertension. *Clinical Gastroenterology and Hepatology*. 2022;20(8):1636-1662.e36. doi:10.1016/j.cgh.2021.07.018.
13. Billey C, Billet S, Robic MA, et al. A prospective study identifying predictive factors of cardiac decompensation after transjugular intrahepatic portosystemic shunt: the Toulouse algorithm. *Hepatology*. 2019;70(6):1928-1941. doi:10.1002/hep.30934.
14. Chopard R, Albertsen IE, Piazza G. Diagnosis and treatment of lower extremity venous thromboembolism: a review. *JAMA*. 2020;324(17):1765-1776.
15. Needleman L, Cronan JJ, Lilly MP, et al. Ultrasound for lower extremity deep venous thrombosis. multidisciplinary recommendations from the Society of Radiologists in Ultrasound Consensus Conference. *Circulation*. 2018;137:1505-1515.
16. Sloves J, Almeida J. Venous duplex ultrasound protocol for ilioacaval disease. *J Vasc Surg Venous Lymphat Disord*. 2018;6(6):748-757.

Suspected Neuroendocrine Tumors of the Abdomen (AB-44)

Guideline

Suspected Neuroendocrine Tumors of the Abdomen (AB-44)

Suspected Neuroendocrine Tumors of the Abdomen (AB-44)

AB.44.A

v1.0.2024

For the evaluation of a suspected neuroendocrine tumor of the abdomen: See **Gastrointestinal/Pancreatic Neuroendocrine Cancers - Suspected/Diagnosis (ONC-15.2)** in the Oncology Imaging Guidelines.

Liver Elastography (AB-45)

Guideline

Liver Elastography (AB-45)

References (AB-45)

Liver Elastography (AB-45)

AB.LE.0045.A

v1.0.2024

- Initial staging of liver fibrosis in suspected non-alcoholic fatty liver disease (NAFLD):
 - Transient Elastography or Vibration-Controlled Transient Elastography (VCTE, e.g. Fibroscan) (CPT® 91200) is the initial imaging modality
 - Typically repeated within a 3-year period. If repeat transient elastography fails, see MRE criteria below²³
 - Magnetic Resonance Elastography (MRE, CPT® 76391) can be approved for ANY of the following:
 - Transient Elastography failure despite use of an XL-probe, OR BMI ≥ 35
 - Conflict between clinical picture and transient elastography results (e.g., individual with portal hypertension but VCTE suggests no fibrosis)
 - VCTE liver stiffness measurement of ≥ 8 kPa
 - FIB 4 score of >2.67
 - Liver biopsy demonstrates fibrosis stage F2-F4
- Special considerations for MRE:
 - For MRE requests in the setting of hemochromatosis, see: **Hereditary (Primary) Hemochromatosis (HH) and Other Iron Storage Diseases (AB-11.2)**
 - Note: The correct CPT code for MR Elastography is CPT® 76391. It is a stand-alone code and it does not require an additional CPT code such as MRI Abdomen (CPT® 74183).
 - An additional MRI Abdomen code should only be approved if there is another appropriate indication for it, other than the Elastography study (for example, MRE for fibrosis scoring in NAFLD due to a BMI ≥ 35 , AND further evaluation of an indeterminate hepatic lesion).
- The use of other ultrasound elastographic techniques (CPT® 76981, CPT® 76982, and CPT® 76983), including but not limited to acoustic radiation force impulse imaging or real-time tissue elastography for any indication is considered experimental or investigational at this time.

Background and Supporting Information

- For the assessment of cirrhosis in individuals with hepatitis C, the AGA noted that MRE has little to no increase in identifying cirrhosis, but had poorer specificity and thus higher false-positive rates than VCTE. In view of this, the AGA concluded that MRE has a poorer diagnostic performance in this setting, compared to VCTE. In their recommendations for the assessment of fibrosis in chronic liver disease, VCTE was recommended over MRE with the exception of NAFLD in high risk populations, in which MRE resulted in a lower rate of false positives compared to VCTE. This was considered a conditional recommendation with a low quality of evidence.

- Transient Elastography (VCTE) is the most studied elastography technique and informs multiple evidence-based guidelines with respect to fibrosis scoring. No national evidence-based guideline recommends the use of either ARFI or real-time tissue elastography (RTTE) over the use of VCTE for any clinical protocol, nor is there direct evidence that ARFI or RTTE improves health outcomes over and above VCTE.
- Vibration-Controlled Transient Elastography (VCTE) (e.g. Fibroscan, CPT® 91200) may be considered appropriate to assess for advanced fibrosis and cirrhosis in the following conditions: (Note: eviCore does not currently review for this procedure code and providers should contact the insurer directly for any pre-authorization requirements.)
 - Hepatitis C
 - Hepatitis B
 - Chronic alcoholic liver disease
 - All other chronic liver diseases
- FIB-4 index is calculated as follows²²:
 - $FIB-4 = (Age \text{ in years} \times AST \text{ level}) / (\text{Platelet count} \times \sqrt{\text{of ALT}})$

References (AB-45)

v1.0.2024

1. American Gastroenterologic Association Institute guideline on the role of elastography in the evaluation of liver fibrosis. *Gastroenterology*. 2017;152:1536-1543.
2. Conti CB, Cavalcoli F, Fraquelli M, Conte D, Massironi S. Ultrasound elastographic techniques in focal liver lesions. *World Journal of Gastroenterology*. 2016;22(9):2647. doi:10.3748/wjg.v22.i9.2647.
3. The diagnosis and management of nonalcoholic fatty liver disease: Practice guidance from the American Association for the Study of Liver Diseases. *Clinical Liver Disease*. 2018;11(4):81-81. doi:10.1002/cld.722.
4. Li Q, Dhyani M, Grajo JR, Sirlin C, Samir AE. Current status of imaging in nonalcoholic fatty liver disease. *World Journal of Hepatology*. 2018;10(8):530-542. doi:10.4254/wjh.v10.i8.530.
5. Imajo K, Kessoku T, Honda Y, et al. Magnetic Resonance Imaging More Accurately Classifies Steatosis and Fibrosis in Patients With Nonalcoholic Fatty Liver Disease Than Transient Elastography. *Gastroenterology*. 2016;150(3). doi:10.1053/j.gastro.2015.11.048.
6. Chalasani N, Younossi Z, Lavine JE, et al. The diagnosis and management of nonalcoholic fatty liver disease: Practice guidance from the American Association for the Study of Liver Diseases. *Hepatology*. 2017;67(1):328-357. doi:10.1002/hep.29367.
7. Vuppalanchi R, Siddiqui MS, Natta MLV, et al. Performance characteristics of vibration-controlled transient elastography for evaluation of nonalcoholic fatty liver disease. *Hepatology*. 2017;67(1):134-144. doi:10.1002/hep.29489.
8. Castera L, Friedrich-Rust M, Loomba R. Noninvasive assessment of liver disease in patients with nonalcoholic fatty liver disease. *Gastroenterology*. 2019;156(5). doi:10.1053/j.gastro.2018.12.036.
9. Kanwal F, Shubrook JH, Adams LA, et al. Clinical care pathways for the risk stratification and management of patients with nonalcoholic fatty liver disease. *Gastroenterology*. 2021;161(5):1657-1669.
10. Long MT, Nouredin M, Lim JK. AGA Clinical practice update: Diagnosis and management of nonalcoholic fatty liver disease in lean individuals: Expert review. *Gastroenterology*. 2022;163(3):764-774.e1.
11. Murag S, Ahmed A, Kim D. Recent epidemiology of nonalcoholic fatty liver disease. *Gut Liver*. 2021;15(2):206-216. doi:10.5009/gnl20127.
12. Sanyal AJ, Van Natta ML, Clark J, et al. Prospective Study of outcomes in adults with nonalcoholic fatty liver disease. *N Engl J Med*. 2021;385:1559-1569 doi:10.1056/NEJMoa2029349.
13. Cusi K, Isaacs S, Barb D, et al. American Association of Clinical Endocrinology clinical practice guideline for the diagnosis and management of nonalcoholic fatty liver disease in primary care and endocrinology clinical settings. *Endocr Pract*. 2022;28(5):528-562. doi:10.1016/j.eprac.2022.03.010.
14. Mantovani A, Dalbeni A. Treatments for NAFLD: state of the art. *Int J Mol Sci*. 2021;22(5):2350. doi:10.3390/ijms22052350.
15. Selvaraj EA, Mózes EF, Jayaswal ANA, et al. Diagnostic accuracy of elastography and magnetic resonance imaging in patients with NAFLD: a systemic review and meta-analysis. *J Hepatol*. 2021;(75):770-785. doi:10.1016/j.jhep.2021.04.044.
16. Imajo K, Honda Y, Kobayashi T, et al. Direct comparison of US and MR elastography for staging liver fibrosis in patients with nonalcoholic fatty liver disease. *Clin Gastro Hepatol*. 2022;20:908-917. doi:10.1016/j.cgh.2020.12.016.
17. Ajmera A, Nguyen K, Tamaki N, et al. Prognostic utility of magnetic resonance elastography and MEFIB index in predicting liver-related outcomes and mortality in individuals at risk of and with nonalcoholic fatty liver disease. *Therap Adv Gastroenterol*. 2022;(15):1-13. doi:10.1177/17562848221093869.
18. Younossi ZM, Nouredin M, Bernstein D, et al. Role of noninvasive tests in clinical gastroenterology practices to identify patients with nonalcoholic steatohepatitis at high risk of adverse outcomes: expert panel recommendations. *Am J Gastroenterol*. 2021;116(2):254-262. doi:10.14309/ajg000000000001054.
19. Orci LA, Sanduzzi-Zamparelli M, Caballol B, et al. Incidence of hepatocellular carcinoma in patients with nonalcoholic fatty liver disease: a systemic review, meta-analysis, and meta-regression. *Clin Gastroenterol Hepatol*. 2022;20(2):283-292. doi:10.1016/j.cgh.2021.05.002.
20. Sterling RK, Lissen E, Clumeck N, et al. Development of a simple noninvasive index to predict significant fibrosis patients with HIV/HCV co-infection. *Hepatology*. 2006;43:1317-1325.
21. Gidener T, Dierkhising RA, Mara KC, et al. Change in serial liver stiffness measurement by magnetic resonance elastography and outcomes in NAFLD. *Hepatology*. 2023;77(1):268-274. doi:10.1002/hep.32594.

Hiccups (AB-46)

Guideline

Hiccups (AB-46.0)

References (AB-46)

Hiccups (AB-46.0)

AB.HI.0046.0.A

v1.0.2024

- Note: Hiccups may be associated with cerebrovascular disease, brain tumors, and intracranial injury, though it would be very rare for hiccups to be the only presenting symptom of serious neurologic disease. If concern is expressed for neurologic involvement, please see the appropriate guideline in HD imaging (e.g., **Neuromyelitis Optica and NMO Spectrum Disorders (HD-16.2)** and **Anti-MOG syndromes (HD-16.3)**)
- Hiccups <48 hours without any localizing or specific symptoms:
 - No advanced imaging
- Hiccups ≥48 hours:
 - History and physical examination, laboratory and CMP and baseline chest x-ray
 - Abnormal or negative chest x-ray with symptoms referable to the chest:
 - CT Chest with contrast (CPT® 71260)
 - Lab or history/physical findings suggest a gastrointestinal etiology:
 - CT Abdomen with contrast (CPT® 74160)

References (AB-46)

v1.0.2024

1. *British Journal of General Practice*. Hiccups. A Common Problem with Some Unusual Causes and Cures: 2016;66(652):584-586.
2. Steger M, Schneemann M, Fox M. Systemic review: the pathogenesis and pharmacological treatment of hiccups. *Alimentary Pharmacology & Therapeutics*. 2015;42(9):1037-1050. doi:10.1111/apt.13374.

Retroperitoneal Fibrosis (AB-47)

Guideline

Retroperitoneal Fibrosis (AB-47.0)

References (AB-47)

Retroperitoneal Fibrosis (AB-47.0)

AB.RP.0047.0.A

v1.0.2024

- Individuals diagnosed with retroperitoneal fibrosis:
 - ONE of the following every 3 months until stability demonstrated:
 - CT Abdomen and Pelvis with contrast (CPT® 74177)
 - MRI Abdomen and Pelvis without contrast (CPT® 74181 and CPT® 72195)
 - MRI Abdomen and Pelvis with and without contrast (CPT® 74183 and CPT® 72197)
 - Retroperitoneal or Abdominal ultrasound (CPT® 76770 or CPT® 76700) can be approved if requested.
 - After stability established repeat imaging can be approved every 6 months.
 - Requests for non-contrasted studies in individuals with renal insufficiency is appropriate. Gadolinium may induce nephrogenic systemic fibrosis in individuals with moderate or severe renal insufficiency, especially if the GFR is <30 ml/min.
 - Additional imaging:
 - CT Chest (CPT® 71260) can also be performed upon initial diagnosis if requested, to further evaluate for the possibility of malignancy as an underlying etiology.
- PET/CT (CPT® 78815)
 - Can be considered initially, after diagnosis, to establish avidity patterns to assess for the likelihood of malignancy and for stratification for the likelihood of response to steroids.
 - Follow-up can be considered if there is documentation of an anticipated therapeutic change based on the results (such as a change in immunosuppression therapy or stent removal).
- Methysergide-induced retroperitoneal fibrosis:
 - Methysergide for migraine treatment is generally no longer available but is rarely being used at some centers. It has a known complication of retroperitoneal fibrosis.
 - Individuals can be screened at baseline and then every 6 months with ONE of the following:
 - CT Abdomen and Pelvis with contrast (CPT® 74177)
 - CT Abdomen and Pelvis without contrast (CPT® 74176)
 - MRI Abdomen and Pelvis without and with contrast (CPT® 74183 and CPT® 72197)
 - MRI Abdomen and Pelvis without contrast (CPT® 74181 and CPT® 72195)
 - Retroperitoneal ultrasound (CPT® 76770 or CPT® 76775)

Background and Supporting Information

Retroperitoneal fibrosis is a rare disease, and may be idiopathic (IgG4 or non-IgG-4 related) or secondary. Secondary causes include malignancy, infections, previous radiation therapy, previous abdominal surgery, drugs such as methysergide, and biologic agents.

References (AB-47)

v1.0.2024

1. Retroperitoneal Fibrosis Clinical Presentation: History and Physical Examination. Retroperitoneal Fibrosis Clinical Presentation: History and Physical Examination. <https://emedicine.medscape.com/article/458501-clinical>. Published May 30, 2019.
2. Vaglio A, Maritati F. Idiopathic Retroperitoneal Fibrosis. *Journal of the American Society of Nephrology*. 2016;27(7):1880-1889. doi:10.1681/asn.2015101110.
3. Runowska M, Majewski D, Puszczewicz M. Retroperitoneal fibrosis – the state-of-the-art. *Reumatologia/Rheumatology*. 2016;5:256-263. doi:10.5114/reum.2016.63667.
4. Urban M, Palmisano A, Nicastro M, Corradi D, Buzio C, Vaglio A. Idiopathic and secondary forms of retroperitoneal fibrosis: A diagnostic approach. *La Revue de Médecine Interne*. 2015;36(1):15-21. doi:10.1016/j.revmed.2014.10.008.
5. EMA restricts methysergide use, concern over fibrosis. *Reactions Weekly*. 2014;1491(1):2-2. doi:10.1007/s40278-014-9172-x.
6. Fendler WP, Eiber M, Stief CG, Herrmann K. A PET for All Seasons: 18 F-Fluorodeoxyglucose to Characterize Inflammation and Malignancy in Retroperitoneal Fibrosis? *European Urology*. 2017;71(6):934-935. doi:10.1016/j.eururo.2017.01.019.
7. Gu L, Wang Y, Zhang X. Re: Archie Fernando, James Pattison, Catherine Horsfield, David D'Cruz, Gary Cook, Tim O'Brien. [18F]-Fluorodeoxyglucose Positron Emission Tomography in the Diagnosis, Treatment Stratification, and Monitoring of Patients with Retroperitoneal Fibrosis: A Prospective Clinical Study. *Eur Urol* 2017;71:926–33. *European Urology*. 2017;72(2). doi:10.1016/j.eururo.2017.02.029.

Fistulae (AB-48)

Guideline

Fistulae (AB-48)

References (AB-48)

Fistulae (AB-48)

AB.FD.0048.A

v1.0.2024

- Suspected enteric fistulae
 - CT Abdomen and Pelvis with contrast (CPT® 74177)
- Suspected colovesical fistulae
 - CT Abdomen and Pelvis without contrast (CPT® 74176)
- Enterocutaneous fistulae
 - Suspected enterocutaneous fistulae:
 - CT Abdomen and Pelvis with contrast (CPT® 74177)
 - MRI Abdomen and Pelvis without and with contrast (CPT® 74183) is appropriate to substitute if there is a contraindication to CT
 - Surgical planning of known complex fistulae:
 - MRI Abdomen and Pelvis without and with contrast (CPT® 74183) if not already performed
- Complicated diverticulitis with fistula, see: **Acute/Persistent (Non-Chronic) Lower Abdominal Pain (AB-2.2)**
- Perianal/perirectal fistulae and abscess related to Crohn's disease, see: **Perirectal/Perianal Disease (AB-23.3)**
- Other fistulae related to Crohn's disease, see: **Known IBD (AB-23.2)**
- Perianal/perirectal fistulae NOT related to Crohn's disease, see: **Fistula in Ano (PV-21.1)** in the Pelvis Imaging Guidelines
- For colovaginal, rectovesicular, rectovaginal, or urinary-vaginal communicating fistulae, see: **Pelvic Fistula (PV-21.3)** in the Pelvis Imaging Guidelines
- For pilonidal cyst, see: **Pilonidal Cyst (PV-21.4)** in the Pelvis Imaging Guidelines

Background and Supporting Information

- Examples of gastrointestinal fistulae include tracheo- and broncho-esophageal, entero-cutaneous, entero-enteric, entero-colic, entero-vesical, colo-vesical, recto-vaginal, perianal, and aorto-enteric.
- Etiologies of fistulae include: complication of inflammatory disease (e.g., Diverticulitis, Crohn's disease), complication of surgical procedures (which are the most common cause of intestinal fistula, comprising more than half of all fistulae), obstetric injury (e.g., recto-vaginal, ano-vaginal), malignancy, radiation, non-surgical injuries, and foreign bodies.

References (AB-48)

v1.0.2024

1. Expert Panel on Gastrointestinal Imaging. ACR Appropriateness Criteria® Crohn's disease. American College of Radiology (ACR); Reviewed 2021.
2. Lichtenstein GR, Loftus EV, Isaacs KL, Regueiro MD, Gerson LB, Sands BE. ACG Clinical Guideline: Management of Crohn's Disease in Adults. *American Journal of Gastroenterology*. 2018;113(4):481-517. doi:10.1038/ajg.2018.27.
3. Evenson AR, Fischer JE. Current management of enterocutaneous fistula. *J Gastrointest Surg*. 2006;10:455-464. doi:10.1016/j.gassur.2005.08.001.
4. Reed MF, Mathisen DJ. Tracheoesophageal fistula. *Chest Surg Clin N Am*. 2003;13:271-289. doi:10.1016/s1052-3359(03)00030-9.
5. Golabek T, Szymanska A, Szopinski T, Bukowczan J, Furmanek M, Powroznik J, Piotr C. Enterovesical fistulae: aetiology, imaging, and management. *Gastroenterol Res Pract*. 2013;6:617967. doi:10.1155/2013/617967.
6. Dolejs SC, Penning AJ, Guzman MJ, et al. Perioperative Management of Patients with Colovesical Fistula. *J Gastrointest Surg*. 2019;23:1867-1873. doi:10.1007/s11605-018-4034-0.
7. Hyde BJ, Byrnes JN, Occhino JA, Sheedy SP, VanBuren WM. MRI review of female pelvic fistulizing disease. *J Magn Reson Imaging*. 2018;48:1172. doi:10.1002/jmri.26248.
8. Vogel JD, Johnson EK, Morris AM, et al. Clinical Practice Guideline for the Management of Anorectal Abscess, Fistula-in-Ano, and Rectovaginal fistula. *Dis Colon Rectum*. 2016;59:1117-1133. doi:10.1097/DCR.0000000000000733.

Table of Contents

Guideline

- General Considerations (BR-Preface 1)
- Breast Ultrasound (BR-1)
- MRI Breast Coding (BR-2)
- Breast Reconstruction (BR-3)
- MRI Breast Indications (BR-5)
- Nipple Discharge/Galactorrhea (BR-6)
- Breast Pain (Mastodynia) (BR-7)
- Alternative Breast Imaging Approaches (BR-8)
- Suspected Breast Cancer in Males (BR-9)
- Breast Evaluation in Pregnant or Lactating Females (BR-10)
- Transgender Breast Cancer Supplemental Screening (BR-12)
- 3D Rendering (BR-13)
- References (BR)

General Considerations (BR-Preface 1)

Guideline

Abbreviations for Breast Guidelines

General Guidelines (BR-Preface 1.0)

BI-RADSTM Categories Chart (BR-Preface 1.1)

BI-RADSTM Breast Density Categories (BR-Preface 1.2)

Abbreviations for Breast Guidelines

BR.GG.Abbreviations.A
v2.0.2024

Abbreviations for Breast Guidelines	
BI-RADS™	Breast Imaging Reporting and Database System
BRCA	tumor suppressor gene
CAD	computer-aided detection
CT	computed tomography
CTA	computed tomography angiography
CTV	computed tomography venography
DCIS	ductal carcinoma in situ
FDA	Food and Drug Administration
FDG	fluorodeoxyglucose
FNA	fine needle aspiration
HRCT	high resolution computed tomography
LCIS	lobular carcinoma in situ
MRA	magnetic resonance angiography
MRI	magnetic resonance imaging
PEM	positron-emission mammography
PET	positron emission tomography

General Guidelines (BR-Preface 1.0)

BR.GG.0001.0.A
v2.0.2024

- A current clinical evaluation since the onset or change in symptoms is usually required prior to considering advanced imaging.
 - A clinical evaluation should include the following:
 - A relevant history and physical examination since the onset or change in symptoms
 - Appropriate laboratory studies and non-advanced imaging modalities, such as mammogram and/or ultrasound
 - Other meaningful contact (telephone call, electronic mail or messaging) since the onset or change in symptoms by an established individual can substitute for a face-to-face clinical evaluation
- Current clinical evaluation is not required prior to screening studies.
- Throughout this guideline, when MRI Breast is indicated any **ONE** of the following codes is supported:
 - CPT® 77049 MRI Breast Bilateral, including CAD, with and without contrast
 - HCPCS C8908 MRI Breast Bilateral, with and without contrast
- If the individual has breast implants, the following code is supported when MRI Breast is requested to assess integrity of breast implants **AND** is also indicated in the guidelines:
 - CPT® 77047 MRI Breast Bilateral, without contrast

BI-RADS™ Categories Chart (BR-Preface 1.1)

BR.GG.0001.1.A

v2.0.2024

BI-RADS™ Categories Chart	
Category	Description
Category 0: Incomplete	<p>Need additional imaging evaluation or prior mammograms for comparison.</p> <p>Category 0 classification requires that additional imaging study be specified, e.g., ultrasound, additional mammogram view, MRI.</p>
Category 1: Negative	<p>There is nothing to comment on. The breasts are symmetrical and no masses, architectural disturbances, or suspicious calcifications are present.</p>
Category 2: Benign Finding	<p>This is also a negative mammogram, but the interpreter may wish to describe a finding. Involuting, calcified fibroadenomas, multiple secretory calcifications, fat-containing lesions (such as oil cysts, lipomas, galactoceles, and mixed density hamartomas) all have characteristic appearances, and may be labeled with confidence. The interpreter might wish to describe intramammary lymph nodes, implants, etc. while still concluding that there is no mammographic evidence of malignancy.</p>

BI-RADS™ Categories Chart	
Category	Description
<i>Category 3: Probably Benign Finding – Short Interval Follow-up Suggested</i>	A finding placed in this category should have a very high probability of being benign. It is not expected to change over the follow-up interval, but the radiologist would prefer to establish its stability. Data is becoming available that sheds light on the efficacy of short interval follow-up. At the present time, most approaches are intuitive. These will likely undergo future modification as more data accrue as to the validity of an approach, the interval required, and the type of findings that should be followed.
<i>Category 4: Suspicious Abnormality – Biopsy Should Be Considered</i>	There are lesions that do not have the characteristic morphologies of breast cancer but have a definite probability of being malignant. The radiologist has sufficient concern to urge a biopsy. If possible, the relevant possibilities should be cited so that the individual and her physician can make the decision on the ultimate course of action.
<i>Category 5: Highly Suggestive of Malignancy – Appropriate Action Should Be Taken</i>	These lesions have a high probability of being cancer and should be biopsied or treated surgically.
<i>Category 6: Known Biopsy-Proven Malignancy – Appropriate Action Should Be Taken</i>	These lesions have been biopsied and are known to be malignant.

BI-RADS™ Breast Density Categories (BR-Preface 1.2)

BR.GG.0001.2.A

v2.0.2024

BI-RADS™ Breast Density Categories
<i>Category A: Almost entire fatty</i>
<i>Category B: Scattered fibroglandular densities</i>
<i>Category C: Heterogeneously dense</i>
<i>Category D: Extremely dense</i>

Breast Ultrasound (BR-1)

Guideline

Breast Ultrasound (BR-1.1)

Breast Ultrasound (BR-1.1)

BR.US.0001.1.A
v2.0.2024

- Routine performance of breast ultrasound as stand-alone screening or with screening mammography is inappropriate.
 - Breast ultrasound is a supplemental screening alternative for high-risk females (as described in **MRI Breast Indications [BR-5]**) with dense breasts on mammography, when MRI Breast without and with contrast cannot be performed. The inability to perform MRI Breast may be because it cannot be tolerated (i.e., insurmountable claustrophobia or body habitus), or there exists a contraindication (i.e., non-MRI compatible implantable devices or an inability to receive MRI contrast). When a MRI Breast has not been performed in the past year for high-risk screening, then a bilateral breast ultrasound requested for supplemental screening in high-risk females with dense breasts on mammography is supported.
 - Equivocal or Occult Findings:
 - Breast ultrasound (CPT® 76641 or CPT® 76642): Radiologist Report recommendation **and** inconclusive or conflicting findings on mammography or MRI Breast
- Breast ultrasound (CPT® 76641: unilateral, complete; or, CPT® 76642: unilateral, limited) can be used to further evaluate abnormalities found on mammogram, especially in differentiating cysts from solid lesions.
 - A clinical office visit is not necessary prior to breast ultrasound when an abnormality has been identified on recent (within the last 60 days) mammogram.
- BI-RADS™ Cat 3 ultrasound follow-up imaging for stable findings at 6 months:
 - If repeat imaging remains BI-RADS™ 3, repeat at 12 months, 18 months, and 24 months from the date of the initial imaging.
 - After 2 years of stability, the finding should be assessed as benign (Cat 2).
 - If repeat imaging is BI-RADS™ 1 or 2, then imaging reverts to routine per individual's risk profile.
- Mammography and breast ultrasound, in any order, regardless of age for palpable breast masses or other clinical abnormalities (such as skin change, pain, nipple inversion). Ultrasound can enhance biopsy.
- If recent clinical examination is equivocal for rupture of breast implants (saline or silicone), initial imaging is indicated as below:

Evaluation of Suspected Rupture of Breast Implants		
Age	Saline Breast Implant	Silicone Breast Implant
<30	Breast Ultrasound	Breast Ultrasound or MRI Breast without contrast (CPT® 77047)

Evaluation of Suspected Rupture of Breast Implants		
Age	Saline Breast Implant	Silicone Breast Implant
30-39	Breast Ultrasound or mammography/Digital breast tomosynthesis (DBT)	Breast Ultrasound, mammography/Digital breast tomosynthesis (DBT) or MRI Breast without contrast (CPT® 77047)
≥40	Mammography/Digital breast tomosynthesis (DBT)	Mammography/Digital breast tomosynthesis (DBT) or MRI Breast without contrast (CPT® 77047)

- Axilla ultrasound (CPT® 76882)
 - For females with clinically suspicious lymph nodes, pre-operative axillary ultrasound with a FNA or biopsy can help identify individuals who have positive nodes.
 - See **Axillary Lymphadenopathy (and Mass) (CH-2.2)** in the Chest Imaging Guidelines.
 - Bilateral should be coded CPT® 76882 x 2.
- US-guided breast biopsy (CPT® 19083) includes the imaging component.
 - Additional lesions should be billed using CPT® 19084.
- Ultrasound Breast can be repeated at least 6 months after an US-directed breast biopsy to document successful lesion sampling if histology is benign and non-specific, equivocal or uncertain.
- 3D Reconstruction (CPT® 76376 or CPT® 76377) is **NOT** indicated for breast ultrasound. It is commonly requested in conjunction with automated breast ultrasound (ABUS); there is no evidence to support its clinical usefulness.
- State-Specific Density Reporting and Imaging Mandate Laws
 - Breast density notification laws have been put into effect by many states. Breast density notification laws vary, but some also contain mandates for additional imaging, which may include MRI and/or ultrasound. For applicable requests involving members in these states, their legislative mandates should be followed.

MRI Breast Coding (BR-2)

Guideline

MRI Breast Coding (BR-2.1)

MRI Breast Coding (BR-2.1)

BR.MR.0002.1.A

v2.0.2024

- The use of gadolinium contrast is required for the evaluation of breast parenchyma.
- The use of gadolinium contrast is **NOT** necessary for the evaluation of implant integrity in asymptomatic, average-risk individuals.
- Computer-aided detection (CAD) is included with the MRI Breast CPT® 77049 and CPT® 77048 procedures. The use of HCPCS code C8937 (CAD including computer algorithm analysis of MRI Breast data for lesion detection/characterization, pharmacokinetic analysis, with further physician review for interpretation) is **NOT** necessary with these procedures.
 - The use of CAD has little influence on the sensitivity and specificity of MRI Breast interpretation.
 - The use of HCPCS code C8937 (CAD including computer algorithm analysis of MRI Breast data for lesion detection/characterization, pharmacokinetic analysis, with further physician review for interpretation) is currently considered investigational, experimental, and/or unproven.
 - Since the CAD software automatically performs 3D imaging, CPT® 76376 or CPT® 76377 should **NOT** be used in conjunction with MRI Breast.
- MRI-guided breast biopsy (CPT® 19085) includes the imaging component and the needle placement under MR guidance; CPT® 77021 MR guidance for needle placement is **NOT** an appropriate code to bill for a breast biopsy.
 - Additional lesions should be billed using CPT® 19086.
 - eviCore does not manage codes CPT® 19085 or CPT® 19086.

Background and Supporting Information

- Although MRI Breast has superior sensitivity in identifying new unknown malignancies, it carries a significant false positive risk when compared to mammogram and ultrasound. Incidental lesions are seen on 15% of MRI Breast and increase with younger age. The percentage of incidental lesions that turn out to be malignant varies from 3% to 20% depending on the individual population. Cancer is identified by MRI Breast in only 0.7% of those with “inconclusive mammographic lesions.”

Breast Reconstruction (BR-3)

Guideline

Breast Reconstruction (BR-3.1)

Breast Reconstruction (BR-3.1)

BR.RC.0003.1.A
v2.0.2024

- CTA or MRA of the body part from which the free-tissue transfer flap is being taken, can be performed for breast reconstruction preoperative planning.
 - For example, CTA Abdomen and/or Pelvis (CPT® 74175 or CPT® 72191 or CPT® 74174) or MRA Abdomen and/or Pelvis (CPT® 74185 and/or CPT® 72198) for Deep Inferior Epigastric Perforators (DIEP) flap.
- Routine use of CTA Chest (CPT® 72175) to evaluate recipient vessels is **NOT** indicated.
 - **Criteria exception:** In circumstances where there has been previous cardiac/vascular surgery and/or known vascular anomalies in the chest, it may be warranted.
- There is currently insufficient evidence-based data to support the need for routine advanced imaging for TRAM flaps or other flaps performed on a vascular pedicle.

MRI Breast Indications (BR-5)

Guideline

MRI Breast Indications (BR-5.1)

MRI Breast Indications (BR-5.1)

BR.RC.0005.1.U
v2.0.2024

Breast MRI Considerations

- When MRI Breast imaging is clinically indicated (per the criteria listed in the sections below), an MRI Breast Bilateral with and without contrast is supported.
- MRI Breast Unilateral is **NOT** clinically supported.
- See **Breast Ultrasound (BR-1.1)** when there is a contraindication to MRI contrast.
- See **MRI Breast Coding (BR-2)** for MRI-guided breast biopsy.
- See **Breast Cancer (ONC-11)** in the Oncology Imaging Guidelines for imaging indications related to breast cancer as follows:
 - Breast Cancer - Initial work-up/Staging
 - Breast Cancer - Restaging/Recurrence
 - Breast Cancer - Surveillance/Follow-up
 - Annual screening with prior history of breast cancer

Suspected Rupture of Breast Implants

- Routine surveillance imaging for asymptomatic individuals to assess the integrity of breast implants (silicone or saline) is **NOT** supported.
- Breast MRI is **NOT** indicated for evaluation of capsular contracture.
- For suspected ruptured breast implants (saline or silicone), with a recent equivocal clinical examination and/or conventional imaging, the appropriate imaging for further evaluation is indicated in the table below:

Evaluation of Suspected Rupture of Breast Implants		
Age	Saline Breast Implant	Silicone Breast Implant
<30	Breast Ultrasound	Breast Ultrasound or MRI Breast without contrast (CPT® 77047)
30-39	Breast Ultrasound or mammography/Digital breast tomosynthesis (DBT)	Breast Ultrasound, mammography/Digital breast tomosynthesis (DBT) or MRI Breast without contrast (CPT® 77047)
≥40	Mammography/Digital breast tomosynthesis (DBT)	Mammography/Digital breast tomosynthesis (DBT) or MRI Breast without contrast (CPT® 77047)

Malignant Phyllodes Tumor (Cystosarcoma Phyllodes)

- MRI Breast is indicated pre-operatively to establish extent of disease where a diagnosis of malignant phyllodes tumor has previously been established by tissue diagnosis. See **Background and Supporting Information**.

Mammogram and/or US with Equivocal or Occult Findings

- MRI Breast is **NOT** indicated to determine biopsy recommendations for suspicious or indeterminate lesion(s) that can be readily biopsied, either using imaging guidance or physical exam, such as palpable masses and microcalcifications.
- MRI Breast is indicated for **EITHER** of the following:
 - Radiologist Report Recommendation for MRI Breast to assess inconclusive or conflicting findings on mammography or ultrasound with **EITHER** of the following:
 - Findings that are not associated with a discrete palpable mass.
 - Inconclusive findings of fat necrosis (most commonly due to trauma or surgery) in an individual with a history of breast cancer treated with surgery (lumpectomy or mastectomy with or without reconstruction).
 - Documented histopathologic discordance between core-needle biopsy findings and imaging findings. MRI Breast is indicated for further evaluation **after** the discordant biopsy (before consideration for surgical management vs. observation).
 - Discordance exists when the biopsy result does not adequately explain the abnormal (BI-RADS™ 4 or 5) findings on mammogram and/or ultrasound.
- See **MRI BI-RADS™ 3** section for lesions categorized as BI-RADS™ 3 on MRI.
- Lesions that are categorized as BI-RADS™ 3 (low risk, probably benign) **on mammogram and/or ultrasound** are not considered equivocal. MRI Breast is **NOT** indicated for these lesions.
 - Repeat the original study type (mammogram or US) in 6 months
 - If repeat imaging remains BI-RADS™ 3, repeat original study type at 12 months, 18 months, and 24 months from the date of the initial imaging.
 - After 2 years of stability, the finding should be assessed as benign (Cat 2).
 - If repeat imaging is BI-RADS™ 1 or 2, then imaging reverts to routine per individual's risk profile. See **Risk Factors** section.
- MRI Breast is **NOT** indicated for suspicious (BI-RADS™ 4 or 5) lesion on mammogram and/or ultrasound.
 - A lesion categorized as BI-RADS™ 4 or 5 should be biopsied.

MRI BI-RADS™ 3

- A probably benign lesion on **MRI** (MRI BI-RADS™ 3) should undergo repeat MRI in 6 months.

- If repeat imaging remains MRI BI-RADS™ 3, then repeat at 12 months, 18 months, and 24 months from the date of the initial imaging.
 - After 2 years of stability, the finding should be assessed as benign (Cat 2)
- If repeat imaging is BI-RADS™ 1 or 2, then imaging reverts to routine per individual’s risk profile. See **Risk Factors** section.
- For lesions initially seen on MRI Breast **and** that have benign and non-specific, equivocal or uncertain histology (based on a stereotactic, MRI-guided, or US-directed breast biopsy), an MRI Breast can be repeated at least 6 months after the biopsy to document successful lesion sampling.

Risk Factors

- To date, evidence does not suggest improved outcomes for individuals whose only risk factor is breast density. Therefore, MRI Breast is **NOT** indicated for individuals whose only risk factor is dense breasts as determined by mammogram.
 - See **Mammogram and/or US with Equivocal or Occult Findings** section.
- Routine MRI Breast following bilateral mastectomy is **NOT** indicated (even if high-risk screening criteria may otherwise be met).
- Annual MRI Breast screening is indicated for individuals meeting the high-risk criteria in the table below:

High-Risk Indications	
<i>MRI screening to begin at age 20:</i>	
1.	Li-Fraumeni Syndrome (TP53 mutation) should start annual breast screening MRI starting at age 20 or at the age of the earliest diagnosed breast cancer in the family, <u>whichever comes first</u> .
<i>MRI screening to begin at diagnosis but <u>not prior to age 25</u>:</i>	
2.	Individuals with a history of: <ul style="list-style-type: none"> • Atypical ductal hyperplasia (ADH) • Atypical lobular hyperplasia (ALH) • Lobular carcinoma in situ (LCIS)
<i>MRI screening to begin at age determined by gene mutation:</i>	
3.	BRCA 1 or BRCA 2 begin age 25
4.	STK11, Peutz-Jeghers syndrome (PJS), PTEN Mutation (Cowden Syndrome), CDH1, NF1, PALB2, ATM, CHEK2 begin age 30
5.	BARD1, RAD51C, RAD51D begin age 40

High-Risk Indications	
6.	<p>The following have unknown or insufficient evidence of breast cancer risk and additional MRI screening is NOT indicated at this time:</p> <p>MSH2, MLH1, MSH6, PMS2, EPCAM, NBN, genetic variants of unknown significance, genetic variants favoring polymorphism, and genetic variants of intermediate penetrance.</p>
<i>MRI screening begins at age 40:</i>	
7.	<p>If the individual has NOT been tested for BRCA mutation and there is a first-degree relative (parent, sibling, child; half-siblings are considered second-degree relatives) with BRCA 1 or BRCA 2 mutation.</p> <p>Annual screening is NOT indicated if the individual has been tested and is negative for BRCA 1 or BRCA 2 mutation unless they meet other criteria.</p>
<i>MRI screening begins at age 40 or 10 years before the age of relative (lineage as described below) when first diagnosed with breast cancer, <u>but not prior to the age of 25</u>:</i>	
8.	Two or more first-degree relatives with breast or ovarian cancer.
9.	One first-degree relative with breast cancer or ovarian cancer that was diagnosed ≤ age 50.
10.	One first-degree relative with bilateral breast cancer, or both breast and ovarian cancer.
11.	A first- or second-degree male relative (father, brother/half-brother, uncle, grandfather) diagnosed with breast cancer.
12.	<p>Clinical lifetime-risk estimated at greater than or equal to 20% using an acceptable genetic-risk or clinical-risk estimator.</p> <ul style="list-style-type: none"> Acceptable clinical-risk estimator models are Gail (NCI), Claus, Tyrer-Cuzick (IBIS), or BRCAPRO.

High-Risk Indications

*MRI screening to begin at **age 25 or 8 years after completion of radiotherapy** (whichever occurs later - screening MRI Breast is **not supported prior to age 25**):*

13.	<p>Annual MRI Breast and annual mammogram is recommended for individuals who received therapeutic radiation exposure in the following fields while they were under 30 years of age:</p> <ul style="list-style-type: none"> • Chest (thorax) • Whole lung • Mediastinal • Axilla • Mini-mantle, mantle, or extended mantle • Total (TLI) or subtotal (SLTI) lymphoid irradiation • Total body irradiation (TBI)
-----	---

Background and Supporting Information

- myRisk® Hereditary Cancer (Myriad Genetics, Inc.) is not accepted as a risk calculator to determine high-risk for breast cancer.
- MRI should not be used in lieu of biopsy of mammographically, clinically, and/or sonographically suspicious findings (ACR Practice Guidelines).
- State Specific Density Reporting and Imaging Mandate Laws
 - Breast density notification laws have been put into effect by many states. Breast density notification laws vary, but some also contain mandates for additional imaging, which may include MRI and/or ultrasound. For applicable requests involving members in these states, their legislative mandates should be followed.
- Phyllodes Tumor (Cystosarcoma Phyllodes)
 - Phyllodes tumor is usually benign and has clinical characteristics of fibroadenoma, although they may exhibit rapid growth. MRI Breast has not been shown to be of value in distinguishing fibroadenoma from phyllodes tumor.
 - Diagnosis is made by tissue diagnosis (percutaneous core biopsy or excisional biopsy). FNA biopsy is inaccurate in phyllodes tumor diagnosis and is not recommended.
 - Treatment is wide local excision. Axillary lymph node dissection is not necessary. It has a predilection for local recurrence following local excision.
 - If biopsy establishes a diagnosis of **malignant phyllodes** (cystosarcoma phyllodes), it should be treated as a soft tissue sarcoma. See **Sarcomas Bone, Soft Tissue, and GIST(ONC-12)** in the Oncology Imaging Guidelines.

Nipple Discharge/Galactorrhea (BR-6)

Guideline

Nipple Discharge/Galactorrhea (BR-6.1)

Nipple Discharge/Galactorrhea (BR-6.1)

BR.DC.0006.1.A

v2.0.2024

- Pathologic nipple discharge
 - Initial imaging should include diagnostic mammogram and ultrasound (CPT® 76641: unilateral, complete; or, CPT® 76642: unilateral, limited). If these are negative or inconclusive, MRI Breast is the next appropriate imaging study.
- Physiologic nipple discharge
 - If nipple discharge is physiologic, there are no suspicious findings on clinical exam, and mammogram and ultrasound are negative, no additional imaging is necessary, and the individual can be reassured.

Background and Supporting Information

- Physiologic nipple discharge is predominantly bilateral but may be unilateral. It is commonly multi-duct. It is predominantly milky but may be white or a variety of colors including serous, yellow, green, brown, or gray. Evaluation for hyperprolactinemia can be considered.
- For milky discharge, prolactin and TSH levels are recommended to diagnose prolactinoma; pituitary imaging is not needed if normal serum Prolactin.
- Pathologic nipple discharge is defined as unilateral, bloody or serous, arising from a single duct, persistent, and spontaneous.

Breast Pain (Mastodynia) (BR-7)

Guideline

Breast Pain (Mastodynia) (BR-7.1)

Breast Pain (Mastodynia) (BR-7.1)

BR.PA.0007.1.A
v2.0.2024

- Evaluation of breast pain requires a history and physical exam.
- Mammogram and ultrasound are the initial imaging for breast pain.
- Advanced imaging is **NOT** routinely indicated in individuals with breast pain and negative mammogram and ultrasound (CPT® 76641: unilateral, complete; or, CPT® 76642: unilateral, limited).
 - If mammogram and ultrasound are not negative, see **MRI Breast Indications (BR-5)**.

Background and Supporting Information

- The risk of malignancy following a negative clinical examination (clinical breast exam, mammogram, ultrasound) has been estimated to be only 0.5%.

Alternative Breast Imaging Approaches (BR-8)

Guideline

Alternative Breast Imaging Approaches (BR-8.1)

Alternative Breast Imaging Approaches (BR-8.1)

BR.AA.0008.1.A

v2.0.2024

Molecular Breast Imaging (MBI)

- Molecular Breast Imaging (CPT® 78800) is supported in individuals who meet criteria for breast cancer screening with MRI (per BR-5) but for whom MRI is contraindicated.
 - See **MRI Breast Indications (BR-5)**.

Risk Factors

- To date, evidence does not suggest improved outcomes for individuals whose only risk factor is breast density. Therefore, MRI Breast is **NOT** indicated for individuals whose only risk factor is dense breasts as determined by mammogram.
 - See **Mammogram and/or US with Equivocal or Occult Findings** section.
- Routine MRI Breast following bilateral mastectomy is NOT indicated (even if high-risk screening criteria may otherwise be met).
- Annual MRI Breast screening is indicated for individuals meeting the high-risk criteria in the table below:

High-Risk Indications	
<i>MRI screening to begin at age 20:</i>	
1.	Li-Fraumeni Syndrome (TP53 mutation) should start annual breast screening MRI starting at age 20 or at the age of the earliest diagnosed breast cancer in the family, <u>whichever comes first</u> .
<i>MRI screening to begin at diagnosis but <u>not prior to age 25</u>:</i>	
2.	Individuals with a history of: <ul style="list-style-type: none"> • Atypical ductal hyperplasia (ADH) • Atypical lobular hyperplasia (ALH) • Lobular carcinoma in situ (LCIS)
<i>MRI screening to begin at age determined by gene mutation:</i>	
3.	BRCA 1 or BRCA 2 begin age 25
4.	STK11, Peutz-Jeghers syndrome (PJS), PTEN Mutation (Cowden Syndrome), CDH1, NF1, PALB2, ATM, CHEK2 begin age 30
5.	BARD1, RAD51C, RAD51D begin age 40

High-Risk Indications	
6.	<p>The following have unknown or insufficient evidence of breast cancer risk and additional MRI screening is NOT indicated at this time:</p> <p>MSH2, MLH1, MSH6, PMS2, EPCAM, NBN, genetic variants of unknown significance, genetic variants favoring polymorphism, and genetic variants of intermediate penetrance.</p>
<i>MRI screening begins at age 40:</i>	
7.	<p>If the individual has NOT been tested for BRCA mutation and there is a first-degree relative (parent, sibling, child; half -siblings are considered second-degree relatives) with BRCA 1 or BRCA 2 mutation.</p> <p>Annual screening is NOT indicated if the individual has been tested and is negative for BRCA 1 or BRCA 2 mutation unless they meet other criteria.</p>
<i>MRI screening begins at age 40, or 10 years before the age of relative (lineage as described below) when first diagnosed with breast cancer but not prior to the age of 25 :</i>	
8.	Two or more first-degree relatives with breast or ovarian cancer
9.	One first-degree relative with breast cancer or ovarian cancer that was diagnosed ≤ age 50
10.	One first-degree relative with bilateral breast cancer, or both breast and ovarian cancer
11.	A first- or second-degree male relative (father, brother/half-brother, uncle, grandfather) diagnosed with breast cancer
12.	<p>Clinical lifetime- risk estimated at greater than or equal to 20% using an acceptable genetic- risk or clinical-risk estimator</p> <ul style="list-style-type: none"> Acceptable clinical-risk estimator models are Gail (NCI), Claus, Tyrer- Cuzick (IBIS), or BRCAPRO.

High-Risk Indications

*MRI screening to begin at **age 25 or 8 years after completion of radiotherapy** (whichever occurs later - screening MRI Breast is *not supported prior to age 25*):*

13.	<p>Annual MRI Breast and annual mammogram is recommended for individuals who received therapeutic radiation exposure in the following fields while they were under 30 years of age:</p> <ul style="list-style-type: none"> • Chest (thorax) • Whole lung • Mediastinal • Axilla • Mini-mantle, mantle, or extended mantle • Total (TLI) or subtotal (SLTI) lymphoid irradiation • Total body irradiation (TBI)
-----	---

Other Alternative Breast Imaging Techniques

Other alternative breast imaging techniques may have FDA approval, but they remain investigational with respect to **BOTH screening and diagnosis** of breast cancer. These include the following:

- Nuclear breast imaging, including:
 - Scintimammography
 - Breast specific gamma imaging (BSGI)
- PET Mammography (PEM)
- Thermography
- Impedance Mammography
- Other techniques to detect oxygen consumption, light absorption, microwave transmission, nitrous oxide production
- CT Breast (CPT® 0633T, CPT® 0634T, CPT® 0635T, CPT® 0636T, CPT® 0637T, or CPT® 0638T)
- Cone Beam CT Breast

Background and Supporting Information

- CT Breast
 - CT Breast is evolving and currently being studied as a mode of breast cancer detection. It remains under investigation, and is not to be used in lieu of conventional breast imaging modalities.
- Positron Emission Mammography
 - There is currently insufficient data available to generate appropriateness criteria for this modality, and this procedure should be considered investigational at this time.
 - High-resolution positron-emission mammography (PEM) by Naviscan™ PET Systems, also referred to as Naviscan™ or PET mammography, performs high-resolution metabolic imaging for breast cancer using an FDG tracer.

The PEM detectors are integrated into a conventional mammography system, allowing acquisition of the emission images immediately after the mammogram.

- Requesting providers often ask for PEM as CPT® 78811 or “PET scan of the breast.”
- The spatial resolution of this technique is at the individual duct level (1.5 mm) and allows visualization of intraductal as well as invasive breast cancers. This technique is especially adept at detecting ductal carcinoma in situ.
- Early clinical trials have shown high clinical accuracy in characterizing lesions identified as suspicious on conventional imaging or physical examination, as well as in detecting incidental breast cancers not seen on other imaging modalities.
- A prospective multi-center clinical trial for females with newly diagnosed breast cancer anticipating breast-conservation surgery was performed. These females underwent both high-resolution PEM imaging and breast MRI. Results showed that PEM and MRI had comparable breast-level sensitivity, although MRI had greater lesion-level sensitivity and more accurately depicted the need for mastectomy. PEM had greater specificity at the breast and lesion levels. Of these, 3.6% of the females had tumors seen only with PEM.
- The radiation exposure from a PEM study is 23 times higher than for digital mammography.

Suspected Breast Cancer in Males (BR-9)

Guideline

Suspected Breast Cancer in Males (BR-9.1)

Suspected Breast Cancer in Males (BR-9.1)

BR.MA.0009.1.A
v2.0.2024

See **Breast Ultrasound (BR-1)**

- There is limited evidence on the use of MRI in the evaluation of male breast disease.
- Further diagnostic pathway for suspicious clinical or imaging findings usually requires tissue diagnosis.

Background and Supporting Information

- Breast cancer in males presents as a mass, skin/nipple change, or pathologic nipple discharge.

Breast Evaluation in Pregnant or Lactating Females (BR-10)

Guideline

Breast Evaluation in Pregnant or Lactating Females (BR-10.1)

Breast Evaluation in Pregnant or Lactating Females (BR-10.1)

BR.PR.0010.1.A

v2.0.2024

- Breast US (CPT® 76641 or CPT® 76642) is first-line imaging in pregnant and lactating females.
- If pregnant/lactating female has a palpable mass **OR** has persistent unilateral bloody nipple discharge and US is negative or suspicious, follow with diagnostic mammogram (with lead abdominal shielding).
- IV Gadolinium is required with MRI to evaluate breast parenchyma but is contraindicated in pregnancy. Biopsy, rather than advanced imaging, is recommended after inconclusive mammogram and US.

Transgender Breast Cancer Supplemental Screening (BR-12)

Guideline

Transgender Breast Cancer Supplemental Screening (BR-12.1)

Transgender Breast Cancer Supplemental Screening (BR-12.1)

BR.TS.0012.1.A

v2.0.2024

- Annual supplemental Ultrasound **AND/OR** MRI Breast screening is indicated for the following:
 - Transmasculine (female-to-male) with **ALL** of the following risk factors:
 - Reduction mammoplasty or no chest surgery
 - Age ≥ 25
 - High-risk ($\geq 20\%$ lifetime risk)
- Annual Ultrasound and/or MRI Breast, in addition to mammogram, for breast cancer screening is **NOT** indicated in any other scenarios, including **ANY** of the following:
 - Transfeminine (male-to-female)
 - Transmasculine (female-to-male), who have had bilateral mastectomies
 - Transmasculine (female-to-male), who have **NOT** had mastectomies **AND** are at average risk or intermediate risk
- Acceptable models of calculating clinical lifetime-risk include the following: Gail (NCI), Claus, Tyrer-Cuzick (IBIS), or BRCAPRO.

3D Rendering (BR-13)

Guideline

3D Rendering (BR-13.1)

3D Rendering (BR-13.1)

BR.TD.0013.1.A

v2.0.2024

- 3D rendering (CPT® 76376 or CPT® 76377) should **NOT** be used in conjunction with **ANY** 3D mammography code.
- 3D rendering (CPT® 76376 or CPT® 76377) is **NOT** indicated for breast ultrasound. It is commonly requested in conjunction with automated breast ultrasound (ABUS); there is no evidence to support its clinical usefulness.
- 3D rendering (CPT® 76376 or CPT® 76377) should **NOT** be used in conjunction with MRI Breast.

References (BR)

Guideline

References (BR)

References (BR)

v2.0.2024

1. Sprague BL, Stout NK, Schechter C, et al. Benefits, Harms, and Cost-Effectiveness of Supplemental Ultrasonography Screening for Women with Dense Breasts. *Ann Intern Med*. 2015;162(3):157-166. doi: 10.7326/m14-0692.
2. Mendelson EB, Böhm-Vélez M, Berg WA, et al. ACR BI-RADS® Ultrasound. In: ACR BI-RADS® Atlas, Breast imaging reporting and data system. Reston, VA. *Am Coll Radiol*. 2013.
3. Peters NHGM, Borel Rinkes IHM, Zuithoff NPA, Mali WPTM, Moons KGM, Peeters PHM. Meta-Analysis of MR Imaging in the Diagnosis of Breast Lesions. *Radiology*. 2008;246(1):116-124. doi: 10.1148/radiol.2461061298.
4. Moy L, Elias K, Patel V, et al. Is Breast MRI Helpful in the Evaluation of Inconclusive Mammographic Findings? *AJR Am J Roentgenol*. 2009;193(4):986-993. doi: 10.2214/ajr.08.1229.
5. Pinel-Giroux FM, El Khoury MM, Trop I, Bernier C, David J, Lalonde L. Breast Reconstruction: Review of Surgical Methods and Spectrum of Imaging Findings. *Radiographics*. 2013; 33(2):435-453. doi: 10.1148/rg.332125108.
6. Dorrius MD, Jansen-van der Weide MC, van Ooijen PMA, Pijnappel RM, Oudkerk M. Computer-Aided Detection in Breast MRI: a systematic review and meta-analysis. *Eur Radiol*. 2011;21(8):1600-1608. doi: 10.1007/s00330-011-2091-9.
7. Lehman CD, Blume JD, DeMartini WB, Hylton NM, Herman B, Schnall MD. Accuracy and Interpretation Time of Computer-Aided Detection Among Novice and Experienced Breast MRI Readers. *AJR Am J Roentgenol*. 2013;200(6):W683-W689. doi: 10.2214/ajr.11.8394.
8. Saslow D, Boetes C, Burke W, et al. American Cancer Society Guidelines for Breast Screening with MRI as an Adjunct to Mammography. *CA Cancer J Clin*. 2007;57(2):75-89. doi: 10.3322/canjclin.57.2.75.
9. Emaus MJ, Bakker MF, Peeters PHM, et al. MR Imaging as an Additional Screening Modality for the Detection of Breast Cancer in Women aged 50-75 Years with Extremely Dense Breasts: The DENSE Trial Study Design. *Radiology*. 2015; 277(2):527-537. doi: 10.1148/radiol.2015141827.
10. American College of Obstetricians and Gynecologists. Management of women with dense breasts diagnosed by mammography. Committee Opinion No. 625 American College of Obstetricians and Gynecologists. *Obstet Gynecol*. 2015; 125. <https://www.acog.org/Resources-And-Publications/Committee-Opinions/Committee-on-Gynecologic-Practice/Management-of-Women-With-Dense-Breasts-Diagnosed-by-Mammography#here>.
11. Siu AL. Screening for Breast Cancer: U.S. Preventive Services Task Force Recommendation Statement. *Ann Intern Med*. 2016;164(4):279-296. doi: 10.7326/m15-2886.
12. Sickles EA. ACR Appropriateness Criteria® Breast Cancer Screening. *Breast Diseases: A Year Book Quarterly*. 2013;24(3):233-234. doi: 10.1016/j.breastdis.2013.07.011.
13. McCarthy CM, Pusic AL, Kerrigan CL. Silicone Breast Implants and Magnetic Resonance Imaging Screening for Rupture: Do U.S. Food and Drug Administration Recommendations Reflect an Evidence-Based Practice Approach to Patient Care? *Plast Reconstr Surg*. 2008;121(4):1127-1134. doi: 10.1097/01.prs.0000302498.44244.52.
14. Holmich LR, Vejborg IM, Conrad C, et al. Untreated Silicone Breast Implant Rupture. *Plast Reconstr Surg*. 2004;114(1):204-214. doi: 10.1097/01.prs.0000128821.87939.b5.
15. Chaney AW, Pollack A, McNeese MD, et al. Primary treatment of cystosarcoma phyllodes of the breast. *Cancer*. 2000;89(7):1502-1511. doi: 10.1002/1097-0142(20001001)89:7<1502::aid-cnrc13>3.0.co;2-p.
16. Tan H, Zhang S, Liu H, et al. Imaging findings in phyllodes tumors of the breast. *Eur J Radiol*. 2012;81(1):e62-e69. doi: 10.1016/j.ejrad.2011.01.085.
17. National Comprehensive Cancer Network® (NCCN®). NCCN Clinical Practice Guidelines in Oncology (NCCN Guidelines®): Breast Cancer. Version 4.2023. March 23, 2023. Phyllodes Tumor (PHYLL-1-2). Referenced with permission from the NCCN Clinical Practice Guidelines in Oncology (NCCN Guidelines®) for Breast Cancer V.4.2023. ©National Comprehensive Cancer Network, Inc. 2023. All rights reserved. Accessed July 10, 2023. The NCCN Guidelines® and illustrations herein may not be reproduced in any form for any purpose without the express written permission of the NCCN. To view the most recent and complete version of the NCCN Guidelines, go online to NCCN.org.
18. National Comprehensive Cancer Network® (NCCN®). NCCN Clinical Practice Guidelines in Oncology (NCCN Guidelines®): Breast Cancer Risk Reduction. Version 1.2023. October 12, 2022. Referenced with permission from the NCCN Clinical Practice Guidelines in Oncology (NCCN Guidelines®) for Breast Cancer Risk Reduction V.1.2023. ©National Comprehensive Cancer Network, Inc. 2023. All rights reserved. Accessed July 10, 2023. The NCCN Guidelines® and illustrations herein may not be reproduced in any form for any purpose without the express written permission of the NCCN. To view the most recent and complete version of the NCCN Guidelines, go online to NCCN.org.

19. Morris EA, Comstock CE, Lee CH, et al. ACR BI-RADS® Magnetic Resonance Imaging. In: ACR BI-RADS® Atlas, Breast Imaging Reporting and Data System. Reston, VA. *Am Coll Radiol*. 2013.
20. National Comprehensive Cancer Network® (NCCN®). NCCN Clinical Practice Guidelines in Oncology (NCCN Guidelines®): Breast Cancer. Version 4.2023. March 23, 2023. Paget's Disease (PAGET-1-2). National Comprehensive Cancer Network (NCCN) Guidelines Version 2.2022: Breast Cancer. Referenced with permission from the NCCN Clinical Practice Guidelines in Oncology (NCCN Guidelines®) for Breast Cancer V.4.2023. ©National Comprehensive Cancer Network, Inc. 2023. All rights reserved. Accessed July 10, 2023. The NCCN Guidelines® and illustrations herein may not be reproduced in any form for any purpose without the express written permission of the NCCN. To view the most recent and complete version of the NCCN Guidelines, go online to NCCN.org.
21. Lim HS, Jeong SJ, Lee JS, et al. Paget Disease of the Breast: Mammographic, US, and MR Imaging Findings with Pathologic Correlation. *Radiographics*. 2011;31(7): 1973-1987. doi: 10.1148/rg.317115070.22.
22. National Comprehensive Cancer Network® (NCCN®). NCCN Clinical Practice Guidelines in Oncology (NCCN Guidelines®): Genetic/Familial High-Risk Assessment: Breast, Ovarian, and Pancreatic. Version 3.2023. February 13, 2023. Referenced with permission from the NCCN Clinical Practice Guidelines in Oncology (NCCN Guidelines®) for Genetic/Familial High-Risk Assessment: Breast, Ovarian, and Pancreatic V.3.2023. ©National Comprehensive Cancer Network, Inc. 2023. All rights reserved. Accessed July 10, 2023. The NCCN Guidelines® and illustrations herein may not be reproduced in any form for any purpose without the express written permission of the NCCN. To view the most recent and complete version of the NCCN Guidelines, go online to NCCN.org.
23. Lee SJ, Trikha S, Moy L, et al. ACR Appropriateness Criteria® Evaluation of Nipple Discharge. *J Am Coll Radiol*. 2017;14(5):138-153. doi: 10.1016/j.jacr.2017.01.030.
24. Berger N, Luparia A, Di Leo G, et al. Diagnostic Performance of MRI versus Galactography in Women with Pathologic Nipple Discharge: A Systematic Review and Meta-Analysis. *AJR Am J Roentgenol*. 2017;209(2):465-471. doi: 10.2214/ajr.16.16682.
25. Bahl M, Gadd MA, Lehman CD. Diagnostic utility of MRI after negative or inconclusive mammography for the evaluation of pathologic nipple discharge. *AJR Am J Roentgenol*. 2017; 209(6):1404-1410. doi: 10.2214/AJR.17.18139.
26. Morrogh M, Morris EA, Liberman L, Borgen PI, King TA. The Predictive Value of Ductography and Magnetic Resonance Imaging in the Management of Nipple Discharge. *Ann Surg Oncol*. 2007;14(12):3369-3377. doi: 10.1245/s10434-007-9530-5.
27. Berg WA. Nuclear Breast Imaging: Clinical Results and Future Directions. *J Nucl Med*. 2016;57(Supplement_1):46S-52S. doi: 10.2967/jnumed.115.157891.
28. Lee CH, Dershaw DD, Kopans D, et al. Breast cancer screening with imaging: recommendations from the Society of Breast Imaging and the ACR on the use of mammography, breast MRI, breast ultrasound, and other technologies for the detection of clinically occult breast cancer. *J Am Coll Radiol*. 2010; 7(1):18-27. doi: 10.1016/j.jacr.2009.09.022.
29. Monticciolo DL, Newell MS, Moy L, Niell B, Monsees B, Sickles EA. Breast Cancer Screening in Women at Higher-Than-Average Risk: Recommendations From the ACR. *J Am Coll Radiol*. 2018;15(3):408-414. doi: 10.1016/j.jacr.2017.11.034.30.
30. National Comprehensive Cancer Network® (NCCN®). NCCN Clinical Practice Guidelines in Oncology (NCCN Guidelines®): Breast Cancer Screening and Diagnosis. Version 1.2023. June 19, 2023. Referenced with permission from the NCCN Clinical Practice Guidelines in Oncology (NCCN Guidelines®) for Breast Cancer Screening and Diagnosis V.1.2023. ©National Comprehensive Cancer Network, Inc. 2023. All rights reserved. Accessed July 10, 2023. The NCCN Guidelines® and illustrations herein may not be reproduced in any form for any purpose without the express written permission of the NCCN. To view the most recent and complete version of the NCCN Guidelines, go online to NCCN.org.
31. Golan O, Amitai Y, Barnea Y, Menes TS. Yield of surveillance magnetic resonance imaging after bilateral mastectomy and reconstruction: a retrospective cohort study. *Breast Cancer Res Treat*. 2018;174(2):463-468. doi: 10.1007/s10549-018-05077-9.
32. Sanders LM, El-Madany M, Persing A, Mehta A. Use of Contrast-Enhanced MRI in Management of Discordant Core Biopsy Results. *AJR Am J Roentgenol*. 2019;212(5):1157-1165. doi: 10.2214/ajr.18.20157.
33. Sanders LM. Breast MRI in the management of the discordant-benign core biopsy. *Diagn Imaging Eur*. 2019;35(5):13-16.
34. ACR Practice Parameter for the Performance of Contrast-Enhanced Magnetic Resonance Imaging (MRI) of the Breast. Revised 2018. (Resolution 34). <https://www.acr.org/-/media/ACR/Files/Practice-Parameters/mr-contrast-breast.pdf>.
35. Diflorio-Alexander RM, Slanetz PJ, Moy L, et al. ACR Appropriateness Criteria® Breast Imaging of Pregnant and Lactating Women. *J Am Coll Radiol*. 2018;15(11). doi: 10.1016/j.jacr.2018.09.013.

36. Children's Oncology Group. Long-term follow up guidelines for survivors of childhood, adolescent and young adult cancers, version 5.0. Monrovia, CA: Children's Oncology Group; October 2018; 90. http://www.survivorshipguidelines.org/pdf/2018/COG_LTFU_Guidelines_v5.pdf.
37. Boone JM, Kwan ALC, Yang K, Burkett GW, Lindfors KK, Nelson TR. Computed Tomography for Imaging the Breast. *J Mammary Gland Biol Neoplasia*. 2006;11(2):103-111. doi: 10.1007/s10911-006-9017-1.
38. Boone JM, Nelson TR, Lindfors KK, Seibert JA. Dedicated Breast CT: Radiation Dose and Image Quality Evaluation. *Radiology*. 2001;221(3):657-667. doi: 10.1148/radiol.2213010334.
39. Diekmann F. Contrast-enhanced Dedicated Breast CT. *Radiology*. 2011;258(2):650-650. doi:10.1148/radiol.101761
40. Glick SJ. Breast CT. *Annu Rev Biomed Eng*. 2007;9(1):501-526. doi: 10.1146/annurev.bioeng.9.060906.151924.
41. Hendrick RE. Radiation Doses and Cancer Risks from Breast Imaging Studies. *Radiology*. 2010;257(1):246-253. doi:10.1148/radiol.10100570.
42. Lindfors KK, Boone JM, Nelson TR, Yang K, Kwan ALC, Miller DF. Dedicated Breast CT: Initial Clinical Experience. *Radiology*. 2008; 246:725-733.
43. Prionas ND, Lindfors KK, Ray S, et al. Contrast-enhanced Dedicated Breast CT: Initial Clinical Experience. *Radiology*. 2010;256(3):714-723. doi: 10.1148/radiol.10092311.
44. Aminololama-Shakeri S, Abbey CK, Gazi P, et al. Differentiation of ductal carcinoma in-situ from benign micro-calcifications by dedicated breast computed tomography. *Eur J Radiol*. 2016;85(1):297-303. doi: 10.1016/j.ejrad.2015.09.020.
45. Aminololama-Shakeri S, Abbey CK, López JE, et al. Conspicuity of suspicious breast lesions on contrast enhanced breast CT compared to digital breast tomosynthesis and mammography. *Br J Radiol*. 2019;92(1097):20181034. doi: 10.1259/bjr.20181034.
46. Aminololama-Shakeri S, Hargreaves JB, Boone JM, Lindfors KK. Dedicated Breast CT: Screening Technique of the Future. *Curr Breast Cancer Rep*. 2016;8(4):242-247. doi: 10.1007/s12609-016-0227-2.
47. Heller SL, Lourenco AP, Niell BL, et al. ACR Appropriateness Criteria® Imaging After Mastectomy and Breast Reconstruction. *J Am Coll Radiol*. 2020;17(11S):S403-S414. doi: 10.1016/j.jacr.2020.09.009.
48. Mainiero MB, Moy L, Baron P, et al. ACR Appropriateness Criteria® Breast Cancer Screening. *J Am Coll Radiol*. 2017;14(11S):S383-S390. doi: 10.1016/j.jacr.2017.08.044.
49. Lewin AA, Moy L, Baron P, et al. ACR Appropriateness Criteria® Stage I Breast Cancer: Initial Workup and Surveillance for Local Recurrence and Distant Metastases in Asymptomatic Women. *J Am Coll Radiol*. 2019;16(11S):S428-S439. doi: 10.1016/j.jacr.2019.05.024.
50. Holbrook AI, Moy L, Akin EA, et al. ACR Appropriateness Criteria® Breast Pain. *J Am Coll Radiol*. 2018;15(11S):S276-S282. doi: 10.1016/j.jacr.2018.09.014.
51. Lourenco AP, Moy L, Baron P, et al. ACR Appropriateness Criteria® Breast Implant Evaluation. *J Am Coll Radiol*. 2018;15(5S):S13-S25. doi:10.1016/j.jacr.2018.03.009
52. Weinstein SP, Slanetz PJ, Lewin AA, et al. ACR Appropriateness Criteria® Supplemental Breast Cancer Screening Based on Breast Density. *J Am Coll Radiol*. 2021;18(11S):S456-S473. doi: 10.1016/j.jacr.2021.09.002.
53. Brown A, Lourenco AP, Niell BL, et al. ACR Appropriateness Criteria® Transgender Breast Cancer Screening. *J Am Coll Radiol*. 2021;18(11S):S502-S515. doi: 10.1016/j.jacr.2021.09.005.
54. Kanoi AV, Panchal KB, Sen S, Biswas G. Computed tomography angiographic study of internal mammary perforators and their use as recipient vessels for free tissue transfer in breast reconstruction. *Indian J Plast Surg*. 2017;50(01):050-055. doi: 10.4103/ijps.ijps_168_16.
55. Paetau AA, McLaughlin SA, McNeil RB, et al. Capsular Contracture and Possible Implant Rupture: Is Magnetic Resonance Imaging Useful? *Plast Reconstr Surg*. 2010 Mar;125(3):830-5. doi: 10.1097/PRS.0b013e3181cb6066.
56. ACR Practice Parameter for the Performance of Molecular Breast Imaging (MBI) Using a Dedicated Gamma Camera. Revised 2022. (Resolution 42). <https://www.acr.org/-/media/ACR/Files/Practice-Parameters/MBI.pdf>.

Table of Contents

Guideline

General Information

General Information

General Guidelines (CD-1.0)

Stress Testing

Stress Testing without Imaging – Procedures (CD-1.2)

Stress Testing with Imaging – Procedures (CD-1.3)

Stress Testing with Imaging - Indications (CD-1.4)

Stress Testing with Imaging – Preoperative (CD-1.5)

Transplant (CD-1.6)

References (CD-1)

Echocardiography (ECHO)

Transthoracic Echocardiogram (TTE) - Coding (CD-2.1)

Transthoracic Echocardiography (TTE) Indications/initial evaluation (CD-2.2)

Frequency of Echocardiography Testing (CD-2.3)

References

Transesophageal Echocardiography (TEE) (CD-2.4) (CD-2.5)

Stress echocardiography (stress echo) (CD-2.6) (CD-2.7)

3D Echocardiography (CD-2.8)(CD-2.9)

Myocardial strain imaging (CPT® 93356) (CD-2.12)

References (CD-2)

Nuclear Cardiac Imaging

Myocardial Perfusion Imaging (MPI)(CD-3.1)(CD-3.2)

MUGA – Coding (CD-3.3)

MUGA Study – Cardiac Indications (CD-3.4)

Myocardial Sympathetic Innervation Imaging in Heart Failure (CD-3.6)

Myocardial Tc-99m Pyrophosphate Imaging (CD-3.7)

Cardiac Amyloidosis (CD-3.8)

Non-imaging Heart Function and Cardiac Shunt Imaging (CD-1.7)

References (CD-3)

Cardiac CT

Cardiac CT and CTA - General information and coding (CD-4.1)

CT for Coronary Calcium Scoring (CD-4.2)

CCTA – Indications for CCTA (CD-4.3)

CCTA – Regardless of symptoms (CD-4.4)
Fractional Flow Reserve by Computed Tomography (CD-4.5)
CT Heart – Indications (CPT® 75572) (CD-4.6)
CT Heart for Congenital Heart Disease (CD-4.7)
Transcatheter aortic valve replacement (TAVR) (CD-4.8)
3D Predictive model generation for pre-planning of cardiac procedure (CD-4.9)
References (CD-4)

Cardiac MRI

Cardiac MRI – Coding (CD-5.1)
Cardiac MRI and MRA Chest – Indications (excluding Stress MRI) (CD-5.2)
Cardiac MRI – Indications for Stress MRI (CD-5.3)
Cardiac MRI – Aortic Root and Proximal Ascending Aorta (CD-5.4)
Cardiac MRI – Evaluation of Pericardial Effusion or Diagnosis of Pericardial Tamponade (CD-5.5)
Cardiac MRI – Myocarditis (CD-5.6)
Cardiac MRI – Duchenne Muscular Dystrophy (DMD) (CD-5.7)
References (CD-5)

Cardiac PET

Cardiac PET – Coding (CD-6.1)
Cardiac PET – Perfusion – Indications (CD-6.2)
Cardiac PET – Absolute Quantitation of Myocardial Blood Flow (AQMBF) (CD-6.3)
References
Cardiac PET – Metabolic – Indications (CD-6.4)
FDG PET/CT for infections (CD-6.5)
References (CD-6)

Diagnostic Heart Catheterization

Diagnostic Heart Catheterization – Coding (CD-7.1) (CD-7.2)
LHC – Unstable/Active Coronary Artery Syndromes (CD-7.3.1)
Diagnostic Left Heart Catheterization (LHC) (CD-7.3)
Right Heart Catheterization and Right and Left Heart Catheterization without Coronary Angiography (CD-7.4)
Combined Right and Left Heart Catheterization Indications (CD-7.5)
Planned (Staged) Procedures (CD-7.6)
Evaluation of Conditions other than Coronary Artery Disease (CD-7.7)
References (CD-7)

Adult Congenital Heart Disease

Congenital heart disease – General Information (CD-11.1)

ASD-Atrial septal defects (CD-11.2.1)
Anomalous Pulmonary Venous Connections (CD-11.2.2)
Ventricular Septal Defect (VSD) (CD-11.2.3)
Atrioventricular Septal Defect (AV Canal, AVSD, endocardial cushion defect) (CD-11.2.4)
Patent Ductus Arteriosus (PDA) (CD-11.2.5)
Cor Triatriatum (CD-11.2.6)
Congenital Mitral Stenosis (CD-11.2.7)
Subaortic Stenosis (SAS) (CD-11.2.8)
Congenital Valvular Aortic Stenosis (CD-11.2.9)
Aortic disease in Turner Syndrome (CD-11.2.10)
Supravalvular Aortic Stenosis (CD-11.3.1)
Coarctation of the Aorta (CD-11.3.2)
Valvular Pulmonary Stenosis (CD-11.3.3)
Branch and Peripheral pulmonary stenosis (CD-11.3.4)
Double chambered RV (CD-11.3.5)
Ebstein Anomaly (CD-11.3.6)
Tetralogy of Fallot (TOF, VSD with PS) (CD-11.3.7)
Right Ventricle-to-Pulmonary Artery Conduit (CD-11.3.8)
Transposition of the great arteries (TGA) (CD-11.3.9)
Congenitally corrected TGA (CD-11.3.10)
Fontan Palliation of Single Ventricle Physiology (CD-11.3.11)
Severe Pulmonary artery hypertension (PHT) and Eisenmenger syndrome (CD-11.3.12)
Coronary artery anomalies (CD-11.3.13)
Pregnancy – Maternal Imaging (CD-11.4)
References (CD-11)

Maternal Imaging in Cardiovascular Disease

Diagnostic Cardiovascular Imaging Pre-Pregnancy to Post-Partum (CD-15.1)
Maternal imaging in cardiovascular disease (CD-15.2)
Maternal Imaging in Individuals with Aortopathy (CD-15.3)
Imaging in Pregnancy with Congenital Heart Disease (CHD) (CD-15.4)

Condition Specific Imaging

Cardiotoxic Agent-Related Cardiac Dysfunction (CD-12)
Cardiac Sarcoidosis (CD-3.9)
Cardiac Trauma Imaging (CD-10.1)
Congestive Heart Failure (CD-9)
Pre-Surgical Cardiac Testing (CD-13)
Pulmonary Hypertension (PH) (CD-8.1)
Pulmonary Vein Imaging – Indications (CD-8.2)

Hypertrophic Cardiomyopathy (HCM) (CD-14)

General Information

Guideline

General Information
General Guidelines (CD-1.0)

General Information

v2.1.2024

Abbreviations for the Cardiac Imaging Guidelines

Abbreviation	Description
ACC	American College of Cardiology
ACS	acute coronary syndrome
AHA	American Heart Association
ASCOT	Anglo-Scandinavian Cardiac Outcomes Trial
ASD	atrial septal defect
BMI	body mass index
CABG	coronary artery bypass grafting
CAD	coronary artery disease
CAD-RADS	The Coronary Artery Disease Reporting and Data System
CHF	congestive heart failure
COPD	chronic obstructive pulmonary disease
CT	computed tomography
CCTA	coronary computed tomography angiography
CTA	computed tomography angiography
EBCT	electron beam computed tomography
ECP	external counterpulsation (also known as EECP)
ECG	electrocardiogram
ECP	external counterpulsation
ETT	exercise treadmill stress test
FDG	Fluorodeoxyglucose, a radiopharmaceutical used to measure myocardial metabolism
HCM	hypertrophic cardiomyopathy
IV	intravenous
LAD	left anterior descending coronary artery
LDL-C	low density lipoprotein cholesterol
LHC	left heart catheterization
LV	left ventricle

Abbreviation	Description
LVEF	left ventricular ejection fraction
MI	myocardial infarction
MPI	myocardial perfusion imaging (SPECT study, nuclear cardiac study)
MRA	magnetic resonance angiography
MRI	magnetic resonance imaging
mSv	millisievert (a unit of radiation exposure) equal to an effective dose of a joule of energy per kilogram of recipient mass
MUGA	multi gated acquisition scan of the cardiac blood pool
PCI	percutaneous coronary intervention (includes percutaneous coronary angioplasty (PTCA) and coronary artery stenting)
PET	positron emission tomography
PTCA	percutaneous coronary angioplasty
RHC	right heart catheterization
SPECT	single photon emission computed tomography
TEE	transesophageal echocardiogram
TIA	Transient Ischemic Attack
VSD	ventricular septal defect

Glossary

Agatston Score: a nationally recognized calcium score for the coronary arteries based on Hounsfield units and size (area) of the coronary calcium
Angina: principally chest discomfort, exertional (or with emotional stress) and relieved by rest or nitroglycerin
Anginal variants or equivalents: a manifestation of myocardial ischemia which is perceived by individuals to be (otherwise unexplained) dyspnea, unusual fatigue, more often seen in females and may be unassociated with chest pain
ARVD/ARVC – Arrhythmogenic Right Ventricular Dysplasia/Cardiomyopathy: a potentially lethal inherited disease with syncope and rhythm disturbances, including sudden death, as presenting manifestations
BNP: B-type natriuretic peptide, blood test used to diagnose and track heart failure (n-T-pro-BNP is a variant of this test)
Brugada Syndrome: an electrocardiographic pattern that is unique and might be a marker for significant life-threatening dysrhythmias

Double Product (Rate Pressure Product): an index of cardiac oxygen consumption, is the systolic blood pressure times heart rate, generally calculated at peak exercise; over 25000 means an adequate stress load was performed
Fabry’s Disease: an infiltrative cardiomyopathy, can cause heart failure and arrhythmias
Fatigue: a subjective feeling of weakness, tiredness or exhaustion. Exertional fatigue is acute in nature, with rapid onset, short duration, and short recovery period.
Hibernating myocardium: viable but poorly functioning or non-functioning myocardium which likely could benefit from intervention to improve myocardial blood supply
Optimized Medical Therapy: should include (where tolerated) antiplatelet agents, calcium channel antagonists, partial fatty acid oxidase inhibitors (e.g. ranolazine), statins, short-acting nitrates as needed, long-acting nitrates up to 6 months after an acute coronary syndrome episode, beta blocker drugs (optional), angiotensin-converting enzyme (ACE) inhibitors/angiotensin receptor blocking (ARB) agents (optional)
Platypnea: shortness of breath when upright or seated (the opposite of orthopnea) and can indicate cardiac malformations, shunt or tumor
Silent ischemia: absence of ischemic symptoms or signs prior to objective demonstration of ischemia by stress testing and/or demonstration of obstructive CAD
Syncope: loss of consciousness; near-syncope is <u>not</u> syncope
Takotsubo cardiomyopathy: apical dyskinesia oftentimes associated with extreme stress and usually thought to be reversible
Troponin: a marker for ischemic injury, primarily cardiac

Practice Estimate of Effective Radiation Dose chart for Selected Imaging Studies

Imaging Study	Estimate of Effective Radiation Dose
Sestamibi myocardial perfusion study (MPI)	9-12 mSv
PET myocardial perfusion study:	3 mSv
Rubidium-82	2 mSv
NH3	
Thallium myocardial perfusion study (MPI)	22-31 mSv
Diagnostic conventional coronary angiogram (cath)	5-10 mSv

Imaging Study	Estimate of Effective Radiation Dose
Computed tomography coronary angiography (CTCA) (with prospective gating)	5-15 mSv Less than 5 mSv
CT Abdomen and Pelvis	8-14 mSv
Chest x-ray	<0.1 mSv

General Guidelines (CD-1.0)

CD.GG.0001.0.A

v2.1.2024

- A current clinical evaluation (within 60 days) is required prior to considering advanced imaging, which includes:
 - Relevant history and physical examination and appropriate laboratory studies and non-advanced imaging modalities, such as recent ECG (within 60 days), chest x-ray or ECHO/ultrasound, after symptoms started or worsened.
 - Effort should be made to obtain copies of reported “abnormal” ECG studies in order to determine whether the ECG is uninterpretable for ischemia on ETT
 - Most recent previous stress testing and its findings should be obtained
 - Other meaningful contact (telephone call, electronic mail or messaging) by an established individual can substitute for a face-to-face clinical evaluation.
 - A recent clinical evaluation documenting any subjective findings (complaints, changes in behavior) or objective findings (clinical exam findings).
 - Other meaningful contact (telephone call, electronic mail or messaging) by an established individual can substitute for a face-to-face clinical evaluation such as requests based on new increased or worsening symptoms (within the last 60 days).
 - Some conditions may require a face to face evaluation as discussed in the applicable condition -specific guideline sections (such as requests based on new physical exam findings).
 - A recent clinical evaluation may be unnecessary if the individual is undergoing a guideline -supported, scheduled follow -up imaging or other designated procedural evaluation.
 - Exceptions due to routine surveillance indications are addressed in the applicable condition -specific guideline sections
 - Vital signs, height and weight, or BMI, or description of general habitus is needed.
 - Clinical question to be answered by advanced imaging that will affect management of the individual’s clinical condition.
- Cardiac imaging is not indicated if the results will not affect clinical management decisions. If a decision to perform cardiac catheterization or other angiography has already been made, there is often no need for imaging stress testing
- Assessment of ischemic symptoms (if present) based on the descriptions below following this section.

Ischemic evaluation

- For the purposes of guideline sections addressing ischemic evaluation, symptoms can be defined as the following:
 - **Cardiac chest pain/pressure/tightness**¹ (likely anginal symptoms): Chest/epigastric/shoulder/ arm/jaw pain, chest pressure/discomfort occurring with exertion or emotional stress and relieved by rest, nitroglycerin, or both.
 - **Less-likely anginal symptoms:** Symptoms including dyspnea or fatigue when not exertional and not relieved by rest/nitroglycerin; also includes generalized fatigue or chest discomfort occurring in a time course not suggestive of angina (eg, resolves spontaneously within seconds or lasts for an extended period and is unrelated to exertion)
 - **Noncardiac explanation:** An alternative diagnosis, such as gastroesophageal reflux, chest trauma, anemia, chronic obstructive pulmonary disease, or pleurisy, is present and is the most likely explanation for the patient's symptoms
 - **Anginal equivalents** (individuals with previously documented CAD only):
 - Symptoms consistent with individual's known angina pattern in an individual with a history of CABG or PCI
 - Dyspnea on exertion
 - Fatigue (overwhelming sense of exhaustion causing a decreased capacity for physical activity or mental work)
- Other signs and symptoms suggestive of potential cardiac etiology:
 - Dyspnea
 - Orthopnea
 - Paroxysmal nocturnal dyspnea
 - Heartburn unrelated to meals/nausea and vomiting
 - Palpitations
 - Syncope
 - Heart failure
- Chest pain remains the predominant symptom reported by females among those diagnosed with an acute coronary syndrome.
- For the purpose of this guideline, evidence documenting the presence of CAD includes any of the following:
 - Prior heart catheterization or CCTA revealing any of the following:
 - $\geq 40\%$ stenosis of the left main coronary artery
 - $\geq 50\%$ stenosis for other coronary arteries
 - Significant stenosis defined by an FFR of ≤ 0.80
 - History of a prior PCI or CABG

¹ Multimodality Writing Group for Chronic Coronary Disease, Winchester DE, Maron DJ, et al. ACC/AHA/ASE/ASNC/ASPC/HFSA/HRS/SCAI/SCCT/SCMR/STS 2023 Multimodality Appropriate Use Criteria for the Detection and Risk Assessment of Chronic Coronary Disease. J Am Coll Cardiol. 2023;81(25):2445-2467. doi:10.1016/j.jacc.2023.03.411.

- For the purpose of this guideline, evidence documenting the presence of non-obstructive CAD includes prior heart catheterization or CCTA revealing any of the following:
 - <40% stenosis of the left main coronary artery
 - <50% stenosis for other coronary arteries
 - FFR >0.8
- The Coronary Artery Disease Reporting and Data System (CAD-RADS) classification of percentage luminal diameter coronary artery stenosis on coronary CT angiography (CCTA)² is as follows:
 - CAD-RADS 0: 0%
 - CAD-RADS 1: 1 to 24%
 - CAD-RADS 2: 25 to 49%
 - CAD-RADS 3: 50 to 69%
 - CAD-RADS 4: 70 to 99% or ≥50% left main coronary artery stenosis
 - CAD-RADS 5: 100% (total occlusion)
- For the purposes of this guideline, evidence documenting a prior MI includes any of the following:
 - Presence of diagnostic Q waves on an ECG
 - A fixed perfusion defect on MPI
 - Akinetic or dyskinetic wall motion on echocardiogram
 - Area of Late Gadolinium Enhancement (LGE) on cardiac MRI suggesting scar
- Findings that may alter the ECG changes during exercise or are uninterpretable for ischemia on a stress test:
 - Complete Left Bundle Branch Block (bifascicular block involving right bundle branch and left anterior hemiblock does not render ECG uninterpretable for ischemia)
 - Ventricular paced rhythm
 - Pre-excitation pattern such as Wolff-Parkinson-White
 - ≥1.0 mm ST segment depression (NOT nonspecific ST/T wave changes)
 - LVH with repolarization abnormalities, also called LVH with strain (NOT without repolarization abnormalities or by voltage criteria)
 - T wave inversion in at least two contiguous inferior and/or lateral leads. This includes leads II, AVF, V5 or V6. (T wave inversion isolated in lead III or T wave inversion in lead V1 and V2 are not included).
 - Individual on digitalis preparation

References (CD-1)

1. Fihn SD, Gardin JM, Abrams J, et al. 2012 ACCF/AHA/ACP/AATS/PCNA/SCAI/STS Guideline for the Diagnosis and Management of Patients with Stable Ischemic Heart Disease: Executive Summary. *Circulation*. 2012;126(25):3097-3137. doi:10.1161/cir.0b013e3182776f83.

² Fletcher GF, Ades PA, Kligfield P, et al. Exercise standards for testing and training: a scientific statement from the American Heart Association. *Circulation*. 2013;128(8):873-934. doi:10.1161/CIR.0b013e31829b5b44.

2. Qaseem A, Fihn SD, Williams S, et al. A. Diagnosis of Stable Ischemic Heart Disease: Summary of a Clinical Practice Guideline from the American College of Physicians/American College of Cardiology Foundation/American Heart Association/American Association for Thoracic Surgery/Preventive Cardiovascular Nurses Association/Society of Thoracic Surgeons. *Annals of Internal Medicine*. 2012;157(10):729. doi:10.7326/0003-4819-157-10-201211200-00010.
3. Rybicki FJ, Udelson JE, Peacock WF, et al. 2015 ACR/ACC/AHA/AATS/ACEP/ASNC/NASCI/SAEM/SCCT/SCMR/SCPC/SNMMI/STR/STS Appropriate Utilization of Cardiovascular Imaging in Emergency Department Patients with Chest Pain. *J Am Coll Cardiol*. 2016;67(7):853-879. doi:10.1016/j.jacc.2015.09.011.
4. Fleisher LA, Fleischmann KE, Auerbach AD, et al. 2014 ACC/AHA Guideline on Perioperative Cardiovascular Evaluation and Management of Patients Undergoing Noncardiac Surgery. *J Am Coll Cardiol*. 2014;64(22):e77-e137. doi:10.1016/j.jacc.2014.07.944.
5. Ho PM, Rumsfeld JS, Peterson PN. Chest pain on exercise treadmill test predicts future cardiac hospitalizations. *Clin Cardiol* 2007; 30:505-510. doi:10.1002/clc.20139.
6. Sechtem U. Do heart transplant recipients need annual coronary angiography? *Eu Heart J* 2001; 22:895–897. doi:10.1053/euhj.2001.2660.
7. Tavel ME. Stress testing in cardiac evaluation: Current concepts with emphasis on the ECG. *Chest* 2001; 119:907-925. doi:10.1378/chest.119.3.907.
8. Wolk MJ, Bailey SR, Doherty JU, et al. ACCF/AHA/ASE/ASNC/HFSA/HRS/SCAI/SCCT/SCMR/STS. 2013 Multi-modality appropriate use criteria for the detection and risk assessment of stable ischemic heart disease: a report of the American College of Cardiology Foundation, Appropriate Use Criteria Task Force, American Heart Association, American Society of Echocardiography, American Society of Nuclear Cardiology, Heart Failure Society of America, Heart Rhythm Society, Society for Cardiovascular Angiography and Interventions, Society of Cardiovascular Computed Tomography, Society for Cardiovascular Magnetic Resonance, and Society of Thoracic Surgeons. *J Am Coll Cardiol* 2014; 63: forthcoming. doi:10.1016/j.jacc.2013.11.009.
9. Blank P, Scheopf UJ, Leipsic JA. CT in transcatheter aortic valve replacement. *Radiology*, 2013; 269(3). doi:10.1148/radiol.13120696.
10. Leipsic JA, Blanke P, Hanley M, et al. ACR Appropriateness Criteria® Imaging for Transcatheter Aortic Valve Replacement. *J Am Coll Radiol*. 2017;14(11). doi:10.1016/j.jacr.2017.08.046.
11. Mieres JH, Gulati M, Bairey Merz N, et al. American Heart Association Cardiac Imaging Committee of the Council on Clinical Cardiology, Cardiovascular Imaging and Intervention Committee of the Council on Cardiovascular Radiology. Role of Noninvasive Testing in the Clinical Evaluation of Women with Suspected Ischemic Heart Disease A Consensus Statement from the American Heart Association. *Circulation*. 2014; 130(4):350. doi:10.1161/CIR.0000000000000061.
12. American College of Cardiology Foundation Appropriate Use Criteria Task Force, American Society of Echocardiography, American Heart Association, et al. ACCF/ASE/AHA/ASNC/HFSA/HRS/SCAI/SCCM/SCCT/SCMR 2011 Appropriate Use Criteria for Echocardiography. A Report of the American College of Cardiology Foundation Appropriate Use Criteria Task Force, American Society of Echocardiography, American Heart Association, American Society of Nuclear Cardiology, Heart Failure Society of America, Heart Rhythm Society, Society for Cardiovascular Angiography and Interventions, Society of Critical Care Medicine, Society of Cardiovascular Computed Tomography, and Society for Cardiovascular Magnetic Resonance Endorsed by the American College of Chest Physicians. *J Am Coll Cardiol* 2011; 57:1126. doi:10.1016/j.echo.2010.12.008.
13. Melon CC, Eshtiaghi P, Luksun WJ, et al. Validated questionnaire vs physicians' judgment to estimate preoperative exercise capacity. *JAMA Intern Med* 2014; 174:1507. doi:10.1001/jamainternmed.2014.2914.
14. Taqueti V, Dorbala S, Wolinsky D. Myocardial perfusion imaging in women for the evaluation of stable ischemic heart disease— state-of-the-evidence and clinical recommendations. *Journal of Nuclear Cardiology*. June 2017. doi.org/10.1007/s12350-017-0926-8.
15. Chamberlain JJ, Johnson EL, Leal S, et al. Cardiovascular Disease and Risk Management: Review of the American Diabetes Association Standards of Medical Care in Diabetes 2018. *Annals of Internal Medicine*. 2018;168(9):640. doi:10.7326/m18-0222.
16. Bateman TM, Dilsizian V, Beanlands RS, Depuey EG, Heller GV, Wolinsky DA. American Society of Nuclear Cardiology and Society of Nuclear Medicine and Molecular Imaging Joint Position Statement on the Clinical Indications for Myocardial Perfusion PET. *Journal of Nuclear Medicine*. 2016;57(10):1654-1656. doi:10.2967/jnumed.116.180448.
17. U.S. Food and Drug Administration. PROLEUKIN® (aldesleukin) for injection, for intravenous infusion. U.S. Food and Drug Administration Website. <https://www.accessdata.fda.gov>.
18. Gulati M, Levy PD, Mukherjee D, et al. 2021 AHA/ACC/ASE/CHEST/SAEM/SCCT/SCMR Guideline for the Evaluation and Diagnosis of Chest Pain: A Report of the American College of Cardiology/American Heart Association Joint Committee on Clinical Practice Guidelines [published correction appears in *Circulation*. 2021 Nov 30;144(22):e455]. *Circulation*. 2021;144(22):e368-e454. doi:10.1161/CIR.0000000000001029.

19. Kidney Disease: Improving Global Outcomes (KDIGO) Kidney Transplant Candidate Work Group. KDIGO Clinical Practice Guideline on the Evaluation and Management of Candidates for Kidney Transplantation. *Transplantation*. 2020;104: S1 – S103.
20. Wenger NK, Lloyd-Jones DM, Elkind MSV, et al. Call to Action for Cardiovascular Disease in Women: Epidemiology, Awareness, Access, and Delivery of Equitable Health Care: A Presidential Advisory From the American Heart Association. *Circulation*. 2022;145(23):e1059-e1071. doi:10.1161/CIR.0000000000001071.
21. Fleisher LA, Fleischmann KE, Auerbach AD, et al. 2014 ACC/AHA guideline on perioperative cardiovascular evaluation and management of patients undergoing noncardiac surgery: a report of the American College of Cardiology/American Heart Association Task Force on Practice Guidelines. *Circulation*. 2014;130(24):e278-e333. doi:10.1161/CIR.000000000000106.
22. Schwarze ML, Barnato AE, Rathouz PJ, et al. Development of a List of High-Risk Operations for Patients 65 Years and Older. *JAMA Surg*. 2015;150(4):325–331. doi:10.1001/jamasurg.2014.1819.
23. Cury RC, Leipsic J, Abbara S, et al. CAD-RADS™ 2.0 - 2022 Coronary Artery Disease-Reporting and Data System: An Expert Consensus Document of the Society of Cardiovascular Computed Tomography (SCCT), the American College of Cardiology (ACC), the American College of Radiology (ACR), and the North America Society of Cardiovascular Imaging (NASCI). *J Cardiovasc Comput Tomogr*. 2022;16(6):536-557. doi:10.1016/j.jcct.2022.07.002.
24. Fletcher GF, Ades PA, Kligfield P, et al. Exercise standards for testing and training: a scientific statement from the American Heart Association. *Circulation*. 2013;128(8):873-934. doi:10.1161/CIR.0b013e31829b5b44.
25. Multimodality Writing Group for Chronic Coronary Disease, Winchester DE, Maron DJ, et al. ACC/AHA/ASE/ASNC/ASPC/HFSA/HRS/SCAI/SCCT/SCMR/STS 2023 Multimodality Appropriate Use Criteria for the Detection and Risk Assessment of Chronic Coronary Disease. *J Am Coll Cardiol*. 2023;81(25):2445-2467. doi:10.1016/j.jacc.2023.03.410.
26. Cohn PF, Fox KM, Daly C. Silent myocardial ischemia. *Circulation*. 2003 Sep 9;108(10):1263-77. doi: 10.1161/01.CIR.0000088001.59265.EE.

Stress Testing

Guideline

Stress Testing without Imaging – Procedures (CD-1.2)

Stress Testing with Imaging – Procedures (CD-1.3)

Stress Testing with Imaging - Indications (CD-1.4)

Stress Testing with Imaging – Preoperative (CD-1.5)

Transplant (CD-1.6)

References (CD-1)

Stress Testing without Imaging – Procedures (CD-1.2)

CD.ST.0001.2.A

v2.1.2024

The Exercise Treadmill Test (ETT) is without imaging.

- Necessary components of an ETT include:
 - ECG that can be interpreted for ischemia.
 - Individual capable of exercise to achieve target heart rate on a treadmill or similar device (5 METs or greater; see functional capacity below). Target heart rate is calculated as 85% of the maximum age predicted heart rate (MPHR). MPHR is estimated as 220 minus the individual's age.
- An abnormal ETT (exercise treadmill test) includes at least one of the following:
 - ST segment depression (horizontal or downsloping, ≥ 1.0 mm below baseline)
 - Development of chest pain
 - Drop in systolic blood pressure >10 mmHg during exercise
 - Non-sustained ventricular tachycardia ≥ 3 consecutive ventricular beats at a rate of >100 beats per minute
 - Sustained ventricular tachycardia (ventricular rhythm at rate >100 beats/minute lasting >30 seconds or requiring termination due to hemodynamic compromise in <30 seconds)
- Functional capacity ≥ 5 METs equates to the following:
 - Can walk four blocks without stopping
 - Can walk up a hill
 - Can climb one flight of stairs without stopping
 - Can perform heavy work around the house
 - Can walk 4 mph at a brisk pace

Background and supporting information

An observational study found that, compared with the Duke Activity Status Index, subjective assessment by clinicians generally underestimated exercise capacity

Upsloping ST segment depression is not considered to be an abnormal ETT finding because of its low specificity.

Stress Testing with Imaging – Procedures (CD-1.3)

CD.ST.0001.3.A

v2.1.2024

- Imaging Stress Tests include any one of the following:
 - Stress Echocardiography see **Stress Echocardiography (Stress Echo) – Coding (CD-2.7)**
 - SPECT MPI see **Myocardial Perfusion Imaging (MPI) – Coding (CD-3.1)**
 - Stress perfusion MRI see **Cardiac MRI – Indications for Stress MRI (CD-5.3)**
 - PET Perfusion see **Cardiac PET-Perfusion-Indications (CD-6.2)**
- Stress testing with imaging can be performed with maximal exercise or chemical stress (adenosine, dipyridamole, dobutamine, or regadenoson) and does not alter the CPT® codes used to report these studies.

Stress Testing with Imaging - Indications (CD-1.4)

CD.ST.0001.4.A

v2.1.2024

Stress echo, SPECT MPI or stress MRI

Codes addressed

Description	CPT®
Cardiac MRI for morphology and function without contrast, with stress imaging	75559
Cardiac MRI for morphology and function without and with contrast, with stress imaging	75563
MPI, tomographic (SPECT) including attenuation correction, qualitative or quantitative wall motion, ejection fraction by first pass or gated technique, additional quantification, when performed); single study, at rest or stress (exercise or pharmacologic)	78451
MPI, tomographic (SPECT) (including attenuation correction, qualitative or quantitative wall motion, ejection fraction by first pass or gated technique, additional quantification, when performed); multiple studies, at rest and/or stress (exercise or pharmacologic) and/or redistribution and/or rest reinjection	78452
Echocardiography (TTE), (2D), with or without m-mode, during rest and cardiovascular stress, with interpretation and report	93350
Echocardiography (TTE), (2D), m-mode, during rest and cardiovascular stress test using treadmill, bicycle exercise and/or pharmacologically induced stress, with interpretation	93351

Stress test with imaging (Stress echo, SPECT MPI, or stress MRI) is indicated for **any** of the following:

Likely anginal symptoms

New, recurrent or worsening likely anginal symptoms as defined in **General Guidelines (CD-1.0)**

Symptomatic with known CAD

Prior history of PCI (percutaneous coronary intervention) or CABG (coronary artery bypass graft surgery) or a history of obstructive CAD as defined in **General Guidelines (CD-1.0)** and **either** of the following:

- Likely anginal symptoms as defined in **General Guidelines (CD-1.0)**
- Symptoms similar to prior ischemic episode

Symptomatic with uninterpretable ECG

New, recurrent, or worsening symptoms of chest pain, or exertional dyspnea, or exertional fatigue and resting ECG is uninterpretable for ischemia due to **any** of the following:

- Complete Left Bundle Branch Block (bifascicular block involving right bundle branch and left anterior hemiblock does not render ECG uninterpretable for ischemia)
- Ventricular paced rhythm
- Pre-excitation pattern such as Wolff-Parkinson-White
- Greater or equal to 1.0 mm ST segment depression (NOT nonspecific ST/T wave changes)
- LVH with repolarization abnormalities, also called LVH with strain (NOT without repolarization abnormalities or by voltage criteria)
- T wave inversion in at least two contiguous inferior and/or lateral leads. This includes leads II, AVF, V5 or V6. (T wave inversion isolated in lead III or T wave inversion in lead V1 and V2 are not included)
- Individual on digitalis preparation

Symptomatic with inconclusive or abnormal ETT or elevated CAC

New, recurrent or worsening symptoms of chest pain, or exertional dyspnea, or exertional fatigue and any of the following:

- Inconclusive ETT (exercise treadmill test) due to any of the following:
 - <85% maximum predicted heart rate achieved
 - Exercise ECG is uninterpretable for ischemia (for example due to development of rate-related left bundle branch block during exercise)
- Abnormal ETT as defined in **Stress Testing without Imaging – Procedures (CD-1.2)**
- Coronary artery calcium (CAC) score ≥ 100

Heart failure or left ventricular systolic dysfunction

Stress test with imaging is indicated to evaluate heart failure or left ventricular systolic dysfunction when there is documentation of **any** of the following:

- New or worsening heart failure
- New left ventricular systolic dysfunction (left ventricular ejection fraction <50%)
- Worsening left ventricular systolic dysfunction (decline in left ventricular ejection fraction $\geq 10\%$)
- Significant ischemic ventricular dysfunction (suspected hibernating myocardium) to assess myocardial viability when there are persistent symptoms or heart failure and revascularization is being considered.

Note MRI, cardiac PET, SPECT MPI, or Dobutamine stress echo can be used to assess myocardial viability depending on physician preference. See also **Cardiac PET – Metabolic – Indications (CD-6.4)**

Syncope or arrhythmia

Stress test with imaging is indicated for **any** of the following:

- Syncope of suspected ischemic etiology not otherwise explained
- Sustained ventricular tachycardia (ventricular rhythm at rate >100 beats/minute lasting >30 seconds or requiring termination due to hemodynamic compromise in <30 seconds).
- Non-sustained ventricular tachycardia ≥ 3 consecutive ventricular beats at rate >100 beats/minute
- Frequent PVCs (premature ventricular contractions) > 30 PVCs per hour
- Prior to starting a Class IC antiarrhythmic agent (flecainide or propafenone) to assess for CAD and annually while taking the medication

With or without symptoms for moderate coronary artery stenosis

Stress test with imaging is indicated to evaluate the functional significance of moderate stenosis when there is documentation of **either** of the following:

- CCTA (coronary computed tomography angiography) with moderate stenosis (50 to 69% - CAD-RADS 3 as defined in **General Guidelines CD-1.0**)
- Invasive coronary angiography with intermediate severity stenosis and invasive physiological testing has not been done

Without symptoms

Stress test with imaging is indicated for any of the following:

- Prior to starting Interleukin-2

- An uninterpretable ECG as described in **General Guidelines (CD 1.0)** that has not been previously evaluated
- Every 2 years if there is a history of silent ischemia (absence of ischemic symptoms or signs prior to objective demonstration of ischemia by stress testing and/or demonstration of obstructive CAD as defined in **General Guidelines (CD-1.0)**
- Prior to starting a Class IC antiarrhythmic agent (flecainide or propafenone) to assess for CAD and annually while taking the medication
- Asymptomatic individual who has an ischemic EKG response on ETT (horizontal or downsloping ST depression ≥ 1.0 mm below baseline).

Cardiac perfusion PET

codes addressed

Description	CPT®
Myocardial imaging, positron emission tomography (PET), perfusion study (including ventricular wall motion[s] and/or ejection fraction[s], when performed); single study, at rest or stress (exercise or pharmacologic), with concurrently acquired computed tomography transmission scan	78430
Myocardial imaging, positron emission tomography (PET), perfusion study (including ventricular wall motion[s] and/or ejection fraction[s], when performed); multiple studies at rest and stress (exercise or pharmacologic), with concurrently acquired computed tomography transmission scan	78431
Myocardial imaging, positron emission tomography (PET), perfusion study (including ventricular wall motion[s] and/or ejection fraction[s], when performed); single study at rest or stress (exercise or pharmacologic)	78491
Myocardial imaging, positron emission tomography (PET), perfusion study (including ventricular wall motion[s] and/or ejection fraction[s], when performed); multiple studies at rest and stress (exercise or pharmacologic)	78492

Stress test with imaging using cardiac perfusion PET (CPT® 78430, 78431, 78491, 78492) is indicated in place of stress echo, SPECT MPI, or stress MRI when **any** of the above indications for stress testing with imaging (symptomatic or regardless of symptoms) have been met **and** there is documentation of **one** of the following:

- Individual is severely obese
- Individual has large breasts or implants
- Individual incapable of exercise due to physical (musculoskeletal or neurological) inability to achieve target heart rate.

Note Target heart rate is calculated as 85% of the maximum age predicted heart rate (MPHR). MPHR is estimated as 220 minus the individual's age. See **Cardiac PET – Perfusion – Indications (CD-6.2)** for additional indications for cardiac PET perfusion

Stress Testing with Imaging – Preoperative (CD-1.5)

CD.ST.0001.5.A

v2.1.2024

- There are **2** steps that determine the need for imaging stress testing in (stable) pre-operative individuals:
 - Step1: Would the individual qualify for imaging stress testing independent of planned surgery?
 - If yes, proceed to stress testing guidelines **Stress Testing with Imaging – Indications (CD-1.4)**
 - If no, go to step 2
 - Step 2: Is the surgery considered high, moderate or low-risk? (see **Table-2**) If high or moderate-risk, proceed below. If low-risk, there is no evidence to determine a need for preoperative cardiac testing.
 - **High-Risk Surgery:** All individuals in this category should receive an imaging stress test if there has not been an imaging stress test within 1 year unless the individual has developed new cardiac symptoms or a new change in the EKG since the last stress test.
 - **Intermediate-Risk Surgery:** One or more clinical risk factors and unable to perform an ETT per guidelines if there has not been an imaging stress test within 1 year unless the individual has developed new cardiac symptoms or a new change in the EKG since the last stress test.
 - **Low-Risk:** Preoperative imaging stress testing is not supported.
 - Clinical Risk Factors (for cardiac death and non-fatal MI at time of non-cardiac surgery)
 - History of ischemic heart disease (previous MI, previous positive stress test, use of nitroglycerin, typical angina, ECG Q waves, previous PCI or CABG)
 - History of compensated previous congestive heart failure (history of heart failure, previous pulmonary edema, third heart sound, bilateral rales, chest x-ray showing heart failure)
 - History of previous TIA or stroke
 - Diabetes Mellitus
 - Creatinine level > 2 mg/dL

Table-2

Cardiac Risk Stratification List		
High-Risk (> 5%)	Intermediate-Risk (1-5%)	Low-Risk (<1%)
<ul style="list-style-type: none">• Open aortic and other major open vascular surgery• Open peripheral vascular surgery• Esophagectomy• Pneumonectomy• Open intraperitoneal and/or intrathoracic surgery with organ resection	<ul style="list-style-type: none">• Open intraperitoneal and/or intrathoracic surgery without major organ resection• Open carotid endarterectomy• Head and neck surgery• Open orthopedic surgery• Open prostate surgery	<ul style="list-style-type: none">• Endoscopic procedures• Superficial procedures• Cataract surgery• Breast surgery• Ambulatory surgery• Laparoscopic and endovascular procedures that are unlikely to require further extensive surgical intervention

Transplant (CD-1.6)

CD.ST.0001.6.A

v2.1.2024

- Stress Testing in individuals for Non-Cardiac Transplant
 - Individuals who are candidates for any type of organ, bone marrow, or stem cell transplant can undergo imaging stress testing every year (stress echo, SPECT MPI, stress MRI, or stress cardiac PET perfusion per the transplant center's protocol) prior to transplant. See **Kidney Transplant, Pre-Transplant Imaging Studies (AB-42.5)**.
 - Individuals who have undergone organ transplant are at increased risk for ischemic heart disease secondary to their medication. Risk of vasculopathy is 7% at one-year, 32% at five years and 53% at ten years. An imaging stress test can be repeated annually after transplant for at least two years or within one year of a prior cardiac imaging study if there is evidence of progressive vasculopathy.
 - After two consecutive normal imaging stress tests, repeated testing is not supported more often than every other year without evidence for progressive vasculopathy or new symptoms.
 - Stress testing after five years may proceed according to normal patterns of consideration.
- Post-Cardiac transplant assessment of transplant CAD:
 - One of the following imaging studies may be performed annually:
 - SPECT MPI
 - Stress ECHO
 - Stress MRI
 - Cardiac PET perfusion

References (CD-1)

CD.GG.0001.0.A

v2.1.2024

1. Fihn SD, Gardin JM, Abrams J, et al. 2012 ACCF/AHA/ACP/AATS/PCNA/SCAI/STS Guideline for the Diagnosis and Management of Patients with Stable Ischemic Heart Disease: Executive Summary. *Circulation*. 2012;126(25):3097-3137. doi:10.1161/cir.0b013e3182776f83.
2. Qaseem A, Fihn SD, Williams S, et al. A. Diagnosis of Stable Ischemic Heart Disease: Summary of a Clinical Practice Guideline from the American College of Physicians/American College of Cardiology Foundation/American Heart Association/American Association for Thoracic Surgery/Preventive Cardiovascular Nurses Association/Society of Thoracic Surgeons. *Annals of Internal Medicine*. 2012;157(10):729. doi:10.7326/0003-4819-157-10-201211200-00010.
3. Rybicki FJ, Udelson JE, Peacock WF, et al. 2015 ACR/ACC/AHA/AATS/ACEP/ASNC/NASCI/SAEM/SCCT/SCMR/SCPC/SNMMI/STR/STS Appropriate Utilization of Cardiovascular Imaging in Emergency Department Patients with Chest Pain. *J Am Coll Cardiol*. 2016;67(7):853-879. doi:10.1016/j.jacc.2015.09.011.
4. Fleisher LA, Fleischmann KE, Auerbach AD, et al. 2014 ACC/AHA Guideline on Perioperative Cardiovascular Evaluation and Management of Patients Undergoing Noncardiac Surgery. *J Am Coll Cardiol*. 2014;64(22):e77-e137. doi:10.1016/j.jacc.2014.07.944.
5. Ho PM, Rumsfeld JS, Peterson PN. Chest pain on exercise treadmill test predicts future cardiac hospitalizations. *Clin Cardiol* 2007; 30:505-510. doi:10.1002/clc.20139.
6. Sechtem U. Do heart transplant recipients need annual coronary angiography? *Eu Heart J* 2001; 22:895-897. doi:10.1053/euhj.2001.2660.
7. Tavel ME. Stress testing in cardiac evaluation: Current concepts with emphasis on the ECG. *Chest* 2001; 119:907-925. doi:10.1378/chest.119.3.907.
8. Wolk MJ, Bailey SR, Doherty JU, et al. ACCF/AHA/ASE/ASNC/HFSA/HRS/SCAI/SCCT/SCMR/STS. 2013 Multi-modality appropriate use criteria for the detection and risk assessment of stable ischemic heart disease: a report of the American College of Cardiology Foundation, Appropriate Use Criteria Task Force, American Heart Association, American Society of Echocardiography, American Society of Nuclear Cardiology, Heart Failure Society of America, Heart Rhythm Society, Society for Cardiovascular Angiography and Interventions, Society of Cardiovascular Computed Tomography, Society for Cardiovascular Magnetic Resonance, and Society of Thoracic Surgeons. *J Am Coll Cardiol* 2014; 63: forthcoming. doi:10.1016/j.jacc.2013.11.009.
9. Blank P, Scheopf UJ, Leipsic JA. CT in transcatheter aortic valve replacement. *Radiology*, 2013; 269(3). doi:10.1148/radiol.13120696.
10. Leipsic JA, Blanke P, Hanley M, et al. ACR Appropriateness Criteria® Imaging for Transcatheter Aortic Valve Replacement. *J Am Coll Radiol*. 2017;14(11). doi:10.1016/j.jacr.2017.08.046.
11. Mieres JH, Gulati M, Bairey Merz N, et al. American Heart Association Cardiac Imaging Committee of the Council on Clinical Cardiology, Cardiovascular Imaging and Intervention Committee of the Council on Cardiovascular Radiology. Role of Noninvasive Testing in the Clinical Evaluation of Women with Suspected Ischemic Heart Disease A Consensus Statement from the American Heart Association. *Circulation*. 2014; 130(4):350. doi:10.1161/CIR.0000000000000061.
12. American College of Cardiology Foundation Appropriate Use Criteria Task Force, American Society of Echocardiography, American Heart Association, et al. ACCF/ASE/AHA/ASNC/HFSA/HRS/SCAI/SCCM/SCCT/SCMR 2011 Appropriate Use Criteria for Echocardiography. A Report of the American College of Cardiology Foundation Appropriate Use Criteria Task Force, American Society of Echocardiography, American Heart Association, American Society of Nuclear Cardiology, Heart Failure Society of America, Heart Rhythm Society, Society for Cardiovascular Angiography and Interventions, Society of Critical Care Medicine, Society of Cardiovascular Computed Tomography, and Society for Cardiovascular Magnetic Resonance Endorsed by the American College of Chest Physicians. *J Am Coll Cardiol* 2011; 57:1126. doi:10.1016/j.echo.2010.12.008.
13. Melon CC, Eshtiaghi P, Luksun WJ, et al. Validated questionnaire vs physicians' judgment to estimate preoperative exercise capacity. *JAMA Intern Med* 2014; 174:1507. doi:10.1001/jamainternmed.2014.2914.
14. Taqueti V, Dorbala S, Wolinsky D. Myocardial perfusion imaging in women for the evaluation of stable ischemic heart disease—state-of-the-evidence and clinical recommendations. *Journal of Nuclear Cardiology*. June 2017. doi.org/10.1007/s12350-017-0926-8.
15. Chamberlain JJ, Johnson EL, Leal S, et al. Cardiovascular Disease and Risk Management: Review of the American Diabetes Association Standards of Medical Care in Diabetes 2018. *Annals of Internal Medicine*. 2018;168(9):640. doi:10.7326/m18-0222.
16. Bateman TM, Dilsizian V, Beanlands RS, Depuey EG, Heller GV, Wolinsky DA. American Society of Nuclear Cardiology and Society of Nuclear Medicine and Molecular Imaging Joint Position Statement on

- the Clinical Indications for Myocardial Perfusion PET. *Journal of Nuclear Medicine*. 2016;57(10):1654-1656. doi:10.2967/jnumed.116.180448.
17. U.S. Food and Drug Administration. PROLEUKIN® (aldesleukin) for injection, for intravenous infusion. U.S. Food and Drug Administration Website. <https://www.accessdata.fda.gov>.
 18. Gulati M, Levy PD, Mukherjee D, et al. 2021 AHA/ACC/AASE/CHEST/SAEM/SCCT/SCMR Guideline for the Evaluation and Diagnosis of Chest Pain: A Report of the American College of Cardiology/American Heart Association Joint Committee on Clinical Practice Guidelines [published correction appears in *Circulation*. 2021 Nov 30;144(22):e455]. *Circulation*. 2021;144(22):e368-e454. doi:10.1161/CIR.0000000000001029.
 19. Kidney Disease: Improving Global Outcomes (KDIGO) Kidney Transplant Candidate Work Group. KDIGO Clinical Practice Guideline on the Evaluation and Management of Candidates for Kidney Transplantation. *Transplantation*. 2020;104: S1 – S103.
 20. Wenger NK, Lloyd-Jones DM, Elkind MSV, et al. Call to Action for Cardiovascular Disease in Women: Epidemiology, Awareness, Access, and Delivery of Equitable Health Care: A Presidential Advisory From the American Heart Association. *Circulation*. 2022;145(23):e1059-e1071. doi:10.1161/CIR.0000000000001071.
 21. Fleisher LA, Fleischmann KE, Auerbach AD, et al. 2014 ACC/AHA guideline on perioperative cardiovascular evaluation and management of patients undergoing noncardiac surgery: a report of the American College of Cardiology/American Heart Association Task Force on Practice Guidelines. *Circulation*. 2014;130(24):e278-e333. doi:10.1161/CIR.000000000000106.
 22. Schwarze ML, Barnato AE, Rathouz PJ, et al. Development of a List of High-Risk Operations for Patients 65 Years and Older. *JAMA Surg*. 2015;150(4):325–331. doi:10.1001/jamasurg.2014.1819.
 23. Cury RC, Leipsic J, Abbara S, et al. CAD-RADS™ 2.0 - 2022 Coronary Artery Disease-Reporting and Data System: An Expert Consensus Document of the Society of Cardiovascular Computed Tomography (SCCT), the American College of Cardiology (ACC), the American College of Radiology (ACR), and the North America Society of Cardiovascular Imaging (NASCI). *J Cardiovasc Comput Tomogr*. 2022;16(6):536-557. doi:10.1016/j.jcct.2022.07.002.
 24. Fletcher GF, Ades PA, Kligfield P, et al. Exercise standards for testing and training: a scientific statement from the American Heart Association. *Circulation*. 2013;128(8):873-934. doi:10.1161/CIR.0b013e31829b5b44.
 25. Multimodality Writing Group for Chronic Coronary Disease, Winchester DE, Maron DJ, et al. ACC/AHA/AASE/ASNC/ASPC/HFSA/HRS/SCAI/SCCT/SCMR/STS 2023 Multimodality Appropriate Use Criteria for the Detection and Risk Assessment of Chronic Coronary Disease. *J Am Coll Cardiol*. 2023;81(25):2445-2467. doi:10.1016/j.jacc.2023.03.410.
 26. Cohn PF, Fox KM, Daly C. Silent myocardial ischemia. *Circulation*. 2003 Sep 9;108(10):1263-77. doi: 10.1161/01.CIR.0000088001.59265.EE.

Echocardiography (ECHO)

Guideline

Transthoracic Echocardiogram (TTE) - Coding (CD-2.1)

Transthoracic Echocardiography (TTE) Indications/initial evaluation (CD-2.2)

Frequency of Echocardiography Testing (CD-2.3)

References

Transesophageal Echocardiography (TEE) (CD-2.4) (CD-2.5)

Stress echocardiography (stress echo) (CD-2.6) (CD-2.7)

3D Echocardiography (CD-2.8)(CD-2.9)

Myocardial strain imaging (CPT® 93356) (CD-2.12)

References (CD-2)

Transthoracic Echocardiogram (TTE) - Coding (CD-2.1)

CD.EC.0002.1.A

v2.1.2024

Guideline

Transthoracic Echocardiography (TTE) - Coding
 Transthoracic Echocardiography (TTE) – Coding - General Information (CD-2.1.1)
 Myocardial contrast perfusion echocardiography (CPT 0439T) (CD-2.11)

Transthoracic Echocardiography (TTE) - Coding

Transthoracic Echocardiography

Description	CPT®
TTE for congenital cardiac anomalies, complete	93303
TTE for congenital cardiac anomalies, follow-up or limited	93304
TTE with 2-D, M-mode, Doppler and color flow, complete	93306
TTE with 2-D, M-mode, without Doppler or color flow	93307
TTE with 2-D, M-mode, follow-up or limited	93308

3D Echocardiography

Description	CPT®
3D echocardiographic imaging and postprocessing during transesophageal echocardiography, or during transthoracic echocardiography for congenital cardiac anomalies, for the assessment of cardiac structure(s) (eg, cardiac chambers and valves, left atrial appendage, interatrial septum, interventricular septum) and function, when performed (List separately in addition to code for echocardiographic imaging) Code with (93303-93304, 93312, 93314, 93315, 93317, 93350-93351)	+93319

Doppler Echocardiography

Description	CPT®
Doppler echo, pulsed wave and/or spectral display	+93320
Doppler echo, pulsed wave and/or spectral display, follow-up or limited study	+93321

Description	CPT®
Doppler echo, color flow velocity mapping	+93325
CPT® 93320 and CPT® 93321 should not be requested or billed together	

C Codes

C codes are unique temporary codes established by CMS. C codes were established for contrast echocardiography. Each echocardiography C code corresponds to a standard echo code (Class I CPT® code) The C code and the matching CPT code should not both be approved.

C Code	Transthoracic Echocardiography	CPT®
C8921	TTE for congenital cardiac anomalies, complete	93303
C8922	TTE for congenital cardiac anomalies, follow-up or limited	93304
C8929	TTE with 2-D, M-mode, Doppler and color flow, complete	93306
C8923	TTE with 2-D, M-mode, without Doppler or color flow	93307
C8924	TTE with 2-D, M-mode, follow-up or limited	93308

Myocardial strain imaging

Description	CPT®
Myocardial strain imaging using speckle tracking-derived assessment of myocardial mechanics (List separately in addition to codes for echocardiography imaging)	+93356

Investigational codes

Description	CPT®
Myocardial contrast perfusion echocardiography, at rest or with stress, for assessment of myocardial ischemia or viability	0439T

Transthoracic Echocardiography (TTE) – Coding - General Information (CD-2.1.1)

- Complete transthoracic echocardiogram with spectral and color flow Doppler (CPT® 93306).
 - 93306 includes the Doppler exams, so CPT® codes 93320-93325 should not be assigned together with CPT® 93306.

- Doppler codes (CPT®93320, CPT® 93321, and CPT® 93325) are 'add-on codes' (as denoted by the + sign) and are assigned in addition to code for the primary procedure.
- For a 2D transthoracic echocardiogram without Doppler, report CPT® 93307.
- Limited transthoracic echocardiogram (CPT® 93308) should be billed if the report does not "evaluate or document the attempt to evaluate" all of the required structures.
 - A limited transthoracic echocardiogram is reported with CPT® 93308.
 - CPT® 93321 (not CPT® 93308 if Doppler is included in the study. CPT® 93325 can be reported with CPT® 93308 if color flow Doppler is included in the study.
 - A limited congenital transthoracic echocardiogram is reported with CPT® 93304.
- Doppler echo may be used for evaluation of the following:
 - Shortness of breath
 - Known or suspected valvular disease
 - Known or suspected hypertrophic obstructive cardiomyopathy
 - Shunt detection

Background and Supporting Information

- Providers performing echo on a pediatric individual, may not know what procedure codes they will be reporting until the initial study is completed.
- If a congenital issue is found on the initial echo, a complete echo is reported with codes CPT® 93303, CPT® 93320, and CPT® 93325 because CPT® 93303 does NOT include Doppler and color flow mapping.
- If no congenital issue is discovered, then CPT® 93306 is reported alone and includes 2-D, Doppler, and color flow mapping.
- Since providers may not know the appropriate code/s that will be reported at the time of the pre-authorization request, they may request all 4 codes (CPT® 93303, CPT® 93320, CPT® 93325, and CPT® 93306).
- CPT® 76376 and CPT® 76377 are not unique to 3D Echo. These codes also apply to 3D rendering of MRI and CT studies, see **3D Echocardiography – Coding (CD-2.9)**
- CPT® 93325 may also be used with fetal echocardiography
- CPT® 93319 3D echo imaging postprocessing of TEE or TTE to evaluate congenital cardiac abnormalities. see **3D Echocardiography – Coding (CD-2.9)**

Myocardial contrast perfusion echocardiography (CPT® 0439T) (CD-2.11)

- Investigational see **Transthoracic Echocardiography (TTE) – Coding (CD-2.1)**

Transthoracic Echocardiography (TTE) Indications/initial evaluation (CD-2.2)

CD.EC.0002.2.A

v2.1.2024

Transthoracic Echocardiography (TTE) is indicated for initial evaluation for any of the following:

Symptoms or signs suggesting cardiovascular disease

- Chest pain/discomfort
- Dyspnea/shortness of breath, or hypoxemia
- Palpitations
- Presyncope/Syncope
- Headache with transcranial Doppler evidence of a shunt or high-degree of suspicion for embolic process
- Dependent lower extremity edema
- Abnormal precordial or peripheral pulse
- New or changing heart murmur or click
- Suspected hypertensive heart disease (initial evaluation)
- Initial evaluation of known/suspected heart failure based on symptoms and/or signs
- Suspected endocarditis with any:
 - Fever
 - Peripheral stigmata of endocarditis
 - New murmur
- History of rheumatic heart disease
- Suspected pericardial diseases
- Suspected cardiac injury due to blunt chest trauma

Diagnostic tests suggesting cardiovascular disease

- Newly diagnosed RBBB or LBBB
- Frequent VPCs defined as occurring more frequently than 30 times per hour or occurring in a pattern of bigeminy, trigeminy, or runs of ventricular tachycardia
- Non sustained or sustained ventricular tachycardia (VT)
- Ventricular fibrillation (VF)
- Newly diagnosed atrial fibrillation/flutter
- Cardiomegaly on a Chest X ray or other imaging
- Elevated level of cardiac biomarkers (Creatinine Kinase isoforms, Troponin I or T, Brain Natriuretic Peptide (BNP), N Terminal pro b-type natriuretic peptide (NT-

- proBNP) above the normal reference range as defined by the local laboratory assays)
- Initial evaluation of known/suspected heart failure based on diagnostic tests
- Suspected inherited or acquired cardiomyopathy (e.g., restrictive, infiltrative, dilated, hypertrophic)
- Suspected pulmonary hypertension. See **Pulmonary Hypertension CD-8.1**
 - ECG changes of right ventricular hypertrophy
 - Right ventricular hypertrophy or pulmonary artery dilation on other imaging
 - Pulmonary embolism with persistent or new symptoms
- Dilated aortic root and/or ascending aorta seen on other imaging
- Suspected endocarditis with positive blood cultures indicating bacteremia
- Suspected pericardial diseases
- Cardiac mass suspected on other imaging
- To rule out intra-cardiac thrombus in individuals with left ventricular systolic dysfunction prior to undergoing catheter ablation of ventricular arrhythmia.
- ≥6 weeks post myocardial infarction

Extra-cardiac conditions and therapies associated with cardiovascular disease or risk

- CONDITIONS
 - Initial cardiac evaluation of a known systemic, congenital, or acquired disease that could be associated with structural heart disease
 - At risk for developing iron-overload cardiomyopathy (hereditary hemochromatosis or hereditary or acquired hematologic conditions requiring multiple transfusions)
 - Known or suspected connective tissue disease or a genetic condition that predisposes to an aortic aneurysm or dissection (may repeat every two years if negative) See **Screening for Vascular related genetic connective tissue Disorders PVD-2.2**
 - At risk for pulmonary hypertension. See **Pulmonary Hypertension CD-8.1**
 - Scleroderma
 - Lupus
 - Mixed connective tissue disease
 - Hereditary Hemorrhagic Telangiectasia
 - Individuals with pulmonary hypertension mutations (e.g., BMPR2)
 - Suspected pulmonary hypertension in the presence of:
 - Liver disease
 - Lung disease
 - HIV

- Newly diagnosed or strongly suspected cerebral ischemia or peripheral embolic event
- THERAPIES
 - Use of anorectic drugs, ergot derivatives, or other agents associated with valvular heart disease
 - Pre-procedure evaluation for TIPS (transjugular intrahepatic portosystemic shunt) See **Hepatic Arteries and Veins AB-43.1**
 - Prior to solid organ transplant or hematopoietic stem cell transplant
 - Prior to exposure to cardiotoxic medications or radiation therapy. See **Cardiotoxic agent/Cancer Therapeutics-Related Cardiac Dysfunction CD-12.1**

Inherited cardiovascular conditions

- Member has first degree relative diagnosed with thoracic aortic aneurysm or dissection (may repeat every two years if negative). See **Screening for Vascular related genetic connective tissue Disorders PVD-2.2**, **Thoracic Aortic Aneurysm PVD-6.2**
- Member has first degree relative diagnosed with Bicuspid aortic valve. See **Screening for TAA in individuals with bicuspid aortic valves PVD-2.3**
- Member has diagnosed first degree relative or member is genotype positive for an inherited cardiomyopathy including any of the following:
 - Hypertrophic cardiomyopathy
 - Non compaction cardiomyopathy
 - Familial Dilated Cardiomyopathy
 - Arrhythmogenic Cardiomyopathy (e.g., ARVC)

Additional indications

- One repeat echo can be approved if requested for contrast study (for evaluation of shunts or for left ventricular cavity opacification) when the results of the initial study indicate the need for contrast but contrast was not administered at the initial study.
- Evaluation of congenital heart disease: see **Adult Congenital Heart Disease CD-11** and **Congenital Heart Disease PEDCD-2** in the Pediatric Cardiology imaging guidelines

Frequency of Echocardiography Testing (CD-2.3)

CD.EC.0002.3.A

v2.1.2024

Guideline

Repeat testing by interval
Repeat testing per condition

Repeat testing by interval

Repeat Transthoracic Echocardiography (TTE) is indicated for any of the following:

Every 3 years

Valvular heart disease (See also below indications for Valve surgery or intervention)

- Bicuspid aortic valve
- Mild aortic stenosis or aortic valve sclerosis without stenosis
- Mild aortic or mitral regurgitation
- Any mitral stenosis that is not severe, mitral valve area $>1.5 \text{ cm}^2$
- Rheumatic valve changes with commissural fusion
- Surgical valve repair or replacement (including bioprosthetic valve <10 years since implant)

Cardiomyopathy

- First degree relative with a diagnosis of inherited cardiomyopathy including:
 - Hypertrophic Cardiomyopathy
 - Familial Dilated Cardiomyopathy
 - Idiopathic Dilated Cardiomyopathy
- Individuals genotype-positive for:
 - Familial Dilated Cardiomyopathy
 - Arrhythmogenic Cardiomyopathy (e.g., ARVC)

Every 2 years

Vascular disease

- First degree relative with known thoracic aortic aneurysm or dissection a repeat echo is allowed every two years when both:

- Prior aortic imaging (echo, CT, MR) is negative
- Last aortic imaging was ≥ 2 years. See **Screening for Vascular related genetic connective tissue Disorders (PVD-2.2)**

Every year

Valvular heart disease (See also below indications for Valve surgery or intervention)

- Moderate or severe regurgitation
- Moderate or severe stenosis
- Significant valve deformity (regardless of extent of regurgitation or stenosis) when there is documentation of either:
 - Thickened myxomatous valve
 - Bileaflet prolapse
- Surgical bioprosthetic valve replacement ≥ 10 years since implant

Cardiomyopathy/heart failure

- Left ventricular systolic dysfunction to evaluate the effectiveness of ongoing therapy
- Hypertrophic cardiomyopathy See below indications for hypertrophic cardiomyopathy. See **Hypertrophic Cardiomyopathy CD-14**
- Frequent right ventricular pacing $>40\%$
- Chronic LBBB
- Left ventricular non-compaction cardiomyopathy
- At risk for developing iron-overload cardiomyopathy (hereditary hemochromatosis or hereditary or acquired hematologic conditions requiring multiple transfusions)
- Inherited neuromuscular, metabolic, hematologic or cutaneous syndromes that are known to be associated with the development of cardiomyopathy

Pericardial disease

- Chronic pericardial effusions when findings would potentially alter therapy

Vascular disease

- Aortic root dilatation that has not yet been repaired See **Thoracic aortic aneurysm PVD 6.2** and
- For post-repair see **Post-Aortic Endovascular/Open Surgery Surveillance Studies PVD-6.8**

At risk for pulmonary Hypertension See **Pulmonary Hypertension CD-8.1**

- Systemic Sclerosis or Scleroderma
- Individuals with pulmonary hypertension mutations (e.g., BMPR2)
- First-degree relatives of individuals with pulmonary hypertension
- Connective tissue disorder with symptoms consistent with pulmonary hypertension
- Individuals with TR velocity ≥ 2.8 m/s, with no other findings on additional testing

- Individuals being treated with medications associated with pulmonary hypertension
- Individuals who have a concern documented for pulmonary hypertension and had a negative echocardiogram but still show signs or symptoms of pulmonary hypertension

Every 6 months or twice a year

Valvular heart disease

- Asymptomatic, severe mitral regurgitation if valve surgery is being considered

Pulmonary Hypertension (See below indications for Pulmonary Hypertension, See **Pulmonary Hypertension CD-8.1**)

- Surveillance of stable individuals with moderate or severe pulmonary hypertension (pulmonary artery systolic pressure ≥ 50 mmHg)

Anytime

Repeat transthoracic echocardiogram is indicated **anytime** (without regard for the number or timing of previous ECHO studies) if there is a **change** in clinical status, or **new signs and symptoms** with documentation of **any** of the following:

- Cardiac murmurs
- Myocardial infarction or acute coronary syndrome
- Congestive heart failure (new or worsening):
 - New symptoms of dyspnea
 - Orthopnea
 - Paroxysmal nocturnal dyspnea
 - Elevated BNP
- Known pericardial disease with clinical concern for cardiac tamponade or pericardial constriction
- Infective endocarditis for any of the following:
 - Repeat imaging within 5–7 days for initially negative or inconclusive imaging when clinical suspicion of endocarditis remains high
 - New or worsening symptoms or signs of endocarditis
 - As needed to guide changes in antibiotic therapy
 - At completion of antibiotic therapy
- Stroke/transient ischemic attack
- Decompression illness
- Prosthetic valve dysfunction or thrombosis
- Cardiac transplant
- Individuals with Left Ventricular Assist Device (LVAD)

- See also section on **Repeat testing per condition** below and **Left ventricular assist devices (LVAD) (CD-9.4)**

Repeat testing per condition

Repeat Transthoracic Echocardiography (TTE) is indicated for any of the following:

Valve surgery or intervention

Repeat Transthoracic Echocardiography (TTE) is indicated for any of the following:

- **Surgical valve repair or replacement** (including bioprosthetic valve <10 years since implant)
 - 6 weeks post-surgery to establish baseline
 - Surveillance every 3 years after surgery
- **Surgical bioprosthetic valve replacement ≥10 years since implant**
 - Annually
- **TAVR**
 - One week after procedure to establish baseline
 - 1 month post-procedure
 - 1 year post-procedure
 - Thereafter annually
- **Mitra-Clip**
 - 1 month post-procedure
 - 6 months post-procedure
 - 1 year post-procedure
 - Thereafter annually to 5 years

See also **Transcatheter Aortic Valve Replacement (TAVR) CD-4.8**

See also **Percutaneous Mitral Valve Repair (mitral valve clip) (CD-13.5)**

PFO closure, TIPS, Cardiac device therapy, LVAD

Repeat Transthoracic Echocardiography (TTE) is indicated for any of the following:

- **PFO Closure**
 - Pre-operative evaluation for closure of PFO
 - Post-procedural evaluation of PFO repair
 - 6 month follow-up after PFO repair
 - Annually if there is a residual shunt on post-operative imaging

For ASD closure see **ASD-Atrial septal defects (CD 11.2.1)**

- **TIPS (transjugular intrahepatic portosystemic shunt)** See [Hepatic Arteries and Veins AB 43.1](#)
 - One time post-procedure for routine follow-up
 - **Any time** post-procedure (either):
 - For new signs or symptoms
 - For concern for new or worsening pulmonary hypertension or heart failure
- **Cardiac device therapy**
 - Re-evaluation is indicated 3 months after revascularization or maximally tolerated optimal medical therapy to determine either:
 - Candidacy for device therapy
 - Optimal choice of device
 - One time follow up within 12 months of implantation of a CRT-D device
- **Left ventricular assist device (LVAD)** See [Left ventricular assist devices \(LVAD\) \(CD-9.4\)](#)
 - Prior to implant
 - Routine Post-implant at the following intervals:
 - 2 weeks
 - One month
 - Three months
 - Six months
 - Twelve months
 - Every 6 months thereafter

Pulmonary hypertension

Repeat Transthoracic Echocardiography (TTE) is indicated for individuals with known pulmonary hypertension for any of the following:

- **Routine follow up**
 - Every 6 months for surveillance of stable individuals with moderate or severe pulmonary hypertension (pulmonary artery systolic pressure ≥ 50 mm Hg)
- **Pregnancy**
 - Prior to planned pregnancy
 - During pregnancy as often as requested by the provider
- **Pre-procedure**
 - Prior to planned intubation (e.g., for elective surgery)
- **Clinical/therapy change:**
 - Anytime, without regard for the number or timing of previous ECHO studies to evaluate either:
 - Change in therapy

- Change in clinical findings or symptoms
- Therapy changes:
 - At baseline
 - Then every 3 months

See also **Pulmonary Hypertension CD-8.1**

Hypertrophic Cardiomyopathy (HCM)

Repeat Transthoracic Echocardiography (TTE) is indicated for individuals with hypertrophic cardiomyopathy for any of the following:

- **Routine Surveillance Imaging**
 - Every year
- **Mavacamten: Initiation of treatment**
 - Baseline at the beginning of treatment
 - 4 weeks after treatment initiation
 - 8 weeks after treatment initiation
 - 12 weeks after treatment initiation
 - Then every 12 weeks while on mavacamten
- **Mavacamten: Changes in treatment**
 - 4 weeks after any interruption of treatment (any missed dose)
 - After any dosage change (including restart of treatment):
 - 4 weeks after dosage change
 - 12 weeks after dosage change
 - After initiating a weak CYP2C19 inhibitor (e.g., omeprazole) or moderate CYP3A4 inhibitor (e.g., ciprofloxacin):
 - 4 weeks after start of medication
 - 12 weeks after start of medication
 - At any time regardless of timing of prior echo when there are new cardiac signs or symptoms, or worsening of clinical status
- **Post- Septal Reduction Therapy (SRT)**
 - Within 3 to 6 months after surgical myectomy or alcohol septal ablation

Cardiotoxic Agents

For re-evaluation in an individual previously or currently undergoing therapy with cardiotoxic agents or radiation therapy follow **Cardiotoxic agent/Cancer Therapeutics-Related Cardiac Dysfunction (CD-12.1)**

Background and supporting information

Decisions regarding routine echocardiographic follow-up should not be based on the degree of regurgitation alone, but should take into account associated structural valvular and cardiac abnormalities. For example: a structurally normal mitral valve with moderate mitral regurgitation by color flow Doppler and normal left atrial size, does not generally require routine echocardiographic follow-up. However, a thickened, myxomatous appearing mitral valve with bi-leaflet prolapse and only trivial or mild mitral regurgitation, should be followed echocardiographically at routine intervals.

References

CD.EC.0002.3.A

v2.1.2024

1. Kottam A et al. American Heart Association Council on Cardiovascular Radiology and Intervention. State-of-the-Art Imaging of Infiltrative Cardiomyopathies: A Scientific Statement From the American Heart Association. *Circ Cardiovasc Imaging*. 2023 Nov;16(11):e000081. doi: 10.1161/HCI.0000000000000081.
2. Delgado V et al. ESC Scientific Document Group. 2023 ESC Guidelines for the management of endocarditis. *Eur Heart J*. 2023 Oct 14;44(39):3948-4042. doi: 10.1093/eurheartj/ehad193. Erratum in: *Eur Heart J*. 2023 Sep 20.
3. Arbelo E et al. ESC Scientific Document Group. 2023 ESC Guidelines for the management of cardiomyopathies. *Eur Heart J*. 2023 Oct 1;44(37):3503-3626. doi: 10.1093/eurheartj/ehad194.
4. McDonagh TA et al ESC Scientific Document Group. 2023 Focused Update of the 2021 ESC Guidelines for the diagnosis and treatment of acute and chronic heart failure. *Eur Heart J*. 2023 Oct 1;44(37):3627-3639. doi: 10.1093/eurheartj/ehad195. Chung MK, et al. 2023 HRS/APHRS/LAHRS guideline on cardiac physiologic pacing for the avoidance and mitigation of heart failure. *Heart Rhythm*. 2023 May 15:S1547-5271(23)02026-X. doi: 10.1016/j.hrthm.2023.03.1538.
5. Isselbacher EM et al. 2022 ACC/AHA Guideline for the Diagnosis and Management of Aortic Disease: A Report of the American Heart Association/American College of Cardiology Joint Committee on Clinical Practice Guidelines. *Circulation*. 2022 Dec 13;146(24):e334-e482. doi: 10.1161/CIR.0000000000001106. Epub 2022 Nov 2.
6. Heidenreich PA, Bozkurt B, Aguilar D, et al.. 2022 AHA/ACC/HFSA guideline for the management of heart failure: a report of the American College of Cardiology/American Heart Association Joint Committee on Clinical Practice Guidelines. *Circulation*. 2022 May 3;145:e895–e1032. doi: 10.1161/CIR.0000000000001063
7. Writing Committee Members; Otto CM, 2020 ACC/AHA Guideline for the Management of Patients With Valvular Heart Disease: A Report of the American College of Cardiology/American Heart Association Joint Committee on Clinical Practice Guidelines. *J Am Coll Cardiol*. 2021 Feb 2;77(4):e25-e197.
8. Ommen SR et al. 2020 AHA/ACC Guideline for the Diagnosis and Treatment of Patients With Hypertrophic Cardiomyopathy: A Report of the American College of Cardiology/American Heart Association Joint Committee on Clinical Practice Guidelines. *Circulation*. 2020 Dec 22;142(25):e558-e631. doi: 10.1161/CIR.0000000000000937. Epub 2020 Nov 20.
9. Doherty JU et al. ACC/AATS/AHA/ASE/ASNC/HRS/SCAI/SCCT/SCMR/STS 2019 Appropriate Use Criteria for Multimodality Imaging in the Assessment of Cardiac Structure and Function in Nonvalvular Heart Disease. *J Am Coll Cardiol*. 2019 Feb 5;73(4):488-516. doi: 10.1016/j.jacc.2018.10.038. Epub 2019 Jan 7.
10. Doherty JU et al. ACC/AATS/AHA/ASE/ASNC/HRS/SCAI/SCCT/SCMR/STS 2017 Appropriate Use Criteria for Multimodality Imaging in Valvular Heart Disease. *J Am Coll Cardiol*. 2017 Sep 26;70(13):1647-1672. doi: 10.1016/j.jacc.2017.07.732. Epub 2017 Sep 1.
11. Faqih SA, Noto-Kadou-Kaza B, Abouamrane LM, Mtiou N, El Khayat S, Zamd M, Medkouri G, Benghanem MG, Ramdani B. Pulmonary hypertension: prevalence and risk factors. *Int J Cardiol Heart Vasc*. 2016 May 9;11:87-89.
12. Adler Yet al. 2015 ESC Guidelines for the diagnosis and management of pericardial diseases. *Eur Heart J*. 2015 Nov 7;36(42):2921-2964. doi: 10.1093/eurheartj/ehv318. Epub 2015 Aug 29.
13. Douglas, Pamela S et al. ACCF/ASE/AHA/ASNC/HFSA/HRS/SCAI/SCCM/SCCT/SCMR 2011 Appropriate Use Criteria for Echocardiography. *J Am Soc Echocardiogr*. 2011 Mar;24(3):229-67.

Transesophageal Echocardiography (TEE) (CD-2.4) (CD-2.5)

CD.EC.0002.4.A

v2.1.2024

Guideline

Transesophageal echocardiography (TEE) – coding (CD-2.4)
Transesophageal echocardiography (TEE) – indications (CD-2.5)

Transesophageal echocardiography (TEE) – coding (CD-2.4)

TEE coding

Transesophageal Echocardiography	CPT®
TEE with 2-D, M-mode, probe placement, image acquisition, interpretation and report	93312
TEE probe placement only	93313
TEE image acquisition, interpretation, and report only	93314
TEE for congenital anomalies with 2-D, M-mode, probe placement, image acquisition, interpretation and report	93315
TEE for congenital anomalies, probe placement only	93316
TEE for congenital anomalies, image acquisition, interpretation and report only	93317
TEE for monitoring purposes, ongoing assessment of cardiac pumping function on an immediate time basis	93318

Doppler Echocardiography

Description	CPT®
Doppler echo, pulsed wave and/or spectral display	+93320
Doppler echo, pulsed wave and/or spectral display, follow-up or limited study	+93321
Doppler echo, color flow velocity mapping	+93325

Description	CPT®
Doppler echo, if performed, may be reported separately in addition to the primary TEE codes: CPT® 93312, CPT® 93314, CPT® 93315, and CPT® 93317	

C codes

HCPCS	Description	CPT®
C8925	TEE with 2-D, M-mode, probe placement, image acquisition, interpretation and report	93312
C8926	TEE for congenital anomalies with 2-D, M-mode, probe placement, image acquisition, interpretation and report	93315
C8927	TEE for monitoring purposes, ongoing assessment of cardiac pumping function on an immediate time basis	93318

- The complete transesophageal echocardiogram service, including both (1) probe (transducer) placement and (2) image acquisition/interpretation, is reported with CPT® 93312.
 - Probe placement only is reported with CPT® 93313.
 - The image acquisition/interpretation only is reported with CPT® 93314.
- Physicians assign codes CPT® 93312, CPT® 93313, and/or CPT® 93314 to report professional services if the test is performed in a hospital or other facility where the physician cannot bill globally.
 - Modifier -26 (professional component) is appended to the appropriate code
 - CPT® 93313 and CPT® 93314 should never be used together. If both services are provided, CPT® 93312 is reported.
- Hospitals should report TEE procedures using CPT® 93312 (the complete service). CPT® 93313 and CPT® 93314 are not used for hospital billing.
- Monitoring of patients undergoing cardiac surgery is CPT® 93318.

Transesophageal echocardiography (TEE) – indications (CD-2.5)

- Limited transthoracic echo window when further information is needed to guide management (e.g. suspected or confirmed endocarditis, suspected intracardiac mass, etc.)

- Assessing valvular dysfunction, especially mitral regurgitation, when TTE is inadequate and intervention is being considered to repair/replace valve.
- Evaluation of cardiac mass, suspected tumor or thrombus
- Preprocedural assessment of PFO/ASD
- Preoperative evaluation prior to planned LVAD implant
- Embolic source or intracardiac shunting when TTE is inconclusive
 - Examples: atrial septal defect, ventricular septal defect, patent foramen ovale, aortic cholesterol plaques, thrombus in cardiac chambers, valve vegetation, tumor
- Embolic events when there is an abnormal TTE or a history of atrial fibrillation
 - Clarify atria/atrial appendage, aorta, mitral/aortic valve beyond the information that other imaging studies have provided
- Cardiac valve dysfunction
 - Differentiation of tricuspid from bicuspid aortic valve in setting of aortic enlargement or significant stenosis or significant regurgitation
 - Congenital abnormalities
- Assessing for left atrial thrombus prior to cardioversion of atrial fibrillation or atrial flutter.
- Assessing for left atrial thrombus prior to planned atrial fibrillation ablation/pulmonary vein isolation procedure.
- For initial imaging of ascending and descending thoracic aortic aneurysms.
- For repeat imaging or established thoracic aneurysms, TEE is indicated **only** when imaging with CT or MR is contraindicated.
- Left atrial appendage (LAA) Closure device (e.g., WATCHMAN®)
 - Preprocedural evaluation with or without 3D imaging
 - Repeat TEE 45 days post procedure
 - If the TEE at 45 days showed a peri-device gap ≥ 5 mm or Device Related Thrombus, another follow up TEE, usually 3- 6 months can be performed before the one year surveillance
 - 1 year post procedure
 - See also **Percutaneous Mitral Valve Repair (mitral valve clip) (CD-13.5)**

Stress echocardiography (stress echo) (CD-2.6) (CD-2.7)

CD.EC.0002.7.A

v2.1.2024

Guideline

Stress echo – coding (CD-2.6)

Stress echo-indications other than ruling out CAD (CD-2.7)

Stress echo – coding (CD-2.6)

Associated codes

Stress Echocardiography	CPT®
Echo, transthoracic, with (2D), includes M-mode, during rest and exercise stress test and/or pharmacologically induced stress, with report; ³	93350
Echo, transthoracic, with (2D), includes M-mode, during rest and exercise stress test and/or pharmacologically induced stress, with report: including performance of continuous electrocardiographic monitoring, with physician supervision ⁴	93351
Doppler Echocardiography	
Doppler echo, pulsed wave and/or spectral display ⁵	+93320
Doppler echo, pulsed wave and/or spectral display, follow-up/limited study	+93321
Doppler echo, color flow velocity mapping ⁶	+93325

Associated HCPCS codes

CPT®	Stress Echocardiography	HCPCS
93350	Echo, transthoracic, with (2D), includes M-mode, during rest and exercise stress test and/or pharmacologically induced stress, with report; ⁷	C8928

³ CPT® 93350 and CPT® 93351 do not include Doppler studies

⁴ CPT® 93350 and CPT® 93351 do not include Doppler studies

⁵ Doppler echo (CPT® +93320 and CPT® +93325), if performed, may be reported separately in addition to the primary SE codes: CPT® 93350 or CPT® 93351.

⁶ Doppler echo (CPT® +93320 and CPT® +93325), if performed, may be reported separately in addition to the primary SE codes: CPT® 93350 or CPT® 93351.

⁷ CPT® 93350 and CPT® 93351 do not include Doppler studies

CPT®	Stress Echocardiography	HCPCS
93351	Echo, transthoracic, with (2D), includes M-mode, during rest and exercise stress test and/or pharmacologically induced stress, with report: including performance of continuous electrocardiographic monitoring, with physician supervision ⁸	C8930

Stress echo-indications other than ruling out CAD (CD-2.7)

CPT® 93350 or 93351

- See: **Stress Testing with Imaging – Indications (CD-1.4)**
- In addition to the evaluation of CAD, stress echo can be used to evaluate the following conditions:
 - Dyspnea on exertion (specifically to evaluate pulmonary hypertension)
 - Right heart dysfunction
 - Valvular heart disease when the outcome would affect a therapeutic or interventional decision
 - Pulmonary hypertension when the outcome will measure response to therapy and/or prognostic information
 - Hypertrophic cardiomyopathy (as defined in **Obstructive Hypertrophic Cardiomyopathy (HCM) (CD-12.3)** for **either** of the following:
 - Exercise stress echo (CPT® 93351 or 93350) is indicated for the detection and quantification of dynamic left ventricular outflow tract obstruction in symptomatic individuals with HCM who do **not** have a resting or provokable outflow tract gradient ≥ 50 mm Hg on TTE.
 - Stress echo can be repeated when there is documentation of **any** of the following:
 - In 1 to 2 years if the resting or provokable outflow tract gradient is < 30 mm Hg on prior stress echo
 - Worsening symptoms
 - There has been a therapeutic change (i.e., change in medication, surgical procedure performed).
- In general spectral Doppler (CPT® 93320 or 93321) and color-flow Doppler (CPT® 93325) are necessary in the evaluation of the above conditions and can be added to the stress echo code.

⁸ CPT® 93350 and CPT® 93351 do not include Doppler studies

3D Echocardiography (CD-2.8)(CD-2.9)

CD.EC.0002.9.A

v2.1.2024

Guideline

3D echocardiography – coding (CD-2.8)

3D echocardiography – indications (CD-2.9)

3D echocardiography – coding (CD-2.8)

- CPT® 93319 with one of the following (CPT® 93303, 93304, 93312, 93314, 93315, or 93317) for congenital cardiac abnormalities

3D echocardiography – indications (CD-2.9)

Echocardiography with 3-dimensional (3D) rendering (CPT® 93319) is becoming universally available, yet its utility remains limited based on the current literature.

- 3D Echo may be indicated when a primary echocardiogram is approved and **one** of the following is needed:
 - Left ventricular volume and ejection fraction assessment when measurements are needed for treatment decision (e.g., implantation of ICD, alteration in cardiotoxic chemotherapy)
 - Mitral valve anatomy specifically related to mitral valve stenosis
 - Preprocedural evaluation of left atrial appendage occlusion (e.g., WATCHMAN®)
 - Preoperative evaluation for LVAD implant
 - Guidance of transcatheter procedures such as:
 - Mitral valve clipping
 - TAVR
 - Left atrial appendage closure device (e.g., WATCHMAN®)

Myocardial strain imaging (CPT® 93356) (CD-2.12)

CD.EC.0002.12.A

v2.1.2024

- Myocardial strain imaging (CPT® 93356, speckle tracking longitudinal strain) is indicated for the initial evaluation of LVH, in addition to the primary echocardiogram, when there is documentation of **both**:
 - Unclear etiology
 - Concern for infiltrative cardiomyopathy
- See myocardial strain imaging in **Cardiotoxic Agent-Related Cardiac Dysfunction (CD-12)**
- Myocardial strain imaging (CPT® 93356) in addition to the primary echocardiogram in individuals receiving therapy with cardiotoxic agents for ANY of the following:
 - Initial evaluation-prior to treatment with EITHER:
 - Medications that could result in cardiotoxicity/heart failure
 - Radiation that could result in cardiotoxicity/heart failure
 - Re-evaluation of an individual previously or currently undergoing therapy as per echocardiogram parameters. See **Cardiotoxic agent/Cancer Therapeutics-Related Cardiac Dysfunction (CD-12.1)**
 - Re-evaluation of an individual undergoing therapy with worsening symptoms

References (CD-2)

CD.EC.0002.A

v2.1.2024

1. Douglas PS, Khandheria B, Stainback RF, et al. ACCF/AASE/ACEP/AHA/ASNC/SCAI/SCCT/SCMR 2008 appropriateness criteria for stress echocardiography: a report of the American College of Cardiology Foundation Appropriateness Criteria Task Force, American Society of Echocardiography, American College of Emergency Physicians, American Heart Association, American Society of Nuclear Cardiology, Society for Cardiovascular Angiography and Interventions, Society of Cardiovascular Computed Tomography, and Society for Cardiovascular Magnetic Resonance: endorsed by the Heart Rhythm Society and the Society of Critical Care Medicine. *Circulation*. 2008;117(11):1478-1497. doi:10.1161/CIRCULATIONAHA.107.189097.
2. Pellikka PA, Nagueh SF, Elhendy AA, Kuehl CA, Sawada SG. American Society of Echocardiography Recommendations for Performance, Interpretation, and Application of Stress Echocardiography. *J Am Soc Echocardiogr*. 2007;20(9):1021-1041. doi:10.1016/j.echo.2007.07.003.
3. Holmes DR, Mack MJ, Kaul S, et al. 2012 ACCF/AATS/SCAI/STS Expert Consensus Document on Transcatheter Aortic Valve Replacement. *The Annals of Thoracic Surgery*. 2012;93(4):1340-1395. doi:10.1016/j.athoracsur.2012.01.084.
4. Wolk MJ, Bailey SR, Doherty JU, et al. ACCF/AHA/AASE/ASNC/HFSA/HRS/SCAI/SCCT/SCMR/STS 2013 Multimodality Appropriate Use Criteria for the Detection and Risk Assessment of Stable Ischemic Heart Disease. *J Am Coll Cardiol*. 2014;63(4):380-406. doi:10.1016/j.jacc.2013.11.009.
5. Doherty JU, Kort S, Mehran R, Schoenhagen P, Soman P. ACC/AATS/AHA/AASE/ASNC/HRS/SCAI/SCCT/SCMR/STS 2017 Appropriate Use Criteria for Multimodality Imaging in Valvular Heart Disease. *J Am Coll Cardiol* 2017;70(13):1647-1672. doi:10.1016/j.jacc.2017.07.732.
6. Khanna D, Gladue H, Channick R, et al. Recommendations for Screening and Detection of Connective Tissue Disease-Associated Pulmonary Arterial Hypertension. *Arthritis & Rheumatism*. 2013;65(12):3194-3201. doi:10.1002/art.38172.
7. Simonneau G, Gatzoulis MA, Adatia I, et al. Updated Clinical Classification of Pulmonary Hypertension. *J Am Coll Cardiol*. 2013;62(25). doi:10.1016/j.jacc.2013.10.029.
8. Tolle JJ, Waxman AB, Horn TLV, Pappagianopoulos PP, Systrom DM. Exercise-Induced Pulmonary Arterial Hypertension. *Circulation*. 2008;118(21):2183-2189. doi:10.1161/circulationaha.108.787101.
9. Vainrib AF, Harb SC, Jaber W, et al. Left Atrial Appendage Occlusion/Exclusion: Procedural Image Guidance with Transesophageal Echocardiography. *J Am Soc Echocardiogr*. 2018;31(4):454-474. doi:10.1016/j.echo.2017.09.014.
10. Lentine KL, Costa SP, Weir MR, et al. Cardiac Disease Evaluation and Management Among Kidney and Liver Transplantation Candidates. *Circulation*. 2012;126(5):617-663. doi:10.1161/cir.0b013e31823eb07a.
11. Stainback RF, Estep JD, Agler DA, et al. Echocardiography in the Management of Patients with Left Ventricular Assist Devices: Recommendations from the American Society of Echocardiography. *J Am Soc Echocardiogr*. 2015;28(8):853-909. doi:10.1016/j.echo.2015.05.008.
12. Sachdeva R, Valente AM, Armstrong AK, et al. ACC/AHA/AASE/HRS/ISACHD/SCAI/SCCT/SCMR/SOPE 2020 Appropriate Use Criteria for Multimodality Imaging During the Follow-Up Care of Patients with Congenital Heart Disease. *J Am Coll Cardiol*. 2020;75(6):657-703. doi:10.1016/j.jacc.2019.10.002.
13. Stout KK, Daniels CJ, Aboulhosn JA, et al. 2018 AHA/ACC Guideline for the Management of Adults with Congenital Heart Disease: A Report of the American College of Cardiology/American Heart Association Task Force on Clinical Practice Guidelines. *Circulation*. 2019;139(14). doi:10.1161/cir.0000000000000603.
14. Otto CM, Nishimura RA, Bonow RO, et al. 2020 ACC/AHA Guideline for the Management of Patients with Valvular Heart Disease: A Report of the American College of Cardiology/American Heart Association Joint Committee on Clinical Practice Guidelines. *Circulation*. 2021;143(5). doi:10.1161/cir.0000000000000923.
15. Hiratzka LF, Bakris GL, Beckman JA, et al. 2010 ACCF/AHA/AATS/ACR/ASA/SCA/SCAI/SIR/STS/SVM Guidelines for the diagnosis and management of patients with thoracic aortic disease. A Report of the American College of Cardiology Foundation/American Heart Association Task Force on Practice Guidelines, American Association for Thoracic Surgery, American College of Radiology, American Stroke Association, Society of Cardiovascular Anesthesiologists, Society for Cardiovascular Angiography and Interventions, Society of Interventional Radiology, Society of Thoracic Surgeons, and Society for Vascular Medicine [published correction appears in *J Am Coll Cardiol*. 2013 Sep 10;62(11):1039-40]. *J Am Coll Cardiol*. 2010;55(14):e27-e129. doi:10.1016/j.jacc.2010.02.015.
16. Ge Y, Gupta S, Fentanes E, et al. Role of Cardiac CT in Pre-Procedure Planning for Transcatheter Mitral Valve Replacement. *JACC: Cardiovasc Imag*. 2021. doi:10.1016/j.jcmg.2020.12.018.
17. Blanke P, Weir-McCall JR, Achenbach S, et al. Computed Tomography Imaging in the Context of Transcatheter Aortic Valve Implantation (TAVI)/Transcatheter Aortic Valve Replacement (TAVR). *JACC: Cardiovasc Imag*. 2019;12(1):1-24. doi:10.1016/j.jcmg.2018.12.003.

18. Doherty JU, Kort S, Mehran R, et al. ACC/AATS/AHA/ASE/ASNC/HRS/SCAI/SCCT/SCMR/STS 2019 Appropriate Use Criteria for Multimodality Imaging in the Assessment of Cardiac Structure and Function in Nonvalvular Heart Disease: A Report of the American College of Cardiology Appropriate Use Criteria Task Force, American Association for Thoracic Surgery, American Heart Association, American Society of Echocardiography, American Society of Nuclear Cardiology, Heart Rhythm Society, Society for Cardiovascular Angiography and Interventions, Society of Cardiovascular Computed Tomography, Society for Cardiovascular Magnetic Resonance, and the Society of Thoracic Surgeons. *J Am Coll Cardiol*. 2019;73(4):488-516. doi:10.1016/j.jacc.2018.10.038.
19. Behr ER, Dalageorgou C, Christiansen M, et al. Sudden arrhythmic death syndrome: familial evaluation identifies inheritable heart disease in the majority of families. *Eur Heart J*. 2008;29(13):1670-1680. doi:10.1093/eurheartj/ehn219.
20. Emery MS, Kovacs RJ. Sudden Cardiac Death in Athletes. *JACC Heart Fail*. 2018;6(1):30-40. doi:10.1016/j.jchf.2017.07.014.
21. Ommen SR, Mital S, Burke MA, et al. 2020 AHA/ACC Guideline for the Diagnosis and Treatment of Patients With Hypertrophic Cardiomyopathy: A Report of the American College of Cardiology/American Heart Association Joint Committee on Clinical Practice Guidelines. *J Am Coll Cardiol*. 2020;76(25):e159-e240. doi:10.1016/j.jacc.2020.08.045.
22. Sweet M, Taylor MR, Mestroni L. Diagnosis, prevalence, and screening of familial dilated cardiomyopathy. *Expert Opin Orphan Drugs*. 2015;3(8):869-876. doi:10.1517/21678707.2015.1057498.
23. TeRiele, Anneline, James, Cynthia, Approach to family screening in arrhythmogenic right ventricular dysplasia/ Cardiomyopathy. *Eur Heart J*. (2016) 37, 755-763 doi:10.1093/eurheartj/ehv387.
24. Tanaka H. Efficacy of echocardiography for differential diagnosis of left ventricular hypertrophy: special focus on speckle-tracking longitudinal strain. *J Echocardiogr*. 2021;19(2):71-79. doi:10.1007/s12574-020-00508-3.
25. Nagueh SF, Phelan D, Abraham T, et al. Recommendations for Multimodality Cardiovascular Imaging of Patients with Hypertrophic Cardiomyopathy: An Update from the American Society of Echocardiography, in Collaboration with the American Society of Nuclear Cardiology, the Society for Cardiovascular Magnetic Resonance, and the Society of Cardiovascular Computed Tomography. *J Am Soc Echocardiogr*. 2022;35(6):533-569. doi:10.1016/j.echo.2022.03.012.
26. Chung MK, Patton KK, Lau CP, et al. 2023 HRS/APHRS/LAHRs guideline on cardiac physiologic pacing for the avoidance and mitigation of heart failure [published online ahead of print, 2023 May 20]. *Heart Rhythm*. 2023;S1547-5271(23)02026-X. doi:10.1016/j.hrthm.2023.03.1538.
27. Cronin EM, Bogun FM, Maury P, et al. 2019 HRS/EHRA/APHRS/LAHRs expert consensus statement on catheter ablation of ventricular arrhythmias: Executive summary. *Heart Rhythm*. Jan 2020;17(1):e155-e205. doi:10.1016/j.hrthm.2019.03.015.
28. Faqih SA, Noto-Kadou-Kaza B, Abouamrane LM, Mtiou N, El Khayat S, Zamd M, Medkouri G, Benghanem MG, Ramdani B. Pulmonary hypertension: prevalence and risk factors. *Int J Cardiol Heart Vasc*. 2016 May 9;11:87-89.
29. Heidenreich PA, Bozkurt B, Aguilar D, et al. 2022 AHA/ACC/HFSA guideline for the management of heart failure: a report of the American College of Cardiology/American Heart Association Joint Committee on Clinical Practice Guidelines. *Circulation*. 2022;145:e895-e1032. doi: 10.1161/CIR.0000000000001063.
30. Shovlin CL, Condliffe R, Donaldson JW on behalf of the British Thoracic Society, et al. British Thoracic Society Clinical Statement on Pulmonary Arteriovenous Malformations. *Thorax* 2017;72:1154-1163. doi:10.1136/thoraxjnl-2017-210764.
31. Cheng XS, VanWagner LB, Costa SP, et al. Emerging Evidence on Coronary Heart Disease Screening in Kidney and Liver Transplantation Candidates: A Scientific Statement From the American Heart Association: Endorsed by the American Society of Transplantation. *Circulation*. 2022;146(21):e299-e324. doi:10.1161/CIR.0000000000001104.
32. Humbert M, Kovacs G, Hoeper M, et al. 2022 ESC/ERS Guidelines for the diagnosis and treatment of pulmonary hypertension: Developed by the task force for the diagnosis and treatment of pulmonary hypertension of the European Society of Cardiology (ESC) and the European Respiratory Society (ERS). Endorsed by the International Society for Heart and Lung Transplantation (ISHLT) and the European Reference Network on rare respiratory diseases (ERN-LUNG). *Eu Heart J* 2022; 43(38) 3618–3731. doi.org/10.1093/eurheartj/ehac237.
33. Billey C, Billet S, Robic MA, et al. A Prospective Study Identifying Predictive Factors of Cardiac Decompensation After Transjugular Intrahepatic Portosystemic Shunt: The Toulouse Algorithm, *Hepatology* 2019; 70(6)1928-1941. doi.org/10.1002/hep.30934.
34. Boie JR, Thornburg BG, Asrani SK, et al. North American Practice-Based Recommendations for Transjugular Intrahepatic Portosystemic Shunts in Portal Hypertension. *Clinical Gastroenterology and Hepatology* 2022;20(8)1636-1662. doi.org/10.1016/j.cgh.2021.07.018.

Nuclear Cardiac Imaging

Guideline

Myocardial Perfusion Imaging (MPI)(CD-3.1)(CD-3.2)

MUGA – Coding (CD-3.3)

MUGA Study – Cardiac Indications (CD-3.4)

Myocardial Sympathetic Innervation Imaging in Heart Failure (CD-3.6)

Myocardial Tc-99m Pyrophosphate Imaging (CD-3.7)

Cardiac Amyloidosis (CD-3.8)

Non-imaging Heart Function and Cardiac Shunt Imaging (CD-1.7)

References (CD-3)

Myocardial Perfusion Imaging (MPI) (CD-3.1)(CD-3.2)

CD.NC.0003.1.A

v2.1.2024

Myocardial Perfusion Imaging (MPI) – Coding (CD-3.1)

Nuclear Cardiac Imaging Procedure Codes	
Myocardial Perfusion Imaging (MPI)	CPT®
MPI, tomographic (SPECT) (including attenuation correction, qualitative or quantitative wall motion, ejection fraction by first pass or gated technique, additional quantification, when performed); single study, at rest or stress (exercise or pharmacologic)	78451
MPI, tomographic (SPECT) (including attenuation correction, qualitative or quantitative wall motion, ejection fraction by first pass or gated technique, additional quantification, when performed); multiple studies, at rest and/or stress (exercise or pharmacologic) and/or redistribution and/or rest reinjection	78452
Absolute quantitation of myocardial blood flow (AQMBF), single-photon emission computed tomography (SPECT), with exercise or pharmacologic stress, and at rest, when performed (List separately in addition to code for primary procedure)	+0742T

- The most commonly performed myocardial perfusion imaging are single (at rest or stress, CPT® 78451) and multiple (at rest and stress, CPT® 78452) SPECT studies.
 - Evaluation of the individual’s left ventricular wall motion and ejection fraction are routinely performed during MPI and are included in the code’s definition.
 - First pass studies, (CPT® 78481 and CPT® 78483), MUGA, (CPT® 78472 and CPT® 78473) and SPECT MUGA (CPT® 78494) should not be reported in conjunction with MPI codes.
 - Attenuation correction, when performed, is included in the MPI service by code definition. No additional code should be assigned for the billing of attenuation correction.

- **Multi-day Studies:** In the absence of written payer guidelines to the contrary, it is not appropriate to bill separately for the rest and stress segments of MPI even if performed on separate calendar dates. A single code is assigned to define the entire procedure on the date all portions of the study are completed.

Note 3D rendering should not be billed in conjunction with MPI.

MPI – Indications (CD-3.2)

See: **Stress Testing with Imaging – Indications (CD-1.4)**

Absolute quantitation of myocardial blood flow (AQMBF)(SPECT)

- AQMBF obtained by CZT-SPECT is considered experimental, investigational, or unproven at this time.

References

1. Bailly M, Thibault F, Courtehoux M, Metrard G, Ribeiro MJ. Impact of attenuation correction for CZT-SPECT measurement of myocardial blood flow. J Nucl Cardiol. 2021;28(6):2560-2568. doi:10.1007/s12350-020-02075-7.
2. Acampa W, Zampella E, Assante R, et al. Quantification of myocardial perfusion reserve by CZT-SPECT: A head to head comparison with 82Rubidium PET imaging. J Nucl Cardiol. 2021;28(6):2827-2839. doi:10.1007/s12350-020-02129-w.
3. Wang L, Zheng Y, Zhang J, et al. Diagnostic value of quantitative myocardial blood flow assessment by NaI(Tl) SPECT in detecting significant stenosis: a prospective, multi-center study [published online ahead of print, 2022 Aug 15]. J Nucl Cardiol. 2022;10.1007/s12350-022-03085-3. doi:10.1007/s12350-022-03085-3.
4. Pang Z, Wang J, Li S, Chen Y, Wang X, Li J. Diagnostic analysis of new quantitative parameters of low-dose dynamic myocardial perfusion imaging with CZT SPECT in the detection of suspected or known coronary artery disease. Int J Cardiovasc Imaging. 2021 Jan;37(1):367-378. doi: 10.1007/s10554-020-01962-x. Epub 2020 Sep 10. PMID: 32914404; PMCID: PMC7878253.

MUGA – Coding (CD-3.3)

CD.NC.0003.3.A
v2.1.2024

Cardiac blood pool imaging, or radionuclide ventriculography, can be used to evaluate ventricular function. Cardiac blood pool imaging includes first pass studies (CPT® 78481 and 78483) as well as gated equilibrium studies (CPT® 78472, 78473, 78494, and +78496).

Gated equilibrium studies can also be referred to as multi-gated acquisition (MUGA) scan or equilibrium radionuclide angiography (ERNA). Imaging for gated equilibrium studies can be planar or three-dimensional (single photon emission computed tomography, SPECT).

Of note, all cardiac blood pool imaging is synchronized with electrocardiographic RR interval (EKG-gated); thus, regular rhythm is required for accurate LV assessment.

Gated Equilibrium Studies – Planar	CPT®
Cardiac blood pool imaging, gated equilibrium; planar, single study at rest or stress, wall motion study plus ejection fraction, with or without quantitative processing	78472
Cardiac blood pool imaging, gated equilibrium; planar, multiple studies, wall motion study plus ejection fraction, at rest and stress , with or without additional quantification	78473
Gated Equilibrium Studies - SPECT	CPT®
Cardiac blood pool imaging, gated equilibrium, SPECT, at rest, wall motion study plus ejection fraction, with or without quantitative processing	78494
First Pass studies	CPT®
Cardiac blood pool imaging (planar), first pass technique; single study, at rest or with stress (exercise and/or pharmacologic), wall motion study plus ejection fraction, with or without quantification	78481
Cardiac blood pool imaging (planar), first pass technique; multiple studies, at rest and with stress (exercise and/or pharmacologic), wall motion study plus ejection fraction, with or without quantification	78483
Cardiac blood pool imaging, gated equilibrium, single study , at rest, with right ventricular ejection fraction by first pass technique (List separately in addition to code for primary procedure) This CPT code is an add-on code to 78472.	+78496

- The technique employed for a MUGA service guides the code assignment.
 - CPT® 78472 is used for a planar MUGA scan at rest or stress
 - CPT® 78473 for planar MUGA scans, multiple studies at rest and stress.

- Planar MUGA studies (CPT® 78472 and CPT® 78473) should not be reported in conjunction with:
 - SPECT MPI (CPT® 78451 - CPT® 78454)
 - First pass studies (CPT® 78481- CPT® 78483)
 - SPECT MUGA (CPT® 78494).
- CPT® +78496 is assigned only in conjunction with CPT® 78472.

MUGA Study – Cardiac Indications (CD-3.4)

CD.NC.0003.4.A

v2.1.2024

MUGA (Multi Gated Acquisition) – Blood Pool Imaging Indications

- Echocardiography is the preferred method of following left ventricular systolic function.
- MUGA may be indicated when a recent ECHO, as indicated in **Transthoracic Echocardiography (TTE) – Indications (CD-2.2)** and/or **Frequency of Echocardiography Testing (CD 2.3)**, was technically limited and prevented accurate assessment of left ventricular function.
- MUGA is indicated when there is a significant discrepancy between LVEF assessment by ECHO and another modality (i.e., one study reports normal LVEF and the other, a reduced LVEF) AND there is clear documentation as to how quantitative measurement of LVEF will affect individual management (e.g., implantation of an ICD, alteration in cardiotoxic chemotherapy, etc.).
- MUGA may be performed in place of an ECHO in the following circumstances:
 - To determine candidacy for ICD/CRT and/or to determine optimal choice of device in individuals who meet criteria for ICD based on ejection fraction and other criteria.
 - When previously or currently undergoing therapy with potentially cardiotoxic agents, including chemotherapy and radiation, AND a history of previous low LV ejection fraction (LVEF <50%). See **Cardiotoxic agent/Cancer Therapeutics-Related Cardiac Dysfunction (CD-12.1)**
- MUGA is **not** indicated when requested simply to compare LVEF by the same modality, a prior MUGA is not a reason to approve another MUGA.

Right ventricular first pass study

- (CPT® 78472 and 78496) may be performed when ECHO is technically limited and prevents accurate assessment of RV function AND when further information about RV function is needed to guide management (e.g. established/diagnosed pulmonary hypertension, suspected or confirmed pulmonary embolus).

First pass studies

- First pass studies (CPT® 78481 and CPT® 78483) may be approved in place of MUGA when indications are met for MUGA and/or there is need for information that cannot be obtained by MUGA.

- First pass studies, (CPT® 78481 and CPT® 78483), MUGA (CPT® 78472 and CPT® 78473) and SPECT MUGA (CPT® 78494) should not be reported in conjunction with MPI codes.

Myocardial Sympathetic Innervation Imaging in Heart Failure (CD-3.6)

CD.CS.0009.A

v2.1.2024

- Nuclear imaging using I-123-meta-iodobenzylguanidine (I-123-mIBG) in an attempt to image increased myocardial sympathetic activity is considered to be experimental and investigational.
- The AMA has established the following set of Category III codes to report these studies:
 - **0331T** - Myocardial sympathetic innervation imaging, planar qualitative and quantitative assessment
 - **0332T** - Myocardial sympathetic innervation imaging, planar qualitative and quantitative assessment; with tomographic SPECT.

Background and supporting information

In heart failure, the sympathetic nervous system is activated in order to compensate for the decreased myocardial function. Initially, this is beneficial, however, long-term this compensatory mechanism is detrimental and causes further damage.

Markers have been developed, using radioactive iodine, in an attempt to image this increased myocardial sympathetic activity. Currently, AdreView™ (Iodine-123 meta-iodobenzylguanidine), is the only FDA-approved imaging agent available for this purpose.

Myocardial Tc-99m Pyrophosphate Imaging (CD-3.7)

CD.NC.0003.7.A

v2.1.2024

Myocardial Tc-99m Pyrophosphate Imaging	
MUGA (Multi Gated Acquisition) – Blood Pool Imaging	CPT®
Myocardial Imaging, infarct avid, planar, qualitative or quantitative	78466
Myocardial Imaging, infarct avid, planar, qualitative or quantitative with ejection fraction by first pass technique	78468
Myocardial Imaging, infarct avid, planar, qualitative or quantitative tomographic SPECT with or without quantification	78469
Radiopharmaceutical Localization Imaging Limited area	78800
Radiopharmaceutical Localization Imaging SPECT Note: When reporting CPT® 78803, planar imaging of a limited area or multiple areas should be included with the SPECT	78803
Radiopharmaceutical localization of tumor, inflammatory process or distribution of radiopharmaceutical agent(s) (includes vascular flow and blood pool imaging, when performed); tomographic (SPECT) with concurrently acquired computed tomography (CT) transmission scan for anatomical review, localization and determination/detection of pathology, single area (e.g., head, neck, chest, pelvis), single-day imaging	78830

- Historically this method of imaging the myocardium was used to identify recent infarction, hence, the term "infarct-avid scan." Although still available, the sensitivity and specificity for identifying infarcted myocardial tissue are variable and the current use for this indication is limited. See [Cardiac MRI \(CD-5\)](#).

Cardiac Amyloidosis (CD-3.8)

CD.NC.0003.8.A

v2.1.2024

- Tc-99m pyrophosphate imaging (CPT[®] 78803 or 78830) may be used to identify cardiac amyloidosis. Chest SPECT and planar imaging may be used, as well as whole-body imaging for identification of systemic ATTR (transthyretin) amyloidosis. See **Myocardial Tc-99m Pyrophosphate Imaging (CD-3.7)** for coding information
- For a single planar imaging session alone (without a SPECT study), report CPT[®] 78800 Radiopharmaceutical Localization Imaging Limited area
- Tc-99m pyrophosphate imaging can be pursued for diagnosis of ATTR amyloidosis in the presence of known systemic amyloidosis if Cardiac MRI (CMR) is either contraindicated or indeterminate in individuals undergoing evaluation for kidney transplant. See **Kidney Transplant, Pre-Transplant Imaging Studies (AB-42.5)**.
- Tc-99m pyrophosphate imaging can be pursued for diagnosis of ATTR amyloidosis after screening for presence of a monoclonal light chain to exclude AL amyloidosis:
 - Serum kappa/lambda free light chain ratio (not SPEP)
 - Abnormal if ratio is <0.26 or >1.65
 - Serum and urine immunofixation electrophoresis (IFE)
 - Abnormal if monoclonal protein detected
- Tc-99m pyrophosphate imaging may also be used for the following:
 - Diagnosis of cardiac ATTR in individuals with cardiac MRI or echocardiography findings consistent with or suggestive of cardiac amyloidosis.
 - Individuals with suspected cardiac ATTR amyloidosis and contraindications to CMR such as renal insufficiency or an implantable cardiac device.
 - Individuals with systemic amyloidosis who are being evaluated for kidney transplant if CMR is either contraindicated or indeterminate. See **Kidney Transplant, Pre-Transplant Imaging Studies (AB-42.5)**.
- Cardiac follow-up should be based on Echocardiogram, Tn, NT-proBNP, clinical exam and symptoms

Background and supporting information

- The following conditions would raise high index of suspicion:
 - Left ventricular hypertrophy but low voltage on ECG
 - Heart failure with preserved ejection fraction and an increase in left ventricular wall thickness.
 - Unexplained heart failure with preserved ejection fraction and concomitant right heart failure in an individual over the age of 60
 - Individuals, especially elderly males, with signs/symptoms of heart failure and any of the following:
 - Lumbar spinal stenosis

- Spontaneous biceps tendon rupture
- Bilateral carpal tunnel syndrome
- Atrial arrhythmia in the absence of usual risk factors
- Known or suspected familial amyloidosis.
- Low flow, low gradient aortic stenosis

Non-imaging Heart Function and Cardiac Shunt Imaging (CD-1.7)

CD.NC.0001.7.A

v2.1.2024

- Procedures reported with CPT® 78414 and CPT® 78428 are essentially obsolete and should not be performed in lieu of other preferred modalities.
- Echocardiogram is the preferred method for cardiac shunt detection, rather than the cardiac shunt imaging study described by CPT® 78428.
- Ejection fraction can be obtained by echocardiogram, SPECT MPI, MUGA study, cardiac MRI, cardiac CT, or cardiac PET depending on the clinical situation, rather than by the non-imaging heart function study described by CPT® 78414.

References (CD-3)

v2.1.2024

1. American Association of Physicists in Medicine (AAPM) Report 96, January 2008. Report of AAPM Task Group 23, "The measurement, reporting and management of radiation dose in CT." https://www.aapm.org/pubs/reports/RPT_96.pdf.
2. Boden WE, O'Rourke RA, Teo KK, et al. Impact of optimal medical therapy with or without percutaneous coronary intervention on long-term cardiovascular end points in patients with stable coronary artery disease (from the COURAGE trial). *Am J Cardiol*, 2009 July; 104(1):1-4. doi.org/10.1016/j.amjcard.2009.02.059.
3. Guarneri V, Lenihan DJ, Valero V, et al. Long-term cardiac tolerability of trastuzumab in metastatic breast cancer: the M.D. Anderson Cancer Center experience. *J Clinical Oncology* 2006 Sept; 24:4107-4115. doi:10.1200/JCO.2005.04.9551.
4. Hendel RC, Berman DS, Carli MFD, et al. ACCF/ASNC/ACR/AHA/ASE/SCCT/SCMR/SNM 2009 Appropriate Use Criteria for Cardiac Radionuclide Imaging. *J Am Coll Cardiol*. 2009;53(23):2201-2229. doi:10.1016/j.jacc.2009.02.013.
5. Highlights of Prescribing Information HERCEPTIN® (trastuzumab) for injection, for intravenous use Initial U.S. Approval: 1998. Revised: April 2017. <http://www.gene.com/gene/products/information/pdf/herceptin-prescribing.pdf>.
6. Sciammarella MG, Gerson M, Buxton AE, et al. ASNC/SNMMI Model Coverage Policy: Myocardial sympathetic innervation imaging: Iodine-123 meta-iodobenzylguanidine ((123)I)-mIBG). *J Nucl Cardiol*. 2015;22(4):804-811. doi:10.1007/s12350-015-0202-8.
7. Bokhari S, Castano A, Pozniakoff T, et al. (99m)Tc-pyrophosphate scintigraphy for differentiating light-chain cardiac amyloidosis from the transthyretin-related familial and senile cardiac amyloidosis. *Circ Cardiovasc Imaging* 2013; 6:195. doi:10.1161/CIRCIMAGING.112.000132.
8. Plana JC, Galderisi M, Barac A, et al. Expert consensus for multimodality imaging evaluation of adult patients during and after cancer therapy: a report from the American Society of Echocardiography and the European Association of Cardiovascular Imaging. *European Heart Journal - Cardiovascular Imaging*. 2014;15(10):1063-1093. doi:10.1093/ehjci/jeu192.
9. Dorbala S, Bokhari S, Miller E, et al. 99mTechnetium-Pyrophosphate Imaging for Transthyretin Cardiac Amyloidosis. *ASNC PRACTICE POINTS 2016*. <https://www.asnc.org/Files/Practice%20Resources/Practice%20Points/ASNC%20Practice%20Point-99mTechnetiumPyrophosphateImaging2016.pdf>.
10. Rapezzi C, Quarta CC, Guidalotti PL, et al. Role of 99mTc-DPD Scintigraphy in Diagnosis and Prognosis of Hereditary Transthyretin-Related Cardiac Amyloidosis. *JACC: Cardiovascular Imaging*. 2011;4(6):659-670. doi:10.1016/j.jcmg.2011.03.016.
11. Dorbala S, Ananthasubramaniam K, Armstrong IS, et al. Single Photon Emission Computed Tomography (SPECT) Myocardial Perfusion Imaging Guidelines: Instrumentation, Acquisition, Processing, and Interpretation. *J Nuc Cardiol*. 2018. doi:10.1007/s12350-018-1283-y.
12. Doherty JU, Kort S, Mehran R, et al. ACC/AATS/AHA/ASE/ASNC/HRS/SCAI/SCCT/SCMR/STS 2019 Appropriate Use Criteria for Multimodality Imaging in the Assessment of Cardiac Structure and Function in Nonvalvular Heart Disease. *J Am Coll Cardiol*. 2019;73(4):488-516. doi:10.1016/j.jacc.2018.10.038.
13. Witteles RM, Liedtke M. AL Amyloidosis for the Cardiologist and Oncologist. *JACC: CardioOncology*. 2019;1(1):117-130. doi:10.1016/j.jacc.2019.08.002.
14. Ruberg FL, Grogan M, Hanna M, Kelly JW, Maurer MS. Transthyretin Amyloid Cardiomyopathy. *J Am Coll Cardiol*. 2019;73(22):2872-2891. doi:10.1016/j.jacc.2019.04.003.
15. Dorbala S, Cuddy S, Falk RH. How to Image Cardiac Amyloidosis. *JACC: Cardiovascular Imaging*. 2020;13(6):1368-1383. doi:10.1016/j.jcmg.2019.07.015.
16. Jitendra M. MUGA scan (CPT code 78472, 78473, 78494) Coding Tips. Medical Coding Guide. <https://www.americanmedicalcoding.com/muga-scan-cpt-code/>. Published November 10, 2020.
17. Kittleson MM, Maurer MS, Ambardekar AV, et al. Cardiac Amyloidosis: Evolving Diagnosis and Management: A Scientific Statement From the American Heart Association [published correction appears in *Circulation*. 2021 Jul 6;144(1):e10] [published correction appears in *Circulation*. 2021 Jul 6;144(1):e11]. *Circulation*. 2020;142(1):e7-e22. doi:10.1161/CIR.0000000000000792.
18. Kidney Disease: Improving Global Outcomes (KDIGO) Kidney Transplant Candidate Work Group. KDIGO Clinical Practice Guideline on the Evaluation and Management of Candidates for Kidney Transplantation. *Transplantation*. 2020;104: S1 – S103.
19. Fleisher LA, Fleischmann KE, Auerbach AD, et al. 2014 ACC/AHA guideline on perioperative cardiovascular evaluation and management of patients undergoing noncardiac surgery: a report of the American College of Cardiology/American Heart Association Task Force on practice guidelines. *J Am Coll Cardiol* 2014; 64:e77.

20. Winchester DE, Maron DJ, Blankstein R, et al. ACC/AHA/ASE/ASNC/ASPC/HFSA/HRS/SCAI/SCCT/SCMR/STS 2023 Multimodality Appropriate Use Criteria for the Detection and Risk Assessment of Chronic Coronary Disease: A Report of the American College of Cardiology Solution Set Oversight Committee, American Heart Association, American Society of Echocardiography, American Society of Nuclear Cardiology, American Society of Preventive Cardiology, Heart Failure Society of America, Heart Rhythm Society, Society for Cardiovascular Angiography and Interventions, Society of Cardiovascular Computed Tomography, Society for Cardiovascular Magnetic Resonance, and Society of Thoracic Surgeons. *J Am Coll Cardiol* 2023;May 25:[Epub ahead of print].
21. Blanke P, Weir-McCall JR, Achenbach S, et al. Computed tomography imaging in the context of transcatheter aortic valve implantation (TAVI) / transcatheter aortic valve replacement (TAVR): An expert consensus document of the Society of Cardiovascular Computed Tomography. *J Cardiovasc Comput Tomogr*. 2019;13(1):1-20. doi:10.1016/j.jcct.2018.11.008.

Cardiac CT

Guideline

- Cardiac CT and CTA - General information and coding (CD-4.1)
- CT for Coronary Calcium Scoring (CD-4.2)
- CCTA – Indications for CCTA (CD-4.3)
- CCTA – Regardless of symptoms (CD-4.4)
- Fractional Flow Reserve by Computed Tomography (CD-4.5)
- CT Heart – Indications (CPT® 75572) (CD-4.6)
- CT Heart for Congenital Heart Disease (CD-4.7)
- Transcatheter aortic valve replacement (TAVR) (CD-4.8)
- 3D Predictive model generation for pre-planning of cardiac procedure (CD-4.9)
- References (CD-4)

Cardiac CT and CTA - General information and coding (CD-4.1)

CD.CT.0004.1.A

v2.1.2024

Guideline

Associated Codes

Cardiac CT and CTA - General information (CD-4.1)

Associated Codes

Cardiac Imaging Procedure Codes

Cardiac CT and CCTA	CPT®
<p>CT, heart, without contrast, with quantitative evaluation of coronary calcium</p> <ul style="list-style-type: none"> The code set for Cardiac CT and CCTA (CPT® 75572-CPT® 75574), include quantitative and functional assessment (for example, calcium scoring) if performed CPT® 75571 describes a non-contrast CT of the heart with calcium scoring and should be reported only when calcium scoring is performed as a stand-alone procedure. <ul style="list-style-type: none"> Can be used to report a preliminary non-contrast scan which indicates an excessive amount of calcium such that the original scheduled study must be discontinued. CPT® 75571 should not be reported in conjunction with any of the contrast CT/CTA codes (CPT® 75572- CPT® 75574). 	75571
CT, heart, with contrast, for evaluation of cardiac structure and morphology (including 3D image post-processing, assessment of cardiac function, and evaluation of venous structures, if performed).	75572
Computed tomography, heart, with contrast material, for evaluation of cardiac structure and morphology in the setting of congenital heart disease (including 3D image post-processing, assessment of left ventricular [LV] cardiac function, right ventricular [RV] structure and function and evaluation of vascular structures, if performed).	75573
CTA, heart, coronary arteries and bypass grafts (when present), with contrast, including 3D image post-processing (including 3D image post-processing, assessment of cardiac function, and evaluation of venous structures, if performed).	75574

Cardiac CT and CCTA	CPT®
Noninvasive estimate of coronary fractional flow reserve (FFR) derived from augmentative software analysis of the data set from a coronary computed tomography angiography, with interpretation and report by a physician or other qualified health care professional	75580

Cardiac Imaging Procedure Codes

Description	CPT®
Automated quantification and characterization of coronary atherosclerotic plaque to assess severity of coronary disease, using data from coronary computed tomographic angiography; data preparation and transmission, computerized analysis of data, with review of computerized analysis output to reconcile discordant data, interpretation and report	0623T
Automated quantification and characterization of coronary atherosclerotic plaque to assess severity of coronary disease, using data from coronary computed tomographic angiography; data preparation and transmission	0624T
Automated quantification and characterization of coronary atherosclerotic plaque to assess severity of coronary disease, using data from coronary computed tomographic angiography; computerized analysis of data from coronary computed tomographic angiography	0625T
Automated quantification and characterization of coronary atherosclerotic plaque to assess severity of coronary disease, using data from coronary computed tomographic angiography; review of computerized analysis output to reconcile discordant data, interpretation and report	0626T

Cardiac CT and CTA - General information (CD-4.1)

- Only one code from the set: CPT® 75572 - CPT® 75574 can be reported per encounter.
- CPT® 75574 includes evaluation of cardiac structure and morphology when performed; therefore, additional code/s should not be assigned.
- Automated quantification and characterization of coronary atherosclerotic plaque (CPT® 0623T, 0624T, 0625T, 0626T) is a service in which coronary computed tomographic angiography (CCTA) data are analyzed using computerized algorithms to assess the extent and severity of coronary artery disease. The use of automated quantification and characterization of coronary atherosclerotic plaque is considered investigational and experimental at this time.

Background and Supporting Information

The high negative predictive value (98%-99%) of CCTA in ruling out significant coronary artery disease has been confirmed in multiple studies.

3D rendering should not be billed in conjunction with Cardiac CT and CCTA.

CT for Coronary Calcium Scoring (CD-4.2)

CD.CT.0004.2.A

v2.1.2024

CPT® 75571

Coronary artery calcium score (CPT® 75571) is **not** supported for evaluation of CAD in symptomatic individuals.

CT Calcium Scoring-Asymptomatic and for CAD Screening

- Coronary artery calcium score (CPT® 75571) is indicated when there is documentation of **all** of the following:
 - Results will impact risk-based decisions for preventive interventions
 - An LDL-C level ≥ 70 mg/dL (1.8 mmol/L) AND < 190 mg/dL (4.9 mmol/L)
 - Individual is an adult age 40-75
 - 10-year ASCVD risk including pooled cohort equation is between 5.0% to 19.9%
 - There is no documented CAD
 - Individual is not currently on a statin
 - Individual is not a smoker
 - There is no history of diabetes
 - There is no family history of premature CAD
 - There has been no calcium score performed in the previous 5 years
 - There has been no prior calcium score > 0
- Coronary calcium scoring is **not** indicated in someone with known CAD.

CT Calcium Scoring For Low Gradient Aortic Stenosis

- Coronary artery calcium score (CPT® 75571) is indicated in low gradient aortic stenosis when symptomatic, severe aortic stenosis is suspected. Low gradient aortic stenosis is defined as an AVA < 1 and a mean gradient < 40 mmHg.

CCTA – Indications for CCTA (CD-4.3)

CD.CT.0004.3.A

v2.1.2024

CCTA (CPT® 75574) is indicated for any of the following:

- New, recurrent or worsening likely anginal symptoms as defined in **General Guidelines (CD-1.0)**
- New, recurrent or worsening symptoms of chest pain, or exertional dyspnea, or exertional fatigue and any of the following:
 - Persistent symptoms after a normal stress test
 - Equivocal, borderline, abnormal or discordant prior noninvasive evaluation where obstructive coronary artery disease remains a concern (<90 days)
 - Abnormal rest ECG findings, such as a new LBBB, or T-wave inversions, when ischemia is a concern
 - A prior CABG when **only** graft patency is a concern
- Evaluation of an individual under the age of 40 for suspected anomalous coronary artery(ies) or for treatment planning when there is a history of one or more of the following:
 - Syncopal episodes during strenuous activities
 - Persistent chest pain brought on by exertion or emotional stress, and normal stress test
 - Full sibling(s) with history of sudden death syndrome before age 40 or with documented anomalous coronary artery
 - Resuscitated sudden death and contraindications for conventional coronary angiography
 - Prior nondiagnostic coronary angiography in determining the course of the anomalous coronary artery in relation to the great vessels, origin of a coronary artery or bypass graft location (any):
 - Anomalies of origin:
 - LCA or the RCA arising from the pulmonary artery;
 - Interarterial course between the pulmonary artery and the aorta of either the RCA arising from the left sinus of Valsalva or the LCA arising from the right sinus of Valsalva
 - Anomalies of course:
 - Myocardial bridging
 - Anomalies of termination:
 - Coronary artery fistula
- Initial imaging study in individuals with hypertrophic cardiomyopathy and stable anginal symptoms.
 - Chest discomfort is common in individuals with hypertrophic cardiomyopathy. The incidence of false positive myocardial perfusion imaging abnormalities is

higher in these individuals, whereas the incidence of severe coronary artery stenosis is low.

- Individuals who have recovered from unexplained sudden cardiac arrest in lieu of invasive coronary angiography (**both**):
 - Confirm the presence or absence of ischemic heart disease
 - Exclude the presence of an anomalous coronary artery.

CCTA – Regardless of symptoms (CD-4.4)

CD.CT.0004.4.A

v2.1.2024

(CPT® 75574)

- Evaluation of newly diagnosed congestive heart failure or cardiomyopathy (all):
 - No prior history of coronary artery disease, the ejection fraction is <50 percent
 - No contraindications to cardiac CT angiography.
 - No cardiac catheterization, SPECT, cardiac PET, or stress echocardiogram has been performed since the diagnosis of congestive heart failure or cardiomyopathy.
- Unclear coronary artery anatomy despite conventional cardiac catheterization
- Re-do CABG (**either**)
 - Assess bypass graft patency
 - Evaluate the location of the left internal mammary artery (LIMA) and or right internal mammary artery (RIMA) prior to repeat bypass surgery
- Follow-up Left main stent one time at 6-12 months
- Evaluate coronary artery anomalies and other complex congenital heart disease of cardiac chambers or great vessels:
 - Report CPT® 75574 for evaluating coronary artery anomalies.
 - Report CPT® 75573 for congenital heart disease.
 - To evaluate the great vessels, CTA Chest (CPT® 71275) can be performed instead of CCTA or in addition to CCTA.
 - For anomalous pulmonary venous return, can add CT Abdomen and Pelvis with contrast (CPT® 74177).
- When CCTA will replace conventional invasive coronary angiography for any of the following:
 - Ventricular tachycardia (6-beat runs or greater)
 - Delayed presentation or retrospective evaluation of suspected Takotsubo syndrome (stress cardiomyopathy)
 - Preoperative assessment of the coronary arteries in planned surgery for any of the following:
 - Aortic dissection
 - Aortic aneurysm
 - Valvular surgery
 - Liver transplant (for initial pre-transplant evaluation and may be repeated once in 3 years)

- To assess for coronary involvement in individuals with systemic vasculitis (e.g. Giant Cell Arteritis, Takayasu's, Kawasaki's disease) when there are clinical features suggestive of underlying vasculitis including:
 - Unexplained elevated cardiac markers (erythrocyte sedimentation rate, C-reactive protein)
 - Constitutional symptoms (fever, chills, night sweats, weight loss)
 - Multiple visceral infarcts in the absence of embolic etiology
- **Cardiac Trauma:** CTA Chest (CPT® 71275) and CCTA (CPT® 75574) are useful in detecting aortic and coronary injury and can help in the evaluation of myocardial and pericardial injury see **Cardiac Trauma – Imaging (CD-10.1)**
- Preoperative assessment for planned liver or kidney transplant

Fractional Flow Reserve by Computed Tomography (CD-4.5)

CD.CT.0004.5.A

v2.1.2024

Fractional flow reserve (FFR) (CPT® 75580) is typically measured using invasive techniques. FFR can be obtained noninvasively from coronary computed tomography angiography data (FFR-CT).

- Indications for FFR-CT:
 - To further assess CAD seen on a recent CCTA that is of uncertain physiologic significance

CT Heart – Indications (CPT® 75572) (CD-4.6)

CD.CT.0004.6.A

v2.1.2024

CT heart – indications

- Cardiac vein identification for lead placement in individuals needing left ventricular pacing.
- Pulmonary vein isolation procedure (ablation) for atrial fibrillation:
 - MRI Cardiac (CPT® 75557 or CPT® 75561), MRV Chest (CPT® 71555), CTV Chest (CPT® 71275), or CT Cardiac (CPT® 75572) can be performed to evaluate the anatomy of the pulmonary veins prior to an ablation procedure performed for atrial fibrillation.
 - Study may be repeated post-procedure between 3-6 months after ablation because of a 1%-2% incidence of asymptomatic pulmonary vein stenosis
 - See **Pulmonary Vein Imaging – Indications (CD-8.2)**
- If echocardiogram is inconclusive for:
 - Cardiac or pericardial tumor or mass
 - Cardiac thrombus
 - Pericarditis/constrictive pericarditis
 - Complications of cardiac surgery
- In place of MRI when there is clinical suspicion of arrhythmogenic right ventricular dysplasia or arrhythmogenic cardiomyopathy (ARVD/ARVC) if the clinical suspicion is supported by established criteria for ARVD-see **Cardiac MRI – Indications (excluding Stress MRI) (CD-5.2)**
- Recurrent laryngeal nerve palsy due to cardiac chamber enlargement.
- CT Cardiac (CPT® 75572) can be performed instead of TEE for assessment of left atrial appendage (LAA) occlusion device or to assess for thrombus, see: **Transesophageal Echocardiography (TEE) – Indications (CD-2.5)**
- Coronary imaging is not included in the code definition for CPT® 71275.
 - The AMA definition for CPT® 71275 reads: "CTA Chest (non-coronary), with contrast material(s), including non-contrast images, if performed, and image post-processing."

CT Heart for Congenital Heart Disease (CD-4.7)

CD.CT.0004.7.A

v2.1.2024

CT Heart for Congenital Heart Disease (CPT® 75573) (CD-4.7)

- Coronary artery anomaly evaluation
 - A cardiac catheterization was performed, and not all coronary arteries were identified.
- Thoracic arteriovenous anomaly evaluation
 - A MRI Cardiac or CT angiogram Chest was performed and suggested congenital heart disease.
- Complex adult congenital heart disease evaluation
 - No CT Cardiac or MRI Cardiac has been performed, and there is a contraindication to MRI Cardiac.
 - A CT Cardiac or MRI Cardiac was performed one year ago or more.
- See also section **Adult Congenital Heart Disease (CD-11)**

Transcatheter aortic valve replacement (TAVR) (CD-4.8)

CD.CT.0004.8.A

v2.1.2024

Pre-surgical aortic valve replacement

- Once the decision has been made for aortic valve replacement, the following may be used to determine if an individual is a candidate for TAVR:
 - CTA Chest (CPT® 71275), Abdomen and Pelvis (combination code CPT® 74174) are indicated, and
 - CT Cardiac (CPT® 75572) is indicated to measure the aortic annulus or
 - Coronary CTA (CCTA CPT® 75574) is indicated to both measure the aortic annulus and assess the coronary arteries in lieu of heart catheterization
- A repeat diagnostic left heart catheterization is **not** medically necessary when the individual is undergoing a transcatheter aortic valve replacement (TAVR).

Transfemoral access not feasible

Alternative imaging can be obtained to evaluate vascular access for TAVR in individuals for whom it is documented either via the office note or prior imaging that transfemoral access would not be feasible due to **any** of the following exclusion criteria:

- Small vessels
- Highly calcified vessels
- Stenosed or occluded vessels
- Prior aortoiliac vascular intervention

Imaging is indicated based on the documented intended access site (transaxillary or transcarotid) and should be of the involved body areas. The following studies are indicated based on the documented planned access site:

- CTA of the Head (CPT® 70496) and/or Neck (CPT® 70498) for transcarotid access
- CTA of the Chest (CPT® 71275) and/or Upper extremity (CPT® 73206) for transaxillary access

Post-TAVR

CT Cardiac (CPT® 75572) is indicated:

- If any of the post-TAVR TTEs are indeterminate or raises a concern about any of the following:
 - Valve thrombosis
 - Infective endocarditis
 - Structural degeneration

- When a Valve in Valve implantation or surgical re-do AVR is being contemplated
- Routine CT surveillance or follow up for incidental Hypoattenuated Leaflet Thickening (HALT) with or without restricted leaflet motion, also referred to as Hypoattenuation Affecting Motion (HAM) is NOT recommended

3D Predictive model generation for pre-planning of cardiac procedure (CD 4.9)

CD.CT.0004.9.A

v2.1.2024

Coding

Description	HCPCS
3D predictive model generation for pre-planning of a cardiac procedure, using data from cardiac computed tomographic angiography with report	C9793

Criteria

3D predictive model generation for pre-planning of a cardiac procedure, using data from cardiac computed tomographic angiography is considered to be experimental, investigational or unproven.

Background and supporting information

Cardiac Computed Tomography Angiography is a 3D imaging acquisition, viewing and reporting system. Standard Cardiac Computed Tomography Angiography includes the viewing of 3D images. Currently, there is not enough data to support the use of 3D predictive model generation for pre-planning of cardiac procedures (CPT® C9793). It has not been shown to improve outcomes when compared with standard Cardiac Computed Tomography Angiography.

References

1. Sachdeva R, Armstrong AK, Arnaout R, et al. Novel Techniques in Imaging Congenital Heart Disease: JACC Scientific Statement. *J Am Coll Cardiol.* 2024;83(1):63-81. doi:10.1016/j.jacc.2023.10.025.
2. Jone, P, Gearhart, A, Lei, H. et al. Artificial Intelligence in Congenital Heart Disease: Current State and Prospects. *JACC Adv.* 2022 Dec, 1 (5) . doi:10.1016/j.jacadv.2022.100153.

References (CD-4)

v2.1.2024

1. Taylor AJ, Cerqueira M, Hodgson JM, et al. ACCF/SCCT/ACR/AHA/ASE/ASNC/ NASCI/SCAI/SCMR 2010 appropriate use criteria for cardiac computed tomography: a report of the American College of Cardiology Foundation Appropriate Use Criteria Task Force, the Society of Cardiovascular Computed Tomography, the American College of Echocardiography, the American Society of Nuclear Cardiology, the North American Society for Cardiovascular Imaging, the Society for Cardiovascular Angiography and Interventions, and the Society for Cardiovascular Magnetic Resonance. *J Am Coll Cardiol* 2010; 56:1864-1894. doi:10.1016/j.jacc.2010.07.005.
2. Curry SJ, Krist AH, Owens DK, et al. Risk Assessment for Cardiovascular Disease with Nontraditional Risk Factors. *Jama*. 2018;320(3):272-280. doi:10.1001/jama.2018.8359.
3. Boden WE, O'Rourke RA, Teo KK, et al. Impact of Optimal Medical Therapy With or Without Percutaneous Coronary Intervention on Long-Term Cardiovascular End Points in Patients With Stable Coronary Artery Disease (from the COURAGE Trial). *J Am Coll Cardiol*. 2009;104(1):1-4. doi:10.1016/j.amjcard.2009.02.059.
4. Einstein AJ, Henzlova MJ, Rajagopalan S. Estimating Risk of Cancer Associated with Radiation Exposure From 64-Slice Computed Tomography Coronary Angiography. *Jama*. 2007;298(3):317. doi:10.1001/jama.298.3.317.
5. Schlosser T, Konorza T, Hunold P, et al. Noninvasive visualization of coronary artery bypass grafts using 16-detector row computed tomography. *J Am Coll Cardiol*, 2004; 44:1224-1229. doi:10.1016/j.jacc.2003.09.075.
6. Douglas PS, DeBruyne B, Pontone G, Patel MR, et al. 1-year outcomes of FFRct-guided care in patients with suspected coronary disease: The PLATFORM Study. *J Am Coll Cardiol*, 2016; 68:435-45. doi:10.1016/j.jacc.2016.05.056.
7. Norgaard B, Leipsic J, Gaur S, et al. Diagnostic performance of noninvasive fractional flow reserve derived from coronary computed tomography angiography in suspected coronary artery disease. *J Am Coll Cardiol*, 2014; 63:1145-55. doi:10.1016/j.jacc.2013.11.043.
8. Ko BS, Cameron JD, Munnur RK, Wong DTL, et al. Cardiac CT: atherosclerosis to acute coronary syndrome. *J Am Coll Cardiol*. December 2016;4(6). doi:10.3978/j.issn.2223-3652.2014.11.03.
9. Holmes D Jr, Mack M, Kaul S, et al. 2012 ACCF/AATS/SCAI/STS expert consensus document on transcatheter aortic valve replacement. *J Am Coll Cardiol*, 2012; 59:1200. doi:10.1016/j.jacc.2012.01.001.
10. NICE medical technology advisory committee. Overview: HeartFlow FFRCT for estimating fractional flow reserve from coronary CT angiography: Guidance. NICE: National Institute for health and care excellence. <https://www.nice.org.uk/guidance/mtg32>. Published February 2017.
11. American College of Cardiology Foundation Task Force on Expert Consensus Documents, Mark DB, Berman DS, et al. ACCF/ACR/AHA/NASCI/SAIP/SCAI/SCCT 2010 expert consensus document on coronary computed tomographic angiography: a report of the American College of Cardiology Foundation Task Force on Expert Consensus Documents. *J Am Coll Cardiol*. 2010; 55:2663. doi:10.1161/CIR.0b013e3181d4b618.
12. Doherty JU, Kort S, Mehran R, Schoenhagen P, Soman P. ACC/AATS/AHA/ASE/ASNC/HRS/SCAI/SCCT/SCMR/STS 2017 Appropriate Use Criteria for Multimodality Imaging in Valvular Heart Disease. *Journal of Nuclear Cardiology*. 2017;24(6):2043-2063. doi:10.1007/s12350-017-1070-1.
13. The Medicare Learning Network®. MEDICARE PREVENTIVE SERVICES. Preventive Services Chart Medicare Learning Network®. ICN MLN006559. https://www.cms.gov/Medicare/Prevention/PrevntionGenInfo/medicare-preventive-services/MPS-QuickReferenceChart-1.html#CARDIO_DIS. Published June 2019.
14. Grundy SM, Stone NJ, Bailey AL, et al. 2018 AHA/ACC/AACVPR/AAPA/ABC/ACPM/ADA/AGS/APhA/ASPC/NLA/PCNA Guideline on the Management of Blood Cholesterol: A Report of the American College of Cardiology/American Heart Association Task Force on Clinical Practice Guidelines. *Circulation*. 2019;139(25). doi:10.1161/cir.0000000000000625.
15. Arnett DK, Blumenthal RS, Albert MA, et al. 2019 ACC/AHA Guideline on the Primary Prevention of Cardiovascular Disease. *Circulation*. 2019;140(11):e596-e646. doi:10.1161/cir.0000000000000678.
16. Korsholm K, Berti S, Iriart X, et al. Expert Recommendations on Cardiac Computed Tomography for Planning Transcatheter Left Atrial Appendage Occlusion. *JACC: Cardiovascular Interventions*. 2020;13(3):277-292. doi:10.1016/j.jcin.2019.08.054.
17. Koster MJ, Warrington KJ. Vasculitis of the Coronary Arteries. *American College of Cardiology Latest in Cardiology*. <https://www.acc.org/latest-in-cardiology/articles/2019/03/13/06/50/vasculitis-of-the-coronary-arteries>. Published March 13, 2019. Accessed July 29, 2020.

18. Opolski MP, Staruch AD, Jakubczyk M, et al. CT Angiography for the Detection of Coronary Artery Stenoses in Patients Referred for Cardiac Valve Surgery. *JACC: Cardiovascular Imaging*. 2016;9(9):1059-1070. doi:10.1016/j.jcmg.2015.09.028.
19. Stout KK, Daniels CJ, Aboulhosn JA, et al. 2018 AHA/ACC Guideline for the Management of Adults with Congenital Heart Disease: A Report of the American College of Cardiology/American Heart Association Task Force on Clinical Practice Guidelines. *Circulation*. 2019;139(14). doi:10.1161/cir.0000000000000603.
20. Al-Khatib SM, Stevenson WG, Ackerman MJ, et al. 2017 AHA/ACC/HRS Guideline for Management of Patients with Ventricular Arrhythmias and the Prevention of Sudden Cardiac Death. *Circulation*. 2018;138(13):e272-e391. doi:10.1161/cir.0000000000000549.
21. Gräni C, Buechel RR, Kaufmann PA, Kwong RY. Multimodality Imaging in Individuals with Anomalous Coronary Arteries. *JACC: Cardiovascular Imaging*. 2017;10(4):471-481. doi:10.1016/j.jcmg.2017.02.004.
22. Kim SY, Seo JB, Do K-H, et al. Coronary Artery Anomalies: Classification and ECG-gated Multi-Detector Row CT Findings with Angiographic Correlation. *RadioGraphics*. 2006;26(2):317-333. doi:10.1148/rg.262055068.
23. Ghadri JR, Kazakauskaitė E, Braunschweig S, et al. Congenital coronary anomalies detected by coronary computed tomography compared to invasive coronary angiography. *BMC Cardiovascular Disorders*. 2014;14(1). doi:10.1186/1471-2261-14-81.
24. Shariat M, Thavendiranathan P, Nguyen E, et al. Utility of coronary CT angiography in outpatients with hypertrophic cardiomyopathy presenting with angina symptoms. *J Cardiovasc Comput Tomogr*. 2014;8(6):429-437. doi:10.1016/j.jcct.2014.09.007.
25. Lyon AR, Bossone E, Schneider B, et al. Current state of knowledge on Takotsubo syndrome: a Position Statement from the Taskforce on Takotsubo Syndrome of the Heart Failure Association of the European Society of Cardiology. *European Journal of Heart Failure*. 2015;18(1):8-27. doi:10.1002/ehf.424.
26. Levine A, Hecht HS. Cardiac CT Angiography in Congestive Heart Failure. *Journal of Nuclear Medicine*. 2015;56(Supplement_4). doi:10.2967/jnumed.114.150441.
27. Hecht H, Blaha MJ, Berman DS, et al. Clinical indications for coronary artery calcium scoring in asymptomatic patients: Expert consensus statement from the Society of Cardiovascular Computed Tomography. *J Cardiovasc Comput Tomogr*. 2017;11(2):157-168. doi:10.1016/j.jcct.2017.02.010.
28. Williams MC, Kwiecinski J, Doris M, et al. Low-Attenuation Noncalcified Plaque on Coronary Computed Tomography Angiography Predicts Myocardial Infarction. *Circulation*. 2020;141(18):1452-1462. doi:10.1161/circulationaha.119.044720.
29. Daghm M, Bing R, Fayad ZA, Dweck MR. Noninvasive Imaging to Assess Atherosclerotic Plaque Composition and Disease Activity. *JACC: Cardiovasc Imaging*. 2020;13(4):1055-1068. doi:10.1016/j.jcmg.2019.03.033.
30. Shaw LJ, Blankstein R, Bax JJ, et al. Society of Cardiovascular Computed Tomography / North American Society of Cardiovascular Imaging – Expert Consensus Document on Coronary CT Imaging of Atherosclerotic Plaque. *J Cardiovasc Comput Tomogr*. 2020. doi:10.1016/j.jcct.2020.11.002.
31. Writing Committee Members, Otto CM, Nishimura RA, et al. 2020 ACC/AHA Guideline for the Management of Patients With Valvular Heart Disease: A Report of the American College of Cardiology/American Heart Association Joint Committee on Clinical Practice Guidelines [published correction appears in *J Am Coll Cardiol*. 2021 Feb 2;77(4):509] [published correction appears in *J Am Coll Cardiol*. 2021 Mar 9;77(9):1275]. *J Am Coll Cardiol*. 2021;77(4):e25-e197. doi:10.1016/j.jacc.2020.11.018
32. Blanke P, Weir-McCall JR, Achenbach S, et al. Computed tomography imaging in the context of transcatheter aortic valve implantation (TAVI) / transcatheter aortic valve replacement (TAVR): An expert consensus document of the Society of Cardiovascular Computed Tomography. *J Cardiovasc Comput Tomogr*. 2019;13(1):1-20. doi:10.1016/j.jcct.2018.11.008.
33. Cheng XS, VanWagner LB, Costa SP, et al. Emerging Evidence on Coronary Heart Disease Screening in Kidney and Liver Transplantation Candidates: A Scientific Statement from the American Heart Association. *Circulation*. 2022 Oct. 146:e299–e324. doi.org/10.1161/CIR.0000000000001104.
34. Kumamaru KK, Kondo T, Kumamaru H, et al. Repeat Coronary Computed Tomographic Angiography in Patients with a Prior Scan Excluding Significant Stenosis. *Circ Cardiovasc Imaging*. 2014;7:788-795. doi.org/10.1161/CIRCIMAGING.113.001549.
35. VanWagner LB, Harinstein ME, Runo JR, et al. Multidisciplinary approach to cardiac and pulmonary vascular disease risk assessment in liver transplantation: An evaluation of the evidence and consensus recommendations. *Am J Transplant*. 2018;18:30–42. doi.org/10.1111/ajt.14531.
36. Löffler AI, Gonzalez JA, Sundararaman SK, et al. Coronary Computed Tomography Angiography Demonstrates a High Burden of Coronary Artery Disease Despite Low-Risk Nuclear Studies in Pre-Liver Transplant Evaluation. *Liver Transplantation*. 2020 November; 26(11): 1398–1408. doi.org/10.1002/lt.25869.
37. Halvorsen S, Mehilli J, Cassese S, et al. 2022 ESC Guidelines on cardiovascular assessment and management of patients undergoing non-cardiac surgery. *Eur Heart J*. 2022;43(39):3826-3924. doi:10.1093/eurheartj/ehac270.

38. Multimodality Writing Group for Chronic Coronary Disease; Winchester DE, Maron DJ, Blankstein R, Chang IC, Kirtane AJ, Kwong RY, Pellikka PA, Prutkin JM, Russell R, Sandhu AT. ACC/AHA/ASE/ASNC/ASPC/HFSA/HRS/SCAI/SCCT/SCMR/STS 2023 Multimodality Appropriate Use Criteria for the Detection and Risk Assessment of Chronic Coronary Disease. *J Am Coll Cardiol*. 2023 Jun 27;81(25):2445-2467. doi: 10.1016/j.jacc.2023.03.410.
39. Virani SS et al. 2023 AHA/ACC/ACCP/ASPC/NLA/PCNA Guideline for the Management of Patients With Chronic Coronary Disease: A Report of the American Heart Association/American College of Cardiology Joint Committee on Clinical Practice Guidelines. *Circulation*. 2023 Aug 29;148(9):e9-e119. doi: 10.1161/CIR.0000000000001168. Epub 2023 Jul 20. Erratum in: *Circulation*. 2023 Sep 26;148(13):e148. Erratum in: *Circulation*. 2023 Dec 5;148(23):e186.
40. Yu MM et al. Prognostic value of coronary CT angiography in heart failure patients with preserved ejection fraction. *Eur Radiol*. 2023 May;33(5):3052-3063. doi: 10.1007/s00330-022-09380-4.
41. Sachdeva R, Armstrong AK, Arnaut R, et al. Novel Techniques in Imaging Congenital Heart Disease: JACC Scientific Statement. *J Am Coll Cardiol*. 2024;83(1):63-81. doi:10.1016/j.jacc.2023.10.025.
42. Jone P, Gearhart A, Lei H. et al. Artificial Intelligence in Congenital Heart Disease: Current State and Prospects. *JACC Adv*. 2022 Dec, 1 (5) . doi:10.1016/j.jacadv.2022.100153.

Cardiac MRI

Guideline

Cardiac MRI – Coding (CD-5.1)

Cardiac MRI and MRA Chest – Indications (excluding Stress MRI)
(CD-5.2)

Cardiac MRI – Indications for Stress MRI (CD-5.3)

Cardiac MRI – Aortic Root and Proximal Ascending Aorta (CD-5.4)

Cardiac MRI – Evaluation of Pericardial Effusion or Diagnosis of Pericardial
Tamponade (CD-5.5)

Cardiac MRI – Myocarditis (CD-5.6)

Cardiac MRI – Duchenne Muscular Dystrophy (DMD) (CD-5.7)

References (CD-5)

Cardiac MRI – Coding (CD-5.1)

CD.MRI.0005.1.A
v2.1.2024

Cardiac Imaging Procedure Codes	
Cardiac MRI	CPT®/HCPCS
Cardiac magnetic resonance imaging for morphology and function without contrast	75557
Cardiac magnetic resonance imaging for morphology and function without contrast; with stress imaging	75559
Cardiac magnetic resonance imaging for morphology and function without and with contrast and further sequences	75561
Cardiac magnetic resonance imaging for morphology and function without and with contrast and further sequences; with stress imaging	75563
Cardiac magnetic resonance imaging for velocity flow mapping (List separately in addition to code for primary procedure)	+75565
Cardiac magnetic resonance imaging for morphology and function, quantification of segmental dysfunction; with strain imaging	C9762
Cardiac magnetic resonance imaging for morphology and function, quantification of segmental dysfunction; with stress imaging	C9763

- Only one procedure code from the set (CPT® 75557- CPT® 75563) should be reported per session.
- Only one flow velocity measurement (CPT® +75565) should be reported per session when indicated.
- C9762--Cardiac magnetic resonance imaging for morphology and function, quantification of segmental dysfunction; with strain imaging. The use of CMR strain imaging for the quantification of segmental dysfunction is considered investigational and experimental at this time.
- C9763--Cardiac magnetic resonance imaging for morphology and function, quantification of segmental dysfunction; with stress imaging. The use of stress CMR for the quantification of segmental dysfunction is considered investigational and experimental at this time.

Cardiac MRI and MRA Chest – Indications (excluding Stress MRI) (CD-5.2)

CD.MRI.0005.2.A

v2.1.2024

- Assess myocardial viability (to differentiate hibernating myocardium from scar) when necessary to determine if revascularization should be performed (CPT® 75561)
- Assessment of global ventricular function, myocardial composition and mass if a specific clinical question is left unanswered by a recent echocardiogram and results will affect individual management (CPT® 75557 or CPT® 75561). Particularly useful in evaluating:
 - Cardiomyopathy (ischemic, diabetic, hypertrophic, or muscular dystrophy)
 - Non-compaction
 - Infiltrative heart disease such as amyloid, iron overload cardiomyopathy (hemosiderosis, hemochromatosis)
 - Post cardiac transplant
 - Hypertrophic cardiomyopathy
 - Suspected acute myocarditis, cardiac aneurysm, trauma, and contusions
 - Monitoring cancer chemotherapy effect on the heart (especially if an accurate assessment of right ventricular function is documented as necessary).
- Pre and post-operative congenital heart disease assessment see **Adult Congenital Heart Disease (CD-11)** for defect specific indications (CPT® 75557 or CPT® 75561).
 - MRA Chest (CPT® 71555) may be added if the aorta or pulmonary artery need to be visualized beyond the root.
 - May add CPT® +75565 in conjunction with CPT® 75557 or CPT® 75561, only if there is a need to clarify findings on a recent echocardiogram and cardiac Doppler study when there is documentation of **either** of the following:
 - Significant valvular disease that may require intervention
 - Intracardiac flow disturbances (e.g., ASD, VSD)
- MRA Chest (CPT® 71555) may be indicated for the following:
 - Thoracic aortic dissection see **Aortic Dissection and Other Aortic Conditions (PVD-6.7)** in the Peripheral Vascular Disease Imaging Guidelines
 - Coarctation of the aorta see:
 - **Coarctation of the Aorta (CD-11.3.2)** for adults
 - **Aortic Coarctation and IAA (interrupted aortic arch) (PEDCD-2.4.11)** for infants and children in the Pediatric Cardiac Imaging Guideline
 - Thoracic aortic aneurysm see **Thoracic Aortic Aneurysm (TAA) (PVD-6.2)** in the Peripheral Vascular Disease Imaging Guidelines.

- Coarctation of the aorta
 - Follow-up (surveillance) imaging after repair of coarctation:
 - Adults: see **Coarctation of the Aorta (CD-11.3.2)**
 - Infants and children: see **Aortic Coarctation and IAA (interrupted aortic arch) (PEDCD-2.4.11)** in the Pediatric Cardiac Imaging Guideline
- Arrhythmogenic right ventricular dysplasia or arrhythmogenic right ventricular cardiomyopathy (ARVD/ARVC) suspicion (CPT® 75557 or CPT® 75561)—must have one of the following:
 - Non-sustained or sustained VT of LBBB morphology OR >500 PVC's over 24 hours on event recorder or Holter monitor.
 - ARVD/ARVC confirmed in a first-degree relative either by criteria, autopsy, pathogenic genetic mutation or sudden death <35 years of age with suspected ARVD/ARVC.
 - Inverted T waves in right precordial leads (V1, V2 and V3) or beyond in individuals >14 years of age in the absence of complete RBBB
 - Right ventricular akinesis, dyskinesia or aneurysm noted on echo or RV angiography.
- Differentiate constrictive pericarditis from restrictive cardiomyopathy (CPT® 75561).
- Evaluate cardiac tumor or mass when echocardiogram is inconclusive.
- Evaluate valvular heart disease when echocardiogram is inconclusive:
 - CPT® 75557 **or** CPT® 75561
 - May add CPT® 75565 when there is documentation of either of the following:
 - Significant valvular disease that may require intervention
 - Intracardiac flow disturbances (e.g., ASD, VSD)
- MRI Cardiac (CPT® 75557 or CPT® 75561) *or* chest MRV (CPT® 71555), but not both, for pulmonary vein anatomy for planned ablation procedures in individuals with atrial fibrillation. See **Pulmonary Vein Imaging – Indications (CD-8.2)** for guidelines on follow-up imaging after ablation procedure.
- Suspected cardiac thrombus when echocardiogram is inconclusive (CPT® 75557).
- Right ventricular function evaluation (CPT® 75557 in conjunction with CPT® +75565) if there has been a recent ECHO and there is documented need to perform Cardiac MRI in order to resolve an unanswered question about flow dynamics.
- Cardiac MRI (CPT® 75557 or CPT® 75561) and CMR velocity flow mapping (CPT® 75565) for preoperative evaluation prior to planned LVAD implant
- Shunting through a VSD (CPT® 75557 in conjunction with CPT® +75565) if a recent ECHO has been done, including a bubble study, and there is documented need to perform Cardiac MRI in order to resolve an unanswered question about flow dynamics.
- Conditions that would **not** require an echo prior to an MRI:
 - Anomalous coronary arteries: Cardiac MRI (CPT® 75561) or CCTA (CPT® 75574) is much better at detecting this than conventional angiography.
 - Assess coronary arteries in Kawasaki's disease.

- Fabry disease
 - Late enhancement MRI may predict the effect of enzyme replacement therapy on myocardial changes that occur with this disease (CPT® 75561).
- Initial evaluation for cardiac sarcoidosis.

Cardiac MRI – Indications for Stress MRI (CD-5.3)

CD.MRI.0005.3.A

v2.1.2024

- For indications for Stress MRI see **Stress Testing with Imaging – Indications (CD-1.4)**.
- If a nuclear perfusion (MPI) stress test was performed and was equivocal, a stress MRI is indicated.

Cardiac MRI – Aortic Root and Proximal Ascending Aorta (CD-5.4)

CD.MRI.0005.4.A

v2.1.2024

- See- Thoracic Aortic Aneurysm (TAA) (PVD-6.2) in the Peripheral Vascular Disease imaging guidelines

Cardiac MRI – Evaluation of Pericardial Effusion or Diagnosis of Pericardial Tamponade (CD-5.5)

CD.MRI.0005.5.A

v2.1.2024

- Contrast-enhanced cardiac MRI (CPT® 75561) is useful for evaluating pericarditis, neoplastic and other effusion, tamponade or myocardial infiltration if a specific clinical question is left unanswered by echocardiogram or another recent imaging study.

Cardiac MRI – Myocarditis (CD-5.6)

CD.MRI.0005.6.A

v2.1.2024

Clinical evaluation of suspected myocarditis

Initial testing for suspected myocarditis should consist of an electrocardiogram, measurement of cardiac troponin, and an echocardiogram.

Cardiac MRI is indicated for suspected myocarditis in the presence of **all** of the following:

- New onset or persisting symptoms suggestive of myocarditis documented by **any** of the following:
 - Dyspnea
 - Chest pain
 - Palpitations
 - Syncope
 - Effort intolerance
- Evidence for recent or ongoing myocardial injury documented by **any** of the following results on initial screening:
 - Ventricular dysfunction noted on any cardiac imaging study, or
 - New or persisting ECG abnormalities suspicious for myocarditis
 - ST changes, T wave changes, Q waves, or
 - conduction abnormalities, such as LBBB or AV block, or
 - VT or VF
 - Elevated troponin
- Strong suspicion for viral etiology of myocardial injury with documentation of **both**:
 - Recent systemic viral disease, recent mRNA COVID-19 vaccination, or prior myocarditis
 - No evidence of coronary ischemia as documented by **any** of the following:
 - Lack of risk factors for CAD
 - Age under 35 years
 - Negative cardiac imaging study, such as MPI, CCTA, cath

Return to Play Screening for athletes at risk for myocarditis

Cardiac MRI is indicated for **Return to Play Screening** for athletes when there is documentation of **both** of the following:

- Individual has a history of a clinical condition associated with myocarditis (i.e., COVID-19 infection or recent mRNA COVID-19 vaccination)
- Initial screening has been performed with documentation of **either** of the following:
 - Initial screening (ECG, troponin, and TTE) showed evidence for recent or ongoing myocardial injury (as defined above in Clinical Evaluation of Suspected Myocarditis) with ongoing symptoms concerning for myocarditis (dyspnea, chest pain, palpitations, syncope, or effort intolerance).
 - Normal results of initial screening with persistent or new onset symptoms concerning for myocarditis.

Background and Supporting Information

As noted in the "2022 ACC expert consensus decision pathway on cardiovascular sequelae of COVID-19 in adults" and the 2017 "Sports cardiology: core curriculum for providing cardiovascular care to competitive athletes and highly active people", an athlete is defined as an individual who places a high premium on exercise training, competition, and sports achievement.

Cardiac MRI – Duchenne Muscular Dystrophy (DMD) (CD-5.7)

CD.MRI.0005.7.A

v2.1.2024

Cardiac MRI (CPT® 75557 or 75561-does not include 75565 or 71555 unless otherwise indicated)

- Asymptomatic individual with documented DMD can have annual surveillance cardiac MRI starting at 6 years old (yearly echo is recommended prior to age 6)
- Asymptomatic, documented carrier of DMD can have cardiac MRI every 3 years starting at 18

References (CD-5)

v2.1.2024

1. Hamdan A, Charalampos K, Roettgen R, et al. Magnetic resonance imaging versus computed tomography for characterization of pulmonary vein morphology before radiofrequency catheter ablation of atrial fibrillation. *Am J Cardiol*. 2009; 104:1540-1546. doi:10.1016/j.amjcard.2009.07.029.
2. Hendel RC, Kramer CM, Patel MR, et al. ACCF/ACR/SCCT/SCMR/ ASNC/NASCI/SCAI/SIR 2006 Appropriateness Criteria for computed tomography and cardiac magnetic resonance imaging. *J Am Coll Cardiol*. 2006; 48(7):1475-1497. Accessed November 30, 2017. doi:10.1016/j.jacc.2006.07.003.
3. Doherty JU, Kort S, Mehran R, et al. ACC/AATS/AHA/ASE/ASNC/HRS/SCAI/SCCT/SCMR/STS 2019 Appropriate Use Criteria for Multimodality Imaging in the Assessment of Cardiac Structure and Function in Nonvalvular Heart Disease. *J Am Coll Cardiol*. 2019;73(4):488-516. doi:10.1016/j.jacc.2018.10.038.
4. Hundley WG, Bluemke DA, Finn JP, et al. ACCF/ACR/AHA/NASCI/SCMR 2010 Expert Consensus Document on Cardiovascular Magnetic Resonance. *J Am Coll Cardiol*. 2010;55(23):2614-2662. doi:10.1016/j.jacc.2009.11.011.
5. Friedrich MG, Sechtem U, Schulz-Menger J, et al. Cardiovascular Magnetic Resonance in Myocarditis: A JACC White Paper. *J Am Coll Cardiol*. 2009;53(17):1475-1487. doi:10.1016/j.jacc.2009.02.007.
6. Riele AST, Tandri H, Sanborn DM, Bluemke DA. Noninvasive Multimodality Imaging in ARVD/C. *JACC: Cardiovasc Imaging*. 2015;8(5):597-611. doi:10.1016/j.jcmg.2015.02.007.
7. Verhaert D, Richards K, Rafael-Fortney JA, Raman SV. Cardiac involvement in patients with muscular dystrophies: magnetic resonance imaging phenotype and genotypic considerations. *Circ Cardiovasc Imaging*. 2011;4(1):67-76. doi:10.1161/CIRCIMAGING.110.960740.
8. Feingold B, Mahle WT, Auerbach S, et al. Management of Cardiac Involvement Associated With Neuromuscular Diseases: A Scientific Statement From the American Heart Association. *Circulation*. 2017;136(13). doi:10.1161/cir.0000000000000526
9. Mah ML, Cripe L, Slawinski MK, et al. Duchenne and Becker muscular dystrophy carriers: Evidence of cardiomyopathy by exercise and cardiac MRI testing. *International Journal of Cardiology*. 2020;316:257-265. doi:10.1016/j.ijcard.2020.05.052
10. Power LC, O'Grady GL, Hornung TS, Jefferies C, Gusso S, Hofman PL. Imaging the heart to detect cardiomyopathy in Duchenne muscular dystrophy: A review. *Neuromuscular Disorders*. 2018;28(9):717-730. doi:10.1016/j.nmd.2018.05.011
11. Hor KN, Mah ML, Johnston P, Cripe TP, Cripe LH. Advances in the diagnosis and management of cardiomyopathy in Duchenne muscular dystrophy. *Neuromuscular Disorders*. 2018;28(9):711-716. doi:10.1016/j.nmd.2018.06.014.
12. Birnkrant DJ, Bushby K, Bann CM, et al. Diagnosis and management of Duchenne muscular dystrophy, part 2: respiratory, cardiac, bone health, and orthopaedic management. *The Lancet Neurology*. 2018;17(4):347-361. doi:10.1016/s1474-4422(18)30025-5.
13. Baggish AL, Battle RW, Beckerman JG, et al. Sports Cardiology: Core Curriculum for Providing Cardiovascular Care to Competitive Athletes and Highly Active People. *J Am Coll Cardiol*. 2017;70(15):1902-1918. doi:10.1016/j.jacc.2017.08.055.
14. Ammirati E, Frigerio M, Adler ED, et al. Management of Acute Myocarditis and Chronic Inflammatory Cardiomyopathy: An Expert Consensus Document. *Circ Heart Fail*. 2020;13(11):e007405. doi:10.1161/CIRCHEARTFAILURE.120.007405.
15. Gluckman TJ, Bhave NM, et al. 2022 ACC Expert Consensus Decision Pathway on Cardiovascular Sequelae of COVID-19 in Adults: Myocarditis and Other Myocardial Involvement, Post-Acute Sequelae of SARS-CoV-2 Infection, and Return to Play: A Report of the American College of Cardiology Solution Set Oversight Committee. *J Am Coll Cardiol*. 2022;79(17):1717-1756. doi:10.1016/j.jacc.2022.02.003.

Cardiac PET

Guideline

Cardiac PET – Coding (CD-6.1)

Cardiac PET – Perfusion – Indications (CD-6.2)

Cardiac PET – Absolute Quantitation of Myocardial Blood Flow (AQMBF) (CD-6.3)

References

Cardiac PET – Metabolic – Indications (CD-6.4)

FDG PET/CT for infections (CD-6.5)

References (CD-6)

Cardiac PET – Coding (CD-6.1)

CD.PET.0006.1.A
v2.1.2024

Cardiac Imaging Procedure Codes	
Cardiac PET	CPT®
Myocardial imaging, positron emission tomography (PET), metabolic evaluation study (including ventricular wall motion[s] and/or ejection fraction[s], when performed), single study	78459
Myocardial imaging, positron emission tomography (PET), perfusion study (including ventricular wall motion[s] and/or ejection fraction[s], when performed); single study at rest or stress (exercise or pharmacologic)	78491
Myocardial imaging, positron emission tomography (PET), perfusion study (including ventricular wall motion[s] and/or ejection fraction[s], when performed); multiple studies at rest and stress (exercise or pharmacologic)	78492
Myocardial imaging, positron emission tomography (PET), metabolic evaluation study (including ventricular wall motion[s] and/or ejection fraction[s], when performed), single study; with concurrently acquired computed tomography transmission scan	78429
Myocardial imaging, positron emission tomography (PET), perfusion study (including ventricular wall motion[s] and/or ejection fraction[s], when performed); single study, at rest or stress (exercise or pharmacologic), with concurrently acquired computed tomography transmission scan	78430

Cardiac Imaging Procedure Codes	
Cardiac PET	CPT®
Myocardial imaging, positron emission tomography (PET), perfusion study (including ventricular wall motion[s] and/or ejection fraction[s], when performed); multiple studies at rest and stress (exercise or pharmacologic), with concurrently acquired computed tomography transmission scan	78431
Myocardial imaging, positron emission tomography (PET), combined perfusion with metabolic evaluation study (including ventricular wall motion[s] and/or ejection fraction[s], when performed), dual radiotracer (e.g., myocardial viability);	78432
Myocardial imaging, positron emission tomography (PET), combined perfusion with metabolic evaluation study (including ventricular wall motion[s] and/or ejection fraction[s], when performed), dual radiotracer (e.g., myocardial viability); with concurrently acquired computed tomography transmission scan	78433
Absolute quantitation of myocardial blood flow (AQMBF), positron emission tomography (PET), rest and pharmacologic stress (List separately in addition to code for primary procedure)	+78434
Positron emission tomography (PET) with concurrently acquired computed tomography (CT) for attenuation correction and anatomical localization imaging; skull base to mid-thigh	78815

- 3D rendering should not be billed in conjunction with PET.
- Separate codes for such related services as treadmill testing (CPT® 93015-CPT® 93018) and radiopharmaceuticals should be assigned in addition to perfusion PET. These services are paid according to each individual payer.

Cardiac PET – Perfusion – Indications (CD-6.2)

CD.PET.0006.2.A

v2.1.2024

CPT[®]78430, CPT[®] 78431, CPT[®]78491 and CPT[®]78492

- Meets all of the criteria for an imaging stress test in **Stress Testing with Imaging – Indications (CD-1.4)** and additionally any one of the following:
 - Individual is severely obese (for example BMI >40 kg/m²) or
 - Individual has large breasts or implants
 - Individual incapable of exercise due to physical (musculoskeletal or neurological) inability to achieve target heart rate. Target heart rate is calculated as 85% of the maximum age predicted heart rate (MPHR). MPHR is estimated as 220 minus the individual's age
- Equivocal nuclear perfusion (SPECT MPI) stress test
- Routine use in post heart transplant assessment of transplant CAD

Cardiac PET – Absolute Quantitation of Myocardial Blood Flow (AQMBF) (CD-6.3)

CD.PET.0006.3.A
v2.1.2024

Absolute Quantitation of Myocardial Blood Flow (CPT[®] 78434)

Quantitation of myocardial blood flow at rest and with stress in ml/g/min and the calculation of myocardial perfusion reserve (the ratio of stress to rest flow) can be used for diagnosis and prognosis of coronary artery disease and cardiac endothelial dysfunction that can be seen in diabetes, left ventricular hypertrophy, heart transplantation vasculopathy among other conditions.

- AQMBF with PET (CPT 78434) is an add-on procedure that is indicated when one of the following apply:
 - Primary study Myocardial PET rest/stress perfusion (CPT[®] 78492 or 78431 only) has been approved
 - Primary study Myocardial PET rest/stress perfusion (CPT[®] 78492 or 78431 only) has been ordered and is being approved at the same time (see- **Cardiac PET - Perfusion - Indications (CD-6.2)** or **Stress Testing with Imaging - Indications (CD-1.4)**).

Background and supporting information

Despite its utility, AQMBF is a technically challenging measurement. Variables include:

- Different tracers (N-13 ammonia vs Rb-82 Cl) give different values
- Different mathematical models used (static vs dynamic)
- Different stressors are used that give different hyperemic flow results (adenosine vs dipyridamole vs regadenoson)
- Data can be collected in 2D vs 3D modes. Saturation of crystals is more problematic in 3D.
- Cardiac, respiratory and patient motion can degrade measurement accuracy .
- Different vendor software is used by different reading labs.
- Resting blood flow can be elevated due to pain, anxiety, lack of vagal tone, hypertension, etc. and can be normalized by using the rate pressure product (RPP) for calculation of myocardial perfusion reserve (MBF) the ratio of myocardial hyperemic flow/rest flow.

eviCore along with the American Society of Nuclear Medicine, the American College of Cardiology, and the Society of Nuclear Medicine and Metabolic Imaging agree that to minimize the above listed variables, AQMBF should only be approved when performed by **(all)**:

- Laboratories that are Intersocietal Accreditation Commission (IAC), American College of Radiology (ACR), or Joint Commission cardiac PET accredited.
- Interpreting physician(s) must be Board certified in Nuclear Cardiology (CBNC), Nuclear Medicine (ABNM), or Radiology (ABR) and have additional training in measuring AQMBF.
- Individual laboratories should have a standard protocol (same tracer, camera, software, stressor, model etc.) for use for all patients.
- Reports should contain rest myocardial blood flow (MBF) and stress MBF in ml/g/min, and myocardial blood flow reserve (MBFR) reported as the ratio of stress to rest MBF (with normal limits).
- Laboratories should have the ability to perform rate-pressure-product (RPP) correction of resting MBF when resting MBF is elevated due to elevated resting RPP and include mention of the true measured resting MBF and MBFR as well as the RPP-corrected resting MBF and RPP-corrected MBFR in the conclusions of the report.
- Health plans will be responsible for verifying requirements.

References

CD.PET.0006.3.A

v2.1.2024

1. Bateman TM, Heller GV, Beanlands R, et al. Practical guide for interpreting and reporting cardiac PET measurements of myocardial blood flow: an Information Statement from the American Society of Nuclear Cardiology, and the Society of Nuclear Medicine and Molecular Imaging. *J Nucl Cardiol.* 2021;28(2):768-787. doi:10.1007/s12350-021-02552-7.
2. Murthy VL, Bateman TM, Beanlands RS, et al. Clinical Quantification of Myocardial Blood Flow Using PET: Joint Position Paper of the SNMMI Cardiovascular Council and the ASNC. *J Nucl Med.* 2018;59(2):273-293. doi:10.2967/jnumed.117.201368.
3. Patel KK, Spertus JA, Chan PS, et al. Myocardial blood flow reserve assessed by positron emission tomography myocardial perfusion imaging identifies patients with a survival benefit from early revascularization. *Eur Heart J.* 2020;41(6):759-768. doi:10.1093/eurheartj/ehz389.
4. Ngo V, Martineau P, Harel F, Pelletier-Galarneau M. Improving Detection of CAD and Prognosis with PET/CT Quantitative Absolute Myocardial Blood Flow Measurements. *Curr Cardiol Rep.* 2022 Dec;24(12):1855-1864. doi: 10.1007/s11886-022-01805-2. Epub 2022 Nov 8. PMID: 36348147.

Cardiac PET – Metabolic – Indications (CD-6.4)

CD.PET.0006.4.A

v2.1.2024

- Cardiac PET Metabolic and cardiac SPECT or PET perfusion (CPT® 78429 or CPT® 78459 and CPT® 78451, or CPT® 78432, or CPT® 78433)
 - To determine myocardial viability when a previous study has shown significant left ventricular dysfunction when under consideration for revascularization
- To diagnose strongly suspected cardiac sarcoid or monitor response to therapy for established cardiac sarcoid see **Cardiac Sarcoidosis (CD-3.9)**

FDG PET/CT for infections (CD-6.5)

CD.PET.0006.5.A

v2.1.2024

- FDG PET/CT (CPT® 78815 or CPT® 78429) is indicated in the assessment of suspected prosthetic heart valve endocarditis when there is documentation of **both** of the following:
 - TTE and/or TEE are equivocal or non-diagnostic
 - Suspicion for prosthetic heart valve endocarditis remains high (all):
 - C-reactive protein ≥ 40 mg/L
 - No evidence of prolonged antibiotic therapy
 - The implantation was ≥ 3 months ago and there is no evidence of surgical adhesives used during the valve implantation
- FDG PET/CT for LVAD driveline infection (CPT® 78815 or 78429)
 - Early infection detection for LVAD drivelines is desirable, since once the infection extends to the cannula and pump pocket, eradication becomes difficult. CT findings are nonspecific and metal device artifacts of the driveline itself affects sensitivity.
 - FDG PET/CT is indicated for suspected LVAD infection if other studies and examination remain inconclusive.

References (CD-6)

v2.1.2024

1. Einstein AJ, Moser KW, Thompson RC, et al. Radiation Dose to Patients from Cardiac Diagnostic Imaging. *Circulation*. 2007;116(11):1290-1305. doi:10.1161/circulationaha.107.688101.
2. Youssef G, Mylonas I, Leung E, et al. The Use of 18F-FDG PET in the Diagnosis of Cardiac Sarcoidosis: A Systematic Review and Metaanalysis Including the Ontario Experience. *Journal of Nuclear Medicine*. <http://jnm.snmjournals.org/content/53/2/241.long>. Published February 1, 2012.
3. Blankstein R, Osborne M, Naya M, et al. Cardiac Positron Emission Tomography Enhances Prognostic Assessments of Patients with Suspected Cardiac Sarcoidosis. *Journal of the American College of Cardiology*. 2014;63(4):329-336. doi:10.1016/j.jacc.2013.09.022.
4. Habib G, Lancellotti P, Antunes MJ, et al. 2015 ESC Guidelines for the management of infective endocarditis. *European Heart Journal*. 2015;36(44):3075-3128. doi:10.1093/eurheartj/ehv319.
5. Swart LE, Gomes A, Scholtens AM, et al. Improving the Diagnostic Performance of 18 F-Fluorodeoxyglucose Positron-Emission Tomography/Computed Tomography in Prosthetic Heart Valve Endocarditis. *Circulation*. 2018;138(14):1412-1427. doi:10.1161/circulationaha.118.035032.
6. Kim J, Feller ED, Chen W, Liang Y, Dilsizian V. FDG PET/CT for Early Detection and Localization of Left Ventricular Assist Device Infection. *JACC: Cardiovascular Imaging*. 2019;12(4):722-729. doi:10.1016/j.jcmg.2018.01.024.
7. Tam MC, Patel VN, Weinberg RL, et al. Diagnostic Accuracy of FDG PET/CT in Suspected LVAD Infections. *JACC: Cardiovascular Imaging*. 2020;13(5):1191-1202. doi:10.1016/j.jcmg.2019.04.024.
8. Harnett DT, Hazra S, Maze R, et al. Clinical performance of Rb-82 myocardial perfusion PET and Tc-99m-based SPECT in patients with extreme obesity. *J Nucl Cardiol*. 2017;26(1):275-283. doi:10.1007/s12350-017-0855-6.
9. Defining Adult Overweight and Obesity. Centers for Disease Control and Prevention. <https://www.cdc.gov/obesity/adult/defining.html>. Published March 3, 2021.
10. Gulati M, Levy PD, Mukherjee D, et al. 2021 AHA/ACC/AASE/CHEST/SAEM/SCCT/SCMR Guideline for the Evaluation and Diagnosis of Chest Pain: A Report of the American College of Cardiology/American Heart Association Joint Committee on Clinical Practice Guidelines [published correction appears in *Circulation*. 2021 Nov 30;144(22):e455]. *Circulation*. 2021;144(22):e368-e454. doi:10.1161/CIR.0000000000001029

Diagnostic Heart Catheterization

Guideline

Diagnostic Heart Catheterization – Coding (CD-7.1) (CD-7.2)
LHC – Unstable/Active Coronary Artery Syndromes (CD-7.3.1)
Diagnostic Left Heart Catheterization (LHC) (CD-7.3)
Right Heart Catheterization and Right and Left Heart Catheterization without Coronary Angiography (CD-7.4)
Combined Right and Left Heart Catheterization Indications (CD-7.5)
Planned (Staged) Procedures (CD-7.6)
Evaluation of Conditions other than Coronary Artery Disease (CD-7.7)
References (CD-7)

Diagnostic Heart Catheterization – Coding (CD-7.1) (CD-7.2)

CD.DHC.0007.1.A

v2.1.2024

Guideline

Diagnostic Heart Catheterization – Code Sets (CD-7.1)

Diagnostic Heart Catheterization – Coding Notes (CD-7.2)

Diagnostic Heart Catheterization – Code Sets (CD-7.1)

Cardiac Catheterization Procedure Codes

Cardiac Cath Procedure	CPT®
Congenital Heart Disease Code “Set”	93593-93597
Right heart catheterization for congenital heart defect(s) including imaging guidance by the proceduralist to advance the catheter to the target zone; normal native connections	93593
Right heart catheterization for congenital heart defect(s) including imaging guidance by the proceduralist to advance the catheter to the target zone; abnormal native connections	93594
Left heart catheterization for congenital heart defect(s) including imaging guidance by the proceduralist to advance the catheter to the target zone, normal or abnormal native connections	93595
Right and left heart catheterization for congenital heart defect(s) including imaging guidance by the proceduralist to advance the catheter to the target zone(s); normal native connections	93596
Right and left heart catheterization for congenital heart defect(s) including imaging guidance by the proceduralist to advance the catheter to the target zone(s); abnormal native connections	93597
Anomalous coronary arteries, patent foramen ovale, mitral valve prolapse, and bicuspid aortic valve	93451-93464, 93566-93568
RHC without LHC or coronaries	93451
LHC without RHC or coronaries	93452

Cardiac Cath Procedure	CPT®
RHC and retrograde LHC without coronaries	93453
Native coronary artery catheterization;	93454
with bypass grafts	93455
with RHC	93456
with RHC and bypass grafts	93457
with LHC	93458
with LHC and bypass grafts	93459
with RHC and LHC	93460
with RHC and LHC and bypass grafts	93461
LHC by trans-septal or apical puncture	+93462
Angiography of non-coronary arteries and veins performed as a distinct service	Select appropriate codes from the Radiology and Vascular Injection Procedures sections.

- CPT® 93593 to 93597 are indicated for invasive evaluation of congenital heart disease. See specific conditions in **Adult Congenital Heart Disease (CD-11)**

Diagnostic Heart Catheterization – Coding Notes (CD-7.2)

- Cardiac catheterization (CPT® 93451-CPT® 93461) includes all "road mapping" angiography necessary to place the catheters, including any injections and imaging supervision, interpretation and report.
- Cardiac catheterization (CPT® 93452-CPT® 93461) (for all conditions other than congenital heart disease) includes contrast injections, imaging supervision, interpretation and report for imaging typically performed.
- Catheter placements in native coronaries or bypass grafts (CPT® 93454-CPT® 93461) include intraprocedural injections for bypass graft angiography, imaging supervision and interpretation.
- Injection codes CPT® 93563-CPT® 93565 should not be used in conjunction with CPT® 93452-CPT® 93461.
- Codes CPT® 93451-CPT® 93461 do not include contrast injections and imaging supervision, interpretation and report for imaging that is separately identified by the following specific procedure codes: CPT® 93566, CPT® 93567 and CPT® 93568.
- Separate diagnostic cardiac catheterization codes should only be assigned in conjunction with interventional procedures in the following circumstances:
 - No prior or recent diagnostic catheterization is available to guide therapy
 - Individual's condition has significantly changed since the last diagnostic cath
 - The treatment plan may be affected

- Other vessels may be identified for treatment
- Further establishment of a diagnosis from a non-invasive study is necessary

LHC – Unstable/Active Coronary Artery Syndromes (CD-7.3.1)

CD.DHC.0008.A

v2.1.2024

Diagnostic Left Heart Catheterization (LHC) is indicated for individuals in acute settings or with **active** unstable angina and should be handled as medical emergencies.

- LHC may be indicated for new onset, accelerating, or worsening ischemic symptoms suggestive of acute coronary syndrome (ACS) occurring at rest, or with minimal exertion resolving with rest, including:
 - Cardiac chest pain (typical angina) with or without new onset, evolving ischemic EKG changes
 - Symptoms consistent with the known angina pattern in an individual with a history of CABG or PCI
- Left and right heart cath may be indicated in place of a left heart cath if the above criteria has been met and there is documentation of any of the following:
 - The major component of the individual's symptoms is dyspnea
 - Newly diagnosed or worsening cardiomyopathy
 - For surgical planning prior to any of the following:
 - Heart valve surgery
 - Congenital heart defect repair
 - Lung transplant
 - Liver transplant

Diagnostic Left Heart Catheterization (LHC) (CD-7.3)

CD.DHC.0007.3.A

v2.1.2024

Guideline

Stable Established CAD Post Revascularization with CABG or PCI (CD-7.3.2)

Stable Symptomatic Suspected or Established Coronary Artery Disease (CD-7.3.3)

Exclusion of Significant Coronary Artery Disease Involvement in other Cardiac Pathology (CD-7.3.4)

Evaluation of structural heart disease (CD-7.3.5)

Angiography-Derived Fractional Flow Reserve (CD-7.3.6)

Stable Established CAD Post Revascularization with CABG or PCI (CD-7.3.2)

Note These guidelines apply to individuals with stable conditions and who are not in the acute setting (acute coronary syndrome or unstable angina).

- Diagnostic Left Heart Catheterization (LHC) is indicated in individuals with established Coronary Artery Disease (CAD) post revascularization by percutaneous coronary intervention (PCI) or coronary artery bypass graft surgery (CABG) when there is documentation of **one** of the following:
 - New, recurrent, or worsening ischemic symptoms similar to prior ischemic episode.
 - New, recurrent, or worsening likely anginal symptoms as defined in **General Guidelines (CD-1.0)**
 - New, recurrent, or worsening symptoms of chest pain, or exertional dyspnea, or exertional fatigue AND intermediate or high-risk findings on non-invasive stress testing as documented by one of the following:
 - Cardiac chest pain induced by exercise treadmill testing or dobutamine stress testing
 - Exercise treadmill testing inducing any of the following:
 - At least 1 mm downsloping ST-depression
 - 2 mm horizontal ST-depression
 - At least 1 mm ST-elevation in two leads
 - Ventricular tachycardia of at least 3 consecutive beats
 - Myocardial perfusion imaging (SPECT or PET) with $\geq 5\%$ reversible ischemic burden

- Stress echo with at least 2 segments of inducible ischemia
- Severe stress induced left ventricular dysfunction (drop in left ventricular ejection fraction with stress $\geq 10\%$)
- New left ventricular systolic dysfunction (left ventricular ejection fraction $< 50\%$)
- Worsening left ventricular systolic dysfunction (decline in left ventricular ejection fraction $\geq 10\%$)
- New or worsened congestive heart failure
- Ventricular fibrillation
- Sustained ventricular tachycardia
- Left and right heart cath may be indicated in place of a left heart cath if the above criteria has been met and there is documentation of **any** of the following:
 - The major component of the individual's symptoms is dyspnea
 - Newly diagnosed or worsening cardiomyopathy
 - For surgical planning prior to any of the following:
 - Heart valve surgery
 - Congenital heart defect repair
 - Lung transplant
 - Liver transplant

Stable Symptomatic Suspected or Established Coronary Artery Disease (CD-7.3.3)

For the purpose of this guideline, likely anginal symptoms is defined in **General Guidelines (CD-1.0)**

- Diagnostic left heart catheterization to screen for coronary artery disease (CAD) in asymptomatic individuals who are not anticipating other cardiac procedures is **not** indicated
- LHC with coronary arteriography (CPT[®] 93454, 93455, 93458, 93459) is indicated when there is documentation of one of the following:
 - New onset, persistent, or worsening of likely anginal symptoms and either:
 - Symptomatic failure of a 12 week trial of OMT including as tolerated all of the following:
 - Anti-platelet therapy
 - Statin and/or other lipid-lowering therapy
 - Anti-anginal therapy implemented to pursue a goal heart rate of 60 beats per minute or less
 - Anti-hypertensive therapy as may be indicated to pursue a goal systolic blood pressure (sbp) of less than 140 mmHg and a goal diastolic blood pressure (DBP) of less than 90 mmHg
 - Worsening of likely anginal symptoms during 12 week trial of OMT
 - New onset, persistent, or worsening of likely anginal symptoms and documentation of **both** of the following:

- Established CAD per **General Guidelines (CD- 1.0)** or age ≥ 50 years and/or ≥ 2 CAD risk factors (diabetes mellitus, smoking, family history of premature CAD, hypertension, dyslipidemia), and
- Likely anginal symptoms at a low level of exercise or at rest despite optimal medical therapy
- LHC may be indicated irrespective of OMT for symptomatic individuals who also have high-risk findings on Coronary CT Angiography See **CCTA – Indications for CCTA (CD-4.3)**, to include any of the following:
 - Left main coronary artery stenosis $\geq 40\%$
 - Proximal or mid left anterior descending coronary artery stenosis $\geq 70\%$
 - Proximal or mid double-vessel coronary artery stenosis $\geq 60\%$
 - Proximal or mid triple-vessel coronary artery stenosis $\geq 50\%$
 - CT-FFR measured to be ≤ 0.8 in the proximal or mid segment of any coronary artery irrespective of degree of stenosis
- LHC may be indicated irrespective of OMT for symptomatic individuals who have BOTH likely anginal symptoms and high-risk findings on non-invasive stress testing including any of the following:
 - Cardiac chest pain induced by exercise treadmill testing or dobutamine stress testing
 - Myocardial perfusion imaging with $\geq 10\%$ reversible ischemic burden
 - Stress echo with at least 3 segments of inducible ischemia
 - Exercise treadmill testing inducing at least 2.5 mm downsloping ST-depression or 3 mm horizontal ST-depression in two leads
 - Ventricular tachycardia of at least 3 consecutive beats induced by an exercise treadmill test
- LHC may be indicated for any of the following if coronary artery disease is suspected:
 - New or worsened congestive heart failure
 - New left ventricular systolic dysfunction (left ventricular ejection fraction $< 50\%$)
 - Worsening left ventricular systolic dysfunction (decline in left ventricular ejection fraction $\geq 10\%$)
 - Ventricular fibrillation or sustained ventricular tachycardia
- Left and right heart cath may be indicated in place of a left heart cath if the above criteria has been met and there is documentation of any of the following:
 - The major component of the individual's symptoms is dyspnea
 - Newly diagnosed or worsening cardiomyopathy
 - For surgical planning prior to any of the following:
 - Heart valve surgery
 - Congenital heart defect repair
 - Lung transplant
 - Liver transplant

Background and supporting information

In addition to OMT, physician-guided behavioral modification therapy (BMT) is recommended including all of the following:

- Mediterranean diet
- Moderate intensity physical activity for at least thirty minutes per day at least five times per week as possible
- Attempts at smoking cessation to include at least one of the following:
 - Cognitive behavioral therapy
 - Nicotine withdrawal replacement therapy

Exclusion of Significant Coronary Artery Disease Involvement in other Cardiac Pathology (CD-7.3.4)

- LHC is indicated when the etiology is unclear for **any** of the following if coronary artery disease is suspected:
 - New or worsened congestive heart failure
 - New left ventricular systolic dysfunction (left ventricular ejection fraction <50%)
 - Worsening left ventricular systolic dysfunction (decline in left ventricular ejection fraction $\geq 10\%$)
 - Ventricular fibrillation or sustained ventricular tachycardia
 - Unheralded syncope (not near syncope)
 - Suspected myocarditis
- Left and right heart cath may be indicated in place of a left heart cath if the above criteria has been met and there is documentation of any of the following:
 - The major component of the individual's symptoms is dyspnea
 - Newly diagnosed or worsening cardiomyopathy
 - For surgical planning prior to any of the following:
 - Heart valve surgery
 - Congenital heart defect repair
 - Lung transplant
 - Liver transplant

Evaluation of structural heart disease (CD-7.3.5)

Left heart catheterization with coronary arteriography (CPT[®] 93458 or CPT[®] 93454) is indicated for any of the following

- Evaluation prior to planned invasive procedure or surgery

- Ruling out coronary artery disease prior to planned non-coronary cardiac or great vessel surgery (i.e., cardiac valve surgery, aortic dissection, aortic aneurysm, congenital disease repair such as atrial septal defect, etc.).
- Pre-organ transplant (non-cardiac) - in place of stress imaging for initial pre-transplant evaluation (per the transplant center's protocol) **or** if stress imaging is positive for ischemia. Repeat periodic screening while on a transplant waiting list (in the absence of other clinical indications) is not supported. See **Kidney Transplant, Pre-Transplant Imaging Studies (AB-42.5)**.
- Prior to catheter ablation of ventricular arrhythmia at one of the following sites:
 - Sinus of Valsalva
 - Coronary venous system
 - Epicardium
- Valvular heart disease when either:
 - There is a discrepancy between the clinical findings (history, physical exam, and non-invasive test results)
 - Valvular surgery is being considered.
- Suspected pericardial disease.
- Previous cardiac transplant:
 - Per transplant center protocol
 - To assess for accelerated coronary artery disease associated with cardiac transplantation.
- Left and right heart cath may be indicated in place of a left heart cath if the above criteria has been met and there is documentation of any of the following:
 - The major component of the individual's symptoms is dyspnea
 - Newly diagnosed or worsening cardiomyopathy
 - For surgical planning prior to any of the following:
 - Heart valve surgery
 - Congenital heart defect repair
 - Lung transplant
 - Liver transplant

Angiography-Derived Fractional Flow Reserve (CD-7.3.6)

Coding

Description	HCPCS
Catheter placement in coronary artery(s) for coronary angiography, including intraprocedural injection(s) for coronary angiography, imaging supervision and interpretation with left heart catheterization including intraprocedural injection(s) for left ventriculography, when performed and intraprocedural coronary fractional flow reserve (FFR) with 3d functional mapping of color-coded FFR values for the coronary tree, derived from coronary angiogram data, for real-time review and interpretation of possible atherosclerotic stenosis(es) intervention	C7557

Criteria

Angiography-Derived Fractional Flow Reserve based on three-dimensional reconstruction of angiographic images is considered to be experimental, investigational, or unproven.

Background and supporting information

Fractional flow reserve (FFR) is an index of the physiological significance of a coronary artery stenosis. It is derived by using a coronary artery pressure guidewire to measure the distal coronary artery pressure. Angiography-Derived Fractional Flow Reserve is an alternative approach to derive FFR without the use of a coronary artery pressure guidewire, based on three-dimensional reconstruction of angiographic images. Mathematical modeling based on hemodynamic laws is then applied to the three-dimensional reconstruction to derive the pressure dynamics along the coronary artery, with results displayed in a color-coded map. Further research is needed to evaluate the accuracy and applicability of Angiography-Derived Fractional Flow Reserve.

References

1. Morris PD, Curzen N, Gunn JP. Angiography-Derived Fractional Flow Reserve: More or Less Physiology? *J Am Heart Assoc.* 2020 Mar 17;9(6):e015586. doi: 10.1161/JAHA.119.015586.
2. Witberg G et al. Clinical Outcomes of FFRangio-Guided Treatment for Coronary Artery Disease. *JACC Cardiovasc Interv.* 2022 Feb 28;15(4):468-470. doi: 10.1016/j.jcin.2021.11.039.
3. Arefinia F et al. Non-invasive fractional flow reserve estimation using deep learning on intermediate left anterior descending coronary artery lesion angiography images. *Sci Rep.* 2024 Jan 20;14(1):1818. doi: 10.1038/s41598-024-52360-5.
4. Advancing Cath Lab Results With FFRangio Coronary Physiology Assessment (ALL-RISE) ClinicalTrials.gov Identifier: NCT05893498. Study Start: 2023-06-21. Primary Completion (Estimated): 2024-12. Clinical Trials.gov.

Right Heart Catheterization and Right and Left Heart Catheterization without Coronary Angiography (CD-7.4)

CD.DHC.0007.4.A

v2.1.2024

- Diagnostic right heart catheterization (CPT® 93451) OR Diagnostic right and left heart catheterization without coronary angiography (CPT® 93453) is indicated when results will impact the diagnosis and management of **any** of the following:
 - Atrial septal defect (ASD) including shunt detection and quantification
 - Ventricular septal defect (VSD) including shunt detection and quantification
 - Patent foramen ovale (PFO)
 - Anomalous pulmonary venous return
 - Congenital defects including persistent left vena cava
 - Pulmonary hypertension
 - Pericardial diseases (constrictive or restrictive pericarditis)
 - Valvular disease
 - Right heart failure
 - Left heart failure
 - Newly diagnosed or worsening cardiomyopathy
 - Preoperative evaluation for valve surgery
 - During a left heart cath where the etiology of the symptoms remains unclear
 - Pre-lung transplant to assess pulmonary pressures
 - Uncertain intravascular volume status with an unclear etiology
 - Prior to LVAD implant and post LVAD implant as needed for hemodynamic assessment to guide changes to therapy
 - Assessment post-cardiac transplant
 - For routine endomyocardial biopsy
 - Assess for rejection
 - Assess pulmonary artery pressure
 - Can be done per the institution protocol or anytime organ rejection is suspected and biopsy is needed for assessment
 - Evaluation of right ventricular morphology.
 - Suspected arrhythmogenic right ventricular dysplasia.

Background and supporting information

General information RHC (CPT® 93451)

- It is performed most commonly from the femoral vein, less often through the subclavian, brachial, or internal jugular vein and inter-atrial septal puncture approach.
- It includes a full oximetry for detection and quantification of shunts.
- Cardiac outputs are calculated by several techniques including the Fick thermodilution

Combined Right and Left Heart Catheterization Indications (CD-7.5)

CD.DHC.0007.5.A

v2.1.2024

Combined Right and Left Heart Catheterization (CPT® 93460 or CPT® 93461) is indicated for the following:

- Preoperative evaluation for valve surgery
- The indications for **Diagnostic Left Heart Catheterization (LHC) (CD-7.3)** are met and **any** of the following are present:
 - The major component of the individual's symptoms is dyspnea
 - The indications are met according to **Right Heart Catheterization (RHC) (CD-7.4)**
 - Newly diagnosed or worsening cardiomyopathy
- See **Right Heart Catheterization and Right and Left Heart Catheterization without Coronary Angiography (CD- 7.4)** for CPT® 93453

Planned (Staged) Procedures (CD-7.6)

CD.DHC.0007.6.A

v2.1.2024

Planned (staged) coronary intervention

- Planned (Staged) Coronary Interventions applies to individuals with clinically stable symptoms if there is documentation of a recent diagnostic catheterization finding of a significant lesion that was not intervened as part of the initial procedure and the documentation explicitly states that a subsequent procedure will be performed for planned/staged PCI of that lesion.
- The CPT® codes for percutaneous coronary interventions (PCI) include the following imaging services necessary for the procedure(s):
 - Contrast injection, angiography, 'road-mapping', and fluoroscopic guidance
 - Vessel measurement
 - Angiography following coronary angioplasty, stent placement, and atherectomy
- Separate codes for these services should not be assigned in addition to the PCI code/s because the services are already included.
- A repeat diagnostic left heart catheterization is not medically necessary when the individual is undergoing a planned staged percutaneous coronary intervention.

Planned coronary artery lesion assessment

A repeat complete diagnostic left heart catheterization is not medically necessary for the purpose of coronary artery lesion assessment using any of the following:

- Intravascular ultrasound (IVUS)
- Optical coherence tomography (OCT)
- Fractional flow reserve (FFR)
- Instantaneous wave-free ratio (iFR)

Evaluation of Conditions other than Coronary Artery Disease (CD-7.7)

CD.DHC.0077.A

v2.1.2024

- Right and left heart catheterization (CPT® 93453) is indicated for any of the following:
 - Preoperative assessment prior to planned valvular surgery
 - Evaluation of pulmonary hypertension out of proportion to or unexplained by the severity of valvular disease documented by other non-invasive imaging modalities (i.e., echo, CMR)
 - Left ventricular dysfunction out of proportion to the severity of valvular disease documented by other non-invasive imaging modalities
 - Suspected pericardial tamponade as documented by clinical findings or other non-invasive imaging modalities
 - Suspected, or clinical uncertainty, between constrictive pericarditis vs. restrictive cardiomyopathy physiology when there are questions left unanswered by other cardiac non-invasive imaging modalities
 - Known or suspected cardiomyopathy with or without heart failure documented by prior advanced imaging
 - Re-evaluation of known cardiomyopathy for any of the following:
 - Change in clinical status
 - Change in cardiac exam
 - When required to guide therapy
 - Hypertrophic Cardiomyopathy
 - Subvalvular aortic stenosis
- Right and left heart catheterization (CPT® 93453) is indicated when there is uncertainty between clinical impression and other non-invasive imaging modalities to evaluate the following valvular diseases:
 - Mitral stenosis
 - Mitral regurgitation
 - Aortic stenosis
 - Aortic regurgitation
- Left heart catheterization (CPT® 93452) for hemodynamic evaluation of the left ventricle and aorta is indicated to evaluate aortic stenosis when there is uncertainty between the clinical impression and non-invasive imaging modality findings.

References (CD-7)

v2.1.2024

1. Amsterdam EA, Wenger NK, Brindis RG, et al. 2014 AHA/ACC Guideline for the Management of Patients with Non-ST-Elevation Acute Coronary Syndromes: Executive Summary: A Report of the American College of Cardiology/American Heart Association Task Force on Practice Guidelines. *Circulation*. 2014;130(25):2354-2394. doi:10.1161/cir.000000000000133.
2. Levine GN, Bates ER, Bittl JA, et al. 2016 ACC/AHA Guideline Focused Update on Duration of Dual Antiplatelet Therapy in Patients With Coronary Artery Disease: A Report of the American College of Cardiology/American Heart Association Task Force on Clinical Practice Guidelines: An Update of the 2011 ACCF/AHA/SCAI Guideline for Percutaneous Coronary Intervention, 2011 ACCF/AHA Guideline for Coronary Artery Bypass Graft Surgery, 2012 ACC/AHA/ACP/AATS/PCNA/SCAI/STS Guideline for the Diagnosis and Management of Patients with Stable Ischemic Heart Disease, 2013 ACCF/AHA Guideline for the Management of ST-Elevation Myocardial Infarction, 2014 AHA/ACC Guideline for the Management of Patients With Non-ST-Elevation Acute Coronary Syndromes, and 2014 ACC/AHA Guideline on Perioperative Cardiovascular Evaluation and Management of Patients Undergoing Noncardiac Surgery. *Circulation*. 2016;134(10). doi:10.1161/cir.0000000000000404.
3. Fihn SD, Gardin JM, Abrams J, et al. 2012 ACCF/AHA/ACP/AATS/PCNA/SCAI/STS Guideline for the Diagnosis and Management of Patients with Stable Ischemic Heart Disease. *J Am Coll Cardiol*. 2012;60(24). doi:10.1016/j.jacc.2012.07.013.
4. Fihn SD, Blankenship JC, Alexander KP, et al. 2014 ACC/AHA/AATS/PCNA/SCAI/STS Focused Update of the Guideline for the Diagnosis and Management of Patients with Stable Ischemic Heart Disease: A Report of the American College of Cardiology/American Heart Association Task Force on Practice Guidelines, and the American Association for Thoracic Surgery, Preventive Cardiovascular Nurses Association, Society for Cardiovascular Angiography and Interventions, and Society of Thoracic Surgeons. *Circulation*. 2014;130(19):1749-1767. doi:10.1161/cir.0000000000000095.
5. Boden WE, O'Rourke RA, Teo KK, et al. Impact of Optimal Medical Therapy With or Without Percutaneous Coronary Intervention on Long-Term Cardiovascular End Points in Patients With Stable Coronary Artery Disease (from the COURAGE Trial). *Am J Cardiol*. 2009;104(1):1-4. doi:10.1016/j.amjcard.2009.02.059.
6. Whelton PK, Carey RM, Aronow WS, et al. 2017 ACC/AHA/AAPA/ABC/ACPM/AGS/APhA/ASH/ASPC/NMA/PCNA guideline for the prevention, detection, evaluation, and management of high blood pressure in adults: a report of the American College of Cardiology/American Heart Association Task Force on Clinical Practice Guidelines. *J Am Coll Cardiol* 2018;71:e127-248. doi:10.1016/j.jacc.2017.11.001.
7. Maron DJ, Hochman JS, Reynolds HR, et al. Initial Invasive or Conservative Strategy for Stable Coronary Disease. *N Engl J Med*. 2020;382(15):1395-1407. doi:10.1056/nejmoa1915922.
8. Neumann FJ, Sousa-Uva M, Ahlsson A, et al. 2018 ESC/EACTS Guidelines on myocardial revascularization. *European Heart Journal*. 2018;40(2):87-165. doi:10.1093/eurheartj/ehy394.
9. Gulati M, Levy PD, Mukherjee D, et al. 2021 AHA/ACC/ASE/CHEST/SAEM/SCCT/SCMR Guideline for the Evaluation and Diagnosis of Chest Pain: A Report of the American College of Cardiology/American Heart Association Joint Committee on Clinical Practice Guidelines [published correction appears in *Circulation*. 2021 Nov 30;144(22):e455]. *Circulation*. 2021;144(22):e368-e454. doi:10.1161/CIR.0000000000001029.
10. Patel MR, Bailey SR, Bonow RO, et al. ACCF/SCAI/AATS/AHA/ASE/ASNC/HFSA/HRS/SCCM/SCCT/SCMR/STS 2012 appropriate use criteria for diagnostic catheterization: American College of Cardiology Foundation Appropriate Use Criteria Task Force Society for Cardiovascular Angiography and Interventions American Association for Thoracic Surgery American Heart Association, American Society of Echocardiography American Society of Nuclear Cardiology Heart Failure Society of America Heart Rhythm Society, Society of Critical Care Medicine Society of Cardiovascular Computed Tomography Society for Cardiovascular Magnetic Resonance Society of Thoracic Surgeons. *Catheter Cardiovasc Interv*. 2012;80(3):E50-E81. doi:10.1002/ccd.24467.
11. Nishimura RA, Carabello BA. Hemodynamics in the cardiac catheterization laboratory of the 21st century. *Circulation*. 2012;125(17):2138-2150. doi:10.1161/CIRCULATIONAHA.111.060319.
12. Patel MR, Calhoun JH, Dehmer GJ, et al. ACC/AATS/AHA/ASE/ASNC/SCAI/SCCT/STS 2017 Appropriate Use Criteria for Coronary Revascularization in Patients With Stable Ischemic Heart Disease: A Report of the American College of Cardiology Appropriate Use Criteria Task Force, American Association for Thoracic Surgery, American Heart Association, American Society of Echocardiography, American Society of Nuclear Cardiology, Society for Cardiovascular Angiography and Interventions, Society of Cardiovascular Computed Tomography, and Society of Thoracic Surgeons [published correction appears in *J Am Coll Cardiol*. 2018 Apr 13;]. *J Am Coll Cardiol*. 2017;69(17):2212-2241. doi:10.1016/j.jacc.2017.02.001.

13. Kidney Disease: Improving Global Outcomes (KDIGO) Kidney Transplant Candidate Work Group. KDIGO Clinical Practice Guideline on the Evaluation and Management of Candidates for Kidney Transplantation. *Transplantation*. 2020;104: S1 – S103.
14. Spitzer E, McFadden E, Vranckx P, et al. Defining Staged Procedures for Percutaneous Coronary Intervention Trials. *J Am Coll Cardiol Interv*. 2018 May, 11 (9) 823–832. <https://doi.org/10.1016/j.jcin.2018.03.044>.
15. Multimodality Writing Group for Chronic Coronary Disease, Winchester DE, Maron DJ, et al. ACC/AHA/ASE/ASNC/ASPC/HFSA/HRS/SCAI/SCCT/SCMR/STS 2023 Multimodality Appropriate Use Criteria for the Detection and Risk Assessment of Chronic Coronary Disease. *J Am Coll Cardiol*. 2023;81(25):2445-2467. doi:10.1016/j.jacc.2023.03.410.
16. D'Avila A, Gutierrez P, Scanavacca M, et al. Effects of radiofrequency pulses delivered in the vicinity of the coronary arteries: implications for nonsurgical transthoracic epicardial catheter ablation to treat ventricular tachycardia. *Pacing Clin Electrophysiol* 2002;25:1488–1495.
17. Cronin EM, Bogun FM, Maury P, et al. 2019 HRS/EHRA/APHRS/LAHR expert consensus statement on catheter ablation of ventricular arrhythmias. *Heart Rhythm*. 2020 Jan;17(1):e2-e154.
18. Yamada T, McElderry HT, Doppalapudi H, et al. Idiopathic ventricular arrhythmias originating from the aortic root prevalence, electrocardiographic and electrophysiologic characteristics, and results of radiofrequency catheter ablation. *J Am Coll Cardiol* 2008; 52:139–147.
19. Baman TS, Ilg KJ, Gupta SK, et al. Mapping and ablation of epicardial idiopathic ventricular arrhythmias from within the coronary venous system. *Circ Arrhythm Electrophysiol* 2010;3:274–279.
20. Cheng XS, VanWagner LB, Costa SP, et al. Emerging Evidence on Coronary Heart Disease Screening in Kidney and Liver Transplantation Candidates: A Scientific Statement From the American Heart Association: Endorsed by the American Society of Transplantation. *Circulation*. 2022;146(21):e299-e324. doi:10.1161/CIR.0000000000001104.
21. VanWagner LB, Harinstein ME, Runo JR, et al. Multidisciplinary approach to cardiac and pulmonary vascular disease risk assessment in liver transplantation: An evaluation of the evidence and consensus recommendations. *Am J Transplant*. 2018;18(1):30-42. doi:10.1111/ajt.14531.
22. Patel MR, Calhoon JH, Dehmer GJ, et al. ACC/AATS/AHA/ASE/ASNC/SCAI/SCCT/STS 2017 Appropriate Use Criteria for Coronary Revascularization in Patients With Stable Ischemic Heart Disease: A Report of the American College of Cardiology Appropriate Use Criteria Task Force, American Association for Thoracic Surgery, American Heart Association, American Society of Echocardiography, American Society of Nuclear Cardiology, Society for Cardiovascular Angiography and Interventions, Society of Cardiovascular Computed Tomography, and Society of Thoracic Surgeons [published correction appears in *J Am Coll Cardiol*. 2018 Apr 13;:]. *J Am Coll Cardiol*. 2017;69(17):2212-2241. doi:10.1016/j.jacc.2017.02.001.
23. Humbert M, Kovacs G, Hoeper M, et al. 2022 ESC/ERS Guidelines for the diagnosis and treatment of pulmonary hypertension: Developed by the task force for the diagnosis and treatment of pulmonary hypertension of the European Society of Cardiology (ESC) and the European Respiratory Society (ERS). Endorsed by the International Society for Heart and Lung Transplantation (ISHLT) and the European Reference Network on rare respiratory diseases (ERN-LUNG). *Eur Heart J* 2022;43(38):3618–3731. doi.org/10.1093/eurheartj/ehac237.
24. Morris PD, Curzen N, Gunn JP. Angiography-Derived Fractional Flow Reserve: More or Less Physiology? *J Am Heart Assoc*. 2020 Mar 17;9(6):e015586. doi: 10.1161/JAHA.119.015586.
25. Witberg G et al. Clinical Outcomes of FFRangio-Guided Treatment for Coronary Artery Disease. *JACC Cardiovasc Interv*. 2022 Feb 28;15(4):468-470. doi: 10.1016/j.jcin.2021.11.039.
26. Arefinia F et al. Non-invasive fractional flow reserve estimation using deep learning on intermediate left anterior descending coronary artery lesion angiography images. *Sci Rep*. 2024 Jan 20;14(1):1818. doi: 10.1038/s41598-024-52360-5.
27. Advancing Cath Lab Results With FFRangio Coronary Physiology Assessment (ALL-RISE) ClinicalTrials.gov Identifier: NCT05893498. Study Start: 2023-06-21. Primary Completion (Estimated): 2024-12. ClinicalTrials.gov.

Adult Congenital Heart Disease

Guideline

- Congenital heart disease – General Information (CD-11.1)
- ASD-Atrial septal defects (CD-11.2.1)
- Anomalous Pulmonary Venous Connections (CD-11.2.2)
- Ventricular Septal Defect (VSD) (CD-11.2.3)
- Atrioventricular Septal Defect (AV Canal, AVSD, endocardial cushion defect) (CD-11.2.4)
- Patent Ductus Arteriosus (PDA) (CD-11.2.5)
- Cor Triatriatum (CD-11.2.6)
- Congenital Mitral Stenosis (CD-11.2.7)
- Subaortic Stenosis (SAS) (CD-11.2.8)
- Congenital Valvular Aortic Stenosis (CD-11.2.9)
- Aortic disease in Turner Syndrome (CD-11.2.10)
- Supravalvular Aortic Stenosis (CD-11.3.1)
- Coarctation of the Aorta (CD-11.3.2)
- Valvular Pulmonary Stenosis (CD-11.3.3)
- Branch and Peripheral pulmonary stenosis (CD-11.3.4)
- Double chambered RV (CD-11.3.5)
- Ebstein Anomaly (CD-11.3.6)
- Tetralogy of Fallot (TOF, VSD with PS) (CD-11.3.7)
- Right Ventricle-to-Pulmonary Artery Conduit (CD-11.3.8)
- Transposition of the great arteries (TGA) (CD-11.3.9)
- Congenitally corrected TGA (CD-11.3.10)
- Fontan Palliation of Single Ventricle Physiology (CD-11.3.11)
- Severe Pulmonary artery hypertension (PHT) and Eisenmenger syndrome (CD-11.3.12)
- Coronary artery anomalies (CD-11.3.13)
- Pregnancy – Maternal Imaging (CD-11.4)
- References (CD-11)

Congenital heart disease – General Information (CD-11.1)

CD.CHD.0011.1.A

v2.1.2024

- This section covers adult congenital heart disease (CHD), for other associated disorders please see the condition specific sections
 - Marfan Syndrome
 - Hypertrophic cardiomyopathy (HCM)
 - Bicuspid aortic valve (BAV)

Guideline

Definitions (CD-11.1.1)

Modalities (CD-11.1.2)

Coding (CD-11.1.3)

Congenital Heart Disease Imaging Indications

Aortopathies with CHD

Definitions (CD-11.1.1)

- Physiological stages (A, B, C, D)
 - Each congenital heart lesion is divided into 4 physiological stages (A, B, C, D)

Characteristics	Physiological stage			
	A	B	C	D
NYHA functional class	I	II	III	IV
Hemodynamic or anatomic sequelae	None	Mild ventricular enlargement of dysfunction, small shunt	Moderate or greater, ventricular dysfunction. Any venous or arterial stenosis	Moderate or greater, ventricular dysfunction. Any venous or arterial stenosis
Valvular	None	Mild	Moderate or greater	Moderate or greater
Aortic enlargement	None	Mild	Moderate	Severe
Exercise capacity limitation	Normal	Abnormal objective cardiac limitation	Moderate	Severe

Characteristics	Physiological stage			
	A	B	C	D
Renal hepatic pulmonary dysfunction	None		Mild but responsive to medication	Refractory to treatment
Cyanosis/hypoxemia	None		Mild	Severe
Arrhythmias	None	Arrhythmia not requiring treatment	Needs rx	Refractory to rx
Pulmonary hypertension	None		Mild to moderate	Severe or Eisenmenger

- CHD Anatomic classification
 - Class I-Simple
 - Native disease
 - Isolated small ASD
 - Isolated small VSD
 - Mild isolated pulmonic stenosis
 - Repaired conditions
 - Previously ligated or occluded ductus arteriosus
 - Repaired secundum ASD or sinus venosus defect without significant residual shunt or chamber enlargement
 - Repaired VSD without significant residual shunt or chamber enlargement
 - Class II-Moderate Complexity
 - Repaired or unrepaired conditions
 - Aorto-left ventricular fistula
 - Anomalous pulmonary venous connection, partial or total
 - Anomalous coronary artery arising from the pulmonary artery
 - Anomalous aortic origin of a coronary artery from the opposite sinus
 - AVSD (partial or complete, including primum ASD)
 - Congenital aortic valve disease
 - Congenital mitral valve disease
 - Coarctation of the aorta
 - Ebstein anomaly (disease spectrum includes mild, moderate, and severe variations)
 - Infundibular right ventricular outflow obstruction
 - Ostium primum ASD
 - Moderate and large unrepaired secundum ASD

- Moderate and large persistently patent ductus arteriosus
- Pulmonary valve regurgitation (moderate or greater)
- Pulmonary valve stenosis (moderate or greater)
- Peripheral pulmonary stenosis
- Sinus of Valsalva fistula/aneurysm
- Sinus venosus defect
- Subvalvular aortic stenosis (excluding HCM; HCM not addressed in these guidelines)
- Supravalvular aortic stenosis
- Straddling atrioventricular valve
- Repaired tetralogy of Fallot
- VSD with associated abnormality and/or moderate or greater shunt
- Class III- Great Complexity (or Complex)
 - Cyanotic congenital heart defect (unrepaired or palliated, all forms)
 - Double-outlet ventricle
 - Fontan procedure
 - Interrupted aortic arch
 - Mitral atresia
 - Single ventricle (including double inlet left ventricle, tricuspid atresia, hypoplastic left heart, any other anatomic abnormality with a functionally single ventricle)
 - Pulmonary atresia (all forms)
 - TGA (classic or d-TGA; CCTGA or l-TGA)
 - Truncus arteriosus
 - Other abnormalities of atrioventricular and ventriculoarterial connection (i.e., crisscross heart, isomerism, heterotaxy syndromes, ventricular inversion)

Modalities (CD-11.1.2)

- Echocardiogram- transthoracic (TTE) or transesophageal (TEE)
 - Transthoracic echocardiography (TTE) is an indispensable tool in the initial and serial follow-up evaluation to identify abnormalities and changes that commonly influence management decisions.
- Cardiac MRI (CMR)
 - CMR plays a valuable role in assessment of RV size and function, because it provides data that are reproducible and more reliable than data obtained with alternative imaging techniques
 - For intracardiac congenital heart disease, CMR will typically include flow velocity mapping for shunts and flow assessment.
 - Imaging that only requires aortic arch imaging, does not require intracardiac CMR, only MRA Chest.

- Cardiac Computed Tomography (CCT) and Cardiac Computed Tomography Angiography (CCTA)
 - The most important disadvantage of CCT (including CT angiography) as an imaging technique is the associated exposure to ionizing radiation.
- Cardiac catheterization
 - (hemodynamic and/or angiographic) in individuals with adult CHD AP classification II and III, or interventional cardiac catheterization in individuals with adult CHD AP classification I to III should be performed by, or in collaboration with, cardiologists with expertise in adult CHD
- Exercise Testing
 - Exercise test does not imply stress imaging
- Stress Imaging
 - Includes-MPI, stress echo, stress MRI
 - PET stress may be included as per **Cardiac PET (CD-6)**
- Circumstances where CMR, CCT, TEE, and/or Cardiac Catheterization may be Superior to TTE
 - Assessment of RV size and function in repaired Tetralogy of Fallot (TOF), systemic right ventricles, and other conditions associated with right ventricular (RV) volume and pressure overload
 - Identification of anomalous pulmonary venous connections
 - Serial assessment of thoracic aortic aneurysms, especially when the dilation might extend beyond the echocardiographic windows
 - Accurate assessment of pulmonary artery (PA) pressure and pulmonary vascular resistance
 - Assessment for re-coarctation of the aorta
 - Sinus venosus defects
 - Vascular rings
 - Evaluation of coronary anomalies
 - Quantification of valvular regurgitation

Coding (CD-11.1.3)

Modality	
Echocardiogram	
Transthoracic echocardiogram (TTE)	CPT®
TTE for congenital cardiac anomalies; complete	93303
TTE for congenital cardiac anomalies; limited study	93304

Modality	
TTE (2D) m-mode recording, complete, with spectral and color flow doppler echocardiography	93306
TTE (2D) with or without m-mode recording; complete	93307
TTE (2D) with or without m-mode recording; limited study	93308
Transesophageal echocardiogram (TEE)	
TEE (2D) including probe placement, imaging, interpretation, and report	93312
TEE for congenital cardiac anomalies; including probe placement, imaging, interpretation, and report	93315
MRI	
cardiac (CMR)	CPT®
Cardiac MRI for morphology and function without contrast	75557
Cardiac MRI for morphology and function without and with contrast	75561
MRI Chest	
MRI Chest without contrast	71550
MRI Chest with contrast	71551
MRI Chest with & without contrast	71552
MRI Angiography (MRA) MRA Chest	
MRA Chest (excluding myocardium) with or without contrast	71555
CT	
Cardiac (CCT)	CPT®
CT, Heart, with contrast material, for evaluation of cardiac structure and morphology	75572
CT, Heart, with contrast material, for evaluation of cardiac structure and morphology in the setting of congenital heart disease	75573
CT Angiography-cardiac (CCTA)	CPT®

Modality	
CTA Heart, coronary arteries and bypass grafts (when present), with contrast, including 3D image post-processing	75574
CT-Chest	CPT®
CT Thorax without contrast	71250
CT Thorax with contrast	71260
CT Thorax without & with contrast	71270
CT Angiography-Chest (CTA Chest)	CPT®
CTA Chest without and with contrast	71275
Stress Imaging (echo, MRI, MPI)	
Stress echo	CPT®
Echocardiography (TTE), (2D), with or without m-mode, during rest and cardiovascular stress, with interpretation and report	93350
Echocardiography (TTE), (2D), m-mode, during rest and cardiovascular stress test using treadmill, bicycle exercise and/or pharmacologically induced stress, with interpretation	93351
Stress MRI	CPT®
Cardiac MRI for morphology and function without contrast, with stress imaging	75559
Cardiac MRI for morphology and function without and with contrast, with stress imaging	75563
Myocardial perfusion imaging (MPI)	CPT®
MPI, tomographic (SPECT) including attenuation correction, qualitative or quantitative wall motion, ejection fraction by first pass or gated technique, additional quantification, when performed); single study, at rest or stress (exercise or pharmacologic)	78451

Modality	
MPI, tomographic (SPECT) (including attenuation correction, qualitative or quantitative wall motion, ejection fraction by first pass or gated technique, additional quantification, when performed); multiple studies, at rest and/or stress (exercise or pharmacologic) and/or redistribution and/or rest reinjection	78452
Pulmonary perfusion imaging	CPT®
Pulmonary perfusion imaging (e.g., particulate)	78580
Pulmonary ventilation (e.g., aerosol or gas) and perfusion imaging	78582
Quantitative differential pulmonary perfusion, including imaging when performed	78597
Quantitative differential pulmonary perfusion and ventilation (e.g., aerosol or gas), including imaging when performed	78598

Congenital Heart Disease Imaging Indications

- The following sections are based on the congenital heart lesion. Requests for imaging based on other cardiac conditions, such as CAD, HCM, acquired valvular lesions, should follow the adult cardiac guidelines for those conditions.

Aortopathies with CHD

- Dilated aortic arches are not uncommon with several congenital heart diseases and postoperative procedures including- Aortic stenosis, Ross repair, Tetralogy of Fallot, Transposition of the great arteries (TGA), Pulmonary atresia, hypoplastic left heart syndrome (HLHS), Truncus Arteriosus, single ventricle.

ASD-Atrial septal defects (CD-11.2.1)

CD.CHD.0011.2.1.A

v2.1.2024

Initial studies-Diagnosis, clinical changes, consideration of surgery

- Echocardiogram at time of diagnosis
 - CMR, CCT CPT® 75573), and/or TEE are useful if echo (TTE) is suboptimal and either:
 - ASD is suspected
 - To evaluate pulmonary venous connections in known ASD
 - MRA Chest or CTA Chest may be indicated if echo shows pulmonary venous anomalies
 - If normal, repeat pulmonary vein imaging is not required.
- Transesophageal echocardiogram (TEE) is recommended to guide percutaneous ASD closure
- Diagnostic cath is indicated when there is either:
 - Evidence of pulmonary hypertension
 - Unanswered questions on CMR/CCT for venous drainage.

Post-procedure imaging

- TTE is indicated post ASD device placement:
 - 6 months to evaluate for erosion
 - 1 week (if Amplatzer)
 - 1 month
 - 6 months
 - 12 months
 - then every 1-2 years
- Due to low-risk of erosion in PFO devices- PFO device closure requires follow-up at 6-12 months. No additional evaluation unless PFO not closed

Stress imaging and coronary artery imaging is based on **Stress Testing with Imaging – Indications (CD-1.4)**

Follow-up ASD if surgically closed or if no interventions

Modality	Physiological stage / intervals for routine imaging (months)			
Physiological stage	A	B	C	D
TTE	36	24	12	12

Anomalous Pulmonary Venous Connections (CD-11.2.2)

CD.CHD.0011.2.2.A

v2.1.2024

Initial studies-Diagnosis, clinical changes, consideration of surgery

- Echocardiogram at time of diagnosis
 - CMR and/or MRA Chest, or CT Cardiac and/or CTA Chest at time of diagnosis if any issues with pulmonary veins or RV volume.
 - Cardiac Cath at time of diagnosis for hemodynamic data and issues not answered on other imaging
- Routine stress imaging or coronary artery imaging not required.
- Echo, CMR, CT, per cardiology request for clinical changes
 - Diagnostic heart catheterization if questions unanswered on imaging

Follow-up Anomalous Pulmonary Venous Connections

Modality	Physiological stage / intervals for routine imaging (months)			
Physiological stage	A	B	C	D
Echo (TTE)	36	24	12	12

Ventricular Septal Defect (VSD) (CD-11.2.3)

CD.CHD.0011.2.3.A
v2.1.2024

Initial studies-Diagnosis, clinical changes, consideration of surgery

- Echo (TTE) at time of diagnosis
 - CMR or CCT can be performed if questions are unanswered on echo
 - Catheterization at time of diagnosis for hemodynamics if pulmonary hypertension (PHT) or shunt size is a question

Long term follow-up VSD

Modality	Physiological stage / intervals for routine imaging (months)			
Physiological stage	A	B	C	D
Echo (TTE)	36	24	12	12

Atrioventricular Septal Defect (AV Canal, AVSD, endocardial cushion defect) (CD-11.2.4)

CD.CHD.0011.2.4.A

v2.1.2024

Initial studies-Diagnosis, clinical changes, consideration of surgery

- Echo (TTE) at time of diagnosis
 - CMR or CT Cardiac at time of diagnosis if there are unanswered questions on echo
 - Cardiac cath at time of diagnosis when CMR and TTE leave questions unanswered that affect individual management
- Stress imaging per **Stress Testing with Imaging – Indications (CD-1.4)**

Long term follow-up -AVSD

Modality	Physiological stage / intervals for routine imaging (months)			
Physiological stage	A	B	C	D
Echo (TTE)	24	24	12	12

Patent Ductus Arteriosus (PDA) (CD-11.2.5)

CD.CHD.0011.2.5.A
v2.1.2024

Initial studies-Diagnosis, clinical changes, consideration of surgery

- Echo at time of diagnosis
 - MR Chest or CT Chest if there are questions left unanswered by echo
 - Cardiac Cath for hemodynamics (if planned device closure, diagnostic cardiac cath is not indicated as it is included in the procedure code)
- Stress imaging per **Stress Testing with Imaging – Indications (CD-1.4)**

Long term follow-up PDA

Modality	Physiological stage / intervals for routine imaging (months)			
Physiological stage	A	B	C	D
Echo (TTE)	36	24	12	12

Cor Triatriatum (CD-11.2.6)

CD.CHD.0011.2.6.A

v2.1.2024

Initial studies-Diagnosis, clinical changes, consideration of surgery

- Echocardiogram (TTE) at time of diagnosis
 - CMR and/or MRA Chest or CT Cardiac and/or CTA Chest may be approved
 - Diagnostic cath may be approved if additional information is required for medical management

Long term follow-up

- Stress imaging per [Stress Testing with Imaging – Indications \(CD-1.4\)](#)

Congenital Mitral Stenosis (CD-11.2.7)

CD.CHD.0011.2.7.A

v2.1.2024

Initial studies-Diagnosis, clinical changes, consideration of surgery

- Echocardiogram (TTE) at time of diagnosis

Long term follow-up congenital mitral stenosis

Modality	Physiological stage / intervals for routine imaging (months)			
Physiological stage	A	B	C	D
Echo (TTE)	24	24	12	12

Subaortic Stenosis (SAS) (CD-11.2.8)

CD.CHD.0011.2.8.A

v2.1.2024

This section relates to subaortic stenosis caused by a discrete membrane or tunnel-like obstruction.

Initial imaging/diagnosis, clinical changes, consideration of surgery

Modality	Initial imaging/diagnosis	Clinical changes	Consideration of surgery
Echo (TTE) (CPT® 93303 or 93304 or 93306 or 93308)	At time of diagnosis	For any clinical changes	If cardiac intervention is being considered
Stress echo or (CPT® 93351 or 93352) OR Stress MRI (CPT® 75559 or 75563)	Once at the time of diagnosis	<ul style="list-style-type: none"> New or changed signs or symptoms of ischemia Changes in cardiac function Any signs or symptoms allowed in <u>Stress Testing with Imaging – Indications (CD-1.4)</u> 	If cardiac intervention is being considered

Long term follow-up SAS

Modality	Physiological stage / intervals for routine imaging (months)			
	A	B	C	D
Echo (TTE)	24	24	12	12
Stress imaging		24	24	12

Congenital Valvular Aortic Stenosis (CD-11.2.9)

CD.CHD.0011.2.9.A

v2.1.2024

Initial studies-Diagnosis, clinical changes, consideration of surgery

- Echocardiogram (TTE) at time of diagnosis
- TEE may be required if TTE limited or equivocal
- MRA Chest or CTA Chest if one of the following:
 - Suspicion of Coarctation based on exam and echocardiogram
 - Proximal ascending aorta not well visualized on TTE

Routine follow-up Congenital Valvular Aortic Stenosis

Modality	Physiological stage / intervals for routine imaging			
Stage (valvular AS)	Progressive (stage B) Mild Vmax 2.0-2.9 m/s	Progressive (stage B) Moderate Vmax 3.0-3.9 m/s	Severe (stage C) ≥ 4.0 m/s	Aortic root dilation >4.5 cm
echo (TTE)	3 years	1 years	6 months	12 months
MRA Chest or CTA				if ascending allowed yearly

Degree of aortic stenosis (AS) severity			
	Mild AS	Moderate AS	Severe AS
Vmax (m/s) ^a maximum Doppler velocity	2.0-2.9	3.0-3.9	≥ 4.0
Mean gradient (mmHg) ^a	<30	30-49	≥ 50
AVA (cm ²) aortic valve area	>1.5	1.0-1.5	<1.0

Degree of aortic stenosis (AS) severity			
	Mild AS	Moderate AS	Severe AS
AVAi (cm ² /m ² BSA) indexed aortic valve area	≥1.0	0.6-0.9	<0.6
^a At normal transvalvular flow, BSA= body surface area			

Adapted from: ESC Guidelines for the management of grown-up congenital heart disease (new version 2010): The Task Force on the Management of Grown-up Congenital Heart Disease of the European Society of Cardiology (ESC).

Aortic disease in Turner Syndrome (CD-11.2.10)

CD.CHD.0011.2.10.A

v2.1.2024

Dissection more common for a given aortic diameter. Mid-ascending aortic disease more common and may not be reliably seen on echocardiogram

Initial studies-Diagnosis, clinical changes, consideration of surgery

- Echocardiogram (TTE) at time of diagnosis
- MRA Chest or CTA Chest to rule out mid ascending aortic aneurysm if mid aorta was not seen on echocardiogram.

Surveillance

- Echocardiogram (TTE) yearly
 - MRA Chest or CTA if mid ascending aorta not visualized
- For documented thoracic aortic aneurysm (TAA) \leq 4cm
 - Routine MRA Chest or CTA yearly
- For documented thoracic aortic aneurysm (TAA) $>$ 4cm
 - MRA Chest or CTA every 6 months.

Supravalvular Aortic Stenosis (CD-11.3.1)

CD.CHD.0011.3.1.A
v2.1.2024

Supravalvular aortic stenosis is a relatively rare condition overall but is seen commonly in individuals with Williams syndrome or homozygous familial hypercholesterolemia.

Initial studies-Diagnosis, clinical changes, consideration of surgery

- Echocardiogram (TTE) at time of diagnosis
- MRA Chest or CTA Chest
- Cardiac MRI or CTA Cardiac to assess coronary ostia
- Cardiac cath for any individuals pre-cardiac intervention for coronary arteries
- New cardiac symptoms-any of the following:
 - CT Cardiac or cardiac MR
 - CTA Chest or MRA Chest
 - Stress imaging as per **Stress Testing with Imaging – Indications (CD-1.4)**

Routine follow-up supravalvular AS

Modality	Physiological stage / intervals for routine imaging (months)			
Physiological stage	A	B	C	D
TTE	24	24	12	12
CMR or CCT	36	36	36	36

Coarctation of the Aorta (CD-11.3.2)

CD.CHD.0011.3.2.A

v2.1.2024

Coarctation is suspected based on clinical findings:

- BP higher in upper extremities than in the lower extremities
- Absent femoral pulses
- Continuous murmur
- Abdominal bruit
- Berry aneurysm with hemorrhage
- Rib notching on x-ray
- Abnormal thoracic aortic imaging and blood pressures

Initial studies-Diagnosis, clinical changes, consideration of surgery

- Echocardiogram (TTE) at time of diagnosis
 - No further imaging is required if echocardiogram (TTE), blood pressure, and exam rule out Coarctation.
 - If echo and exam are equivocal or positive one of the following is indicated:
 - CTA Chest
 - MRA Chest
 - Individuals with Coarctation of the aorta do not require intra-cardiac MRI unless issue cannot be resolved on echocardiogram.
 - Screening for intracranial aneurysm by MRA or CTA of head is allowed
- ETT for diagnosis of exercise induced hypertension does not require imaging
- Cardiac MRI not required unless issues unresolved by echo for intracardiac anatomy
- Diagnostic cath can be approved prior to stenting of the coarctation
- Stress imaging, TEE, Cardiac MRI or CT, Coronary imaging not routine

Symptomatic

- Individuals with Coarctation are at risk for dissection. When individual has new or worsening symptoms any of the following:
 - Echocardiogram (TTE)
 - MRA Chest or CTA.
- For exertional symptoms, one of the following:
 - Stress imaging-per **Stress Testing with Imaging – Indications (CD-1.4)**
 - Cardiac MRI or CT Cardiac

Routine follow-up Coarctation of the Aorta

Modality	Physiological stage / intervals for routine imaging (months)			
Physiological stage	A	B	C	D
TTE	24	24	12	12
MRA Chest or CTA Chest	36	36	12	12

Valvular Pulmonary Stenosis (CD-11.3.3)

CD.CHD.0011.3.3.A

v2.1.2024

Overview Initial studies-Diagnosis, clinical changes, consideration of surgery

- Echocardiogram (TTE) at time of diagnosis
- For issues affecting management not well visualized on TTE
 - Cardiac MRI or CT Cardiac
 - MRA Chest or CTA Chest

Valvular PS routine follow-up and testing.

- Echocardiogram-stages
 - Mild PS – peak gradient <36 mmHg (peak velocity < 3m/s)
 - Moderate PS- peak gradient 36-64 mmHg (peak velocity 3-4 m/s)
 - Severe PS- peak gradient >64 mmHg (peak velocity > 4 m/s); or mean gradient >35 mmHg.
- Routine stress imaging is not required
- Routine chest or cardiac or ischemia workup not required.

Valvular PS routine imaging

Modality	Physiological stage / intervals for routine imaging (months)			
Physiological stage	A	B	C	D
TTE	36	24	12	12

Isolated Pulmonary regurgitation after PS repair-Echo and CMR at same interval as TOF

Modality	Physiological stage / intervals for routine imaging (months)			
Physiological stage	A	B	C	D
TTE	24	12	12	12
CMR	36	24	12	12

Branch and Peripheral pulmonary stenosis (CD-11.3.4)

CD.CHD.0011.3.4.A

v2.1.2024

Overview

- Can be seen in newborns as a normal variant in the first 6 months of life
- Can be seen in surgeries of right ventricular outflow (TOF)
 - Noonan
 - Alagille
 - Williams
 - Maternal rubella exposure
 - Keutel syndrome

Initial studies-Diagnosis, clinical changes, consideration of surgery

- Echocardiogram (TTE) at time of diagnosis
- Baseline MRA Chest or CTA Chest
- Cath may be considered if other advanced imaging is not adequate for management
- VQ scan or MRA Chest for differential blood flow

Routine follow-up branch and peripheral pulmonary stenosis

Modality	Physiological stage / intervals for routine imaging (months)			
Physiological stage	A	B	C	D
TTE	24	24	12	12
Cardiac MRI or CT Cardiac	36	36	24	24
MRA Chest or CTA Chest	36	36	24	24

Double chambered RV (CD-11.3.5)

CD.CHD.0011.3.5.A

v2.1.2024

Initial studies-Diagnosis, clinical changes, consideration of surgery

- Echocardiogram (TTE) at time of diagnosis

Routine follow-up double chambered right ventricle (RV)

Modality	Physiological stage / intervals for routine imaging (months)			
Physiological stage	A	B	C	D
Echo (TTE)	24	24	12	12

Ebstein Anomaly (CD-11.3.6)

CD.CHD.0011.3.6.A

v2.1.2024

Overview Initial studies-Diagnosis, clinical changes, consideration of surgery

- Echocardiogram (TTE) at time of diagnosis
- TEE if either:
 - TTE is not adequate
 - If surgery/intervention planned
- Cardiac MRI or CT Cardiac at time of Diagnosis

Routine follow-up Ebstein Anomaly

Modality	Physiological stage / intervals for routine imaging (months)			
Physiological stage	A	B	C	D
Echo (TTE)	12	12	12	12
Cardiac MRI or CT Cardiac	60	36	24	12

Tetralogy of Fallot (TOF, VSD with PS) (CD-11.3.7)

CD.CHD.0011.3.7.A

v2.1.2024

Includes TOF with pulmonary atresia, VSD PA

Initial studies-Diagnosis, clinical changes, consideration of surgery

- Echocardiogram (TTE) at time of diagnosis
- Cardiac MR or CTA Cardiac at time of diagnosis
- MRA Chest or CTA Chest at time of diagnosis
- Cardiac catheterization if other advanced imaging leaves unanswered questions

Prior to cardiac intervention or surgery

- Repeat imaging Echo/MR/CT
- Cath prior to surgery or intervention
 - If planned Catheter Pulmonary Valve replacement, procedure includes diagnostic cath and hemodynamics and diagnostic cath is not billed separately

New or worsening symptoms

- Repeat advanced imaging
 - New or worsening symptoms
 - New EKG changes
- Stress imaging (stress echo, stress MRI, or MPI) allowed for typical chest pain, even if intermediate pretest probability at atypical symptoms in individuals with known or undefined coronary artery (CA) anatomy or CA pathology
- VQ scan or MRA chest for left/right perfusion abnormality

Routine Follow-up Tetralogy of Fallot (TOF)

Modality	Physiological stage / intervals for routine imaging (months)			
	A	B	C	D
TTE	24	12	12	12
Cardiac MRI or CCTA	36	24	12	12

Modality	Physiological stage / intervals for routine imaging (months)			
Physiological stage	A	B	C	D
CTA Chest or MRA	36	24	12	12

Right Ventricle-to-Pulmonary Artery Conduit (CD-11.3.8)

CD.CHD.0011.3.8.A

v2.1.2024

Initial studies-Diagnosis, clinical changes, consideration of surgery. Surgical repair for many lesions such as TOF/ Truncus /Pulmonary atresia

- Echocardiogram (TTE) at time of diagnosis
- Cardiac MRI or CTA Cardiac
- MRA Chest or CTA Chest
- Prior to interventions or surgery may repeat any of the above imaging
- Cath allowed for new symptoms or with new imaging findings as needed for management
- Stress imaging (stress echo, stress MRI or MPI) as requested for symptoms

Routine follow-up Right Ventricle-to-Pulmonary Artery Conduit

Modality	Physiological stage / intervals for routine imaging (months)			
Physiological stage	A	B	C	D
TTE	12	12	12	12
CMR or CCTA	36	36	12	12
MRA Chest or CTA Chest	36	36	12	12

Transposition of the great arteries (TGA) (CD-11.3.9)

CD.CHD.0011.3.9.A

v2.1.2024

Initial studies-Diagnosis, clinical changes, consideration of surgery

- Echocardiogram (TTE) at time of diagnosis
- Baseline Cardiac MRI or CCTA
- Baseline MRA Chest or CTA
- Stress imaging as requested for symptoms or signs of ischemia
- V/Q scan for left to right PA perfusion or MRA Chest
- Symptomatic individuals should be offered stress physiological imaging and repeat anatomic imaging considered if symptoms are suggestive of coronary ischemia (regardless of diamond forester pretest probability category)
- Cath right and left heart when issues not elucidated on advanced imaging

Routine follow-up TGA

Modality	Physiological stage / intervals for routine imaging (months)			
Physiological stage	A	B	C	D
TTE	12	12	12	12
CMR or CCTA	36	24	12	12
MRA Chest or CTA Chest	36	24	12	12

Congenitally corrected TGA (CD-11.3.10)

CD.CHD.0011.3.10.A
v2.1.2024

Initial studies-Diagnosis, clinical changes, consideration of surgery

- Echocardiogram (TTE) at time of diagnosis
- Baseline CMR and MRA Chest
- CMR and/or Echo for changes in clinical status

Routine follow-up congenitally corrected TGA

Modality	Physiological stage / intervals for routine imaging (months)			
Physiological stage	A	B	C	D
Echo (TTE)	12	12	12	12
CMR or CCTA	36	36	12	12
CTA Chest or MRA Chest	36	36	12	12

Fontan Palliation of Single Ventricle Physiology (CD-11.3.11)

CD.CHD.0011.3.11.A

v2.1.2024

Including Tricuspid Atresia and Double Inlet Left Ventricle, HLHS, HRHS, PA, Mitral atresia, AVC unbalanced, single ventricle, DIRV, pulmonary atresia, HLHS, Glen procedure, TA, double outlet right ventricle (DORV), and single ventricle physiology

Initial studies-Diagnosis, clinical changes, consideration of surgery

- Echocardiogram (TTE) at time of diagnosis and with any new Symptoms
- CMR or CCTA can be done annually (vs. based on below chart) on individuals who have prior issues that were equivocal on echo, and the data is required (i.e. very poor windows)
 - Cardiac catheterization prior to surgical interventions
- Echo/CMR or CCTA/MRA Chest or CTA Chest/cath with any new signs or symptoms
- V/Q scan or MRA for lung perfusion left vs. right

Routine follow-up Fontan Palliation of Single Ventricle Physiology

Modality	Physiological stage / intervals for routine imaging (months)			
Physiological stage	A	B	C	D
Echo (TTE)	12	12	12	12
CMR or CT Cardiac	36	24	24	24
CTA Chest or MRA	36	24	24	24
Cardiac catheterization	120 (10 years)	120 (10 years)	120 (10 years)	120 (10 years)

Severe Pulmonary artery hypertension (PHT) and Eisenmenger syndrome (CD-11.3.12)

CD.CHD.0011.3.12.A

v2.1.2024

Initial studies-Diagnosis, clinical changes, consideration of surgery

- Echo (TTE)
 - Initial diagnosis
 - With new signs or symptoms
- Cardiac cath
 - Echo (TTE) results suggest PHT
 - New signs or symptoms with PHT

Long term follow-up Severe Pulmonary artery hypertension (PHT) and Eisenmenger syndrome

Modality	Physiological stage / intervals for routine imaging (months)			
Physiological stage	A	B	C	D
TTE			6	6
CMR or CCT			As needed	As needed
MRA Chest or CTA Chest			As needed	As needed
Cath			As needed	As needed

Coronary artery anomalies (CD-11.3.13)

CD.CHD.0011.3.13.A

v2.1.2024

Initial studies-Diagnosis, clinical changes, consideration of surgery

- Echocardiogram (TTE)
 - At baseline
 - Any signs or symptoms
- Coronary CT/MR/Cath for initial evaluation
- Coronary artery from wrong sinus-baseline stress imaging regardless of symptoms
- Stress imaging for any cardiac signs or symptoms
- For Kawasaki GL regarding echo, Stress imaging, coronary imaging, see pediatric GL **Kawasaki Disease (PEDCD-6)**

Pregnancy – Maternal Imaging (CD-11.4)

CD.DHC.0011.4.A

v2.1.2024

- Overview
 - World Health Organization (WHO) classification:
 - WHO classification I: no detectable increased risk of maternal mortality and no/mild increase in morbidity.
 - Uncomplicated small or mild pulmonary stenosis
 - Patent Ductus Arteriosus (PDA)
 - Mitral valve prolapse
 - Successfully repaired simple lesions (atrial or ventricular septal defect, patent ductus arteriosus, anomalous pulmonary venous connection)
 - WHO classification II: small increase in maternal risk mortality or moderate increase in morbidity.
 - Unrepaired atrial or ventricular septal defect
 - Repaired tetralogy of Fallot
 - WHO classification II–III (depending on individual)
 - Mild left ventricular impairment
 - Native or tissue valvular heart disease not considered WHO I or IV
 - Marfan syndrome without aortic dilation
 - Aorta <45 mm in association with bicuspid aortic valve disease
 - Repaired coarctation
 - WHO classification III: significantly increased risk of maternal mortality or severe morbidity. Expert counseling required. If pregnancy is decided upon, intensive specialist cardiac and obstetric monitoring needed throughout pregnancy, childbirth and the puerperium.
 - Mechanical valve
 - Systemic right ventricle
 - Fontan circulation
 - Unrepaired cyanotic heart disease
 - Other complex congenital heart disease
 - Aortic dilation 40–45 mm in Marfan syndrome
 - Aortic dilation 45–50 mm in bicuspid aortic valve disease
 - WHO classification IV: extremely high risk of maternal mortality or severe morbidity; pregnancy contraindicated. If pregnancy occurs, termination should be discussed. If pregnancy continues, care as for WHO class III.
 - Pulmonary arterial hypertension from any cause

- Severe systemic ventricular dysfunction (LVEF <30%, NYHA functional class III–IV)
- Severe mitral stenosis; severe symptomatic aortic stenosis
- Marfan syndrome with aorta dilated >45 mm
- Aortic dilation >50 mm in aortic disease associated with bicuspid aortic valve
- Native severe coarctation of the aorta

Adapted from: Elkayam U, Goland S, Pieper PG, Silversides CK. High-Risk Cardiac Disease in Pregnancy. Journal of the American College of Cardiology.

- Congenital heart disease imaging in pregnancy
 - Echocardiogram (TTE) when planning pregnancy
 - TEE if TTE equivocal
 - CMR can be performed prior to planning pregnancy in those lesions where CMR would be routinely performed at some later date
 - CTA Chest or MRA Chest of arch if known disease with aortic involvement or if known dilation
 - Repeat echocardiogram and MR (can be without gad) can be performed based on the WHO classification II, III, IV, or other risk factors
 - Severe complex CHD TTE (93306)
 - Every 2-4 weeks for major physiological changes
 - As often as needed for any of the following:
 - Pulmonary hypertension
 - Changes in function
 - To guide delivery after 24 weeks
 - Echo can be performed if new signs or symptoms during pregnancy
 - Postpartum first year can have more frequent imaging
 - Stress imaging pre/during pregnancy for individuals with known coronary artery anomaly, pulmonary hypertension, LVOT obstruction, cardiac dysfunction, single ventricle.
 - WHO II, III, IV, can have echo/MR/CT/stress imaging prior to pregnancy
 - WHO I- one echocardiogram during pregnancy
 - WHO II- one echocardiogram per trimester during pregnancy
 - WHO II/III- echocardiogram every 2 months during pregnancy
 - WHO III/IV- echocardiogram monthly during pregnancy
 - Individuals may require more (even weekly) if treatment decision, delivery is considered.
- Syndromes that allow cardiac imaging at the time of diagnosis if not previously done. This list is not exhaustive
 - DiGeorge/velocardiofacial (22q11.2)
 - Down syndrome (trisomy 21)

- Holt Oram (TBX5)
- Klinefelter syndrome (47 XXY)
- Noonan (PTPN11, KRAS, SOS1 RAF1, NRAS, BRAF, MAP2K1)
- Turner (45X)
- Williams (7q11.23 deletion)
- Any syndrome associated with congenital heart disease.
- Echocardiogram at time of Diagnosis (either genetic testing or clinical features)
- CMR or CCTA if arch involved in disease.
- See **Maternal Imaging in Cardiovascular Disease (CD-15)**

References (CD-11)

v2.1.2024

1. Mcelhinney DB, Quartermain MD, Kenny D, Alboliras E, Amin Z. Relative Risk Factors for Cardiac Erosion Following Transcatheter Closure of Atrial Septal Defects. *Circulation*. 2016;133(18):1738-1746. doi:10.1161/circulationaha.115.019987.
2. Center for Devices and Radiological Health. 2018 Meeting Materials of the Circulatory System Devices Panel. U.S. Food and Drug Administration. <https://www.fda.gov/advisory-committees/circulatory-system-devices-panel/2018-meeting-materials-circulatory-system-devices-panel>. Published December 3, 2018.
3. Doherty JU, Kort S, Mehran R, Schoenhagen P, Soman P. ACC/AATS/AHA/ASE/ASNC/HRS/SCAI/SCCT/SCMR/STS 2019 Appropriate Use Criteria for Multimodality Imaging in the Assessment of Cardiac Structure and Function in Nonvalvular Heart Disease. *J Nucl Cardiol*. 2019;26(4):1392-1413. doi:10.1007/s12350-019-01751-7.
4. Stout KK, Daniels CJ, Aboulhosn JA, et al. 2018 AHA/ACC Guideline for the Management of Adults with Congenital Heart Disease: A Report of the American College of Cardiology/American Heart Association Task Force on Clinical Practice Guidelines. *Circulation*. 2019;139(14). doi:10.1161/cir.0000000000000603
5. Silvestry FE, Cohen MS, Armsby LB, et al. Guidelines for the Echocardiographic Assessment of Atrial Septal Defect and Patent Foramen Ovale: From the American Society of Echocardiography and Society for Cardiac Angiography and Interventions. *J Am Soc Echocardiogr*. 2015;28(8):910-958. doi:10.1016/j.echo.2015.05.015.
6. El-Said HG, Bratincsak A, Foerster SR, et al. Safety of Percutaneous Patent Ductus Arteriosus Closure: An Unselected Multicenter Population Experience. *Journal of the American Heart Association*. 2013;2(6). doi:10.1161/jaha.113.000424.
7. Franklin RCG, Béland MJ, Colan SD, et al. Nomenclature for congenital and paediatric cardiac disease: the International Paediatric and Congenital Cardiac Code (IPCCC) and the Eleventh Iteration of the International Classification of Diseases (ICD-11). *Cardiology in the Young*. 2017;27(10):1872-1938. doi:10.1017/s1047951117002244.
8. Whelton PK, Carey RM, Aronow WS, et al. 2017 ACC/AHA/AAPA/ABC/ACPM/AGS/APhA/ASH/ASPC/NMA/PCNA Guideline for the Prevention, Detection, Evaluation, and Management of High Blood Pressure in Adults: A Report of the American College of Cardiology/American Heart Association Task Force on Clinical Practice Guidelines. *Hypertension*. 2018;71(6). doi:10.1161/hyp.0000000000000065.
9. Shen W-K, Sheldon RS, Benditt DG, et al. 2017 ACC/AHA/HRS Guideline for the Evaluation and Management of Patients with Syncope: A Report of the American College of Cardiology/American Heart Association Task Force on Clinical Practice Guidelines and the Heart Rhythm Society. *Circulation*. 2017;136(5). doi:10.1161/cir.0000000000000499.
10. Page RL, Joglar JA, Caldwell MA, et al. 2015 ACC/AHA/HRS Guideline for the Management of Adult Patients with Supraventricular Tachycardia. *Circulation*. 2016;133(14). doi:10.1161/cir.0000000000000311.
11. Chaikof EL, Dalman RL, Eskandari MK, et al. The Society for Vascular Surgery practice guidelines on the care of patients with an abdominal aortic aneurysm. *Journal of Vascular Surgery*. 2018;67(1). doi:10.1016/j.jvs.2017.10.044.
12. AMPLATZER PFO Occluder: PFO Closure Device. Abbott Cardiovascular. <https://www.cardiovascular.abbott/us/en/hcp/products/structural-heart/amplatzer-pfo.html>.
13. Madhkour R, Wahl A, Praz F, Meier B. Amplatzer patent foramen ovale occluder: safety and efficacy. *Expert Review of Medical Devices*. 2019;16(3):173-182. doi:10.1080/17434440.2019.1581060.
14. Drummond A. AMPLATZER Patent Foramen Ovale (PFO) Occluder: FDA Review of P120021 Office of Device Evaluation Center for Devices and Radiological Health (CDRH) Food and Drug Administration May 24, 2016. <https://www.fda.gov/media/98643/download>.
15. Updates to Instructions for Use (IFU) concerning Erosion with the Amplatzer Atrial Septal Occluder (ASO). Last updated on 06 Jul 2014. https://www.hsa.gov.sg/content/hsa/en/Health_Products_Regulation/Safety_Information_and_Product_Recalls/Dear_Healthcare_Professional_Letters/2013/Updates_to_Instructions_for_Use_IFU_concerning_Erosion_with_the_Amplatzer_Atrial_Septal_Occluder_ASO.html.
16. Amsterdam EA, Wenger NK, Brindis RG, et al. 2014 AHA/ACC Guideline for the Management of Patients with Non–ST-Elevation Acute Coronary Syndromes. *Circulation*. 2014;130(25). doi:10.1161/cir.0000000000000134.
17. Priori SG, Wilde AA, Horie M, et al. Executive summary: HRS/EHRA/APHRS expert consensus statement on the diagnosis and management of patients with inherited primary arrhythmia syndromes. *EP Europace*. 2013;15(10):1389-1406. doi:10.1093/europace/eut272.

18. Daniels CJ, Bradley EA, Landzberg MJ, et al. Fontan-Associated Liver Disease. *J Am Coll Cardiol*. 2017;70(25):3173-3194. doi:10.1016/j.jacc.2017.10.045.
19. Collado FMS, Poulin MF, Murphy JJ, Jneid H, Kavinsky CJ. Patent Foramen Ovale Closure for Stroke Prevention and Other Disorders. *Journal of the American Heart Association*. 2018;7(12). doi:10.1161/jaha.117.007146.
20. Khairy P, Hare GFV, Balaji S, et al. PACES/HRS Expert Consensus Statement on the Recognition and Management of Arrhythmias in Adult Congenital Heart Disease. *Canadian Journal of Cardiology*. 2014;30(10). doi:10.1016/j.cjca.2014.09.002.
21. Kusumoto FM, Schoenfeld MH, Barrett C, et al. 2018 ACC/AHA/HRS Guideline on the Evaluation and Management of Patients with Bradycardia and Cardiac Conduction Delay. *J Am Coll Cardiol*. 2018. doi:10.1016/j.jacc.2018.10.044.
22. Fleisher LA, Fleischmann KE, Auerbach AD, et al. 2014 ACC/AHA Guideline on Perioperative Cardiovascular Evaluation and Management of Patients Undergoing Noncardiac Surgery. *J Am Coll Cardiol*. 2014;64(22). doi:10.1016/j.jacc.2014.07.944.
23. Galiè N, Humbert M, Vachiery J-L, et al. 2015 ESC/ERS Guidelines for the diagnosis and treatment of pulmonary hypertension. *European Respiratory Journal*. 2015;46(4):903-975. doi:10.1183/13993003.01032-2015.
24. Otto CM, Kumbhani DJ, Alexander KP, et al. 2017 ACC Expert Consensus Decision Pathway for Transcatheter Aortic Valve Replacement in the Management of Adults with Aortic Stenosis. *J Am Coll Cardiol*. 2017;69(10):1313-1346. doi:10.1016/j.jacc.2016.12.006.
25. O'gara PT, Kushner FG, Ascheim DD, et al. 2013 ACCF/AHA Guideline for the Management of ST-Elevation Myocardial Infarction. *J Am Coll Cardiol*. 2013;61(4). doi:10.1016/j.jacc.2012.11.019.
26. Stout KK, Daniels CJ, Aboulhosn JA, et al. 2018 AHA/ACC Guideline for the Management of Adults with Congenital Heart Disease. *J Am Coll Cardiol*. 2018;73(12). doi:10.1016/j.jacc.2018.08.1029.
27. Elkayam U, Goland S, Pieper PG, Silversides CK. High-Risk Cardiac Disease in Pregnancy. *J Am Coll Cardiol*. 2016;68(4):396-410. doi:10.1016/j.jacc.2016.05.048.
28. Sachdeva R, Valente AM, Armstrong AK, et al. ACC/AHA/ASE/HRS/ISACHD/SCAI/SCCT/SCMR/SOPE 2020 Appropriate Use Criteria for Multimodality Imaging During the Follow-Up Care of Patients with Congenital Heart Disease. *J Am Coll Cardiol*. 2020;75(6):657-703. doi:10.1016/j.jacc.2019.10.002.
29. Rychik J, Atz AM, Celermajer DS, et al. Evaluation and Management of the Child and Adult With Fontan Circulation: A Scientific Statement From the American Heart Association [published online ahead of print, 2019 Jul 1]. *Circulation*. 2019; doi:10.1161/CIR.0000000000000696.

Maternal Imaging in Cardiovascular Disease

Guideline

Diagnostic Cardiovascular Imaging Pre-Pregnancy to Post-Partum (CD-15.1)

Maternal imaging in cardiovascular disease (CD-15.2)

Maternal Imaging in Individuals with Aortopathy (CD-15.3)

Imaging in Pregnancy with Congenital Heart Disease (CHD) (CD-15.4)

Diagnostic Cardiovascular Imaging Pre-Pregnancy to Post-Partum (CD- 15.1)

CD.MI.0015.1.A
v2.1.2024

Guideline

Maternal imaging in cardiovascular disease
Peripartum Red Flag Signs and Symptoms
Imaging Modalities in Maternal Imaging
Background and Supporting Information
References

Maternal imaging in cardiovascular disease

Ultrasound and magnetic resonance are the preferred imaging modalities to minimize radiation exposure in pregnancy. When imaging using ionizing radiation is necessary, radiation exposure should follow the ALARA principle (As Low As Reasonably Achievable). Shared decision making regarding diagnostic testing should occur in consultation with the individual, cardiologist, and obstetrical team when weighing the risk of fetal exposure to radiation against the need to diagnose or plan treatment for serious illness.

Peripartum Red Flag Signs and Symptoms

Imaging as requested, as listed within **Imaging Modalities in Maternal Imaging** (Echocardiogram, Exercise stress echo, Coronary angiography, Cardiac MRI), is indicated for peripartum individuals for any of the following **red flag** signs or symptoms:

- Chest pain
- Dyspnea
- Orthopnea
- Cough
- Lower extremity edema when there is a concern for heart disease
- Tachycardia
- Unheralded syncope
- Headache
- Acute visual changes
- New onset hypotension
- Hypertension

Imaging Modalities in Maternal Imaging

Transthoracic echocardiography (TTE)

- TTE (CPT® 93306) is the primary cardiac imaging modality in pregnancy. Baseline and surveillance echocardiography is indicated for several conditions as noted in **Maternal imaging in cardiovascular disease (CD-15.2)** Table 1.
- A repeat echocardiogram is indicated when there are new or worsening cardiovascular signs or symptoms, as described in **Peripartum Red Flags, Transthoracic Echocardiography (TTE)– Indications/initial evaluation (CD-2.2)** and **Frequency of Echocardiography Testing (CD-2.3)**, during and after pregnancy.

Exercise Stress Echo

- Exercise stress echo (CPT® 93350, 93351) is indicated pre-conception to assist with risk stratification in individuals with a documented history of **any** of the following:
 - Current left ventricular dysfunction
 - Previous history of left ventricular dysfunction
 - Valvular heart disease of any severity
 - There is a concern for myocardial reserve
- See Stress echocardiogram in **Stress Testing with Imaging – Indications (CD-1.4)** and **Stress echo–indications other than ruling out CAD (CD-2.7)**
- See **Hypertrophic Cardiomyopathy (CD-14)**

Coronary Angiography

- Fetal risk from ionizing radiation is highest before 20 weeks gestational age. When coronary angiography is medically necessary, the ALARA principle should be followed. Invasive management of acute coronary syndrome is associated with lower in-hospital mortality and should be considered. See **Diagnostic Heart Catheterization**

Cardiac MRI

- Cardiac MRI (CPT® 75557) is utilized in pregnant individuals to measure aortic dimensions, wall motion and ventricular function when the echocardiogram is non-diagnostic. Gadolinium-based contrast agents are not necessary in aortic imaging or most other indications in pregnancy. **See Cardiac MRI**

Background and Supporting Information

- Cardiovascular disease (CVD) in pregnancy has become increasingly prevalent in recent years.
- The increase in plasma volume during pregnancy requires significant physiological adaptation.
- Maternal mortality has increased in the last two decades with CVD accounting for 33% of all deaths.
- Invasive management of myocardial infarction (MI) is associated with lower in-hospital mortality.

- Research has underrepresented females of childbearing age leading to significant deficits in our knowledge of cardiovascular care of these individuals.
- **Cardiac Imaging using ionizing radiation**
 - Multiple imaging modalities expose the pregnant individual and fetus to ionizing radiation.
 - This exposure causes concern for an elevated risk of childhood cancer.
 - Shared decision-making should be employed when weighing the fetal exposure to radiation against the need to diagnose serious illness

References

1. Park K, Bairey Merz CN, Bello NA, et al. Management of Women With Acquired Cardiovascular Disease From Pre-Conception Through Pregnancy and Postpartum: JACC Focus Seminar 3/5. *J Am Coll Cardiol.* 2021;77(14):1799-1812. doi:10.1016/j.jacc.2021.01.057.
2. Bello NA, Bairey Merz CN, Brown H, et al. Diagnostic Cardiovascular Imaging and Therapeutic Strategies in Pregnancy: JACC Focus Seminar 4/5. *J Am Coll Cardiol.* 2021;77(14):1813-1822. doi:10.1016/j.jacc.2021.01.056.

Maternal imaging in cardiovascular disease (CD-15.2)

CD.MI.0015.2.A

v2.1.2024

Table 1: Suggested frequency of echo monitoring during pregnancy

Cardiovascular disease	Monitoring frequency
Hypertensive disorders of pregnancy (BP \geq 130/90)	<ul style="list-style-type: none"> An echocardiogram (TTE) (CPT® 93303, 93304, 93306, 93307, 93308) is indicated once during pregnancy in all hypertensive disorders of pregnancy. A repeat TTE is indicated when there are new or worsening cardiovascular signs or symptoms
Valvular disorders/Native and Prosthetic	<ul style="list-style-type: none"> One TTE is indicated during the first trimester (weeks 1-12 of pregnancy) for individuals with known or suspected valvular heart disease. A repeat TTE is indicated when there are new or worsening cardiovascular signs or symptoms
Severe Aortic stenosis (AS)	<ul style="list-style-type: none"> A repeat TTE is indicated every 1-2 months or when there are new or worsening cardiovascular signs or symptoms
Mitral stenosis (MS)	<ul style="list-style-type: none"> TTE is indicated each trimester (12 weeks) and prior to delivery in individuals with mild MS. TTE is indicated every 1–2 months in individuals with moderate to severe MS. A repeat TTE is indicated when there are new or worsening cardiovascular signs or symptoms
Dilated cardiomyopathy	<ul style="list-style-type: none"> TTE is indicated during each trimester (12 weeks) A repeat TTE is indicated when there are new or worsening cardiovascular signs or symptoms
Hypertrophic cardiomyopathy	<ul style="list-style-type: none"> TTE is indicated in asymptomatic individuals each trimester TTE is indicated in symptomatic individuals every 1-2 months. A repeat TTE is indicated when there are new or worsening cardiovascular signs or symptoms

Cardiovascular disease	Monitoring frequency
Peripartum cardiomyopathy	<p>TTE is indicated in individuals with signs and symptoms of heart failure.</p> <ul style="list-style-type: none"> • A repeat TTE is indicated when there are new or worsening cardiovascular signs or symptoms • TTE is indicated in subsequent pregnancies: <ul style="list-style-type: none"> • At the time of the first prenatal visit • At the end of the first and second trimesters • One month prior to delivery • After delivery prior to discharge • One month postpartum • At any time when there are worsening signs or symptoms of heart failure • Cabergoline
Pulmonary hypertension	<ul style="list-style-type: none"> • TTE is indicated in individuals with signs and symptoms of pulmonary hypertension • A repeat TTE is indicated at the discretion of the health care provider.

References

1. O'Kelly AC, Sharma G, Vaught AJ, Zakaria S. The Use of Echocardiography and Advanced Cardiac Ultrasonography During Pregnancy. *Curr Treat Options Cardiovasc Med.* 2019;21(11):71. Published 2019 Nov 21. doi:10.1007/s11936-019-0785-5.
2. Bello NA, Bairey Merz CN, Brown H, et al. Diagnostic Cardiovascular Imaging and Therapeutic Strategies in Pregnancy: JACC Focus Seminar 4/5. *J Am Coll Cardiol.* 2021;77(14):1813-1822. doi:10.1016/j.jacc.2021.01.056.
3. Hemnes AR, Kiely DG, Cockrill BA, et al. Statement on pregnancy in pulmonary hypertension from the Pulmonary Vascular Research Institute. *Pulm Circ.* 2015;5(3):435-465. doi:10.1086/682230.

Maternal Imaging in Individuals with Aortopathy (CD-15.3)

CD.MI.0015.3.A

v2.1.2024

Pre-pregnancy imaging

Individuals at risk for aortic aneurysms (**Table 15-3-1**) should be evaluated with echocardiogram (TTE) **and** Computed Tomography (CT)/ Magnetic Resonance Imaging (MRI) of the Chest/Abdomen/Pelvis (**Table 15-3-2**) within 1 year prior to conception to evaluate for aortic valve disease and aortic dimensions.

Table 15-3-1

Individuals at risk for aortic aneurysm, aortic dissection, limb-threatening ischemia
Bicuspid Aortic Valve
Turner Syndrome
Coarctation of the Aorta
Marfan Syndrome
Type IV Ehlers-Danlos
Loeys-Dietz
Familial Thoracic Aortic Disease and Aortic Dissection (defined as first-degree relative with history of aortic dissection or thoracic aortic aneurysm or two second-degree relatives with history of aortic dissection or thoracic aortic aneurysm)

Table 15-3-2

Imaging for Aortic conditions	CPT®
CT Chest and/or Abdomen and/or Pelvis	71260
	74177
	74160
	72193

Imaging for Aortic conditions	CPT®
CTA Chest and/or Abdomen and/or Pelvis	71275
	74175
	72191
	74174
MRA Chest and/or Abdomen and/or Pelvis	71555
	74185
	72198
Transthoracic Echocardiogram (TTE)	93303
	93304
	93306
	93307
	93308
Transesophageal Echocardiogram (TEE)	93312
	93313
	93314
	93315
	93316
	93317
Doppler echocardiography- is indicated as add-on codes for TEE	+93320
	+93321
	+93325

Surveillance imaging during pregnancy and postpartum

Follow-up imaging with Echocardiogram (TTE) and CTA/MRA. TEE can be substituted if TTE is equivocal.

Table 15-3-3

Suggested Frequency of Aortic Imaging during pregnancy and postpartum in individuals known to be high-risk for aortic aneurysm

Condition	WHO Class	Imaging frequency	Postpartum (up to 42 days after birth)
Turner Syndrome	<ul style="list-style-type: none"> II-III: Aortic root <20mm/m² with associated risk factors or <25 mm/m without associated risk factors 	<ul style="list-style-type: none"> Once during pregnancy if normal aortic dimension, or every two months if repaired coarctation 	<ul style="list-style-type: none"> Once during the postpartum period
	<ul style="list-style-type: none"> IV: Aortic root ≥20mm/m² with associated risk factors or ≥25 mm/m without associated risk factors 	<ul style="list-style-type: none"> Every 6 weeks if aorta diameter dilated >30mm 	<ul style="list-style-type: none"> Once during the postpartum period
	<ul style="list-style-type: none"> Any patient with Turner who has severe coarctation 	<ul style="list-style-type: none"> At discretion of provider 	<ul style="list-style-type: none"> Once during the postpartum period
Marfan Syndrome	<ul style="list-style-type: none"> III: Aortic root <45mm, mod-severe Aortic Insufficiency 	<ul style="list-style-type: none"> Every trimester if <40mm 	<ul style="list-style-type: none"> Once during the postpartum period
	<ul style="list-style-type: none"> IV: Aortic root ≥45mm, history of dissection 	<ul style="list-style-type: none"> Every 6 weeks if aorta is ≥40mm 	<ul style="list-style-type: none"> Once during the postpartum period
Vascular Ehlers-Danlos	<ul style="list-style-type: none"> Type IV 	<ul style="list-style-type: none"> Every 6 weeks 	<ul style="list-style-type: none"> Once during the postpartum period
Loeys-Dietz	<ul style="list-style-type: none"> III: Aortic diameter <40mm 	<ul style="list-style-type: none"> Every 6 weeks 	<ul style="list-style-type: none"> Once during the postpartum period
	<ul style="list-style-type: none"> IV: Aortic diameter ≥40mm 	<ul style="list-style-type: none"> Every 6 weeks 	<ul style="list-style-type: none"> Once during the postpartum period
Familial thoracic aortic aneurysms and	<ul style="list-style-type: none"> III: Aortic diameter <40mm 	<ul style="list-style-type: none"> Every trimester if <40mm aortic diameter 	<ul style="list-style-type: none"> Once during the postpartum period

Condition	WHO Class	Imaging frequency	Postpartum (up to 42 days after birth)
dissections	<ul style="list-style-type: none">IV: Aortic diameter ≥ 40mm	<ul style="list-style-type: none">Every 6 weeks if ≥ 40mm aortic diameter	<ul style="list-style-type: none">Once during the postpartum period

Background and supporting information

First-degree relative (sibling, parent, child).

Second-degree relative (aunt/uncles, grandparent, niece, nephew, cousin, or half-sibling of an individual)

References

1. Lindley KJ, Bairey Merz CN, Asgar AW, et al. Management of Women With Congenital or Inherited Cardiovascular Disease From Pre-Conception Through Pregnancy and Postpartum: JACC Focus Seminar 2/5. *J Am Coll Cardiol.* 2021;77(14):1778-1798. doi:10.1016/j.jacc.2021.02.026.

Imaging in Pregnancy with Congenital Heart Disease (CHD) (CD-15.4)

CD.MI.0015.4.A

v2.1.2024

Pre-pregnancy imaging based on the World Health Organization (WHO) chart for imaging in pregnancy with CHD

Imaging modality and indication	CPT®
Echo (TTE) when planning pregnancy	93306
TEE if TTE equivocal	93312
CMR (cardiac MRI) can be performed prior to pregnancy in those lesions where CMR would be routinely performed at some later date	75557
CTA or MRA of chest if known aortic disease, Pulmonary artery disease, anomalous pulmonary veins, anomalous systemic veins. (also see peripartum aortopathy table.)	71275, 71555
Echo with new signs or symptoms	93303, 93304, 93306, 93308
Postpartum imaging per provider requested frequency	imaging as noted above
Stress imaging pre/during pregnancy when known Coronary artery anomaly, pulmonary hypertension, LVOT obstruction, cardiac dysfunction, single	93350, 93351, 93320, 93325
WHO II, III, IV, can have echo/MR/CT/stress imaging prior to pregnancy	imaging as noted above

Surveillance Imaging

Surveillance imaging after baseline studies.

TTE frequency after initial imaging, (Individuals who also have aortopathy can have Chest MRA in addition to echo at same frequency.) Individuals with known poor/inadequate imaging on echo, can have CMR in lieu of echocardiogram.

The World Health Organization modified classification of maternal cardiovascular risk

The World Health Organization established a modified classification of maternal cardiovascular risk used as a tool to evaluate risk status for pregnant individuals with various cardiovascular conditions. See **Pregnancy-Maternal Imaging (CD-11.4)**

Class	Risk	Sample Lesions
WHO Class I	No detectable increased risk of maternal mortality and no or mild increase in morbidity.	<ul style="list-style-type: none"> Mild Pulmonary stenosis Small PDA Mild MVP Successfully repaired simple lesions (ASD, VSD, PDA, anomalous pulmonary venous drainage) Isolated PACs or PVCs
WHO Class II	Small increased risk of maternal mortality or moderate increase in morbidity.	<ul style="list-style-type: none"> Un-operated ASD or VSD Repaired TOF (uncomplicated) Most arrhythmias
WHO Class II-III	Intermediate increased risk of maternal mortality or moderate to severe increase in morbidity.	<ul style="list-style-type: none"> Mild left ventricular impairment Hypertrophic cardiomyopathy Native or tissue valvular heart disease not considered WHO I or IV Aorta <45 mm in aortic disease associated with bicuspid aortic valve Repaired coarctation
WHO Class III	Significantly increased risk of maternal mortality or severe morbidity. <ul style="list-style-type: none"> Expert counseling required. If pregnancy is decided upon, intensive specialist cardiac and obstetric monitoring needed throughout pregnancy, childbirth and the postpartum period. 	<ul style="list-style-type: none"> Mechanical valve Systemic right ventricle Fontan circulation Unrepaired cyanotic heart disease Other complex congenital heart disease

Class	Risk	Sample Lesions
WHO Class IV	<p>Extremely high-risk of maternal mortality or severe morbidity.</p> <ul style="list-style-type: none">• Pregnancy contraindicated.• If pregnancy occurs, termination should be discussed.• If pregnancy continues, care as for WHO class III.	<ul style="list-style-type: none">• Pulmonary arterial hypertension from any cause• Severe systemic ventricular dysfunction (LVEF <30%, NYHA functional class III-IV)• Severe mitral stenosis; severe symptomatic aortic stenosis• Aortic dilation ≥ 50 mm in aortic disease associated with bicuspid aortic valve• Native severe coarctation of the aorta

References

1. Steiner JM, Lokken E, Bayley E, et al. Cardiac and Pregnancy Outcomes of Pregnant Patients With Congenital Heart Disease According to Risk Classification System. *Am J Cardiol.* 2021;161:95-101. doi:10.1016/j.amjcard.2021.08.037.
2. Canobbio MM, Warnes CA, Aboulhosn J, et al. Management of Pregnancy in Patients With Complex Congenital Heart Disease: A Scientific Statement for Healthcare Professionals From the American Heart Association. *Circulation.* 2017;135(8):e50-e87. doi:10.1161/CIR.0000000000000458.

Condition Specific Imaging

Guideline

Cardiotoxic Agent-Related Cardiac Dysfunction (CD-12)
Cardiac Sarcoidosis (CD-3.9)
Cardiac Trauma Imaging (CD-10.1)
Congestive Heart Failure (CD-9)
Pre-Surgical Cardiac Testing (CD-13)
Pulmonary Hypertension (PH) (CD-8.1)
Pulmonary Vein Imaging – Indications (CD-8.2)
Hypertrophic Cardiomyopathy (HCM) (CD-14)

Cardiotoxic Agent-Related Cardiac Dysfunction (CD-12)

CD.CS.0012.A

v2.1.2024

Guideline

Cardiotoxic agent/Cancer Therapeutics-Related Cardiac Dysfunction (CD-12.1)

Myocardial Strain Imaging (CD-12.2)

Mavacamten for Obstructive Hypertrophic Cardiomyopathy (HCM) (CD-12.3)

References (CD-12)

Cardiotoxic agent/Cancer Therapeutics-Related Cardiac Dysfunction (CD-12.1)

Transthoracic Echocardiogram (TTE)

Transthoracic Echocardiogram (TTE) is indicated to determine Left Ventricular (LV) function in individuals on cardiotoxic chemotherapeutic drugs

- 3D echocardiography CPT[®] 93319 is indicated in addition to the primary TTE and is the preferred echocardiography modality for the assessment of left ventricular ejection fraction (LVEF) and cardiac volumes. See **3D Echocardiography (CD 2.9)**
- Myocardial strain imaging (CPT[®] 93356) to obtain a Global Longitudinal Strain (GLS) is indicated as an important adjunct in screening for CTRCD. See **Myocardial Strain Imaging (CD 12.2)**

Multimodality imaging

- Guidelines support using echocardiography rather than MUGA for the determination of LVEF and/or wall motion EXCEPT in one of the circumstances described previously in **MUGA Study – Cardiac Indications (CD-3.4)**. (see **Background and supporting information** below).
- CT coronary calcium scoring (CPT[®] 75571) is indicated every 5 years to screen for radiation induced coronary artery disease, unless previous coronary calcium score is >0 in cancer survivors who have received chest radiation therapy.
- Cardiac MRI (CMR) is indicated in the evaluation of CTRCD for the following:
 - TTE is not diagnostic
 - Tissue characterization for cardiomyopathy or myocarditis, particularly when Immune Checkpoint Inhibitor Myocarditis is being questioned.
 - See also **Cardiac MRI and MRA Chest – Indications (CD 5.2)**.

Frequency of CTRCD screening

- Baseline
 - All patients can have a baseline TTE prior to initiation of cardiotoxic agents
- During treatment with cardiotoxic agents
 - The frequency of monitoring depends on the agent administered and the patient's baseline cardiovascular toxicity risk. (See **Background and Supporting Information** below)
- Post treatment with cardiotoxic agents surveillance
 - One TTE is indicated 3 to 12 months after completion of therapy
- Adult cancer survivors
 - Long term surveillance TTE is indicated every 5 years, except in those with low risk
 - Additional surveillance TTE, at 1 and 3 years after cancer therapy completion is indicated in those deemed to be high risk for CTRCD
- Adult survivors of childhood and adolescent cancer
 - Surveillance TTE is indicated every 2 years for survivors with indeterminate risk due to unknown cancer therapy history
 - Surveillance TTE is indicated every 2 years for high risk survivors, defined as a history of any of the following:
 - Radiation dose ≥ 30 Gy
 - Anthracycline dose of < 100 mg/m² and radiation dose ≥ 15 Gy
 - Anthracycline dose ≥ 250 mg/m²
 - Surveillance TTE is indicated every 5 years for moderate risk survivors, defined as a history of any of the following:
 - Radiation dose ≥ 15 to < 30 Gy
 - Anthracycline dose of < 250 mg/m² and radiation dose < 15 Gy
 - No screening is indicated in low risk survivors, defined as a history of any of the following:
 - Anthracycline dose of > 0 to < 100 mg/m²
 - Radiation dose > 0 to < 15 Gy
- TTE is indicated for cancer survivors with a history of chest radiotherapy or anthracycline exposure who are pregnant or planning to become pregnant as follows:
 - Baseline exam
 - 12 weeks of pregnancy if missed the baseline TTE or in high risk survivors
 - 20 weeks of pregnancy for high risk survivors
 - TTE can be repeated for any symptoms at any other time as needed during or immediately following pregnancy

- Adults who received anthracyclines in childhood see **Cardiotoxicity and Echocardiography (PEDONC-19.2)**

Background and supporting information

- High value screening protocol to detect CTRCD using TTE (CPT® 93306 or 93308) is contingent upon careful baseline cardiotoxicity risk assessment and stratification into low, moderate and high risk. Currently, there is no universally accepted risk score, documentation of risk by the provider is sufficient to guide screening strategy.
- Advantages of Echocardiography in comparison to MUGA in individuals on cardiotoxic chemotherapy:
 - No ionizing radiation
 - No IV access required when echo contrast is not used
 - Allows view of the pericardium to look for effusion
 - Allows estimate of pulmonary pressure
 - May allow visualization of a clot or tumor in the Inferior Vena Cava (IVC) and/or the right heart

Myocardial Strain Imaging (CD-12.2)

- Myocardial strain imaging (CPT® 93356) in addition to the primary echocardiogram in individuals receiving therapy with cardiotoxic agents for ANY of the following:
 - Initial evaluation-prior to treatment with EITHER:
 - Medications that could result in cardiotoxicity/heart failure
 - Radiation that could result in cardiotoxicity/heart failure
 - Re-evaluation of an individual previously or currently undergoing therapy as per echocardiogram parameters. See **Cardiotoxic agent/Cancer Therapeutics-Related Cardiac Dysfunction (CD-12.1)**
 - Re-evaluation of an individual undergoing therapy with worsening symptoms

Mavacamten for Obstructive Hypertrophic Cardiomyopathy (HCM) (CD-12.3)

Echocardiogram (CPT® 93306) is indicated for individuals treated with mavacamten for class II-III obstructive HCM as follows:

Initiation of treatment

- Baseline-at the beginning of treatment
- 4 weeks after treatment initiation
- 8 weeks after treatment initiation
- 12 weeks after treatment initiation
- Then every 12 weeks while on mavacamten

Changes in treatment

- 4 weeks after any interruption of treatment (any missed dose)
- After any dosage change (including restart of treatment):
 - 4 weeks after dosage change
 - 12 weeks after dosage change
- After initiating a weak CYP2C19 inhibitor (e.g., omeprazole) or moderate CYP3A4 inhibitor (e.g., ciprofloxacin):
 - 4 weeks after start of medication
 - 12 weeks after start of medication
- At any time regardless of timing of prior echo when there are new cardiac signs or symptoms, or worsening of clinical status

See also **Hypertrophic Cardiomyopathy (HCM) (CD-14)**

Background and supporting information

Hypertrophic Cardiomyopathy (HCM) is a clinical diagnosis, established by imaging with 2D echocardiography or cardiovascular magnetic resonance (CMR) showing a maximal end-diastolic wall thickness of ≥ 15 mm anywhere in the left ventricle, in the absence of another cause of hypertrophy in adults. More limited hypertrophy (13–14 mm) can be diagnostic, particularly when present in family members of a patient with HCM or in conjunction with a positive genetic test, and/or associated with typical dynamic outflow obstruction, or distinctly abnormal ECG patterns.

References (CD-12)

1. Hendel RC, Berman DS, Carli MFD, et al. ACCF/ASNC/ACR/AHA/ASE/SCCT/SCMR/SNM 2009 Appropriate Use Criteria for Cardiac Radionuclide Imaging. *Circulation*. 2009;119(22). doi:10.1161/circulationaha.109.192519.
2. Genentech: Herceptin® (trastuzumab) - Information for Healthcare Providers. Genentech: Herceptin® (trastuzumab) - Information for Healthcare Providers. <https://www.gene.com/medical-professionals/medicines/herceptin>.
3. Virizuela JA, García AM, Peñas RDL, et al. SEOM clinical guidelines on cardiovascular toxicity (2018). *Clinical and Translational Oncology*. 2019;21(1):94-105. doi:10.1007/s12094-018-02017-3.
4. Friedman DL, Hudson MM. Health Link: Heart Health. Long-Term Follow-Up Guidelines for Survivors of Childhood, Adolescent, and Young Adult Cancers. <http://www.survivorshipguidelines.org/>. Published October 2018.
5. Marian AJ, Braunwald E. Hypertrophic Cardiomyopathy: Genetics, Pathogenesis, Clinical Manifestations, Diagnosis, and Therapy. *Circ Res*. 2017;121(7):749-770. doi:10.1161/CIRCRESAHA.117.311059.
6. CAMZYOS. Highlights of Prescribing Information. Bristol Myers Squibb. April 2022. https://packageinserts.bms.com/pi/pi_camzyos.pdf.
7. Lopez-Mattei J, et al. Cardiac computed tomographic imaging in cardio-oncology: An expert consensus document of the Society of Cardiovascular Computed Tomography (SCCT). Endorsed by the International Cardio-Oncology Society (ICOS). *J Cardiovasc Comput Tomogr*. 2023 Jan-Feb;17(1):66-83.
8. Ehrhardt MJ, Leerink JM, et al. Systematic review and updated recommendations for cardiomyopathy surveillance for survivors of childhood, adolescent, and young adult cancer from the International Late Effects of Childhood Cancer Guideline Harmonization Group. *Lancet Oncol*. 2023 Mar;24(3):e108-e120.
9. Lyon AR, Wilhelm M, Zamorano JL, et al. 2022 ESC Guidelines on cardio-oncology developed in collaboration with the European Hematology Association (EHA), the European Society for Therapeutic

Radiology and Oncology (ESTRO) and the International Cardio-Oncology Society (IC-OS). *Eur Heart J.* 2022 Nov 1;43(41):4229-4361.

Cardiac Sarcoidosis (CD-3.9)

CD.CS.0003.9.A

v2.1.2024

Guideline

Cardiac Sarcoidosis (CD-3.9)

References

Cardiac Sarcoidosis (CD-3.9)

Suspected cardiac sarcoidosis (see [Background and Supporting Information](#))

- MRI imaging of the heart with gadolinium (CPT[®] 75561). Initial imaging for identification of suspected cardiac sarcoid should be cardiac MRI with late gadolinium enhancement (LGE) protocol unless there is a contraindication to MRI imaging (non-MRI safe pacemaker, renal failure). Absence of LGE is a strong negative predictor for low rates of cardiac morbidity and mortality from cardiac sarcoid and further testing is not usually indicated.
- PET – Metabolic imaging with F-18 FDG for diagnosis if there is a contraindication to MRI and cardiac sarcoid is suspected. Requires PET with F-18 FDG metabolic study combined with a PET perfusion study (CPT[®] 78432 or CPT[®] 78433) OR PET metabolic study (CPT[®] 78459 or CPT[®] 78429) and SPECT perfusion image (CPT[®] 78451).
 - For equivocal MRI
 - To confirm diagnosis if suggested by MRI

Monitoring of treatment of established cardiac sarcoidosis

- PET - Cardiac PET metabolic is indicated to monitor therapy in cardiac sarcoidosis. Requires PET with F-18 FDG metabolic study combined with a PET perfusion study (CPT[®] 78432 or CPT[®] 78433) OR PET metabolic study (CPT[®] 78459 or CPT[®] 78429) and SPECT perfusion image (CPT[®] 78451).
 - Prior to treatment of cardiac sarcoid
 - PET (heart FDG metabolic with perfusion study as above) can be repeated at 3-6 month intervals if there is active disease or to make therapeutic decisions.

Background and supporting information

- Cardiac imaging is reasonable to detect cardiac sarcoid in the following:
 - Any patient with extra cardiac sarcoid even if no cardiac symptoms
 - Echo with basal thinning of the intraventricular septum, depressed EF <50 or regional wall motion abnormality not associated with CAD

- Young patients with unexplained ventricular tachycardia, especially monomorphic VT
- Patients with unexplained cardiomyopathy or heart failure (i.e., CAD has been ruled out)
- Patients with unexplained arrhythmia especially advanced AV block or VT
- Full body PET/CT (CPT[®] 78815) is not indicated for the diagnosis or monitoring response to therapy of cardiac sarcoid. It may be considered to assist in diagnosis and/or treatment options in some instances of pulmonary sarcoid. See **Sarcoid (CH-15.1)** in the Chest Imaging Guidelines

References

1. Birnie DH, Sauer WH, Bogun F, et al. HRS expert consensus statement on the diagnosis and management of arrhythmias associated with cardiac sarcoidosis. *Heart Rhythm*. 2014;11(7):1305-1323. doi:10.1016/j.hrthm.2014.03.043.
2. Blankstein R, Waller AH. Evaluation of Known or Suspected Cardiac Sarcoidosis. *Circ Cardiovasc Imaging*. 2016;9(3):e000867. doi:10.1161/CIRCIMAGING.113.000867.
3. Bravo PE, Singh A, Di Carli MF, Blankstein R. Advanced cardiovascular imaging for the evaluation of cardiac sarcoidosis. *J Nucl Cardiol*. 2019;26(1):188-199. doi:10.1007/s12350-018-01488-9.
4. Kim SJ, Pak K, Kim K. Diagnostic performance of F-18 FDG PET for detection of cardiac sarcoidosis; A systematic review and meta-analysis. *J Nucl Cardiol*. 2020;27(6):2103-2115. doi:10.1007/s12350-018-01582-y.
5. Manabe O, Oyama-Manabe N, Aikawa T, et al. Advances in Diagnostic Imaging for Cardiac Sarcoidosis. *J Clin Med*. 2021;10(24):5808. doi:10.3390/jcm10245808.
6. Ramirez R, Trivieri M, Fayad ZA, et al. Advanced Imaging in Cardiac Sarcoidosis. *J Nucl Med*. 2019;60(7):892-898. doi:10.2967/jnumed.119.228130
7. Writing group; Document reading group; EACVI Reviewers: This document was reviewed by members of the EACVI Scientific Documents Committee for 2014–2016 and 2016–2018. A joint procedural position statement on imaging in cardiac sarcoidosis: from the Cardiovascular and Inflammation & Infection Committees of the European Association of Nuclear Medicine, the European Association of Cardiovascular Imaging, and the American Society of Nuclear Cardiology. *Eur Heart J Cardiovasc Imaging*. 2017;18(10):1073-1089. doi:10.1093/ehjci/jex146.
8. Terasaki F, Azuma A, Anzai T, et al. JCS 2016 Guideline on Diagnosis and Treatment of Cardiac Sarcoidosis - Digest Version. *Circ J*. 2019;83(11):2329-2388. doi:10.1253/circj.CJ-19-0508.
9. Trivieri MG, Spagnolo P, Birnie D, et al. Challenges in Cardiac and Pulmonary Sarcoidosis: JACC State-of-the-Art Review. *J Am Coll Cardiol*. 2020;76(16):1878-1901. doi:10.1016/j.jacc.2020.08.042.
10. Ungprasert P, Carmona EM, Utz JP, et al. Epidemiology of Sarcoidosis 1946-2013: A Population-Based Study. *Mayo Clin Proc*. 2016;91(2):183-188. doi:10.1016/j.mayocp.2015.10.024.

Cardiac Trauma Imaging (CD-10.1)

CD.CS.0010.1.A

v2.1.2024

Guideline

Cardiac Trauma Imaging (CD-10.1)

References (CD-10)

Cardiac Trauma Imaging (CD-10.1)

- One of the following can be used to evaluate cardiac or aortic trauma:
 - Echocardiogram (TTE, TEE)
 - Cardiac MRI Cardiac (CPT® 75557 or CPT® 75561, and CPT® 75565)
 - Cardiac CT Cardiac (CPT® 75572)
 - CCTA (CPT® 75574)
 - Chest CTA Chest (CPT® 71275)
 - Chest CT Chest (CPT® 71260, CPT® 71270)

References (CD-10)

1. Conn A. Chest trauma. In: Trauma: A Comprehensive Emergency Medicine Approach. New York, NY: Cambridge University Press; 2011:190-212.
2. Stojanovska J, Hurwitz Koweek LM, Chung JH, et al. ACR Appropriateness Criteria® Blunt Chest Trauma-Suspected Cardiac Injury. Revised 2020. Am Coll Radiol (ACR). Available at <https://acsearch.acr.org/docs/3082590/Narrative/>.

Congestive Heart Failure (CD-9)

CD.CS.0009.A

v2.1.2024

Guideline

CHF – Imaging (CD-9.1)

Myocardial Sympathetic Innervation Imaging in Heart Failure (CD-3.6)

Left ventricular assist devices (LVAD) (CD-9.4)

References (CD-9)

CHF – Imaging (CD-9.1)

- Congestive heart failure (CHF), including post-cardiac transplant failure:
 - Echocardiogram is the first study after the clinical evaluation for suspected CHF.
 - MUGA, cardiac MRI or cardiac CT may be indicated if the ECHO is limited or does not completely answer the question.
 - Stress test to assess for CAD may be indicated. Follow stress testing guideline: **Stress Testing with Imaging – Indications (CD-1.4)**
- Arteriovenous fistula with “high output” heart failure:
 - CT Chest with contrast (CPT® 71260) and/or CT Abdomen and/or CT Pelvis with contrast (CPT® 74160 or CPT® 72193 or CPT® 74177) **OR**
 - CTA Chest (CPT® 71275) and/or CTA Abdomen and/or CTA Pelvis (CPT® 74175 or CPT® 72191 or CPT® 74174) **OR**
 - MRI Chest and/or MRI Abdomen and/or MRI Pelvis without and with contrast (CPT® 71552 and/or CPT® 74183 and/or CPT® 72197) **OR**
 - MRA Chest and/or MRA Abdomen and/or MRA Pelvis (CPT® 71555 and/or CPT® 74185 and/or CPT® 72198)
- Right-sided congestive heart failure can be a manifestation of pulmonary hypertension or serious lung disease.
 - CT Chest (CPT® 71260) or CTA Chest (CPT® 71275) to evaluate for recurrent pulmonary embolism

Myocardial Sympathetic Innervation Imaging in Heart Failure (CD-3.6)

- Nuclear imaging using I-123-meta-iodobenzylguanidine (I-123-mIBG) in an attempt to image increased myocardial sympathetic activity is considered to be experimental and investigational.
- The AMA has established the following set of Category III codes to report these studies:
 - **0331T** - Myocardial sympathetic innervation imaging, planar qualitative and quantitative assessment
 - **0332T** - Myocardial sympathetic innervation imaging, planar qualitative and quantitative assessment; with tomographic SPECT.

Background and supporting information

In heart failure, the sympathetic nervous system is activated in order to compensate for the decreased myocardial function. Initially, this is beneficial, however, long-term this compensatory mechanism is detrimental and causes further damage.

Markers have been developed, using radioactive iodine, in an attempt to image this increased myocardial sympathetic activity. Currently, AdreView™ (Iodine-123 meta-iodobenzylguanidine), is the only FDA-approved imaging agent available for this purpose.

Left ventricular assist devices (LVAD) (CD-9.4)

Left ventricular assist devices (LVAD) are implantable devices used in individuals with advanced heart failure refractory to medical therapy as a bridge to transplantation or as a destination therapy.

Pre-LVAD implant

The following imaging studies are indicated for preoperative evaluation prior to planned LVAD implant:

- TTE (CPT® 93306)
- 3D rendering for echocardiography (CPT® 76376 or CPT® 76377)
- Cardiac MRI (CPT® 75557 or CPT® 75561) and CMR velocity flow mapping (CPT® 75565)
- CT Chest (CPT® 71250 or CPT® 71260) or CTA Chest (CPT® 71275) or MRI Chest (CPT® 71552) or MRA Chest (CPT® 71555)
- CTA Abdomen and pelvis (CPT® 74174) or MRA abdomen and pelvis (CPT® 74185 and CPT® 72198)
- CT coronary angiography (CPT® 75574) in individuals post-coronary artery bypass grafting to assess the location and course of the bypass grafts to guide the surgical approach
- Transesophageal echocardiography (CPT® 93312, 93320, 93325)
- Right heart catheterization (CPT® 93451) or Right and left heart catheterization (CPT 93453)

Post LVAD implant

TTE (CPT® 93306) is indicated as follows:

- Post-implant at the following intervals:
 - 2 weeks
 - One month

- Three months
- Six months
- Twelve months
- Every 6 months thereafter

CT

- CTA Chest (CPT® 71275) or CT Chest with contrast (CPT® 71260) is indicated for evaluation of LVAD malfunction
- CT Chest without contrast (CPT® 71250) or CT Chest with contrast (CPT® 71260) indicated for the evaluation of LVAD-related infections

FDG PET/CT for LVAD driveline infection (CPT® 78815 or CPT®78429)

- Early infection detection for LVAD drivelines is desirable, since once the infection extends to the cannula and pump pocket, eradication becomes difficult. CT findings are nonspecific and metal device artifacts of the driveline itself affects sensitivity.
- FDG PET/CT can be approved for suspected LVAD infection if other studies and examination remain inconclusive.
- See **FDG PET/CT for Infections (CD-6.5)**

Right heart catheterization (RHC)

- RHC (CPT® 93451) or Right and Left heart catheterization (CPT® 93453) as needed for hemodynamic assessment to guide changes to therapy

References (CD-9)

1. Yancy CW, Jessup M, Bozkurt B, et al. 2013 ACCF/AHA Guideline for the Management of Heart Failure: Executive Summary: A Report of the American College of Cardiology Foundation/American Heart Association Task Force on Practice Guidelines. *Circulation*. 2013;128(16):1810-1852. doi:10.1161/cir.0b013e31829e8807.
2. Yancy CW, Jessup M, Bozkurt B, et al. 2016 ACC/AHA/HFSA Focused Update on New Pharmacological Therapy for Heart Failure: An Update of the 2013 ACCF/AHA Guideline for the Management of Heart Failure. *Journal of Cardiac Failure*. 2016;22(9):659-669. doi:10.1016/j.cardfail.2016.07.001.
3. Ponikowski P, Voors AA, Anker SD, et al. 2016 ESC Guidelines for the diagnosis and treatment of acute and chronic heart failure. *European Heart Journal*. 2016;37(27):2129-2200. doi:10.1093/eurheartj/ehw128.
4. Nakata T, Nakajima K, Yamashina S, et al. A Pooled Analysis of Multicenter Cohort Studies of 123I-mIBG Imaging of Sympathetic Innervation for Assessment of Long-Term Prognosis in Heart Failure. *JACC: Cardiovascular Imaging*. 2013;6(7):772-784. doi:10.1016/j.jcmg.2013.02.007.
5. Stainback RF, Estep JD, Agler DA, et al. Echocardiography in the Management of Patients with Left Ventricular Assist Devices: Recommendations from the American Society of Echocardiography. *Journal of the American Society of Echocardiography*. 2015;28(8):853-909. doi:10.1016/j.echo.2015.05.008.
6. Slaughter MS, Pagani FD, Rogers JG, et al. Clinical management of continuous-flow left ventricular assist devices in advanced heart failure. *The Journal of Heart and Lung Transplantation*. 2010;29(4). doi:10.1016/j.healun.2010.01.011.
7. Kirklin JK, Pagani FD, Goldstein DJ, et al. American Association for Thoracic Surgery/International Society for Heart and Lung Transplantation guidelines on selected topics in mechanical circulatory support. *J Thorac Cardiovasc Surg*. 2020;159(3):865-896. doi:10.1016/j.jtcvs.2019.12.021.
8. Saeed D, Feldman D, Banayosy AE, et al. The 2023 International Society for Heart and Lung Transplantation Guidelines for Mechanical Circulatory Support: A 10- Year Update. *J Heart Lung Transplant*. 2023;42(7):e1-e222. doi:10.1016/j.healun.2022.12.004.
9. Pergola V, Cameli M, Dandel M, Soliman-Aboumarie H. Editorial: Multimodality imaging of left ventricular assist devices: applications in advanced heart failure. *Front Cardiovasc Med*. 2023;10:1277563. Published 2023 Sep 28. doi:10.3389/fcvm.2023.1277563.

10. Masarone D, Houston B, Falco L, et al. How to Select Patients for Left Ventricular Assist Devices? A Guide for Clinical Practice. *J Clin Med.* 2023;12(16):5216. Published 2023 Aug 10. doi:10.3390/jcm12165216.

Pre-Surgical Cardiac Testing (CD-13)

CD.CS.0013.A

v2.1.2024

Guideline

- Pre-Surgical Cardiac Testing – General Information (CD-13.1)
- Primary Cardiac Surgery – No Previous Cardiac Surgery (CD-13.2)
- Re-operative cardiac surgery (CD-13.3)
- Minimally Invasive Valve Surgery (CD-13.4)
- Percutaneous Mitral Valve Repair (mitral valve clip) (CD-13.5)
- References (CD-13)

Pre-Surgical Cardiac Testing – General Information (CD-13.1)

- It is important to differentiate requests for preoperative CT imaging before cardiac surgery according to type of procedure planned:
 - Primary cardiac operation—individuals who have not had prior heart surgery
 - Redo procedures—individuals who have had a prior procedure (it is important to determine the type of procedure as this may impact which modality is most appropriate for the pre-operative assessment)
 - Minimally invasive procedures, such as minimally invasive aortic valve operations, minimally invasive or robotic mitral operations, TAVR, MitraClip™ or other percutaneous valve procedures (such as valve in valve aortic or mitral, percutaneous tricuspid and TMVR which will be increasing in the future)
- In re-operative cardiac surgery, the benefit of preoperative CT is to assess for aortic calcifications, to evaluate the anatomic relationships in the mediastinum, such as the location of the various cardiac chambers and great vessels and proximity to the sternum, and to assess for the location of prior bypass grafts. Information can then be used to change the operative strategy including non-midline approach, peripheral vascular exposure, and alternative cannulation sites and for establishing cardiopulmonary bypass before re-sternotomy. These techniques can result in decreased incidence of intraoperative injury to heart, great vessels and prior bypass grafts and lower rates of postoperative stroke. IV contrast is necessary with these studies to delineate the anatomic structures. However, in individuals with renal insufficiency, the provider might choose to forgo the contrast if does not want to contrast load the individual prior to placing them on the heart-lung machine.
- Aortic atherosclerosis is recognized as the single most important determinant of postoperative stroke. There is evidence to support that preoperative CT is associated with lower postoperative stroke rates and mortality after primary cardiac surgery.
 - CT Chest without contrast (CPT® 71250) can be performed pre-operatively to allow the surgeon to:
 - Visualize the extent and location of aortic atherosclerosis

- Change the operative strategy such as those problematic areas are avoided

Primary Cardiac Surgery – No Previous Cardiac Surgery (CD-13.2)

- CT Chest without contrast (CPT® 71250) to evaluate for the presence of ascending aortic calcification may be indicated prior to primary cardiac surgery when there is documented high-risk for aortic calcification including any of the following:
 - Aortic calcification on chest x-ray or other diagnostic test (TEE, fluoroscopy, etc.)
 - Calcific aortic stenosis
 - End stage renal disease (dialysis)

Re-operative cardiac surgery (CD-13.3)

- Individuals undergoing re-operative cardiac surgery may undergo **one** of the following tests for preoperative assessment:
 - CT Chest with contrast
 - CTA Chest
 - CCTA only if prior CABG (this might be in addition to CT with contrast as CCTA will not show the extent of the thoracic aorta that needs to be visualized)
 - CT Heart usually does not provide the necessary information, and is not indicated routinely.

Minimally Invasive Valve Surgery (CD-13.4)

- See **Transcatheter Aortic Valve Replacement (TAVR) (CD-4.8)**
- For an individual undergoing minimally invasive aortic valve surgery and minimally invasive or robotic mitral valve surgery, **ONE** of the following for preoperative assessment of an individual's suitability for the approach and for subsequent procedure planning:
 - CTA Chest, CTA Abdomen and Pelvis
 - CT Chest and CT Abdomen and Pelvis with contrast

Percutaneous Mitral Valve Repair (mitral valve clip) (CD-13.5)

- Percutaneous treatment of mitral regurgitation can be accomplished using venous access to apply a clip device (e.g., MitraClip™ currently FDA approved) to provide edge-to-edge mitral leaflet coaptation, approximating opposing sections of the anterior and posterior mitral valve leaflets. FDA approved indications include treatment for individuals with symptomatic, moderate to severe or severe primary mitral regurgitation whose surgical risks are prohibitive, as well as symptomatic moderate to severe or severe secondary mitral regurgitation who have failed optimal medical therapy. This therapy should include, if indicated, cardiac resynchronization therapy.
- The following imaging may be used to determine if an individual is eligible for the procedure:

- Transthoracic echo with or without 3D rendering
- Transesophageal echo with or without 3D rendering
- Heart catheterization, including right heart cath if requested
- Because this is a venous approach, CTA of Abdomen, Chest, and/or Pelvis **is not** indicated.
- Post-procedure transthoracic echo (TTE) can be performed at the following intervals:
 - One month
 - Six months
 - One year

References (CD-13)

1. Cantinotti M. The importance and ways of exploring the entire chest before and after cardiac surgery: Chest radiography, lung ultrasonography, and computed tomography. *The Journal of Thoracic and Cardiovascular Surgery*. 2018;155(5):2041-2042. doi:10.1016/j.jtcvs.2018.01.032.
2. Merlo A, Chen K, Deo S, Markowitz A. Does routine preoperative computed tomography imaging provide clinical utility in patients undergoing primary cardiac surgery? *Interactive CardioVascular and Thoracic Surgery*. 2017;25(4):659-662. doi:10.1093/icvts/ivx098.
3. Erthal F, Inacio JR, Hazra S, Chan V, Chow BJW. Cardiac Computed Tomography Before and After Cardiac Surgery. *J Thorac Imaging*. 2018 May;33(3):156-167. doi:10.1097/RTI.0000000000000295.
4. Moodley S, Schoenhagen P, Gillinov AM, et al. Preoperative multidetector computed tomography angiography for planning of minimally invasive robotic mitral valve surgery impact on decision making. *J Thorac Cardiovasc Surg*. 2013 Aug;146(2):262-8. doi:10.1016/j.jtcvs.2012.06.052.
5. den Harder AM, de Heer LM, Meijer RC, et al. Effect of computed tomography before cardiac surgery on surgical strategy, mortality and stroke. *Eur J Radiol*. 2016 Apr;85(4):744-50. doi:10.1016/j.ejrad.2016.01.003.
6. Dass C, Simpson SA, Steiner RM, Guy TS. Preprocedural Computed Tomography Evaluation for Minimally Invasive Mitral Valve Surgery. *Journal of Thoracic Imaging*. 2015;30(6):386-396. doi:10.1097/rti.0000000000000170.
7. Adler Y, Fisman EZ, Shemesh J, et al. Spiral computed tomography evidence of close correlation between coronary and thoracic aorta calcifications. *Atherosclerosis*. 2004 Sep;176(1):133-8. doi:10.1016/j.atherosclerosis.2004.03.027.
8. van der Linden J, Hadjinikolaou L, Bergman P, et al. Postoperative stroke in cardiac surgery is related to the location and extent of atherosclerotic disease in the ascending aorta. *J Am Coll Cardiol*. 2001 Jul;38(1):131-5. doi:10.1016/s0735-1097(01)01328-6.
9. Lapar DJ, Ailawadi G, Irvine JN Jr, et al. Preoperative computed tomography is associated with lower risk of perioperative stroke in reoperative cardiac surgery. *Interact Cardiovasc Thorac Surg*. 2011 Jun;12(6):919-23. doi:10.1510/icvts.2010.265165.
10. Nishi H, Mitsuno M, Tanaka H, Ryomoto M, Fukui S, Miyamoto Y. Who needs preoperative routine chest computed tomography for prevention of stroke in cardiac surgery? *Interact Cardiovasc Thorac Surg*. 2010 Jul;11(1):30-3. doi:10.1510/icvts.2009.231761.
11. Akhtar NJ, Markowitz AH, Gilkeson RC. Multidetector computed tomography in the preoperative assessment of cardiac surgery patients. *Radiol Clin North Am*. 2010 Jan;48(1):117-39. doi:10.1016/j.rcl.2009.09.002.
12. Khan NU, Yonan N. Does preoperative computed tomography reduce the risks associated with re-do cardiac surgery? *Interact Cardiovasc Thorac Surg*. 2009 Jul;9(1):119-23. doi:10.1510/icvts.2008.189506.
13. Bergman P, Linden JVD, Forsberg K, Öhman M. Preoperative Computed Tomography or Intraoperative Epiaortic Ultrasound for the Diagnosis of Atherosclerosis of the Ascending Aorta? *The Heart Surgery Forum*. 2004;7(3). doi:10.1532/hfsf98.20033009.
14. Lee R, Matsutani N, Polimenakos AC, et al. Preoperative noncontrast chest computed tomography identifies potential aortic emboli. *Ann Thorac Surg*. 2007 Jul;84(1):38-41; discussion 42.
15. Nishi H, Mitsuno M, Ryomoto M, Miyamoto Y. Comprehensive approach for clamping severely calcified ascending aorta using computed tomography. *Interactive CardioVascular and Thoracic Surgery*. 2010;10(1):18-20. doi:10.1510/icvts.2009.216242.

16. Aviram G, Sharony R, Kramer A, et al. Modification of Surgical Planning Based on Cardiac Multidetector Computed Tomography in Reoperative Heart Surgery. *The Annals of Thoracic Surgery*. 2005;79(2):589-595. doi:10.1016/j.athoracsur.2004.07.012.
17. Harder AMD, Heer LMD, Maurovich-Horvat P, et al. Ultra low-dose chest CT with iterative reconstructions as an alternative to conventional chest x-ray prior to heart surgery (CRICKET study): Rationale and design of a multicenter randomized trial. *Journal of Cardiovascular Computed Tomography*. 2016;10(3):242-245. doi:10.1016/j.jcct.2016.01.016.
18. O'gara PT, Grayburn PA, Badhwar V, et al. 2017 ACC Expert Consensus Decision Pathway on the Management of Mitral Regurgitation. *J Am Coll Cardiol*. 2017;70(19):2421-2449. doi:10.1016/j.jacc.2017.09.019.
19. Doherty JU, Kort S, Mehran R, Schoenhagen P, Soman P. ACC/AATS/AHA/ASE/ASNC/HRS/SCAI/SCCT/SCMR/STS 2017 appropriate use criteria for multimodality imaging in valvular heart disease: a report of the American College of Cardiology Appropriate Use Criteria Task Force, American Association for Thoracic Surgery, American Heart Association, American Society of Echocardiography, American Society of Nuclear Cardiology, Heart Rhythm Society, Society for Cardiovascular Angiography and Interventions, Society of Cardiovascular Computed Tomography, Society for Cardiovascular Magnetic Resonance, and Society of Thoracic Surgeons. *J Am Coll Cardiol* 2017;70:1647–72. doi:10.1007/s12350-017-1070-1.
20. Nishi H, Mitsuno M, Tanaka H, Ryomoto M, Fukui S, Miyamoto Y. Who needs preoperative routine chest computed tomography for prevention of stroke in cardiac surgery? *Interactive CardioVascular and Thoracic Surgery*. 2010;11(1):30-33. doi:10.1510/icvts.2009.231761.

Pulmonary Hypertension (PH) (CD-8.1)

CD.CS.0008.1.A

v2.1.2024

Guideline

Pulmonary Hypertension - Imaging indications

References

Pulmonary Hypertension - Imaging indications

Transthoracic echocardiogram (TTE) (CPT® 93306) should be performed initially as it can help determine the probability of pulmonary hypertension.

Screening

A screening echocardiogram (TTE) for PH is indicated in individuals with documented history of **any** of the following:

- Individuals preoperatively for planned liver transplant.
- Individuals evaluated for transjugular portosystemic shunt
- Portal Hypertension
- Liver disease with signs and symptoms of PH
- Bronchopulmonary dysplasia

Annual screening echo (TTE) is indicated in individuals with a documented history of any of the following:

- Systemic sclerosis (SSc)
- Individuals with PH mutations (e.g., BMPR2)
- First-degree relatives of individuals with PH
- Connective tissue disorder with symptoms consistent with PH
- Individuals with TR velocity ≥ 2.8 m/s, with no other findings on additional testing
- Individuals being treated with medications associated with PH
- Individuals who have a concern documented for PH and had a negative echocardiogram but still show signs or symptoms of PH

Follow-up testing is not indicated in individuals with TR velocity < 2.8 m/s and no other signs, symptoms, or risk factors of PH

Initial imaging

Transthoracic echocardiogram (TTE) (CPT® 93306) is indicated for symptoms and signs of pulmonary hypertension (PH) including **any** of the following:

- Notes documenting clinical concern for pulmonary hypertension

- EKG findings concerning for PH such as **any** of the following:
 - Right ventricular hypertrophy (RVH)
 - Right axis deviation
 - Right atrial enlargement
- Right ventricular hypertrophy or pulmonary artery dilation on other images
- History of pulmonary embolism with persistent or new onset DOE, or exercise limitation
- Suspected PH in individuals with lung disease
- DOE in individuals with connective tissue disorder, HIV, portal hypertension, SSc.
- Symptoms of PH (**any** of the following):
 - Breathlessness
 - SOB
 - Decreased exercise tolerance
 - Fatigue and rapid exhaustion
 - Palpitations
 - Dyspnea on bending forward
 - Hemoptysis
 - Exercise induced abdominal distention and nausea
 - Weight gain due to fluid retention
 - Syncope during or shortly after physical activity
 - Exertional chest pain

Stress Echo (CPT® 93350 or 93351) is indicated for **any** of the following:

- To assess for treatment in the setting of concomitant valvular disease
- As indicated by **Stress Testing with Imaging - Indications (CD-1.4)** or **Stress Echo-Indications Other than Ruling out CAD (CD-2.7)**
- There is documented concern for chronic thrombo-embolic pulmonary hypertension

Cardiac MRI (CPT® 75557) is indicated when there is documentation of **any** of the following:

- TTE is equivocal or unclear (e.g., for RV function) and the information is needed for management
- MRI and TTE may both be required for individuals who need RV pressure and function assessed, and prior RV function cannot be assessed by echocardiogram
- MRI can replace TTE when the issue that makes the imaging by echo unclear is likely to be seen in future echocardiograms

Other advanced imaging is indicated after TTE for the following:

- High-resolution CT Chest (CPT® 71250) is indicated in the setting of hypoxemia to rule out restrictive lung disorders such as pulmonary fibrosis

- CTA Chest (CPT® 71275) or MRA Chest (CPT® 71555) is indicated to evaluate for suspected acute and/or chronic pulmonary embolism
- V/Q scan (CPT® 78580-Pulmonary Perfusion Imaging or CPT® 78582- Pulmonary Ventilation (e.g., Aerosol or Gas) and Perfusion Imaging) is indicated to evaluate for any of the following:
 - Suspected acute pulmonary embolism
 - To evaluate for chronic thromboembolic pulmonary hypertension at 3 to 6 months post pulmonary embolism if both of the following apply:
 - Persistent or new onset dyspnea on exertion or exercise limitation
 - Evidence of pulmonary hypertension on follow up echo
 - To evaluate for chronic thromboembolic pulmonary hypertension in individuals with pulmonary hypertension of uncertain etiology
- SPECT imaging (CPT® 78803) or SPECT/CT imaging (CPT® 78830) can be added to V/Q scan if requested
- Transesophageal (TEE) contrast echocardiography or other imaging techniques (e.g.,CT angiography, cardiac MRI) may be indicated, in addition to 2D Doppler and contrast examinations, to identify CHD to detect or exclude **any** of the following:
 - Sinus venosus
 - Atrial septal defects
 - Patent ductus arteriosus
 - Anomalous pulmonary venous connections

Indications for initial Catheterization

Right heart catheterization (RHC) is indicated for **any** of the following:

- Echo findings
 - TR velocity ≥ 3.4 m/second
 - TR velocity ≥ 2.9 m/second and presence of other PH signs on echo or other testing, or risk factors or associated indications
- Individuals with SSc where breathlessness remains unexplained (RHC is recommended despite normal echocardiogram).
- Individuals with connective tissue disorder who have symptoms or concerns for PH with a negative or equivocal echocardiogram.
- When recommended to determine if shunt closure is recommended due to congenital heart disease
- RHC if **moderate** to **severe** PH on echocardiogram (See **Background and Supporting Information** for definitions of mild, moderate and severe PH)
- RHC is indicated prior to starting PH medical therapy.
- Individuals with **low**-risk profile (based on an evidence based PAH Risk Score Calculator such as REVEAL 2.0, ESC/ERS & Compera 2.0) only need cath if indicated for another reason or equivocal studies.(See **Background and Supporting Information** for additional information about PH risk profile)

- RHC allowed when LHC indicated for separate indication.
- RHC preoperative for surgical intervention treating the cause of PH (MV, TV, AV, PV).
- Eisenmenger syndrome – RHC is indicated when requested by provider.

Left heart catheterization (LHC) or Right and left heart catheterization as per the following guidelines:

- **Evaluation of Conditions Other than Coronary Artery Disease (CD-7.7)**
- **Diagnostic Left Heart Catheterization (LHC) (CD-7.3)**

Repeat Testing

Follow-up echocardiogram (TTE) on patients with PH

- Every 6 months for surveillance of stable individuals with moderate or severe pulmonary hypertension (pulmonary artery systolic pressure ≥ 50 mm Hg)
- Prior to planned intubation (e.g., for elective surgery)
- Prior to planned pregnancy
- During pregnancy as often as requested by provider
- Anytime, without regard for the number or timing of previous ECHO studies to evaluate either:
 - Change in therapy
 - Change in clinical findings or symptoms
- Echocardiogram at baseline then every 3 months with therapy changes in stable patients

Pulmonary embolism (PE)

- TTE is indicated 3 to 6 months post pulmonary embolism if **any** of the following apply:
 - Persistent or new onset dyspnea on exertion, or exercise limitation
 - Pulmonary hypertension or right ventricular dysfunction on initial echo at PE diagnosis
 - History of recurrent pulmonary embolism

RHC is indicated for known PH as follows:

- At baseline
- Then every 6 months
- Anytime for clinical changes or with treatment changes

Other related sections

- **Frequency of Echocardiography Testing (CD-2.3)** in the Cardiac Imaging Guidelines

- **Right Heart Catheterization (RHC) (CD-7.4)** in the Cardiac Imaging Guidelines
- **Pulmonary hypertension (PHT) and Eisenmenger syndrome (CD-11.3.12)** in the Cardiac Imaging Guidelines
- **Congenital Heart Disease Modality Considerations (PEDCD-2.3)** in the Pediatric Cardiac Imaging Guidelines
- **Pediatric Pulmonary Hypertension - General (PEDCD-7)** in the Pediatric Cardiac Imaging Guidelines
- **Pulmonary Embolism (PE) (CH-25)** in the Chest Imaging Guidelines

Background and supporting information

Pulmonary hypertension (PH) is a complex, chronic disease with multiple etiologies, that requires extensive evaluation, including ECG (right ventricular hypertrophy with/without strain, right atrial dilatation); chest x-ray; arterial blood gas, pulmonary function testing, CT angiography based on the etiology.

PH can be subdivided into the following five groups based on the underlying cause:

- Pulmonary arterial hypertension (PAH)
- PH due to left heart disease
- PH due to lung disease
- Chronic thromboembolic PH (CTEPH)
- PH with unclear and/or multifactorial mechanisms

Probability of PH is assessed at initial evaluation:

- **High** probability:
 - TR velocity ≥ 3.4 m/s
 - TR velocity between 2.9 to 3.4 m/s and **one** of the following:
 - Right ventricle or pulmonary artery enlargement
 - Interventricular septum flattening
 - Right ventricular systolic dysfunction
- **Intermediate** probability:
 - TR velocity between 2.9 to 3.4 m/s in the absence of other signs of PH
- **Low** probability:
 - TR velocity < 2.8 m/s

Peak TR velocity ≥ 2.8 m/s may suggest PH; however, the presence or absence of PH cannot be reliably determined by TR velocity alone

In addition to the tricuspid regurgitation velocity, other findings on echo can increase the probability of PH, examples of these findings include:

- Abnormal tricuspid annular plane systolic excursion (TAPSE)
- Abnormal RV fractional area change (RV-FAC)

- Abnormal RV free-wall strain
- Abnormal tricuspid annulus velocity (S' wave) derived from tissue Doppler imaging
- Abnormal RV ejection fraction (RVEF) derived from 3D echocardiography

MRI can be a useful test especially with respect to RV function

Right heart cath is the gold standard for diagnosing PH

See **Severe Pulmonary Artery Hypertension (PH) and Eisenmenger Syndrome (CD-11.3.12)** for additional information regarding Eisenmenger Syndrome

References

1. Abman SH, Hansmann G, Archer SL, et al. Pediatric Pulmonary Hypertension: Guidelines From the American Heart Association and American Thoracic Society [published correction appears in *Circulation*. 2016 Jan 26;133(4):e368]. *Circulation*. 2015;132(21):2037-2099. doi:10.1161/CIR.0000000000000329.
2. Alabed S, Shahin Y, Garg P, et al. Cardiac-MRI Predicts Clinical Worsening and Mortality in Pulmonary Arterial Hypertension: A Systematic Review and Meta-Analysis [published correction appears in *JACC Cardiovasc Imaging*. 2021 Apr;14(4):884]. *JACC Cardiovasc Imaging*. 2021;14(5):931-942. doi:10.1016/j.jcmg.2020.08.013.
3. Alabed S, Uthoff J, Zhou S, et al. Machine learning cardiac-MRI features predict mortality in newly diagnosed pulmonary arterial hypertension. *European Heart Journal - Digital Health*. 2022;3(2):265-275. doi:10.1093/ehjdh/ztac022.
4. Bossone E, Dellegrottaglie S, Patel S, et al. Multimodality imaging in pulmonary hypertension. *Can J Cardiol*. 2015;31(4):440-459. doi:10.1016/j.cjca.2015.02.012.
5. Broncano J, Bhalla S, Gutierrez FR, et al. Cardiac MRI in Pulmonary Hypertension: From Magnet to Bedside. *Radiographics*. 2020;40(4):982-1002. doi:10.1148/rg.2020190179.
6. Dong Y, Pan Z, Wang D, et al. Prognostic Value of Cardiac Magnetic Resonance-Derived Right Ventricular Remodeling Parameters in Pulmonary Hypertension: A Systematic Review and Meta-Analysis. *Circ Cardiovasc Imaging*. 2020;13(7):e010568. doi:10.1161/CIRCIMAGING.120.010568.
7. Expert Panel on Thoracic Imaging, Sirajuddin A, Mirmomen SM, et al. ACR Appropriateness Criteria® Suspected Pulmonary Hypertension: 2022 Update. *J Am Coll Radiol*. 2022;19(11S):S502-S512. doi:10.1016/j.jacr.2022.09.018.
8. Goh ZM, Balasubramanian N, Alabed S, et al. Right ventricular remodelling in pulmonary arterial hypertension predicts treatment response. *Heart*. 2022;108(17):1392-1400. Published 2022 Aug 11. doi:10.1136/heartjnl-2021-320733.
9. Hulten EA, Bradley AJ. Cardiac Magnetic Resonance Evaluation of Pulmonary Arterial Hypertension: Transforming From Supplementary to Primary Imaging Modality? *JACC Cardiovasc Imaging*. 2021;14(5):943-946. doi:10.1016/j.jcmg.2020.11.022.
10. Humbert M, Kovacs G, Hoeper MM, et al. 2022 ESC/ERS Guidelines for the diagnosis and treatment of pulmonary hypertension. *Eur Heart J*. 2022;43(38):3618-3731. doi:10.1093/eurheartj/ehac237.
11. Kaemmerer H, Apitz C, Brockmeier K, et al. Pulmonary hypertension in adults with congenital heart disease: Updated recommendations from the Cologne Consensus Conference 2018. *Int J Cardiol*. 2018;272S:79-88. doi:10.1016/j.ijcard.2018.08.078.
12. Lewis MJ, Van Dissel A, Kochav J, et al. Cardiac MRI predictors of adverse outcomes in adults with a systemic right ventricle. *ESC Heart Fail*. 2022;9(2):834-841. doi:10.1002/ehf2.13745.
13. Mazurek A, Dziuk M, Witkowska-Patena E, Piszczek S, Gizewska A. The Utility of Hybrid SPECT/CT Lung Perfusion Scintigraphy in Pulmonary Embolism Diagnosis. *Respiration*. 2015;90(5):393-401. doi:10.1159/000439543.
14. McLaughlin VV, Archer SL, Badesch DB, et al. ACCF/AHA 2009 expert consensus document on pulmonary hypertension a report of the American College of Cardiology Foundation Task Force on Expert Consensus Documents and the American Heart Association developed in collaboration with the American College of Chest Physicians; American Thoracic Society, Inc.; and the Pulmonary Hypertension Association. *J Am Coll Cardiol*. 2009;53(17):1573-1619. doi:10.1016/j.jacc.2009.01.004.
15. Moledina S, Pandya B, Bartsota M, et al. Prognostic significance of cardiac magnetic resonance imaging in children with pulmonary hypertension. *Circ Cardiovasc Imaging*. 2013;6(3):407-414. doi:10.1161/CIRCIMAGING.112.000082.
16. Osterfeld E, Kjellström B. The Conundrum of Right Ventricular Remodeling and Outcome in Pulmonary Hypertension. *Circ Cardiovasc Imaging*. 2020;13(7):e011208. doi:10.1161/CIRCIMAGING.120.011208.

17. Reddy YNV, Carter RE, Obokata M, Redfield MM, Borlaug BA. A Simple, Evidence-Based Approach to Help Guide Diagnosis of Heart Failure with Preserved Ejection Fraction. *Circulation*. 2018;138(9):861-870. doi:10.1161/CIRCULATIONAHA.118.034646.
18. Remy-Jardin M, Ryerson CJ, Schiebler ML, et al. Imaging of Pulmonary Hypertension in Adults: A Position Paper from the Fleischner Society. *Radiology*. 2021;298(3):531-549. doi:10.1148/radiol.2020203108.
19. Runser LA, Gauer R, Houser A. Syncope: Evaluation and Differential Diagnosis. *AAFP Home*. <https://www.aafp.org/afp/2017/0301/p303.html>. Published March 1, 2017.
20. Sato T, Ambale-Venkatesh B, Zimmerman SL, et al. Right ventricular function as assessed by cardiac magnetic resonance imaging-derived strain parameters compared to high-fidelity micromanometer catheter measurements. *Pulm Circ*. 2021;11(4):20458940211032529. Published 2021 Sep 24. doi:10.1177/20458940211032529.
21. Thenappan T, Ormiston ML, Ryan JJ, Archer SL. Pulmonary arterial hypertension: pathogenesis and clinical management. *BMJ*. 2018;360:j5492. Published 2018 Mar 14. doi:10.1136/bmj.j5492.
22. van der Bruggen CE, Handoko ML, Bogaard HJ, et al. The Value of Hemodynamic Measurements or Cardiac MRI in the Follow-up of Patients with Idiopathic Pulmonary Arterial Hypertension. *Chest*. 2021;159(4):1575-1585. doi:10.1016/j.chest.2020.10.077.
23. van Wolferen SA, Marcus JT, Boonstra A, et al. Prognostic value of right ventricular mass, volume, and function in idiopathic pulmonary arterial hypertension. *Eur Heart J*. 2007;28(10):1250-1257. doi:10.1093/eurheartj/ehl477.
24. Xue L, Yang Y, Sun B, Liu B, Zeng Q, Xiong C. Mildly Elevated Pulmonary Arterial Pressure Is Associated with a High Risk of Progression to Pulmonary Hypertension and Increased Mortality: A Systematic Review and Meta-Analysis. *J Am Heart Assoc*. 2021;10(7):e018374.
25. Yaghi S, Novikov A, Trandafirescu T. Clinical update on pulmonary hypertension. *J Investig Med*. 2020;68(4):821-827. doi:10.1136/jim-2020-001291.
26. Chemla D, Castelain V, Hervé P, Lecarpentier Y, Brimiouille S. Haemodynamic evaluation of pulmonary hypertension. *Eur Respir J*. 2002;20(5):1314-1331. doi:10.1183/09031936.02.00068002.
27. Boucly A, Weatherald J, Salvale L, et al. External validation of a refined four-stratum risk assessment score from the French pulmonary hypertension registry. *Eur Respir J* 2022; 59:2102419 [DOI: 10.1183/13993003.02419-2021].

Pulmonary Vein Imaging – Indications (CD-8.2)

CD.CS.0008.2.A

v2.1.2024

Guideline

Indications

References

Indications

- MRI Cardiac (CPT® 75557 or CPT® 75561), MRV Chest (CPT® 71555), CTV Chest (CPT® 71275), or CT Cardiac (CPT® 75572) to evaluate anatomy of the pulmonary veins:
 - Prior to planned atrial fibrillation ablation/pulmonary vein isolation procedure
 - Post-procedure between 3-6 months after ablation because of a 1% to 2% incidence of asymptomatic pulmonary vein stenosis
 - If no pulmonary vein stenosis is present, no further follow-up imaging is required
 - If pulmonary vein stenosis is present on imaging following ablation and symptoms of pulmonary vein stenosis (usually shortness of breath) are present, can be imaged at 1, 3, 6, and 12 months

Background and Supporting Information

The majority (81%) of pulmonary vein stenosis remain stable over 1 year. Progression occurs in 8.8% and regression occurs in a small percentage.

References

1. Abman SH, Hansmann G, Archer SL, et al. Pediatric Pulmonary Hypertension: Guidelines From the American Heart Association and American Thoracic Society [published correction appears in *Circulation*. 2016 Jan 26;133(4):e368]. *Circulation*. 2015;132(21):2037-2099. doi:10.1161/CIR.0000000000000329.
2. Alabed S, Shahin Y, Garg P, et al. Cardiac-MRI Predicts Clinical Worsening and Mortality in Pulmonary Arterial Hypertension: A Systematic Review and Meta-Analysis [published correction appears in *JACC Cardiovasc Imaging*. 2021 Apr;14(4):884]. *JACC Cardiovasc Imaging*. 2021;14(5):931-942. doi:10.1016/j.jcmg.2020.08.013.
3. Alabed S, Uthoff J, Zhou S, et al. Machine learning cardiac-MRI features predict mortality in newly diagnosed pulmonary arterial hypertension. *European Heart Journal - Digital Health*. 2022;3(2):265-275. doi:10.1093/ehjdh/ztac022.
4. Bossone E, Dellegrottaglie S, Patel S, et al. Multimodality imaging in pulmonary hypertension. *Can J Cardiol*. 2015;31(4):440-459. doi:10.1016/j.cjca.2015.02.012.
5. Broncano J, Bhalla S, Gutierrez FR, et al. Cardiac MRI in Pulmonary Hypertension: From Magnet to Bedside. *Radiographics*. 2020;40(4):982-1002. doi:10.1148/rg.2020190179.
6. Dong Y, Pan Z, Wang D, et al. Prognostic Value of Cardiac Magnetic Resonance-Derived Right Ventricular Remodeling Parameters in Pulmonary Hypertension: A Systematic Review and Meta-Analysis. *Circ Cardiovasc Imaging*. 2020;13(7):e010568. doi:10.1161/CIRCIMAGING.120.010568.
7. Expert Panel on Thoracic Imaging, Sirajuddin A, Mirmomen SM, et al. ACR Appropriateness Criteria® Suspected Pulmonary Hypertension: 2022 Update. *J Am Coll Radiol*. 2022;19(11S):S502-S512. doi:10.1016/j.jacr.2022.09.018.

8. Goh ZM, Balasubramanian N, Alabed S, et al. Right ventricular remodelling in pulmonary arterial hypertension predicts treatment response. *Heart*. 2022;108(17):1392-1400. Published 2022 Aug 11. doi:10.1136/heartjnl-2021-320733.
9. Hulten EA, Bradley AJ. Cardiac Magnetic Resonance Evaluation of Pulmonary Arterial Hypertension: Transforming From Supplementary to Primary Imaging Modality? *JACC Cardiovasc Imaging*. 2021;14(5):943-946. doi:10.1016/j.jcmg.2020.11.022.
10. Humbert M, Kovacs G, Hoeper MM, et al. 2022 ESC/ERS Guidelines for the diagnosis and treatment of pulmonary hypertension. *Eur Heart J*. 2022;43(38):3618-3731. doi:10.1093/eurheartj/ehac237.
11. Kaemmerer H, Apitz C, Brockmeier K, et al. Pulmonary hypertension in adults with congenital heart disease: Updated recommendations from the Cologne Consensus Conference 2018. *Int J Cardiol*. 2018;272S:79-88. doi:10.1016/j.ijcard.2018.08.078.
12. Lewis MJ, Van Dissel A, Kochav J, et al. Cardiac MRI predictors of adverse outcomes in adults with a systemic right ventricle. *ESC Heart Fail*. 2022;9(2):834-841. doi:10.1002/ehf2.13745.
13. Mazurek A, Dziuk M, Witkowska-Patena E, Piszczek S, Gizewska A. The Utility of Hybrid SPECT/CT Lung Perfusion Scintigraphy in Pulmonary Embolism Diagnosis. *Respiration*. 2015;90(5):393-401. doi:10.1159/000439543.
14. McLaughlin VV, Archer SL, Badesch DB, et al. ACCF/AHA 2009 expert consensus document on pulmonary hypertension a report of the American College of Cardiology Foundation Task Force on Expert Consensus Documents and the American Heart Association developed in collaboration with the American College of Chest Physicians; American Thoracic Society, Inc.; and the Pulmonary Hypertension Association. *J Am Coll Cardiol*. 2009;53(17):1573-1619. doi:10.1016/j.jacc.2009.01.004.
15. Moledina S, Pandya B, Bartsota M, et al. Prognostic significance of cardiac magnetic resonance imaging in children with pulmonary hypertension. *Circ Cardiovasc Imaging*. 2013;6(3):407-414. doi:10.1161/CIRCIMAGING.112.000082.
16. Ostenfeld E, Kjellström B. The Conundrum of Right Ventricular Remodeling and Outcome in Pulmonary Hypertension. *Circ Cardiovasc Imaging*. 2020;13(7):e011208. doi:10.1161/CIRCIMAGING.120.011208.
17. Reddy YNV, Carter RE, Obokata M, Redfield MM, Borlaug BA. A Simple, Evidence-Based Approach to Help Guide Diagnosis of Heart Failure with Preserved Ejection Fraction. *Circulation*. 2018;138(9):861-870. doi:10.1161/CIRCULATIONAHA.118.034646.
18. Remy-Jardin M, Ryerson CJ, Schiebler ML, et al. Imaging of Pulmonary Hypertension in Adults: A Position Paper from the Fleischner Society. *Radiology*. 2021;298(3):531-549. doi:10.1148/radiol.2020203108.
19. Runser LA, Gauer R, Houser A. Syncope: Evaluation and Differential Diagnosis. *AAFP Home*. <https://www.aafp.org/afp/2017/0301/p303.html>. Published March 1, 2017.
20. Sato T, Ambale-Venkatesh B, Zimmerman SL, et al. Right ventricular function as assessed by cardiac magnetic resonance imaging-derived strain parameters compared to high-fidelity micromanometer catheter measurements. *Pulm Circ*. 2021;11(4):20458940211032529. Published 2021 Sep 24. doi:10.1177/20458940211032529.
21. Thenappan T, Ormiston ML, Ryan JJ, Archer SL. Pulmonary arterial hypertension: pathogenesis and clinical management. *BMJ*. 2018;360:j5492. Published 2018 Mar 14. doi:10.1136/bmj.j5492.
22. van der Bruggen CE, Handoko ML, Bogaard HJ, et al. The Value of Hemodynamic Measurements or Cardiac MRI in the Follow-up of Patients with Idiopathic Pulmonary Arterial Hypertension. *Chest*. 2021;159(4):1575-1585. doi:10.1016/j.chest.2020.10.077.
23. van Wolferen SA, Marcus JT, Boonstra A, et al. Prognostic value of right ventricular mass, volume, and function in idiopathic pulmonary arterial hypertension. *Eur Heart J*. 2007;28(10):1250-1257. doi:10.1093/eurheartj/ehl477.
24. Xue L, Yang Y, Sun B, Liu B, Zeng Q, Xiong C. Mildly Elevated Pulmonary Arterial Pressure Is Associated with a High Risk of Progression to Pulmonary Hypertension and Increased Mortality: A Systematic Review and Meta-Analysis. *J Am Heart Assoc*. 2021;10(7):e018374.
25. Yaghi S, Novikov A, Trandafirescu T. Clinical update on pulmonary hypertension. *J Investig Med*. 2020;68(4):821-827. doi:10.1136/jim-2020-001291.
26. Chemla D, Castelain V, Hervé P, Lecarpentier Y, Brimiouille S. Haemodynamic evaluation of pulmonary hypertension. *Eur Respir J*. 2002;20(5):1314-1331. doi:10.1183/09031936.02.00068002.
27. Boucly A, Weatherald J, Salvale L, et al. External validation of a refined four-stratum risk assessment score from the French pulmonary hypertension registry. *Eur Respir J* 2022; 59:2102419 [DOI: 10.1183/13993003.02419-2021].

Hypertrophic Cardiomyopathy (HCM) (CD-14)

CD.CS.0014.A

v2.1.2024

Hypertrophic Cardiomyopathy (HCM) is a clinical diagnosis, established by imaging with 2D echocardiography or cardiovascular magnetic resonance (CMR) showing a maximal end-diastolic wall thickness of ≥ 15 mm anywhere in the left ventricle, in the absence of another cause of hypertrophy in adults. More limited hypertrophy (13–14 mm) can be diagnostic, particularly when present in family members of a patient with HCM or in conjunction with a positive genetic test, and/or associated with typical dynamic outflow obstruction, or distinctly abnormal ECG patterns.

Screening

- Screening for inherited hypertrophic cardiomyopathy see **Transthoracic Echocardiography (TTE) – Indications (CD-2.2)** and **Frequency of Echocardiography Testing (CD-2.3)**

Initial imaging, new or changed symptoms

TTE

- TTE is indicated for the initial evaluation of a genotype positive individual with inherited hypertrophic cardiomyopathy

Stress echocardiogram

- Exercise stress echo (CPT® 93351 or 93350) is indicated for the detection and quantification of dynamic left ventricular outflow tract obstruction in symptomatic individuals with HCM who do **not** have a resting or provokable outflow tract gradient ≥ 50 mm Hg on TTE.
- Stress echo can be repeated when there is documentation of **any** of the following:
 - In 1 to 2 years if the resting or provokable outflow tract gradient is < 30 mm Hg on prior stress echo
 - Worsening symptoms
 - There has been a therapeutic change (i.e., change in medication, surgical procedure performed).

CCTA (CPT® 75574)

- Initial imaging study in individuals with hypertrophic cardiomyopathy and stable anginal symptoms.
 - Chest discomfort is common in individuals with hypertrophic cardiomyopathy. The incidence of false positive myocardial perfusion imaging abnormalities is

higher in these individuals, whereas the incidence of severe coronary artery stenosis is low.

Cardiac MRI (CMR)

- Cardiac MRI (CPT® 75557 or CPT® 75561) for assessment of global ventricular function, myocardial composition and mass if a specific clinical question is left unanswered by a recent echocardiogram and results will affect patient management.

Surveillance imaging

- TTE is indicated every year when there is no change in clinical status or treatment

Monitoring treatment

Repeat TTE (CPT® 93306) is indicated in individuals with Obstructive Hypertrophic Cardiomyopathy (HCM) for the following:

Mavacamten for obstructive hypertrophic cardiomyopathy

Initiation of treatment

- Baseline-at the beginning of treatment
- 4 weeks after treatment initiation
- 8 weeks after treatment initiation
- 12 weeks after treatment initiation
- Then every 12 weeks while on mavacamten

Changes in treatment

- 4 weeks after any interruption of treatment (any missed dose)
- After any dosage change (including restart of treatment):
 - 4 weeks after dosage change
 - 12 weeks after dosage change
- After initiating a weak CYP2C19 inhibitor (e.g., omeprazole) or moderate CYP3A4 inhibitor (e.g., ciprofloxacin):
 - 4 weeks after start of medication
 - 12 weeks after start of medication
- At any time regardless of timing of prior echo when there are new cardiac signs or symptoms, or worsening of clinical status

Post- Septal Reduction Therapy (SRT)

TTE is indicated within 3 to 6 months after SRT (surgical myectomy or alcohol septal ablation) to evaluate the procedural results in individuals with hypertrophic cardiomyopathy

References

1. Arbelo E, Protonotarios A, Gimeno JR, et al. 2023 ESC Guidelines for the management of cardiomyopathies. *Eur Heart J*. 2023;44(37):3503-3626. doi:10.1093/eurheartj/ehad194.
2. Ommen, Steve R et al. 2020 AHA/ACC Guideline for the Diagnosis and Treatment of Patients With Hypertrophic Cardiomyopathy: Executive Summary: A Report of the American College of Cardiology/American Heart Association Joint Committee on Clinical Practice Guidelines. *Circulation*. 2020 Dec 22;142(25):e533-e557.
3. Nagueh SF, Phelan D, et al. Recommendations for Multimodality Cardiovascular Imaging of Patients with Hypertrophic Cardiomyopathy: An Update from the American Society of Echocardiography, in Collaboration with the American Society of Nuclear Cardiology, the Society for Cardiovascular Magnetic Resonance, and the Society of Cardiovascular Computed Tomography. *J Am Soc Echocardiogr*. 2022 Jun;35(6):533-569.

Table of Contents

Guideline

General Information

Abbreviations

Glossary

Preface to the Cardiac Implantable Device (CID) guideline

General information (CRID-1)

Pacemaker Devices

Indications for Permanent Pacemaker Implantation (CRID-7)

Permanent Pacemaker Implantation - Non-indications (CRID-9)

Leadless pacemaker (CRID-11.1)

Implantable cardioverter-defibrillator (ICD) Devices

Definite indications for ICD implantation (CRID-2)

Reasonable indications for ICD implantation (CRID-3)

ICD implantation non-indications (CRID-4)

Cardiac Resynchronization Therapy (CRT) Devices

Indications for cardiac resynchronization therapy (CRT)-D implantation (CRID-5)

Cardiac resynchronization therapy (CRT)-D implantation - non-indications (CRID-6)

Cardiac resynchronization therapy (CRT)-P (CRID-10)

Wireless Cardiac Resynchronization (CRID-11.2)

Other Cardiac Implantable Devices

Wireless Pulmonary Artery Pressure Sensor (CRID-11.3)

References

References

General Information

Guideline

Abbreviations

Glossary

Preface to the Cardiac Implantable Device (CID) guideline

General information (CRID-1)

Abbreviations

v1.0.2024

- **ACE inhibitor** — Angiotensin-converting enzyme inhibitor
- **AMI** — Acute myocardial infarction
- **ARVC** — Arrhythmogenic right ventricular cardiomyopathy
- **AV** — Atrioventricular
- **CC** — Complications/comorbid conditions
- **CHF** — Congestive heart failure
- **CM** — Cardiomyopathy
- **CRT** — Cardiac resynchronization therapy
- **EP** — Electrophysiology
- **GDMT** — Guideline-directed medical therapy
- **HCM** — Hypertrophic cardiomyopathy
- **ICD** — Implantable cardioverter defibrillator
- **LBBB** — Left bundle branch block
- **LV** — Left ventricle
- **LVEF** — Left ventricular ejection fraction
- **MCC** — Major complications/comorbid conditions
- **MI** — Myocardial infarction
- **NCCM** — Non-compaction cardiomyopathy
- **NYHA** — New York Heart Association functional classification
- **RBBB** — Right bundle branch block
- **RV** — Right ventricle
- **TAVR** — Transcatheter aortic valve replacement
- **VF** — Ventricular fibrillation
- **VT** — Ventricular tachycardia

Glossary

v1.0.2024

- **NYHA Heart Failure Definitions** — **class I** - No symptoms and no limitation in ordinary physical activity, e.g. shortness of breath when walking, climbing stairs etc. **class II** - Mild symptoms (mild shortness of breath and/or angina) and slight limitation during ordinary activity.
class III - Marked limitation in activity due to symptoms, even during less-than-ordinary activity, e.g. walking short distances (20–100 m). Comfortable only at rest.
class IV - Severe limitations. Experiences symptoms even while at rest. Mostly bedbound patients
- **Abnormal blood pressure response to exercise** — Flat response/failure to augment; rise then fall during exercise; vasoactive cardiovascular drugs may result in an abnormal blood pressure response to exercise
- **Ambulatory class IV CHF** — Class IV heart failure with: 1) no active acute coronary syndrome; 2) no inotropes; and 3) on GDMT
- **Incessant VT:** — Frequent recurrences of ongoing hemodynamically stable VT
- **Hypertrophic cardiomyopathy** — Hypertrophic Cardiomyopathy (HCM) is a clinical diagnosis, established by imaging with 2D echocardiography or cardiovascular magnetic resonance (CMR) showing a maximal end-diastolic wall thickness of ≥ 15 mm anywhere in the left ventricle, in the absence of another cause of hypertrophy in adults. More limited hypertrophy (13–14 mm) can be diagnostic, particularly when present in family members of a patient with HCM or in conjunction with a positive genetic test, and/or associated with typical dynamic outflow obstruction, or distinctly abnormal ECG patterns.
- **Long QT Syndrome (LQTS):** — A congenital disorder characterized by a prolongation of the QT interval on ECG and a propensity to ventricular tachyarrhythmias, which may lead to syncope, cardiac arrest, or sudden death. The QT interval on the ECG, measured from the beginning of the QRS complex to the end of the T wave, represents the duration of activation and recovery of the ventricular myocardium. QT intervals corrected for heart rate (QTc) longer than 0.44 seconds are generally considered abnormal, though a normal QTc can be more prolonged in females (up to 0.46 sec). The Bazett formula is the formula most commonly used to calculate the QTc, as follows: $QTc = QT / \sqrt{RR}$ (in seconds).
- **Non-Compaction Cardiomyopathy:** — A rare congenital cardiomyopathy that affects children and adults. It results from the failure of myocardial development during embryogenesis. It is also called spongiform cardiomyopathy. Symptoms are often a result of a poor pumping performance by the heart. The disease can be associated with other problems with the heart and the body.

- **Non-Sustained Ventricular Tachycardia (NSVT):** — Three or more consecutive ventricular beats at a rate of greater than 120 beats/min with a duration of less than 30 seconds
- **Optimal Medical Therapy:** — Optimal medical therapy for heart failure should include a beta-blocker and one of the following:
 - ACE inhibitor
 - angiotensin II receptor blocker
 - angiotensin receptor-neprilysin inhibitor
- **Structural Heart Disease:** — A structural or functional abnormality of the heart, or of the blood vessels supplying the heart, that impairs its normal functioning.

Preface to the Cardiac Implantable Device (CID) guideline

CID.AD.100.A

v1.0.2024

Guideline

Guideline development (Preface-1)

Benefits, coverage policies, and eligibility issues (Preface-2)

Clinical information (Preface-3)

References (Preface-4)

Copyright information (Preface-5)

Trademarks (Preface-6)

Guideline development (Preface-1)

- The eviCore evidence-based, proprietary clinical guidelines evaluate a range of advanced imaging and procedures, including CT, MRI, PET, and Radiation Oncology, Sleep Studies, and Cardiac and Spine interventions.
- eviCore healthcare reserves the right to change and update the guidelines. The guidelines undergo a formal review annually. eviCore's guidelines are based upon major national and international association and society guidelines and criteria, peer-reviewed literature, major treatises, and input from health plans, practicing academic and community-based physicians.
- These guidelines are not intended to supersede or replace sound medical judgment, but instead should facilitate the identification of the most appropriate imaging procedure, given the patient's clinical condition. These guidelines are written to cover medical conditions as experienced by the majority of patients. However, these guidelines may not be applicable in certain clinical circumstances, and physician judgment can override the guidelines.
- Clinical decisions, including treatment decisions, are the responsibility of the patient and his/her provider. Clinicians are expected to use independent medical judgment which takes into account the clinical circumstances to determine patient management decisions.
- eviCore supports the Choosing Wisely® initiative (www.choosingwisely.org) by the American Board of Internal Medicine (ABIM) Foundation and many national physician organizations, to reduce the overuse of diagnostic tests that are low value, no value, or whose risks are greater than the benefits.
- eviCore's guidelines are based upon expert consensus and analysis reported by the following specialty societies, publications, studies and trials:
 - The American College of Cardiology (ACC)
 - The American Heart Association (AHA)
 - The Heart Rhythm Society (HRS)

- The Multicenter Automatic Defibrillator Implantation Trial (MADIT/MADIT-2)
- The Multicenter Unsustained Tachycardia Trial (MUSTT)
- The Defibrillator in Acute Myocardial Infarction Trial (DINAMIT)
- The Resynchronization/defibrillation for Ambulatory Heart Failure Trial (RAFT)
- The Sudden Cardiac Death in Heart Failure Trial (SCD-HeFT)
- The Resynchronization Reverses Remodeling in Systolic Left Ventricular Dysfunction trial (REVERSE)
- Immediate Risk Stratification Improves Survival trial (IRIS)
- The Comparison of Medical Therapy, Pacing, and Defibrillation in Heart Failure trial (COMPANION)
- The Antiarrhythmic Versus Implantable Defibrillators trial (AVID)
- The Canadian Implantable Defibrillator Study (CIDS)
- The Cardiac Arrest Study Hamburg (CASH)

Benefits, coverage policies, and eligibility issues (Preface-2)

- Benefits, coverage policies, and eligibility issues pertaining to each Health Plan may take precedence over eviCore's guidelines. Providers are urged to obtain written instructions and requirements directly from each payer.
- Medicare Coverage Policies
 - For Medicare and Medicare Advantage enrollees, the coverage policies of CMS (Centers for Medicare and Medicaid Services) may take precedence over eviCore's guidelines
 - Payors may choose to adopt other evidence-based guidelines (such as eviCore's guidelines) rather than using Local Coverage Determinations and other Medicare coverage policy
- Investigational and Experimental Studies
 - Certain imaging studies described in these guidelines are considered investigational by various payors, and their coverage policies may take precedence over eviCore's guidelines
- Clinical and Research Trials
 - Similar to investigational and experimental studies, clinical trial imaging requests will be considered to determine whether they meet health plan coverage and eviCore's evidence-based guidelines
- State and federal legislations may need to be considered in the review of advanced imaging requests

Clinical information (Preface-3)

- The philosophy behind eviCore guidelines entails using an evidence-based approach to determine the most appropriate procedure for each individual, at the most appropriate time in the diagnostic and treatment cycle.
- Procedures should be requested after initial consultation and physician treatment planning, and following full counseling of the individual.

- Current clinical information, which may include history, physical examination, symptoms, laboratory results, and imaging reports, are necessary for determining the medical necessity of implantable cardiac devices.
- The information provided to eviCore should have clinical relevance to the request.
- If the information provided makes no reference to the potential indication for the request, then the medical necessity for the procedure(s) cannot be supported.

References (Preface-4)

- References are available at the end of the guidelines

Copyright information (Preface-5)

©2023 eviCore healthcare. All rights reserved. No part of these materials may be changed, reproduced, or transmitted in any form or by any means, electronic or mechanical, including photocopying or recording, or in any information storage or retrieval system, without the prior express written permission of eviCore.

Trademarks (Preface-6)

CPT® (Current Procedural Terminology) is a registered trademark of the American Medical Association (AMA). CPT® five digit codes, nomenclature and other data are copyright 2023 American Medical Association. All Rights Reserved. No fee schedules, basic units, relative values or related listings are included in the CPT® book. AMA does not directly or indirectly practice medicine or dispense medical services. AMA assumes no liability for the data contained herein or not contained herein.

General information (CRID-1)

CID.AD.101.A
v1.0.2024

Guideline

General Guidelines (CRID-1.0)

Procedure codes (CRID-1.1)

Removal and replacement (CRID-1.2)

General Guidelines (CRID-1.0)

- Current clinical information, which may include history, physical examination, symptoms, laboratory results, and imaging reports, are necessary for determining the medical necessity of implantable cardiac devices.
- The information provided to eviCore should have clinical relevance to the request.
- If the information provided makes no reference to the potential indication for the request, then the medical necessity for the procedure(s) cannot be supported.
- Requests for a device when a same or similar device has already been placed is not supported without clear documentation that fulfills guideline criteria.

Procedure codes (CRID-1.1)

Procedure description	CPT®
Insertion of new or replacement of permanent pacemaker with transvenous electrode(s); atrial	33206
Insertion of new or replacement of permanent pacemaker with transvenous electrode(s); ventricular	33207
Insertion of new or replacement of permanent pacemaker with transvenous electrode(s); atrial and ventricular	33208
Insertion of pacemaker pulse generator only; single existing single lead	33212
Insertion of pacemaker pulse generator only; with existing dual leads	33213
Upgrade of implanted pacemaker system, conversion of single chamber system to dual chamber system (includes removal of previously placed pulse generator, testing of existing lead, insertion of new lead, insertion of new pulse generator)	33214
Removal of permanent pacemaker pulse generator with replacement of pacemaker pulse generator; single lead system	33227
Removal of permanent pacemaker pulse generator with replacement of pacemaker pulse generator; dual lead system	33228
Insertion of pacemaker pulse generator only; with existing multiple leads	33221

Procedure description	CPT®
Insertion of pacing electrode, cardiac venous system, for left ventricular pacing, with attachment to previously placed pacemaker or pacing cardioverter-defibrillator pulse generator	33224
Insertion of pacing electrode, cardiac venous system, for left ventricular pacing, at time of insertion of pacing cardioverter-defibrillator pulse generator (including upgrade to dual chamber system and pocket revision)	33225
Removal of permanent pacemaker pulse generator with replacement of pacemaker pulse generator; multiple lead system	33229
Insertion of pacing cardioverter-defibrillator pulse generator only; with existing dual leads	33230
Insertion of pacing cardioverter-defibrillator pulse generator only; with existing multiple leads	33231
Insertion of pacing cardioverter-defibrillator pulse generator only; with existing single leads	33240
Insertion or replacement of permanent pacing cardioverter-defibrillator system with transvenous lead(s), single or dual chamber	33249
Removal of pacing cardioverter-defibrillator pulse generator with replacement of pacing cardioverter-defibrillator pulse generator; single lead system	33262
Removal of pacing cardioverter-defibrillator pulse generator with replacement of pacing cardioverter-defibrillator pulse generator; dual lead system	33263
Removal of pacing cardioverter-defibrillator pulse generator with replacement of pacing cardioverter-defibrillator pulse generator; multiple lead system	33264
Insertion or replacement of permanent subcutaneous implantable defibrillator system, with subcutaneous electrode, including defibrillation threshold evaluation, induction of arrhythmia, evaluation of sensing for arrhythmia termination, and programming or reprogramming of sensing or therapeutic parameters when performed	33270
Transcatheter insertion or replacement of permanent leadless pacemaker, right ventricular, including imaging guidance (e.g., fluoroscopy, venous ultrasound, ventriculography, femoral venography) and device evaluation (e.g., interrogation or programming), when performed	33274

Procedure description	CPT®
Transcatheter implantation of wireless pulmonary artery pressure sensor for long-term hemodynamic monitoring, including deployment and calibration of the sensor, right heart catheterization, selective pulmonary catheterization, radiological supervision and interpretation, and pulmonary artery angiography, when performed	33289
Insertion of wireless cardiac stimulator for left ventricular pacing, including device interrogation and programming, and imaging supervision and interpretation, when performed; complete system (includes electrode and generator [transmitter and battery])	0515T
Insertion of wireless cardiac stimulator for left ventricular pacing, including device interrogation and programming, and imaging supervision and interpretation, when performed; electrode only	0516T
Insertion of wireless cardiac stimulator for left ventricular pacing, including device interrogation and programming, and imaging supervision and interpretation, when performed; pulse generator component(s) (battery and/or transmitter) only	0517T
Removal and replacement of wireless cardiac stimulator for left ventricular pacing; pulse generator component(s) (battery and/or transmitter)	0519T
Removal and replacement of wireless cardiac stimulator for left ventricular pacing; pulse generator component(s) (battery and/or transmitter), including placement of a new electrode	0520T
Insertion or replacement of implantable cardioverter-defibrillator system with substernal electrode(s), including all imaging guidance and electrophysiological evaluation (includes defibrillation threshold evaluation, induction of arrhythmia, evaluation of sensing for arrhythmia termination, and programming or reprogramming of sensing or therapeutic parameters), when performed	0571T
Insertion of substernal implantable defibrillator electrode	0572T
Removal and replacement of substernal implantable defibrillator pulse generator	0614T
Transcatheter insertion of permanent dual-chamber leadless pacemaker, including imaging guidance (eg, fluoroscopy, venous ultrasound, right atrial angiography, right ventriculography, femoral venography) and device evaluation (eg, interrogation or programming), when performed; complete system (ie, right atrial and right ventricular pacemaker components)	0795T
Transcatheter insertion of right atrial pacemaker component (when an existing right ventricular single leadless pacemaker exists to create a dual-chamber leadless pacemaker system)	0796T

Procedure description	CPT®
Transcatheter insertion of right ventricular pacemaker component (when part of a dual-chamber leadless pacemaker system)	0797T
Transcatheter removal of permanent dual-chamber leadless pacemaker, including imaging guidance (eg, fluoroscopy, venous ultrasound, right atrial angiography, right ventriculography, femoral venography), when performed; complete system (ie, right atrial and right ventricular pacemaker components)	0798T
Transcatheter removal of right atrial pacemaker component	0799T
Transcatheter removal of right ventricular pacemaker component (when part of a dual-chamber leadless pacemaker system)	0800T
Transcatheter removal and replacement of permanent dual-chamber leadless pacemaker, including imaging guidance (eg, fluoroscopy, venous ultrasound, right atrial angiography, right ventriculography, femoral venography) and device evaluation (eg, interrogation or programming), when performed; dual-chamber system (ie, right atrial and right ventricular pacemaker components)	0801T
Transcatheter removal and replacement of right atrial pacemaker component	0802T
Transcatheter removal and replacement of right ventricular pacemaker component (when part of a dual-chamber leadless pacemaker system)	0803T
Transcatheter insertion of permanent single-chamber leadless pacemaker, right atrial, including imaging guidance (eg, fluoroscopy, venous ultrasound, right atrial angiography and/or right ventriculography, femoral venography, cavography) and device evaluation (eg, interrogation or programming), when performed	0823T
Transcatheter removal of permanent single-chamber leadless pacemaker, right atrial, including imaging guidance (eg, fluoroscopy, venous ultrasound, right atrial angiography and/or right ventriculography, femoral venography, cavography), when performed	0824T
Transcatheter removal and replacement of permanent single-chamber leadless pacemaker, right atrial, including imaging guidance (eg, fluoroscopy, venous ultrasound, right atrial angiography and/or right ventriculography, femoral venography, cavography) and device evaluation (eg, interrogation or programming), when performed	0825T

Removal and replacement (CRID-1.2)

- Generator replacement (CPT® 33212, 33213, 33221, 33227, 33228, 33229, 33230, 33231, 33240, 33262, 33263, 33264, 0614T, 0801T, 0802T, 0803T) with a same or similar device is indicated when:
 - Interrogation shows device is nearing Elective Replacement Indicator (ERI) or End of Life (EOL).
 - Interrogation report documents the device is not functioning correctly and requires replacement.

Pacemaker Devices

Guideline

Indications for Permanent Pacemaker Implantation (CRID-7)

Permanent Pacemaker Implantation - Non-indications (CRID-9)

Leadless pacemaker (CRID-11.1)

Indications for Permanent Pacemaker Implantation (CRID-7)

CID.PM.105.A

v1.0.2024

CPT® 33206, 33207, 33208

Sinus node dysfunction

Permanent pacemaker implantation is indicated for any of the following:

- Symptomatic sinus node dysfunction as evidenced by both of the following:
 - Documented sinus node dysfunction including one of the below:
 - Sinus bradycardia at rate <50 beats per minute
 - Sinus pauses >3 seconds
 - Symptoms attributable to sinus node dysfunction including one of the below:
 - Syncope or pre-syncope
 - Heart failure symptoms
 - Exertional fatigue and impaired exercise tolerance
- Sinus bradycardia at rate <40 beats per minute and symptoms possibly related to bradycardia
- Symptomatic sinus bradycardia (as defined above) as a consequence of guideline directed management and continued treatment is clinically necessary
- Symptoms attributable to bradycardia as listed above and evidence of tachy-brady syndrome (sinus bradycardia, ectopic atrial bradycardia, or sinus pause alternating with periods of atrial flutter or atrial fibrillation)
- Symptomatic chronotropic incompetence defined as limitations due to the inability to achieve 80% of maximum predicted heart rate (220-age)

Atrioventricular block (AVB)

Permanent pacemaker implantation is indicated for any of the following:

- AVB including one of the below with or without symptoms:
 - Second-degree Mobitz type II
 - High-grade (≥ 2 consecutive P waves at a constant physiologic rate that do not conduct to the ventricles)
 - Third-degree (complete heart block)
- Any degree of AVB with one of the following symptoms that are clearly attributable to the AVB:
 - Syncope or pre-syncope

- Heart failure symptoms
- Exertional fatigue and impaired exercise tolerance
- Third-degree and advanced second-degree AV block at any anatomic level associated with sustained or non-sustained ventricular tachycardia (ventricular rhythm at rate >100 bpm lasting ≥ 3 consecutive beats) presumed due to AV block
- Marked first-degree AVB (PR interval >0.3 seconds) or second-degree AVB with symptoms similar to those of pacemaker syndrome
- Symptomatic AVB as a consequence of guideline directed management and continued treatment is clinically necessary
- Persistent or permanent atrial fibrillation and symptomatic bradycardia including one of the following:
 - Rate <50 beats per minute
 - Regular QRS intervals indicating complete AVB
- Second degree AV block with a documented pause of ≥ 5 seconds during waking in the presence of atrial fibrillation, with or without symptoms
- Second degree AV block with documented periods of asystole ≥ 3.0 seconds in the presence of sinus rhythm, with or without symptoms
- Second-degree AVB noted to be located at intra- or infra-His levels at electrophysiology study (EPS), with or without symptoms
- Any AVB indication listed above occurring after acute myocardial infarction that does not resolve within 5 days
- Congenital complete or high-degree AVB in the presence of any of the following:
 - Symptoms
 - Wide QRS escape rhythm
 - Mean daytime heart rate below 50 bpm
 - Pauses >3 times the cycle length of the ventricular escape rhythm
 - Complex ventricular ectopy
 - Prolonged QT interval
 - Ventricular dysfunction, ventricular dilatation or significant mitral regurgitation

Conduction Disorders with 1:1 Atrioventricular Conduction

Permanent pacemaker implantation is indicated for any of the following:

- Individuals with syncope and bundle branch block and one of the following at electrophysiology study (EPS):
 - Baseline HV interval ≥ 70 ms
 - Second- or third-degree intra- or infra-Hisian block during incremental atrial pacing
- Alternating bundle branch block with or without symptoms
- HV interval ≥ 100 milliseconds noted at EPS, with or without symptoms

- Intra- or infra- Hisian block noted at EPS, with or without symptoms

Recurrent syncope

Permanent pacemaker implantation is indicated for individuals with recurrent syncope and any of the following:

- Spontaneous documented symptomatic asystolic pause >3 seconds due to sinus arrest or atrioventricular block (AVB)
- Spontaneous documented asymptomatic asystolic pause >6 seconds due to sinus arrest or AVB
- Cardioinhibitory carotid sinus syndrome as documented by one of the below:
 - Syncope caused by spontaneously occurring carotid sinus stimulation
 - Carotid sinus pressure that induces syncope and/or ventricular asystole of ≥ 3 seconds
- Syncope associated with asystole of ≥ 3 seconds during tilt testing
- Bundle branch block and one of the following at electrophysiology study (EPS):
 - Baseline HV interval ≥ 70 ms
 - Second- or third-degree intra- or infra-Hisian block during incremental atrial pacing
- Syncope after cardiac transplantation with or without documentation of bradyarrhythmia

Peri-procedural and post-operative indications

Permanent pacemaker implantation is indicated for any of the following:

- Prior to a planned catheter ablation of the atrioventricular (AV) junction for one of the following:
 - Rate control strategy for management of atrial fibrillation
 - Supraventricular tachycardia resulting in tachycardia induced cardiomyopathy that is not controlled with ablation or medical therapy
- Post Transcatheter Aortic Valve Implantation (TAVI) for any of the following:
 - Complete or high-degree atrioventricular block (AVB) that persists for 24 to 48 hours after TAVI
 - New-onset alternating bundle branch block after TAVI
 - Pre-existing right bundle branch block (RBBB) and new conduction abnormality onset during or after (TAVI) such as:
 - Transient high-degree AVB
 - PR prolongation
 - QRS axis change

- Sinus node dysfunction or AVB associated with symptoms or hemodynamic instability occurring after cardiac surgery that does not resolve within 5 days
- Post cardiac transplant for any of the following:
 - Relative bradycardia that is prolonged or recurrent, which limits rehabilitation or discharge after postoperative recovery
 - Syncope with or without documentation of bradyarrhythmia

Neuromuscular diseases known to involve the heart

Permanent pacemaker implantation may be considered for progressive neuromuscular diseases known to involve the heart with any degree of atrioventricular (AV) block including first degree AV block or any fascicular block, with or without symptoms, because there may be unpredictable progression of AV conduction disease.

Progressive neuromuscular diseases known to involve the heart include:

- Myotonic muscular dystrophy
- Kearns-Sayre syndrome
- Erb dystrophy (limb-girdle muscular dystrophy)
- Peroneal muscular atrophy

References

1. Kusumoto FM, Schoenfeld MH, Barrett C, et al. 2018 ACC/AHA/HRS Guideline on the Evaluation and Management of Patients With Bradycardia and Cardiac Conduction Delay: A Report of the American College of Cardiology/American Heart Association Task Force on Clinical Practice Guidelines and the Heart Rhythm Society [published correction appears in *J Am Coll Cardiol*. 2019 Aug 20;74(7):1016-1018]. *J Am Coll Cardiol*. 2019;74(7):e51-e156. doi:10.1016/j.jacc.2018.10.044.
2. Glikson M, Nielsen JC, Kronborg MB, et al. 2021 ESC Guidelines on cardiac pacing and cardiac resynchronization therapy [published correction appears in *Eur Heart J*. 2022 May 1;43(17):1651]. *Eur Heart J*. 2021;42(35):3427-3520. doi:10.1093/eurheartj/ehab364.
3. Writing Committee Members, Shah MJ, Silka MJ, et al. 2021 PACES Expert Consensus Statement on the Indications and Management of Cardiovascular Implantable Electronic Devices in Pediatric Patients. *Heart Rhythm*. 2021;18(11):1888-1924. doi:10.1016/j.hrthm.2021.07.038.

Permanent Pacemaker Implantation - Non-indications (CRID-9)

CID.PM.103.A

v1.0.2024

- Permanent pacemaker implantation is **not** indicated in any of the following settings:
 - Sinus node dysfunction when there is documentation of any of the following
 - Individual is asymptomatic
 - The symptoms suggestive of bradycardia have been clearly documented to occur in the absence of bradycardia
 - Sinus node dysfunction is due to nonessential drug therapy
 - Fascicular block without AV block or without symptoms concerning for AV block
 - Incidentally noted hypersensitive cardioinhibitory response to carotid sinus stimulation when the individual remains asymptomatic or has vague symptoms
 - Asymptomatic first-degree AV block
 - Asymptomatic type-1 second-degree AV block at the supra-His (AV node) level or that which is not known to be intra- or infra-Hisian
 - Asymptomatic transient AV block in the absence of intraventricular conduction defects or in isolated single fascicular block
 - Situational vasovagal syncope when avoidance behavior is effectively preventing syncopal episodes
 - Prior to Transcatheter Aortic Valve Replacement (TAVR) as a prophylactic measure in individuals with right bundle branch block (RBBB) when there is no indication for permanent pacing
 - For the purpose of cardiac contractility modulation

References

1. Correction to: 2022 AHA/ACC/HFSA Guideline for the Management of Heart Failure: A Report of the American College of Cardiology/American Heart Association Joint Committee on Clinical Practice Guidelines. *Circulation*. 2023;147(14):e674. doi:10.1161/CIR.0000000000001142.
2. Heidenreich PA, Bozkurt B, Aguilar D, et al. 2022 AHA/ACC/HFSA Guideline for the Management of Heart Failure: A Report of the American College of Cardiology/American Heart Association Joint Committee on Clinical Practice Guidelines [published correction appears in *Circulation*. 2022 May 3;145(18):e1033] [published correction appears in *Circulation*. 2022 Sep 27;146(13):e185] [published correction appears in *Circulation*. 2023 Apr 4;147(14):e674]. *Circulation*. 2022;145(18):e895-e1032. doi:10.1161/CIR.0000000000001063.
3. Borggreffe MM, Lawo T, Butter C, et al. Randomized, double blind study of non-excitatory, cardiac contractility modulation electrical impulses for symptomatic heart failure. *Eur Heart J*. 2008;29(8):1019-1028. doi:10.1093/eurheartj/ehn020.
4. Abraham WT, Kuck KH, Goldsmith RL, et al. A Randomized Controlled Trial to Evaluate the Safety and Efficacy of Cardiac Contractility Modulation [published correction appears in *JACC Heart Fail*. 2023 Jan;11(1):132]. *JACC Heart Fail*. 2018;6(10):874-883. doi:10.1016/j.jchf.2018.04.010.
5. Borggreffe M, Mann DL. Cardiac Contractility Modulation in 2018. *Circulation*. 2018;138(24):2738-2740. doi:10.1161/CIRCULATIONAHA.118.036460.

6. Kadish A, Nademanee K, Volosin K, et al. A randomized controlled trial evaluating the safety and efficacy of cardiac contractility modulation in advanced heart failure [published correction appears in *Am Heart J*. 2011 Jun;161(6):1220]. *Am Heart J*. 2011;161(2):329-337.e3372. doi:10.1016/j.ahj.2010.10.025.
7. McDonagh TA, Metra M, Adamo M, et al. 2021 ESC Guidelines for the diagnosis and treatment of acute and chronic heart failure: Developed by the Task Force for the diagnosis and treatment of acute and chronic heart failure of the European Society of Cardiology (ESC). With the special contribution of the Heart Failure Association (HFA) of the ESC. *Eur J Heart Fail*. 2022;24(1):4-131. doi:10.1002/ejhf.2333.

Leadless pacemaker (CRID-11.1)

CID.PM.104.A

v1.0.2024

Leadless right ventricular pacemaker (CRID-11.1.1)

Indications for permanent right ventricular leadless pacemaker (CPT® 33274) implant - **all** of the following must be met:

- Meets **one** of the following indications for leadless right ventricular pacemaker:
 - Symptomatic paroxysmal or permanent high-grade AV block in the presence of Atrial Fibrillation (AF)
 - Symptomatic paroxysmal or permanent high-grade AV block in the absence of AF, as an alternative to dual chamber pacing, when atrial lead placement is considered difficult, high risk, or not deemed necessary for effective therapy
 - Symptomatic bradycardia-tachycardia syndrome or sinus node dysfunction (sinus bradycardia or sinus pauses), as an alternative to atrial or dual chamber pacing, when atrial lead placement is considered difficult, high risk, or not deemed necessary for effective therapy
- The following contraindications for leadless pacemaker are **not** present:
 - An implanted inferior vena cava filter
 - A mechanical tricuspid valve

Leadless dual chamber pacemaker system (CRID-11.1.2)

Indications for permanent dual chamber leadless pacemaker implant (CPT® 0795T) - **all** of the following must be met:

- Meets one of the following indications for leadless dual chamber pacemaker:
 - Sick sinus syndrome
 - Chronic, symptomatic second- and third-degree AV block
 - Recurrent Adams-Stokes syndrome
 - Symptomatic bilateral bundle branch block when tachyarrhythmia and other causes have been ruled out
- The following contraindications for leadless pacemaker are **not** present:
 - An implanted inferior vena cava filter
 - A mechanical tricuspid valve

Leadless right atrial pacemaker (CRID-11.1.3)

Indications for permanent leadless right atrial pacemaker implant (CPT® 0823T) - **all** of the following must be met:

- Meets the following indication for leadless right atrial pacemaker:
 - Sinus node dysfunction with normal AV and intraventricular conduction systems
- The following contraindications for leadless pacemaker are not present:

- An implanted inferior vena cava filter
- A mechanical tricuspid valve

General information

Right ventricular leadless pacemaker

The permanent right ventricular leadless pacemakers (CPT® 33274) consists of a single leadless device implanted directly into the right ventricle. The Medtronic Micra™ VR and Abbott Aveir™ VR right ventricular leadless pacemakers are capable only of VVI and VVIR pacing. The Medtronic Micra™ AV right ventricular leadless pacemaker is also capable of VDD pacing. The right ventricular leadless pacemakers do not have capability for atrial pacing. The estimated battery life is about 10 years

Dual chamber leadless pacemaker

In contrast to the right ventricular leadless pacemakers referred to above, the dual chamber leadless pacemaker (i.e., Abbott Aveir™ DR leadless pacemaker system) has dual-chamber sensing and pacing functionality. The Abbott Aveir™ DR leadless pacemaker system consists of two separate components: one implanted in the right atrium and the other in the right ventricle.

References

1. Ngo L, Nour D, Denman RA, et al. Safety and Efficacy of Leadless Pacemakers: A Systematic Review and Meta-Analysis. *J Am Heart Assoc.* 2021 Jul 6;10(13):e019212. doi:10.1161/JAHA.120.019212.
2. Reddy V, Exner D, Doshi R, et al. Primary Results on Safety and Efficacy From the LEADLESS II–Phase 2 Worldwide Clinical Trial. *J Am Coll Cardiol EP.* 2022 Jan;8(1):115–117. doi:10.1016/j.jacep.2021.11.002.
3. Neugebauer F, Noti F, van Gool S, et al. Leadless atrioventricular synchronous pacing in an outpatient setting: Early lessons learned on factors affecting atrioventricular synchrony. *Heart Rhythm.* 2022 May;19(5):748-756. doi:10.1016/j.hrthm.2021.12.025.
4. El-Chami MF, Bockstedt L, Longacre C, et al. Leadless vs. transvenous single-chamber ventricular pacing in the Micra CED study: 2-year follow-up. *Eur Heart J.* 2022 March;43(12):1207-1215. doi:10.1093/eurheartj/ehab767.
5. Knops RE, Reddy VY, Ip JE, et al. A Dual-Chamber Leadless Pacemaker. *N Engl J Med.* 2023;388(25):2360-2370. doi:10.1056/NEJMoa2300080.
6. U.S. Food and Drug Administration (FDA). Summary of Safety and Effectiveness Data (SSED): Aveir™ DR Leadless System (PMS P150035/S003). 6/29/2023. [cited 10/01/2023]. 'Available from:' https://www.accessdata.fda.gov/cdrh_docs/pdf15/P150035S003B.pdf.
7. U.S. Food and Drug Administration (FDA). FDA Approval Order June 29, 2023: Aveir™ DR Leadless System (PMS P150035/S003). 6/29/2023. [cited 10/01/2023]. Available from: https://www.accessdata.fda.gov/cdrh_docs/pdf15/P150035S003A.pdf.

Implantable cardioverter- defibrillator (ICD) Devices

Guideline

- Definite indications for ICD implantation (CRID-2)
- Reasonable indications for ICD implantation (CRID-3)
- ICD implantation non-indications (CRID-4)

Definite indications for ICD implantation (CRID-2)

CID.ICD.100.A

v1.0.2024

Procedures included

CPT® 33249, 33270

Guideline

Survivors of cardiac arrest (CRID-2.1)

Structural heart disease with sustained VT (CRID-2.2)

Syncope of undetermined origin and positive EP study (CRID-2.3)

Unexplained syncope (CRID-2.4)

Ischemic cardiomyopathy (CRID-2.5)

Non-ischemic dilated cardiomyopathy (DCM) (CRID-2.6)

Survivors of cardiac arrest (CRID-2.1)

- ICD implantation is indicated in individuals who are survivors of cardiac arrest due to ventricular tachycardia (VT) or ventricular fibrillation (VF) after evaluation has excluded any completely reversible causes

Structural heart disease with sustained VT (CRID-2.2)

- ICD implantation is indicated in individuals with structural heart disease (such as prior myocardial infarction (MI), congenital heart disease, and/or ventricular dysfunction) and spontaneous, sustained VT (greater than 30 seconds), whether hemodynamically stable or unstable

Syncope of undetermined origin and positive EP study (CRID-2.3)

- ICD implantation is indicated in individuals with syncope of undetermined origin who have clinically relevant, hemodynamically significant sustained VT or VF induced at electrophysiology (EP) study

Unexplained syncope (CRID-2.4)

- ICD implantation is indicated in individuals with unexplained syncope, significant left ventricular (LV) dysfunction (LV ejection fraction less than 50%), and structural heart disease such as prior myocardial infarction (MI), congenital heart disease, and/or ventricular dysfunction

Ischemic cardiomyopathy (CRID-2.5)

- ICD implantation is indicated in individuals with **any** of the following:
 - Left ventricular systolic dysfunction due to ischemic heart disease and **all** of the following:
 - LV ejection fraction $\leq 35\%$ despite ≥ 3 months of **optimal medical therapy**
 - Symptomatic heart failure (NYHA functional Class II or III)
 - Left ventricular systolic dysfunction due to ischemic heart disease and **all** of the following:
 - LV ejection fraction $\leq 30\%$ despite ≥ 3 months of **optimal medical therapy**
 - NYHA functional Class I
 - Left ventricular systolic dysfunction due to ischemic heart disease and **all** of the following:
 - LV ejection fraction $\leq 40\%$ despite ≥ 3 months of **optimal medical therapy**
 - Non-sustained ventricular tachycardia
 - Inducible sustained monomorphic ventricular tachycardia at electrophysiological (EP) study

Optimal medical therapy should include a beta-blocker and **one** of the following:

- ACE inhibitor
- angiotensin II receptor blocker
- angiotensin receptor-neprilysin inhibitor

Non-ischemic dilated cardiomyopathy (DCM) (CRID-2.6)

- ICD implantation is indicated in individuals with nonischemic dilated cardiomyopathy who have **all** of the following:
 - LV ejection fraction $\leq 35\%$ despite ≥ 3 months of **optimal medical therapy**
 - Symptomatic heart failure (NYHA Class II or III CHF)

Reasonable indications for ICD implantation (CRID-3)

CID.ICD.101.A

v1.0.2024

Procedures included

CPT® 33249, 33270

Guideline

General considerations (CRID-3.1)

Sustained ventricular tachycardia with normal LV function (CRID-3.2)

Cardiomyopathy (CRID-3.3)

Long QT syndrome (CRID-3.4)

Brugada syndrome (CRID-3.5)

Catecholaminergic polymorphic ventricular tachycardia (CRID-3.6)

Muscular Dystrophy (CRID-3.8)

Other indications (CRID-3.7)

General considerations (CRID-3.1)

- For the “reasonable” or “considered” indications listed in this CRID-3 guideline, consensus opinion is less clear about the use of ICD implantation in these settings. Limited evidence suggests that ICD placement may be reasonable or may be considered; this category includes VF or hypotensive VT events where pharmaceutical or ablative techniques are indicated but the results of treatment are too unpredictable to withhold ICD implantation.

Sustained ventricular tachycardia with normal LV function (CRID-3.2)

- ICD implantation is reasonable for individuals with sustained VT and normal or near-normal ventricular function

Cardiomyopathy (CRID-3.3)

Individuals with cardiomyopathy who have one or more risk factors for sudden cardiac death

Hypertrophic Cardiomyopathy:

ICD implantation is reasonable for individuals with hypertrophic cardiomyopathy who have one or more risk factors for sudden cardiac death including the following:

- Unheralded syncope
- Family history of sudden death
- Septal wall thickness ≥ 30 mm

- Abnormal blood pressure response to exercise (SBP increase of <20mm/hg with exercise or a drop in BP)
- Ventricular tachycardia, sustained or nonsustained
- LV apical aneurysm, independent of size
- LV ejection fraction < 50%

Cardiomyopathy due to Arrhythmogenic Right Ventricular Cardiomyopathy (ARVC):

ICD implantation is reasonable for individuals with ARVC who have one or more risk factors for sudden cardiac death Risk factors for sudden cardiac death include the following:

- Unheralded syncope
- Family history of sudden death
- Ventricular tachycardia, sustained or nonsustained
- Clinical signs of RV failure

Long QT syndrome (CRID-3.4)

- ICD implantation is reasonable in Long-QT Syndrome in the following settings:
 - Syncope and/or VT while receiving beta-blockers or if beta-blockers are contraindicated
 - Asymptomatic with other risk factors for sudden cardiac death
 - Risk factors for sudden cardiac death include the following:
 - QT_c greater than 500 msec or
 - LQT 2 or 3
 - Family history of sudden death

Brugada syndrome(CRID-3.5)

- ICD implantation is reasonable for individuals with Brugada Syndrome who have had the following:
 - Syncope or
 - Documented or inducible VT or VF

Catecholaminergic polymorphic ventricular tachycardia (CRID-3.6)

- ICD implantation is reasonable for individuals with catecholaminergic polymorphic VT who have syncope and/or documented sustained VT while receiving beta-blockers.

Muscular Dystrophy (CRID-3.8)

- ICD implantation is reasonable, regardless of LV ejection fraction for **any** of the following:
 - Emery-Dreifuss muscular dystrophy (EDMD)
 - Limb-Girdle Type 1B muscular dystrophy (LGMD1B)
 - Myotonic Dystrophy Type 1 with an indication for a permanent pacemaker
 - Lamin A/C (LMNA) mutation (for patients who don't meet the above criteria of EDMD or LGMD1B) when there is documentation of **two or more** of the following risk factors for sudden cardiac death:
 - Non-sustained ventricular tachycardia
 - LVEF < 45%
 - Non-missense mutation (ins-del/truncating or mutations affecting splicing)
 - Male sex at birth
 - For sustained VT see **Sustained Ventricular Tachycardia with Normal LV Function**

Other indications (CRID-3.7)

- ICD implantation is reasonable, regardless of LV ejection fraction measurement, for individuals with:
 - Cardiac sarcoidosis
 - Giant cell myocarditis
 - Chagas disease
- LV non compaction
 - ICD implantation should be considered for the primary prevention of sudden cardiac death due to malignant ventricular arrhythmias in individuals with non-compaction cardiomyopathy and impaired LV function (LV ejection fraction less than 50%)
 - ICD implantation is also indicated for normal LV function (LVEF greater than 50%) primary prevention cases with positive family history of sudden cardiac death. This exception is due to the presence of sarcomeric gene mutations reported in non-compaction cardiomyopathy
- ICD implantation may be considered in affected individuals with a familial cardiomyopathy associated with sudden death

ICD implantation non-indications (CRID-4)

CID.ICD.102.A

v1.0.2024

Guideline

- Ischemic cardiomyopathy (CRID-4.1)
- NYHA class IV CHF (CRID-4.2)
- Limited life expectancy (CRID-4.3)
- Incessant VT or VF (CRID-4.4)
- Psychiatric conditions (CRID-4.5)
- Reversible causes of VT/VF (CRID-4.6)
- Ablation candidate, no structural heart disease (CRID-4.7)
- Substernal implantable cardioverter-defibrillator (CRID-4.8)

Ischemic cardiomyopathy (CRID-4.1)

- ICD implantation is **not** indicated in individuals who have had a myocardial infarction within the past 40 days or who have had coronary revascularization within the past 90 days **unless** the following applies:
 - A separate indication for permanent pacemaker implantation exists (thus preventing a likely repeat procedure for an upgraded device in the near future)

NYHA class IV CHF (CRID-4.2)

- ICD implantation is **not** indicated for individuals with NYHA functional class IV symptoms **unless** one of the following applies:
 - It is a CRT-D device meeting the indications for CRT-D implantation listed in **Sinus Rhythm, Dilated Cardiomyopathy with NYHA Class II, III, or IV Congestive Heart Failure (CHF)**
 - The individual is awaiting heart transplantation
 - Left ventricular assist device (LVAD) is being used as destination therapy

Limited life expectancy (CRID-4.3)

- ICD implantation is **not** indicated for individuals who do not have a reasonable expectation of survival with an acceptable functional status for at least one year, even if they meet ICD implantation criteria listed in:
 - **Definite Indications for ICD Implantation** or
 - **Reasonable Indications for ICD Implantation**

Incessant VT or VF (CRID-4.4)

- ICD implantation is **not** indicated for individuals with incessant VT or VF
 - Incessant VT or VF is defined as hemodynamically stable VT or VF continuing for hours

Psychiatric conditions (CRID-4.5)

- ICD implantation is **not** indicated in individuals with significant psychiatric illnesses that may be aggravated by device implantation or that may preclude systematic follow-up.

Reversible causes of VT/VF (CRID-4.6)

- ICD implantation is **not** indicated when VF or VT is due to a reversible cause such as:
 - Severe electrolyte disturbance
 - Drug-induced torsades de pointes
 - Acute, reperfused myocardial infarction with preserved ejection fraction

Ablation candidate, no structural heart disease (CRID-4.7)

- ICD implantation is **not** indicated if the individual has no structural heart disease and is a candidate for ablation. Surgical or catheter ablation can be curative in this setting.

Substernal implantable cardioverter-defibrillator (CRID-4.8)

CPT® 0571T

- Substernal implantable cardioverter-defibrillator systems involve inserting a defibrillator lead directly beneath the sternum anterior to the heart, and is intended to provide anti-tachycardia pacing as well as post-shock pacing without intravenous leads.
- At this time substernal implantable cardioverter-defibrillator systems are considered experimental and investigational.

Cardiac Resynchronization Therapy (CRT) Devices

Guideline

Indications for cardiac resynchronization therapy (CRT)-D implantation (CRID-5)

Cardiac resynchronization therapy (CRT)-D implantation - non-indications (CRID-6)

Cardiac resynchronization therapy (CRT)-P (CRID-10)

Wireless Cardiac Resynchronization (CRID-11.2)

Indications for cardiac resynchronization therapy (CRT)-D implantation (CRID-5)

CID.CRT.100.A
v1.0.2024

Procedures included

CPT® 33224, 33225, 33208, 33229, 33249, 33264

Guideline

- Sinus rhythm, dilated cardiomyopathy with LBBB (CRID-5.1)
- Sinus rhythm, dilated cardiomyopathy with non-LBBB (CRID-5.3)
- Atrial fibrillation and NYHA class II, III, or IV Congestive Heart Failure (CRID-5.4)
- Dilated Cardiomyopathy with atrial fibrillation requiring AV Junction ablation for heart rate control (CRID-5.5)
- Dilated Cardiomyopathy with high-grade AV block (CRID-5.6)
- Indications for upgrade to CRT-D (CRID-5.7)

Sinus rhythm, dilated cardiomyopathy with LBBB (CRID-5.1)

- CRT-D is indicated in individuals with ischemic or nonischemic dilated cardiomyopathy who have **all** of the following
 - LV ejection fraction $\leq 35\%$ despite **optimal medical therapy (OMT)**
 - Left bundle branch block with QRS ≥ 120 msec
 - Symptomatic heart failure NYHA functional Class II, III, or ambulatory class IV
- CRT-P can be indicated when all of the requirements of CRT-D have been met and the individual in consultation with the providing physician declines the ICD function

Sinus rhythm, dilated cardiomyopathy with non-LBBB (CRID-5.3)

- CRT-D is indicated in individuals with ischemic or nonischemic dilated cardiomyopathy who have **all** of the following
 - LV ejection fraction $\leq 35\%$ despite **optimal medical therapy (OMT)**
 - Non-LBBB pattern with QRS duration ≥ 150 ms
 - Symptomatic heart failure NYHA class III, or ambulatory class IV
- CRT-P can be indicated when all of the requirements of CRT-D have been met and the individual in consultation with the providing physician declines the ICD function

Atrial fibrillation and NYHA class II, III, or IV Congestive Heart Failure (CRID-5.4)

- CRT-D is indicated in individuals with atrial fibrillation who have **all** of the following:
 - LV ejection fraction $\leq 35\%$ despite **optimal medical therapy (OMT)**
 - Meet one of the following CRT criteria:
 - Left bundle branch block (LBBB) with a QRS duration ≥ 120 ms and symptomatic heart failure New York Heart Association (NYHA) functional class II, III, or ambulatory class IV
 - Non-LBBB pattern with a QRS duration ≥ 150 and symptomatic heart failure NYHA class III or ambulatory class IV
 - Non-pharmacologic or pharmacologic rate control will allow near 100% biventricular pacing with CRT
- CRT-P can be indicated when all of the requirements of CRT-D have been met and the individual in consultation with the providing physician declines the ICD function

Dilated Cardiomyopathy with atrial fibrillation requiring AV Junction ablation for heart rate control (CRID-5.5)

CRT-D is indicated in individuals with atrial fibrillation and **all** of the following:

- LV ejection fraction $\leq 35\%$ **optimal medical therapy (OMT)**
- Uncontrolled heart rate requiring atrioventricular (AV) Junction ablation

CRT-P can be indicated when all of the requirements of CRT-D have been met and the individual in consultation with the providing physician declines the ICD function

Dilated Cardiomyopathy with high-grade AV block (CRID-5.6)

CRT-D is indicated in individuals in sinus rhythm or atrial fibrillation who have **all** of the following:

- LV ejection fraction $\leq 35\%$ despite **optimal medical therapy (OMT)**
- High-grade atrioventricular (AV) block requiring ventricular pacing

CRT-P can be indicated when all of the requirements of CRT-D have been met and the individual in consultation with the providing physician declines the ICD function

Indications for upgrade to CRT-D (CRID-5.7)

Upgrade to CRT-D is indicated in individuals who have **all** of the following:

- LV ejection fraction $\leq 35\%$ despite **optimal medical therapy (OMT)**
- New or worsening symptomatic heart failure (NYHA functional Class II, III, or ambulatory class IV) following implantation of a non-CRT pacemaker or cardioverter-defibrillator (ICD)
- Ventricular pacing $> 40\%$

CRT-P can be indicated when all of the requirements of CRT-D have been met and the individual in consultation with the providing physician declines the ICD function

Cardiac resynchronization therapy (CRT)-D implantation - non-indications (CRID-6)

CID.CRT.101.A
v1.0.2024

Guideline

Ischemic cardiomyopathy (CRID-6.1)

Reversible causes of cardiomyopathy (CRID-6.2)

Ischemic cardiomyopathy (CRID-6.1)

- CRT-D or CRT-P implantation is **not** indicated in individuals who have had a myocardial infarction within the past 40 days or who have had coronary revascularization within the past 90 days **unless** the following applies
 - A separate indication for permanent pacemaker implantation exists (thus preventing a likely repeat procedure for an upgraded device in the near future)

Reversible causes of cardiomyopathy (CRID-6.2)

- CRT-D implantation is **not** indicated in the setting of a reversible cardiomyopathy such as: toxic, metabolic, or tachycardia induced cardiomyopathy
 - Once the reversible aberration is corrected, clinical reassessment is indicated

Cardiac resynchronization therapy (CRT)-P (CRID-10)

CID.CRT.102.A

v1.0.2024

Indications for CRT-P (CRID-10.1)

Procedures included

CPT® 33224, 33225, 33208, 33229

CRT-P is indicated for any of the following:

- High grade AV block and NYHA Class I, II or III Congestive Heart Failure:
 - CRT-P implantation is indicated in individuals who have **all** of the following:
 - LV ejection fraction <50%
 - NYHA Class I, II, or III heart failure
 - High grade AV block, including AV nodal ablation, requiring more than 40% ventricular pacing (CRT)-P
- Pacing-induced cardiomyopathy
 - Upgrade from non-CRT pacemaker to CRT-P is indicated in individuals who have **all** of the following:
 - LV EF >50% prior to implantation of non-CRT pacemaker
 - Right ventricular pacing burden ≥40%
 - One of the following occurring after implantation of non-CRT pacemaker:
 - Decline in LV EF ≥10%
 - New or worsening heart failure symptoms NYHA Class II or III
- See also **Indications for Cardiac Resynchronization Therapy (CRT)-D Implantation** for individuals who have met requirements for CRT-D, but decline the ICD function

Indications for conduction system pacing

His bundle pacing or left bundle branch area pacing (CPT® 33207 or CPT® 33208) may be considered when CRID 10.1 indications for CRT-P are met and one of the following applies:

- LV lead placement was attempted and was unsuccessful or suboptimal
- His bundle pacing or left bundle branch area pacing is planned in place of biventricular pacing

Wireless Cardiac Resynchronization (CRID-11.2)

CID.CRT.104.A

v1.0.2024

Wireless cardiac resynchronization - Criteria (CRID-11.2)

- Permanent LV leadless pacemakers (CPT® 0515T) are implanted directly in the left ventricle for synchronization with RV leads in the setting of cardiac resynchronization therapy. At this time they are considered experimental and investigational.

Other Cardiac Implantable Devices

Guideline

Wireless Pulmonary Artery Pressure Sensor (CRID-11.3)

Wireless Pulmonary Artery Pressure Sensor (CRID-11.3)

CID.OD.100.A

v1.0.2024

Wireless pulmonary artery pressure sensor - Criteria

Wireless Pulmonary Artery Pressure Sensor devices (CPT® 33289) such as, CardioMEMS™ HF System, are implanted into a branch of the pulmonary artery during right heart catheterization and require a specialized delivery system. These devices monitor constant pulmonary artery pressures over time, utilizing the concept that as pulmonary artery pressures increase, outpatient medical therapy can be adjusted. This can potentially reduce inpatient admissions and treatment.

- Although FDA approved, these devices have yet to be incorporated into the standard of care and remain investigational and experimental at this time.

References

Guideline

References

References

v1.0.2024

1. Josephson ME and Nisam S. The AVID trial executive committee. Are implantable cardioverter-defibrillators or drugs more effective in prolonging life? *Am J Cardiol*. 1997 Mar;79(5):661-663. doi:10.1016/S0002-9149(96)00834-X.
2. Kuck K-H, Cappato R, Siebels J, et al. Randomized Comparison of Antiarrhythmic Drug Therapy With Implantable Defibrillators in Patients Resuscitated From Cardiac Arrest. *Circulation*. 2000;102(7):748-754. doi:10.1161/01.cir.102.7.748.
3. Connolly SJ, Gent M, Roberts RS, et al. Canadian Implantable Defibrillator Study (CIDS). A randomized trial of the implantable cardioverter defibrillator against amiodarone. *Circulation*. 2000 Mar;101(11):1297-1302. doi:10.1161/01.cir.101.11.1297.
4. Gronefeld G, Connolly SJ, and Hohnloser SH. The Defibrillator in Acute Myocardial Infarction Trial (DINAMIT) rationale, design and specific aims. *Card Electrophysiol Rev*. 2003 Dec;7(4):447-451. doi:10.1023/B:CEPR.0000023154.52786.f4.
5. Steinbeck G, Andresen D, Seidl K, et al. Defibrillator implantation early after myocardial infarction.(IRIS). *N Engl J Med*. 2009 Oct;361:1427-1436. doi:10.1056/NEJMoa0901889.
6. Moss A, Hall W, Cannom D, et al. Cardiac-resynchronization therapy for the prevention of heart-failure events (MADIT2). *N Engl J Med*. 2009 Oct; 361:1329-1338. doi:10.1056/NEJMoa0906431.
7. Bardy G, Lee K, Mark D, et al. Amiodarone or an implantable cardioverter-defibrillator for congestive heart failure.(SCD-HeFT). *N Engl J Med*. 2005 Jan;352:225-37. doi:10.1056/NEJMoa043399.
8. Buxton AE, Lee KL, DiCarlo L, et al. Electrophysiologic testing to identify patients with coronary artery disease who are at risk for sudden death. Multicenter Unsustained Tachycardia Trial Investigators. (MUSTT). *N Engl J Med*. 2000 Jun;342:1937-1945. doi:10.1056/NEJM200006293422602.
9. Epstein A, Dimarco J, Ellenbogen K, et al. ACC/AHA/HRS 2008 Guidelines for device-based therapy of cardiac rhythm abnormalities: A Report of the American College of Cardiology/American Heart Association Task Force on Practice Guidelines (Writing Committee to revise the ACC/AHA/NASPE 2002 Guideline update for implantation of cardiac pacemakers and anti-arrhythmia devices): Developed in Collaboration With the American Association for Thoracic Surgery and Society of Thoracic Surgeons. *Circulation*. 2008 May;117(21). doi:10.1161/CIRCULATIONAHA.108.189742.
10. Russo AM, Stainback RF, Bailey SR, et al. ACCF/HRS/AHA/ASE/HFSA/SCAI/SCCT/SCMR 2013 appropriate use criteria for implantable cardioverter-defibrillators and cardiac resynchronization therapy: a report of the American College of Cardiology Foundation appropriate use criteria task force, Heart Rhythm Society, American Heart Association, American Society of Echocardiography, Heart Failure Society of America, Society for Cardiovascular Angiography and Interventions, Society of Cardiovascular Computed Tomography, and Society for Cardiovascular Magnetic Resonance. *J Am Coll Cardiol*. 2013 Apr; 10(4):e11-e58. doi:10.1016/j.jacc.2012.12.017.
11. Gersh BJ, Maron BJ, Bonow RO, et al. 2011 ACCF/AHA Guideline for the Diagnosis and Treatment of Hypertrophic Cardiomyopathy. *Circulation*. 2011;124(24). doi:10.1161/cir.0b013e318223e2bd.
12. Caliskan K, Szili-Torok T, Theuns D, et al. Indications and outcome of implantable cardioverter-defibrillators for primary and secondary prophylaxis in patients with noncompaction cardiomyopathy. *J Cardiovasc Electrophysiol*. 2011 Aug;22(8):898-904. doi:10.1111/j.1540-8167.2011.02015.x.
13. Zareba W, Klein H, Cygankiewicz I, et al. Effectiveness of cardiac resynchronization therapy by QRS morphology in Multicenter Automatic Defibrillator Implantation Trial – Cardiac Resynchronization Therapy (MADIT-CRT). *Circulation*. 2011 Mar;123(10):1061-1072. doi:10.1161/CIRCULATIONAHA.110.960898.
14. Tang AS, Wells GA, Talajic M, et al. Cardiac-Resynchronization Therapy for Mild-to-Moderate Heart Failure. *N Engl J Med*. 2010;363(25):2385-2395. doi:10.1056/nejmoa1009540.
15. Linde C, Gold MR, Abraham WT, et al. Rationale and design of a randomized controlled trial to assess the safety and efficacy of cardiac resynchronization therapy in patients with asymptomatic left ventricular dysfunction with previous symptoms or mild heart failure—the Resynchronization reVERses Remodeling in Systolic left ventricular dysfunction (REVERSE) study. *Am Heart J*. 2006 Feb;151(2):288-294. doi:10.1016/j.ahj.2005.03.002.
16. Tracy C, Epstein A, Darbar D, et al. 2012 ACCF/AHA/HRS focused update of the 2008 guidelines for device-based therapy of cardiac rhythm abnormalities: A report of the American College of Cardiology Foundation/American Heart Association Task Force on Practice Guidelines. *J Thorac Cardiovasc Surg*. 2012 Dec; 144(6): e127–e145. doi:10.1016/j.jtcvs.2012.08.032.
17. Yancy CW, Jessup M, Bozkurt B, et al. 2013 ACCF/AHA guideline for the management of heart failure: a report of the American College of Cardiology Foundation/American Heart Association Task Force on practice guidelines. *Circulation*. 2013 Oct;128:e240-e327. doi:10.1161/CIR.0b013e31829e8776.

18. Daubert J-C, Saxon L, Adamson PB, et al. 2012 EHRA/HRS expert consensus statement on cardiac resynchronization therapy in heart failure: Implant and follow-up recommendations and management: A registered branch of the European Society of Cardiology (ESC), and the Heart Rhythm Society; and in collaboration with the Heart Failure Society of America (HFSA), the American Society of Echocardiography (ASE), the American Heart Association (AHA), the European Association of Echocardiography (EAE) of the ESC and the Heart Failure Association of the ESC (HFA). * Endorsed by the governing bodies of AHA, ASE, EAE, HFSA, HFA, EHRA, and HRS. *Europace*. 2012;14(9):1236-1286. doi:10.1093/europace/eus222.
19. Healey JS, Hohnloser SH, Exner DV, et al. Cardiac resynchronization therapy in patients with permanent atrial fibrillation: results from the Resynchronization for Ambulatory Heart Failure Trial (RAFT). *Circulation: Heart failure*. 2012 Sept;5(5):566-570. doi:10.1161/CIRCHEARTFAILURE.112.968867.
20. Curtis AB, Worley SJ, Adamson PB, et al. Biventricular pacing for atrioventricular block and systolic dysfunction. *N Engl J Med*. 2013 Apr; 368:1585-93. doi:10.1056/NEJMoa1210356.
21. Bristow MR, Saxon LA, Boehmer J, et al. Cardiac-Resynchronization Therapy with or without an Implantable Defibrillator in Advanced Chronic Heart Failure. *N Engl J Med*. 2004 May; 350:2140-2150. doi:10.1056/NEJMoa032423.
22. Kay R, Estioko M, and Wiener I. Primary sick sinus syndrome as an indication for chronic pacemaker therapy in young adults: Incidence, clinical features, and long-term evaluation. *Am Heart J*. 1982 Mar;103(3):338-42. doi:10.1016/0002-8703(82)90271-x.
23. Kusumoto F and Goldschlager N. Cardiac pacing. *N Engl J Med*. 1996 Jan; 334:89-99. doi:10.1056/NEJM199601113340206.
24. Rasmussen K. Chronic sinus node disease: natural course and indications for pacing. *Euro Heart J*. 1981 Dec;2(6):455-459. doi:10.1093/oxfordjournals.eurheartj.a061236.
25. Linde-Edelstam C, Nordlander R, Pehrsson SK, et al. A double-blind study of submaximal exercise tolerance and variation in paced rate in atrial synchronous compared to activity sensor modulated ventricular pacing. *PACE*. 1992 Jun;15(6):905-15. doi:10.1111/j.1540-8159.1992.tb03081.x.
26. Charles R, Holt S, Kay JM, et al. Myocardial ultrastructure and the development of atrioventricular block in Kearns-Sayre syndrome. *Circulation*. 1981 Jan;63(1):214-219. doi:10.1161/01.cir.63.1.214.
27. Clemmensen P, Bates ER, Califf RM, et al. Complete atrioventricular block complicating inferior wall acute myocardial infarction treated with reperfusion therapy. TAMI Study Group. *Am J Cardiol*. 1991 Feb;67(4):225-230. doi:10.1016/0002-9149(91)90550-5.
28. Ector H, Rolies L, and De Geest H. Dynamic electrocardiography and ventricular pauses of 3 seconds and more: etiology and therapeutic implications. *PACE*. 1983 May;6(3):548-551. doi:10.1111/j.1540-8159.1983.tb05294.x.
29. Glikson M, Dearani JA, HybergerLK, et al. Indications, effectiveness, and long-term dependency in permanent pacing after cardiac surgery. *Am J Cardiology*. 1997 Nov;80(10):1309-13. doi:10.1016/S0002-9149(97)00671-1.
30. Hiromasa S, Ikeda T, Kubota K, et al. Myotonic dystrophy: ambulatory electrocardiogram, electrophysiologic study, and echocardiographic evaluation. *Am Heart J*. 1987 Jun;113(6):1482-1488. doi:10.1016/0002-8703(87)90665-X.
31. Kastor JA. Atrioventricular block (first of two parts). *N Engl J Med*. 1975;292:462-5. doi:10.1056/NEJM197502272920906.
32. Kastor JA. Atrioventricular block (second of two parts). *N Engl J Med*. 1975 Mar;292:572-574. doi:10.1056/NEJM197503132921106.
33. Perloff JK, Stevenson WG, Roberts NK, et al. Cardiac involvement in myotonic muscular dystrophy (Steinert's disease): a prospective study of 25 patients. *Am J Cardiol*. 1984 Nov;54(8):1074-81. doi:10.1016/S0002-9149(84)80147-2.
34. Zipes DP. Second-degree atrioventricular block. *Circulation*. 1979 Sept;60(3):465-72. doi:10.1161/01.CIR.60.3.465.
35. LangbergJJ, Chin MC, Rosenqvist M, et al. Catheter ablation of the atrioventricular junction with radiofrequency energy. *Circulation*. 1989 Dec;80(6):1527-1535. doi:10.1161/01.CIR.80.6.1527.
36. Fujimura O, Klein GJ, Yee R, et al. Mode of onset of atrial fibrillation in the Wolff-Parkinson-White syndrome: How important is the accessory pathway? *J Am Coll Cardiol*. 1990 Apr;15(5):1082-1086. doi:10.1016/0735-1097(90)90244-J.
37. Reiffel J and Kuehnert M. Electrophysiological testing of sinus node function: diagnostic and prognostic application-including updated information from sinus node electrograms. *PACE*. 1994 Mar;17(3):349-65. doi:10.1111/j.1540-8159.1994.tb01397.x.
38. Sheldon R, Koshman ML, Wilson W, et al. Effect of dual-chamber pacing with automatic rate-drop sensing on recurrent neurally mediated syncope. *Am J Cardiol*. 1998 Jan;81(2):158-162. doi:10.1111/j.1540-8159.1994.tb01397.x.
39. Barold SS. Indications for permanent cardiac pacing in first-degree AV block: class I, II, or III? *PACE*. 1996 May;19(5):747-751. doi:10.1111/j.1540-8159.1996.tb03355.x.

40. Connelly DT and Steinhaus DM. Mobitz type I atrioventricular block: an indication for permanent pacing? *PACE*. 1996 Mar;19(3):261-264. doi:10.1111/j.1540-8159.1996.tb03325.x.
41. British Pacing and Electrophysiology Group. Recommendations for pacemaker prescription for symptomatic bradycardia. Report of a working party of the British Pacing and Electrophysiology Group. *Br Heart J*. 1991;66(2):185-191.
42. Connolly SJ, Sheldon R, Thorpe KE, et al. Pacemaker therapy for prevention of syncope in patients with recurrent severe vasovagal syncope: Second Vasovagal Pacemaker Study (VPS II): A randomized trial. *JAMA*. 2003;289(17):2224-2229. doi:10.1001/jama.289.17.2224.
43. Epstein AE, DiMarco JP, Ellenbogen KA, et al. 2012 ACCF/AHA/HRS Focused Update of the 2008 Guidelines for Device-Based Therapy of Cardiac Rhythm Abnormalities: A Report of the American College of Cardiology Foundation/American Heart Association Task Force on Practice Guidelines. *Circulation*. 2012 Sept;126(14):p1784-1800. doi:10.1161/CIR.0b013e3182618569.
44. Al-Khatib SM, Stevenson WG, Ackerman MJ, et al. 2017 AHA/ACC/HRS Guideline for Management of Patients With Ventricular Arrhythmias and the Prevention of Sudden Cardiac Death. *Circulation*. 2018;138(13). doi:10.1161/cir.0000000000000549.
45. Kusumoto FM, Calkins H, Boehmer J, et al. HRS/ACC/AHA expert consensus statement on the use of implantable cardioverter-defibrillator therapy in patients who are not included or not well represented in clinical trials. *J Am Coll Cardiol*. 2014;64:1143-77. doi:10.1161/CIR.0000000000000056.
46. Bernard ML. Pacing Without Wires: Leadless Cardiac Pacing. *Ochsner J*. 2016;16(3):238-242.
47. Abraham WT, Perl L. Implantable Hemodynamic Monitoring for Heart Failure Patients. *J Am Coll Cardiol*. 2017;70(3):389-398. doi:10.1016/j.jacc.2017.05.052.
48. Reddy VY, Miller MA, Neuzil P, et al. Cardiac Resynchronization Therapy With Wireless Left Ventricular Endocardial Pacing. *J Am Coll Cardiol*. 2017;69(17):2119-2129. doi:10.1016/j.jacc.2017.02.059.
49. Kirkfeldt RE, Johansen JB, Nohr EA, et al. Complications after cardiac implantable electronic device implantations: an analysis of a complete, nationwide cohort in Denmark. *Eur Heart J*. 2014;35:1186-1194. doi:10.1093/eurheartj/ehf511.
50. Udo EO, Zuihoff NPA, van Hemel NM, et al. Incidence and predictors of short and long-term complications in pacemaker therapy: The FOLLOWPACE study. *Heart Rhythm*. 2012;9:728-735. doi:10.1016/j.hrthm.2011.12.014.
51. Reynolds D, Duray GZ, Omar R, et al. A leadless intracardiac transcatheter pacing system. *N Engl J Med*. 2016;374:533-541. doi:10.1056/NEJMoa1511643.
52. Tracy CM, Epstein AE, Darbar D, et al. 2012 ACCF/AHA/HRS Focused Update Incorporated into the ACCF/AHA/HRS 2008 Guidelines for Device-Based Therapy of Cardiac Rhythm Abnormalities: A Report of the American College of Cardiology Foundation/American Heart Association Task Force on Practice Guidelines and the Heart Rhythm Society. *J Am Coll Cardiol*. 2013;61:e6-e75. doi:10.1016/j.jacc.2012.11.007.
53. Okabe T, El-Chami MF, Lloyd MS, et al. Leadless pacemaker implantation and concurrent atrioventricular junction ablation in patients with atrial fibrillation. *Pacing Clin Electrophysiol*. doi:10.1111/pace.13312.
54. Epstein AE, DiMarco JP, Ellenbogen KA, et al. ACC/AHA/HRS 2008 guidelines for device based therapy of cardiac rhythm abnormalities: a report of the American College of Cardiology/American Heart Association Task Force on Practice Guidelines (Writing Committee to Revise the ACC/AHA/NASPE 2002 Guideline Update for Implantation of Cardiac Pacemakers and Antiarrhythmia Devices). *Circulation*. 2008; 117:e350-e408. doi: 10.1161/CIRCULATIONAHA.108.189742.
55. Boersma LV, Merkely B, Neuzil P, et al. Therapy From a Novel Substernal Lead. *JACC: Clinical Electrophysiology*. 2019;5(2):186-196. doi:10.1016/j.jacep.2018.11.003.
56. Ommen SR, Mital S, Burke MA, et al. 2020 AHA/ACC Guideline for the Diagnosis and Treatment of Patients with Hypertrophic Cardiomyopathy. *Circulation*. 2020;142(25). doi:10.1161/cir.0000000000000937.
57. Glikson M, Nielsen JC, Kronborg MB, et al. 2021 ESC Guidelines on cardiac pacing and cardiac resynchronization therapy: Developed by the Task Force on cardiac pacing and cardiac resynchronization therapy of the European Society of Cardiology (ESC) With the special contribution of the European Heart Rhythm Association (EHRA). *Rev Esp Cardiol (Engl Ed)*. 2022;75(5):430. doi:10.1016/j.rec.2022.04.004.
58. Al-Khatib SM, Stevenson WG, Ackerman MJ, et al. 2017 AHA/ACC/HRS Guideline for Management of Patients With Ventricular Arrhythmias and the Prevention of Sudden Cardiac Death: A Report of the American College of Cardiology/American Heart Association Task Force on Clinical Practice Guidelines and the Heart Rhythm Society. *Circulation*. 2018 Sep 25;138(13):e272-e391. doi: 10.1161/CIR.0000000000000549.
59. Zeppenfeld K, Tfelt-Hansen J, de Riva M, et al. 2022 ESC Guidelines for the management of patients with ventricular arrhythmias and the prevention of sudden cardiac death. *Eur Heart J*. 2022 Oct 21;43(40):3997-4126. doi: 10.1093/eurheartj/ehac262.
60. McDonagh TA, Metra M, et al. 2021 ESC Guidelines for the diagnosis and treatment of acute and chronic heart failure: Developed by the Task Force for the diagnosis and treatment of acute and chronic heart failure of the European Society of Cardiology (ESC). With the special contribution of the Heart Failure Association (HFA) of the ESC. *Eur J Heart Fail*. 2022;24(1):4-131. doi:10.1002/ehfj.2333.

61. Heidenreich PA, Bozkurt B, Aguilar D, et al. 2022 AHA/ACC/HFSA Guideline for the Management of Heart Failure: A Report of the American College of Cardiology/American Heart Association Joint Committee on Clinical Practice Guidelines [published correction appears in *Circulation*. 2022 May 3;145(18):e1033] [published correction appears in *Circulation*. 2022 Sep 27;146(13):e185] [published correction appears in *Circulation*. 2023 Apr 4;147(14):e674]. *Circulation*. 2022;145(18):e895-e1032. doi:10.1161/CIR.0000000000001063.
62. Chung MK, Patton KK, Lau CP, et al. 2023 HRS/APHRS/LAHRS guideline on cardiac physiologic pacing for the avoidance and mitigation of heart failure. *Heart Rhythm*. 2023;20(9):e17-e91. doi:10.1016/j.hrthm.2023.03.1538.

Table of Contents

Guideline

- General Guidelines (CH-1)
- Lymphadenopathy (CH-2)
- Cough (CH-3)
- Non-Cardiac Chest Pain (CH-4)
- Dyspnea/Shortness of Breath (CH-5)
- Hemoptysis (CH-6)
- Bronchiectasis (CH-7)
- Bronchitis (CH-8)
- Asbestos Exposure (CH-9)
- Chronic Obstructive Pulmonary Disease (COPD) (CH-10)
- Interstitial Disease (CH-11)
- Pneumonia and Coronavirus Disease 2019 (COVID-19) (CH-13)
- Other Chest Infections (CH-14)
- Sarcoid (CH-15)
- Solitary Pulmonary Nodule (SPN) (CH-16)
- Pleural-Based Nodules and Other Abnormalities (CH-17)
- Pleural Effusion (CH-18)
- Pneumothorax/Hemothorax (CH-19)
- Mediastinal Mass (CH-20)
- Chest Trauma (CH-21)
- Chest Wall Mass (CH-22)
- Pectus Excavatum and Pectus Carinatum (CH-23)
- Pulmonary Arteriovenous Fistula (AVM) (CH-24)
- Pulmonary Embolism (PE) (CH-25)
- Pulmonary Hypertension (CH-26)
- Subclavian Steal Syndrome (CH-27)
- Superior Vena Cava (SVC) Syndrome (CH-28)
- Elevated Hemidiaphragm (CH-30)
- Thoracic Outlet Syndrome (TOS) (CH-31)
- Lung Transplantation (CH-32)
- Lung Cancer Screening (CH-33)

General Guidelines (CH-1)

Guideline

Abbreviations for Chest Guidelines

General Guidelines (CH-1.0)

General Guidelines – Chest X-Ray (CH-1.1)

General Guidelines – Chest Ultrasound (CH-1.2)

General Guidelines – CT Chest (CH-1.3)

General Guidelines – CTA Chest (CPT 71275) (CH-1.4)

General Guidelines – MRI Chest without and with Contrast (CPT 71552)
(CH-1.5)

General Guidelines – Nuclear Medicine (CH-1.6)

Navigational Bronchoscopy (CH-1.7)

References (CH-1)

Abbreviations for Chest Guidelines

CH.GG.Abbreviations.A
v2.0.2024

Abbreviations for Chest Guidelines	
AAA	abdominal aortic aneurysm
ACE	angiotensin-converting enzyme
AVM	arteriovenous malformation
BP	blood pressure
CAD	computer-aided detection
CBC	Complete blood count
COPD	chronic obstructive pulmonary disease
CT	computed tomography
CTA	computed tomography angiography
CTV	computed tomography venography
DVT	deep venous thrombosis
ECG	electrocardiogram
EM	electromagnetic
EMG	electromyogram
FDA	Food and Drug Administration
FDG	fluorodeoxyglucose
FNA	fine needle aspiration
GERD	gastroesophageal reflux disease
GI	gastrointestinal
HRCT	high resolution computed tomography
IPF	idiopathic pulmonary fibrosis
LFTP	localized fibrous tumor of the pleura
MRA	magnetic resonance angiography
MRI	magnetic resonance imaging
MRV	magnetic resonance venography
NCV	nerve conduction velocity
PE	pulmonary embolus
PET	positron emission tomography
PFT	pulmonary function tests

Abbreviations for Chest Guidelines	
PPD	purified protein derivative of tuberculin
RODEO	Rotating Delivery of Excitation Off-resonance MRI
SPN	solitary pulmonary nodule
SVC	superior vena cava

General Guidelines (CH-1.0)

CH.GG.0001.0.A
v2.0.2024

- A pertinent clinical evaluation since the onset or change in symptoms is required prior to considering advanced imaging.
 - A pertinent clinical evaluation should include the following:
 - A detailed history and physical examination
 - Appropriate laboratory studies and basic imaging, such as plain radiography or ultrasound
 - A recent chest x-ray since the onset or change in symptoms that has been over read by a radiologist would be performed in many of these cases prior to considering advanced imaging.^{1,2}
 - Identify and compare with previous chest films to determine presence and stability.
 - For an established individual a meaningful technological contact (telehealth visit, telephone call, electronic mail or messaging) since the onset or change in symptoms can serve as a pertinent clinical evaluation.

General Guidelines – Chest X-Ray (CH-1.1)

CH.GG.0001.1.A

v2.0.2024

- Chest x-ray can help identify previously unidentified disease and direct proper advanced imaging for such conditions as:
 - Pneumothorax (See **Pneumothorax/Hemothorax (CH-19.1)**)
 - Pneumomediastinum (See **Pneumothorax/Hemothorax (CH-19.1)**)
 - Fractured ribs (See **Chest Trauma (CH-21.1)**)
 - Chest wall mass (See **Chest Wall Mass (CH-22.1)**)
 - Acute and chronic infections (See **Pneumonia and Coronavirus Disease 2019 (COVID-19) (CH-13)** and **Other Chest Infections (CH-14)**)
 - Malignancies
- Exceptions to preliminary chest x-ray include such conditions as:
 - Supraclavicular lymphadenopathy (See **Supraclavicular Region (CH-2.1)**)
 - Known Bronchiectasis (See **Bronchiectasis (CH-7.1)**)
 - Suspected Interstitial lung disease (See **Interstitial Lung Disease (ILD)/Diffuse Lung Disease (DLD) (CH-11.1)**)
 - Positive PPD or tuberculosis (See **Other Chest Infections (CH-14)**)
 - Suspected Pulmonary AVM (See **Pulmonary Hypertension (CH-26.1)**)

General Guidelines – Chest Ultrasound (CH-1.2)

CH.GG.0001.2.A

v2.0.2024

- Chest ultrasound (CPT® 76604) includes transverse, longitudinal, and oblique images of the chest wall with measurements of chest wall thickness, and also includes imaging of the mediastinum.
 - Chest ultrasound:
 - CPT® 76604
 - Breast ultrasound:
 - CPT®76641: unilateral, complete.
 - CPT®76642: unilateral, limited.
 - CPT®76641 and CPT®76642 should be reported only once per breast, per imaging session
 - Axillary ultrasound:
 - CPT® 76882 (unilateral); if bilateral, can be reported as CPT® 76882 x 2

General Guidelines – CT Chest (CH-1.3)

CH.GG.0001.3.A

v2.0.2024

- Intrathoracic abnormalities found on chest x-ray, fluoroscopy, CT Abdomen, or other imaging modalities can be further evaluated with CT Chest with contrast (CPT® 71260).
- CT Chest without contrast (CPT® 71250) can be used for the following:
 - Individual has contraindication to contrast
 - Follow-up of pulmonary nodule(s)
 - High Resolution CT (HRCT)
- Low-dose CT Chest (CPT® 71271) See **Lung Cancer Screening (CH-33)**
- CT Chest without and with contrast (CPT® 71270) does not add significant diagnostic information above and beyond that provided by CT Chest with contrast, unless a question regarding calcification, most often within a lung nodule, needs to be resolved.¹

CT Chest Coding Notes:

- High resolution CT Chest should be reported only with an appropriate code from the set CPT® 71250-CPT® 71270.
 - No additional CPT® codes should be reported for the “high resolution” portion of the scan. The “high resolution” involves additional slices which are not separately billable.

General Guidelines – CTA Chest (CPT® 71275) (CH-1.4)

CH.GG.0001.4.A

v2.0.2024

- CTA Chest (CPT® 71275) can be considered for suspected Pulmonary Embolism and Thoracic Aortic disease.
 - CTA prior to minimally invasive or robotic surgery (See **Transcatheter Aortic Valve Replacement (TAVR) (CD-4.8)** in the Cardiac Imaging Guidelines).

General Guidelines – MRI Chest without and with Contrast (CPT® 71552) (CH-1.5)

CH.GG.0001.5.A

v2.0.2024

- Indications for MRI Chest are infrequent and may relate to concerns about CT contrast such as renal insufficiency or contrast allergy. MRI may be indicated:
 - Clarification of some equivocal findings on previous imaging studies, which are often in the thymic mediastinal region or determining margin (vascular/soft tissue) involvement with tumor and determined on a case-by-case basis.
 - Certain conditions include:
 - Chest wall mass (See **Chest Wall Mass (CH-22.1)**)
 - Chest muscle tendon injuries (See **Muscle/Tendon Unit Injuries/Diseases (MS-11.1)** in the Musculoskeletal Imaging Guidelines)
 - Pectoralis tendon rupture (See **Shoulder (MS-19)**)
 - Brachial plexopathy (See **Brachial Plexus (PN-4.1)** in the Peripheral Nerve Disorders Imaging Guidelines)
 - Thymoma (See **Thymoma and Thymic Carcinoma - Suspected/Diagnosis (ONC-10.5)** in the Oncology Imaging Guidelines)

General Guidelines – Nuclear Medicine (CH-1.6)

CH.GG.0001.6.A
v2.0.2024

CPT	Description
78580	Pulmonary perfusion imaging (eg, particulate)
78582	Pulmonary ventilation (eg, aerosol or gas) and perfusion imaging
78597	Quantitative differential pulmonary perfusion, including imaging when performed
78598	Quantitative differential pulmonary perfusion and ventilation (e.g., aerosol or gas), including imaging when performed

- Pulmonary perfusion imaging (eg, particulate) (CPT® 78580) and Pulmonary ventilation (eg, aerosol or gas) and perfusion imaging (CPT® 78582) See **Pulmonary Embolism (CH-25.1)**
- Quantitative differential pulmonary perfusion, including imaging when performed (CPT® 78597) and Quantitative differential pulmonary perfusion and ventilation (e.g., aerosol or gas), including imaging when performed (CPT® 78598) See **Pre-Operative Assessment (CH-5.2)**

Navigational Bronchoscopy (CH-1.7)

CH.GG.0001.7.A
v2.0.2024

- CPT® 76497 (Unlisted CT procedure) can be considered if:
 - A CT Chest has been performed within the last 6 weeks and study is needed for navigational bronchoscopy.
- CT Chest without contrast (CPT® 71250) can be considered for:
 - Previous diagnostic scan was ≥ 6 weeks ago and study is needed for navigational bronchoscopy

Background and Supporting Information

- **Navigational Bronchoscopy:** This is a form of guided bronchoscopy. A special sensor inside a bronchoscopy is used to navigate to the desired location within the lung. Computer software generates a virtual bronchial tree which provides a road map to the target lesion. A thin-cut CT Chest with optimized reconstruction parameters is required to generate the virtual map of the lungs. A previous CT Chest may not be usable for navigation if it was not formatted correctly, even if done just a few days prior.

References (CH-1)

v2.0.2024

1. Raof S, Feigin D, Sung A, Raof S, Irugulpati L, Rosenow EC 3rd. Interpretation of plain chest roentgenogram. *Chest*. 2012;141(2):545-558. doi:10.1378/chest.10-1302
2. Eisen LA, Berger JS, Hegde A, Schneider RF. Competency in chest radiography. A comparison of medical students, residents, and fellows. *J Gen Intern Med*. 2006;21(5):460-465. doi:10.1111/j.1525-1497.2006.00427.x
3. Rawson JV, Pelletier AL. When to Order a Contrast-Enhanced CT. *Am Fam Physician*. 2013;88(5):312-316.
4. *RECOMMENDED CT SCAN and RECONSTRUCTION PARAMETERS SUPPLEMENT*. <https://www.medtronic.com/content/dam/covidien/library/us/en/product/interventional-lung-solutions/illumisite-platform-scan-parameters-information-sheet.pdf>
5. Gildea TR, Mazzone PJ, Karnak D, Meziane M, Mehta AC. Electromagnetic navigation diagnostic bronchoscopy: a prospective study. *Am J Respir Crit Care Med*. 2006;174(9):982-989. doi:10.1164/rccm.200603-344OC
6. Mehta AC, Hood KL, Schwarz Y, Solomon SB. The Evolutional History of Electromagnetic Navigation Bronchoscopy: State of the Art. *Chest*. 2018;154(4):935-947. doi:10.1016/j.chest.2018.04.029

Lymphadenopathy (CH-2)

Guideline

Supraclavicular Region (CH-2.1)

Axillary Lymphadenopathy (and Mass) (CH-2.2)

Mediastinal Lymphadenopathy (CH-2.3)

References (CH-2)

Supraclavicular Region (CH-2.1)

CH.LA.0002.1.A

v2.0.2024

- Ultrasound (CPT® 76536) is the initial study for palpable or suspected lymphadenopathy.
 - Allows simultaneous ultrasound-guided core needle biopsy (CPT® 76942)
 - CT Neck with contrast (CPT® 70491) or CT Chest with contrast (CPT® 71260) if ultrasound is indeterminate
 - See **General Guidelines (Neck-1.0)** in the Neck Imaging Guidelines

Axillary Lymphadenopathy (and Mass) (CH-2.2)

CH.LA.0002.2.A

v2.0.2024

- There is no evidence-based support for advanced imaging of clinically evidenced axillary lymphadenopathy prior to a biopsy.^{2,3} If axillary node biopsy reveals benign findings, advanced imaging is not indicated. If axillary node biopsy reveals findings concerning for malignancy, pathology results will determine the need for further advanced imaging. See **Carcinoma of Unknown Primary Site (ONC-31.7)** in the Oncology imaging Guidelines for imaging recommendations for carcinoma found in an axillary lymph node.
- Localized axillary lymphadenopathy:
 - Axillary US (CPT® 76882)
 - Initial evaluation of any axillary mass or enlarged node
 - Search for adjacent hand or arm injury or infection, and
 - 3-4 week observation if benign clinical picture (for ipsilateral COVID vaccination-related adenopathy, observation for 12 or more weeks is recommended)⁴. Follow-up imaging with ultrasound can be obtained if there is a significant risk of metastatic adenopathy (e.g., breast, head and neck, upper extremity/trunk melanoma or lymphoma⁵)
 - If axillary adenopathy is unchanged, then consider additional follow up 6 months after initial presentation⁴
 - Ultrasound directed core needle biopsy or surgical excisional biopsy of the most abnormal lymph node if condition persists, or malignancy is suspected, or surgical excisional biopsy if core needle biopsy results are non-diagnostic.
 - No advanced imaging indicated.
- Generalized axillary lymphadenopathy:
 - Axillary US (CPT® 76882)
 - Initial evaluation of any axillary mass or enlarged node
 - Ultrasound directed core needle biopsy or surgical excisional biopsy of the most abnormal lymph node if condition persists, if malignancy is suspected, or surgical excisional biopsy if core needle biopsy results are non-diagnostic.
 - Diagnostic work-up, including serological tests, for systemic diseases
 - See **Non-Hodgkin Lymphomas (ONC-27)** in the Oncology Imaging Guidelines.
- Occult Primary Cancer in axillary lymph node(s):
 - See **Metastatic Cancer, Carcinoma of Unknown Primary Site, and Other Types of Cancer (ONC-31)** in the Oncology Imaging Guidelines.

Background and Supporting Information

- Adenocarcinoma is the most common histology, with breast cancer seen most often; non-palpable breast cancer and axillary metastases accounts for less than 0.5% of all breast cancers. Carcinomas of the lung, thyroid, stomach, colon, rectum, and pancreas have the potential to spread to axillary lymph nodes, but these metastases are rarely the first manifestations of disease.
- COVID-19 vaccine-related unilateral axillary adenopathy has been well documented to occur in 12% of recipients after the first dose and up to 16% after the second dose.¹ In some series the incidence has been as high as 53%.² Adenopathy usually develops within the first few days after vaccination and lasts a mean of 10 days. However, 29% had lymphadenopathy which persisted >6 weeks.³ PET-CT can provide false positive results of unilateral axillary adenopathy up to 7-10 weeks post vaccination. Due to these concerns, in individuals with cancer history it is recommended that the vaccination be provided in the contralateral arm, especially in case of unilateral breast cancer.
- The Society for Breast Imaging (SBI) recommends that for unilateral axillary adenopathy on screening exams who received a recent COVID-19 vaccination in the ipsilateral upper extremity, a follow up interval of 12 or more weeks is recommended. If axillary adenopathy persists after short term follow up, then consider lymph node sampling to exclude breast and non-breast malignancy.⁴ Imaging for urgent cancer related clinical indication should not be delayed in relationship to COVID vaccine timing. For routine surveillance, screening and similar non-urgent indications, postponement of imaging for at least 6 weeks after vaccinations should be considered.⁵ However, the SBI no longer recommends delaying screening mammograms around COVID-19 vaccinations.^{4, 5}

Mediastinal Lymphadenopathy (CH-2.3)

CH.LA.0002.3.A

v2.0.2024

- CT Chest with contrast (CPT® 71260) if mediastinal abnormalities are detected on a chest x-ray (over read by a radiologist), other non-dedicated advanced chest imaging, or clarification of mediastinal abnormalities on a non-contrast CT Chest.
 - Follow-up CT Chest (CPT® 71260) after 3-6 months if:
 - Enlarged lymph nodes, ≥ 15 mm, are in the mediastinum with no other thoracic abnormalities; and
 - Low risk or no clinical suspicion for malignancy.
 - Thereafter, stability or decreasing size, does not require further advanced imaging.
 - Further evaluations:
 - Lymph node biopsy (see methods below) should be considered for:
 - Persistent or increasing lymphadenopathy on follow-up CT Chest; or
 - Suspected malignancy.
 - See **Non-Hodgkin Lymphomas (ONC-27)** and/or **Hodgkin Lymphoma (ONC-28)** in the Oncology Imaging Guidelines for suspicion of Lymphoma
- PET/CT (CPT® 78815) can be considered for enlarged lymph nodes, ≥ 15 mm with no explainable disease or increasing lymph node size on follow-up CT Chest

Background and Supporting Information

- Incidentally detected lymph nodes < 15 mm (in short axis) in individuals with no other findings do not require further evaluation.
- Most benign nodes have smooth and well-defined borders, show uniform and homogeneous attenuation, and demonstrate a central fatty hilum
- Explainable disease such as emphysema, interstitial lung disease, sarcoidosis, cardiac disease.
- Unexplained causes, consider lymphoma, undiagnosed metastatic disease, including testicular carcinoma in young male, and infection.
- Lymphadenopathy from neoplasms as well as from benign sources of inflammation can result in a positive PET scan. Therefore, the use of PET may not be helpful prior to histologic diagnosis.
- Less invasive methods of mediastinal biopsies are CT or ultrasound directed percutaneous biopsy, transbronchial biopsy, transbronchial biopsy using endobronchial ultrasound, and endoscopic ultrasound-guided FNA.
- More invasive and traditional methods are mediastinoscopy or thoracoscopy/thoracotomy.

References (CH-2)

v2.0.2024

1. Mehta N, Sales RM, Babagbemi K, et al. Unilateral axillary Adenopathy in the setting of COVID-19 vaccine. *Clin Imaging*. 2021;75:12-15. doi:10.1016/j.clinimag.2021.01.016
2. Eifer M, Tau N, Alhoubani Y, et al. COVID-19 mRNA Vaccination: Age and Immune Status and Its Association with Axillary Lymph Node PET/CT Uptake. *J Nucl Med*. 2022;63(1):134-139. doi:10.2967/jnumed.121.262194
3. Garreffa E, Hamad A, O'Sullivan CC, et al. Regional lymphadenopathy following COVID-19 vaccination: Literature review and considerations for patient management in breast cancer care. *Eur J Cancer*. 2021;159:38-51. doi:10.1016/j.ejca.2021.09.033
4. Grimm L, Destounis S, Dogan B, et al. Revised SBI Recommendations for the Management of Axillary Adenopathy in Patients with Recent COVID-19 Vaccination Society of Breast Imaging Patient Care and Delivery Committee. https://assets-002.noviams.com/novi-file-uploads/sbi/pdfs-and-documents/policy-and-position-statements/2022/SBI-recommendations-for-managing-axillary-adenopathy-post-COVID-vaccination_updatedFeb2022.pdf.
5. Becker AS, Perez-Johnston R, Chikarmane SA, et al. Multidisciplinary Recommendations Regarding Post-Vaccine Adenopathy and Radiologic Imaging: *Radiology* Scientific Expert Panel. *Radiology*. 2021;300(2):E323-E327. doi:10.1148/radiol.2021210436
6. van Overhagen H, Brakel K, Heijnenbroek MW, et al. Metastases in supraclavicular lymph nodes in lung cancer: assessment with palpation, US, and CT. *Radiology*. 2004;232(1):75-80. doi:10.1148/radiol.2321030663
7. Lehman CD, DeMartini W, Anderson BO, Edge SB. Indications for breast MRI in the patient with newly diagnosed breast cancer. *J Natl Compr Canc Netw*. 2009;7(2):193-201. doi:10.6004/jnccn.2009.0013
8. Yamaguchi H, Ishikawa M, Hatanaka K, Uekusa T, Ishimaru M, Nagawa H. Occult breast cancer presenting as axillary metastases. *Breast*. 2006;15(2):259-262. doi:10.1016/j.breast.2005.04.018
9. Stigt JA, Boers JE, Oostdijk AH, van den Berg JW, Groen HJ. Mediastinal incidentalomas. *J Thorac Oncol*. 2011;6(8):1345-1349. doi:10.1097/JTO.0b013e31821d41c8
10. English BS, Ray CE, Chang JY, et al. Expert Panel on Interventional Radiology. ACR Appropriateness Criteria® Radiologic Management of Thoracic Nodules and Masses. Am Coll Radiol (ACR); Date of Origin: 1996. Revised: 2015. <https://acsearch.acr.org/docs/69343/Narrative/>
11. Munden RF, Carter BW, Chiles C, et al. Managing Incidental Findings on Thoracic CT: Mediastinal and Cardiovascular Findings. A White Paper of the ACR Incidental Findings Committee. *J Am Coll Radiol*. 2018;15(8):1087-1096. doi:10.1016/j.jacr.2018.04.029

Cough (CH-3)

Guideline

Cough (CH-3.1)

References (CH-3)

Cough (CH-3.1)

CH.CH.0003.1.A

v2.0.2024

- Initial evaluation should include a recent chest x-ray after the current episode of cough started or changed.^{1,2}
 - In addition all medications known to cause coughing (e.g. ACE inhibitors, Sitagliptin) should be discontinued.^{1,2,3}
- CT Chest (either with contrast [CPT[®] 71260] or without contrast [CPT[®] 71250]), if the initial chest x-ray is without abnormalities and all medications known to cause coughing have been discontinued, for the following:
 - Non-Smoker cough after the following sequence for a total 3-week trial and investigation after ALL of the following:⁴
 - Antihistamine and decongestant or intranasal glucocorticoid treatment.^{1,2,7}
 - Spirometry and/or pulmonary function tests (PFT's).^{1,4,8}
 - Empiric trial of corticosteroids (oral or inhaled) and/or leukotriene receptor antagonist (e.g. Montelukast).^{1,2,4,8,9}
 - Treatment of gastroesophageal reflux disease (GERD).^{1,2,4,8,9}
 - See **Sinus and Facial Imaging (HD-29.1)** in the Head Imaging Guidelines.
 - Current or past cigarette smokers with either⁴:
 - New cough lasting greater than 2 weeks.
 - Changed chronic cough in worsening frequency or character
 - See **Hemoptysis (CH-6.1)**
 - For any abnormalities present on the initial chest x-ray, advanced chest imaging can be performed according to the relevant Chest Imaging Guidelines section.¹
- CT Maxillofacial without contrast (CPT[®] 70486) or CT Sinus, limited without contrast (CPT[®] 76380) is indicated in those with suspicion of Upper Airway Cough Syndrome (UACS) in the following:^{4,5,6}
 - Clinical criteria for chronic rhinosinusitis (CRS) or acute/recurrent rhinosinusitis are met, as per Sinus and Facial Imaging (HD 29.1); **OR ALL** of the following:
 - At least a one week trial of daily antihistamine/decongestant
 - Initial evaluation with a chest x-ray and/or CT Chest after the current episode of cough started or changed
 - All medications known to cause cough have been discontinued

Background and Supporting Information

- The resolution of cough usually will occur at a median time of 26 days of stopping use of the angiotensin-converting enzyme (ACE) inhibitor drug.² Smoking cessation is “almost always effective” in resolving cough in smoker.²
- Cough after URI (Upper Respiratory Infection) can typically last beyond 2-3 weeks.³

- Objective evidence of classic asthmatic cough conventionally requires some evidence of variable airflow obstruction such as peak flow variability, or reversibility to bronchodilator of >12-15%.⁸
- In adult patients with chronic cough suspected to be due to reflux-cough syndrome, it is recommended that treatment include (1) diet modification to promote weight loss in overweight or obese patients; (2) head of bed elevation and avoiding meals within 3 hours of bedtime; and (3) in patients who report heartburn or regurgitation, PPI's, H-2 receptor antagonists, alginate or antacid therapy sufficient to control these symptoms.⁹

References (CH-3)

v2.0.2024

1. Gibson P, Wang G, McGarvey L, et al. Treatment of Unexplained Chronic Cough: CHEST Guideline and Expert Panel Report. *Chest*. 2016;149(1):27-44. doi:10.1378/chest.15-1496
2. Pratter MR, Brightling CE, Boulet LP, Irwin RS. An empiric integrative approach to the management of cough: ACCP evidence-based clinical practice guidelines. *Chest*. 2006;129(1 Suppl):222S-231S. doi:10.1378/chest.129.1_suppl.222S
3. Ebell MH, Lundgren J, Youngpairoj S. How long does a cough last? Comparing patients' expectations with data from a systematic review of the literature. *Ann Fam Med*. 2013;11(1):5-13. doi:10.1370/afm.1430
4. Irwin RS, French CL, Chang AB, Altman KW; CHEST Expert Cough Panel*. Classification of Cough as a Symptom in Adults and Management Algorithms: CHEST Guideline and Expert Panel Report. *Chest*. 2018;153(1):196-209. doi:10.1016/j.chest.2017.10.016
5. Pratter MR. Chronic upper airway cough syndrome secondary to rhinosinus diseases (previously referred to as postnasal drip syndrome): ACCP evidence-based clinical practice guidelines. *Chest*. 2006;129(1 Suppl):63S-71S. doi:10.1378/chest.129.1_suppl.63S
6. Donaldson AM. Upper Airway Cough Syndrome. *Otolaryngol Clin North Am*. 2023;56(1):147-155. doi:10.1016/j.otc.2022.09.011
7. Dykewicz MS, Wallace DV, Amrol DJ, et al. Rhinitis 2020: A practice parameter update. *J Allergy Clin Immunol*. 2020;146(4):721-767. doi:10.1016/j.jaci.2020.07.007
8. Morice AH, Millqvist E, Bieksiene K, et al. ERS guidelines on the diagnosis and treatment of chronic cough in adults and children [published correction appears in *Eur Respir J*. 2020 Nov 19;56(5):]. *Eur Respir J*. 2020;55(1):1901136. Published 2020 Jan 2. doi:10.1183/13993003.01136-2019
9. Kahrilas PJ, Altman KW, Chang AB, et al. Chronic Cough Due to Gastroesophageal Reflux in Adults: CHEST Guideline and Expert Panel Report. *Chest*. 2016;150(6):1341-1360. doi:10.1016/j.chest.2016.08.1458

Non-Cardiac Chest Pain (CH-4)

Guideline

Non-Cardiac Chest Pain (CH-4.0)

Non-Cardiac Chest Pain – Imaging (CH-4.1)

Costochondritis/Other Musculoskeletal Chest Wall Syndrome (CH-4.2)

References (CH-4)

Non-Cardiac Chest Pain (CH-4.0)

CH.CP.0004.0.A

v2.0.2024

- See the following guidelines:
 - **Pulmonary Embolism (PE) (CH-25.1)**
 - **General Guidelines (CD-1)** in the Cardiac Imaging Guidelines
- “Evidence is not conclusive whether Triple-rule-out CT (CAD, PE, and AD) will improve efficiency of patient management” with acute chest pain.¹
- MRI is not supported in the evaluation of chest pain.

Non-Cardiac Chest Pain – Imaging (CH-4.1)

CH.CP.0004.1.A

v2.0.2024

- Initial evaluation should include a chest x-ray.
 - CT Chest with contrast (CPT® 71260) or CTA Chest (CPT® 71275) if x-ray is abnormal. See **Pneumonia (CH-13.1)**
- Sub-Sternal Non-Cardiac Chest Pain:
 - If x-ray is normal and the chest pain is substernal, the individual should undergo evaluation of other possible causes of pain prior to advanced imaging (CT Chest with contrast or CTA Chest) including:^{1,2,3}
 - Cardiac evaluation^{1,2} (See **General Guidelines (CD-1)** in the Cardiac Imaging Guidelines)
 - GI any ONE of the following since GERD is the cause in almost 60%:
 - Trial of anti-reflux medication, or pH probe, or esophageal manometry¹ or
 - Barium swallow or endoscopy
 - Pulmonary Function Test (PFT's)^{1,2}
 - CT Chest with contrast (CPT® 71260) if persistent:
 - The initial chest x-ray reveals no abnormalities with known Sickle cell disease²
- Non-Cardiac Chest Pain, other than Sub-Sternal:
 - If x-ray is normal and the chest pain is in a location other than substernal:
 - CT Chest with (CPT® 71260) or without (CPT® 71250) contrast and/or bone scan for:
 - Known or suspected malignancy, including individuals with chest pain associated with cough and weight loss
 - CT Chest with (CPT® 71260) or without (CPT® 71250) contrast for:
 - Suspected infectious or inflammatory condition
 - History of prior chest intervention (surgery, Radiation Therapy)
 - MRI Chest without and with contrast (CPT® 71552) for:
 - Necrotizing fasciitis
 - Surgical planning prior to debridement procedures

Costochondritis/Other Musculoskeletal Chest Wall Syndrome (CH-4.2)

CH.CP.0004.2.A

v2.0.2024

- Costochondritis or other suggested musculoskeletal chest wall syndrome does not require advanced imaging (CT or MRI) unless it meets other criteria in these guidelines.

Background and Supporting Information

- Chest x-ray could identify pneumothorax, pneumomediastinum, fractured ribs, acute and chronic infections, and malignancies.¹
- Costochondritis can be readily diagnosed with palpation tenderness and/or hooking maneuver and imaging is non-specific.³

References (CH-4)

v2.0.2024

1. Hoffmann U, Akers SR, Brown RK, et al. ACR Appropriateness Criteria® Acute Nonspecific Chest Pain-Low Probability of Coronary Artery Disease [published correction appears in *J Am Coll Radiol*. 2016 Feb;13(2):231]. *J Am Coll Radiol*. 2015;12(12 Pt A):1266-1271. doi:10.1016/j.jacr.2015.09.004
2. Expert Panel on Cardiac Imaging: Shah AB, Kirsch J, et al. ACR Appropriateness Criteria® Chronic Chest Pain-Noncardiac Etiology Unlikely-Low to Intermediate Probability of Coronary Artery Disease. *J Am Coll Radiol*. 2018;15(11S):S283-S290. doi:10.1016/j.jacr.2018.09.021
3. Proulx A, Zryd TW. Costochondritis: diagnosis and treatment. *Am Fam Physician*. 2009;80(6):617-620.
4. Expert Panel on Thoracic Imaging, Stowell JT, Walker CM, et al. ACR Appropriateness Criteria® Nontraumatic Chest Wall Pain. *J Am Coll Radiol*. 2021;18(11S):S394-S405. doi:10.1016/j.jacr.2021.08.004

Dyspnea/Shortness of Breath (CH-5)

Guideline

Dyspnea/Shortness of Breath (CH-5.1)

Pre-Operative Assessment (CH-5.2)

Post Endobronchial Valve (EBV) Placement (CH-5.3)

References (CH-5)

Dyspnea/Shortness of Breath (CH-5.1)

CH.SB.0005.1.A
v2.0.2024

- Initial evaluation should include a recent chest x-ray.^{1,2}
 - CT Chest without contrast (CPT® 71250) if x-ray is abnormal.^{1,2}
 - CT Chest without contrast (CPT® 71250, including HRCT), or CT Chest with contrast (CPT® 71260) if the initial chest x-ray is indeterminate and the following evaluations have been conducted and are indeterminate:²
 - ECG, echocardiogram or stress testing,² and
 - Pulse oximetry and pulmonary function studies (PFT's)²
- If pulmonary embolus (PE) is suspected, See **Pulmonary Embolism (PE) (CH-25)**.

Background and Supporting Information

- Dyspnea is the subjective experience of breathing discomfort.

Pre-Operative Assessment (CH-5.2)

CH.SB.0005.2.A
v2.0.2024

- For pre-operative assessment prior to a planned segmental, lobar or lung removal,^{3,4} as well as for pre-interventional assessment prior to a planned endobronchial valve (e.g. Zephyr valve) placement, the following can be considered:
 - “Split Function Studies” (CPT® 78597-Quantitative Differential Pulmonary Perfusion, Including Imaging When Performed or CPT® 78598-Quantitative Differential Pulmonary Perfusion and Ventilation (e.g., Aerosol or Gas), Including Imaging When Performed) or SPECT/CT (CPT® 78830)
AND/OR
 - CT Chest (CPT® 71250, CPT® 71260 or CPT® 71270) for pre-interventional procedure assessment prior to a planned endobronchial valve (e.g. Zephyr Valve) placement.

Post Endobronchial Valve (EBV) Placement (CH-5.3)

CH.SB.0005.3.A

v2.0.2024

- Suspected Post EBV Complication:
 - Initial evaluation should include a recent chest x-ray
 - CT Chest without contrast (CPT® 71250) or CT Chest with contrast (CPT® 71260) is appropriate for:
 - Acute loss of benefit, lack of initial benefit, increased dyspnea, sudden chest pain, increased cough, suspected valve malposition/migration, or to evaluate target lobe volume reduction

References (CH-5)

v2.0.2024

1. Expert Panel on Thoracic Imaging.; McComb BL, Ravenel JG, et al. ACR Appropriateness Criteria® Chronic Dyspnea-Noncardiovascular Origin. *J Am Coll Radiol*. 2018;15(11S):S291-S301. doi:10.1016/j.jacr.2018.09.015
2. Expert Panel on Cardiac Imaging.; Vogel-Claussen J, Elshafee ASM, et al. ACR Appropriateness Criteria® Dyspnea-Suspected Cardiac Origin. *J Am Coll Radiol*. 2017;14(5S):S127-S137. doi:10.1016/j.jacr.2017.01.032
3. Morton K. Chapter 4. In: Morton K, eds. *Diagnostic Imaging: Nuclear Medicine*. Amirsys;2007:2-15.
4. Thrall JH, Ziessman HA. *Nuclear Medicine: The Requisites*. 2nd ed. Mosby; 2001:145-165.
5. Scirba FC, Ernst A, Herth FJ, et al. A randomized study of endobronchial valves for advanced emphysema. *N Engl J Med*. 2010;363(13):1233-1244. doi:10.1056/NEJMoa0900928
6. Davey C, Zoumot Z, Jordan S, et al. Bronchoscopic lung volume reduction with endobronchial valves for patients with heterogeneous emphysema and intact interlobar fissures (the BeLieVeR-HIFi study): a randomised controlled trial. *Lancet*. 2015;386(9998):1066-1073. doi:10.1016/S0140-6736(15)60001-0
7. Klooster K, ten Hacken NH, Hartman JE, Kerstjens HA, van Rikxoort EM, Slebos DJ. Endobronchial Valves for Emphysema without Interlobar Collateral Ventilation. *N Engl J Med*. 2015;373(24):2325-2335. doi:10.1056/NEJMoa1507807
8. Kristiansen JF, Perch M, Iversen M, Krakauer M, Mortensen J. Lobar Quantification by Ventilation/Perfusion SPECT/CT in Patients with Severe Emphysema Undergoing Lung Volume Reduction with Endobronchial Valves. *Respiration*. 2019;98(3):230-238. doi:10.1159/000500407
9. Koster TD, Klooster K, Ten Hacken NHT, van Dijk M, Slebos DJ. Endobronchial valve therapy for severe emphysema: an overview of valve-related complications and its management. *Expert Rev Respir Med*. 2020;14(12):1235-1247. doi:10.1080/17476348.2020.1813571
10. Slebos DJ, Shah PL, Herth FJ, Valipour A. Endobronchial Valves for Endoscopic Lung Volume Reduction: Best Practice Recommendations from Expert Panel on Endoscopic Lung Volume Reduction. *Respiration*. 2017;93(2):138-150. doi:10.1159/000453588

Hemoptysis (CH-6)

Guideline

Hemoptysis (CH-6.1)

Reference (CH-6)

Hemoptysis (CH-6.1)

CH.HS.0006.1.A
v2.0.2024

- Following a chest x-ray performed after hemoptysis started or worsened the following is indicated:
 - CT Chest with contrast (CPT® 71260) or CTA Chest (CPT® 71275)
- For recurrent hemoptysis, (hemoptysis occurring after medical therapy or embolization), the following is indicated:
 - CTA Chest (CPT® 71275)

NOTE:

- CT Chest without contrast, (CPT® 71250), is only warranted in individuals with poor renal function or life-threatening contrast allergy.
- There is no data to support the use of CT Chest without and with contrast, (CPT® 71270), in the diagnosis of hemoptysis.

Background and Supporting Information

- Chest x-ray has been shown to predict the side and cause of bleeding in up to 82% of individuals and can be abnormal in up to 90% of cases. The most common cause of hemoptysis was acute bronchitis with the second most common cause as respiratory tract neoplasm. Bronchiectasis and tuberculosis were additional common causes

Reference (CH-6)

v2.0.2024

1. Expert Panel on Thoracic Imaging, Olsen KM, Manouchehr-Pour S, et al. ACR Appropriateness Criteria® Hemoptysis. *J Am Coll Radiol*. 2020;17(5S):S148-S159. doi:10.1016/j.jacr.2020.01.043

Bronchiectasis (CH-7)

Guideline

Bronchiectasis (CH-7.1)

Adult Cystic Fibrosis (CH-7.2)

References (CH-7)

Bronchiectasis (CH-7.1)

CH.BR.0007.1.A

v2.0.2024

- High resolution CT Chest (HRCT) without contrast (CPT® 71250) for ANY of the following:^{4,5}
 - To confirm suspected diagnosis of bronchiectasis after an initial x-ray.^{1,2}
 - For known bronchiectasis with worsening symptoms or worsening PFT's.²
 - For hemoptysis with known or suspected bronchiectasis.³

Adult Cystic Fibrosis (CH-7.2)

CH.BR.0007.2.A

v2.0.2024

- CT Chest without contrast (CPT® 71250) or with contrast (CPT® 71260) is indicated for the following (without initial Chest x-ray):
 - Suspected or initial diagnosis of Cystic Fibrosis
 - Biennially, (every 2 years), for routine surveillance
 - Persistent respiratory symptoms with reduced lung function despite therapy
 - Exacerbations when Chest x-ray is indeterminate
 - Hemoptysis
 - Suspected fungal pneumonia
 - Pre and post-lung transplant evaluation
- See **Bronchiectasis (CH-7.1)**

References (CH-7)

v2.0.2024

1. Schneebaum N, Blau H, Soferman R, et al. Use and yield of chest computed tomography in the diagnostic evaluation of pediatric lung disease. *Pediatrics*. 2009;124(2):472-479. doi:10.1542/peds.2008-2694
2. Rosen MJ. Chronic cough due to bronchiectasis: ACCP evidence-based clinical practice guidelines. *Chest*. 2006;129(1 Suppl):122S-131S. doi:10.1378/chest.129.1_suppl.122s
3. Pasteur MC, Bilton D, Hill AT; British Thoracic Society Bronchiectasis non-CF Guideline Group. British Thoracic Society guideline for non-CF bronchiectasis. *Thorax*. 2010;65 Suppl 1:i1-i58. doi:10.1136/thx.2010.136119
4. Expert Panel on Thoracic Imaging, Olsen KM, Manouchehr-Pour S, et al. ACR Appropriateness Criteria® Hemoptysis. *J Am Coll Radiol*. 2020;17(5S):S148-S159. doi:10.1016/j.jacr.2020.01.043
5. Hansell DM. Bronchiectasis. *Radiol Clin North Am*. 1998;36(1):107-128. doi:10.1016/s0033-8389(05)70009-9
6. Ciet P, Bertolo S, Ros M, et al. State-of-the-art review of lung imaging in cystic fibrosis with recommendations for pulmonologists and radiologists from the “iMAging managEment of cySTic fibROsis” (MAESTRO) consortium. *Eur Respir Rev*. 2022;31(163):210173. Published 2022 Mar 23. doi:10.1183/16000617.0173-2021
7. Averill S, Lubner MG, Menias CO, et al. Multisystem Imaging Findings of Cystic Fibrosis in Adults: Recognizing Typical and Atypical Patterns of Disease. *AJR Am J Roentgenol*. 2017;209(1):3-18. doi:10.2214/AJR.16.17462

Bronchitis (CH-8)

Guideline

Bronchitis (CH-8.1)

References (CH-8)

Bronchitis (CH-8.1)

CH.BH.0008.1.A
v2.0.2024

- Advanced imaging is not needed for bronchitis.^{1,2}
- Chest x-ray to determine if any abnormality is present.

References (CH-8)

v2.0.2024

1. Braman SS. Chronic cough due to acute bronchitis: ACCP evidence-based clinical practice guidelines. *Chest*. 2006;129(1 Suppl):95S-103S. doi:10.1378/chest.129.1_suppl.95s
2. *Eligible Population Key Components Assessment Diagnosis Treatment Education and Counseling Approved by MQIC Medical Directors.*; 2020.
http://www.mqic.org/pdf/mqic_management_of_uncomplicated_acute_bronchitis_in_adults_cpg.pdf

Asbestos Exposure (CH-9)

Guideline

Asbestos Exposure (CH-9.1)

References (CH-9)

Asbestos Exposure (CH-9.1)

CH.AE.0009.1.A
v2.0.2024

- Chest x-ray as radiographic screening for asbestos exposure.^{1,2}
 - Stable calcified pleural plaques on chest x-ray do not require advanced imaging of the chest.²
- CT Chest should not be used to screen populations at risk for asbestos-related diseases.²
- High resolution CT Chest (HRCT) (CPT® 71250) for ANY of the following:²
 - Any change seen on chest x-ray.
 - Progressive respiratory symptoms that may indicate the development or progression of asbestos related interstitial fibrosis.

Background and Supporting Information

- Asbestosis and asbestos-related diseases include: pleural effusion, pleural plaques, lung cancer, and malignant mesothelioma. The risk of developing mesothelioma increases with increasing intensity and duration of exposure.

References (CH-9)

v2.0.2024

1. OSHA, Occupational Safety and Health Standards, Medical surveillance guidelines for asbestos, 1910.1001 App H. https://www.osha.gov/pls/oshaweb/owadisp.show_document?p_table=standards&p_id=9995.
2. Banks DE, Shi R, McLarty J, et al. American College of Chest Physicians consensus statement on the respiratory health effects of asbestos. Results of a Delphi study. *Chest*. 2009;135(6):1619-1627. doi:10.1378/chest.08-1345
3. Agency for Toxic Substances and Disease Registry. Asbestos. Updated 2011. <https://www.atsdr.cdc.gov/substances/toxsubstance.asp?toxid=4>.

Chronic Obstructive Pulmonary Disease (COPD) (CH-10)

Guideline

COPD (CH-10.1)

References (CH-10)

COPD (CH-10.1)

CH.PD.0010.1.A

v2.0.2024

- Chest x-ray should be performed initially.
 - CT Chest without contrast (CPT® 71250) or CT Chest with contrast (CPT® 71260)^{1,2} can be performed if:
 - Emphysema is known or suspected and a pre-operative study for Lung Volume Reduction Surgery (LVRS) is being requested.¹ OR
 - Definitive diagnosis is not yet determined by PFT's, appropriate laboratory studies and chest x-ray and ONE of the following is suspected:
 - Bronchiectasis
 - Sarcoidosis
 - Emphysema
 - Pneumoconiosis
 - Idiopathic pulmonary fibrosis
 - Langerhans cell histiocytosis
 - Hypersensitivity pneumonitis
 - Bronchiolitis obliterans
 - Lipoid pneumonia
 - Drug toxicity
 - Lymphangitic cancer²
 - Alpha-1-Antitrypsin Deficiency
- Lung cancer screening is discussed in the following guideline:
 - See “Screening Indications” in **Lung Cancer Screening (CH-33)**
- Pre-interventional lung procedure assessment prior to a planned endobronchial valve (e.g. Zephyr valve) placement
 - See **Pre-Operative Assessment (CH-5.2)**

Background and Supporting Information

- COPD includes asthmatic bronchitis, chronic bronchitis, and emphysema. COPD is airflow reduction (FEV1/FVC ratio <0.7 or FEV1 <80% predicted) in the presence of respiratory symptoms, such as dyspnea. Advanced chest imaging is not typically indicated in COPD exacerbation, which is an acute change in baseline dyspnea, cough, and/or sputum beyond normal day-to-day variations.²

References (CH-10)

v2.0.2024

1. Expert Panel on Thoracic Imaging; McComb BL, Ravenel JG, et al. ACR Appropriateness Criteria® Chronic Dyspnea-Noncardiovascular Origin. *J Am Coll Radiol*. 2018;15(11S):S291-S301. doi:10.1016/j.jacr.2018.09.015
2. Austin JH. Pulmonary emphysema: imaging assessment of lung volume reduction surgery [published correction appears in *Radiology* 1999 Sep;212(3):912]. *Radiology*. 1999;212(1):1-3. doi:10.1148/radiology.212.1.r99jl521

Interstitial Disease (CH-11)

Guideline

Interstitial Lung Disease (ILD)/Diffuse Lung Disease (DLD) (CH-11.1)
E-cigarette, or Vaping, Product Use–Associated Lung Injury (EVALI)
(CH-11.2)
References (CH-11)

Interstitial Lung Disease (ILD)/Diffuse Lung Disease (DLD) (CH-11.1)

CH.ID.0011.1.A

v2.0.2024

- High resolution CT Chest (HRCT) without contrast (CPT[®] 71250) is the diagnostic modality of choice to evaluate or CT Chest with contrast (CPT[®] 71260)¹⁰ (See **Background and Supporting Information**) for:
 - Interstitial changes or diffuse parenchymal changes identified on other imaging (including chest x-ray) in individuals with pulmonary symptoms and abnormal pulmonary function studies (PFT's) (See **Dyspnea/Shortness of Breath (CH-5.1)**)¹⁻⁶
 - In individuals with pulmonary symptoms and abnormal pulmonary function studies (PFT's) and normal chest x-ray with high clinical suspicion for ILD or DLD, including but not limited to entities such as Hypersensitivity Pneumonitis, Cryptogenic Organizing Pneumonia (COP, formally known as BOOP), and Eosinophilic Pneumonia, as chest x-ray can be normal in up to 10% of ILD^{8,9}
 - Initial imaging to identify interstitial disease with a connective tissue disease diagnosis, or significant exposures including (chest x-ray not required):
 - Rheumatoid arthritis
 - Scleroderma
 - Idiopathic inflammatory myopathies (polymyositis, dermatomyositis, inclusion body myositis)
 - Systemic lupus erythematosus
 - Sjögren's syndrome
 - Mixed connective tissue disease
 - Significant exposure and concern for:
 - Asbestosis
 - Silicosis
 - Coal miner's lung disease^{1-6,11}
 - At any time for detection of Progressive Pulmonary Fibrosis (PPF), in individuals with ILD of known or unknown etiology, defined by at least one of the following:¹²
 - New or worsening respiratory symptoms
 - Worsening PFT's, defined as decline of either:
 - FVC of 5% or greater within the past year
 - DLCO of 10% or greater within the past year
 - Once a year in individuals with known pulmonary fibrosis if needed for:¹⁰
 - Serial examination for improvements in diagnostic accuracy, or
 - Evaluation of disease reversibility, stability, or progression.
- Concern for interstitial lung disease post-COVID See **Coronavirus Disease 2019 (COVID-19) (CH-13.2)**

Background and Supporting Information

- DLD refers to diffuse parenchymal lung diseases or interstitial lung diseases. There are a multitude of pathologies that demonstrate involvement of the alveola, airways, or both, in addition to the pulmonary interstitium. A single term of ILD would not fully address the entities that are mostly parenchymal in nature, hence the term Diffuse Lung Disease is more technically correct. Both terms are included here for convenience and recognition.
- There is no relevant literature to support the use of CT with IV contrast for initial or follow-up imaging of ILD; however, IV contrast may be of use in evaluation of alternative diagnoses with overlapping clinical features or conditions that also involve the pleura, mediastinum, and pulmonary vessels.
- Progression of fibrosis is typically assessed visually, relying on the percentage of lung volume containing fibrotic features in the upper, mid, and lower lung zones. An increased extent of fibrotic features denotes progression. These may include increased traction bronchiectasis and bronchiolectasis, new ground-glass opacity with traction bronchiectasis, new fine reticulation, increased coarseness of reticular abnormality, new or increased honeycombing, and increased lobar volume loss.¹²

E-cigarette, or Vaping, Product Use– Associated Lung Injury (EVALI) (CH- 11.2)

CH.ID.0011.2.A
v2.0.2024

- CT Chest with or without contrast (CPT® 71250 or CPT® 71260) if EVALI is suspected.⁷

References (CH-11)

v2.0.2024

1. Expert Panel on Thoracic Imaging, Cox CW, Chung JH, et al. ACR Appropriateness Criteria® Occupational Lung Diseases. *J Am Coll Radiol*. 2020;17(5S):S188-S197. doi:10.1016/j.jacr.2020.01.022
2. Expert Panel on Thoracic Imaging:, McComb BL, Ravenel JG, et al. ACR Appropriateness Criteria® Chronic Dyspnea-Noncardiovascular Origin. *J Am Coll Radiol*. 2018;15(11S):S291-S301. doi:10.1016/j.jacr.2018.09.015
3. Misumi S, Lynch DA. Idiopathic pulmonary fibrosis/usual interstitial pneumonia: imaging diagnosis, spectrum of abnormalities, and temporal progression. *Proc Am Thorac Soc*. 2006;3(4):307-314. doi:10.1513/pats.200602-018TK
4. Bradley B, Branley HM, Egan JJ, et al. Interstitial lung disease guideline: the British Thoracic Society in collaboration with the Thoracic Society of Australia and New Zealand and the Irish Thoracic Society [published correction appears in *Thorax*. 2008 Nov;63(11):1029. multiple author names added]. *Thorax*. 2008;63 Suppl 5:v1-v58. doi:10.1136/thx.2008.101691
5. Dempsey OJ, Kerr KM, Remmen H, Denison AR. How to investigate a patient with suspected interstitial lung disease. *BMJ*. 2010;340:c2843. Published 2010 Jun 9. doi:10.1136/bmj.c2843
6. Castellino FV, Varga J. Interstitial lung disease in connective tissue diseases: evolving concepts of pathogenesis and management. *Arthritis Res Ther*. 2010;12(4):213. doi:10.1186/ar3097
7. https://www.cdc.gov/mmwr/volumes/68/wr/mm6846e2.htm?s_cid=mm6846e2_w.
8. Epler GR, McLoud TC, Gaensler EA, Mikus JP, Carrington CB. Normal chest roentgenograms in chronic diffuse infiltrative lung disease. *N Engl J Med*. 1978;298(17):934-939. doi:10.1056/NEJM197804272981703
9. Raghu G, Remy-Jardin M, Ryerson CJ, et al. Diagnosis of Hypersensitivity Pneumonitis in Adults. An Official ATS/JRS/ALAT Clinical Practice Guideline [published correction appears in *Am J Respir Crit Care Med*. 2021 Jan 1;203(1):150-151] [published correction appears in *Am J Respir Crit Care Med*. 2022 Aug 15;206(4):518]. *Am J Respir Crit Care Med*. 2020;202(3):e36-e69. doi:10.1164/rccm.202005-2032ST
10. Expert Panel on Thoracic Imaging:, Hobbs SB, Chung JH, et al. ACR Appropriateness Criteria® Diffuse Lung Disease. *J Am Coll Radiol*. 2021;18(11S):S320-S329. doi:10.1016/j.jacr.2021.08.008
11. Mathai SC, Danoff SK. Management of interstitial lung disease associated with connective tissue disease. *BMJ*. 2016;352:h6819. Published 2016 Feb 24. doi:10.1136/bmj.h6819
12. Raghu G, Remy-Jardin M, Richeldi L, et al. Idiopathic Pulmonary Fibrosis (an Update) and Progressive Pulmonary Fibrosis in Adults: An Official ATS/ERS/JRS/ALAT Clinical Practice Guideline. *Am J Respir Crit Care Med*. 2022;205(9):e18-e47. doi:10.1164/rccm.202202-0399ST

Pneumonia and Coronavirus Disease 2019 (COVID-19) (CH-13)

Guideline

Pneumonia (CH-13.1)

Coronavirus Disease 2019 (COVID-19) (CH-13.2)

References (CH-13)

Pneumonia (CH-13.1)

CH.PN.0013.1.A

v2.0.2024

- Chest x-ray should be performed initially in all individuals with suspected pneumonia, prior to considering advanced imaging.^{1, 2}
 - CT Chest without or with contrast (CPT[®] 71250 or CPT[®] 71260) if initial or repeat chest x-ray findings reveal:
 - Complication of pneumonia (e.g. abscess, effusion, hypoxemia, respiratory distress, necrotizing pneumonia, pneumothorax).^{1, 2}
 - Possible lung mass associated with the infiltrate.²
- CT Chest without or with contrast (CPT[®] 71250 or CPT[®] 71260) for immunocompromised individuals with any of the following:¹⁵
 - High suspicion for pneumonia despite equivocal or negative CXR
 - Persistent radiographic abnormalities
 - Multiple or diffuse opacities or nodules

Coronavirus Disease 2019 (COVID-19) (CH-13.2)

CH.PN.0013.2.A

v2.0.2024

- CT Chest without contrast (CPT®71250), or with contrast (CPT®71260) in the following clinical situations:
 - Imaging for initial diagnosis:
 - Symptomatic COVID-19 positive individuals with underlying comorbidities (including but not limited to age >65 years, chronic lung disease, current or former smoker, chronic kidney disease, chronic liver disease, dementia, diabetes, Down’s syndrome, HIV or other primary, secondary or acquired immunodeficiency, mood disorders, BMI ≥30, pregnancy, solid organ or blood stem cell transplant, cerebrovascular disease, substance use disorder, tuberculosis, cardiovascular disease, malignancy, bronchopulmonary dysplasia, chronic infections, or immunocompromised state). See CDC’s list of higher risk for severe COVID for additional information: <https://www.cdc.gov/coronavirus/2019-ncov/need-extra-precautions/people-with-medical-conditions.html>
 - Moderate to severe symptomatic individuals with evidence of significant pulmonary dysfunction or damage (e.g., hypoxemia, moderate-to-severe dyspnea), suspected of having COVID-19, regardless of COVID-19 test results or when viral testing is not available.
 - Thromboembolic complications including pulmonary embolism, stroke and mesenteric ischemia are recognized complications of COVID-19. See **Pulmonary Embolism (CH-25.1)**, **Mesenteric Ischemia (AB-6.1)** in the Abdomen Imaging Guidelines, and **Stroke/TIA (HD-21.1)** in the Head Imaging Guidelines for appropriate imaging guidance.
 - Other systemic complications are being recognized as medical knowledge about this condition evolves. Imaging for possible COVID-19 complications should be managed by the appropriate condition based guidelines.
 - Imaging after initial diagnosis:
 - Imaging in the following clinical circumstances:
 - If there is significant worsening of symptoms in a COVID-19 positive individual and imaging will be used to modify individual management.
 - A recovered COVID-19 positive individual with significant residual functional impairment and/or persistence hypoxemia.
 - Symptomatic post-COVID individuals with concern for interstitial lung disease including organizing pneumonia imaging can be considered pre and post treatment.¹¹

Background and Supporting Information

- The role of advanced imaging in the diagnosis and management of COVID-19 is very dynamic in this rapidly evolving condition.
- Findings on both Chest X-ray and CT Chest are non-specific. Chest X-rays may show patchy opacities with lower lung predominance. CT may show peripheral multifocal ground glass opacities with lower lung predominance. However, a significant portion of cases have opacities without a clear or specific distribution.^{3,4,6} A reverse halo sign or other findings of organizing pneumonia may be seen later during the course of illness. Atypical findings include isolated lobar or segmental consolidation without ground glass opacities, discrete small centrilobular ("tree-in-bud") nodules, pleural effusion.⁸
 - Pediatric individuals may have less pronounced imaging findings than adults.
- CT Chest abnormalities are common 3 months after discharge in adults who have been hospitalized for COVID-19 and are associated with more severe acute disease. Fibrosis was seen in a minority of people.^{13,14} Most people re-imaged at one year showed radiologic improvement.¹³
- Major professional society guidelines to date:
 - The American College of Radiology (ACR) recommends that CT Chest should not be used for screening or as a first-line test to diagnose COVID-19.³
 - The Centers for Disease Control and Prevention (CDC) recommends viral testing as the only specific method of diagnosis.⁴
 - The CDC has stated that symptoms may appear 2-14 days after exposure to the virus. These symptoms may include:⁵
 - Fever or chills
 - Cough
 - Shortness of breath or difficulty breathing
 - Fatigue
 - Muscle or body aches
 - Headache
 - New loss of taste or smell
 - Sore throat
 - Congestion or runny nose
 - Nausea or vomiting
 - Diarrhea
 - The Fleischner Society consensus statement published on April 7, 2020, recommends against the use of imaging in individuals with suspected COVID-19 who are either asymptomatic or have only mild symptoms without evidence of significant pulmonary dysfunction or damage (e.g., absence of hypoxemia, no or mild dyspnea).⁶
 - According to The American Society of Transplantation, screening donors is based on methods below. Screening donors encompasses three different methods.⁷

- Epidemiologic screening for travel and potential exposures
- Screening for symptoms suggestive of COVID-19
- Viral testing (Nucleic acid testing of specimens)
- There is no current indication for screening asymptomatic donors with advanced imaging

References (CH-13)

v2.0.2024

1. Mandell LA, Wunderink RG, Anzueto A, et al. Infectious Diseases Society of America/American Thoracic Society consensus guidelines on the management of community-acquired pneumonia in adults. *Clin Infect Dis*. 2007;44 Suppl 2(Suppl 2):S27-S72. doi:10.1086/511159
2. Expert Panel on Thoracic Imaging:, Jokerst C, Chung JH, et al. ACR Appropriateness Criteria® Acute Respiratory Illness in Immunocompetent Patients. *J Am Coll Radiol*. 2018;15(11S):S240-S251. doi:10.1016/j.jacr.2018.09.012
3. American College of Radiology. ACR Recommendations for the use of Chest Radiography and Computed Tomography (CT) for Suspected COVID-19 Infection. [acr.org](https://www.acr.org/Advocacy-and-Economics/ACR-Position-Statements/Recommendations-for-Chest-Radiography-and-CT-for-Suspected-COVID19-Infection). Available at <https://www.acr.org/Advocacy-and-Economics/ACR-Position-Statements/Recommendations-for-Chest-Radiography-and-CT-for-Suspected-COVID19-Infection>. 3/22/2020
4. Evaluating and Testing Persons for Coronavirus Disease 2019 (COVID-19). Centers for Disease Control and Prevention. National Center for Immunization and Respiratory Diseases (NCIRD), Division of Viral Diseases. <https://www.cdc.gov/coronavirus/2019-ncov/symptoms-testing/testing.html>
5. Symptoms of Coronavirus. Centers for Disease Control and Prevention. National Center for Immunization and Respiratory Diseases (NCIRD), Division of Viral Diseases. Page last reviewed: May 13, 2020. <https://www.cdc.gov/coronavirus/2019-ncov/symptoms-testing/symptoms.html>
6. Foust AM, Phillips GS, Chu WC, et al. International Expert Consensus Statement on Chest Imaging in Pediatric COVID-19 Patient Management: Imaging Findings, Imaging Study Reporting and Imaging Study Recommendations. *Radiol Cardiothorac Imaging*. 2020;2(2):e200214. Published 2020 Apr 23. doi:10.1148/ryct.2020200214
7. Rubin GD, Ryerson CJ, Haramati LB, et al. The Role of Chest Imaging in Patient Management During the COVID-19 Pandemic: A Multinational Consensus Statement from the Fleischner Society. *Radiology*. 2020;296(1):172-180. doi:10.1148/radiol.2020201365
8. Scott Simpson, Fernando U. Kay, Suhny Abbara, Sanjeev Bhalla, Jonathan H. Chung, Michael Chung, Travis S. Henry, Jeffrey P. Kanne, Seth Kligerman, Jane P. Ko, and Harold Litt . Radiological Society of North America Expert Consensus Statement on Reporting Chest CT Findings Related to COVID-19. Endorsed by the Society of Thoracic Radiology, the American College of Radiology, and RSNA. Published online: March 25 2020 <https://pubs.rsna.org/doi/10.1148/ryct.2020200152>
9. American Society of Transplantation: *SARS-CoV-2: Recommendations and Guidance for Organ Donor Testing and Evaluation*. Updated: January 18, 2023. <https://www.myast.org/sites/default/files/Donor%20Testing%20Document1.18.23.pdf>
10. Grillet F, Behr J, Calame P, Aubry S, Delabrousse E. Acute Pulmonary Embolism Associated with COVID-19 Pneumonia Detected by Pulmonary CT Angiography. *Radiology*. 2020;296(3):E186-E188. doi:10.1148/radiol.2020201544
11. Myall KJ, Mukherjee B, Castanheira AM, et al. Persistent Post-COVID-19 Interstitial Lung Disease. An Observational Study of Corticosteroid Treatment. *Ann Am Thorac Soc*. 2021;18(5):799-806. doi:10.1513/AnnalsATS.202008-1002OC
12. Ambardar SR, Hightower SL, Huprikar NA, Chung KK, Singhal A, Collen JF. Post-COVID-19 Pulmonary Fibrosis: Novel Sequelae of the Current Pandemic. *J Clin Med*. 2021;10(11):2452. Published 2021 Jun 1. doi:10.3390/jcm10112452
13. Vijayakumar B, Tonkin J, Devaraj A, et al. CT Lung Abnormalities after COVID-19 at 3 Months and 1 Year after Hospital Discharge. *Radiology*. 2022;303(2):444-454. doi:10.1148/radiol.2021211746
14. van den Borst B, Peters JB, Brink M, et al. Comprehensive Health Assessment 3 Months After Recovery From Acute Coronavirus Disease 2019 (COVID-19). *Clin Infect Dis*. 2021;73(5):e1089-1098. doi:10.1093/cid/ciaa1750
15. Expert Panel on Thoracic Imaging, Lee C, Colletti PM, et al. ACR Appropriateness Criteria® Acute Respiratory Illness in Immunocompromised Patients. *J Am Coll Radiol*. 2019;16(11S):S331-S339. doi:10.1016/j.jacr.2019.05.019

Other Chest Infections (CH-14)

Guideline

PPD or TB (Mycobacterium tuberculosis and Nontuberculous Mycobacterial Pulmonary Disease (NTM-PD)) (CH-14.1)

Fungal Infections (Suspected or Known) (CH-14.2)

Wegener's Granulomatosis/Granulomatosis with Polyangiitis (CH-14.3)

Suspected Sternal Dehiscence (CH-14.4)

References (CH-14)

PPD or TB (Mycobacterium tuberculosis and Nontuberculous Mycobacterial Pulmonary Disease (NTM-PD)) (CH-14.1)

CH.CI.0014.1.A

v2.0.2024

- CT Chest with contrast (CPT® 71260) or CT Chest without contrast (CPT® 71250) with ANY of the following:
 - Normal or equivocal chest x-ray with ONE of the following:¹
 - Positive PPD skin test or other positive tuberculin skin tests OR
 - Positive QuantiFERON-TB Gold OR
 - Suspected active (or reactivated) tuberculosis
 - Suspected complications or progression of tuberculosis (e.g. pleural tuberculosis, empyema, and mediastinitis)²
 - Suspected NTM-PD
 - If CT Chest is unremarkable, there is insufficient data to support performing subsequent CT Chest unless symptoms develop or chest x-ray shows a new abnormality.
 - Follow-up CT Chest with contrast (CPT® 71260) or without contrast (CPT® 71250) with frequency at the discretion of or in consultation with the pulmonary or infectious disease specialist (not to exceed 3 studies in 3 months).
 - Re-evaluate individuals undergoing active treatment who had abnormalities seen only on CT Chest.

Fungal Infections (Suspected or Known) (CH-14.2)

CH.CI.0014.2.A

v2.0.2024

- CT Chest with contrast (CPT® 71260) or High resolution CT Chest (HRCT) without contrast (CPT® 71250):^{3,4}
 - Initial diagnosis of any fungal pneumonia or chest infection^{3,4}
 - Suspected complications or progression of the fungal chest infection (e.g. worsening pneumonitis; pleural effusion, empyema, mediastinitis)
 - Suspected Allergic Bronchopulmonary Aspergillosis (ABPA) in asthmatics with atypical presentation or poor response to conventional therapy.^{7,8,9}
- Follow-up CT Chest with contrast (CPT® 71260) or High resolution CT Chest (HRCT) without contrast (CPT® 71250) with frequency at the discretion of or in consultation with the pulmonary or infectious disease specialist.

Wegener's Granulomatosis/Granulomatosis with Polyangiitis (CH-14.3)

CH.CI.0014.3.A

v2.0.2024

- CT Chest without contrast (CPT® 71250)* should be done in all individuals who have pulmonary symptoms and are newly diagnosed or suspected of having Antineutrophil cytoplasmic autoantibody (ANCA)-associated vasculitides (AAV) for a baseline prior to initiating immunosuppressive therapy.^{5,6}
- Selective use of additional imaging is useful in evaluating individuals who are suspected or known to have AAV, including CT Head (sinuses, orbits, mastoids) in individuals with visual or upper respiratory track symptoms or signs, and CT Neck (subglottic region) in individuals with symptoms or signs of subglottic stenosis.⁶

*In most situations, CT scans in individuals with AAV should be performed without an iodinated contrast agent administered.⁶

Suspected Sternal Dehiscence (CH-14.4)

CH.CI.0014.4.A

v2.0.2024

- Sternal wound dehiscence is primarily a clinical determination.
- Chest x-ray is performed prior to advanced imaging to identify abnormalities in the sternal wire integrity and/or a midsternal stripe. Other findings include rotated, shifted or ruptured wires.
- CT Chest without contrast (CPT® 71250) or CT Chest with contrast (CPT® 71260) for:
 - Differentiating sternal wire migration from sternal dehiscence¹⁰
 - Planned debridement and/or repair.

See **Infection – General (MS-9.1)** for concerns for osteomyelitis or soft tissue infection

References (CH-14)

v2.0.2024

1. Expert Panel on Thoracic Imaging:, Ravenel JG, Chung JH, et al. ACR Appropriateness Criteria® Imaging of Possible Tuberculosis. *J Am Coll Radiol*. 2017;14(5S):S160-S165. doi:10.1016/j.jacr.2017.02.022
2. Expert Panel on Thoracic Imaging, Lee C, Colletti PM, et al. ACR Appropriateness Criteria® Acute Respiratory Illness in Immunocompromised Patients. *J Am Coll Radiol*. 2019;16(11S):S331-S339. doi:10.1016/j.jacr.2019.05.019
3. Walker CM, Abbott GF, Greene RE, Shepard JA, Vummidi D, Digumarthy SR. Imaging pulmonary infection: classic signs and patterns [published correction appears in *AJR Am J Roentgenol*. 2014 Jun;202(6):1396]. *AJR Am J Roentgenol*. 2014;202(3):479-492. doi:10.2214/AJR.13.11463
4. Cordier JF, Valeyre D, Guillevin L, Loire R, Brechot JM. Pulmonary Wegener's granulomatosis. A clinical and imaging study of 77 cases. *Chest*. 1990;97(4):906-912. doi:10.1378/chest.97.4.906
5. Peivandi AA, Vogel N, Opfermann UT, et al. Early detection of sternal dehiscence by conventional chest X-ray. *Thorac Cardiovasc Surg*. 2006;54(2):108-111. doi:10.1055/s-2005-872864
6. Kumar K, Loebinger MR. Nontuberculous Mycobacterial Pulmonary Disease: Clinical Epidemiologic Features, Risk Factors, and Diagnosis: The Nontuberculous Mycobacterial Series. *Chest*. 2022;161(3):637-646. doi:10.1016/j.chest.2021.10.003
7. Ash SY, Diaz AA. The role of imaging in the assessment of severe asthma. *Curr Opin Pulm Med*. 2017;23(1):97-102. doi:10.1097/MCP.0000000000000341
8. Ward S, Heyneman L, Lee MJ, Leung AN, Hansell DM, Müller NL. Accuracy of CT in the diagnosis of allergic bronchopulmonary aspergillosis in asthmatic patients. *AJR Am J Roentgenol*. 1999;173(4):937-942. doi:10.2214/ajr.173.4.10511153
9. Richards JC, Lynch D, Koelsch T, Dyer D. Imaging of Asthma. *Immunol Allergy Clin North Am*. 2016;36(3):529-545. doi:10.1016/j.iac.2016.03.005
10. Hota P, Dass C, Erkmen C, Donuru A, Kumaran M. Poststernotomy Complications: A Multimodal Review of Normal and Abnormal Postoperative Imaging Findings. *AJR Am J Roentgenol*. 2018;211(6):1194-1205. doi:10.2214/AJR.18.19782

Sarcoid (CH-15)

Guideline

Sarcoid (CH-15.1)

References (CH-15)

Sarcoid (CH-15.1)

CH.SA.0015.1.A
v2.0.2024

- CT Chest with contrast (CPT® 71260) or without contrast (CPT® 71250) for:
 - Establish or rule out the diagnosis when suspected
- Subsequent CT Chest with contrast (CPT® 71260) or without contrast (CPT® 71250), in known sarcoid, for ANY of the following:¹
 - Development of worsening symptoms
 - New symptoms appear after a period of being asymptomatic
 - Treatment change is being considered
- If CT is equivocal, definitive diagnosis can only be made by biopsy.^{2,3,4}
- PET/CT should not be used in the standard work-up of all sarcoid individuals. There is currently no evidence to support the use of PET/CT for screening.
- PET/CT (CPT® 78815) can be considered under the following conditions:^{5,6,7}
 - Help guide biopsy location if:
 - Known lesion on CT Chest is difficult to access, to help identify alternative biopsy location
 - No apparent lung involvement and to identify an extrapulmonary biopsy site
 - Differentiation of reversible granulomatous disease from irreversible pulmonary fibrosis and will affect treatment options
 - Help identify treatment failure where either current treatment will be modified or new treatment will be introduced

References (CH-15)

v2.0.2024

1. Hantous-Zannad S, Charrada L, Zidi A, Mestiri I, Ben Miled-M'rad K. Apport de la TDM dans l'exploration de la sarcoïdose thoracique [Value of CT scanning in the investigation of thoracic sarcoidosis]. *Rev Mal Respir.* 2003;20(2 Pt 1):207-213.
2. Okumura W, Iwasaki T, Toyama T, et al. Usefulness of fasting 18F-FDG PET in identification of cardiac sarcoidosis. *J Nucl Med.* 2004;45(12):1989-1998.
3. Sarcoidosis. foundation.chestnet.org. <https://foundation.chestnet.org/lung-health-a-z/sarcoidosis/>
4. Baughman RP, Culver DA, Judson MA. A concise review of pulmonary sarcoidosis. *Am J Respir Crit Care Med.* 2011;183(5):573-581. doi:10.1164/rccm.201006-0865CI
5. Akaike G, Itani M, Shah H, et al. PET/CT in the Diagnosis and Workup of Sarcoidosis: Focus on Atypical Manifestations. *Radiographics.* 2018;38(5):1536-1549. doi:10.1148/rg.2018180053
6. Keijsers RG, van den Heuvel DA, Grutters JC. Imaging the inflammatory activity of sarcoidosis. *Eur Respir J.* 2013;41(3):743-751. doi:10.1183/09031936.00088612
7. Teirstein AS, Machac J, Almeida O, Lu P, Padilla ML, Iannuzzi MC. Results of 188 whole-body fluorodeoxyglucose positron emission tomography scans in 137 patients with sarcoidosis. *Chest.* 2007;132(6):1949-1953. doi:10.1378/chest.07-1178.

Solitary Pulmonary Nodule (SPN) (CH-16)

Guideline

Solitary Pulmonary Nodule (CH-16.0)

Solitary Pulmonary Nodule – Imaging (CH-16.1)

Incidental Pulmonary Nodules Detected on CT Images (CH-16.2)

Interval Imaging Outcomes (CH-16.3)

PET (CH-16.4)

References (CH-16)

Solitary Pulmonary Nodule (CH-16.0)

CH.SN.0016.0.A

v2.0.2024

- For Lung Cancer Screening (LDCT) including incidental findings from LDCT, See **Lung Cancer Screening (CH-33)**

Solitary Pulmonary Nodule – Imaging (CH-16.1)

CH.SN.0016.1.A

v2.0.2024

- For these guidelines, manual nodule measurements should be based on the average of long- and short-axis diameters. The size threshold (<6 mm) corresponds to a rounded measurement of 5 mm or less in these guidelines. Measurements should be rounded to the nearest millimeter. Prediction models used to estimate malignancy yield better results with the average diameter than with the maximum transverse diameter. The dimension of small pulmonary nodules (<10mm) should be expressed as the average of the maximal long-axis and perpendicular maximal short-axis measurements in the same plane. For larger nodules and for masses larger than 10 mm, it is generally appropriate to record both long- and short-axis dimensions, with the long-axis dimension being used to determine the T factor in lung cancer staging and being a criterion for tumor response to treatment.^{1,13}
- A pulmonary nodule can be determined to have changed in size when its average diameter has increased or decreased by at least 2mm (rounded to the nearest millimeter). Smaller changes do not reliably indicate change.¹³
- Maximum intensity projection (MIP), and Minimum intensity projection (MinIP) are 2D projections of the volumetric (3D) acquisition data.^{11,12} These projections may be of use in evaluation pulmonary nodules, but these projections are included in the cross sectional imaging base codes, and is not separately reimbursable.
- CT Chest with contrast (CPT® 71260) or CT Chest without contrast (CPT® 71250) initially for discrete nodule(s) in the following scenarios:^{1,2,3}
 - Lung nodule(s) seen on an imaging study other than a “dedicated” CT or MRI Chest. Examples of other studies:
 - Chest x-ray
 - CT Abdomen
 - MRI Spine
 - Coronary CTA¹
 - But NOT in the following which are considered initial dedicated advanced chest imaging:
 - CT Chest without and with contrast (CPT® 71270)
 - CTA Chest (CPT® 71275)
 - MRI Chest without contrast (CPT® 71550)
 - MRI Chest without and with contrast (CPT® 71552)
 - MRA Chest without and with contrast (CPT® 71555)
- Comparisons should include the earliest available study and the more recent previous CT Chest scans to determine if nodule was present and stable.¹
 - Similar-sized pleural nodule(s) is treated as a pulmonary nodule(s)

- The size of the lung or pleural nodule(s) is crucial information for decisions making regarding follow-up. The largest of multiple lung and/or pleural nodules will guide the surveillance interval. (See **Incidental Pulmonary Nodules Detected on CT Images (CH-16.2)**, and **Pleural-Based Nodules and Other Abnormalities (CH-17.1)**)

Background and Supporting Information

Abnormality examples include: mass, opacity, lesion, density, nodule, and calcification.

Incidental Pulmonary Nodules Detected on CT Images (CH-16.2)

CH.SN.0016.2.A

v2.0.2024

Incidentally Detected Solid Pulmonary Nodules Follow-up Recommendations*				
Nodule Type	<6 mm (<100 mm ³)	6–8 mm	>8 mm	Comments
Single Nodule	Follow-up (optional) CT at 12 months. No routine follow-up if stable at 12 months	CT at 6–12 months, then CT at 18–24 months if stable	CT at 3 months, then CT at 6-12 and then at 18-24 months if stable. Consider PET/CT** or biopsy	Certain individuals at high-risk with suspicious nodule morphology, upper lobe location, or both may warrant 12-month follow-up
Multiple Nodules	Follow-up (optional) CT at 12 months. *No routine follow-up if stable at 12 months	CT at 3–6 months, then at 18–24 months if stable	CT at 3–6 months, then at 18–24 months if stable. Consider PET/CT** or biopsy	Use most suspicious nodule as a guide to management. Follow-up intervals may vary according to size and risk.

Incidentally Detected Sub-Solid Pulmonary Nodules Follow-up Recommendations			
Nodule Type	<6mm (<100 mm ³)	≥6mm (≥100 mm ³)	Comments
Single Ground glass opacity (GGO)	Consider follow-up at 2 and 4 years. If solid component(s) or growth develops, consider resection.	CT at 6–12 months to confirm persistence, then follow-up with CT every 2 years until 5 years	In certain suspicious nodules, <6 mm, consider follow-up at 2 and 4 years. If solid component(s) or growth develops, consider resection.

Incidentally Detected Sub-Solid Pulmonary Nodules Follow-up Recommendations			
Single Part-solid	Consider follow-up at 2 and 4 years. If growth develops, consider resection.	CT at 3–6 months to confirm persistence. If unchanged and solid component remains <6 mm, then annual CT should be performed for 5 years. If the solid component has suspicious morphology (i.e., lobulated margins or cystic components), is >8 mm or is growing: Consider PET/CT** or biopsy	In practice, part-solid nodules cannot be defined as such until ≥6 mm. Persistent part-solid nodules with solid components ≥6 mm should be considered highly suspicious.
Multiple Part-Solid	CT at 3–6 months. If stable, consider CT at 2 and 4 years.	CT at 3–6 months. Subsequent management based on the most suspicious nodule(s).	Multiple <6 mm pure ground-glass nodules are usually benign.

(*Following the Fleischner Society Guidelines for high-risk which include American College of Chest Physicians intermediate and high-risk categories.^{1,2})

Pulmonary Cyst(s)¹⁰

- May represent a rare form of adenocarcinoma, squamous cell carcinoma, or small cell carcinoma.
- Short-term initial imaging to exclude rapid growth can be considered at 3-6 months.
- Further imaging can be managed according to the part-solid pathway above.

**PET/CT consider for ≥8 mm solid lung nodule or solid component of a sub-solid nodule, not for groundglass opacity.

If a PET/CT was found to be negative, follow-up with CT at 3 months, 9 months, and 21–24 months, if stable.

If a PET/CT was found to be positive, a biopsy was negative or non-diagnostic, follow-up with CT at 3 months, 12 months, and 24 months, if stable.

Interval Imaging Outcomes (CH-16.3)

CH.SN.0016.3.A
v2.0.2024

- No further advanced imaging is necessary if a nodule has been:
 - Stable for 2 years
 - Nodules(s) stable on chest x-ray.
 - Nodule(s) ≥ 6 mm stable on CT Chest.¹
 - Stable for 1 year
 - Nodule(s) < 6 mm.¹
 - At any time, if:
 - Classically benign characteristics by chest x-ray or previous CT (e.g. benign calcification pattern typical for a granuloma or hamartoma).
 - Decreasing or disappearing nodule(s).³
- Lung nodule(s) which increases in size or number should no longer be considered for CT screening or surveillance.^{1,2,3,7}
 - With an increase in nodule(s) size or number, tissue sampling or other further diagnostic investigations should be considered.
 - PET, for solid nodules ≥ 8 mm, should be considered (See **PET (CH-16.4)**)

PET (CH-16.4)

CH.SN.0016.4.A

v2.0.2024

- PET/CT (CPT® 78815) for a solid lung nodule ≥ 8 mm on dedicated advanced chest imaging, as described in **Solitary Pulmonary Nodule – Imaging (CH-16.1)**. See Non-Small Cell Lung Cancer – Suspected/Diagnosis (ONC-8.2) in the Oncology Imaging Guidelines for lung mass ≥ 3.1 cm
 - If there is a history of malignancy, refer to the appropriate Oncology restaging/recurrence guideline for indications for PET imaging
 - Pleural nodule, See **Pleural-Based Nodules and Other Abnormalities (CH-17.1)**
 - Serial PET studies are not considered indicated
 - Not appropriate for infiltrate, ground glass opacity, or hilar enlargement
 - Mediastinal lymphadenopathy - See **Mediastinal Lymphadenopathy (CH-2.3)** or Sarcoid concerns – See **Sarcoid (CH-15.1)**

Background and Supporting Information

- A **nodule** is any pulmonary or pleural lesion that is a discrete, spherical opacity 2-30 mm in diameter surrounded by normal lung tissue. A larger nodule is called a mass. Entities that are not nodules, and are considered benign, include non-spherical linear, sheet-like, two-dimensional or scarring opacities.³
- **Malignant** nodule features can include spiculation, abnormal calcification, size greater than 7-10 mm, interval growth, history of a cancer that tends to metastasize to the lung or mediastinum, and/or smoking history.^{1,3}
 - A nodule that grows at a rate consistent with cancer (doubling time 100 to 400 days) may be sampled for biopsy or resected.¹
 - Less than 1% of <6 mm lung nodules are malignant.¹
 - Three percent of all 8 mm lung nodules are malignant.¹
 - Only one follow-up at 6-12 months is sufficient for 6-8 mm nodules and not all require traditional 2 year follow-up.¹
 - The larger the solid component of a subsolid nodule, the greater the risk of invasiveness and metastases.¹
 - Increased risk of primary cancer as the total nodule count increased from 1 to 4 but decreased risk in individuals with 5 or more nodules, most of which likely resulted from prior granulomatous infection.¹
 - A nodule that does not grow in 6 months has a risk of malignancy at $<10\%$.
- **Benign** features in solid nodules can include benign calcification (80% granuloma, 10% hamartoma), multiple areas of calcification, small size, multiple nodules, negative PET, and stability of size over 2 years.³
- **Ground glass** or subsolid opacities, which can harbor indolent adenocarcinoma with average doubling times of 3–5 years.¹

- **Repeat PET** is discouraged. If the original PET is positive, biopsy may be performed. If the original PET is negative but subsequent CT Chest shows an increase in nodule size, biopsy may be performed.
- **Positive PET** is defined as a standardized uptake value (SUV) in the lung nodule greater than the baseline mediastinal blood pool. A positive PET can occur with infection or inflammation, including absence of lung cancer with localized infection, presence of lung cancer with associated (post-obstructive) infection and/or related inflammation.
- **False negative PET** can be seen in individuals with adenocarcinoma in situ (formally known as bronchoalveolar carcinoma), carcinoid tumors, a small size nodule, non-solid or ground glass opacity.⁹ High pre-test likelihood of malignancy with negative findings on PET only reduces the likelihood of malignancy to 14%; while in an individual with a low pre-test likelihood (20%) of malignancy, a negative PET reduces the likelihood of malignancy to 1%.⁶
- Individuals aged 35 years or younger¹
 - Considered to have an overall low risk for pulmonary malignancy
 - In this age group, nodules are most likely to be infectious rather than cancer
 - Management of incidentally-found pulmonary nodules in this group should be individualized

References (CH-16)

v2.0.2024

1. MacMahon H, Naidich DP, Goo JM, et al. Guidelines for Management of Incidental Pulmonary Nodules Detected on CT Images: From the Fleischner Society 2017. *Radiology*. 2017;284(1):228-243. doi:10.1148/radiol.2017161659
2. Gould MK, Donington J, Lynch WR, et al. Evaluation of individuals with pulmonary nodules: when is it lung cancer? Diagnosis and management of lung cancer, 3rd ed: American College of Chest Physicians evidence-based clinical practice guidelines. *Chest* 2013;143(5 Suppl):e93S-e120S. doi:10.1378/chest.12-2351
3. Kanne JP, Jensen LE, Mohammed TL, et al. ACR Appropriateness Criteria® radiographically detected solitary pulmonary nodule. *J Thorac Imaging*. 2013;28(1):W1-W3. doi:10.1097/RTI.0b013e31827657c8
4. Tan BB, Flaherty KR, Kazerooni EA, Iannettoni MD; American College of Chest Physicians. The solitary pulmonary nodule. *Chest*. 2003;123(1 Suppl):89S-96S. doi:10.1378/chest.123.1_suppl.89s
5. Khandani, AH, Fielding JR. PET in management of small pulmonary nodules. *Radiology*. 2007;242(3):948-949. doi:10.1148/radiol.2423060308
6. Truong MT, Ko JP, Rossi SE, et al. Update in the evaluation of the solitary pulmonary nodule. *Radiographics*. 2014;34(6):1658-1679. doi:10.1148/rg.346130092
7. Lung CT Screening Reporting and Data System (Lung-RADS™), American College of Radiology, Quality & Safety. <https://www.acr.org/Quality-Safety/Resources/LungRADS>.
8. National Comprehensive Cancer Network® (NCCN®) Guidelines® Version 1.2024 – July 19, 2023. Lung Cancer Screening. https://www.nccn.org/professionals/physician_gls/pdf/lung_screening.pdf. Referenced with permission from the NCCN Clinical Practice Guidelines in Oncology (NCCN Guidelines®) for Lung Cancer Screening Version 1.2024. © 2023 National Comprehensive Cancer Network® (NCCN®). All rights reserved. NCCN Guidelines® and illustrations herein may not be reproduced in any form for any purpose without the express written permission of the NCCN. To view the most recent and complete version of the NCCN Guidelines®, go online to NCCN.org.
9. National Comprehensive Cancer Network® (NCCN®) Guidelines® Version 3.2023 – April 13, 2023. Non-Small Cell Lung Cancer. https://www.nccn.org/professionals/physician_gls/pdf/nscl.pdf. Referenced with permission from the NCCN Clinical Practice Guidelines in Oncology (NCCN Guidelines®) for Non-Small Cell Lung Cancer Version 3.2023. © 2023 National Comprehensive Cancer Network® (NCCN®). All rights reserved. NCCN Guidelines® and illustrations herein may not be reproduced in any form for any purpose without the express written permission of the NCCN. To view the most recent and complete version of the NCCN Guidelines®, go online to NCCN.org.
10. Mets OM, Schaefer-Prokop CM, de Jong PA. Cyst-related primary lung malignancies: an important and relatively unknown imaging appearance of (early) lung cancer. *Eur Respir Rev*. 2018;27(150):180079. Published 2018 Dec 19. doi:10.1183/16000617.0079-2018
11. Fishman EK, Ney DR, Heath DG, Corl FM, Horton KM, Johnson PT. Volume rendering versus maximum intensity projection in CT angiography: what works best, when, and why. *Radiographics*. 2006;26(3):905-922. doi:10.1148/rg.263055186
12. Naeem MQ, Darira J, Ahmed MS, Hamid K, Ali M, Shazlee MK. Comparison of Maximum Intensity Projection and Volume Rendering in Detecting Pulmonary Nodules on Multidetector Computed Tomography. *Cureus*. 2021;13(3):e14025. Published 2021 Mar 21. doi:10.7759/cureus.14025
13. Bankier AA, MacMahon H, Goo JM, Rubin GD, Schaefer-Prokop CM, Naidich DP. Recommendations for Measuring Pulmonary Nodules at CT: A Statement from the Fleischner Society. *Radiology*. 2017;285(2):584-600. doi:10.1148/radiol.2017162894

Pleural-Based Nodules and Other Abnormalities (CH-17)

Guideline

Pleural-Based Nodules and Other Abnormalities (CH-17.1)

Reference (CH-17)

Pleural-Based Nodules and Other Abnormalities (CH-17.1)

CH.PB.0017.1.A

v2.0.2024

- CT Chest with contrast (CPT® 71260) or CT Chest without contrast (CPT® 71250) (with contrast is preferred for initial evaluation) for pleural nodule(s).¹
 - Pleural nodule(s) seen on an imaging study other than a “dedicated” CT or MRI Chest.¹
 - Pleural nodule(s) identified incidentally on any of the following dedicated chest studies can replace CT Chest as the initial dedicated study.¹
 - CT Chest without and with contrast (CPT® 71270).
 - CTA Chest (CPT® 71275).
 - MRI Chest without contrast (CPT® 71550).
 - MRI Chest without and with contrast (CPT® 71552).
 - MRA Chest without and with contrast (CPT® 71555).
 - After preliminary comparison with any available previous chest films to determine presence and stability.
 - Using largest measurement of multiple nodule(s). (See **Solitary Pulmonary Nodule – Imaging (CH-16.1)**).
 - Following the Fleischner Society Guidelines for high-risk. (See **Incidental Pulmonary Nodules Detected on CT Images (CH-16.2)**)¹
- PET/CT (CPT® 78815) can be considered if dedicated CT or MRI Chest identifies a pleural nodule/mass or defined area of pleural thickening that is ≥ 8 mm when there is a likelihood of malignancy including current or previous malignancy, pleural effusion, bone erosion, chest pain.¹

Background and Supporting Information

- Pleural nodule/mass or thickening without suggestion of malignancy would undergo surveillance or biopsy.
- A study looking at over 8,700 LDCT chest scans identified 943 noncalcified nodules attached to the costal pleura, of these 897 were < 10 mm in size. There were 603 that were either lentiform, oval, semicircular or triangular in shape and had smooth margins. All of these nodules, that met these qualifications of shape, size and smooth margins, were benign. Follow-up with annual screening, rather than more immediate work-up, was recommended.²

Reference (CH-17)

v2.0.2024

1. Rivera MP, Mehta AC, Wahidi MM. Establishing the diagnosis of lung cancer: Diagnosis and management of lung cancer, 3rd ed: American College of Chest Physicians evidence-based clinical practice guidelines. *Chest*. 2013;143(5 Suppl):e142S-e165S. doi:10.1378/chest.12-2353
2. Zhu Y, Yip R, You N, Henschke CI, Yankelevitz DF. Management of Nodules Attached to the Costal Pleura at Low-Dose CT Screening for Lung Cancer. *Radiology*. 2020;297(3):710-718. doi:10.1148/radiol.2020202388

Pleural Effusion (CH-18)

Guideline

Pleural Effusion (CH-18.1)

References (CH-18)

Pleural Effusion (CH-18.1)

CH.EF.0018.1.A
v2.0.2024

- CT Chest with contrast (CPT® 71260) after:^{1,2}
 - Chest x-ray including lateral decubitus films; **and**
 - Thoracentesis to determine if fluid is exudative or transudative and remove as much as possible (this fluid can obscure the underlying lung parenchyma and possibly a mass) **or**
 - Concern for loculated effusion, empyema, paramediastinal location, subpleural lung abscess or cavitation³
- Chest ultrasound (CPT® 76604) can be used as an alternative to chest x-ray to evaluate for the presence of fluid within the pleural spaces and guide thoracentesis.

Background and Supporting Information

- Bilateral effusions are more often systemic related transudates (congestive heart failure, renal failure, liver insufficiency, etc.), and advanced imaging is rarely needed. Large unilateral effusions can be malignant. Analysis of fluid may include: cytology, culture, cell count, and biochemical studies.

References (CH-18)

v2.0.2024

1. Light RW, Macgregor MI, Luchsinger PC, Ball WC Jr. Pleural effusions: the diagnostic separation of transudates and exudates. *Ann Intern Med* 1972;77(4):507-513. doi:10.7326/0003-4819-77-4-507
2. MacDuff A, Arnold A, Harvey J; BTS Pleural Disease Guideline Group. Management of spontaneous pneumothorax: British Thoracic Society Pleural Disease Guideline 2010. *Thorax*. 2010;65 Suppl 2:ii18-ii31. doi:10.1136/thx.2010.136986
3. Heffner JE, Klein JS, Hampson C. Diagnostic utility and clinical application of imaging for pleural space infections. *Chest*. 2010;137(2):467-479. doi:10.1378/chest.08-3002

Pneumothorax/ Hemothorax (CH-19)

Guideline

Pneumothorax/Hemothorax (CH-19.1)

Pneumomediastinum; Subcutaneous Emphysema (CH-19.2)

References (CH-19)

Pneumothorax/Hemothorax (CH-19.1)

CH.PT.0019.1.A

v2.0.2024

Chest x-ray and CT Chest are the first line tests for detecting pneumothorax/hemothorax and ruling out other lung diseases.⁸

- Chest x-ray initially.
 - CT Chest with contrast (CPT[®] 71260) or without contrast (CPT[®] 71250) if:
 - Diagnosis of a small pneumothorax is in doubt, and the presence of a pneumothorax will affect individual treatment decisions.¹
 - Preoperative study for treatment of pneumothorax.¹
 - Pneumothorax associated with hemothorax.²
 - Suspected complications from hemothorax (e.g. empyema).²
 - Suspected Alpha-1-Antitrypsin Deficiency (even without pneumothorax).³
 - Suspected Cystic Lung Disease, including Lymphangioliomyomatosis (LAM), tuberous sclerosis (TS), or Birt-Hogg-Dube (BHD) syndrome.^{6,7}
 - To determine the etiology of persistent pneumothorax/air leak, such as chest tube malposition, bronchopleural fistula, loculated pneumothorax, lung parenchymal disease.¹¹
 - Suspected catamenial pneumothorax/thoracic endometriosis⁸
 - MRI Chest without and with contrast (CPT[®] 71552) or MRI Chest without contrast (CPT[®] 71550) for:
 - Detecting diaphragmatic endometriosis
 - Pre-surgical planning for thoracic endometriosis^{8,9,10}

Pneumomediastinum; Subcutaneous Emphysema (CH-19.2)

CH.PT.0019.2.A

v2.0.2024

- Chest x-ray initially.
 - CT Chest with contrast (CPT® 71260) or without contrast (CPT® 71250) if:
 - Recent vomiting and/or suspected esophageal perforation.^{4,5}
 - Associated pneumopericardium.^{4,5}
 - Associated pneumothorax.^{4,5}
 - Preoperative study for treatment.^{4,5}

Background and Supporting Information

- An expiration chest x-ray can enhance the evaluation of equivocal plain x-ray. There is no data supporting the use of serial CT Chest to follow individuals with a known pneumothorax, pneumomediastinum, or hemothorax who are asymptomatic or have stable symptoms. With the exception of the indications above, advanced imaging of the chest is rarely indicated in the diagnosis or management of pneumothorax, or pneumomediastinum. Inspiratory/expiratory chest x-rays are helpful in defining whether a pneumothorax is present.

References (CH-19)

v2.0.2024

1. Manes N, Hernandez-Rodriguez H, Lopez-Martin S, Sanchez-Gascon F. Pneumothorax--guidelines of action. *Chest*. 2002;121(2):669. doi:10.1378/chest.121.2.669
2. Mowery NT, Gunter OL, Collier BR, et al. Practice management guidelines for management of hemothorax and occult pneumothorax. *J Trauma*. 2011;70(2):510-518. doi:10.1097/TA.0b013e31820b5c31
3. Sandhaus RA, Turino G, Brantly ML, et al. The Diagnosis and Management of Alpha-1 Antitrypsin Deficiency in the Adult. *Chronic Obst Pulm Dis*. 2016;3(3):668-682. Published 2016 Jun 6. doi:10.15326/jcopdf.3.3.2015.0182
4. Daccord C, Good JM, Morren MA, Bonny O, Hohl D, Lazor R. Birt-Hogg-Dubé syndrome. *Eur Respir Rev*. 2020;29(157):200042. Published 2020 Sep 17. doi:10.1183/16000617.0042-2020
5. Iyer VN, Joshi AY, Ryu JH. Spontaneous pneumomediastinum: analysis of 62 consecutive adult patients. *Mayo Clin Proc*. 2009;84(5):417-421. doi:10.1016/S0025-6196(11)60560-0
6. Ryu JH, Moss J, Beck GJ, et al. The NHLBI lymphangioliomyomatosis registry: characteristics of 230 patients at enrollment. *Am J Respir Crit Care Med*. 2006;173(1):105-111. doi:10.1164/rccm.200409-1298OC
7. Raof S, Bondalapati P, Vydyula R, et al. Cystic Lung Diseases: Algorithmic Approach. *Chest*. 2016;150(4):945-965. doi:10.1016/j.chest.2016.04.026
8. Rousset P, Rousset-Jablonski C, Alifano M, Mansuet-Lupo A, Buy JN, Revel MP. Thoracic endometriosis syndrome: CT and MRI features. *Clin Radiol*. 2014;69(3):323-330. doi:10.1016/j.crad.2013.10.014
9. Nezhad C, Lindheim SR, Backhus L, et al. Thoracic Endometriosis Syndrome: A Review of Diagnosis and Management. *JLS*. 2019;23(3):e2019.00029. doi:10.4293/JLS.2019.00029
10. McKee DC, Mansour T, Wasson MN. Thoracic and diaphragmatic endometriosis: an overview of diagnosis and surgical treatment. *Curr Opin Obstet Gynecol*. 2022;34(4):204-209. doi:10.1097/GCO.0000000000000792
11. Chaturvedi A, Lee S, Klionsky N, Chaturvedi A. Demystifying the persistent pneumothorax: role of imaging. *Insights Imaging*. 2016;7(3):411-429. doi:10.1007/s13244-016-0486-5

Mediastinal Mass (CH-20)

Guideline

Mediastinal Mass (CH-20.1)

References (CH-20)

Mediastinal Mass (CH-20.1)

CH.MM.0020.1.A

v2.0.2024

- CT Chest with contrast (CPT® 71260) or CT Chest without contrast (CPT® 71250) or MRI Chest without and with contrast (CPT® 71552) or MRI Chest without contrast (CPT® 71550), to evaluate mediastinal abnormalities, may include, but not limited to mediastinal cyst including bronchogenic, thymic, pericardial or esophageal, seen on chest x-ray or other non-dedicated chest imaging.
- MRI Chest without and with contrast (CPT® 71552) or MRI Chest without contrast (CPT® 71550) can be considered for indeterminate mediastinal mass on CT Chest.
 - Lesions that remain indeterminate on MRI, if biopsy is not performed, surveillance imaging could be performed at 3-12 month intervals over 2 years or more with MRI Chest, depending upon level of clinical concern.
- FDG PET/CT offers limited additional value beyond that of conventional CT in the initial assessment of mediastinal mass(es), with the exception of primary mediastinal lymphoma. See **Non-Hodgkin Lymphomas (ONC-27)** or **Hodgkin Lymphoma (ONC-28)** in the Oncology Imaging Guidelines. A positive FDG PET/CT has little value for discrimination between benign and malignant lesions.
 - MRI Chest without and with contrast (CPT® 71552) or MRI Chest without contrast (CPT® 71550) can be considered for indeterminate mediastinal mass on FDG PET/CT
- CT Chest with contrast (CPT® 71260), or CT Chest without contrast (CPT® 71250) or MRI Chest without and with contrast (CPT® 71552), or MRI Chest without contrast (CPT® 71550) for subsequent evaluations if:
 - New signs or symptoms, or
 - Preoperative assessment
- For Adenopathy; See **Lymphadenopathy (CH-2)**.
- For Goiter; See **Thyroid Nodule (NECK-8.1)** in the Neck Imaging Guidelines.
- For Myasthenia Gravis; See **Neuromuscular Junction Disorders (PN-6.1)** in the Peripheral Nerve Disorders Imaging Guidelines.

References (CH-20)

v2.0.2024

1. Kuhlman JE, Bouchardy L, Fishman EK, Zerhouni EA. CT and MR imaging evaluation of chest wall disorders. *Radiographics*. 1994;14(3):571-595. doi:10.1148/radiographics.14.3.8066273
2. Juanpere S, Cañete N, Ortuño P, Martínez S, Sanchez G, Bernado L. A diagnostic approach to the mediastinal masses. *Insights Imaging*. 2013;4(1):29-52. doi:10.1007/s13244-012-0201-0
3. Komanapalli C, Schipper P, Sukumar M. Pericardial Cyst. October 2022. doi:10.25373/ctsnet.21280404
4. Expert Panel on Thoracic Imaging, Ackman JB, Chung JH, et al. ACR Appropriateness Criteria® Imaging of Mediastinal Masses. *J Am Coll Radiol*. 2021;18(5S):S37-S51. doi:10.1016/j.jacr.2021.01.007

Chest Trauma (CH-21)

Guideline

Chest Trauma (CH-21.1)

References (CH-21)

Chest Trauma (CH-21.1)

CH.CT.0021.1.A

v2.0.2024

- Chest X-ray initially.
 - CT Chest without contrast (CPT® 71250) or with contrast (CPT® 71260) for the following situations:¹
 - Rib¹ or Sternal² Fracture:
 - With associated complications identified clinically or by other imaging, including pneumothorax, hemothorax, pulmonary contusion, atelectasis, flail chest, cardiovascular injury and/or injuries to solid or hollow abdominal organs.¹
 - Uncomplicated, single fractures, multiple fractures, non-acute fractures, or occult rib fractures are NOT an indication for CT Chest unless malignancy is suspected as the etiology.¹
 - Routine follow-up advanced imaging of rib or sternal fractures is not indicated.¹
 - CT Chest without contrast (CPT® 71250) or Tc-99m bone scan whole body (CPT® 78306) for suspected pathological rib fractures, with or without a history of trauma.¹
 - Clavicle Fractures:
 - CT Chest with contrast (CPT® 71260) or CT Chest without contrast (CPT® 71250) or MRI Chest without and with contrast (CPT® 71552) or MRI Chest without contrast (CPT® 71550) for proximal (medial) 1/3 fractures or sternoclavicular dislocations.³
 - X-ray is adequate for evaluation of middle and distal 1/3 fractures.³
 - No advanced imaging of the abdomen or pelvis is indicated when there is chest trauma and no physical examination or laboratory evidence of abdominal and/or pelvic injury.

References (CH-21)

v2.0.2024

1. Expert Panel on Thoracic Imaging; Henry TS, Donnelly EF, et al. ACR Appropriateness Criteria® Rib Fractures. *J Am Coll Radiol*. 2019;16(5S):S227-S234. doi:10.1016/j.jacr.2019.02.019
2. Clancy K, Velopulos C, Bilaniuk JW, et al. Screening for blunt cardiac injury: an Eastern Association for the Surgery of Trauma practice management guideline. *J Trauma Acute Care Surg*. 2012;73(5 Suppl 4):S301-S306. doi:10.1097/TA.0b013e318270193a
3. Throckmorton T, Kuhn JE. Fractures of the medial end of the clavicle. *J Shoulder Elbow Surg*. 2007;16(1):49-54. doi:10.1016/j.jse.2006.05.010

Chest Wall Mass (CH-22)

Guideline

Chest Wall Mass (CH-22.1)

References (CH-22)

Chest Wall Mass (CH-22.1)

CH.CM.0022.1.A

v2.0.2024

- Chest x-ray is useful in the workup of a soft-tissue mass and is almost always indicated as the initial imaging study.¹
 - Chest ultrasound (CPT® 76604) may be useful as an initial imaging study in the setting of a suspected superficial or subcutaneous lipoma. This modality may also be valuable in differentiating cystic from solid lesions and has also been used to assess the vascularity of lesions.¹
 - Following a non-diagnostic Chest x-ray that does not show an obvious lipoma(s) or clearly benign entity (see **Soft Tissue Mass or Lesion of Bone (MS-10)** in the Musculoskeletal Imaging Guidelines), the following may be appropriate:^{1,2}
 - MRI Chest without and with contrast (CPT® 71552) or
 - MRI Chest without contrast (CPT® 71550) or when MRI is contraindicated,
 - CT Chest with contrast (CPT® 71260)

Background and Supporting Information

- Chest x-rays of chest wall masses can detect calcification, ossification, or bone destruction as well as location and size.^{1,2}
- CT Chest without contrast is usually not beneficial in the evaluation of a soft tissue mass. With modern CT technology, calcification can usually be distinguished from vascular enhancement on contrast enhanced scan. In the evaluation of suspected tumors, contrast imaging is especially useful in distinguishing vascularized from potentially necrotic regions of the tumor.¹

References (CH-22)

v2.0.2024

1. Expert Panel on Musculoskeletal Imaging, Garner HW, Wessell DE, et al. ACR Appropriateness Criteria® Soft Tissue Masses: 2022 Update. *J Am Coll Radiol.* 2023;20(5S):S234-S245. doi:10.1016/j.jacr.2023.02.009
2. Expert Panel on Musculoskeletal Imaging, Bestic JM, Wessell DE, et al. ACR Appropriateness Criteria® Primary Bone Tumors. *J Am Coll Radiol.* 2020;17(5S):S226-S238. doi:10.1016/j.jacr.2020.01.038

Pectus Excavatum and Pectus Carinatum (CH-23)

Guideline

Pectus Excavatum and Carinatum (CH-23.1)

References (CH-23)

Pectus Excavatum and Carinatum (CH-23.1)

CH.EC.0023.1.U

v2.0.2024

- CT Chest without contrast (CPT® 71250) or MRI Chest without and with contrast (CPT® 71552) and 3-D reconstruction (CPT® 76377 or CPT® 76376) if:
 - Candidates for surgical correction.^{1,2}
 - Cardiac or pulmonary dysfunction has been identified^{1,2}
 - ECG and echocardiography if cardiac symptoms or evidence of cardiac function abnormalities.
 - Chest x-ray and PFT's if increasing shortness of breath.¹

Background and Supporting Information

- Chest measurements derived from CT Chest, such as the Haller Index or the correction index, are helpful to the thoracic surgeon in pre-operative assessment of chest wall deformities to assess for the appropriateness of operative repair prior to the development of symptomatic pectus deformities.
- The Haller index is calculated using the width of the chest divided by the distance between the posterior surface of the sternum and the anterior surface of the spine. A Haller index score is normal at 2.5 to 2.7 and severe at 3.25 or greater. The correction index uses an equation of $(b-a)/b \times 100$, in which a is the minimum distance between the anterior spine and the posterior surface of the sternum, and b is the maximum distance between the anterior spine and most anterior internal rib. It yields a percentage that the chest would need to be corrected to achieve normal dimensions, with a normal level being 10% or less.³
- Some have suggested that a CXR can replace the CT Chest for Haller Index calculation with a strong correlation and high diagnostic accuracy.⁴
- Expert consensus from The Society of Thoracic Surgeons 2023, recommended that a comprehensive evaluation with spirometry, ECG, and echocardiography be done with any cardio-pulmonary complaint. The Haller index, correction index, pulmonary compression or failed previous repair, in and of itself, was not an indication for surgery. Corrective surgery indications for those with severe pectus excavatum included; progression of deformity, presence of cardio-pulmonary symptoms, mitral valve prolapse, arrhythmia, significant body image disturbances, abnormal PFTs, abnormal cardiac function test or the presence of cardiac compression on imaging, (echo or CT).⁵

References (CH-23)

v2.0.2024

1. Marcovici PA, LoSasso BE, Kruk P, Dwek JR. MRI for the evaluation of pectus excavatum. *Pediatr Radiol.* 2011;41(6):757-758. doi:10.1007/s00247-011-2031-5
2. Goretsky MJ, Kelly RE Jr, Croitoru D, Nuss D. Chest wall anomalies: pectus excavatum and pectus carinatum. *Adolesc Med Clin.* 2004;15(3):455-471. doi:10.1016/j.admecli.2004.06.002
3. Abid I, Ewais MM, Marranca J, Jaroszewski DE. Pectus Excavatum: A Review of Diagnosis and Current Treatment Options. *J Am Osteopath Assoc.* 2017;117(2):106-113. doi:10.7556/jaoa.2017.021
4. Scalise PN, Demehri FR. The management of pectus excavatum in pediatric patients: a narrative review. *Transl Pediatr.* 2023;12(2):208-220. doi:10.21037/tp-22-361
5. Janssen N, Daemen JHT, van Polen EJ, et al. Pectus Excavatum: Consensus and Controversies in Clinical Practice. *Ann Thorac Surg.* 2023;116(1):191-199. doi:10.1016/j.athoracsur.2023.02.059

Pulmonary Arteriovenous Fistula (AVM) (CH-24)

Guideline

Pulmonary AVM (CH-24.1)

References (CH-24)

Pulmonary AVM (CH-24.1)

CH.AV.0024.1.A**v2.0.2024**

- CT Chest with contrast (CPT® 71260), CT Chest without contrast (CPT® 71250), CTA Chest (preferred modality for pre-intervention planning) (CPT® 71275), or MRA Chest (CPT® 71555) for evaluation of:^{1,2,3,5,6,7}
 - Suspected pulmonary AVM, including individuals with HHT (Hereditary Hemorrhagic Telangiectasia) or who have a first degree relative with HHT^{4,5}
 - First degree relatives of an individual with a primary pulmonary AVM
 - Evaluation of individuals with paradoxical embolus/stroke and no evidence of patent foramen ovale on echocardiogram
 - Follow-up of treated AVM's at 6 months post embolization and then every 3-5 years⁴
 - Follow-up of untreated AVM's to be determined by treating physician but no more than annually. Usually the interval is 3-5 years due to the slow-growth nature of PAVM's⁴
 - Treated or untreated PAVM's with recurrent symptoms⁴

Background and Supporting Information

- Pulmonary AVMs are abnormal connections between pulmonary arteries and veins, usually found in the lower lobes, that can be either primary (such as in individuals with HHT) or acquired (such as trauma, bronchiectasis). They can be identified in up to 98% of chest x-rays by a peripheral, circumscribed, non-calcified lesion connected by blood vessels to the hilum of the lung. Treatment is often by surgery or embolization of the feeding artery using platinum coils or detachable balloons.

References (CH-24)

v2.0.2024

1. De Cillis E, Burdi N, Bortone AS, et al. Endovascular treatment of pulmonary and cerebral arteriovenous malformations in patients affected by hereditary haemorrhagic telangiectasia. *Curr Pharm Des.* 2006;12(10):1243-1248. doi:10.2174/138161206776361237
2. Gossage JR, Kanj G. Pulmonary arteriovenous malformations. A state of the art review. *Am J Respir Crit Care Med.* 1998;158(2):643-661. doi:10.1164/ajrccm.158.2.9711041
3. Lee EY, Boiselle PM, Cleveland RH. Multidetector CT evaluation of congenital lung anomalies. *Radiology.* 2008;247(3):632-648. doi:10.1148/radiol.2473062124
4. Faughnan ME, Palda VA, Garcia-Tsao G, et al. International guidelines for the diagnosis and management of hereditary haemorrhagic telangiectasia. *J Med Genet.* 2011;48(2):73-87. doi:10.1136/jmg.2009.069013
5. Faughnan ME, Mager JJ, Hetts SW, et al. Second International Guidelines for the Diagnosis and Management of Hereditary Hemorrhagic Telangiectasia. *Ann Intern Med.* 2020;173(12):989-1001. doi:10.7326/M20-1443
6. Shovlin CL, Condliffe R, Donaldson JW, Kiely DG, Wort SJ; British Thoracic Society Clinical Statement on Pulmonary Arteriovenous Malformations. *Thorax.* 2017;72(12):1154-1163. doi:10.1136/thoraxjnl-2017-210764
7. Hanley M, Ahmed O, Chandra A, et al. ACR Appropriateness Criteria® Clinically Suspected Pulmonary Arteriovenous Malformation. *J Am Coll Radiol.* 2016;13(7):796-800. doi:10.1016/j.jacr.2016.03.020

Pulmonary Embolism (PE) (CH-25)

Guideline

Pulmonary Embolism (CH-25.1)

References (CH-25)

Pulmonary Embolism (CH-25.1)

CH.PE.0025.1.A

v2.0.2024

- CT Chest with contrast with PE protocol (CPT® 71260) or CTA Chest (CPT® 71275) if at least one symptom, clinical/laboratory finding or risk factor from each of the lists below are present.
 - With any ONE of the 3:^{6,7,8}
 - Dyspnea, new onset and otherwise unexplained;
 - Chest Pain, pleuritic;
 - Tachypnea
 - AND, with any ONE of the 3:^{6,7,8}
 - Abnormal **D-dimer** test;
 - Wells Criteria score* higher than 4 points;
 - One Risk Factor** or Symptom** of new onset demonstrating high clinical probability of PE

RISK FACTORS** 6,7,8	SYMPTOMS ATTRIBUTED TO PE** 6,7,8
Immobilization at least 3 days or surgery in last 4 weeks or recent trauma	Signs or symptoms of DVT
Previous history of DVT or PE	Hemoptysis
Cancer actively treated in last 6 months or receiving palliative treatment	Right heart strain or failure
Recent history of a long airplane flight	Systolic BP <90
Use of estrogen-based contraceptives (birth control pills, the patch, and vaginal ring)/Oral estrogen ¹	Syncope
Advanced age (≥70)	Cough
Congestive heart failure	Heart Rate >100
Obesity (BMI ≥35)	Palpitations
Suspicion or diagnosis of COVID-19	

Well's Criteria for Clinical Probability of PE* 6	
Clinical signs/symptoms of DVT (at minimum: leg swelling and pain with palpation of the deep veins)	3
PE is likely or equally likely diagnosis	3
Heart rate >100	1.5

Well's Criteria for Clinical Probability of PE* 6	
Immobilization at least 3 days or surgery in last 4 weeks	1.5
Previous history of DVT or PE	1.5
Hemoptysis	1
Cancer actively treated in last 6 months or receiving palliative treatment	1
Calculate Probability: Low <2 Moderate 2 to 6 High >6	
Using the above criteria, only 3% of individuals with a low pretest probability had PE versus 63% of those with a high pretest probability.	

- Non-urgent cases which do not meet above 2-step criteria, should undergo prior to advanced imaging:⁹
 - Chest x-ray (to rule out other causes of acute chest pain).
 - Primary cardiac and pulmonary etiologies should be eliminated.
- Pregnancy is a risk factor for thrombo-embolic events in and of itself. Additional risk factors are not required. Pregnant individuals with suspected PE are suggested to proceed with:^{11,12,13}
 - If signs/symptoms of DVT are present, Doppler studies of the lower extremities (CPT® 93925 bilateral study or CPT® 93926 unilateral study)
 - If no signs/symptoms of DVT, then chest x-ray should be done first
 - If chest x-ray is normal, then V/Q scan is preferred test
 - If chest x-ray is abnormal or after non-diagnostic V/Q scan or if V/Q scanning is not readily available, then CTA Chest (CPT® 71275) or CT Chest with contrast with PE protocol (CPT® 71260).
- Ventilation-perfusion scans, also called V/Q, scans (CPT® 78580-Pulmonary Perfusion Imaging; CPT® 78582-Pulmonary Ventilation (e.g., Aerosol or Gas) and Perfusion Imaging) or SPECT/CT (CPT® 78830):¹⁵
 - Is not a replacement for CTA Chest⁹
 - Can be considered in any of the following:
 - Suspected pulmonary embolism if there is a contraindication to CT or CTA Chest (ventilation-perfusion scans CPT® 78582)
 - Suspected pulmonary embolism when a chest x-ray is negative and CTA Chest is not diagnostic (CPT® 78580 or CPT® 78582)
 - Follow-up of an equivocal or positive recent ventilation-perfusion lung scan to evaluate for interval change (CPT® 78580)

- Suspected Chronic thromboembolic disease or Chronic thromboembolic pulmonary hypertension*, usually after 3 months of effective anticoagulation¹⁴
- Follow-up Imaging in Stable or Asymptomatic Individuals with Known PE is not warranted^{2,3,4,10}
- Follow-up imaging with CT Chest with contrast with PE protocol (CPT® 71260) or CTA Chest (CPT® 71275) for ANY of the following indications:
 - Recurrent or persistent signs or symptoms such as dyspnea, particularly if present after 3 months of anticoagulation, or
 - Elevated d-dimer which is persistent or recurrently elevated, or
 - Right heart strain or failure identified by EKG, ECHO or Heart catheterization.
- *Pulmonary Artery Hypertension (PAH) - See **Pulmonary Artery Hypertension (PAH) – Indications (CD-8.1)** in the Cardiac Imaging Guidelines

Background and Supporting Information

- Pulmonary embolism is found in approximately 10% of all those that present with suspicion of PE. Dyspnea, pleuritic chest pain and tachypnea occur with about 50% incidence with leg swelling or pain just over 50%.
- D-dimer level has a high sensitivity and low specificity for diagnosing PE.
 - A negative D-dimer in combination with low or moderate PE risk classification has a negative predictive value approaching 100%.
 - D-dimer can be falsely elevated with recent surgery, injury, malignancy, sepsis, diabetes, pregnancy, or other conditions where fibrin products are likely to be present.
- CT imaging has supplanted V/Q scanning since the latter is difficult to obtain quickly, does not provide a substantial cost savings, and does not diagnose other pulmonary pathology.
- The decision to terminate anticoagulation treatment after previous pulmonary embolism (PE) with absent or stable symptoms is based on clinical evaluation and risk factors.
- Repeat studies do not allow one the ability to distinguish new from residual clot, with luminal diameter and clot character poorly correlated to symptoms and ECHO findings.
- Two thirds of individuals with primary thromboembolism have residual pulmonary artery clot at 6 months and 50% remain at one year.
- Subsequent persistence or elevation of D-dimer is associated with increased risk of recurrent PE. ECHO and Right Heart Catheterization (RHC) can identify those with pulmonary hypertension. Yet, 1/2 of all have persistent or new pulmonary hypertension after primary thromboembolism and only half of this latter group has dyspnea at rest or exercise intolerance.
- Of note, pregnancy is accompanied by a progressive increase in D-dimer levels and as such, D-Dimer levels may not be helpful to rule-in or rule-out DVT/PE in pregnancy.^{11,12}

Modality	Fetal radiation exposure in mGy
CXR	0.002-0.1
V/Q	0.32 – 0.74
CTPA	0.03 – 0.66

- Compared with V/Q scan, computed tomography pulmonary angiography (CTPA), is associated with a higher radiation dose to the mother: the calculated doses to breast and lung tissue have been estimated to range from 10 to 60 mGy and 39.5 mGy, respectively with CTPA as compared with 0.98 to 1.07 mGy and 5.7 to 13.5 mGy, respectively with V/Q scan.¹²

References (CH-25)

v2.0.2024

1. Canonico M, Plu-Bureau G, Lowe GD, Scarabin PY. Hormone replacement therapy and risk of venous thromboembolism in postmenopausal women: systematic review and meta-analysis. *BMJ*. 2008;336(7655):1227-1231. doi:10.1136/bmj.39555.441944.BE
2. Fedullo PF, Auger WR, Kerr KM, Rubin LJ. Chronic thromboembolic pulmonary hypertension. *N Engl J Med*. 2001;345(20):1465-1472. doi:10.1056/NEJMra010902
3. Kline JA, Steuerwald MT, Marchick MR, Hernandez-Nino J, Rose GA. Prospective evaluation of right ventricular function and functional status 6 months after acute submassive pulmonary embolism: frequency of persistent or subsequent elevation in estimated pulmonary artery pressure. *Chest*. 2009;136(5):1202-1210. doi:10.1378/chest.08-2988
4. Nijkeuter M, Hovens MM, Davidson BL, Huisman MV. Resolution of thromboemboli in patients with acute pulmonary embolism: a systematic review. *Chest*. 2006;129(1):192-197. doi:10.1378/chest.129.1.192
5. Palareti G, Cosmi B, Legnani C, et al. D-dimer testing to determine the duration of anticoagulation therapy [published correction appears in *N Engl J Med*. 2006 Dec 28;355(26):2797]. *N Engl J Med*. 2006;355(17):1780-1789. doi:10.1056/NEJMoa054444
6. Wells PS, Anderson DR, Rodger M, et al. Excluding pulmonary embolism at the bedside without diagnostic imaging: management of patients with suspected pulmonary embolism presenting to the emergency department by using a simple clinical model and d-dimer. *Ann Intern Med*. 2001;135(2):98-107. doi:10.7326/0003-4819-135-2-200107170-00010
7. Wolf SJ, McCubbin TR, Feldhaus KM, Faragher JP, Adcock DM. Prospective validation of Wells Criteria in the evaluation of patients with suspected pulmonary embolism. *Ann Emerg Med*. 2004;44(5):503-510. doi:10.1016/j.annemergmed.2004.04.002
8. van Belle A, Büller HR, Huisman MV, et al. Effectiveness of managing suspected pulmonary embolism using an algorithm combining clinical probability, D-dimer testing, and computed tomography. *JAMA*. 2006;295(2):172-179. doi:10.1001/jama.295.2.172
9. Expert Panels on Cardiac and Thoracic Imaging; Kirsch J, Brown RKJ, et al. ACR Appropriateness Criteria® Acute Chest Pain-Suspected Pulmonary Embolism. *J Am Coll Radiol*. 2017;14(5S):S2-S12. doi:10.1016/j.jacr.2017.02.027
10. Kearon C, Akl EA, Ornelas J, et al. Antithrombotic Therapy for VTE Disease: CHEST Guideline and Expert Panel Report [published correction appears in *Chest*. 2016 Oct;150(4):988]. *Chest*. 2016;149(2):315-352. doi:10.1016/j.chest.2015.11.026
11. American College of Obstetricians and Gynecologists' Committee on Practice Bulletins—Obstetrics. ACOG Practice Bulletin No. 196: Thromboembolism in Pregnancy [published correction appears in *Obstet Gynecol*. 2018 Oct;132(4):1068]. *Obstet Gynecol*. 2018;132(1):e1-e17. doi:10.1097/AOG.0000000000002706
12. Leung AN, Bull TM, Jaeschke R, et al. An official American Thoracic Society/Society of Thoracic Radiology clinical practice guideline: evaluation of suspected pulmonary embolism in pregnancy. *Am J Respir Crit Care Med*. 2011;184(10):1200-1208. doi:10.1164/rccm.201108-1575ST
13. Lim W, Le Gal G, Bates SM, et al. American Society of Hematology 2018 guidelines for management of venous thromboembolism: diagnosis of venous thromboembolism. *Blood Adv*. 2018;2(22):3226-3256. doi:10.1182/bloodadvances.2018024828
14. Rivera-Lebron B, McDaniel M, Ahrar K, et al. Diagnosis, Treatment and Follow Up of Acute Pulmonary Embolism: Consensus Practice from the PERT Consortium. *Clin Appl Thromb Hemost*. 2019;25:1076029619853037. doi:10.1177/1076029619853037
15. Deroncourt PR, Felder GJ, Royal HD, et al. Ventilation-Perfusion Scan: A Primer for Practicing Radiologists. *Radiographics*. 2021;41(7):2047-2070. doi:10.1148/rg.2021210060

Pulmonary Hypertension (CH-26)

Guideline

Pulmonary Hypertension (CH-26.1)

Pulmonary Hypertension (CH-26.1)

CH.PH.0026.1.A

v2.0.2024

- See the [Pulmonary Artery Hypertension \(PAH\) – Indications \(CD-8.1\)](#)

Subclavian Steal Syndrome (CH-27)

Guideline

Subclavian Steal Syndrome – General (CH-27.0)

Subclavian Steal Syndrome (CH-27.1)

References (CH-27)

Subclavian Steal Syndrome – General (CH-27.0)

CH.SS.0027.0.A

v2.0.2024

- Occurs from blood flowing up the contralateral vertebral artery to the basilar artery and retrograde down the ipsilateral vertebral artery (reversal of flow) to supply collateral circulation to the arm on the side and past the stenotic or occluded proximal subclavian or innominate artery to perfuse that arm.

Subclavian Steal Syndrome (CH-27.1)

CH.SS.0027.1.A

v2.0.2024

- Initial evaluation should include clinical findings satisfying the symptom complex (See **Background and Supporting Information**) and initial imaging with Carotid duplex study (CPT® 93882).
 - Carotid duplex study (CPT® 93882) is the initial and definitive imaging study
 - Reversal of flow in the ipsilateral vertebral artery.
 - If the carotid duplex is not diagnostic for reversal of flow in the ipsilateral vertebral artery, then neurological symptoms should be evaluated according to the Head guidelines.
- MRA Neck and Chest (CPT® 70548 and CPT® 71555) or CTA Neck and Chest (CPT® 70498 and CPT® 71275) can be performed for diagnosis in individuals with symptoms of vertebrobasilar ischemia with either of the following:
 - Clinical exam and duplex study are positive or indeterminate
 - Preoperative studies if they will substitute for invasive angiography.
- MRA Upper extremity (CPT® 73225) or CTA Upper extremity (CPT® 73206) can be performed in symptomatic individuals if needed to exclude pathology distal to the subclavian artery and if they will substitute for invasive angiography.
- See **Stroke/TIA (HD-21.1)** (for vertebrobasilar stroke) in the Head Imaging Guidelines.
- Treatment options include ligation of the ipsilateral vertebral artery, aorta-subclavian artery bypass graft, or subclavian endarterectomy.

Background and Supporting Information

- While MRA does not expose the individual to radiation, CTA should be considered the test of choice for subclavian steal syndrome given its superior spatial and temporal resolution.
- Satisfying the symptom complex
 - Physical examination findings suggestive of subclavian stenosis include a discrepancy of >15 mmHg in blood pressure readings taken in both upper extremities, delayed or decreased amplified pulses in the affected side, and a bruit in the supraclavicular area on the affected side.
 - Symptoms include vertebral basilar artery insufficiency, vertigo, limb paresis, and paresthesias. Bilateral cortical visual disturbances, ataxia, syncope, and dysarthria occur less frequently.
 - Symptoms of cerebral ischemia may be produced by exercise of the affected arm

References (CH-27)

v2.0.2024

1. Van Grimberge F, Dymarkowski S, Budts W, Bogaert J. Role of magnetic resonance in the diagnosis of subclavian steal syndrome. *J Magn Reson Imaging*. 2000;12(2):339-342. doi:10.1002/1522-2586(200008)12:2<339::aid-jmri17>3.0.co;2-8
2. Potter BJ, Pinto DS. Subclavian steal syndrome. *Circulation*. 2014;129(22):2320-2323. doi:10.1161/CIRCULATIONAHA.113.006653

Superior Vena Cava (SVC) Syndrome (CH-28)

Guideline

SVC Syndrome (CH-28.1)

References (CH-28)

SVC Syndrome (CH-28.1)

CH.SV.0028.1.A
v2.0.2024

- CT Chest with contrast (CPT® 71260) for the evaluation of suspected SVC syndrome based on the facial cyanosis and upper extremity swelling without anasarca.^{1,2}
- MRV (CPT® 71555) or CTV (CPT® 71275) Chest when stenting of the SVC is being considered.^{1,2}

Background and Supporting Information

- SVC syndrome is caused by acute or subacute, intrinsic or extrinsic obstruction of the SVC, most commonly from lung cancer (80-85%) and less often benign (fibrosis, mediastinitis, indwelling devices). Other symptoms include dyspnea, headache and dizziness.

References (CH-28)

v2.0.2024

1. Wilson LD, Detterbeck FC, Yahalom J. Clinical practice. Superior vena cava syndrome with malignant causes [published correction appears in *N Engl J Med*. 2008 Mar 6;358(10):1083]. *N Engl J Med*. 2007;356(18):1862-1869. doi:10.1056/NEJMcp067190
2. Lepper PM, Ott SR, Hoppe H, et al. Superior vena cava syndrome in thoracic malignancies. *Respir Care*. 2011;56(5):653-666. doi:10.4187/respcare.00947

Elevated Hemidiaphragm (CH-30)

Guideline

Elevated Hemidiaphragm (CH-30.1)

References (CH-30)

Elevated Hemidiaphragm (CH-30.1)

CH.EH.0030.1.A

v2.0.2024

- CT Chest with contrast (CPT® 71260) and/or CT Neck with contrast (CPT® 70491) with new diaphragmatic paralysis after:^{1,2}
 - Previous chest x-rays are available and reviewed to determine if the diaphragmatic elevation is a new finding, and/or
 - Fluoroscopic examination (“sniff test”) to differentiate true paralysis from weakness.
- CT Abdomen with contrast (CPT® 74160) to rule out liver or abdominal process if CT Chest is negative.^{1,2}
- Repeat advanced imaging studies in the absence of new signs or symptoms are not indicated.

Background and Supporting Information

- The right hemidiaphragm sits about 2 cm higher than the left.
- “Eventration” is thin membranous replacement of muscle, usually on the right, as the most common cause of elevation.
- Any injury to the phrenic nerve from neck to diaphragm can lead to paralysis.
- Common phrenic causes are traumatic or surgical injury or malignancy involving the mediastinum.
- Any loss of lung volume or increased abdominal pressure can lead to diaphragm elevation.

References (CH-30)

v2.0.2024

1. Ko MA, Darling GE. Acquired paralysis of the diaphragm. *Thorac Surg Clin*. 2009;19(4):501-510. doi:10.1016/j.thorsurg.2009.08.011
2. Qureshi A. Diaphragm paralysis. *Semin Respir Crit Care Med*. 2009;30(3):315-320. doi:10.1055/s-0029-1222445

Thoracic Outlet Syndrome (TOS) (CH-31)

Guideline

Thoracic Outlet Syndrome (CH-31.1)

References (CH-31)

Thoracic Outlet Syndrome (CH-31.1)

CH.TO.0031.1.A

v2.0.2024

- Chest x-ray should be performed initially in all cases, after the onset of symptoms or if there has been a change in symptoms, since it can identify bony abnormalities or other causes of upper extremity pain.^{1,2}
- Preferred imaging modality in individuals with suspected TOS varies depending upon suspected etiology. More than one type of imaging may be required for diagnosis in complex cases.^{1,2}
- Neurogenic Thoracic Outlet Syndrome:
 - See **Brachial Plexus (PN-4.1)** in the Peripheral Nerve Disorders Imaging Guidelines
- Venous Thoracic Outlet Syndrome:
 - CT Chest with Contrast (CPT[®] 71260) (preferred study) or MRI Chest with contrast (CPT[®] 71551) or CTV Chest (CPT[®] 71275)
- Arterial Thoracic Outlet Syndrome:
 - CTA Chest (CPT[®] 71275) (preferred study) or MRA Chest (CPT[®] 71555) (preferred study) or CT Chest either without or with contrast (CPT[®] 71250 or CPT[®] 71260) or MRI Chest with contrast (CPT[®] 71551)
- CT Chest with contrast (CPT[®] 71260) or CT Neck with contrast (CPT[®] 70491) can be used in place of MRI for:
 - Suspected anomalous ribs or fractures, as bone anatomy is more easily definable with CT.
 - Postoperative individuals in whom there is a question regarding a remnant first rib.
 - Dialysis-dependent renal failure, claustrophobia, or implanted device incompatibility.
- See **Brachial Plexus (PN-4.1)** in the Peripheral Nerve Disorders Imaging Guidelines.

Background and Supporting Information

- TOS refers to compression of the subclavian vessels and/or brachial plexus at the thoracic outlet of the chest (the area bounded by the two scalene muscles and the first rib).
- There are 3 types, with neurogenic causes seen in 80%, venous causes (also called effort thrombosis) found in 15% and the remaining 5% being arterial in etiology.
- Since this is such a rare entity and diagnosis is difficult, specialist evaluation by a vascular surgeon or thoracic surgeon is helpful in determining the appropriate imaging pathway.

References (CH-31)

v2.0.2024

1. Raptis CA, Sridhar S, Thompson RW, Fowler KJ, Bhalla S. Imaging of the Patient with Thoracic Outlet Syndrome. *Radiographics*. 2016;36(4):984-1000. doi:10.1148/rg.2016150221
2. Expert Panels on Vascular Imaging, Thoracic Imaging, and Neurological Imaging, Zurkiya O, Ganguli S, et al. ACR Appropriateness Criteria® Thoracic Outlet Syndrome. *J Am Coll Radiol*. 2020;17(5S):S323-S334. doi:10.1016/j.jacr.2020.01.029

Lung Transplantation (CH-32)

Guideline

Pre-Transplant Imaging Studies (CH-32.1)

Post-Transplant Imaging Studies (CH-32.2)

Reference (CH-32)

Pre-Transplant Imaging Studies (CH-32.1)

CH.LT.0032.1.A

v2.0.2024

- Individuals on the waiting list or being considered for the lung transplant can undergo advanced imaging per that institution's protocol as long as the studies do not exceed the following:
 - CT Chest with and without contrast (CPT® 71270), CT Chest with contrast (CPT® 71260), or CT Chest without contrast (CPT® 71250)
 - ECHO
 - Imaging Stress Test (MPI, SE, MRI) or Heart Catheterization (Right and Left); Heart catheterization can also be done after a positive stress test.
 - CTA Chest and/or CTA Abdomen and Pelvis and/or CTA Aorta with bilateral lower extremity run-off is indicated without initial ABI's and/or arterial duplex for the following individuals:
 - Prior abdominal or lower extremity vascular intervention (any timeframe is acceptable)
 - Known peripheral artery disease (PAD) from prior imaging
 - Current symptoms of claudication, rest pain or gangrene
 - CTA Chest and/or CTA Abdomen and Pelvis and/or CTA Aorta with bilateral lower extremity run-off is indicated after initial ABI's and/or arterial duplex for the following individuals:
 - Initial ABI's and/or arterial duplex suggest the presence of PAD per one of the following:
 - ABI of <0.9
 - Presence of plaque
 - Presence of vascular calcification, stenosis or occlusion
 - Small vessel size on the duplex
 - CT Abdomen and Pelvis with or without contrast (CPT® 74177 or CPT® 74176) for determining extracorporeal membrane oxygenation (ECMO) candidacy
- Other studies that will be considered include V/Q scan, Six Minute Walk Test.
- See **Transplant (CD-1.6)** in the Cardiac Imaging Guidelines.

Post-Transplant Imaging Studies (CH-32.2)

CH.LT.0032.2.A

v2.0.2024

- CT Chest with and without contrast (CPT® 71270), CT Chest with contrast (CPT® 71260), or CT Chest without contrast (CPT® 71250) is supported for:²
 - Initial post-transplant follow-up.
 - Suspected complication, either surgical, medical or infectious, (See **Background and Supporting Information**)
 - Worsening PFT's
 - New finding on other imaging, including chest x-ray
- See **Transplant (CD-1.6)** in the Cardiac Imaging Guidelines.

Background and Supporting Information

- Complications from lung transplantation are a major cause of morbidity and mortality.
- The three main categories of complications are surgical, medical and infectious.
 - Surgical complications include; anastomotic complications, bronchial dehiscence, bronchial stenosis, pneumothorax, hemothorax, hematoma, wound dehiscence and infection.
 - Medical complications include; primary graft dysfunction, pulmonary embolism and pulmonary infarction, Tracheobronchomalacia, posttransplant lymphoproliferative disease, primary disease recurrence, acute and chronic allograft rejection, including bronchiolitis obliterans and restrictive allograft syndrome.
 - Infectious complications include; hospital and community acquired nonmycobacterial pulmonary infections, mycobacterial infections, fungal infections, and viral infections, (CMV most common).

Reference (CH-32)

v2.0.2024

1. Ng YL, Paul N, Patsios D, et al. Imaging of lung transplantation: review. *AJR Am J Roentgenol.* 2009;192(3 Suppl):S1-S19. doi:10.2214/AJR.07.7061
2. DeFreitas MR, McAdams HP, Azfar Ali H, Iranmanesh AM, Chalian H. Complications of Lung Transplantation: Update on Imaging Manifestations and Management. *Radiol Cardiothorac Imaging.* 2021;3(4):e190252. Published 2021 Aug 26. doi:10.1148/ryct.2021190252
3. Mb D, Bao B, Brechot N, et al. Extracorporeal Life Support Organization (ELSO) Ultrasound Guidance for Extra-Corporeal Membrane Oxygenation Veno-Venous ECMO Specific Guidelines. http://www.else.org/Portals/0/Files/elseo_Ultrasoundguidance_vvecmo_guidelines_MAY2015.pdf.
4. Bonicolini E, Martucci G, Simons J, et al. Limb ischemia in peripheral veno-arterial extracorporeal membrane oxygenation: a narrative review of incidence, prevention, monitoring, and treatment. *Crit Care.* 2019;23(1):266. Published 2019 Jul 30. doi:10.1186/s13054-019-2541-3
5. Hoetzenecker K, Benazzo A, Stork T, et al. Bilateral lung transplantation on intraoperative extracorporeal membrane oxygenator: An observational study. *J Thorac Cardiovasc Surg.* 2020;160(1):320-327.e1. doi:10.1016/j.jtcvs.2019.10.155
6. Faccioli E, Terzi S, Pangoni A, et al. Extracorporeal membrane oxygenation in lung transplantation: Indications, techniques and results. *World J Transplant.* 2021;11(7):290-302. doi:10.5500/wjt.v11.i7.290

Lung Cancer Screening (CH-33)

Guideline

U.S. Preventive Services Task Force: Lung Cancer Screening (Commercial and Medicaid) (CH-33.1)

National Coverage Determination (NCD) for Lung Cancer Screening with Low Dose Computed Tomography (LDCT) (Medicare) (CH-33.2)

Incidental Pulmonary Nodules Detected on Low Dose CT Chest (LDCT) Images (CH-33.3)

References (CH-33)

U.S. Preventive Services Task Force: Lung Cancer Screening (Commercial and Medicaid) (CH-33.1)

CH.CS.0033.1.A

v2.0.2024

- Low-dose CT Chest (CPT® 71271) for lung cancer screening annually if all of the following criteria are met:

Screening Indications – Commercial and Medicaid	Imaging Study
<ul style="list-style-type: none"> • All criteria below must be met: <ul style="list-style-type: none"> • Individual has not received a low-dose CT lung screening in less than 12 months; and • Individual has NO health problems that substantially limit life expectancy or the ability or willingness to have curative lung surgery*; and • Individual is between 50 and 80 years of age; and • Individual has at least a 20 pack-year history of cigarette smoking; and • Currently smokes or quit within the past ≤15 years 	Low-Dose CT Chest without contrast (CPT® 71271)

For incidental nodule(s) detected on previous imaging but do not qualify for LDCT, Lung Cancer Screening See **Solitary Pulmonary Nodule (SPN) (CH-16)**, for CPT® 71250 and CPT® 71260.

*This is based on a range of chest or other organ signs, symptoms or conditions which would question the member’s ability to undergo surgical or non-surgical treatment if a lung cancer was discovered. For example, congestive heart failure, advanced cancer from another site or a member with COPD who uses oxygen when ambulating, would be examples of conditions that would “substantially limit life expectancy.” Conversely, stable COPD and its symptoms, including cough, shortness of breath would not “substantially limit life expectancy.”

National Coverage Determination (NCD) for Lung Cancer Screening with Low Dose Computed Tomography (LDCT) (Medicare) (CH-33.2)

CH.CS.0033.2.A

v2.0.2024

- Medicare criteria for LDCT for Lung Cancer Screening (CPT® 71271) See **NCD 210.14**

Incidental Pulmonary Nodules Detected on Low Dose CT Chest (LDCT) Images (CH-33.3)

CH.CS.0033.3.A

v2.0.2024

- Any Lung-RADS less than 1 year interval follow-up is coded as Low-Dose CT Chest (CPT® 71250) (Not CPT® 71271 which is ONLY the annual screen)
- For lung nodules, including incidental findings from studies other than screening LDCT, or if no longer qualify for screening LDCT, See **Incidental Pulmonary Nodules Detected on CT Images (CH-16.2)**

Lung-RADS Primary Category/Category Descriptor*	Management
0: Incomplete	If findings suggestive of an inflammatory or infectious process, follow-up with LDCT (CPT 71250) in 1-3 months
2: Benign appearance or behavior - very low likelihood of becoming a clinically active cancer due to size or lack of growth	Annual LDCT screening (CPT® 71271) in 12 months
3: Probably benign finding(s) - short term follow-up suggested; includes nodules with a low likelihood of becoming a clinically active cancer	6 month LDCT (CPT® 71250) and if unchanged on this CT it is coded as category 2 and returned to annual LDCT screening (CPT® 71271) in 12 months
4A: Suspicious - Findings for which additional diagnostic testing and/or tissue sampling is recommended	PET/CT (CPT® 78815) when there is a ≥8 mm solid nodule or solid-component Follow-up with LDCT (CPT® 71250) in 3 months and if stable or decreased in size on this CT, it is coded as category 3 with follow-up LDCT (71250) at 6 months, if stable or decreased in size on this CT, return to annual LDCT screening (CPT® 71271) in 12 months

Lung-RADS Primary Category/Category Descriptor*	Management
4B or 4X: Suspicious - Findings for which additional diagnostic testing and/or tissue sampling is recommended	<p>CT Chest with or without contrast, PET/CT (CPT® 78815) and/or tissue sampling depending on the probability of malignancy and comorbidities. PET/CT (CPT® 78815) when there is a ≥ 8 mm solid component.</p> <p>If there is low suspicion of lung cancer, follow-up with LDCT (CPT® 71250) in 3 months with another LDCT (CPT® 71250) in 6 months and if unchanged on this CT return to annual LDCT screening (CPT® 71271) in 12 months</p>

- For those that no longer qualify for annual LDCT for lung cancer screening but have known lung nodules, follow criteria for follow-up under CH-16. For example, a nodule that is new on the last screening LDCT may warrant continued diagnostic CT evaluation per **CH-16.2**.

*Please see note section of the official ACR Lung-RADS V2022 for additional details concerning specific recommendations-<https://www.acr.org/-/media/ACR/Files/RADS/Lung-RADS/Lung-RADS-2022.pdf>

References (CH-33)

v2.0.2024

1. Christensen J, Prosper AE, Wu CC, et al. ACR Lung-RADS v2022: Assessment Categories and Management Recommendations. *Chest*. 2024;165(3):738-753. doi:10.1016/j.chest.2023.10.028.
2. US Preventive Services Task Force. Screening for Lung Cancer: US Preventive Services Task Force Recommendation Statement. *JAMA*. 2021;325(10):962–970. doi:10.1001/jama.2021.1117.
3. CMS Decision Memo for Lung Cancer Screening with Low Dose Computed Tomography (LDCT) (210.14) Effective Date of this Version 2/5/2015.
4. Lung-RADS™ Version 1.1 Assessment Categories Release date: 2022.
<https://www.acr.org/-/media/ACR/Files/RADS/Lung-RADS/Lung-RADS-2022.pdf>.

Table of Contents

Guideline

- General Guidelines (HD-1)**
- Taste and Smell Disorders (HD-2)**
- Ataxia (HD-3)**
- Mental Health Disorders and Mental Status Change (HD-4)**
- Chiari and Skull-Base Malformations (HD-5)**
- Facial Palsy (Bell's Palsy)/Hemifacial Spasm (HD-6)**
- Recurrent Laryngeal Palsy/Vocal Cord Palsy (HD-7)**
- Dementia (HD-8)**
- Epilepsy/Seizures (HD-9)**
- Trigeminal Neuralgia and other Centrally Mediated Facial Pain Syndromes (HD-10)**
- Headache (HD-11)**
- Aneurysm and AVM (HD-12)**
- Head and Facial Trauma (HD-13)**
- CNS and Head Infection/Neuro-COVID-19 (HD-14)**
- Movement Disorders (HD-15)**
- Multiple Sclerosis (MS) and Related Conditions (HD-16)**
- Papilledema/Pseudotumor Cerebri (HD-17)**
- Paresthesias and/or Weakness (HD-18)**
- Pituitary (HD-19)**
- Scalp and Skull (HD-20)**
- Stroke/TIA (HD-21)**
- Cerebral Vasculitis (HD-22)**
- Dizziness, Vertigo and Syncope (HD-23)**
- Other Imaging Studies (HD-24)**
- Epistaxis (HD-25)**
- Mastoid Disease or Ear Pain (HD-26)**
- Hearing Loss and Tinnitus (HD-27)**
- Neurosurgical Imaging (HD-28)**
- Sinus and Facial Imaging (HD-29)**
- Temporomandibular Joint Disease (TMJ) and Dental/Periodontal/Maxillofacial Imaging (HD-30)**
- Eye Disorders and Visual Loss (HD-32)**
- Acoustic Neuroma and Other Cerebellopontine Angle Tumors (HD-33)**
- Pineal/Colloid Cysts (HD-34)**
- Arachnoid Cysts (HD-35)**
- Nuclear Medicine (HD-36)**

Sleep-Related Imaging (HD-37)

General Guidelines (HD-1)

Guideline

Abbreviations for Head Imaging Guidelines

General Guidelines (HD-1.0)

General Guidelines – Anatomic Issues (HD-1.1)

General Guidelines – Modality (HD-1.2)

General Guidelines – MRI Brain (HD-1.3)

General Guidelines – CT Head (HD-1.4)

General Guidelines – CT and MR Angiography (CTA and MRA) (HD-1.5)

General Guidelines – PET Coding Notes (HD-1.6)

General Guidelines – Other Imaging Situations (HD-1.7)

References (HD-1)

Abbreviations for Head Imaging Guidelines

v3.0.2024

Abbreviations for Head Imaging Guidelines	
ACTH	adrenocorticotrophic hormone
AD	Alzheimer’s Disease
ADH	antidiuretic hormone
AION	arteritic ischemic optic neuritis
AVM	arteriovenous malformation
CBCT	Cone-beam computerized tomography
CMV	Cytomegalovirus
CSF	cerebrospinal fluid
CT	computed tomography
CTA	computed tomography angiography
DNA	deoxyribonucleic acid
DWI	diffusion weighted imaging (for MRI)
EEG	electroencephalogram
ENT	Ear, Nose, Throat
ESR	erythrocyte sedimentation rate
FDG	fluorodeoxyglucose
FSH	follicle-stimulating hormone

Head Imaging Guidelines

Abbreviations for Head Imaging Guidelines

FTD	Frontotemporal Dementia
GCA	giant cell arteritis
GCS	Glasgow Coma Scale
HIV	human immunodeficiency virus
LH	luteinizing hormone
MMSE	mini mental status examination
MRA	magnetic resonance angiography
MRI	magnetic resonance imaging
MRN	magnetic resonance neurography
MS	multiple sclerosis
MSI	magnetic source imaging
NAION	non-arteritic ischemic optic neuritis
NPH	normal pressure hydrocephalus
PET	positron emission tomography
PML	progressive multifocal leukoencephalopathy
PNET	primitive neuro ectodermal tumor
PWI	perfusion weighted imaging (for MRI)
SAH	subarachnoid hemorrhage
SIADH	Syndrome of Inappropriate Antidiuretic Hormone Secretion

Abbreviations for Head Imaging Guidelines

SLE	systemic lupus erythematosus
TIA	transient ischemic attack
TMJ	temporomandibular joint disease
TSH	thyroid-stimulating hormone
VBI	vertebrobasilar insufficiency
VP	ventriculoperitoneal
XRT	radiation therapy

General Guidelines (HD-1.0)

HD.GG.0001.0.A

v3.0.2024

- A pertinent clinical evaluation including a detailed history, physical examination including a neurological examination since the onset or change in symptoms, and appropriate laboratory studies should be performed prior to considering the use of an advanced imaging (CT, MR, Nuclear Medicine) procedure.
 - A pertinent clinical evaluation furnished via telehealth since the onset or change in symptoms, is treated the same as an in-person clinical evaluation.
 - An exception to a pertinent clinical evaluation can be made if the individual is undergoing a guideline-supported, scheduled follow-up imaging evaluation.
 - Scheduled follow-up of known problems such as, multiple sclerosis, tumors, or hydrocephalus, scheduled surveillance with no new symptoms, screening asymptomatic individual due to family history or otherwise meet criteria for repeat imaging, as well as appropriate laboratory studies and non-advanced imaging modalities
 - A detailed neurological exam is required prior to advanced imaging except in the following scenarios:
 - Tinnitus, TMJ, sinus or mastoid disease, ear pain, hearing loss, eye disease, pituitary disease, and epistaxis. (A pertinent clinical evaluation since onset of symptoms is still required)
 - The request is from a neurologist, neurosurgeon, neuro-ophthalmologist, endocrinologist, gynecologist, otolaryngologist, or ophthalmologist who has seen the individual since onset of symptoms, or any provider in consultation with one of the above specialists.
- Other meaningful contact (telephone call, electronic mail or messaging) since the onset or change in symptoms, with an established individual can substitute for a face-to-face clinical evaluation
- CT head contrast as requested (CPT[®] 70450 OR CPT[®] 70460 OR CPT[®] 70470) is supported when MRI is contraindicated.

General Guidelines – Anatomic Issues (HD-1.1)

HD.GG.0001.1.A

v3.0.2024

- If two studies using the same modality both cover the anatomic region of clinical interest, only one is generally needed, with the exception of the following scenarios:
 - CT Maxillofacial (CPT[®] 70486, CPT[®] 70487, or CPT[®] 70488) or CT Orbit/Temporal bone (CPT[®] 70480, CPT[®] 70481, or CPT[®] 70482): both cover the structures of the orbits, sinuses, and face. Two separate imaging studies are only supported if there is suspicion of simultaneous involvement of more posterior lesions, especially of the region involving the middle or inner ear.
 - Pituitary Gland: one study (either MRI Brain [CPT[®] 70553] or MRI Orbit, Face, Neck [CPT[®] 70543]) is adequate to report the imaging of the pituitary. If a previous routine MRI Brain was reported to show a possible pituitary tumor, a repeat MRI with dedicated pituitary protocol is supported.
 - Internal Auditory Canal: (IAC) MRI can be reported as a limited study with one code from the set (CPT[®] 70540, CPT[®] 70542, or CPT[®] 70543), but should not be used in conjunction with MRI Brain codes (CPT[®] 70551, CPT[®] 70552, or CPT[®] 70553) if IAC views are performed as part of the brain.
 - Mandible (jaw): CT Maxillofacial (CPT[®] 70486, CPT[®] 70487, or CPT[®] 70488) or CT Neck (CPT[®] 70490, CPT[®] 70491, or CPT[®] 70492) can be used to report imaging of the mandible. CT Neck will also image the submandibular space.
 - If MRI is indicated, MRI Orbit/Face/Neck (CPT[®] 70540, CPT[®] 70542, or CPT[®] 70543) can be used to report imaging of the mandible and submandibular space.
 - MRI Temporomandibular Joint(s) (TMJ) is reported as CPT[®] 70336. This code is inherently bilateral and should not be reported twice on the same date of service.
- Cranial Neuropathies
 - MRI Brain without and with contrast (CPT[®] 70553) or without contrast (CPT[®] 70551) is indicated for all individuals with new or worsening specific cranial nerve abnormalities.²⁹
 - MRI Orbit/Face/Neck without and with contrast (CPT[®] 70543) or without contrast (CPT[®] 70540) is also indicated for individuals with abnormalities in cranial nerves I, II, III, IV, V, VI, VII, IX, X, XI, or XII^{13,29}
 - CT Neck with contrast (CPT[®] 70491) is supported for evaluation of abnormalities involving cranial nerves IX, X, XII, or XII²⁹

- Imaging of the Brain and Orbit, Face and/or Neck may be performed concurrently when requested.²⁹
- For specific cranial neuropathies²⁹, see the corresponding guideline section listed below:
 - CN I: Olfactory nerve (see **Taste and Smell Disorders (HD-2.1)**)
 - CN II, III, IV, VI: Optic, Oculomotor, Trochlear and Abducens (see **Eye Disorders and Visual Loss (HD-32.1)**)
 - CN V: Trigeminal nerve (see **Trigeminal Neuralgia and other Centrally Mediated Facial Pain Syndromes (HD-10.1)**)
 - CN VII: Facial nerve (see **Facial Palsy (HD-6.1)**)
 - CN VIII: Vestibulocochlear nerve (see **Dizziness/Vertigo (HD-23.1)**, **Hearing Loss (HD 27.1)**, **Tinnitus (HD 27.2)**, **Acoustic Neuroma and Other Cerebellopontine Angle Tumors (HD 33.1)**). For isolated nystagmus (see **Eye Disorders and Visual Loss (HD-32.1)**)
 - CN IX: Glossopharyngeal nerve (see **Glossopharyngeal Neuralgia/ Glossopharyngeal Neuropathy (HD-10.2)**)
 - CN X: Vagal nerve, imaging as detailed above (see also **Recurrent Laryngeal Palsy/Vocal Cord Palsy (Neck-7.1)**)
 - CN XI: Spinal accessory nerve, imaging as indicated above
 - CN XII: Hypoglossal nerve, imaging as indicated above
- For cranial neuropathies, whether isolated or multiple, due to clinically suspected stroke and/or vascular dissection (see **General Guidelines - CT and MR Angiography (CTA and MRA) (HD-1.5)**, **Headache and Suspected Vascular Dissection (HD-11.1)** and **Stroke/TIA (HD-21.1)**)

Background and Supporting Information

If a detailed clinical evaluation is unable to localize the site of the lesion, imaging of the entire course of the relevant cranial nerve is required, as cranial neuropathy can result from pathology affecting the nerve fibers at any point along the course of the nerve, from the cranial nerve origin in the brainstem to the end organ supplied by the nerve, requiring multiple imaging modalities.

Number	Cranial Nerve Name	Nerve dysfunction on exam	Guideline Section in HD
I	Olfactory (smell)	Anosmia, hyposmia, parosmia, phantosmia	2

Number	Cranial Nerve Name	Nerve dysfunction on exam	Guideline Section in HD
II	Optic (vision)	Optic neuritis, disc edema, papilledema, afferent pupillary defect APD)	16, 17, 32
III	Oculomotor (eye and pupil movement)	Eye "down and out", +/- dilated pupil, ptosis, diplopia	32
IV	Trochlear (depresses the eye)	Inability to depress the eye, diplopia	32
V	Trigeminal (sensation, mastication, taste)	Pain, numbness, corneal reflex loss, jaw deviation, trigeminal neuralgia, loss of taste	10
VI	Abducens (lateral movement of the eye)	Eye turns medially, inability to abduct, lateral rectus palsy, diplopia	32
VII	Facial (movement facial muscles, taste at 2/3, salivation/lacrimation)	Inability to close eyelid, smile, nasolabial fold flattening, hyperacusis, impaired taste, salivation, lacrimation	6
VIII	Auditory, Vestibular, Vestibulochochlear (hearing and balance)	Hearing loss, tinnitus, vertigo, nystagmus, abnormal gait/ balance, sway on Romberg	23, 27, 33

Number	Cranial Nerve Name	Nerve dysfunction on exam	Guideline Section in HD
IX	Glossopharyngeal (swallow, sensation, pharynx, posterior 1/3 tongue, parotid salivary gland)	Depressed gag reflex and palate, dysphagia, uvula deviation, throat pain	10.2
X	Vagus (swallow, speech, parasympathetic to heart, lungs, GI tract)	Vocal cord paralysis, recurrent laryngeal nerve palsy, spasmodic dysphonia	7.1, 1.1
XI	Spinal Accessory (motor function neck/shoulder)	Sternocleidomastoid (SCM) weakness when turning head opposite, shoulder elevation, winging scapula	1.1
XII	Hypoglossal (tongue movement)	Tongue deviation, atrophy, fasciculation	1.1
INO	Internuclear Ophthalmoplegia (lesion of medial longitudinal fasciculus, CN III, CN VI)	Impaired adduction of ipsilateral eye with nystagmus of abducting eye	16, 21, 22
Horner Syndrome	Disruption of sympathetic innervation to eye and face	Ptosis, miosis (constricted pupil), facial anhidrosis (absence of sweating)	32.2, 11.3

General Guidelines – Modality (HD-1.2)

HD.GG.0001.2.A

v3.0.2024

- MRI is preferable to CT for most indications. For exceptions, See **General Guidelines – CT Head (HD-1.4)**
- MRI for these indications following an initial CT:
 - MRI Brain without and with contrast (CPT[®] 70553) to follow-up abnormalities seen on CT Head without contrast (CPT[®] 70450) when a mass, lesion, or infection is found.
 - MRI Brain without contrast (CPT[®] 70551) or MRI Brain without and with contrast (CPT[®] 70553) (preferred) to follow-up abnormalities seen on CT Head without contrast (CPT[®] 70450) when there is suspected Multiple Sclerosis or other demyelinating disease.
 - MRI Brain without contrast (CPT[®] 70551) or MRI Brain without and with contrast (CPT[®] 70553) to follow up on stroke or TIA when initial CT Head was done on emergent basis.
 - MRI Brain without and with contrast (CPT[®] 70553) or MRI Brain without contrast (CPT[®] 70551) for evaluation of new onset seizures.

General Guidelines – MRI Brain (HD-1.3)

HD.GG.0001.3.A

v3.0.2024

- MRI Brain with contrast (CPT[®] 70552) should not be ordered except to follow-up on a very recent non-contrast MRI Brain.
- After an MRI Brain without contrast (CPT[®] 70551), a follow up MRI brain with contrast (CPT[®] 70552) may be performed at the discretion of a neurologist, a neurosurgeon, or a neuro-ophthalmologist, or any provider in consultation with a neurologist, neurosurgeon, or neuro-ophthalmologist, and/or at the recommendation of the radiologist.³²
- Gadolinium is relatively contraindicated in pregnancy, MRI Brain without contrast (CPT[®] 70551) is supported.³³
- The AMA CPT manual does not describe nor assign any minimum or maximum number of sequences for any CT or MRI study. Both MRI and CT imaging protocols are often influenced by the individual clinical situation of the individual and additional sequences are not uncommon. There are numerous MRI sequences that are performed to evaluate specific clinical questions, and this technology is constantly undergoing development. Additional sequences, however, are still performed and coded under the routine MRI Brain CPT[®] 70551, CPT[®] 70552, or CPT[®] 70553.

General Guidelines – CT Head (HD-1.4)

HD.GG.0001.4.A

v3.0.2024

- Scenarios in which MRI is contraindicated (i.e. pacemakers, ICDs, cochlear implants, aneurysm clips, orbital metallic fragments, etc.)
- In urgent cases, CT Head, contrast as requested is supported [CT Head without and with contrast (CPT[®] 70470), CT Head with contrast (CPT[®] 70460) or CT Head without contrast (CPT[®] 70450)]
- CT Head without contrast (CPT[®] 70450) is supported for:
 - Mass effect
 - Blood/blood products
 - Urgent/emergent settings due to availability and speed of CT
 - Trauma
 - Recent hemorrhage, whether traumatic or spontaneous
 - Bony structures of the head evaluations including dystrophic calcifications
 - Hydrocephalus evaluation and follow-up (some centers use limited non-contrast “fast or rapid MRI” (CPT[®] 70551) to minimize radiation exposure in children).
 - Prior to lumbar puncture in individuals with cranial complaints (without contrast) (CPT[®] 70450)
 - Evaluation of optic disc edema and/or papilledema, a non-contrast CT Head is useful to assess for space-occupying processes such as intracranial hemorrhage, mass effect, and hydrocephalus, See **Papilledema/Pseudotumor Cerebri (HD-17.1)** and **Eye Disorders and Visual Loss (HD-32.1)**

General Guidelines – CT and MR Angiography (CTA and MRA) (HD-1.5)

HD.GG.0001.5.A

v3.0.2024

- MRA Head may be performed without contrast (CPT[®] 70544), with contrast (CPT[®] 70545), or without and with contrast (CPT[®] 70546)
- MRA Neck may be done without contrast (CPT[®] 70547), with contrast (CPT[®] 70548), or without and with contrast (CPT[®] 70549), depending on facility preference and protocols and type of scanner
- CTA Head is performed without and with contrast (CPT[®] 70496)
- CTA Neck is performed with and without contrast (CPT[®] 70498)
- Indications for CTA or MRA Head and Neck vessels include, but are not limited to the following:^{12,24}
 - Pulsatile tinnitus
 - Hemifacial spasm if consideration for surgical decompression
 - Evaluation of stroke or TIA (see **Stroke/TIA (HD-21.1)**) including collateral assessment
 - Trigeminal neuralgia having failed medical therapy (see **Trigeminal Neuralgia and other Centrally Mediated Facial Pain Syndromes (HD-10.1)**)
 - Cerebral venous sinus thrombosis suspected with increased intracranial pressure (refractory headaches, papilledema, diagnosis of pseudotumor cerebri)
 - Aneurysm suspected with acute “thunderclap” headache syndrome and appropriate screening or evaluation of known subarachnoid hemorrhage and pseudoaneurysms (appropriate to limit CTA to include only the head to avoid unnecessary radiation to the individual)
 - Non-inflammatory vasculopathy, including radiation vasculopathy
 - Traumatic vascular injuries
 - Vascular malformations, vascular anatomic variants and fistulas
 - Arterial dissections
 - Tumors of vascular origin or involving vascular structures
 - Surgical and radiation therapy localization, planning and neuronavigation
 - Evaluation for vascular intervention and follow-up including postsurgical/posttreatment vascular complications
 - Intra-cranial pre-operative planning if there is concern of possible vascular involvement or risk for vascular complication from procedure
 - Vasculitis and collagen vascular disease

- Eagle Syndrome - Dynamic/positional CTA to assess for vascular compression (also known as bow-hunter's syndrome)¹² (see **Eagle Syndrome (Neck-10.3)**)
- NOTE: Evaluation of posterior circulation disease requires both neck and head MRA/CTA to visualize the entire vertebral-basilar system.
- MRA Head (CPT[®] 70544, CPT[®] 70545, or CPT[®] 70546) or CTA Head (CPT[®] 70496) is indicated for follow up of aneurysm clipping or coiling procedures (see **Intracranial Aneurysms (HD-12.1)**)
- MRA Head (CPT[®] 70544, CPT[®] 70545, or CPT[®] 70546) or CTA Head (CPT[®] 70496) **AND/OR** MRA Neck (CPT[®] 70547, CPT[®] 70548, or CPT[®] 70549) or CTA Neck (CPT[®] 70498) is indicated if arterial dissection is suspected, or known and re-evaluation is needed (as directed by neurologist or neurosurgeon or any provider in consultation with a neurologist or neurosurgeon)^{12,24}
 - There are high risk scenarios including but not exclusive to: Fibromuscular dysplasia (FMD), Marfan Disease, motor vehicle accident (MVA) with whiplash, or chiropractic manipulation
- Other vascular imaging indications for headaches require additional information.
 - See **Stroke/TIA (HD-21.1)**, **Sudden Onset of Headache (HD-11.3)**, **New Headache Onset Older than Age 50 (HD-11.7)**, **Abnormal Blood Clotting (HD-11.9)**, **Pregnancy (HD-11.10)**, **Physical Exertion (HD-11.11)**, and **Systemic Infections (HD-11.13)**
- CT and MR Venography (CTV and MRV) are reported with the same codes as the CTA/MRA counterpart (there is no specific code for CT/MR venography):
 - If arterial and venous CT or MR studies are both performed in the same session, only **one** CPT[®] code is used to report both procedures
 - If an arterial CTA or MRA study has been performed and subsequently a repeat study is needed to evaluate the venous anatomy, then this study is supported
 - If a venous CTV or MRV study has been performed and subsequently a repeat study is needed to evaluate the arterial anatomy, then this study is supported
 - MRA without and with contrast with venous sinus thrombosis to differentiate total from subtotal occlusion is supported

General Guidelines – PET Coding Notes (HD-1.6)

HD.GG.0001.6.A

v3.0.2024

- Metabolic Brain PET should be reported as Metabolic Brain PET (CPT[®] 78608)
- Amyloid Brain PET should be reported as limited PET (CPT[®] 78811) or limited PET/CT (CPT[®] 78814)

General Guidelines – Other Imaging Situations (HD-1.7)

HD.GG.0001.7.A

v3.0.2024

- Nausea and vomiting, persistent, unexplained and a negative GI evaluation: MRI Brain without contrast (CPT[®] 70551) or without and with contrast (CPT[®] 70553) is supported.
- Screening for metallic fragments before MRI should be done initially with Plain x-ray.
 - The use of CT Orbital to rule out orbital metallic fragments prior to MRI is rarely necessary
 - Plain x-rays are generally sufficient; x-ray detects fragments of 0.12 mm or more, and CT detects those of 0.07 mm or more
- Plain x-ray is generally sufficient to screen for aneurysm clips
- CPT[®] 76377 (3D rendering requiring image post-processing on an independent workstation) or CPT[®] 76376 (3D rendering not requiring image post-processing on an independent workstation) can be considered when performed in conjunction with conventional angiography (i.e.: conventional 4 vessel cerebral angiography).
- Eagle Syndrome
 - See: **Eagle Syndrome (Neck-10.3)**
 - See: **General Guidelines – CT and MR Angiography (CTA and MRA) (HD-1.5)** for vascular imaging related to Eagle Syndrome.¹⁵
- For facial feminization/masculinization procedural planning:
 - Pre-operative CT requests for CT Maxillofacial without contrast (CPT[®] 70486) with or without 3D rendering (CPT[®] 76376 or CPT[®] 76377), and/or CT Neck with contrast (CPT[®] 70491) are supported if the individual has a health plan benefit covering the facial feminization/masculinization and laryngoplasty surgeries and the surgery has been approved.
 - Additionally, CT Head without (CPT[®] 70450) for the following:
 - History of prior cranial surgery
 - History of head trauma
 - Presence of neurological signs and symptoms
 - Pre-operative imaging is not supported if the facial feminization/masculinization and laryngoplasty surgeries are not health plan covered benefits
- 3D Rendering
 - CPT[®] 76377 (3D rendering requiring image post-processing on an independent workstation) or CPT[®] 76376 (3D rendering not requiring image post-processing on an independent workstation) is supported in the following clinical scenarios:

- Bony conditions
 - Evaluation of congenital skull abnormalities in newborns, infants, and toddler (usually for pre-operative planning)
 - Complex joint fractures or pelvis fractures
 - Spine fractures (usually for pre-operative planning)
 - Complex facial fractures
- Pre-operative planning for other complex surgical cases
- Cerebral angiography (see: **Intracranial Aneurysms (HD-12.1)**, **Arteriovenous Malformations (AVMs) and Related Lesions (HD-12.2)**, **Stroke/TIA (HD-21.1)**, and **Cerebral Vasculitis (HD-22.1)**)²⁶
 - 3D Rendering (CPT[®] 76377 or CPT[®] 76376) for surgical planning and surgical follow up after craniotomy when ordered by surgical specialist or any provider in consultation with a surgical specialist.
 - 3D Rendering indications in pediatric head imaging are identical to those in the general imaging guidelines.
 - See **3D Rendering (Preface-4.1)** in the Preface Imaging Guidelines

References (HD-1)

v3.0.2024

1. Grossman RI, Yousem DM. *Neuroradiology*. Philadelphia, PA: Mosby Elsevier; 2010.
2. Latchaw RE, Kucharczyk J, Moseley ME. *Imaging of the nervous system: diagnostic and therapeutic applications*. Philadelphia: Elsevier Mosby; 2005
3. Elan Lewis, Stephan Mayer, Lewis Rowland 13th edition. *Merritt's neurology*. Philadelphia, PA: Lippincott Williams & Wilkins; 2015
4. ACR-ASNR-SPR Practice Parameter for the Performance of Computed Tomography (CT) of the Extracranial Head and Neck Revised 2021. (Resolution 5). <https://www.acr.org/-/media/ACR/Files/Practice-Parameters/CT-Head-Neck>
5. Hornby PJ. Central neurocircuitry associated with emesis. *The American Journal of Medicine*. 2001;111(8):106-112. doi:10.1016/s0002-9343(01)00849-x
6. Shosha E, Dubey D, Palace J, et al. Area postrema syndrome. *Neurology*. 2018;91(17). doi:10.1212/wnl.0000000000006392
7. Singh P, Yoon SS, Kuo B. Nausea: a review of pathophysiology and therapeutics. *Therapeutic Advances in Gastroenterology*. 2015;9(1):98-112. doi:10.1177/1756283x15618131
8. Gutkowski P, Rot S, Fritsch M, Meier U, Gölz L, Lemcke J. Secondary deterioration in patients with normal pressure hydrocephalus after ventriculoperitoneal shunt placement: a proposed algorithm of treatment. *Fluids and Barriers of the CNS*. 2020;17(1). doi:10.1186/s12987-020-00180-w
9. Capitán L, Santamaría JG, Simon D, et al. Facial Gender Confirmation Surgery. *Plastic and Reconstructive Surgery*. 2020;145(4). doi:10.1097/prs.0000000000006686
10. Hatcher-Martin JM, et al. Telemedicine in Neurology. *Telemedicine Work Group of the American Academy of Neurology update*. *Neurology*® 2020;94:30-38. doi:10.1212/WNL.0000000000008708
11. ACR ASNR SPR Practice Parameter for the Performance and Interpretation of Cervicocerebral Computed Tomography Angiography (CTA) Revised 2020
12. ACR ASNR SPR Practice Parameter for the Performance and Interpretation of Magnetic Resonance Imaging (MRI) of the Brain. Revised 2019
13. Expert Panel on Neurologic Imaging; Kennedy TA, Corey AS, et al. ACR Appropriateness Criteria® Orbits Vision and Visual Loss. *J Am Coll Radiol*. 2018;15(5S):S116-S131. doi:10.1016/j.jacr.2018.03.023
14. Ederies A, Demchuk A, Chia T, Gladstone DJ, Dowlatshahi D, Bendavit G, Wong K, Symons SP, Aviv RI. Postcontrast CT extravasation is associated with hematoma expansion in CTA spot negative patients. *Stroke*. 2009 May;40(5):1672-6. doi: 10.1161/STROKEAHA.108.541201
15. Chuang WC, Short JH, McKinney AM, Anker L, Knoll B, McKinney ZJ. Reversible left hemispheric ischemia secondary to carotid compression in Eagle syndrome: surgical and CT angiographic correlation. *AJNR Am J Neuroradiol* 2007;28:143-5
16. Chou DW, Tejani N, Kleinberger A, Shih C. Initial Facial Feminization Surgery Experience in a Multicenter Integrated Health Care System. *Otolaryngology–Head and Neck Surgery*. 2020;163(4):737-742. doi:10.1177/0194599820924635
17. Raffaini M, Perello R, Tremolada C, Agostini T. Evolution of Full Facial Feminization Surgery. *Journal of Craniofacial Surgery*. 2019;30(5):1419-1424. doi:10.1097/scs.0000000000005221
18. Eggerstedt M, Hong YS, Wakefield CJ, Westrick J, Smith RM, Revenaugh PC. Setbacks in Forehead Feminization Cranioplasty: A Systematic Review of Complications and Patient-Reported Outcomes. *Aesthetic Plastic Surgery*. 2020;44(3):743-749. doi:10.1007/s00266-020-01664-8
19. Spiegel JH. Facial Feminization for the Transgender Patient. *Journal of Craniofacial Surgery*. 2019;30(5):1399-1402. doi:10.1097/scs.0000000000005645
20. Callen AL, Badiie RK, Phelps A, Potigailo V, Wang E, Lee S, Talbott J, Glastonbury C, Pomerantz JH, Narvid J. Facial Feminization Surgery: Key CT Findings for Preoperative Planning and Postoperative Evaluation. *AJR* 2020 Dec 30 [published online]. Accepted manuscript. doi:10.2214/AJR.20.25228
21. James SE, Herman JL, Rankin S, Keisling M, Mottet L, Anafi M. (2016). *The Report of the 2015 U.S. Transgender Survey*. Washington, DC: National Center for Transgender Equality

22. Spiegel JH. Gender affirming and aesthetic cranioplasty: what's new? *Curr Opin Otolaryngol Head Neck Surg* 2020, 28:201-205. doi:10.1097/MOO.0000000000000640
23. Pasternak JJ and Abcejo AS. Anesthesia and the brain after concussion. *Curr Opin Anesthesiol* 2020, 33:639–645. doi:10.1097/ACO.0000000000000906
24. PRACTICE PARAMETER 1 Cervicocerebral MRA. <https://www.acr.org/-/media/ACR/Files/Practice-Parameters/cervicocerebralmra.pdf?la=en>
25. ACR-ASNR-SIR-SNIS Practice Parameter for the Performance of Diagnostic Cervicocerebral Catheter Angiography in Adults. Revised 2021. (Resolution 4) <https://www.acr.org/-/media/ACR/Files/Practice-Parameters/cervicocerebralcathangio.pdf?la=en>
26. Expert Panel on Neurologic Imaging, Whitehead MT, Cardenas AM, et al. ACR Appropriateness Criteria® Headache. *J Am Coll Radiol*. 2019;16(11S):S364-S377. doi:10.1016/j.jacr.2019.05.030
27. Expert Panel on Neurological Imaging: Luttrull MD, Boulter DJ, et al. ACR Appropriateness Criteria® Acute Mental Status Change, Delirium, and New Onset Psychosis. *J Am Coll Radiol*. 2019;16(5S):S26-S37. doi:10.1016/j.jacr.2019.02.024
28. Expert Panel on Neurological Imaging: Ledbetter LN, Burns J, et al. ACR Appropriateness Criteria® Cerebrovascular Diseases-Aneurysm, Vascular Malformation, and Subarachnoid Hemorrhage. *J Am Coll Radiol*. 2021;18(11S):S283-S304. doi:10.1016/j.jacr.2021.08.012
29. Expert Panel on Neurological Imaging, Rath TJ, Policeni B, et al. ACR Appropriateness Criteria® Cranial Neuropathy: 2022 Update. *J Am Coll Radiol*. 2022;19(11S):S266-S303. doi:10.1016/j.jacr.2022.09.021
30. Badhey, A et al. Eagle syndrome: A comprehensive review. *Clin Neurol Neurosurg*. 2017 159:34-38. doi: 10.1016/j.clineuro.2017.04.021
31. Jamal B, Jalisi S, Grillone G. Surgical management of long-standing eagle's syndrome. *Annals of Maxillofacial Surgery*. 2017;7(2):232. doi:10.4103/ams.ams_53_17
32. Tillema JM. Imaging of Central Nervous System Demyelinating Disorders. *Continuum (Minneapolis)*. 2023;29(1):292-323. doi:10.1212/CON.0000000000001246
33. American College of Radiology. ACR Manual on Contrast Media. Available at: https://www.acr.org/-/media/ACR/Files/Clinical-Resources/Contrast_Media.pdf. Accessed June 22, 2023.

Taste and Smell Disorders (HD-2)

Guideline

Taste and Smell Disorders (HD-2.1)

References (HD-2)

Taste and Smell Disorders (HD-2.1)

HD.TS.0002.1.A

v3.0.2024

- MRI Brain without and with contrast (CPT[®] 70553) or without contrast (CPT[®] 70551) AND/OR MRI Orbits/Face/Neck without (CPT[®] 70540) or without and with contrast (CPT[®] 70543) is indicated with unexplained unilateral or bilateral anosmia (inability to perceive odor) or dysgeusia (complete or partial loss of taste)
- CT Maxillofacial (CPT[®] 70486, CPT[®] 70487 or CPT[®] 70488) is indicated initially if sinus or facial bone disorders are suspected
- For individuals who test positive for SARS-CoV-2 (see: [Neuro-COVID-19 and Sars-CoV-2 Vaccines \(HD-14.2\)](#) and [Stroke/TIA \(HD-21.1\)](#))

Background and Supporting Information

In those individuals with consideration of COVID-19 due to signs/symptoms, testing to identify for SARS-CoV-2 is encouraged.

References (HD-2)

HD.TS.0002.2.A

v3.0.2024

1. Expert Panel on Neurological Imaging, Rath TJ, Policeni B, et al. ACR Appropriateness Criteria® Cranial Neuropathy: 2022 Update. *J Am Coll Radiol*. 2022;19(11S):S266-S303. doi:10.1016/j.jacr.2022.09.021
2. Devere R. Disorders of Taste and Smell. *CONTINUUM: Lifelong Learning in Neurology*. 2017;23(2):421-446. doi:10.1212/con.0000000000000463
3. ACR-ASNR-SPR Practice Parameter for the Performance of Computed Tomography (CT) of the Extracranial Head and Neck Revised 2021. (Resolution 5). <https://www.acr.org/-/media/ACR/Files/Practice-Parameters/CT-Head-Neck>
4. Politi LS, Salsano E, Grimaldi M. Magnetic Resonance Imaging Alteration of the Brain in a Patient With Coronavirus Disease 2019 (COVID-19) and Anosmia. *JAMA Neurology*. 2020. doi:10.1001/jamaneurol.2020.2125
5. Symptoms of Coronavirus. Centers for Disease Control and Prevention. <https://www.cdc.gov/coronavirus/2019-ncov/symptoms-testing/symptoms.html>. Published May 13, 2020
6. Soler ZM, Patel ZM, Turner JH, Holbrook EH. A primer on viral-associated olfactory loss in the era of COVID-19. *International Forum of Allergy & Rhinology*. 2020;10(7):814-820. doi:10.1002/alr.22578

Ataxia (HD-3)

Guideline

Ataxia (HD-3.1)

References (HD-3)

Ataxia (HD-3.1)

HD.AX.0003.1.A

v3.0.2024

- Common manifestations include: poor coordination, an abnormal (including wide-based) gait, abnormal finger to nose testing, abnormal rapid alternating movements, abnormal eye movements, and/or difficulty with navigation of stairs and around corners.³
- MRI Brain without and with contrast (CPT[®] 70553) **OR** MRI Brain without contrast (CPT[®] 70551) is indicated in all individuals with ataxia:
 - MRI Cervical without contrast or without and with contrast (CPT[®] 72141 or CPT[®] 72156) **AND/OR** MRI Thoracic without contrast or without and with contrast (CPT[®] 72146 or CPT[®] 72157) **AND/OR** MRI Lumbar Spine without contrast or without and with contrast (CPT[®] 72148 or CPT[®] 72158) may be added if spinal disease is suspected
 - If these symptoms are acute and stroke is suspected, see **Stroke/TIA (HD-21.1)**
 - If MS is suspected, see **Multiple Sclerosis (MS) (HD-16.1)**
 - CT Head without contrast (CPT[®] 70450) **AND/OR** CT Orbit/Temporal Bone without contrast (CPT[®] 70480) may be added if these symptoms are acute following head trauma, (see also: **Head Trauma (HD-13.1)**)
- If brain tumor is suspected, see **Primary Central Nervous System Tumors (ONC-2.1)** in the Oncology Imaging Guidelines.
- For suspected Normal Pressure Hydrocephalus, see **Normal Pressure Hydrocephalus (NPH) (HD-8.4)**

Background and Supporting Information

- In general, MRI is preferred over CT, unless there is a history of acute trauma or contraindication to MRI. For all other causes, MRI provides better visualization of the cerebellum and posterior fossa.

References (HD-3)

HD.AX.A

v3.0.2024

1. Expert Panel on Neurologic Imaging: Juliano AF, Policeni B, et al. ACR Appropriateness Criteria® Ataxia. *J Am Coll Radiol*. 2019;16(5S):S44-S56. doi:10.1016/j.jacr.2019.02.021
2. Graff-Radford NR, Jones DT. Normal Pressure Hydrocephalus. *CONTINUUM: Lifelong Learning in Neurology*. 2019;25(1):165-186. doi:10.1212/con.0000000000000689
3. Ashizawa T, Xia G. Ataxia. *CONTINUUM: Lifelong Learning in Neurology*. 2016;22(4):1208-1226. doi:10.1212/con.0000000000000362

Mental Health Disorders and Mental Status Change (HD-4)

Guideline

Autism Spectrum Disorders (HD-4.0)
Mental Health Related Disorders (HD-4.1)
Mental Status Change (HD-4.2)
References (HD-4)

Autism Spectrum Disorders (HD-4.0)

HD.BD.0004.0.A

v3.0.2024

- This group of diagnoses, including Asperger syndrome, is classified as pervasive development disorders (PDD). These diagnoses are established on clinical criteria, and no imaging study can confirm the diagnosis.
- Comprehensive evaluation for autism might include history, physical exam, audiology evaluation, speech, language, and communication assessment, cognitive and behavioral assessments, and academic assessment.
 - MRI Brain without and with contrast (CPT[®] 70553) is indicated for **ANY** of the following:
 - New or worsening focal neurologic findings documented on a pertinent physical
 - Loss of developmental milestones and/or regression
 - PET imaging is considered not medically necessary in the evaluation of individuals with autism spectrum disorders.

Mental Health Related Disorders (HD-4.1)

HD.BD.0004.1.A

v3.0.2024

- Mental health diagnoses, to include Attention Deficit Hyperactivity Disorder (ADHD), do not routinely require advanced imaging.¹²
- MRI Brain without contrast (CPT[®] 70551) **OR** MRI Brain without and with contrast (CPT[®] 70553) **OR** CT Head without contrast (CPT[®] 70450) may be indicated for the exceptions listed below:
 - Acute mental status change, disturbance in consciousness or arousal state
 - Psychotic disorders (including schizophrenia), bipolar disorder and related disorders in the following clinical presentations:
 - Acute psychosis
 - Late onset over age 40
 - Presentation of acute psychiatric symptoms with comorbid serious medical illness
 - Non-auditory hallucinations (e.g., visual, tactile, olfactory) with no known etiology
 - Nonresponse to adequate medication trials
 - Symptoms of an organic brain disorder (e.g., focal deficits, severe headache, or seizures)
- Prior to electroconvulsive therapy (ECT) treatment, the following may be utilized to screen for intracranial disease: MRI Brain without contrast (CPT[®] 70551) **OR** CT Head without contrast (CPT[®] 70450)
- Deep Brain Stimulation Therapy for psychiatric disorders is considered not medically necessary, except for medically refractory Obsessive Compulsive Disorder (OCD).¹¹
 - Imaging supported prior to Deep Brain Stimulation (DBS) therapy for medically refractory Obsessive Compulsive Disorder (OCD):
 - MRI Brain without contrast (CPT[®] 70551) **OR** MRI Brain without and with contrast (CPT[®] 70553) **AND/OR** unlisted CT procedure code (CPT[®] 76497)

Mental Status Change (HD-4.2)

HD.BD.0004.2.A

v3.0.2024

- An initial assessment should be performed prior to imaging requests. The initial assessment should include a history describing the onset, duration, and timeframe (constant versus intermittent or episodic nature) of symptoms.
- Bedside neurologic exam should include a mental status evaluation that provides a description of the level of alertness, other characteristics and/or cognitive testing.
- CT Head without contrast (CPT[®] 70450) **OR** MRI Brain without contrast (CPT[®] 70551) **OR** MRI Brain without and with contrast (CPT[®] 70553) is supported for **ANY** of the following²:
 - Acute or worsening (this includes repeat imaging) mental status change
 - Presence of any Red Flag, including:
 - Language, focal motor or sensory deficit (see **Stroke/TIA (HD-21.1)**)
 - Headache associated with acute mental status or other cognitive change. (see **Headaches with Red Flags (HD-11.2)**)
 - Presence of fever and/ or tachycardia (see **CNS and Head Infection (HD-14.1)**)
 - History of COVID-19 (see **Neuro-COVID-19 and Sars-CoV-2 Vaccines (HD 14.2)**)
 - History of hypertensive urgency associated with the mental status change (see **Stroke/TIA (HD-21.1)** and **Sudden Onset of Headache (HD 11.3)**)
 - Presence of coagulopathy or anticoagulant use (see **Abnormal Blood Clotting (HD 11.9)**)
 - Altered mental status in pregnancy and postpartum period (see **Pregnancy (HD 11.10)**)
 - History of significant antecedent trauma (see **Head Trauma (HD 13.1)**)
 - History of known underlying malignancy (see **Brain Metastases (ONC 31.3)**)
 - Fluctuating alertness or consciousness
 - Glasgow Coma Scale (GCS) score of less than 15 (see **Head Trauma (HD 13.1)**) in the setting of antecedent trauma
 - Acute onset of mental status change or worsening symptoms (this includes repeat imaging) in the setting of **known intracranial process** (mass, recent hemorrhage, recent infarct, central nervous system infection, etc.)
 - MRI Brain without contrast (CPT[®] 70551) **OR** MRI Brain without and with contrast (CPT[®] 70553) is supported with or without a previous CT Head.
 - CT Head without and with contrast (CPT 70470) is supported if clinical concern exists for initial diagnosis or progression of intracranial infection (such as abscesses or empyema), tumor, hemorrhage/stroke and/or inflammatory conditions. (See **CNS and Head Infection (HD 14.1)**, **Neuro-COVID-19 and Sars-**

CoV-2 Vaccines (HD 14.2), Stroke/TIA (HD-21.1) and/or Brain Metastases (ONC 31.3).

- CT Head contrast as requested (CPT[®] 70450 **OR** CPT[®] 70460 **OR** CP^T[®] 70470) is supported when:
 - MRI is contraindicated¹³
 - Clinical urgent setting when head imaging is otherwise supported.
- Condition specific imaging is listed in the associated guideline. These may include but are not limited to:
 - Seizure or suspected seizure. A description of events may include transient alteration of awareness, any neurologic deficit with rapid onset and offset of symptoms, episodic occurrence of symptoms, and/or abnormal rhythmic body movements. (See **Epilepsy/Seizures (HD 9.1)**)
 - Post-COVID syndrome/Long haul COVID/COVID-related neurocognitive syndrome, including associated brain fog, (See **Neuro-COVID-19 and Sars-CoV-2 Vaccines (HD 14.2)**)
 - History of significant antecedent head trauma or possible head trauma is present (See **Head Trauma (HD 13.1)**)
 - Concern for ischemic stroke, intracranial hemorrhage, or focal motor or sensory deficits (See **Stroke/TIA (HD-21.1)**)
 - Concern for mass (See **Low Grade Gliomas (ONC 2.2), High Grade Gliomas (ONC 2.3)** and/or **Brain Metastases (ONC 31.3)**)
 - Suspected increased intracranial pressure (See **Papilledema/Pseudotumor Cerebri (HD 17.1)** and/or **Hydrocephalus Shunts (HD 11.14)**)
 - Hallucinations and/or delusions are present (See **Mental Health Related Disorders (HD-4.1)**)

Background and Supporting Information

This section refers to acute and subacute mental status change, generally implicating signs and symptoms occurring over minutes to days.

Acute mental status change or encephalopathy is characterized by changes in behavior or alertness, agitation, confusion, as opposed to chronic, progressive cognitive decline, such as dementia related disorders.

The terms delirium and psychosis are narrowly defined as follows:

- Delirium refers to acute onset of deficits in attention, awareness, and cognition that fluctuate in severity over time, often associated with psychomotor disturbance, altered sleep cycle, and emotional variability. These disturbances may be hyperactive (restlessness, agitation) or hypoactive (psychomotor retardation, lethargy). There may be accompanying fever, and autonomic symptoms (tachycardia, sweating) depending on underlying etiology.

- Psychosis refers to a disorder of impaired reality testing characterized by the presence of hallucinations and/ or delusions, or both without (without insight into their pathologic nature). This may be associated with disorganized behavior, thought blocking, illogicality, tangentiality, perseveration, neologisms.

The purpose of the initial assessment is to define the category of the etiology. These may include: toxic/ metabolic (hypoglycemic, drug exposures), structural (trauma, stroke, hypoxic-ischemic, hydrocephalus, tumor), paroxysmal (seizure, psychiatric), inflammatory (infectious, autoimmune).

Of note even a mild or trivial, acute insult superimposed upon a chronic pathophysiologic process may cause acute mental status change, and head imaging may or may not be necessary, depending on the provider's pretest suspicion of a new significant diagnosis.

Non response to adequate medication trials may include, but is not limited to, implantation of Vagal Nerve Stimulator (VNS), which is FDA approved for treatment of depression.

References (HD-4)

v3.0.2024

1. Uzelac A. Imaging of Altered Mental Status. *Radiologic Clinics of North America*. 2020;58(1):187-197. doi:10.1016/j.rcl.2019.08.002
2. Expert Panel on Neurological Imaging: Luttrull MD, Boulter DJ, et al. ACR Appropriateness Criteria® Acute Mental Status Change, Delirium, and New Onset Psychosis. *J Am Coll Radiol*. 2019;16(5S):S26-S37. doi:10.1016/j.jacr.2019.02.024
3. Andrea S, Papirny M, Raedler T. Brain Imaging in Adolescents and Young Adults With First-Episode Psychosis. *The Journal of Clinical Psychiatry*. 2019;80(6). doi:10.4088/jcp.18m12665
4. Bridgemohan CF. Chapter 54: Autism spectrum disorder. In: Kliegman RM, St. Geme JW III, Blum NJ, Shah SS, Tasker RC, Wilson KM. eds. *Nelson Textbook of Pediatrics* 21st ed. 2020: 294-302
5. Baker E, and Jeste SS. Diagnosis and Management of Autism Spectrum Disorder in the Era of Genomics. *Pediatric Clinics of North America*. 2015;62(3):607-618. doi:10.1016/j.pcl.2015.03.003
6. Zürcher NR, Bhanot A, McDougle CJ, Hooker JM. A systematic review of molecular imaging (PET and SPECT) in autism spectrum disorder: Current state and future research opportunities. *Neuroscience & Biobehavioral Reviews*. 2015;52:56-73. doi:10.1016/j.neubiorev.2015.02.002.
7. Julayanont P, Suryadevara U. Psychosis. *Continuum (Minneapolis)*. 2021;27(6):1682-1711. doi:10.1212/CON.0000000000001013
8. Keepers GA. American Psychiatric Association. The American Psychiatric Association practice guideline for the treatment of patients with schizophrenia / Guideline Writing Group, Systematic Review Group, Committee on Practice Guidelines. 3rd edition. American Psychiatric Association; 2021
9. Rapinesi C, Kotzalidis GD, Ferracuti S, Sani G, Girardi P, Del Casale A. Brain Stimulation in Obsessive-Compulsive Disorder (OCD): A Systematic Review. *Curr Neuropharmacol*. 2019;17(8):787-807. doi: 10.2174/1570159X17666190409142555. PMID: 30963971; PMCID: PMC7059162.
10. Ali SA, Mathur N, Malhotra AK, Braga RJ. Electroconvulsive Therapy and Schizophrenia: A Systematic Review. *Mol Neuropsychiatry*. 2019 Apr;5(2):75-83. doi: 10.1159/000497376. Epub 2019 Apr 2. PMID: 31192220; PMCID: PMC6528094.
11. Staudt MD, Pouratian N, Miller JP, et al. Congress of Neurological Surgeons Systematic Review and Evidence-Based Guidelines for Deep Brain Stimulation for Obsessive-Compulsive Disorder: Update of the 2014 Guidelines. *Neurosurgery*. 2021;88(4):710-712. doi:10.1093/neuros/nyaa596
12. Pereira-Sanchez V, Castellanos FX. Neuroimaging in attention-deficit/hyperactivity disorder. *Curr Opin Psychiatry*. 2021;34(2):105-111. doi:10.1097/YCO.0000000000000669
13. Expert Panel on MR Safety, Kanal E, Barkovich AJ, et al. ACR guidance document on MR safe practices: 2013. *J Magn Reson Imaging*. 2013;37(3):501-530. doi:10.1002/jmri.24011

Chiari and Skull-Base Malformations (HD-5)

Guideline

Chiari Malformations (HD-5.1)

Chiari II Malformations (Arnold Chiari Malformation) (HD-5.2)

Chiari III and IV Malformations (HD-5.3)

Basilar Impression/Basilar Invagination (HD-5.4)

Platybasia (HD-5.5)

References (HD-5)

Chiari Malformations (HD-5.1)

HD.CM.0005.1.A

v3.0.2024

Indication	Supported Imaging
Initial Evaluation for suspected or known Chiari malformations:	<ul style="list-style-type: none"> • MRI Brain without contrast (CPT[®] 70551) or MRI Brain without and with contrast (CPT[®] 70553) <p>AND/OR</p> <ul style="list-style-type: none"> • MRI Cervical Spine without contrast (CPT[®] 72141) or MRI Cervical Spine without and with contrast (CPT[®] 72156) <p>AND/OR</p> <ul style="list-style-type: none"> • MRI Thoracic Spine without contrast (CPT[®] 72146) or MRI Thoracic Spine without and with contrast (CPT[®] 72157) <p>AND/OR</p> <ul style="list-style-type: none"> • MRI Lumbar Spine without contrast (CPT[®] 72148) or MRI Lumbar Spine without and with contrast (CPT[®] 72158)
Repeat imaging for one of the following: <ul style="list-style-type: none"> • New or worsening signs or symptoms • Surgical procedure is actively being considered • At the discretion of or in consultation with a neurologist and/or neurosurgeon coordinating the individual's care 	<ul style="list-style-type: none"> • MRI Brain without contrast (CPT[®] 70551) or MRI Brain without and with contrast (CPT[®] 70553) <p>AND/OR</p> <ul style="list-style-type: none"> • MRI Cervical Spine without contrast (CPT[®] 72141) or MRI Cervical Spine without and with contrast (CPT[®] 72156) <p>AND/OR</p> <ul style="list-style-type: none"> • MRI Thoracic Spine without contrast (CPT[®] 72146) or MRI Thoracic Spine without and with contrast (CPT[®] 72157) <p>AND/OR</p> <ul style="list-style-type: none"> • MRI Lumbar Spine without contrast (CPT[®] 72148) or MRI Lumbar Spine without and with contrast (CPT[®] 72158)

- Familial screening is NOT indicated for Chiari Malformations.
- For CSF flow imaging (see **CSF Flow Imaging (HD-24.4)**)

Background and Supporting Information

Chiari I malformations involve caudal displacement or herniation of the cerebellar tonsils. Chiari I may be associated with syringomyelia and rarely with hydrocephalus. Most cases are asymptomatic and discovered incidentally on a head scan performed for another indication. When symptoms are present, they are usually nonspecific but can include headache, lower cranial nerve palsies, or sleep apnea.

Chiari II malformations are more severe than Chiari I malformations. These individuals usually present at birth. Myelomeningocele is always present, and syringomyelia and hydrocephalus are extremely common.

Chiari III malformations include cerebellar herniation into a high cervical myelomeningocele. Chiari IV malformation refers to complete cerebellar agenesis. Both Chiari III and IV malformations are noted at birth and are rarely compatible with life.

Repeat brain and spine imaging in individuals with Chiari I malformations and known syringomyelia or hydromyelia is highly individualized.

Chiari II Malformations (Arnold Chiari Malformation) (HD-5.2)

HD.CM.0005.2.A

v3.0.2024

- See [Chiari Malformations \(HD-5.1\)](#)

Chiari III and IV Malformations (HD-5.3)

HD.CM.0005.3.A

v3.0.2024

- See **Chiari Malformations (HD-5.1)**

Basilar Impression/Basilar Invagination (HD-5.4)

HD.CM.0005.4.A

v3.0.2024

Imaging indications for suspected or known Basilar Impression or Basilar Invagination:

- MRI Brain (CPT[®] 70551) **AND/OR** MRI Cervical Spine (CPT[®] 72141) without contrast
- If surgery is being considered, CT Head (CPT[®] 70450) **AND/OR** CT Cervical Spine (CPT[®] 72125) without contrast are also indicated **AND/OR** MRA Head (CPT[®] 70544, CPT[®] 70545, or CPT[®] 70546) **OR** CTA Head (CPT[®] 70496) **AND/OR** MRA Neck (CPT[®] 70547, CPT[®] 70548, or CPT[®] 70549) **OR** CTA Neck (CPT[®] 70498).¹⁴
- One-time screening of first-degree relatives with MRI Brain without contrast (CPT[®] 70551) is supported.

Background and Supporting Information

Basilar impression involves malformation of the occipital bone in relation to C1-2 (cervical vertebrae 1 and 2). The top of the spinal cord is inside the posterior fossa and the foramen magnum is undersized. Over time, this can lead to brain stem and upper spinal cord compression. Basilar impression can also be associated with the Chiari malformation, producing very complex anatomical abnormalities.

Basilar invagination is an abnormality at the craniovertebral junction, either congenital or degenerative, resulting in the odontoid prolapsing into the already limited space of the foramen magnum. It is commonly associated with conditions such as Chiari malformation, syringomyelia, and Klippel-Feil syndrome.¹²

Platybasia (HD-5.5)

HD.CM.0005.5.A

v3.0.2024

Imaging indications for suspected or known Platybasia:

- MRI Brain without contrast (CPT[®] 70551) or CT Head without contrast (CPT[®] 70450)
- If surgery is being considered,
 - CT Head (CPT[®] 70450) **AND/OR**
 - CT Cervical Spine without contrast (CPT[®] 72125) **AND/OR**
 - MRA Head (CPT[®] 70544, CPT[®] 70545, or CPT[®] 70546) **OR**
 - CTA Head (CPT[®] 70496) **AND/OR**
 - MRA Neck (CPT[®] 70547, CPT[®] 70548, or CPT[®] 70549) **OR**
 - CTA Neck (CPT[®] 70498)¹⁴

Background and Supporting Information

Platybasia is a flattening malformation of the skull base, in which the clivus has a horizontal orientation.

References (HD-5)

v3.0.2024

1. Strahle J, Muraszko KM, Kapurch J, et al. Chiari malformation Type I and syrinx in children undergoing magnetic resonance imaging. *J Neurosurg Pediatr.* 2011 Aug; 8 (2): 205-213
2. Strahle J, Muraszko KM, Kapurch J, et al. Natural history of Chiari malformation Type I following decision for conservative treatment. *J Neurosurg Pediatr.* 2011 Aug; 8 (2): 214-221
3. Strahle J, Muraszko KM, Garton HJL, et al. Syrinx location and size according to etiology: identification of Chiari-associated syrinx. *J Neurosurg Pediatr.* 2015 July; 16 (1): 21-9 Epub 2015 Apr 3
4. Strahle J, Smith BW, Martinez M, et al. The association between Chiari malformation Type I, spinal syrinx, and scoliosis. *J Neurosurg Pediatr.* 2015 Jun; 15 (6): 607-611
5. Victorio MC, Khoury CK. Headache and Chiari I Malformation in Children and Adolescents. *Seminars in Pediatric Neurology.* 2016;23(1):35-39
6. Radic JAE, Cochrane DD. Choosing Wisely Canada: Pediatric Neurosurgery Recommendations. *Paediatrics & Child Health.* 2018;23(6):383-387. doi:10.1093/pch/pxy012
7. Smoker WRK and Khanna G. Imaging the craniocervical junction. *Childs Nerv Syst.* 2008 Oct; 24 (10): 1123-1145
8. Kinsman SL and Johnston MV. Congenital anomalies of the central nervous system. *Nelson Textbook of Pediatrics*, Chapter 609. eds Kliegman RM, St. Geme JW III, Blum NJ, Shah SS, Tasker RC, Wilson KM. 21st edition. 2020, pp 3063-3082
9. Dantas FLR, Dantas F, Caires AC, Botelho RV. Natural History and Conservative Treatment Options in Chiari Malformation Type I in Adults: A Literature Update. *Cureus.* 2020;12(12):e12050. Published 2020 Dec 13. doi:10.7759/cureus.12050
10. Holly LT, Batzdorf U. Chiari malformation and syringomyelia. *J Neurosurg Spine.* 2019;31(5):619-628. doi:10.3171/2019.7.SPINE181139
11. Rosenblum JS, Pomeraniec IJ, Heiss JD. Chiari Malformation (Update on Diagnosis and Treatment). *Neurol Clin.* 2022;40(2):297-307. doi:10.1016/j.ncl.2021.11.007
12. Donnally III CJ, Munakomi S, Varacallo M. Basilar Invagination. [Updated 2022 Nov 19]. In: StatPearls [Internet]. Treasure Island (FL): StatPearls Publishing; 2022 Jan-. Available from: <https://www.ncbi.nlm.nih.gov/books/NBK448153/>
13. Brito JNPO, Santos BAD, Nascimento IF, Martins LA, Tavares CB. Basilar invagination associated with chiari malformation type I: A literature review. *Clinics (Sao Paulo).* 2019;74:e653. doi:10.6061/clinics/2019/e653
14. Pinter NK, McVige J, Mechtler L. Basilar Invagination, Basilar Impression, and Platybasia: Clinical and Imaging Aspects. *Curr Pain Headache Rep.* 2016;20(8):49. doi:10.1007/s11916-016-0580-x

Facial Palsy (Bell's Palsy)/Hemifacial Spasm (HD-6)

Guideline

Facial Palsy (HD-6.1)
Hemifacial Spasm (HD-6.2)
References (HD-6)

Facial Palsy (HD-6.1)

HD.FP.0006.1.A

v3.0.2024

- MRI Brain without and with contrast (CPT[®] 70553) (with attention to posterior fossa and IACs) or without contrast (CPT[®] 70551) **AND/OR** MRI Orbit/Face/Neck without contrast (CPT[®] 70540) or with and without contrast (CPT[®] 70543) are supported with the following “red flags” of unexplained facial paresis/paralysis in clinical scenarios with²:
 - Trauma to the temporal bone
 - History of tumor, systemic cancer, HIV or Lyme disease
 - No improvement in 8 weeks
 - No full recovery in 3 months
 - Gradual onset over weeks to months
 - Vertigo or hearing loss
 - Bilateral involvement
 - Other atypical or inconsistent features including:
 - Second episode of paralysis on the same side
 - Paralysis of isolated branches of the facial nerve
 - Paralysis associated with other cranial nerves
- MRI Brain without and with contrast (CPT[®] 70553) for known sarcoidosis with suspected neurosarcoid or CNS involvement is supported, (see also: **Autoimmune/ Paraneoplastic Encephalitis & NeuroInflammatory Disorders (HD-14.3)**)
- CT Orbit/Temporal Bone without contrast (CPT[®] 70480), in the presence of red flags, to assess osseous integrity of the temporal bone, to characterize fractures, pre-surgical anatomy, inflammatory middle ear disease, bone tumor, facial canal foraminal expansion and/or bone erosion.²
- CT Orbit/Temporal Bone with contrast (CPT[®] 70481), in the presence of red flags, for suspected tumors and/or infection.²
- CT Maxillofacial without contrast (CPT[®] 70486) to assess bony facial nerve canal **OR** with contrast (CPT[®] 70487) when infection or tumor are suspected, if requested per institutional protocol.²
- MRA Head without contrast (CPT[®] 70544), with contrast (CPT[®] 70545), or without and with contrast (CPT[®] 70546) **AND/OR** MRA Neck without contrast (CPT[®] 70547), with contrast (CPT[®] 70548), or without and with contrast (CPT[®] 70549) **OR** CTA Head (CPT[®] 70496) **AND/OR** CTA Neck (CPT[®] 70498) for clinically suspected stroke.² (see also: **General Guidelines- CT and MR Angiography (CTA and MRA) (HD-1.5)** and **Stroke/TIA (HD-21.1)**)

Background and Supporting Information

Typical features of Bell's palsy include variable initial ipsilateral temporal and auricular pain before facial weakness, onset over 72 hours, ipsilateral complete facial weakness, and an otherwise normal neurological and systemic examination. There is usually slow improvement over several months. Unless "red flags" are present, imaging is not necessary.

Hemifacial Spasm (HD-6.2)

HD.FP.0006.2.A

v3.0.2024

- For hemifacial spasm, facial synkinesis, or blepharospasm:
 - MRI Brain without and with contrast (CPT[®] 70553)
 - Add CTA Head (CPT[®] 70496) or MRA Head (CPT[®] 70544, CPT[®] 70545, or CPT[®] 70546) for consideration of vascular decompression surgical procedure to clarify the vascular anatomy in individuals who have failed conservative medical management

References (HD-6)

v3.0.2024

1. Baugh RF, Basura GJ, Ishii LE, et al. Clinical practice guideline. Bell's Palsy Executive Summary. *Otolaryngology–Head and Neck Surgery*. 2013;149(5):656-663. doi:10.1177/0194599813506835
2. Expert Panel on Neurological Imaging, Rath TJ, Policeni B, et al. ACR Appropriateness Criteria® Cranial Neuropathy: 2022 Update. *J Am Coll Radiol*. 2022;19(11S):S266-S303. doi:10.1016/j.jacr.2022.09.021
3. Yalho TC, Jankovic J. The many faces of hemifacial spasm: Differential diagnosis of unilateral facial spasms. *Movement Disorders*. 2011;26(9):1582-1592. doi:10.1002/mds.23692
4. Reich SG. Bell's Palsy. *CONTINUUM: Lifelong Learning in Neurology*. 2017;23(2):447-466. doi:10.1212/con.0000000000000447
5. Stern BJ, Royal W, Gelfand JM, et al. Definition and Consensus Diagnostic Criteria for Neurosarcoidosis. *JAMA Neurology*. 2018;75(12):1546. doi:10.1001/jamaneurol.2018.2295

Recurrent Laryngeal Palsy/Vocal Cord Palsy (HD-7)

Guideline

Recurrent Laryngeal Palsy/Vocal Cord Palsy (HD-7.1)

Recurrent Laryngeal Palsy/Vocal Cord Palsy (HD-7.1)

HD.RL.0007.1.A

v3.0.2024

- See [Recurrent Laryngeal Nerve Palsy in Neck-7.1](#)

Dementia (HD-8)

Guideline

Dementia (HD-8.1)

Dementia - PET (HD-8.2)

Lewy Body Dementia (LBD) - SPECT Brain Scan (HD-8.3)

Normal Pressure Hydrocephalus (NPH) (HD-8.4)

Imaging Related to Alzheimer's Treatment with Amyloid Reduction Medications (HD-8.5)

References (HD-8)

Dementia (HD-8.1)

HD.DM.0008.1.A

v3.0.2024

- For acute mental status change See **Mental Status Change (HD-4.2)** and **Stroke/ TIA (HD-21.1)**
- For members being considered for amyloid reducing medications for the treatment of Mild Cognitive Impairment (MCI) due to Alzheimer's disease or mild dementia due to Alzheimer's disease see **Imaging related to Alzheimer's Treatment with Amyloid Reduction Medications (HD-8.5)**
- MRI Brain without contrast (CPT[®] 70551) or MRI Brain without and with contrast (CPT[®] 70553) or CT Head without contrast (CPT[®] 70450) is supported after an initial clinical diagnosis of dementia has been established.
 - The following components are required:
 - A detailed neurological exam is not required when dementia is diagnosed with abnormal bedside mental status testing by score results
 - Established diagnosis of dementia: date of onset of symptoms with documentation of 6 months of cognitive decline based on a detailed history of memory loss with impairment of day-to-day activities confirmed by family members or others with knowledge of the individual's status
 - OR**
 - Results of bedside testing and/or neuropsychological testing can be performed when history and bedside mental status examination cannot provide a confident diagnosis.
 - Examples of abnormal bedside mental status testing such as Mini-Mental Status Exam (MMSE) with score <26, Montreal Cognitive Assessment Survey (MoCA) with score <26, Memory Impairment Screen (MIS) with score <5, the St. Louis University Mental Status (SLUMS) with score <21, or the Eight-item Informant Interview to Differentiate Aging and Dementia (AD8) Dementia Score > 2³¹.
 - Presumptive causes or etiology/ies of dementia
 - Cannot occur exclusively during bouts of delirium
 - Cannot be explained by another mental disorder
- For the evaluation of Normal Pressure Hydrocephalus, see **Normal Pressure Hydrocephalus (HD-8.4)**.
- Quantitative Magnetic Resonance Image (MRI) Analysis of the Brain
 - Volumetric analysis of the temporal lobes and hippocampus or Neuro Quant may be ordered as 3D rendering (CPT[®] 76376 and CPT[®] 76377) or quantitative analysis of the brain (CPT[®] 0865T or CPT[®] 0866T). These studies lack sufficient specificity and sensitivity to be clinically useful in the evaluation or follow up

of individuals with dementia. Their use is limited to research studies and are otherwise considered to be not medically necessary in routine clinical practice.

Dementia - PET (HD-8.2)

HD.DM.0008.2.A

v3.0.2024

- Prior to consideration of PET imaging for a diagnosis of dementia, all of the following components are required:
 - Established diagnosis of dementia: date of onset of symptoms with documentation of 6 months of cognitive decline based on a detailed history of memory loss with impairment of day-to-day activities confirmed by family members or others with knowledge of the individual's status

OR

- Results of bedside testing and/or neuropsychological testing can be performed when history and bedside mental status examination cannot provide a confident diagnosis.
 - Examples of abnormal bedside mental status testing such as Mini-Mental State Exam (MMSE) with score <26, Montreal Cognitive Assessment Survey (MoCA) with score <26, Memory Impairment Screen (MIS) with score <5, the St. Louis University Mental Status (SLUMS) with score <21 or the Eight-item Informant Interview to Differentiate Aging and Dementia (AD8) Dementia Score > 2³¹.
- Results of any structural imaging (MRI or CT Head) performed.
- Presumptive causes or etiology/ies of dementia
 - Cannot occur exclusively during bouts of delirium
 - Cannot be explained by another mental disorder

CPT[®] 78608 is used to report FDG PET metabolic brain studies for dementia, seizure disorders, and dedicated PET tumor imaging studies of the brain.

CPT[®] 78609 is used to report PET Brain perfusion studies that are not performed with FDG. These scans are nationally noncovered by Medicare.

CPT[®] 78811 (limited PET) or CPT[®] 78814 (limited PET/CT) are used to report Amyloid Brain PET (these codes are for static images to measure amyloid, as opposed to the FDG PET which is a metabolic study).

- FDG PET for Dementia and Neurodegenerative Diseases
 - For Medicare members, see the **Medicare National Coverage Determinations (NCD) Manual, Section 220.6.13** for the coverage policy
 - FDG Brain PET (CPT[®] 78608) is useful in distinguishing between Alzheimer's disease (AD) and Frontotemporal dementia (FTD).
 - It is otherwise considered not medically necessary for the purpose of diagnosis and management of mild cognitive impairment (MCI) and other forms of dementia

- including, but not limited to, Lewy Body disease, Parkinson's disease, Normal Pressure Hydrocephalus and Chronic Traumatic Encephalopathy.
- Appropriate documentation should support concern for one of the variants of Frontotemporal dementia (Behavioral Variant or Primary Progressive Aphasia type FTD) based on a detailed history and exam findings (which includes neuropsychological testing) and meet the following criteria:
 - Meets diagnostic criteria for AD and FTLD (frontotemporal lobar dementia) **AND**
 - Has a documented cognitive decline of at least 6 months **AND**
 - Evaluation has ruled out specific alternative neurodegenerative disease or causative factors; and
 - Cause of clinical symptoms is uncertain **AND**
 - The results are expected to help clarify the diagnosis between FTLD and AD and help guide future treatment.
 - Amyloid Brain PET
 - Amyloid Brain PET (CPT[®] 78811 or CPT[®] 78814) imaging is only indicated for treatment with amyloid-reducing medications (see **Imaging Related to Alzheimer's Treatment with Amyloid Reduction Medications (HD-8.5)**).
 - Otherwise, these studies are **NOT** considered medically necessary for any of the following scenarios:
 - Screening for dementia
 - Diagnosis of dementia
 - Differentiating between Alzheimer's disease and other neurodegenerative/ neurologic disorders
 - For Cerebral Amyloid Angiopathy, see **Stroke/TIA (HD-21.1)**
 - FDG-PET(CPT[®] 78608)/MRI Brain without contrast (CPT[®] 70551) OR MRI Brain without and with contrast (CPT[®] 70553) imaging may be considered on a case by case basis for those imaging centers that will utilize FDG-PET/MRI during an initial evaluation (instead of MRI alone) and who also have a standardization of imaging protocol.^{27, 28, 29, 30}

Background and Supporting Information

- The frontotemporal dementias (FTDs) are a group of neurodegenerative disorders that differ from Alzheimer's disease. The basic pathology involves accumulation of tau proteins in the brain rather than amyloid. Onset tends to be younger (less than 65) and progression usually more rapid than in senile dementia-Alzheimer type (SDAT). There is no treatment, and the medications used to help memory in Alzheimer's disease are not effective.
- There are several subtypes of FTD; most common are the behavioral variant with early loss of executive functions, impaired judgment disinhibition and impulsivity, and the semantic variant with primary and progressive loss of language ability. Other less

common subtypes include progressive supranuclear palsy, corticobasal syndrome, and FTD associated with motor neuron disease.

- Diagnosis is based on clinical features, neuropsychological testing, and brain imaging (preferably MRI) to rule out other structural disease. Metabolic (FDG) PET Brain is helpful by demonstrating patterns of abnormality more consistent with FTD than Alzheimer's disease.
- Health plans may have specific criteria that differ in their coverage policies
- Recent research has examined the utility of PET/MRI for evaluation of patients with Dementia. Due to the prolonged acquisition time, motion during a PET may lead to artifacts such as blurring of the images. Use of co-registration of PET with MRI can lead to better PET assessment especially with quantitative measurements^{27,30}. Utilization of PET/MRI provides greater confidence in imaging reading by permitting greater structural correlation. A recent study compared FDG-PET/CT and FDG-PET/MRI in a memory disorders clinic. This study identified more patient with cerebrovascular disease (stroke) and better cortical atrophy characterization²⁸. The authors found that PET/MRI provided significant improvement in diagnosis and management of patients in which dementia is a consideration. Finally a Canadian study suggested that FDG-PET/MRI is "financially justifiable"²⁹.

Lewy Body Dementia (LBD) - SPECT Brain Scan (HD-8.3)

HD.DM.0008.3.A

v3.0.2024

- Dementia with Lewy bodies is often hard to diagnose because its early symptoms may resemble those of Alzheimer's or a psychiatric illness. Over time people with LBD often develop similar symptoms due to the presence of Lewy bodies in the brain.
 - Clinicians and researchers may use the "1-year rule" to help make a diagnosis. If cognitive, psychiatric, emotional, and/or personality symptoms appear at the same time as or at least a year before movement problems/parkinsonism, the diagnosis is dementia with Lewy bodies. If cognitive problems develop more than a year after the onset of movement problems, Parkinson's disease, the diagnosis is Parkinson's disease dementia (PDD).
- Core Clinical Symptoms
 - Dementia
 - Movement problems/parkinsonism
 - Cognitive fluctuations
 - Visual hallucinations
 - REM sleep behavior disorder
- Supportive Clinical Symptoms
 - Extreme sensitivity to antipsychotic medications
 - Falls, fainting
 - Severe problems with involuntary functions (maintaining blood pressure, incontinence, constipation, loss of smell)
 - Changes in personality and mood (depression, apathy, anxiety)
- Prior to consideration of SPECT Brain Scan for a diagnosis of LBD, all of the following components are required:
 - Established diagnosis of dementia: date of onset of symptoms with documentation of 6 months of cognitive decline based on a detailed history of memory loss with impairment of day-to-day activities confirmed by family members or others with knowledge of the individual's status **OR**
 - Results of bedside testing and/or neuropsychological testing can be performed when history and bedside mental status examination cannot provide a confident diagnosis.
 - Examples of abnormal bedside mental status testing such as Mini-Mental State Exam (MMSE) with score <26, Montreal Cognitive Assessment Survey (MoCA) with score <26, Memory Impairment Screen (MIS) with score <5, the St. Louis

University Mental Status (SLUMS) with score <21, or the Eight-item Informant Interview to Differentiate Aging and Dementia (AD8) Dementia Score > 2³¹.

- Results of any structural imaging (MRI or CT Head) performed
- SPECT Brain Scan (CPT[®] 78803 or CPT[®] 78830) is supported after all of the above criteria are met
- PET Brain is not indicated for LBD

Background and Supporting Information

Test Results Supporting Diagnosis

- Abnormal 123iodine-MIBG myocardial scintigraphy showing reduced communication of cardiac nerves
- Sleep study confirming REM sleep behavior disorder without loss of muscle tone

Normal Pressure Hydrocephalus (NPH) (HD-8.4)

HD.DM.0008.4.A

v3.0.2024

- CT Head without contrast (CPT[®] 70450) **OR** MRI Brain without contrast (CPT[®] 70551) is indicated if the individual has at least two symptoms involving gait abnormality (see **Background and Supporting Information**), urinary incontinence, or dementia **AND**
 - The clinical symptoms cannot be completely explained by other neurological or non-neurological disease, **AND**
 - There is no apparent preceding disorder that would cause hydrocephalus^{24,25,26}
- The components of Dementia are delineated in **Dementia (HD-8.1)**, but include:
 - Results of testing and/or neuropsychological testing can be performed when history and mental status examination cannot provide a confident diagnosis.
 - Examples of abnormal mental status testing such as Mini-Mental State Exam (MMSE) with score <26, Montreal Cognitive Assessment Survey (MoCA) with score <26, Memory Impairment Screen (MIS) with score <5, the St. Louis University Mental Status (SLUMS) with score <21, or the Eight-item Informant Interview to Differentiate Aging and Dementia (AD8) Dementia Score > 2³¹.
 - Presumptive causes or etiology/ies of dementia
 - Cannot occur exclusively during bouts of delirium
 - Cannot be explained by another mental disorder
- MRI Brain (CPT[®] 70551, CPT[®] 70552, or CPT[®]70553) is not generally indicated for the diagnosis of NPH if a CT has been performed. However, MRI Brain is indicated if needed for pre-surgical planning.
 - After neuro imaging the next step is CSF sampling, drainage, and dynamics
- Follow-up imaging for individuals diagnosed with NPH with a shunt should follow **Hydrocephalus Shunts (HD-11.14)**, **Low Pressure Headache and CSF Leak (HD-11.15)**, or **Nuclear Medicine (HD-36.1)**

Background and Supporting Information

Normal Pressure Hydrocephalus (NPH) seen typically in the elderly. It comprises a triad of symptoms: cognitive dysfunction, incontinence of urine, and gait disturbance (typically a “magnetic”, small-step, or broad based gait). The reported neuroradiologic marker for this is ventriculomegaly (enlarged ventricles) in the brain. Unfortunately, these symptoms and this neuroradiologic finding is common in the elderly, making the diagnosis of NPH in any given individual problematic. It is radiographically common and clinically rare.

Imaging Related to Alzheimer's Treatment with Amyloid Reduction Medications (HD-8.5)

HD.DM.0008.5.A

v3.0.2024

Health plans may have specific criteria that differ in their coverage policies.

A pertinent clinical evaluation including a detailed history, mental status testing results, and appropriate laboratory studies should be performed prior to considering treatment with amyloid reduction medications.

Medical records should be provided that support a clinical diagnosis of Mild Cognitive Impairment (MCI) due to Alzheimer's Dementia (AD) or early Alzheimer's Dementia (AD). Other conditions such as Dementia with Lewy Bodies (DLB), Frontotemporal Dementia (FTD), vascular dementia, pseudodementia due to mood disorder, vitamin B12 deficiency, untreated thyroid disease, traumatic brain injury, and/or encephalopathy, have been excluded.

Results of bedside testing and/or neuropsychological testing can be performed when history and mental status examination cannot provide a confident diagnosis.

Donanemab (Kisunla®)

Indication	Supported Imaging
<p>Consideration of Donanemab (Kisunla®) therapy and ALL of the following are met:^{17,18}</p> <ul style="list-style-type: none"> • Patient age ≥59 years of age and ≤ 86 years of age • MCI or Mild dementia due to AD • Mini-Mental State Examination (MMSE) score ≥20 and ≤28 • Progressive change in memory function for at least 6 months • No history of prior intracerebral hemorrhage greater than 1 cm, severe white matter disease OR vasogenic edema • Not currently taking another amyloid reducing drug • The medication is prescribed by a neurologist 	<p>Baseline MRI Brain (<i>within 3 months of medication initiation</i>)</p> <ul style="list-style-type: none"> • MRI Brain without contrast (CPT® 70551) OR • MRI Brain without and with contrast (CPT® 70553) AND/OR • Amyloid PET Brain (CPT® 78811 or 78814)
<p>On Donanemab therapy prior to the 2nd, 3rd, 4th and 7th infusions¹⁷</p>	<ul style="list-style-type: none"> • MRI Brain without contrast (CPT® 70551) OR • MRI Brain without and with contrast (CPT® 70553)
<p>Follow up while on Donanemab therapy with radiographically observed Amyloid-Related Imaging Abnormality (ARIA)</p> <p>See Background and Supporting Information</p>	<ul style="list-style-type: none"> • MRI Brain without contrast (CPT® 70551) OR • MRI Brain without and with contrast (CPT® 70553) per the treating neurologist

Indication	Supported Imaging
Neurologic signs and/or symptoms occurring while on treatment with Donanemab ¹⁷	<ul style="list-style-type: none">• CT Head without contrast (CPT[®] 70450) OR• MRI Brain without contrast (CPT[®] 70551) OR• MRI Brain without and with contrast (CPT[®] 70553) <p>A follow up MRI Brain is appropriate after a CT Head if requested.</p>
Follow up imaging at 6, 12 and 18 months. ^{17,18}	Amyloid PET Brain (CPT [®] 78811 or 78814)

Lecanamab (Leqembi®)

Indication	Supported Imaging
<p>Consideration of Lecanemab (Leqembi) therapy and ALL of the following are met:</p> <ul style="list-style-type: none"> • Patient is ≥ 50 years of age and ≤ 90 years of age • MCI or Mild dementia due to AD • Qualifying test scores include Mini-Mental Status Exam (MMSE) with score ≥ 22, Clinical Dementia Rating global score of 0.5 or 1.0, Clinical Dementia Rating-Sum of Boxes (CDR-SB) ≥ 0.5 and/or a Memory Box score of 0.5 or greater • Patient has no history of brain hemorrhage, bleeding disorder or recent history (within 12 months) of stroke or transient ischemic attacks or any history of seizures • Patient is not taking anticoagulant or antiplatelet agents (except aspirin for prevention of cardiovascular or thromboembolic events) • Not currently taking another amyloid reducing drug • The medication is prescribed by a neurologist 	<p>Baseline MRI Brain (<i>within 3 months of medication initiation</i>)</p> <ul style="list-style-type: none"> • MRI Brain without contrast (CPT® 70551) OR • MRI Brain without and with contrast (CPT® 70553) <p>AND/OR</p> <ul style="list-style-type: none"> • Amyloid PET Brain (CPT® 78811 or CPT® 78814)
<p>On Lecanemab therapy prior to 5th, 7th and 14th infusions</p>	<ul style="list-style-type: none"> • MRI Brain without contrast (CPT® 70551) OR • MRI Brain without and with contrast (CPT® 70553)
<p>Follow up while on Lecanemab therapy with radiographically observed Amyloid-Related Imaging Abnormality (ARIA)</p> <p>See Background and Supporting Information</p>	<ul style="list-style-type: none"> • MRI Brain without contrast (CPT® 70551) OR • MRI Brain without and with contrast (CPT® 70553) per the treating neurologist

Indication	Supported Imaging
Neurologic signs and/or symptoms occurring while on treatment with Lecanemab	<ul style="list-style-type: none"> • CT Head without contrast (CPT[®] 70450) OR • MRI Brain without contrast (CPT[®] 70551) OR • MRI Brain without and with contrast (CPT[®] 70553) <p>A follow-up MRI Brain is appropriate after a CT Head if requested</p>
Post-treatment imaging at 18 months	<ul style="list-style-type: none"> • Amyloid PET Brain (CPT[®] 78811 or CPT[®] 78814)

Background and Supporting Information

Amyloid reduction medications are indicated for the treatment of Mild Cognitive Impairment (MCI) due to Alzheimer's disease and mild, early stage Alzheimer's disease.²⁵

These medications are monoclonal antibodies that selectively bind to aggregated forms of beta amyloid. The accumulation of amyloid plaques in the brain is a defining pathophysiologic feature of Alzheimer's disease. In clinical trials, these medications reduce amyloid beta plaque compared with placebo.²⁵

Amyloid related imaging abnormalities (ARIA) have been caused by these medications. ARIA usually occurs early in treatment and may be asymptomatic although serious and life-threatening events may occur. Screening MRI brain prior to treatment initiation and periodic monitoring during treatment is recommended. For moderate to severe ARIA, treatment may be suspended. Once ARIA is identified on a brain MRI, follow up MRIs are indicated to assess for radiographic resolution and/or symptom resolution with the imaging time frame determined by the treating physician. Resumption of dosing is guided by clinical judgment.²⁵

ARIA may be further characterized as ARIA with edema (ARIA-E) or ARIA with hemosiderin (ARIA-H). ARIA-E presents on MRI as brain edema or sulcal effusions. ARIA-H includes microhemorrhage and superficial siderosis. ARIA-E and ARIA-H may occur simultaneously.²⁵

Although ARIA is usually asymptomatic, symptoms associated with ARIA include headache, confusion, visual changes, dizziness, nausea, aphasia, weakness, gait difficulty and seizures, including status epilepticus. Focal neurologic deficits may also occur.²⁵ The risk of ARIA is increased in apolipoprotein E #4 (ApoE #4) homozygotes.²⁵

References (HD-8)

v3.0.2024

1. McKhann GM, Knopman DS, Chertkow H, et al. The diagnosis of dementia due to Alzheimer's disease: Recommendations from the National Institute on Aging-Alzheimer's Association workgroups on diagnostic guidelines for Alzheimer's disease. *Alzheimer's & Dementia*. 2011;7(3):263-269. doi:10.1016/j.jalz.2011.03.005
2. Wippold FJ 2nd, Brown DC, Broderick DF, et al. ACR Appropriateness Criteria Dementia and Movement Disorders. *J Am Coll Radiol*. 2015;12(1):19-28. doi:10.1016/j.jacr.2014.09.025
3. Knopman DS, DeKosky ST, Cummings JL, et al. Practice parameter: Diagnosis of dementia (an evidence-based review): Report of the Quality Standards Subcommittee of the American Academy of Neurology. *Neurology*. 2001;56(9):1143-1153. doi:10.1212/wnl.56.9.1143
4. Johnson KA, Minoshima S, Bohnen NI, et al. Appropriate use criteria for amyloid PET: A report of the Amyloid Imaging Task Force, the Society of Nuclear Medicine and Molecular Imaging, and the Alzheimer's Association. *Alzheimer's & Dementia*. 2013;9(1):E1-E16. doi:10.1016/j.jalz.2013.01.002
5. Rabinovici GD, Gatsonis C, Apgar C, et al. Association of Amyloid Positron Emission Tomography With Subsequent Change in Clinical Management Among Medicare Beneficiaries With Mild Cognitive Impairment or Dementia. *Jama*. 2019;321(13):1286-1294. doi:10.1001/jama.2019.2000
6. Subramaniam RM, Frey KA, Hunt CH, et al. ACR-ACNM Practice Parameter for the Performance of Dopamine Transporter (DaT) Single Photon Emission Computed Tomography (SPECT) Imaging for Movement Disorders. *Clinical Nuclear Medicine*. 2017;42(11):847-852. doi:10.1097/rlu.0000000000001815
7. Graff-Radford NR, Jones DT. Normal Pressure Hydrocephalus. *CONTINUUM: Lifelong Learning in Neurology*. 2019;25(1):165-186. doi:10.1212/con.0000000000000689
8. Tartaglia MC, Rosen HJ, Miller BL. Neuroimaging in Dementia. *Neurotherapeutics*. 2011;8(1):82-92. doi:10.1007/s13311-010-0012-2
9. ACR ACNM ASNR SNMMI Practice Parameter for Brain PET-CT Imaging in Dementia. 2020
10. Consensus Recommendations for the Postmortem Diagnosis of Alzheimer's Disease. *Neurobiology of Aging*. 1997;18(4):S1-S2. doi:10.1016/s0197-4580(97)00057-2
11. Lombardi G, Crescioli G, Cavedo E, et al. Structural magnetic resonance imaging for the early diagnosis of dementia due to Alzheimer's disease in people with mild cognitive impairment. *Cochrane Database of Systematic Reviews*. Published online March 2, 2020. doi:10.1002/14651858.cd009628.pub2
12. Yousaf T, Dervenoulas G, Valkimadi P-E, Politis M. Neuroimaging in Lewy body dementia. *Journal of Neurology*. 2019;266(1):1-26. doi:10.1007/s00415-018-8892-x
13. Goto H, Ishii K, Uemura T, et al. Differential Diagnosis of Dementia with Lewy Bodies and Alzheimer Disease Using Combined MR Imaging and Brain Perfusion Single-Photon Emission Tomography. *American Journal of Neuroradiology*. 2010;31(4):720-725. doi:10.3174/ajnr.a1926
14. McCleery J, Morgan S, Bradley KM, Noel-Storr AH, Ansorge O, Hyde C. Dopamine transporter imaging for the diagnosis of dementia with Lewy bodies. *Cochrane Database of Systematic Reviews*. Published online January 30, 2015. doi:10.1002/14651858.cd010633.pub2
15. Armstrong MJ. Lewy Body Dementias. *CONTINUUM: Lifelong Learning in Neurology*. 2019;25(1):128-146. doi:10.1212/con.0000000000000685
16. American Psychiatric Association. *Diagnostic and Statistical Manual of Mental Disorders*. 5th ed. American Psychiatric Association; 2013. Pages 591-643.
17. Kisunla[®] intravenous infusion [prescribing information]. Indianapolis, IN: Eli Lilly and Company; July 2024
18. Sims JR, Zimmer JA, Evans CD, et al. Donanemab in Early Symptomatic Alzheimer Disease: The TRAILBLAZER-ALZ 2 Randomized Clinical Trial. *JAMA*. 2023;330(6):512-527. doi:10.1001/jama.2023.13239
19. Zukotynski K, Kuo PH, Mikulis D, et al. PET/CT of Dementia. *American Journal of Roentgenology*. 2018;211(2):246-259. doi:10.2214/ajr.18.19822
20. Nakajima M, Yamada S, Miyajima M, et al. Guidelines for Management of Idiopathic Normal Pressure Hydrocephalus (Third Edition): Endorsed by the Japanese Society of Normal Pressure Hydrocephalus. *Neurologia medico-chirurgica*. 2021;61(2):63-97. doi:10.2176/nmc.st.2020-0292
21. Capone PM, Bertelson JA, Ajtai B. Neuroimaging of Normal Pressure Hydrocephalus and Hydrocephalus. *Neurologic Clinics*. 2020;38(1):171-183. doi:10.1016/j.ncl.2019.09.003

22. Park HY, Park CR, Suh CH, Kim MJ, Shim WH, Kim SJ. Prognostic Utility of Disproportionately Enlarged Subarachnoid Space Hydrocephalus in Idiopathic Normal Pressure Hydrocephalus Treated with Ventriculoperitoneal Shunt Surgery: A Systematic Review and Meta-analysis. *American Journal of Neuroradiology*. 2021;42(8):1429-1436. doi:10.3174/ajnr.a7168
23. Chen KT, Salcedo S, Chonde DB, et al. MR-assisted PET motion correction in simultaneous PET/MRI studies of dementia subjects. *J Magn Reson Imaging*. 2018;48(5):1288-1296. doi:10.1002/jmri.26000
24. Kaltoft NS, Marnier L, Larsen VA, Hasselbalch SG, Law I, Henriksen OM. Hybrid FDG PET/MRI vs. FDG PET and CT in patients with suspected dementia - A comparison of diagnostic yield and propagated influence on clinical diagnosis and patient management. *PLoS One*. 2019;14(5):e0216409. Published 2019 May 2. doi:10.1371/journal.pone.0216409
25. Patel KP, Wymer DT, Bhatia VK, Duara R, Rajadhyaksha CD. Multimodality Imaging of Dementia: Clinical Importance and Role of Integrated Anatomic and Molecular Imaging. *Radiographics*. 2020;40(1):200-222. doi:10.1148/rg.2020190070
26. Svensson A, Granvik E, Sjögren Forss K. Performance of the Eight-item Informant Interview to Differentiate Aging and Dementia within a context similar to the Swedish primary healthcare sector: a systematic review of diagnostic test accuracy studies. *Scand J Prim Health Care*. 2020;38(4):454-463. doi:10.1080/02813432.2020.1844370
27. Leqembi[®] intravenous infusion [prescribing information]. Nutley, NJ: Eisai; July 2023.
28. Cummings J, Apostolova L, Rabinovici GD, et al. Lecanemab: Appropriate Use Recommendations. *J Prev Alzheimers Dis*. 2023;10(3):362-377. doi:10.14283/jpad.2023.30
29. Swanson CJ, Zhang Y, Dhadda S, et al. A randomized, double-blind, phase 2b proof-of-concept clinical trial in early Alzheimer's disease with lecanemab, an anti-A β protofibril antibody [published correction appears in *Alzheimers Res Ther*. 2022 May 21;14(1):70]. *Alzheimers Res Ther*. 2021;13(1):80. Published 2021 Apr 17. doi:10.1186/s13195-021-00813-8

Epilepsy/Seizures (HD-9)

Guideline

Epilepsy/Seizures (HD-9.1)

Perioperative Evaluations for Drug-Resistant Epilepsy (HD-9.2)

References (HD-9)

Epilepsy/Seizures (HD-9.1)

HD.EP.0009.1.A

v3.0.2024

- MRI Brain without and with contrast (CPT[®] 70553) **OR** MRI Brain without contrast (CPT[®] 70551) for:
 - Evaluation of new onset seizures
 - Refractory or drug resistant seizures
 - Change in the type of seizure
 - If CT Head was performed for an initial evaluation for new onset seizure, MRI (as described above) is indicated for additional evaluation
 - Follow-up MRI Brain with “Epilepsy Protocol” is supported.
- Repeat imaging at discretion of the neurologist
- MRI Brain without and with contrast (CPT[®] 70553) **OR** MRI Brain without contrast (CPT[®] 70551) **OR** CT Head without contrast (CPT[®] 70450)¹
- CT Head without contrast (CPT[®] 70450) for:
 - Evaluation of structural findings in seizure etiologies that contain dystrophic calcifications, such as with oligodendrogliomas and tuberous sclerosis.
 - Acute setting of seizure evaluation
- CT Head (contrast as requested) (CPT[®]70450, CPT[®]70460 **OR**, CPT[®]70470) when:
 - MRI is contraindicated
 - Request is urgent
- For Seizure and/or Altered Mental Status associated with Head Trauma, see **Head Trauma (HD-13.1)**
- 3D T1 and/or FLAIR sequences are useful in improving lesion detection for the diagnosis and monitoring of epilepsy. 3D T1 and FLAIR sequences do not require an additional CPT[®] for 3D rendering (CPT[®] 76376 and CPT[®] 76377).¹²

Perioperative Evaluations for Drug-Resistant Epilepsy (HD-9.2)

HD.EP.0009.2.A

v3.0.2024

- The following requests are supported for consideration of potential surgery:
 - MRI Brain without contrast (CPT[®] 70551) **OR** MRI Brain with and without contrast (CPT[®] 70553)
 - Follow-up MRI Brain after a previous routine study if performed with special "Epilepsy Protocol" (typically 3T or 7T magnet, thin sections with angled slices through hippocampus and temporal lobes)
 - FDG PET (CPT[®] 78608)
 - Medicare covers FDG PET for pre-surgical evaluation for the purpose of localization of a focus of refractory seizure activity. The complete coverage policy is found in the **Medicare National Coverage Determinations (NCD) Manual, Section 220.6.9**
 - PET/MRI is MRI Brain without contrast (CPT[®] 70551) **OR** MRI Brain with and without (CPT[®] 70553) co-registered **WITH** FDG-PET Brain (CPT[®] 78608) and is supported for pre-surgical evaluation of refractory seizure when requested by neurosurgeon or neurologist or any provider in consultation with a neurosurgeon or neurologist.^{27, 25, 27}
 - Ictal SPECT (CPT[®] 78803)
 - Functional MRI (fMRI) (CPT[®] 70555 or CPT[®] 70554)
 - If MRA Head (CPT[®] 70544) is indicated but Functional MRI (CPT[®] 70554 or CPT[®] 70555) was erroneously ordered, then CPT[®] 70544 may be substituted when appropriate, (see **Functional MRI (fMRI) (HD-24.2)**)
 - MRI Brain without contrast (CPT[®] 70551) **OR** MRI Brain with and without (CPT[®] 70553)
 - Indicated if co-registered with Magnetoencephalography (MEG)¹
 - 3D rendering CPT[®] 76377 (3D rendering requiring image post-processing on an independent workstation) or CPT[®] 76376 (3D rendering not requiring image post-processing on an independent workstation) is not necessary for epilepsy surgery alone, since 3D rendering can be obtained as part of the MRI Brain epilepsy protocol, unless complicated surgical repair considerations involving craniotomy are required.¹²
- When non-invasive EEG monitoring is insufficient, intracranial monitoring with stereo-EEG or grids/strips and depth electrodes is indicated with additional imaging for neuronavigation. See **Neurosurgical Imaging (HD-28.1)** and **Neuronavigation (HD-28.2)**

- Post-operative imaging including after intracranial (EEG) monitoring per neurosurgeon or neurologist or any provider in consultation with neurosurgeon or neurologist.
- See **Primary Central Nervous System Tumors-General Considerations (ONC-2.1)** in the Oncology Imaging Guidelines and/or **Neurosurgical Imaging (HD-28.1)** for additional imaging requests for surgery

Background and Supporting Information

- Magnetoencephalography (MEG) plays an important role in clarifying the significance of abnormalities seen on both structural and functional imaging, for the purpose of epileptogenic zone localization for surgical planning. When used in conjunction with other techniques, MEG plays a major role in the non-invasive epilepsy surgery evaluation. Currently, eviCore reviews only for the MRI co-registered with MEG.
- MEG followed by co-registration with Brain MRI is referred to as Magnetic Source Imaging (MSI)²⁰

Below are examples of surgical treatment or an interventional modality that may be under active consideration for individuals with intractable epilepsy (not all inclusive):

- Focal Resection
 - Temporal Lobe Resection
 - Extratemporal Resection
- Lesionectomy
- Multiple Subpial Transections
- Laser Interstitial Thermal Therapy (LITT)
- Anatomical or Functional Hemispherectomy and Hemispherotomy
- Corpus Callosotomy
- Stereotactic Radiosurgery
- Neurostimulation Device Implantations (Neuromodulation) including
 - Vagus Nerve Stimulation (VNS)
 - Responsive Neurostimulation (RNS) system also known as NeuroPace
 - Deep Brain Stimulation (DBS)

References (HD-9)

v3.0.2024

1. Expert Panel on Neurological Imaging, Lee RK, Burns J, et al. ACR Appropriateness Criteria® Seizures and Epilepsy. *J Am Coll Radiol*. 2020;17(5S):S293-S304. doi:10.1016/j.jacr.2020.01.037
2. Krumholz A, Wiebe S, Gronseth GS, et al. Evidence-based guideline: Management of an unprovoked first seizure in adults: Report of the Guideline Development Subcommittee of the American Academy of Neurology and the American Epilepsy Society. *Neurology*. 2015;84(16):1705-1713. doi:10.1212/wnl.0000000000001487
3. Hirtz D, Berg A, Bettis D, et al. Practice parameter: treatment of the child with a first unprovoked seizure: Report of the Quality Standards Subcommittee of the American Academy of Neurology and the Practice Committee of the Child Neurology Society. *Neurology*. 2003;60(2):166-175. doi:10.1212/01.wnl.0000033622.27961.b6
4. Lapalme-Remis S, Nguyen DK. Neuroimaging of Epilepsy. *Continuum (Minneap Minn)*. 2022;28(2):306-338. doi:10.1212/CON.0000000000001080
5. Tranvinh E, Lanzman B, Provenzale J, Wintermark M. Imaging Evaluation of the Adult Presenting With New-Onset Seizure. *AJR Am J Roentgenol*. 2019;212(1):15-25. doi:10.2214/ajr.18.20202
6. Ho K, Lawn N, Bynevelt M, Lee J, Dunne J. Neuroimaging of first-ever *Neurol Clin Pract*. 2013;3(5):398-403. doi:10.1212/CPJ.0b013e3182a78f25
7. Knowlton RC, Elgavish RA, Bartolucci A, et al. Functional imaging: II. Prediction of epilepsy surgery outcome. *Ann Neurol*. 2008;64(1):35-41. doi:10.1002/ana.21419
8. Weil S, Noachtar S, Arnold S, Yousry TA, Winkler PA, Tatsch K. Ictal ECD-SPECT differentiates between temporal and extratemporal epilepsy: confirmation by excellent postoperative seizure control. *Nucl Med Commun*. 2001;22(2):233-237. doi:10.1097/00006231-200102000-00016.
9. Qiu J, Cui Y, Qi B, Sun L, Zhu Z. The application of preoperative computed tomography angiogram for hemispherectomy. *Clin Pract*. 2017;7(4). doi:10.4081/cp.2017.992.
10. Guedj E, Varrone A, Boellaard R, et al. EANM procedure guidelines for brain PET imaging using [¹⁸F]FDG, version 3 [published correction appears in *Eur J Nucl Med Mol Imaging*. 2022 Mar 7;:]. *Eur J Nucl Med Mol Imaging*. 2022;49(2):632-651. doi:10.1007/s00259-021-05603-w
11. Correction to: EANM procedure guidelines for brain PET imaging using [¹⁸F]FDG, version 3. Guedj E, Varrone A, Boellaard R, Albert NL, Barthel H, van Berckel B, Brendel M, Cecchin D, Ekmekcioglu O, Garibotto V, Lammertsma AA, Law I, Peñuelas I, Semah F, Traub-Weidinger T, van de Giessen E, Van Weehaeghe D, Morbelli S. *Eur J Nucl Med Mol Imaging*. 2022 May;49(6):2100-2101. doi: 10.1007/s00259-022-05755-3.
12. Bernasconi A, Cendes F, Theodore WH, et al. Recommendations for the use of structural magnetic resonance imaging in the care of patients with epilepsy: A consensus report from the International League Against Epilepsy Neuroimaging Task Force. *Epilepsia*. 2019;60(6):1054-1068. doi:10.1111/epi.15612
13. Passaro EA. Neuroimaging in Adults and Children With Epilepsy. *Continuum (Minneap Minn)*. 2023;29(1):104-155. doi:10.1212/CON.0000000000001242
14. Szaflarski JP, Gloss D, Binder JR, et al. Practice guideline summary: Use of fMRI in the presurgical evaluation of patients with epilepsy: Report of the Guideline Development, Dissemination, and Implementation Subcommittee of the American Academy of Neurology. *Neurology*. 2017;88(4):395-402. doi:10.1212/WNL.0000000000003532
15. Ponisio MR, Zempel JM, Day BK, et al. The Role of SPECT and PET in Epilepsy. *AJR Am J Roentgenol*. 2021;216(3):759-768. doi:10.2214/AJR.20.23336
16. Rampf S, Stefan H, Wu X, et al. Magnetoencephalography for epileptic focus localization in a series of 1000 cases. *Brain*. 2019;142(10):3059-3071. doi:10.1093/brain/awz23
17. Culler GW 4th, Jobst BC. Surgical Treatments for Epilepsy. *Continuum (Minneap Minn)*. 2022;28(2):536-558. doi:10.1212/CON.0000000000001106
18. Delev D, Quesada CM, Grote A, et al. A multimodal concept for invasive diagnostics and surgery based on neuronavigated voxel-based morphometric MRI postprocessing data in previously nonlesional epilepsy. *J Neurosurg*. 2018;128(4):1178-1186. doi:10.3171/2016.12.jns161676.
19. Englot DJ, Nagarajan SS, Imber BS, et al. Epileptogenic zone localization using magnetoencephalography predicts seizure freedom in epilepsy surgery. *Epilepsia*. 2015;56(6):949-958. doi:10.1111/epi.13002

20. Laohathai C, Ebersole JS, Mosher JC, et al. Practical Fundamentals of Clinical MEG Interpretation in Epilepsy.*Front Neurol.* 2021;12:722986. Published 2021 Oct 14. doi:10.3389/fneur.2021.722986
21. Carrette E, Stefan H. Evidence for the Role of Magnetic Source Imaging in the Presurgical Evaluation of Refractory Epilepsy Patients.*Front Neurol.* 2019;10:933. Published 2019 Sep 10. doi:10.3389/fneur.2019.00933
22. Spencer D. MRI (minimum recommended imaging) in epilepsy.*Epilepsy Curr.* 2014;14(5):261-263. doi:10.5698/1535-7597-14.5.261
23. Wellmer J, Quesada CM, Rothe L, Elger CE, Bien CG, Urbach H. Proposal for a magnetic resonance imaging protocol for the detection of epileptogenic lesions at early outpatient stages.*Epilepsia.* 2013;54(11):1977-1987. doi:10.1111/epi.12375
24. Oldan JD, Shin HW, Khandani AH, Zamora C, Benefield T, Jewells V. Subsequent experience in hybrid PET-MRI for evaluation of refractory focal onset epilepsy.*Seizure.* 2018;61:128-134. doi:10.1016/j.seizure.2018.07.022
25. Salamon N, Kung J, Shaw SJ, et al. FDG-PET/MRI coregistration improves detection of cortical dysplasia in patients with epilepsy. *Neurology.* 2008;71(20):1594-1601. doi:10.1212/01.wnl.0000334752.41807.2f
26. Johnson R, Rizk G, Kaur H, Ibekwe H, Atta M, Gayed I. Refractory seizures: Prediction of outcome of surgical intervention based on results from PET-CT, PET-MRI and electroencephalography.*Neuroradiol J.* 2020;33(1):57-65. doi:10.1177/1971400919881464
27. Tóth M, Barsi P, Tóth Z, et al. The role of hybrid FDG-PET/MRI on decision-making in presurgical evaluation of drug-resistant epilepsy.*BMC Neurol.* 2021;21(1):363. Published 2021 Sep 18. doi:10.1186/s12883-021-02352-z

Trigeminal Neuralgia and other Centrally Mediated Facial Pain Syndromes (HD-10)

Guideline

Trigeminal Neuralgia/Trigeminal Neuropathy (HD-10.1)

Glossopharyngeal Neuralgia/Glossopharyngeal Neuropathy (HD-10.2)

References (HD-10)

Trigeminal Neuralgia/Trigeminal Neuropathy (HD-10.1)

HD.TM.0010.1.A

v3.0.2024

- MRI Brain without and with contrast (CPT[®] 70553) (with special attention to the skull base) or MRI Brain without contrast (CPT[®] 70551) **AND/OR** facial imaging, MRI Orbit/Face/Neck without contrast (CPT[®] 70540) or MRI Orbit/Face/Neck with and without contrast (CPT[®] 70543)⁵ for:
 - Symptoms of trigeminal neuropathy⁵
 - Suspected trigeminal neuralgia or one of its cranial nerve variants such as glossopharyngeal neuralgia (CN IX), (see **Glossopharyngeal Neuralgia/ Glossopharyngeal Neuropathy (HD-10.2)**)
 - Concern about an underlying diagnosis of multiple sclerosis
 - Trigeminal neuralgia which involves the ophthalmic nerve, (periorbital or forehead pain), once post-herpetic neuralgia (a complication of shingles) has been excluded by history
- CT Maxillofacial without contrast (CPT[®] 70486) or CT Maxillofacial with contrast (CPT[®]70487) for evaluating the skull base and neural foramina⁵
- Contrast-enhanced navigation protocol CT (CPT[®] 76497) for gamma knife stereotactic radiosurgery for trigeminal neuralgia⁵, (see also, **Neuronavigation (HD-28.2)** and **Post Operative Imaging (HD-28.3)**) for post-treatment imaging studies
- MRA Head (CPT[®] 70544, CPT[®] 70545 or CPT[®] 70546) or CTA Head (CPT[®] 70496) for:
 - Trigeminal neuralgia (vascular imaging may be obtained concurrently with structural brain imaging)⁵
 - Failed medical treatment
 - Surgical planning

Background and Supporting Information

The differential diagnosis of facial pain is extensive, complex, and difficult, and there is considerable case-to-case variation in optimal imaging pathway.

Symptoms of trigeminal neuropathy include facial pain, facial numbness, and/or weakness of the muscles of mastication.

Trigeminal neuralgia, also known as tic douloureux (the involuntary wincing associated with the occurrence of pain), refers to sudden, severe, shooting "electrical" pains along

one or more sensory divisions of the trigeminal nerve, provoked by movements such as chewing, or by external stimuli, such as wind blowing or touching the face.

Glossopharyngeal Neuralgia/ Glossopharyngeal Neuropathy (HD-10.2)

HD.TM.0010.2.A

v3.0.2024

- MRI Brain without and with contrast (CPT[®] 70553) or MRI Brain without contrast (CPT[®] 70551) **AND/OR** MRI Orbit/Face/Neck without and with contrast (CPT[®] 70543) or MRI Orbit/Face/Neck without contrast (CPT[®] 70540) for suspected glossopharyngeal neuralgia or neuropathy⁵
- CT Neck with contrast (CPT[®] 70491) to delineate skull base erosion, deep space neck masses, calcifications, the skull base bony anatomy and/or the stylohyoid ligament⁵ (see also **Eagle Syndrome (Neck-10.3)**)
- MRA Head with contrast (CPT[®] 70545), or MRA Head without and with contrast (CPT[®] 70546) **AND/OR** MRA Neck with contrast (CPT[®] 70548), or MRA Neck without and with contrast (CPT[®] 70549), to assess for neurovascular compression for the evaluation of glossopharyngeal neuralgia⁵

Background and Supporting Information

- Glossopharyngeal neuralgia presents as severe pain in the throat and neck, classically triggered by swallowing⁵.
- Glossopharyngeal neuropathy may present with pain, dysphagia, loss of gag reflex, impaired taste, and impaired sensation along posterior one-third of the tongue and/or inability to elevate the palate⁵.

References (HD-10)

v3.0.2024

1. Goh BT, Poon CY, Peck RHL. The importance of routine magnetic resonance imaging in trigeminal neuralgia diagnosis. *Oral Surgery, Oral Medicine, Oral Pathology, Oral Radiology, and Endodontology*. 2001;92(4):424-429. doi:10.1067/moe.2001.115130
2. Yaltho TC, Jankovic J. The many faces of hemifacial spasm: Differential diagnosis of unilateral facial spasms. *Movement Disorders*. 2011;26(9):1582-1592. doi:10.1002/mds.23692
3. Cruccu G. Trigeminal Neuralgia. *CONTINUUM: Lifelong Learning in Neurology*. 2017;23(2):396-420. doi:10.1212/con.0000000000000451
4. AAN Practice Parameter: The Diagnostic Evaluation and Treatment of Trigeminal Neuralgia. October 2008. Reaffirmed 7/21/2018
5. Expert Panel on Neurological Imaging, Rath TJ, Policeni B, et al. ACR Appropriateness Criteria® Cranial Neuropathy: 2022 Update. *J Am Coll Radiol*. 2022;19(11S):S266-S303. doi:10.1016/j.jacr.2022.09.021

Headache (HD-11)

Guideline

- Headache General Guidelines (HD-11.0)
- Headache and Suspected Vascular Dissection (HD-11.1)
- Headaches with Red Flags (HD-11.2)
- Sudden Onset of Headache (HD-11.3)
- Trigeminal Autonomic Cephalgias (HD-11.4)
- Skull Base, Orbit, Periorbital or Oromaxillary (HD-11.5)
- Suspected Intracranial Extension of Sinusitis or Mastoiditis (HD-11.6)
- New Headache Onset Older than Age 50 (HD-11.7)
- Cancer or Immunosuppression (HD-11.8)
- Abnormal Blood Clotting (HD-11.9)
- Pregnancy (HD-11.10)
- Physical Exertion (HD-11.11)
- Headaches Associated With Head Trauma (HD-11.12)
- Systemic Infections (HD-11.13)
- Hydrocephalus Shunts (HD-11.14)
- Low Pressure Headache and CSF Leak (HD-11.15)
- Cervicogenic Headaches Including Occipital Neuritis/Neuralgia (HD-11.16)
- Advanced Imaging Indications Related To Migraines (HD-11.17)
- References (HD-11)

Headache General Guidelines (HD-11.0)

HD.HA.0011.0A

v3.0.2024

- Advanced imaging of the head is NOT indicated for any of the following:
 - Primary headache disorder in the absence of focal neurological deficits or "red flags" (see **Headaches with Red Flags (HD-11.2)** and **Advanced Imaging Indications Related to Migraines (HD-11.17)**)
 - Newly diagnosed migraine or tension-type headache with a normal neurologic exam or for chronic stable headache including migraine with no neurologic deficit.¹⁶
 - Duplex Ultrasound Carotid Arteries (CPT[®] 93880) does not have a role in the evaluation of headaches (including migraines), except for suspected carotid dissection (see **Initial Imaging (PVD-3.1)** in the Peripheral Vascular Disease Imaging Guidelines, **Headache and Suspected Vascular Dissection (HD-11.1)**, and **Stroke/TIA (HD-21.1)**)

Background and Supporting Information

- The yield of detecting abnormal, treatable lesions by CT or MRI in individuals with headache but normal neurological exam has been found to be low¹⁶

Headache and Suspected Vascular Dissection (HD-11.1)

HD.HA.0011.1A

v3.0.2024

- CTA Neck (CPT[®] 70498) and MRA Neck (CPT[®] 70547, CPT[®] 70548, or CPT[®] 70549) are appropriate in the evaluation for headache with suspected carotid or vertebral artery dissection and in certain high risk scenarios including, but not exclusive to: Fibromuscular dysplasia (FMD), Marfan Disease, acute MVA with whiplash, and acute headache and/or neck pain due to chiropractic manipulation.
 - CTA Head (CPT[®] 70496) or MRA Head (CPT[®] 70544, CPT[®] 70545, or CPT[®] 70546) is indicated if there is concern for extension of a carotid dissection to the skull base or above
 - Evaluation of posterior circulation disease requires both neck and head MRA/CTA to visualize the entire vertebral-basilar system
- MRA Neck (CPT[®] 70547, CPT[®] 70548, or CPT[®] 70549) or CTA Neck (CPT[®] 70498) if arterial dissection is suspected, or known and re-evaluation is needed (as directed by neurologist or neurosurgeon or any provider in consultation with a neurologist or neurosurgeon)
- MRA Head (CPT[®] 70544, CPT[®] 70545, or CPT[®] 70546) or CTA Head (CPT[®] 70496, or CPT[®] 70498) if arterial dissection is suspected, or known and re-evaluation is needed (as directed by neurologist or neurosurgeon or any provider in consultation with a neurologist or neurosurgeon)
- Other vascular imaging indications for headaches require additional information.
 - See **Stroke/TIA (HD-21.1)**, **Sudden Onset of Headache (HD-11.3)**, **New Headache Onset Older than Age 50 (HD-11.7)**, **Abnormal Blood Clotting (HD-11.9)**, **Pregnancy (HD-11.10)**, **Physical Exertion (HD-11.11)**, and **Systemic Infections (HD-11.13)**

Headaches with Red Flags (HD-11.2)

HD.HA.0011.2A

v3.0.2024

- MRI Brain without and with contrast (CPT[®] 70553) or MRI Brain without contrast (CPT[®] 70551) or CT Head without contrast (CPT[®] 70450) supported for any of the following:
 - Headache accompanied by seizures, vomiting, focal neurological complaints including dizziness, visual change, altered mental status, or acute hypertension (see **Primary Central Nervous System Tumors – General Considerations (ONC-2.1)** in the Oncology Imaging Guidelines and **Stroke/TIA (HD-21.1)**)
 - Abnormal examination findings (including, but not limited to, altered mental status, papilledema, focal signs or symptoms including unilateral weakness or sensory loss, hyperreflexia, clonus, increased tone, Hoffman or Babinski sign, loss of coordination, seizures, gait disturbance, cranial nerve abnormality, vision loss, nystagmus, dysarthria, dysphagia, fever, meningismus)
- Headaches with any of the following Red Flags - If any of the below unusual symptoms or history are present advanced imaging studies are supported (see relevant section):
 - Cancer history or immunosuppression (see **Cancer or Immunosuppression (HD-11.8)**)
 - Sudden onset (see **Sudden Onset of Headache (HD-11.3)**)
 - New onset age >50 (see **New Headache Onset Older than Age 50 (HD-11.7)** and **Migraine Exceptions (HD-11.17)**)
 - History of head trauma (see **Headaches Associated with Head Trauma (HD-11.12)**, and **Head and Facial Trauma (HD-13)**)
 - Headache precipitated by cough or valsalva, physical exertion, or sexual activity (see **Physical Exertion (HD-11.11)**)
 - Currently pregnant (including pregnancy and the immediate postpartum period) (see **Pregnancy (HD-11.10)**)
 - Hypercoagulable state or bleeding disorder (see **Abnormal Blood Clotting (HD-11.9)**)
 - New persistent headache (see **Migraine Exceptions (HD-11.17)**)
 - Headache awakens individual from sleep (see **Sudden Onset of Headache (HD-11.3)**)
- Chronic headache with significant change in character, severity or frequency of headache (For example: progressively worsening headache over a period of days or weeks, transformation of established migraine to chronic daily headaches):
 - MRI Brain without and with contrast (CPT[®] 70553); or
 - MRI Brain without contrast (CPT[®] 70551); or

- CT Head without contrast (CPT[®] 70450)
- MRA/MRV Head (CPT[®] 70544, CPT[®] 70545, or CPT[®] 70546) or CTA/CTV Head (CPT[®] 70496) can be added to evaluate the recent onset of a progressive, severe, daily headache, with or without papilledema and concern for cerebral venous sinus thrombosis.
 - CT and MR Venography (CTV and MRV) are reported with the same codes as the CTA/MRA counterpart. If arterial and venous CT or MR studies are both performed in the same session, only **ONE** CPT[®] code should be used to report both procedures
- For papilledema, see **Papilledema/Pseudotumor Cerebri (HD-17.1)**

Background and Supporting Information

Aura symptoms may accompany or precede a headache within 60 minutes and may include, but are not exclusive to the following symptoms:²⁸

- Visual (flashing lights, loss of vision)
- Sensory (paresthesia)
- Speech and/or language (difficulty speaking)
- Motor (any weakness)
- Brainstem (dizziness, double vision) and retinal (visual complaints)

Sudden Onset of Headache (HD-11.3)

HD.HA.0011.3.A

v3.0.2024

- For sudden onset of headache including:
 - Worst, most severe headache ever experienced or thunderclap-type (example: awakening from sleep)
 - Sudden onset unilateral headache, suspected carotid or vertebral dissection or ipsilateral Horner's syndrome
 - Consideration of reversible cerebral vasoconstriction syndrome (RCVS) (typically bilateral headache)
 - High risk scenarios including Fibromuscular Dysplasia (FMD), Marfan Disease, MVA with whiplash, and chiropractic manipulation
- If any of these onset of headache features are present, the following are supported:
 - CT Head without contrast (preferred study) (CPT[®] 70450) **OR** MRI Brain without contrast (CPT[®] 70551) **OR** MRI Brain without and with contrast (CPT[®] 70553) **AND/OR**
 - CTA Head (CPT[®] 70496) **or** MRA Head (CPT[®] 70544, CPT[®] 70545, or CPT[®] 70546)
 - MRA Neck (CPT[®] 70547, CPT[®] 70548, or CPT[®] 70549) **OR** CTA Neck (CPT[®] 70498) if carotid or vertebral dissection is suspected
 - CT and MR Venography (CTV and MRV) are reported with the same codes as the CTA/MRA counterpart. If arterial and venous CT or MR studies are both performed in the same session, only **ONE** CPT[®] code should be used to report both procedures
- Repeat MRA/CTA Head and Neck imaging in 2-4 weeks if suspicion of Reversible Cerebral Vasoconstriction Syndrome (RCVS) is high⁸
- MRA Neck (CPT[®] 70547, CPT[®] 70548, or CPT[®] 70549) or CTA Neck (CPT[®] 70498) if arterial dissection is suspected, or known and re-evaluation is needed (as directed by neurologist or neurosurgeon or any provider in consultation with a neurologist or neurosurgeon)
- MRA Head (CPT[®] 70544, CPT[®] 70545, or CPT[®] 70546) or CTA Head (CPT[®] 70496, or CPT[®] 70498) if arterial dissection is suspected, or known and re-evaluation is needed (as directed by neurologist or neurosurgeon or any provider in consultation with a neurologist or neurosurgeon)
- Other vascular imaging indications for headaches require additional information.
 - See **Stroke/TIA (HD-21.1)**, **New Headache Onset Older than Age 50 (HD-11.7)**, **Abnormal Blood Clotting (HD-11.9)**, **Pregnancy (HD-11.10)**, **Physical Exertion (HD-11.11)**, **Intracranial Aneurysms (HD-12.1)**, and **Systemic Infections (HD-11.13)**

Trigeminal Autonomic Cephalgias (HD-11.4)

HD.HA.0011.4.A

v3.0.2024

- For trigeminal autonomic cephalgias and cluster headache²⁷:
 - MRI Brain without and with contrast (preferred study) (CPT[®] 70553) **OR**
 - MRI Brain without contrast (CPT[®] 70551)
 - May also include pituitary screening (see **Pituitary (HD-19)**)
- For facial pain (see **Trigeminal Neuralgia and other Centrally Mediated Facial Pain Syndromes (HD-10)**)

Background and Supporting Information

Trigeminal autonomic cephalgias includes cluster headache, short-lasting, unilateral, neuralgiform headache attacks with conjunctival injection and tearing (SUNCT) syndromes; short-lasting unilateral neuralgiform headache attacks with cranial autonomic symptoms (SUNA) and hemicrania paroxysmal and continua.

Skull Base, Orbit, Periorbital or Oromaxillary (HD-11.5)

HD.HA.0011.5.A

v3.0.2024

- Skull base, orbital, periorbital or oromaxillary¹ imaging is indicated for concern of skull base tumors in individuals with head and neck cancers, other skull base abnormalities seen on previous imaging, any invasive sinus infections as well as sinus tumors or orbital tumors with intracranial extension.
- In these clinical scenarios, the following studies are indicated:
 - MRI Brain and/or Orbits/Face/Neck without and with contrast (preferred study) (CPT[®] 70553 and/or CPT[®] 70543) **OR**
 - MRI Brain and/or Orbits/Face/Neck without contrast (CPT[®] 70551 and/or CPT[®] 70540) **OR**
 - CT Head and/or Orbits/Temporal bone without and with contrast (CPT[®] 70470 and/or CPT[®] 70482) **OR**
 - CT Head and/or Orbits/Temporal bone with contrast (CPT[®] 70460 and/or CPT[®] 70481)

Suspected Intracranial Extension of Sinusitis or Mastoiditis (HD-11.6)

HD.HA.0011.6.A

v3.0.2024

- For suspected intracranial extension of sinusitis or mastoiditis:
 - MRI Brain without and with contrast (CPT[®] 70553)
 - See **Mastoid Disease or Ear Pain (HD-26.1)** and **Skull Base, Orbit, Periorbital or Oromaxillary (HD-11.5)**

New Headache Onset Older than Age 50 (HD-11.7)

HD.HA.0011.7.A

v3.0.2024

- For new onset headache in individuals older than 50 years of age:
 - MRI Brain without and with contrast (preferred study) (CPT[®] 70553) **OR**
 - MRI Brain without contrast (CPT[®] 70551) **OR**
 - CT Head without contrast (CPT[®] 70450)
 - If Giant Cell Arteritis, also known as Temporal Arteritis, is suspected, MRA Head (CPT[®] 70544, CPT[®] 70545, or CPT[®] 70546), see **Cerebral Vasculitis (HD-22)**

Cancer or Immunosuppression (HD-11.8)

HD.HA.0011.8A

v3.0.2024

- For new headache in individuals with cancer or who are immunocompromised:
 - MRI Brain without and with contrast (preferred study) (CPT[®] 70553) **OR**
 - MRI Brain without contrast (CPT[®] 70551)

Abnormal Blood Clotting (HD-11.9)

HD.HA.0011.9A

v3.0.2024

- MRI Brain without and with contrast (CPT[®] 70553) **OR** MRI Brain without (CPT[®] 70551) **OR** CT Head without contrast (CPT[®] 70450):
 - New onset headaches in individual with hypercoagulable states or bleeding disorder
 - MRA/MRV Head (CPT[®] 70544, CPT[®] 70545, or CPT[®] 70546) or CTA/CTV Head (CPT[®] 70496) may be added for venogram when requested.
 - CT and MR Venography (CTV and MRV) are reported with the same codes as the CTA/MRA counterpart. If arterial and venous CT or MR studies are both performed in the same session, only **ONE** CPT[®] code should be used to report both procedures
 - Individuals with potential for bleeding diathesis
 - Taking anticoagulants or two or more antiaggregants or having a medical condition that predisposes to bleeding (for example, but not limited to: thrombocytopenia, liver failure, Idiopathic Thrombocytopenic Purpura (ITP), etc.).

Pregnancy (HD-11.10)

HD.HA.0011.10.A

v3.0.2024

- For new onset headache during pregnancy or immediate post-partum period (within 3 months after delivery):
 - MRI Brain without contrast (Gadolinium relatively contraindicated in pregnancy) (CPT[®] 70551)
 - MRA/MRV Head (CPT[®] 70544, CPT[®] 70545, or CPT[®] 70546) or CTA/CTV Head (CPT[®] 70496) when venogram is requested
 - CT and MR Venography (CTV and MRV) are reported with the same codes as the CTA/MRA counterpart. If arterial and venous CT or MR studies are both performed in the same session, only one CPT[®] code should be used to report both procedures. (Gadolinium relatively contraindicated in pregnancy)
 - Vascular imaging can be performed concurrently with brain imaging
- Important causes of secondary headache include vascular disorders, such as pre-eclampsia, reversible cerebral vasoconstriction syndrome, and cerebral venous thrombosis, as well as idiopathic intracranial hypertension^{1,6}
- For post LP/epidural anesthesia, see **Low Pressure Headache and CSF Leak (HD-11.15)**

Physical Exertion (HD-11.11)

HD.HA.0011.11.A

v3.0.2024

- For onset of headache with Valsalva maneuver, cough, physical exertion, change in position, **or** sexual activity, but not merely a worsening of a pre-existing headache with these activities, the following procedures are supported:²⁶
 - MRI Brain without and with contrast (preferred study) (CPT[®] 70553) **OR**
 - MRI Brain without contrast (CPT[®] 70551) **OR**
 - CT Head without contrast (CPT[®] 70450) **AND/OR**
 - MRA Head (CPT[®] 70544, CPT[®] 70545, or CPT[®] 70546) **OR**
 - CTA Head without and with contrast (CPT[®] 70496)
 - MRA Neck (CPT[®] 70547, CPT[®] 70548, or CPT[®] 70549) or CTA Neck (CPT[®] 70498) if carotid or vertebral artery dissection or aneurysm is suspected

Headaches Associated With Head Trauma (HD-11.12)

HD.HA.0011.12.A

v3.0.2024

- New or progressively worsening headache with subacute head trauma, defined as within 7 days to three months post-trauma, with or without unexplained cognitive or neurologic deficits:¹⁴
 - CT Head without contrast (CPT[®] 70450) **OR**
 - MRI Brain without contrast (CPT[®] 70551)
- Persistent headaches attributed to traumatic injury to the head persisting for longer than 3 months following the injury, with or without unexplained cognitive or neurologic deficits:¹⁴
 - MRI Brain without contrast (CPT[®] 70551) **OR**
 - MRI Brain without and with contrast (CPT[®] 70553)
- Acute head trauma with headache, see **Head Trauma (HD-13.1)**
- Acute headache attributed to traumatic injury to the head that developed within 7 days of injury¹⁴ that does not meet criteria under **Head and Facial Trauma (HD-13)**, other subsections may apply including, but not exclusive to: **Headaches with Red Flags (HD-11.2)** and **Sudden Onset of Headache (HD-11.3)**

Systemic Infections (HD-11.13)

HD.HA.0011.13.A

v3.0.2024

- Headaches in the setting of acute, subacute, or chronic systemic infections:
 - MRI Brain without and with contrast (preferred study) (CPT[®] 70553); or MRI Brain without contrast (CPT[®] 70551)
 - MRA/MRV Head (CPT[®] 70544, CPT[®] 70545, or CPT[®] 70546)
 - CT and MR Venography (CTV and MRV) are reported with the same codes as the CTA/MRA counterpart. If arterial and venous CT or MR studies are both performed in the same session, only one CPT[®] code should be used to report both procedures
 - CT Head without contrast (CPT[®] 70450) or CT Head without and with contrast (CPT[®] 70470) when MRI Brain is contraindicated (see **General Guidelines – CT Head (HD-1.4)** for additional CT Head indications)
 - CT Head without (CPT[®] 70450) prior to performance of Lumbar Puncture (aka spinal tap)
- See **CNS and Head Infection (HD-14.1)**
- See **Neuro-COVID-19 and Sars-CoV-2 Vaccines (HD-14.2)** for headache related to neuro-COVID-19 or SARS-CoV-2 vaccines

Hydrocephalus Shunts (HD-11.14)

HD.HA.0011.14A

v3.0.2024

Initial Imaging Indications

- MRI Brain without and with contrast (CPT[®] 70553) is indicated

Repeat Imaging Indications including CSF flow shunting and Ventriculostomy

- MRI Brain without contrast (CPT[®] 70551) or CT Head without contrast (CPT[®] 70450) for any of the following:
 - New signs or symptoms suggesting shunt malfunction or endoscopic third ventriculostomy (ETV) malfunction
 - Symptoms may include but are not limited to: sepsis after shunt setting adjustments, decreased level of consciousness, protracted vomiting, visual or neurologic deterioration, decline of mentation after initial improvement, or new or changing pattern of seizures
 - Requests ordered by a neurologist, neurosurgeon, or any provider in consultation with a neurologist or neurosurgeon
- MRI Brain without contrast (CPT[®] 70551) or CT Head without contrast (CPT[®] 70450) is indicated in the post-operative period following shunt placement or ETV, with further follow-up imaging 6-12 months after the procedure and then every 12 months for individuals with stable clinical findings
- Shunting into the peritoneum (VP shunts) can give rise to abdominal complications, but these are generally symptomatic, so surveillance imaging of the abdomen is not indicated.
 - Abdominal ultrasound (CPT[®] 76700) for suspicion of CSF pseudocyst formation or distal shunt outlet obstruction.
- See **General Guidelines – Other Imaging Situations (HD-1.7)**

Additional Rarely Used Studies

- Cisternogram (CPT[®] 78630) for the following:
 - Known hydrocephalus with worsening symptoms.
 - Suspected obstructive hydrocephalus.
 - Suspected normal pressure hydrocephalus with gait disturbance and either dementia or urinary incontinence.
 - CSF Leak (see **Low Pressure Headache and CSF Leak (HD-11.15)** and **Nuclear Medicine (HD-36.1)**)
- Cerebrospinal Ventriculography (CPT[®] 78635) for the following:
 - Evaluation of internal shunt, porencephalic cyst, or posterior fossa cyst.

- Nuclear Medicine Shunt Evaluation (CPT[®] 78645) and CSF Flow SPECT (CPT[®] 78803) for the following:
 - Suspected malfunction of ventriculoperitoneal, ventriculopleural, or ventriculovenous shunts.
- For CSF flow imaging, see **CSF Flow Imaging (HD-24.4)**
- See also **General Guidelines - CT Head (HD-1.4)**

Background and Supporting Information

- Ventriculomegaly is the condition where ventricles are enlarged, and this may be due to 1) hydrocephalus, a condition of increased intracranial pressure (ICP) (imaging shows ventricles are disproportionately enlarged compared to sulci), or 2) brain atrophy, most commonly related to age or trauma, which is not associated with increased ICP (imaging shows ventricles and sulci are proportionately enlarged).
- Hydrocephalus is divided into obstructive/non-communicating vs. communicating types, and these usually have different etiologies and radiographic features.
- Obstructive or non-communicating hydrocephalus classically involves an intraventricular obstruction in which CSF flow over the convexities and between the ventricles is reduced, and the proximal ventricle(s) is/are dilated. This is a medical emergency.
- Communicating hydrocephalus involves extraventricular obstruction, poor absorption or overproduction of CSF. There is normal intracranial CSF flow and absence of disproportionate ventricular dilation, yet there is still a mildly increased CSF pressure. Normal pressure hydrocephalus is an example of this type.
- Distinguishing between ventriculomegaly due to brain atrophy and non-communicating hydrocephalus can be difficult with MRI Brain or CT Head alone, and modalities which visualize CSF flow may be useful such as cisternography or CT cisternography.

Low Pressure Headache and CSF Leak (HD-11.15)

HD.HA.0011.15A

v3.0.2024

- Evaluation of suspected CSF leak (rhinorrhea/otorrhea) or refractory post-lumbar puncture or low pressure headache:¹⁵

Indication	Supported Imaging
Intracranial imaging	<ul style="list-style-type: none"> ◦ MRI brain without and with contrast (CPT 70553)
Spinal imaging (MRI)	<ul style="list-style-type: none"> ◦ MRI Cervical Spine without contrast (CPT[®] 72141) or without and with contrast (CPT[®] 72156) <p>AND/OR</p> <ul style="list-style-type: none"> ◦ MRI Thoracic Spine without contrast (CPT[®] 72146) or without and with contrast (CPT[®] 72157) <p>AND/OR</p> <ul style="list-style-type: none"> ◦ MRI Lumbar Spine without contrast (CPT[®] 72148) or without and with contrast (CPT[®] 72158)
Spinal imaging, post-myelogram	<ul style="list-style-type: none"> ◦ CT Cervical Spine with contrast (CPT[®] 72126) <p>AND/OR</p> <ul style="list-style-type: none"> ◦ CT Thoracic Spine with contrast (CPT[®] 72179) <p>AND/OR</p> <ul style="list-style-type: none"> ◦ CT Lumbar Spine with contrast (CPT[®] 72132)
Cisternogram, radionuclide (111 In-DTPA)	<ul style="list-style-type: none"> ◦ Radionuclide cisternogram (CPT[®] 78630)
Cisternogram, post-myelogram (iodinated contrast)	<ul style="list-style-type: none"> ◦ CT Head with contrast (CPT[®] 70451) <p>OR</p> <ul style="list-style-type: none"> ◦ CT Maxillofacial with contrast (CPT[®] 70487) <p>OR</p> <ul style="list-style-type: none"> ◦ CT Temporal Bone with contrast (CPT[®] 70481)

Indication	Supported Imaging
Symptoms of CSF rhinorrhea or otorrhea	<ul style="list-style-type: none"> ◦ CT Head without contrast (CPT[®] 70450) <p>AND/OR</p> <ul style="list-style-type: none"> ◦ CT Maxillofacial without contrast (CPT[®] 70486) <p>OR</p> <ul style="list-style-type: none"> ◦ CT Temporal Bone without contrast (CPT[®] 70480)

- Additional Cisternogram (CPT[®] 78630) indications:
 - Known hydrocephalus with worsening symptoms (for example headache)
 - Suspected obstructive hydrocephalus
- Individuals with a Shunt (see **Hydrocephalus Shunts (HD-11.14)**)

Background and Supporting Information

- Common radiological findings of CSF leaks include: abnormalities of the cribriform plate or ethmoid sinus, dural dehiscence at the anterior skull base, pneumatization of the sphenoid sinus, and fluid within the middle ear.
- CSF leaks may occur in:
 - CSF shunt overdrainage
 - Traumatic CSF leaks
 - Thecal holes and rents from lumbar punctures and epidural catheterizations
 - Spinal and cranial surgeries including skull base and some sinus surgeries
 - Proximal brachial plexus and nerve root avulsion injuries
 - Spontaneous leaks may occur in, but not exclusive to:
 - Pre-existing weakness of the dural sac including:
 - Disorders of connective tissue matrix including Marfan syndrome, Marfanoid features
 - Joint hypermobility
 - Trivial trauma in the setting of preexisting dural weakness
 - Spondylotic spurs, herniated discs

Cervicogenic Headaches Including Occipital Neuritis/Neuralgia (HD-11.16)

HD.HA.0011.16A

v3.0.2024

- Brain imaging should follow applicable sections in **Headache (HD-11)**
- MRI Cervical Spine without contrast (CPT[®] 72141) or CT Cervical Spine without contrast (CPT[®] 72125)
 - Failure of recent (within 3 months) 6-week trial of provider-directed treatment (unless presence of a red flag) as defined in **Red Flag Indications (SP-1.2)**, and clinical re-evaluation after treatment period.
 - See **Neck (Cervical Spine) Pain Without/With Neurological Features (Including Stenosis) (SP-3.1)** and **Neck (Cervical Spine) Trauma (SP-3.2)** in the Spine Imaging Guidelines
 - Exemptions to the 6 weeks of conservative care include:
 - High risk mechanism of cervical spine injury within the last 3 months (see **Neck (Cervical Spine) Trauma (SP-3.2)** in the Spine Imaging Guidelines in the Spine Imaging Guidelines)
 - **Red Flag Indications (SP-1.2)** in the Spine Imaging Guidelines
 - **ANY of the following:**
 - Bony abnormalities: Atlanto-axial dislocations/instability (including but not limited to: Down's syndrome, Ehlers-Danlos and Marfan syndromes and rheumatoid arthritis), platybasia, osteomas, callous formation of the posterior C1/2 arches
 - Posterior fossa lesions, Chiari malformations, demyelinating disease
 - Myelopathy/myelitis (see **Myelopathy (SP-7.1)** in the Spine Imaging Guidelines)

Background and Supporting Information

- Cervicogenic Headache
 - Headache caused by a disorder of the cervical spine, usually accompanied by neck pain or other signs and symptoms of cervical disease. Typical findings include reduced cervical range of motion, side-locked pain, and symptoms exacerbated by provocative maneuvers such as head movement or digital pressure.
- Occipital Neuralgia/Neuritis - Occipital neuralgia is classified unilateral or bilateral paroxysmal, shooting or stabbing pain in the posterior part of the scalp, in the distribution(s) of the greater, lesser and/or third occipital nerves, sometimes

accompanied by diminished sensation or dysaesthesia in the affected area and commonly associated with tenderness over the involved nerve(s).

- Pain has at least two of the following three characteristics:
 - Recurring in paroxysmal attacks lasting from a few seconds to minutes
 - Severe in intensity
 - Shooting, stabbing or sharp in quality
- Pain is associated with both of the following:
 - Dysaesthesia and/or allodynia apparent during innocuous stimulation of the scalp and/or hair
 - Either or both of the following:
 - Tenderness over the affected nerve branches
 - Trigger points at the emergence of the greater occipital nerve or in the distribution of C2
- Pain is eased temporarily by local anaesthetic block of the affected nerve(s)

Advanced Imaging Indications Related To Migraines (HD-11.17)

HD.HA.0011.17A

v3.0.2024

- Advanced imaging of the head is NOT indicated for newly diagnosed migraine with a normal neurological exam or chronic stable migraine with no neurological deficit and/ or no red flags (see **Headaches with Red Flags (HD-11.2)**).
 - See below for advanced imaging indications related to migraines.
- MRI Brain without (CPT[®] 70551) preferred or MRI Brain with and without (CPT[®] 70553) or CT Head without (CPT[®] 70450) for the following:
 - New migraine with age ≥50 (see **New Headache Onset Older than Age 50 (HD-11.7)**)
 - Change in frequency or severity of migraine (See **Headaches with Red Flags (HD-11.2)**)
 - Unusual, prolonged or persistent aura (greater than 60 minutes) (See **Background and Supporting Information**)
 - Worst migraine
 - Hemiplegic migraine
 - Migraine with any motor weakness.
 - Migrainous accompaniments
 - Passing neurological symptoms that can affect vision, speech, movement, and behavior-“mimic stroke”
 - Migraine aura without headache
 - Migraine with an aura in which the aura is neither accompanied nor followed by a headache within 60 minutes.
 - Side-locked migraine (unilateral)
 - Unilateral hemicranial pain – includes primary and secondary causes.
 - New daily persistent headache (new daily headache present greater than three months)
 - Trigeminal autonomic cephalgias includes cluster headache short-lasting, unilateral, neuralgiform headache attacks with conjunctival injection and tearing (SUNCT) syndromes; short-lasting unilateral neuralgiform headache attacks with cranial autonomic symptoms (SUNA) and hemicrania paroxysmal and continua are covered in **Trigeminal Autonomic Cephalgias (HD-11.4)**
 - Post-traumatic migraine
 - See **Head Trauma (HD-13.1)** and **Headaches Associated with Head Trauma (HD-11.12)**

Background and Supporting Information

- Aura symptoms may accompany or precede a headache within 60 minutes and may include, but are not exclusive to, the following symptoms:²⁸
 - Visual (flashing lights, loss of vision)
 - Sensory (paresthesia)
 - Speech and/or language (difficulty speaking)
 - Motor (any weakness)
 - Brainstem (dizziness, double vision) and retinal (visual complaints)

References (HD-11)

v3.0.2024

1. Expert Panel on Neurologic Imaging, Pallavi S, Utukuri MD, et al. ACR Appropriateness Criteria® Headache. Available at <https://acsearch.acr.org/docs/69482/Narrative/> American College of Radiology. 2022.
2. Headache Classification Committee of the International Headache Society (IHS) The International Classification of Headache Disorders, 3rd edition. Cephalalgia. 2018;38(1):1-211
3. Thurtell MJ. Idiopathic Intracranial Hypertension. CONTINUUM: Lifelong Learning in Neurology. 2019;25(5):1289-1309. doi:10.1212/con.0000000000000770
4. Burch R. Headache in Pregnancy and the Puerperium. Neurologic Clinics. 2019;37(1):31-51. doi:10.1016/j.ncl.2018.09.004
5. Jamieson DG, Mcvige JW. Imaging of Neurologic Disorders in Pregnancy. Neurologic Clinics. 2020;38(1):37-64. doi:10.1016/j.ncl.2019.09.001
6. Rayhill M. Headache in Pregnancy and Lactation. *Continuum (Minneapolis)*. 2022; 28(1): 72-92. doi: 10.1212/CON.0000000000001070
7. Kamel H, Navi BB, Sriram N, Hovsepian DA, Devereux RB, Elkind MS. Risk of a Thrombotic Event after the 6-Week Postpartum Period. *New England Journal of Medicine*. 2014;370(14):1307-1315. doi:10.1056/nejmoa1311485
8. Perillo T, Paoletta C, Perrotta G, Serino A, Caranci F, Manto A. Reversible cerebral vasoconstriction syndrome: review of neuroimaging findings. *Radiol Med*. 2022; 127(9): 981-990. doi: 10.1007/s11547-022-01532-2
9. ACR-ASNR-SPR Practice Parameter for the Performance of Computed Tomography (CT) of the Extracranial Head and Neck Revised 2021. (Resolution 5). <https://www.acr.org/-/media/ACR/Files/Practice-Parameters/CT-Head-Neck>
10. Dobrocky T, Nicholson P, Häni L, et al. Spontaneous intracranial hypotension: searching for the CSF leak. *Lancet Neurol*. 2022; 21(4): 369-380. doi: 10.1016/S1474-4422(21)00423-3.
11. Expert Panel on Neurologic Imaging, Salmela MB, Mortazavi S, et al. ACR Appropriateness Criteria® Cerebrovascular Disease. *J Am Coll Radiol*. 2017;14(5S):S34-S61. doi:10.1016/j.jacr.2017.01.051
12. Pruitt AA. Central Nervous System Infections Complicating Immunosuppression and Transplantation. CONTINUUM: Lifelong Learning in Neurology. 2018;24(5):1370-1396. doi:10.1212/con.0000000000000653
13. Evans, RW, Burch RC, Frishberg BM, et al. Neuroimaging for Migraine: The American Headache Society Systematic Review and Evidence-Based Guideline. *Headache: The Journal of Head and Face Pain*. 2020;60(2):318-336. doi:10.1111/head.13720
14. Expert Panel on Neurological Imaging, Shih RY, Burns J, et al. ACR Appropriateness Criteria® Head Trauma: 2021 Update. *J Am Coll Radiol*. 2021;18(5S):S13-S36. doi:10.1016/j.jacr.2021.01.006
15. ACR ASNR SPR Practice Parameter for the Performance of Myelography and Cisternography. Revised 2019
16. Jordan JE, Flanders AE. Headache and Neuroimaging: Why We Continue to Do It. *AJNR Am J Neuroradiol*. 2020; 41(7): 1149-1155. doi: 10.3174/ajnr.A6591
17. Sweet JA, Mitchell LS, Narouze S, et al. Occipital Nerve Stimulation for the Treatment of Patients With Medically Refractory Occipital Neuralgia. *Neurosurgery*. 2015;77(3):332-341. doi:10.1227/neu.0000000000000872
18. <https://ichd-3.org/13-painful-cranial-neuropathies-and-other-facial-pains/13-4-occipital-neuralgia/>
19. <https://ichd-3.org/11-headache-or-facial-pain-attributed-to-disorder-of-the-cranium-neck-eyes-ears-nose-sinuses-teeth-mouth-or-other-facial-or-cervical-structure/11-2-headache-attributed-to-disorder-of-the-neck/11-2-1-cervicogenic-headache/>
20. Doddamani RS, Meena RK, Sawarkar D, Aggarwal D, Chandra PS. Management Options in Occipital Neuralgia: A. *Journal of Peripheral Nerve Surgery Vol*. 2020;4(1)
21. O'Neill F, Nurmikko T, Sommer C. Other facial neuralgias. *Cephalalgia*. 2017;37(7):658-669. doi:10.1177/0333102417689995
22. Barmherzig R, Kingston W. Occipital Neuralgia and Cervicogenic Headache: Diagnosis and Management. *Current Neurology and Neuroscience Reports*. 2019;19(5). doi:10.1007/s11910-019-0937-8
23. Labastida-Ramírez A, Benemei S, Albanese M, et al. Persistent post-traumatic headache: a migrainous loop or not? The clinical evidence. *The Journal of Headache and Pain*. 2020;21(1). doi:10.1186/s10194-020-01122-5

24. Henderson FC, Austin C, Benzel E, et al. Neurological and spinal manifestations of the Ehlers-Danlos syndromes. *American journal of medical genetics Part C, Seminars in medical genetics*. 2017;175(1):195-211. doi:10.1002/ajmg.c.31549
25. Chou DE. Secondary Headache Syndromes. *CONTINUUM: Lifelong Learning in Neurology*. 2018;24(4):1179-1191. doi:10.1212/con.0000000000000640
26. Smith JH. Other Primary Headache Disorder. *Continuum (Minneap Minn)*. 2021; 27(3): 652-664. doi: 10.1212/CON.0000000000000960
27. Nahas SJ. Cluster Headache and Other Trigeminal Autonomic Cephalalgias. *Continuum (Minneap Minn)*. 2021; 27(3): 633-651. doi: 10.1212/CON.0000000000000965
28. Recober A. Pathophysiology of Migraine. *Continuum (Minneap Minn)*. 2021; 27(3): 586-596. doi: 10.1212/COM.0000000000000983

Aneurysm and AVM (HD-12)

Guideline

Intracranial Aneurysms (HD-12.1)

Arteriovenous Malformations (AVMs) and Related Lesions (HD-12.2)

References (HD-12)

Intracranial Aneurysms (HD-12.1)

HD.AN.0012.1.A

v3.0.2024

- CTA Head (CPT[®] 70496) or MRA Head (CPT[®] 70544, CPT[®] 70545, or CPT[®] 70546) in ANY of the following clinical scenarios:
 - Symptoms or signs of cerebral aneurysm, including:
 - "Thunderclap headache" (see **Sudden Onset of Headache (HD-11.3)**)
 - Third nerve palsy with pupillary involvement (pupil-sparing third nerve palsies are not caused by external compression)
 - Suspicion of aneurysm bleed [CT Head or MRI Brain or CSF exam showing evidence of subarachnoid hemorrhage (SAH) or intracerebral hemorrhage]
 - Abnormal CT Head or MRI Brain suggesting possible aneurysm
 - Screening for High Risk Populations as defined by the following criteria (screening usually begins at age 20 unless unusual circumstances as aneurysms are uncommon in children and adolescents):
 - Positive Family History: Two or more first degree relatives (parent, sibling, or child) with history of cerebral aneurysm or SAH: screening every 5 years beginning at age 20
 - One first degree relative (parent, sibling, or child) with history of cerebral aneurysm or SAH can have one screening study but risks and benefits should be discussed with individual
 - Autosomal dominant polycystic kidney disease (screening begins at age 20 to 65 and is repeated at ten-year intervals)
 - Coarctation of the aorta or bicuspid aortic valve
 - Neurofibromatosis Type 1
 - Type 4 (Vascular) Ehlers-Danlos Syndrome
 - Marfan Syndrome
 - Loews-Dietz Syndrome
 - Microcephalic osteodysplastic primordial dwarfism
 - Presence of an azygos anterior cerebral artery
 - Diagnosis of fibromuscular dysplasia (one screening study after confirmed diagnosis)
 - Pseudoxanthoma elasticum
 - Hereditary hemorrhagic telangiectasia (Osler-Weber-Rendu Syndrome)
 - Alpha-1-antitrypsin deficiency
 - Pheochromocytoma
 - Klinefelter syndrome
 - Tuberous sclerosis

- Noonan syndrome
- Alpha-glucosidase deficiency
- Klippel-Trenaunay-Weber Syndrome
- Kawasaki disease
- Glucocorticoid-remediable aldosteronism (GRA)²⁵
- CTA Head (CPT® 70496) to confirm questionable or equivocal findings on an initial MRA Head
- For suspected or confirmed cerebral aneurysm, ruptured or unruptured, for initial evaluation, treatment, intervention or follow up, 3D rendering (CPT® 76377 or CPT® 76376) with cervicocerebral angiography/arteriography and/or cerebral angiography²² (See **General Guidelines - Other Imaging Situations (HD-1.7)**)
- Follow up of known cerebral aneurysm:
 - The optimal interval and duration for radiologic follow-up has not been determined. Radiographic follow-up with MRA Head (CPT® 70544, CPT® 70545, or CPT® 70546) or CTA (CPT® 70496) for unruptured or treated intracranial aneurysm upon request by the neurosurgeon or team managing the intracranial aneurysm.²²
- MRI Brain without contrast (CPT® 70551) or with and without (CPT® 70553) in the following scenarios:
 - If there are new signs, symptoms or clinical findings
 - To evaluate and treat a giant aneurysm (>2.5 cm)
 - Posterior fossa aneurysms
 - Thrombosed or partially thrombosed aneurysms
 - To evaluate the relationship of the aneurysm to the dura
 - To evaluate for the presence of calcification
 - Other surveillance criteria as per the neurosurgeon or team managing the aneurysm repair
- Head imaging (CT Head or MRI Brain contrast as requested) to assess for subacute complications, (i.e. vasospasm, delayed cerebral ischemia and hydrocephalus), beginning days to weeks arising from a subarachnoid hemorrhage and aneurysm treatment upon request from the neurosurgeon and team managing the episode.
- MRI Spinal (Cervical, Thoracic, Lumbar (without and with contrast) [CPT® 72156, CPT® 72157, CPT® 72158]) is indicated to evaluate individuals with SAH and negative studies for brain aneurysm in whom spinal abnormalities (i.e. AVM) may be suspected as the cause of hemorrhage.
- MRA Neck (CPT® 70547, CPT® 70548, or CPT® 70549) or CTA Neck (CPT® 70498) are not supported for screening and for follow-up on surgically treated cerebral aneurysms, except if they are located in the vertebral-basilar system.
- Initial catheter arteriography can be negative in 10%-20% of cases of subarachnoid hemorrhage (SAH). CTA Head (CPT® 70496) and/or MRA Head (CPT® 70544, CPT®

70545, or CPT[®] 70546) if these had not been initially performed. If initial catheter angiography is negative, repeat imaging is indicated.²²

- If an intracranial etiology for SAH has not been found, CTA (CPT[®] 70498) or MRA Neck (CPT[®] 70547, CPT[®] 70548, or CPT[®] 70549) to evaluate for less common causes of SAH.
- High risk scenarios for vascular dissection include, but are not limited to: Fibromuscular dysplasia (FMD), Marfan Disease, MVA with whiplash, and chiropractic manipulation
 - MRA Neck (CPT[®] 70547, CPT[®] 70548, or CPT[®] 70549) or CTA Neck (CPT[®] 70498) if arterial dissection is suspected, or known and re-evaluation is needed (as directed by neurologist or neurosurgeon or any provider in consultation with a neurologist or neurosurgeon)
 - MRA Head (CPT[®] 70544, CPT[®] 70545, or CPT[®] 70546) or CTA Head (CPT[®] 70496, CPT[®] 70498) if arterial dissection is suspected, or known and re-evaluation is needed (as directed by neurologist or neurosurgeon or any provider in consultation with a neurologist or neurosurgeon)
- Other vascular imaging indications for headaches require additional information. See **Stroke/TIA (HD-21.1)**, **Sudden Onset of Headache (HD-11.3)**, **New Headache Onset Older than Age 50 (HD-11.7)**, **Abnormal Blood Clotting (HD-11.9)**, **Pregnancy (HD-11.10)**, **Physical Exertion (HD-11.11)**, and **Systemic Infections (HD-11.13)**

Arteriovenous Malformations (AVMs) and Related Lesions (HD-12.2)

HD.AN.0012.2.A

v3.0.2024

Disorders and Indications (Any of the following)	Supported Imaging
<p>Any aneurysmal and/or AVM disorders listed in this guideline</p> <ul style="list-style-type: none"> • When MRI contraindicated²⁹ • Any emergency setting 	<ul style="list-style-type: none"> • CT head without contrast (CPT[®] 70450) <p>AND/OR</p> <ul style="list-style-type: none"> • CTA head (CPT[®] 70496) <p>AND/OR</p> <ul style="list-style-type: none"> • CTA Neck (CPT[®] 70498)
<p>Known AVM</p> <ul style="list-style-type: none"> • When requested by a neurologist, neurosurgeon or any provider in consultation with a neurologist or neurosurgeon 	<ul style="list-style-type: none"> • MRI Brain without contrast (CPT[®] 70551) <p>OR</p> <ul style="list-style-type: none"> • MRI Brain without and with contrast (CPT[®] 70553) <p>AND/OR</p> <ul style="list-style-type: none"> • MRA Head (CPT[®] 70544, CPT[®]70545, CPT[®] 70546) <p>OR</p> <ul style="list-style-type: none"> • CTA Head (CPT[®] 70496)
<p>Known AVM in the vertebral-basilar system²²</p> <ul style="list-style-type: none"> • When requested by a neurologist, neurosurgeon or any provider in consultation with a neurologist or neurosurgeon 	<ul style="list-style-type: none"> • Imaging as listed above in “known AVM” <p>AND/OR</p> <ul style="list-style-type: none"> • MRA Neck (CPT[®] 70547, CPT[®] 70548, OR CPT[®] 70549) <p>OR</p> <ul style="list-style-type: none"> • CTA Neck (CPT[®] 70498)

Disorders and Indications (Any of the following)	Supported Imaging
<p>Subarachnoid Hemorrhage (SAH)</p> <ul style="list-style-type: none"> • AVM is suspected based on a history of SAH 	<ul style="list-style-type: none"> • MRI Brain without and with contrast (CPT[®] 70553) <p>OR</p> <ul style="list-style-type: none"> • MRI Brain without contrast (CPT[®] 70551)
<p>Hereditary Hemorrhagic Telangiectasia (HHT; Osler-Weber-Rendu Syndrome)</p> <ul style="list-style-type: none"> • Suspected based on family history with at least one affected first-degree relative (biological parent or sibling) • At diagnosis, especially if confirmed by genetic testing • Screening for confirmed HHT • Clinical signs or symptoms concerning for disease progression • When requested by a neurologist, neurosurgeon, geneticist, or any provider in consultation with a neurologist, neurosurgeon or geneticist 	<ul style="list-style-type: none"> • MRI Brain without and with contrast (CPT[®] 70553) <p>OR</p> <ul style="list-style-type: none"> • MRI Brain without contrast (CPT[®] 70551) <p>AND/OR</p> <ul style="list-style-type: none"> • MRA Head (CPT[®] 70544, CPT[®] 70545, CPT[®] 70546) <p>OR</p> <ul style="list-style-type: none"> • CTA Head (CPT[®] 70496)

Disorders and Indications (Any of the following)	Supported Imaging
<p>Capillary Malformation-Arteriovenous Malformation (CM-AVM)</p> <ul style="list-style-type: none"> • Suspected based on family history with at least one affected first-degree relative (biological parent or sibling) • At diagnosis, especially if confirmed by genetic testing • Screening for confirmed CM-AVM • Clinical signs or symptoms concerning for disease progression • When requested by a neurologist, neurosurgeon, geneticist, or any provider in consultation with a neurologist, neurosurgeon or geneticist 	<ul style="list-style-type: none"> • MRI Brain without and with contrast (CPT[®] 70553) <p>OR</p> <ul style="list-style-type: none"> • MRI Brain without contrast (CPT[®] 70551) <p>AND/OR</p> <ul style="list-style-type: none"> • MRA Head (CPT[®] 70544, CPT[®] 70545, CPT[®] 70546) <p>OR</p> <ul style="list-style-type: none"> • CTA Head (CPT[®] 70496) <p>AND/OR</p> <ul style="list-style-type: none"> • MRI Cervical Spine without and with contrast (CPT[®] 72156) <p>OR</p> <ul style="list-style-type: none"> • MRI Cervical Spine without contrast (CPT[®] 72141) <p>AND/OR</p> <ul style="list-style-type: none"> • MRI Thoracic Spine without and with contrast (CPT[®] 72157) <p>OR</p> <ul style="list-style-type: none"> • MRI Thoracic Spine without contrast (CPT[®] 72146)³¹

Disorders and Indications (Any of the following)	Supported Imaging
<p>Cerebral Cavernous Malformations (CCM)</p> <ul style="list-style-type: none"> • At diagnosis, especially if confirmed by genetic testing • Screening for confirmed CCM • Clinical signs or symptoms concerning for disease progression • When requested by a neurologist, neurosurgeon, geneticist, or any provider in consultation with a neurologist, neurosurgeon or geneticist 	<ul style="list-style-type: none"> • MRI Brain without and with contrast (CPT[®] 70553) <p>OR</p> <ul style="list-style-type: none"> • MRI Brain without contrast (CPT[®] 70551) <p>AND/OR</p> <ul style="list-style-type: none"> • MRA Head (CPT[®] 70544, CPT[®] 70545, CPT[®] 70546) <p>OR</p> <ul style="list-style-type: none"> • CTA Head (CPT[®] 70496) <p>AND/OR</p> <ul style="list-style-type: none"> • MRI Cervical Spine without and with contrast (CPT[®] 72156) <p>OR</p> <ul style="list-style-type: none"> • MRI Cervical Spine without contrast (CPT[®] 72141) <p>AND/OR</p> <p>MRI Thoracic Spine without and with contrast (CPT[®] 72157)</p> <p>OR</p> <ul style="list-style-type: none"> • MRI Thoracic Spine without contrast (CPT[®] 72146)

Disorders and Indications (Any of the following)	Supported Imaging
<p>Microcephalic Osteodysplastic Primordial Dwarfism, Type II (MOPD II)¹⁹</p> <ul style="list-style-type: none"> • At diagnosis, especially if confirmed by genetic testing • Screening for confirmed MOPD II, repeated annually • Clinical signs or symptoms concerning for disease progression • When requested by a neurologist, neurosurgeon, geneticist, or any provider in consultation with a neurologist, neurosurgeon or geneticist 	<ul style="list-style-type: none"> • MRI Brain without contrast (CPT[®] 70551) <p>OR</p> <ul style="list-style-type: none"> • MRI Brain without and with contrast (CPT[®] 70553) <p>AND/OR</p> <ul style="list-style-type: none"> • MRA Head (CPT[®] 70544, CPT[®] 70545, CPT[®] 70546) <p>OR</p> <ul style="list-style-type: none"> • CTA Head (CPT[®] 70496) <p>AND/OR</p> <ul style="list-style-type: none"> • MRA Neck (CPT[®] 70547, CPT[®] 70548, OR CPT[®] 70549) <p>OR</p> <ul style="list-style-type: none"> • CTA Neck (CPT[®] 70498)
<p>Sturge-Weber Syndrome</p> <ul style="list-style-type: none"> • At diagnosis • Clinical signs or symptoms concerning for disease progression • When requested by a neurologist or neurosurgeon or any provider in consultation with a neurologist or neurosurgeon 	<ul style="list-style-type: none"> • MRI Brain without contrast (CPT[®] 70551) <p>OR</p> <ul style="list-style-type: none"> • MRI Brain without and with contrast (CPT[®] 70553) <p>AND/OR</p> <ul style="list-style-type: none"> • MRI Orbits/Face/Neck without and with contrast (CPT[®] 70543) <p>OR</p> <ul style="list-style-type: none"> • MRI Orbits/Face/Neck without contrast (CPT[®] 70540)

- MRI Brain without and with contrast (CPT[®] 70553) **OR** MRI Brain without contrast (CPT[®] 70551), **OR** CT head without contrast (CPT[®] 70450) **AND/OR** MRA Head (CPT[®] 70544, CPT[®] 70545, or CPT[®] 70546) or CTA Head (CPT[®] 70496) supported for symptoms including headache, seizure, and/or focal neurologic deficits^{11,20,26}

- For concerns related to stroke, see **Stroke/TIA HD-21.1**
- 3D imaging (CPT[®] 76376 or CPT[®] 76377) with MRI Brain without and with contrast (CPT[®] 70553) OR MRI Brain without contrast (CPT[®] 70551) is supported
- 3D Rendering (CPT[®] 76377 or CPT[®] 76376) with cerebral angiography to define the presence, location, and anatomy of intracranial and cervical vascular malformations at diagnosis and for follow up, including post-treatment.^{11,26}
- See **General Guidelines - Other Imaging Situations (HD-1.7)** and **Background and Supporting Information**
- See **General Guidelines – CT and MR Angiography (CTA and MRA) (HD-1.5)**
- Functional MRI (CPT[®] 70554 OR CPT[®] 70555) for surgical planning, see **Functional MRI (fMRI) (HD-24.2)**¹¹

Background and Supporting Information

- Trauma is the most common reason for subarachnoid hemorrhage. Ruptured berry aneurysm is the most common reason for non-traumatic subarachnoid hemorrhage in adults
- Small aneurysms are present in about 1% to 2% of adults, but very few ever reach a size for which bleeding is a risk (>5 mm). Small (<3 to 4 mm) unruptured aneurysms in those with no personal history of SAH have a 0.1% to 0.5% a year rate of bleeding. The risk of cerebral aneurysm with family history ranges from 2% with one first degree relative to 30% to 35% for identical twin or two parents. The risks and benefits of screening these populations need to be considered before advanced imaging.
- AVMs most often come to clinical notice either by bleeding or by acting as a seizure focus. They are usually congenital, recognized later in life and have an initial risk of bleeding of 2% per year.
- Cerebral angiography is a form of angiography which provides images of blood vessels in and around the brain and/or neck. This is a catheter based procedure, using x-ray imaging guidance and iodine-based contrast to visualize blood vessels.
- Most intracranial AVMs are congenital, vary widely in their location and type, and are discovered at birth due to associated clinical findings or incidentally later in life. Certain hereditary conditions are associated with an increased risk for AVM development.
- Vascular malformations include arteriovenous, venous, cavernous, and capillary malformations.
- Hereditary AVMs usually have an autosomal dominant pattern of inheritance.^{10,19,31,33}

References (HD-12)

HD.AN.0012.3.A

v3.0.2024

1. Rozenfeld MN, Ansari SA, Shaibani A, Russell EJ, Mohan P, Hurley MC. Should Patients with Autosomal Dominant Polycystic Kidney Disease Be Screened for Cerebral Aneurysms? *American Journal of Neuroradiology*. 2013;35(1):3-9. doi:10.3174/ajnr.a3437
2. Vlak MHM, Rinkel GJE, Greebe P, Greving JP, Algra A. Lifetime risks for aneurysmal subarachnoid haemorrhage: multivariable risk stratification. *Journal of Neurology, Neurosurgery & Psychiatry*. 2013;84(6):619-623. doi:10.1136/jnnp-2012-303783
3. Nguyen TN. Management of Unruptured Intracranial Aneurysms and Brain Arteriovenous Malformations. *Continuum (Minneapolis)*. 2023;29(2):584-604. doi:10.1212/CON.0000000000001247
4. Thompson BG, Brown RD, Amin-Hanjani S, et al. Guidelines for the Management of Patients With Unruptured Intracranial Aneurysms. *Stroke*. 2015;46(8):2368-2400. doi:10.1161/str.000000000000070
5. Chu LC, Johnson PT, Dietz HC, Fishman EK. CT Angiographic Evaluation of Genetic Vascular Disease: Role in Detection, Staging, and Management of Complex Vascular Pathologic Conditions. *American Journal of Roentgenology*. 2014;202(5):1120-1129. doi:10.2214/ajr.13.11485
6. Hishikawa T, Date I, Tokunaga K, et al. Risk of rupture of unruptured cerebral aneurysms in elderly patients. *Neurology*. 2015;85(21):1879-1885. doi:10.1212/wnl.0000000000002149
7. Backes, D, Rinkel GJE, Greving JP, et al. ELAPSS score for prediction of risk of growth of unruptured intracranial aneurysms. *Neurology*. 2017;88(17):1600-1606. doi:10.1212/wnl.0000000000003865
8. Ding D, Etminan N. A model for predicting the growth of unruptured intracranial aneurysms. *Neurology*. 2017;88(17):1594-1595. doi:10.1212/wl.0000000000003874
9. Kadian-Dodov D, Gornik HL, Gu X, et al. Dissection and Aneurysm in Patients With Fibromuscular Dysplasia. *Journal of the American College of Cardiology*. 2016;68(2):176-185. doi:10.1016/j.jacc.2016.04.044
10. McDonald J, Stevenson DA. Hereditary Hemorrhagic Telangiectasia. In: Adam MP, Mirzaa GM, Pagon RA, et al., eds. *GeneReviews*®. Seattle (WA): University of Washington, Seattle; June 26, 2000. [Updated 2021 Nov 24]
11. Derdeyn CP, Zipfel GJ, Albuquerque FC, et al. Management of Brain Arteriovenous Malformations: A Scientific Statement for Healthcare Professionals From the American Heart Association/American Stroke Association. *Stroke*. 2017;48(8). doi:10.1161/str.000000000000134.
12. Expert Panel on Neurologic Imaging: Salmela MB, Mortazavi S, et al. ACR Appropriateness Criteria® Cerebrovascular Disease. *J Am Coll Radiol*. 2017;14(5S):S34-S61. doi:10.1016/j.jacr.2017.01.051
13. Rosser T. Neurocutaneous Disorders. CONTINUUM: Lifelong Learning in Neurology. 2018;24(1):96-129. doi:10.1212/con.0000000000000562
14. Horne MA, Flemming KD, Su I-C, et al. Clinical course of untreated cerebral cavernous malformations: a meta-analysis of individual patient data. *The Lancet Neurology*. 2016;15(2):166-173. doi:10.1016/s1474-4422(15)00303-8
15. Vella M, Alexander M, Mabray M, et al. Comparison of MRI, MRA, and DSA for Detection of Cerebral Arteriovenous Malformations in Hereditary Hemorrhagic Telangiectasia. *American Journal of Neuroradiology*. 2020;41(6):969-975. doi:10.3174/ajnr.a6549
16. Lawton MT and Vates GE. Subarachnoid Hemorrhage. *N Engl J Med* 2017;377:257-66. doi: 10.1056/NEJMcp1605827
17. Connolly ES, Rabinstein AA, Carhuapoma JR, et al. Guidelines for the Management of Aneurysmal Subarachnoid Hemorrhage. *Stroke*. 2012;43(6):1711-1737. doi:10.1161/str.0b013e3182587839
18. Meschia JF, Bushnell C, Boden-Albala B, et al. Guidelines for the Primary Prevention of Stroke. *Stroke*. 2014;45(12):3754-3832. doi:10.1161/str.0000000000000046
19. Michael B. Bober and Andrew P. Jackson, Microcephalic Osteodysplastic Primordial Dwarfism Type II: A clinical review Current Osteoporosis Report (2017) 15:61-69 doi: 10.1007/s11914-017-0348-1
20. Chen, C-J et al. Brain arteriovenous malformations: A review of natural history, pathobiology, and interventions *Neurology* 2020 95(20):917-927. doi: 10.1212/WNL.0000000000010968

21. ACR-ASNR-SIR-SNIS Practice Parameter for the Performance of Diagnostic Cervicocerebral Catheter Angiography in Adults. Revised 2016. (Resolution 13) <https://www.acr.org/-/media/ACR/Files/Practice-Parameters/CervicoCerebralCathAngio.pdf>
22. Expert Panel on Neurological Imaging, Ledbetter LN, Burns J, et al. ACR Appropriateness Criteria® Cerebrovascular Diseases-Aneurysm, Vascular Malformation, and Subarachnoid Hemorrhage. *J Am Coll Radiol.* 2021;18(11S):S283-S304. doi:10.1016/j.jacr.2021.08.012
23. Nesvick CL, Oushy S, Ravindran K, et al. Repeat Catheter Angiography in Patients with Aneurysmal-Pattern Angiographically Negative Subarachnoid Hemorrhage. *Neurocritical Care.* Published online June 28, 2021. doi:10.1007/s12028-021-01247-8
24. Rosenberg TL, Suen JY, Richter GT. Arteriovenous Malformations of the Head and Neck. *Otolaryngologic Clinics of North America.* 2018;51(1):185-195. doi:10.1016/j.otc.2017.09.005
25. Litchfield WR, Anderson BF, Weiss RJ, Lifton RP, Dluhy RG. Intracranial aneurysm and hemorrhagic stroke in glucocorticoid-remediable aldosteronism. *Hypertension.* 1998;31(1 Pt 2):445-450. doi:10.1161/01.hyp.31.1.445
26. Johnson MD, Staarmann B, Zuccarello M. A Rational Approach to the Management of Cerebral Arteriovenous Malformations. *World Neurosurg.* 2022;159:338-347. doi:10.1016/j.wneu.2021.08.045
27. Hoh BL, Ko NU, Amin-Hanjani S, et al. 2023 Guideline for the Management of Patients With Aneurysmal Subarachnoid Hemorrhage: A Guideline From the American Heart Association/American Stroke Association [published online ahead of print, 2023 May 22]. *Stroke.* 2023;10.1161/STR.0000000000000436. doi:10.1161/STR.0000000000000436
28. Faughnan ME, Mager JJ, Hetts SW, et al. Second International Guidelines for the Diagnosis and Management of Hereditary Hemorrhagic Telangiectasia. *Ann Intern Med.* 2020;173(12):989-1001. doi:10.7326/M20-1443
29. Expert Panel on MR Safety, Kanal E, Barkovich AJ, et al. ACR guidance document on MR safe practices: 2013. *J Magn Reson Imaging.* 2013;37(3):501-530. doi:10.1002/jmri.24011
30. Sabeti S, Ball KL, Bhattacharya SK, et al. Consensus Statement for the Management and Treatment of Sturge-Weber Syndrome: Neurology, Neuroimaging, and Ophthalmology Recommendations. *Pediatr Neurol.* 2021;121:59-66. doi:10.1016/j.pediatrneurol.2021.04.013
31. Bayrak-Toydemir P, Stevenson DA. Capillary Malformation-Arteriovenous Malformation Syndrome. In: Adam MP, Mirzaa GM, Pagon RA, et al., eds. *GeneReviews®.* Seattle (WA): University of Washington, Seattle; February 22, 2011. Updated: September 12, 2019.
32. Hammill AM, Wusik K, Kasthuri RS. Hereditary hemorrhagic telangiectasia (HHT): a practical guide to management. *Hematology Am Soc Hematol Educ Program.* 2021;2021(1):469-477. doi:10.1182/hematology.2021000281
33. Morrison L, Akers A. Cerebral Cavernous Malformation, Familial. In: Adam MP, Mirzaa GM, Pagon RA, et al., eds. *GeneReviews®.* Seattle (WA): University of Washington, Seattle; February 24, 2003.

Head and Facial Trauma (HD-13)

Guideline

Head Trauma (HD-13.1)

Facial Trauma (HD-13.2)

References (HD-13)

Head Trauma (HD-13.1)

HD.TR.0013.1.A

v3.0.2024

For acute head trauma (0 to 7 days post-trauma)⁷

- CT Head without contrast (CPT[®] 70450) is preferred in individuals with **ANY** of the following modified Canadian CT Head Rule/New Orleans Criteria.^{1,7,9}
 - Regardless of documented or stated head impact, ANY "dangerous mechanism of injury", either direct or indirect, including, but not exclusive to:
 - Fall from height greater than 3 feet
 - Fall greater than 5 steps down stairs
 - Any pedestrian motor vehicle accident
 - High impact motor vehicle accident
 - Individual >60 years old
 - Loss of consciousness, amnesia, or disorientation accompanying blunt head trauma within 24 hours
 - Taking one anticoagulant or two antiaggregants, (e.g., aspirin and Plavix)
 - Known platelet or clotting disorder
 - Glasgow coma scale (GCS) score of less than 15 at 2 hours following injury
 - >30 minutes of amnesia before impact
 - Suspected open skull fracture
 - Signs of basilar skull fracture (Battle's sign, Raccoon eyes, CSF rhinorrhea, cranial nerve palsy, hemotympanum, acute hearing loss)
 - Vomiting
 - Alcohol or drug intoxication
 - Visible trauma above clavicles
 - Deficits in short term memory, altered level of alertness, abnormal behavior or focal neurological deficit
 - Seizure
 - Headache [See **Headache Associated with Head Trauma (HD-11.12)**]

For subacute head trauma (7 days to 3 months post-trauma)⁷ and chronic head trauma (greater than 3 months post-trauma) symptoms⁷

- MRI Brain without contrast (CPT[®] 70551) or CT Head without contrast (CPT[®] 70450) is indicated for the initial imaging of individuals with subacute or chronic head trauma and unexplained cognitive or neurologic deficits.⁷
- MRI Brain without and with contrast (CPT[®] 70553) if post-traumatic infection is suspected

Repeat and follow-up imaging

- Follow-up imaging for known subdural hematomas, intracerebral hemorrhage, or contusions can be done at the discretion of the ordering provider with one of the following:
 - MRI Brain without and with contrast (CPT[®] 70553) **OR**
 - MRI Brain without contrast (CPT[®] 70551) **OR**
 - CT Head without and with contrast (CPT[®] 70470) **OR**
 - CT Head without contrast (CPT[®] 70450)
- For short term follow-up imaging of acute traumatic brain injury (TBI) without neurologic deterioration, CT Head without contrast (CPT[®] 70450) is the most appropriate imaging study in individuals with ANY of the following risk factors
 - subfrontal/temporal intraparenchymal contusions
 - anticoagulation
 - age >65 years
 - intracranial hemorrhage
- MRI Brain without contrast (CPT[®] 70551) or MRI Brain without and with contrast (CPT[®] 70553) can be approved as a complementary study when neurological findings or symptoms are not sufficiently explained by CT or in subacute and chronic TBI for new, persistent, or slowly progressive symptoms.⁷

For suspected intracranial venous or arterial injury

- CTA/CTV Head (CPT[®] 70496) **OR** MRA/MRV Head (CPT[®] 70544, CPT[®] 70545, or CPT[®] 70546)
 - CT and MR Venography (CTV and MRV) are reported with the same codes as the CTA/MRA counterpart. If arterial and venous CT or MR studies are both performed in the same session, only one CPT[®] code should be used to report both procedures (see **General Guidelines - CT and MR Angiography (CTA and MRA) (HD-1.5)**)

SPECT, PET, CT/MRI perfusion, DTI (diffusion tensor imaging), functional MRI, and MR spectroscopy are not considered routine clinical practice at this time.^{3,7}

See **Neck (Cervical Spine) Pain Without/With Neurological Features (Including Stenosis) and Trauma (SP-3.2)** in the Spine Imaging Guidelines

See **General Guidelines – CT and MR Angiography (CTA and MRA) (HD-1.5)** for traumatic vascular injuries

Background and Supporting Information

Individuals with head trauma are at risk for facial and cervical trauma.

Recent studies have shown that Diffusion tensor MRI tractography may be more sensitive in demonstrating abnormalities such as axonal injury in closed head injury than conventional MRI, but these techniques are best described presently as research tools and their use in clinical practice is not determined.^{3,8}

Decisions regarding return to normal activities, including sports, are made based on the clinical status of the individual and repeat imaging is unnecessary.

In cases of post-traumatic infection, contrast-enhanced MRI or CT may be helpful

Facial Trauma (HD-13.2)

HD.TR.0013.2.A

v3.0.2024

- CT Maxillofacial without contrast (CPT[®] 70486) indicated for any concern regarding significant injury to facial structures including but not limited to:
 - Concern for orbital, maxillary, or mandibular fractures
 - Trauma with associated symptoms of anosmia, hearing, vision or speech changes, vertigo, facial numbness
 - Physical exam findings of CSF rhinorrhea (suspected post traumatic CSF leak), malocclusion, severe focal facial tenderness, focal loss of facial sensation
- CT Orbits/Temporal Bone without contrast (CPT[®] 70480) and/or CT Head without contrast (CPT[®] 70450)¹¹:
 - Concern for orbital injury or orbital wall fracture
 - Symptoms of diplopia, blurred vision, vision loss
 - Physical exam findings of enophthalmos, entrapment of extraocular muscle(s)
 - Suspicion for temporal bone fracture
 - Physical exam findings of CSF otorrhea (suspected post-traumatic CSF leak)
- If concern for CSF leak and CT Maxillofacial or Temporal bone is inconclusive⁷ (see **Low Pressure Headache and CSF Leak (HD-11.15)**)

Background and Supporting Information

Imaging is not necessary in the evaluation of simple nasal fractures if tenderness and swelling is limited to the nasal bridge, the individual can breathe through each naris, and there is no septal hematoma.

References (HD-13)

HD.TR.0013.3.A

v3.0.2024

1. Stiell IG, Wells GA, Vandemheen K, et al. The Canadian CT Head Rule for patients with minor head injury. *Lancet*. 2001;357(9266):1391-1396. doi:10.1016/s0140-6736(00)04561-x
2. Giza CC, Kutcher JS, Ashwal S, et al. Summary of evidence-based guideline update: Evaluation and management of concussion in sports: Report of the Guideline Development Subcommittee of the American Academy of Neurology. *Neurology*. 2013;80(24):2250-2257. doi:10.1212/wnl.0b013e31828d57dd
3. Silverberg ND, Iaccarino MA, Panenka WJ, et al. Management of Concussion and Mild Traumatic Brain Injury: A Synthesis of Practice Guidelines. *Arch Phys Med Rehabil*. 2020;101(2): 382-393. doi: 10.1016/j.apmr.2019.10.179.
4. Hoffmann JF. An Algorithm for the Initial Management of Nasal Trauma. *Facial Plast Surg*. 2015;31(3): 183-193. doi: 10.1055/s-0035-1555618.
5. Sun JK, Lemay DR. Imaging of facial trauma. *Neuroimaging Clin N Am*. 2002;12(2):295-309. doi:10.1016/s1052-5149(02)00002-3
6. Harmon KG, Clugston JR, Dec K, et al. American Medical Society for Sports Medicine position statement on concussion in sport. *B J Sports Med*. 2019;53(4):213-225. doi:10.1136/bjsports-2018-100338
7. Expert Panel on Neurological Imaging, Shih RY, Burns J, et al. ACR Appropriateness Criteria® Head Trauma: 2021 Update. *J Am Coll Radiol*. 2021;18(5S):S13-S36. doi:10.1016/j.jacr.2021.01.006
8. Wintermark M, Sanelli PC, Anzai Y, et al. Imaging Evidence and Recommendations for Traumatic Brain Injury: Conventional Neuroimaging Techniques. *J A Coll Radiol*. 2015;12(2):e1-e14. doi:10.1016/j.jacr.2014.10.014
9. Papa L, Stiell IG, Clement CM, et al. Performance of the Canadian CT Head Rule and the New Orleans Criteria for predicting any traumatic intracranial injury on computed tomography in a United States Level I trauma center. *Acad Emerg Med*. 2012;19(1): 2-10. doi: 10.1111/j.1553-2712.2011.01247.x.
10. Reljic T, Mahony H, Djulbegovic B, et al. Value of Repeat Head Computed Tomography after Traumatic Brain Injury: Systematic Review and Meta-Analysis. *J Neurotrauma*. 2014;31(1):78-98. doi:10.1089/neu.2013.2873
11. Expert Panel on Neurologic Imaging, Kennedy TA, Corey AS, et al. ACR Appropriateness Criteria® Orbits Vision and Visual Loss. *J Am Coll Radiol*. 2018;15(5S):S116-S131. doi:10.1016/j.jacr.2018.03.023
12. Mower WR, Hoffman JR, Herbert M, et al. Developing a Decision Instrument to Guide Computed Tomographic Imaging of Blunt Head Injury Patients. *J Trauma*. 2005;59(4):954-959. doi:10.1097/01.ta.0000187813.79047.42
13. Haydel MJ, Preston CA, Mills TJ, Luber S, Blaudeau E, Deblieux PM. Indications for Computed Tomography in Patients with Minor Head Injury. *N Engl J Med*. 2000;343(2):100-105. doi:10.1056/nejm200007133430204
14. https://www.cdc.gov/traumaticbraininjury/pdf/tbi_clinicians_factsheet-a.pdf
15. ACR-ASNR-SPR Practice Parameter for the Performance of Computed Tomography (CT) of the Extracranial Head and Neck Revised 2021. (Resolution 5). <https://www.acr.org/-/media/ACR/Files/Practice-Parameters/CT-Head-Neck>

CNS and Head Infection/ Neuro-COVID-19 (HD-14)

Guideline

CNS and Head Infection (HD-14.1)

Neuro-COVID-19 and Sars-CoV-2 Vaccines (HD-14.2)

Autoimmune/Paraneoplastic Encephalitis & Neuroinflammatory Disorders (HD-14.3)

References (HD-14)

CNS and Head Infection (HD-14.1)

HD.HI.0014.1.A

v3.0.2024

INITIAL IMAGING

- Signs of intracranial infection include, but are not limited to
 - headaches, seizures, meningeal signs (neck stiffness)
 - new focal neurological deficits in a setting of fever or elevated white blood cell count (WBC)
 - known infection elsewhere or
 - immunosuppression
- **ONE** of the following studies for suspected intracranial infection if any of these signs of infection are present:
 - MRI Brain without and with contrast (CPT[®] 70553) (preferred) **OR** MRI Brain without contrast (CPT[®] 70551) **OR**
 - CT Head (CPT[®] 70450, CPT[®] 70460, or CPT[®] 70470) in cases where MRI is contraindicated
 - If vascular involvement is suspected, in addition to MRI Brain, the following are supported²¹:
 - MRA Head (CPT[®] 70544, CPT[®] 70545, or CPT[®] 70546) **OR**
 - CTA Head (CPT[®] 70496) **AND/OR**
 - MRA Neck (CPT[®] 70547, CPT[®] 70548, or CPT[®] 70549) **OR**
 - CTA Neck (CPT[®] 70498)
 - (CT and MR Venography (CTV and MRV) are reported with the same codes as the CTA/MRA counterpart (there is no specific code for CT/MR venography)
 - Concern for vasculitis, see **Cerebral Vasculitis (HD-22.1)**

REPEAT IMAGING

- As requested by an infectious disease specialist, neurologist, neurosurgeon, radiologist or any provider coordinating care with an infectious disease specialist, neurologist, neurosurgeon or radiologist
- Repeat imaging would refer to any of the CPT codes listed above as initial imaging.
 - See **General Guidelines – CT Head (HD-1.4)** regarding additional indications for CT Head.
 - See **Skull Base Osteomyelitis (SBO) (HD-20.1)**, **Sinus and Facial Imaging (HD-29.1)**, **Dental/Periodontal/Maxillofacial Imaging (HD-30.2)**, **Mental Status Change (HD-4.2)**, and **Eye Disorders and Visual Loss (HD-32.1)**

Neuro-COVID-19 and Sars-CoV-2 Vaccines (HD-14.2)

HD.HI.0014.2.A

v3.0.2024

- The following studies are supported for evaluation of:
 - Acute or chronic Neuro-COVID-19 syndrome
 - MRI Brain without contrast (CPT[®] 70551) **OR**
 - MRI Brain without and with contrast (CPT[®] 70553) **OR**
 - CT head without contrast (CPT[®] 70450) **OR**
 - CT head without and with contrast (CPT[®] 70470) is supported if there is a contraindication to MRI **AND/OR**
 - MRA Head (CPT[®] 70544, CPT[®] 70545, or CPT[®] 70546) OR CTA Head (CPT[®] 70496) **AND/OR**
 - MRA Neck (CPT[®] 70547, CPT[®] 70548, or CPT[®] 70549) or CTA Neck (CPT[®] 70498)
 - CT and MR Venography (CTV and MRV) are reported with the same codes as the CTA/MRA counterpart (there is no specific code for CT/MR venography):
 - If arterial and venous CT or MR studies are both performed in the same session, only one CPT[®] code is used to report both procedures
 - If an arterial CTA or MRA study has been performed and subsequently a repeat study is needed to evaluate the venous anatomy, then this study is supported
 - If a venous CTV or MRV has been performed and subsequently a repeat study is needed to evaluate the arterial anatomy, then this study is supported
 - MRA without and with contrast with venous sinus thrombosis to differentiate total from subtotal occlusion is supported
 - Suspected neurologic adverse reactions after SARS- CoV-2 vaccination:
 - MRI Brain without contrast (CPT[®] 70551) **OR**
 - MRI Brain without and with contrast (CPT[®] 70553) **OR**
 - CT head without contrast (CPT[®] 70450) **OR**
 - CT head without and with contrast (CPT[®] 70470) is supported if there is a contraindication to MRI **AND/OR**
 - MRA Head (CPT[®] 70544, CPT[®] 70545, or CPT[®] 70546) OR CTA Head (CPT[®] 70496) **AND/OR**
 - MRA Neck (CPT[®] 70547, CPT[®] 70548, or CPT[®] 70549) or CTA Neck (CPT[®] 70498)

- CT and MR Venography (CTV and MRV) are reported with the same codes as the CTA/MRA counterpart (there is no specific code for CT/MR venography):
 - If arterial and venous CT or MR studies are both performed in the same session, only one CPT[®] code is used to report both procedures
 - If an arterial CTA or MRA study has been performed and subsequently a repeat study is needed to evaluate the venous anatomy, then this study is supported
 - If a venous CTV or MRV has been performed and subsequently a repeat study is needed to evaluate the arterial anatomy, then this study is supported
 - MRA without and with contrast with venous sinus thrombosis to differentiate total from subtotal occlusion is supported
- If suspected transverse myelitis and/or COVID infection, then ANY the following are supported:
 - MRI Cervical without and with contrast (CPT[®] 72156)
 - MRI Thoracic without and with contrast (CPT[®] 72157)
 - MRI Lumbar Spine without and with contrast (CPT[®] 72158)^{35,36}
 - See **Stroke/TIA (HD-21.1)** for vascular imaging
 - See **Transverse Myelitis (HD-16.4)** regarding spine imaging to evaluate for post-vaccination neurological syndrome
- Repeat imaging considered on a case-by-case basis for a change in neurological symptoms or signs on the neurological exam and/or change in the treatment.

Background and Supporting Information

- The findings observed in the central nervous system in the acute-phase of COVID-19 may extend into a prolonged symptomatic phase of Neuro-COVID in long haulers with chronic COVID syndrome. Symptoms may include, but are not inclusive to: "brain fog", dizziness, inability to concentrate, psychiatric symptoms, and confusion.^{8,9}
- Acute-phase neurologic manifestations of COVID-19 include: headache, dizziness, taste and smell dysfunction, impaired consciousness (described as confusion or agitation), cerebrovascular events (ischemic stroke, cerebral venous sinus thrombosis, cerebral hemorrhage), seizures, meningoencephalitis, and immune-mediated neurologic diseases (Guillan-Barre syndrome, Miller-Fisher syndrome, polyneuritis cranialis, transverse myelitis).^{10,11,15,16,20}
- Neurologic adverse reactions in those receiving SARS-CoV-2 vaccines, including mRNA vaccines (Pfizer, Moderna), have been reported, and include, although not limited to: headache, Guillan-Barre syndrome, transverse myelitis, facial nerve palsy, small fiber neuropathy, autoimmune encephalitis, reversible cerebral vasoconstriction syndrome, multiple sclerosis, neuromyelitis optica, intracerebral bleeding, cerebral venous sinus thrombosis, hypophysitis, epilepsy, encephalopathy, and acute disseminated encephalomyelitis.^{13,14,17,18,19,21}

- Cases of Thrombosis with Thrombocytopenia Syndrome (TTS) following administration of the Johnson & Johnson/Janssen COVID-19 Vaccine have been reported in males and females, in a wide age range of individuals 18 years and older, with the highest reporting rate (approximately 8 cases per 1,000,000 doses administered) in females ages 30-49 years; overall, approximately 15% of TTS cases have been fatal. Currently available evidence supports a causal relationship between TTS and the Johnson & Johnson/Janssen COVID-19 Vaccine. The clinical course of these events shares features with autoimmune heparin-induced thrombocytopenia. In individuals with suspected TTS following administration of the Johnson & Johnson/Janssen COVID-19 Vaccine, the use of heparin may be harmful and alternative treatments may be needed. Consultation with hematology specialists is strongly recommended. The American Society of Hematology has published considerations relevant to the diagnosis and treatment of TTS following administration of the Janssen COVID-19 Vaccine (<https://www.hematology.org/covid-19/vaccine-induced-immunethrombotic-thrombocytopenia>). (see Full EUA Prescribing Information).
- Janssen COVID-19 Vaccine EUA Fact Sheet for Healthcare Providers 03132023 ([fda.gov](https://www.fda.gov))

Autoimmune/Paraneoplastic Encephalitis & Neuroinflammatory Disorders (HD-14.3)

HD.HI.0014.3.A

v3.0.2024

Indications:

When acute/ subacute or rapid progression (< 3 months) of altered mental status, focal findings including cranial nerve, motor or sensory symptoms or memory loss or psychiatric symptoms, seizure, and/ or focal CNS findings are present.²⁶

OR

There is a stated concern for neuro-inflammatory encephalitis from a neurologist, neurosurgeon or psychiatrist²⁶:

Initial Imaging²⁶:

- MRI Brain without and with contrast (CPT[®] 70553; preferred study) **OR** MRI Brain without contrast (CPT[®] 70551) **OR**
- CT Head without contrast (CPT[®] 70450) **OR** CT Head without and with contrast (CPT[®] 70470) when MRI is unavailable or contraindicated or for bony pathology concerns
- CTA Head (CPT[®] 70496) **AND/OR** CTA Neck (CPT[®] 70498) for evaluating large vessel obstructions, aneurysms and vascular malformations, dissection, vasospasm, and vasculopathies such as CNS vasculitis (see **Cerebral Vasculitis (HD 22.1)**, **Intracranial Aneurysms (HD 12.1)**, **Arteriovenous Malformations (AVMs) and Related Lesions (HD 12.2)**, **Stroke/TIA (HD 21.1)**)

Repeat Imaging:

MRI Brain without and with contrast (CPT[®] 70553) **OR** MRI Brain without contrast (CPT[®] 70551) when specialized sequences are needed such as, but not limited to²⁶:

- High T2 contrast sequences (CISS, FIESTA) sequences to identify blood (SWI) or
- To identify acute cytotoxic edema (DWI) or
- When requested by a neurologist, oncologist, rheumatologist or infectious disease specialist

Metabolic (FDG) Brain PET (CPT[®] 78608) is indicated to evaluate individuals suspected of having encephalitis, including autoimmune encephalitis, if diagnosis remains unclear after evaluation with MRI Brain, CSF analysis, and/or lab testing including serology.²⁶

Neurosarcoidosis^{31,32,33,34.}

- Supported for known or suspected neurosarcoidosis.
 - MRI Brain without and with contrast (CPT[®] 70553)
- AND/OR**
- If spinal cord involvement suspected, then
 - MRI Cervical Spine without and with contrast (CPT[®] 72156) **AND/OR**
 - MRI Thoracic Spine without and with contrast (CPT[®] 72157) **AND/OR**
 - MRI Lumbar Spine without and with contrast (CPT[®] 72158)
- AND/OR**
- If peri-orbital involvement suspected, then
 - MRI Orbits/Face/Neck without and with contrast (CPT[®] 70543)
- Repeat imaging supported if requested by neurologist, rheumatologist, ophthalmologist, oncologist or radiologist or provider in consultation with a neurologist, rheumatologist, ophthalmologist, oncologist or radiologist.
- For non-neurologic imaging related to sarcoidosis (see **Sarcoid (CH-15.1)**)

Background and Supporting Information²⁶

Supportive studies in the evaluation of Autoimmune/Paraneoplastic Encephalopathy include:

- CSF pleocytosis (>5 WBC/ μ L) or
- EEG changes or
- Supporting labs (including positive CSF antibody positivity and/or serologies)

Potential etiologies:

- Paraneoplastic
 - NMDA Receptor encephalitis
 - LGI1 antibody encephalitis
- Autoimmune
 - Neurosarcoidosis can involve any of the following:
 - Brain, Cranial Nerves, Spinal Cord and/or Peripheral Nerves
 - Acute Disseminated Encephalomyelitis (ADEM), Anti-MOG Syndrome, Multiple Sclerosis (MS), Neuromyelitis Optica (NMO)
 - IgG4 related disease
 - CNS histiocytosis
- Neuro-rheumatologic
 - ANCA related disease

- Behcet's disease
- Sjogren Syndrome +/- Rheumatoid Arthritis (RA)

FDG-PET imaging of the brain for paraneoplastic and autoimmune encephalitis may be more sensitive than Brain MRI (87% vs. 56%) but is nonspecific. Areas of hypometabolism are seen in neurodegenerative disorders such as dementias. However, topographic patterns of hypometabolism may help characterize the disorder as autoimmune/ paraneoplastic encephalitis, in a way that may help clarify diagnosis and alter management strategies. For example, anterior to posterior gradient of hypometabolism is seen in NMDA Receptor encephalitis. Hemispheric hypometabolism out of proportion to atrophy characterizes Rasmussen encephalitis.²⁶

Non-head Imaging

- MRI is helpful in determining the length of spine lesion (short versus longitudinally extensive transverse myelitis), width (partial versus transverse), and location (eccentric, central, hemicord, anterior versus posterior, conus, tracts, or meningeal).
 - See **Myelopathy (SP 7.1)** and **Anti-MOG Syndromes (HD 16.3)**
- The Trident Sign on axial MRI, which has been described in relation to neurosarcoidosis, demonstrates leptomeningeal or dorsal subpial enhancement that may or may not involve the central canal.
 - See **Myelopathy (SP 7.1)**
- Involvement of the conus medullaris is a clue to Anti-MOG (Myelin Oligodendrocyte Glycoprotein-associated disorder) as the cause of longitudinally extensive transverse myelitis.
 - See **Transverse Myelitis (HD 16.4)**
- CT of the chest, abdomen, and pelvis with contrast is a generally accepted first method of screening for occult malignancy or systemic inflammation (e.g., sarcoidosis).
 - See **Paraneoplastic Syndromes (ONC 30.3)** and **Sarcoid (CH 15.1)**

References (HD-14)

v3.0.2024

1. Abdalkader M, Xie J, Cervantes-Arslanian A, Takahashi C, Mian AZ. Imaging of Intracranial Infections. *Seminars in Neurology*. 2019;39(03):322-333. doi:10.1055/s-0039-1693161
2. Probasco JC, Solnes L, Nalluri A, et al. Abnormal brain metabolism on FDG-PET/CT is a common early finding in autoimmune encephalitis. *Neurology - Neuroimmunology Neuroinflammation*. 2017;4(4). doi:10.1212/nxi.0000000000000352
3. Rubin R. As Their Numbers Grow, COVID-19 "Long Haulers" Stump Experts. *JAMA*. 2020;324(14):1381–1383. doi:10.1001/jama.2020.17709
4. E. M. Liotta et al. Frequent neurologic manifestations and encephalopathy-associated morbidity in Covid-19 patients. *Annals of Clinical and Translational Neurology* 2020; 7(11): 2221–2230 doi: 10.1002/acn3.51210.
5. Chen X, Laurent S, Onur OA, Kleineberg NN, Fink GR, Schweitzer F, Warnke C. A systematic review of neurological symptoms and complications of COVID-19. *Journal of Neurology*. 2021 Feb;268(2):392-402. doi: 10.1007/s00415-020-10067-3
6. Finsterer J Neurological side effects of SARS#CoV#2 vaccinations Acta Neurol Scand. 2022 145(1): 5–9. doi: 10.1111/ane.13550
7. Kaulen LD, Doubrovinskaia S, Mooshage C, Jordan B, Purrucker J, Haubner C, Seliger C, Lorenz HM, Nagel S, Wildemann B, Bendszus M, Wick W, Schönenberger S. Neurological autoimmune diseases following vaccinations against SARS-CoV-2: a case series. *Eur J Neurol*. 2022 Feb;29(2):555-563. doi: 10.1111/ene.15147
8. Maury A, Lyoubi A, Peiffer-Smadja N, de Broucker T, Meppiel E. Neurological manifestations associated with SARS-CoV-2 and other coronaviruses: A narrative review for clinicians. *Rev Neurol (Paris)*. 2021 Jan-Feb;177(1-2):51-64. doi: 10.1016/j.neurol.2020.10.001
9. Moreno-Escobar MC, Kataria S, Khan E, Subedi R, Tandon M, Peshwe K, Kramer J, Niaze F, Sriwastava S. Acute transverse myelitis with Dysautonomia following SARS-CoV-2 infection: A case report and review of literature. *J Neuroimmunol*. 2021 Apr 15;353:577523. doi: 10.1016/j.jneuroim.2021.577523
10. Patone M, Handunnetthi L, Saatci D, Pan J, Katikireddi SV, Razvi S, Hunt D, Mei XW, Dixon S, Zaccardi F, Khunti K, Watkinson P, Coupland CAC, Doidge J, Harrison DA, Ramanan R, Sheikh A, Robertson C, Hippisley-Cox J. Neurological complications after first dose of COVID-19 vaccines and SARS-CoV-2 infection. *Nat Med*. 2021 Dec;27(12):2144-2153. doi: 10.1038/s41591-021-01556-7
11. Rosenblum HG, Hadler SC, Moulia D, Shimabukuro TT, Su JR, Tepper NK, Ess KC, Woo EJ, Mba-Jonas A, Alimchandani M, Nair N, Klein NP, Hanson KE, Markowitz LE, Wharton M, McNally VV, Romero JR, Talbot HK, Lee GM, Daley MF, Mbaeyi SA, Oliver SE. Use of COVID-19 Vaccines After Reports of Adverse Events Among Adult Recipients of Janssen (Johnson & Johnson) and mRNA COVID-19 Vaccines (Pfizer-BioNTech and Moderna): Update from the Advisory Committee on Immunization Practices - United States, July 2021. *MMWR Morb Mortal Wkly Rep*. 2021 Aug 13;70(32):1094-1099. doi: 10.15585/mmwr.mm7032e4
12. Rosenblum HG, Gee J, Liu R, Marquez PL, Zhang B, Strid P, Abara WE, McNeil MM, Myers TR, Hause AM, Su JR, Markowitz LE, Shimabukuro TT, Shay DK. Safety of mRNA vaccines administered during the initial 6 months of the US COVID-19 vaccination programme: an observational study of reports to the Vaccine Adverse Event Reporting System and v-safe. *Lancet Infect Dis*. 2022 Mar 7:S1473-3099(22)00054-8. doi: 10.1016/S1473-3099(22)00054-8
13. Vasconcelos TMF, Oliveira DN, Ferreira GM, Torres FC, Castro JDV, Braga-Neto P, Sobreira-Neto MA. Covid-19 post-infectious acute transverse myelitis responsive to corticosteroid therapy: report of two clinical cases. *J Neurovirol*. 2021 Oct;27(5):791-796. doi: 10.1007/s13365-021-01010-x 12
14. Frontera JA, Tamborska AA, Doheim MF, Garcia-Azorin D, Gezegen H, Guekht A, Yusof Khan AHK, Santacatterina M, Sejvar J, Thakur KT, Westenberg E, Winkler AS, Beghi E; contributors from the Global COVID-19 Neuro Research Coalition. Neurological Events Reported after COVID-19 Vaccines: An Analysis of VAERS. *Ann Neurol*. 2022 Mar 2. doi: 10.1002/ana.26339
15. ACR–ASNR–SPR PRACTICE PARAMETER FOR THE PERFORMANCE OF COMPUTED TOMOGRAPHY (CT) OF THE HEAD <https://www.acr.org/-/media/ACR/Files/Practice-Parameters/CT-Head.pdf>

16. Expert Panel on Neurological Imaging, Rath TJ, Policeni B, et al. ACR Appropriateness Criteria® Cranial Neuropathy: 2022 Update. *J Am Coll Radiol*. 2022;19(11S):S266-S303. doi:10.1016/j.jacr.2022.09.021
17. Anand P. Neurologic Infections in Patients on Immunomodulatory and Immunosuppressive Therapies. *Continuum (Minneap Minn)*. 2021;27(4):1066-1104. doi:10.1212/CON.0000000000000985
18. Chow F. Neurosyphilis. *Continuum (Minneap Minn)*. 2021;27(4):1018-1039. doi:10.1212/CON.0000000000000982
19. Roos KL. Neurologic Complications of Lyme Disease. *Continuum (Minneap Minn)*. 2021;27(4):1040-1050. doi:10.1212/CON.0000000000001015
20. Singh SK, Hasbun R. Neuroradiology of infectious diseases. *Curr Opin Infect Dis*. 2021;34(3):228-237. doi:10.1097/QCO.0000000000000725
21. Weidauer S, Wagner M, Enkirch SJ, Hattingen E. CNS Infections in Immunoincompetent Patients : Neuroradiological and Clinical Features. *Clin Neuroradiol*. 2020;30(1):9-25. doi:10.1007/s00062-019-00837-6
22. Sakai M, Higashi M, Fujiwara T, et al. MRI imaging features of HIV-related central nervous system diseases: diagnosis by pattern recognition in daily practice. *Jpn J Radiol*. 2021;39(11):1023-1038. doi:10.1007/s11604-021-01150-4
23. Corrêa DG, de Souza SR, Freddi TAL, Fonseca APA, Dos Santos RQ, Hygino da Cruz LC Jr. Imaging features of neurosyphilis. *J Neuroradiol*. 2023;50(2):241-252. doi:10.1016/j.neurad.2023.01.003
24. Beghi E, Helbok R, Ozturk S, et al. Short- and long-term outcome and predictors in an international cohort of patients with neuro-COVID-19. *Eur J Neurol*. 2022;29(6):1663-1684. doi:10.1111/ene.15293
25. Premraj L, Kannapadi NV, Briggs J, Seal SM, Battaglini D, Fanning J, Suen J, Robba C, Fraser J, Cho SM. Mid and long-term neurological and neuropsychiatric manifestations of post-COVID-19 syndrome: A meta-analysis. *J Neurol Sci*. 2022 Mar 15;434:120162. doi: 10.1016/j.jns.2022.120162. Epub 2022 Jan 29. PMID: 35121209; PMCID: PMC8798975.
26. Wahed LA, Cho TA. Imaging of Central Nervous System Autoimmune, Paraneoplastic, and Neuro-rheumatologic Disorders. *Continuum (Minneap Minn)*. 2023 Feb 1;29(1):255-291. doi: 10.1212/CON.0000000000001244. PMID: 367958880.
27. Bordonne, M., Chawki, M.B., Doyen, M. et al. Brain 18F-FDG PET for the diagnosis of autoimmune encephalitis: a systematic review and a meta-analysis. *Eur J Nucl Med Mol Imaging* 48, 3847–3858 (2021). <https://doi.org/10.1007/s00259-021-05299-y>
28. Graus F, Titulaer MJ, Balu R, et al. A clinical approach to diagnosis of autoimmune encephalitis. *Lancet Neurol*. 2016;15(4):391-404. doi:10.1016/S1474-4422(15)00401-9
29. Budhram A, Leung A, Nicolle MW, Burneo JG. Diagnosing autoimmune limbic encephalitis. *CMAJ*. 2019;191(19):E529-E534. doi:10.1503/cmaj.181548
30. Solnes LB, Jones KM, Rowe SP, et al. Diagnostic Value of ¹⁸F-FDG PET/CT Versus MRI in the Setting of Antibody-Specific Autoimmune Encephalitis. *J Nucl Med*. 2017;58(8):1307-1313. doi:10.2967/jnumed.116.184333
31. Stern BJ, Royal W, Gelfand JM, et al. Definition and Consensus Diagnostic Criteria for Neurosarcoidosis: From the Neurosarcoidosis Consortium Consensus Group. *JAMA Neurology*. 2018;75(12):1546. doi:10.1001/jamaneurol.2018.2295.
32. Bradshaw MJ, Pawate S, Koth LL, Cho TA, Gelfand JM. Neurosarcoidosis: Pathophysiology, Diagnosis, and Treatment. *Neurol Neuroimmunol Neuroinflamm*. 2021 Oct 4;8(6):e1084. doi: 10.1212/NXI.0000000000001084
33. Fritz D, van de Beek D, Brouwer MC. Clinical features, treatment and outcome in neurosarcoidosis: systematic review and meta-analysis. *BMC Neurol*. 2016 Nov 15;16(1):220. doi: 10.1186/s12883-016-0741-x
34. Pawate S. Sarcoidosis and the Nervous System. *Continuum (Minneap Minn)*. 2020 Jun;26(3):695-715. doi: 10.1212/CON.0000000000000855
35. Khan E, Shrestha AK, Colantonio MA, Liberio RN, Sriwastava S. Acute transverse myelitis following SARS-CoV-2 vaccination: a case report and review of the literature. *J Neurol*. 2022;269(3):1121-1132. doi:10.1007/s00415-021-10785-2
36. Ismail II, Salama S. Association of CNS demyelination and COVID-19 infection: an updated systematic review. *J Neurol*. 2022;269(2):541-576. doi:10.1007/s00415-021-10752-x

Movement Disorders (HD-15)

Guideline

Movement Disorders (HD-15.1)

References (HD-15)

Movement Disorders (HD-15.1)

HD.MD.0015.1.A

v3.0.2024

- The majority of movement disorders are diagnosed based on a clinical diagnosis and do not require imaging. These include:
 - Typical Parkinson's Disease
 - Essential Tremor or tremors of anxiety or weakness
 - Restless Leg Syndrome
 - Tics or spasms which can be duplicated at will
- MRI Brain without contrast (CPT[®] 70551) or MRI brain without and with contrast (CPT[®] 70553) in the following clinical scenarios:
 - Clinical diagnostic uncertainty
 - Incomplete or uncertain response to medication
 - Atypical Parkinsonism suspected because of unusual clinical features. These may include, but are not limited to:
 - Persistent unilateral signs or symptoms
 - Onset under age 50
 - Rapid progression
 - See **Background and Supporting Information** for further information on atypical parkinsonism and Parkinson's Plus Syndromes
 - Suspected Huntington Disease
- Evaluation for surgical treatment of Essential Tremor, Parkinson's disease, and/or Spasmodic Torticollis/Dystonia, see **Torticollis and Dystonia (Neck-10.2)** in the Neck Imaging Guidelines
 - Deep Brain Stimulation (DBS) therapy
 - MRI Brain without contrast (CPT[®] 70551) **OR** MRI Brain without and with contrast (CPT[®] 70553) **AND/OR** unlisted CT procedure code (CPT[®] 76497)
 - MR guided Focused Ultrasound:
 - CT Head without contrast (CPT[®] 70450) to evaluate bone density **AND/OR** MRI Brain without contrast (CPT[®] 70551) **OR** MRI Brain without and with contrast (CPT[®] 70553)
 - Repeat imaging studies for pre-surgical evaluation, MRI Brain without contrast (CPT[®] 70551) **OR** MRI Brain without and with contrast (CPT[®] 70553) **AND/OR** CT Head without contrast (CPT[®] 70450), when ordered by a Neurosurgeon or Neurologist or any provider in consultation with a Neurosurgeon or Neurologist if greater than 6 months old **and/or** for new symptoms/signs

- Post op imaging when ordered by a Neurosurgeon or Neurologist or any provider in consultation with a Neurosurgeon or Neurologist for either procedure, see also **Post-Operative Imaging (HD-28.3)** indications
- Dopamine Transporter Scan [DAT-SPECT Radiopharmaceutical Localization SPECT (Ioflupane I-123 SPECT)] (CPT[®] 78803 or CPT[®] 78830 **OR** Fluorodopa F¹⁸ (F-DOPA) PET Brain (CPT[®] 78606)^{2,3,16,17,18}:
 - To evaluate motor symptoms (tremor, rigidity, bradykinesia, and/or postural instability) in suspected Parkinsonian Syndromes (Parkinson Disease, Multiple System Atrophy, Progressive Supranuclear Palsy, Corticobasal Degeneration) when the diagnosis is unclear, to differentiate from non-neurodegenerative disorders, such as Essential Tremor, drug-induced tremor, vascular parkinsonism, and/or psychogenic tremor
 - Imaging with either modality, **not both**, is supported when the diagnosis remains unclear after evaluation by a neurologist, medication trials and brain imaging.¹
 - See **Background and Supporting Information** for additional information regarding Parkinson's Plus Syndromes.
 - Neither DAT Scans nor F-DOPA PET scans are useful for differentiation of subtypes of Parkinson's syndromes, to monitor progression of disease or predict risk of development of disease mainly to exclude other conditions with similar clinical presentations.
- MRI Brain with and without (CPT[®] 70553) for initial imaging for suspected motor neuron disease (see **Motor Neuron Disease/Amyotrophic Lateral Sclerosis (ALS) (PND-8.1)** in the Peripheral Nerve Disorders Imaging Guideline)
- Dementia associated with movement disorder (see **Lewy Body Dementia (LBD) – SPECT Brain Scan (HD-8.3)**)

Background and Supporting Information

- Parkinson's Plus Syndromes are a group of disorders characterized by atypical parkinsonism. They are NOT Parkinson's disease. They represent different neurodegenerative diseases with features of PD, and may be confused with PD. These syndromes include, but are not limited to:
 - Multiple system atrophy: orthostatic hypotension (dysautonomia), dysphonia, dysarthria
 - Progressive Supranuclear Palsy: balance difficulties, vertical gaze paresis
 - Corticobasal Syndrome: dysphasia, apraxia, myoclonus, alien-limb phenomenon
- These are distinct entities. Care must be taken to determine if there are unusual features present that will suggest atypical parkinsonian syndrome.
- Dementia with Lewy bodies (DLB): dementia prior to movement disorder (see **Lewy Body Dementia (LBD) - SPECT Brain Scan (HD-8.3)**)

References (HD-15)

v3.0.2024

1. Expert Panel on Neurological Imaging, Harvey HB, Watson LC, et al. ACR Appropriateness Criteria® Movement Disorders and Neurodegenerative Diseases. *J Am Coll Radiol*. 2020;17(5S):S175-S187. doi:10.1016/j.jacr.2020.01.042
2. Thaler A, Alcalay RN. Diagnosis and Medical Management of Parkinson Disease. *Continuum (Minneapolis)*. 2022;28(5):1281-1300. doi:10.1212/CON.0000000000001152
3. Maiti B, Perlmutter JS. Imaging in Movement Disorders. *Continuum (Minneapolis)*. 2023;29(1):194-218. doi:10.1212/CON.0000000000001210
4. Subramaniam RM, Frey KA, Hunt CH, et al. ACR-ACNM Practice Parameter for the Performance of Dopamine Transporter (DaT) Single Photon Emission Computed Tomography (SPECT) Imaging for Movement Disorders. *Clinical Nuclear Medicine*. 2017;42(11):847-852. doi:10.1097/rlu.0000000000001815
5. Bega D, Gonzalez-Latapi P, Zadikoff C, Spies W, Simuni T. Is There a Role for DAT-SPECT Imaging in a Specialty Movement Disorders Practice? *Neurodegenerative Diseases*. 2015;15(2):81-86. doi:10.1159/000370116
6. Mohammed N, Patra D, Nanda A. A meta-analysis of outcomes and complications of magnetic resonance-guided focused ultrasound in the treatment of essential tremor. *Neurosurgical Focus*. 2018;44(2). doi:10.3171/2017.11.focus17628
7. Schreglmann SR, Krauss JK, Chang JW, Bhatia KP, Kägi G. Functional lesional neurosurgery for tremor: a systematic review and meta-analysis. *Journal of Neurology, Neurosurgery & Psychiatry*. 2018;89(7):717-726. doi:10.1136/jnnp-2017-316302
8. Halpern CH, Santini V, Lipsman N, et al. Three-year follow-up of prospective trial of focused ultrasound thalamotomy for essential tremor. *Neurology*. 2019;93(24). doi:10.1212/wnl.0000000000008561
9. Pouratian N, Baltuch G, Elias WJ, Gross R. American Society for Stereotactic and Functional Neurosurgery Position Statement on Magnetic Resonance-Guided Focused Ultrasound for the Management of Essential Tremor. *Neurosurgery*. 2019. doi:10.1093/neuros/nyz510
10. Shah BR, et al. Advanced MRI techniques for transcranial high intensity focused ultrasound targeting. *Brain* 2020;1-9. doi:10.1093/brain/awaa107
11. Elias JW. A randomized Trial of Focused Ultrasound Thalamotomy for Essential Tremor. *N Engl J Med* 2016;375:730-9. doi: 10.1056/NEJMoa1600159
12. Rughani A, Schwalb JM, Sidiropoulos C, et al. Congress of Neurological Surgeons Systematic Review and Evidence-Based Guideline on Subthalamic Nucleus and Globus Pallidus Internus Deep Brain Stimulation for the Treatment of Patients With Parkinson's Disease: Executive Summary. *Neurosurgery*. 2018;82(6):753-756. doi:10.1093/neuros/nyy037.
13. Y. Xiao, J. C. Lau, D. Hemachandra, G. Gilmore, A. Khan and T. M. Peters, "Image guidance in deep brain stimulation surgery to treat Parkinson's disease: a comprehensive review," in *IEEE Transactions on Biomedical Engineering*, doi: 10.1109/TBME.2020.3006765.
14. Sakamoto F, Shiraishi S, Ogasawara K, et al. A diagnostic strategy for Lewy body disease using DAT-SPECT, MIBG and Combined index. *Annals of Nuclear Medicine*. 2020;34(6):415-423. doi:10.1007/s12149-020-01464-9.
15. Humanitarian Device Exemption. U.S. Food and Drug Administration (FDA). Page Last Updated: 07/12/2021. <https://www.accessdata.fda.gov/scripts/cdrh/cfdocs/cfhde/hde.cfm?id=H020007>
16. Fluorodopa F18 Injection Package Insert. Highlights of prescribing information. U.S. Food and Drug Administration Website. https://www.accessdata.fda.gov/drugsatfda_docs/label/2019/200655s000lbl.pdf. Revised 10/2019.
17. Dhawan V, Niethammer MH, Lesser ML, et al. Prospective F-18 FDOPA PET Imaging Study in Human PD. *Nucl Med Mol Imaging*. 2022;56(3):147-157. doi:10.1007/s13139-022-00748-4
18. Morbelli S, Esposito G, Arbizu J, et al. EANM practice guideline/SNMMI procedure standard for dopaminergic imaging in Parkinsonian syndromes 1.0. *Eur J Nucl Med Mol Imaging*. 2020;47(8):1885-1912. doi:10.1007/s00259-020-04817-8

Multiple Sclerosis (MS) and Related Conditions (HD-16)

Guideline

Multiple Sclerosis (MS) (HD-16.1)
Neuromyelitis Optica and NMO Spectrum Disorders (HD-16.2)
MOG Antibody-Associated Disease (MOGAD) (HD-16.3)
Transverse Myelitis (HD-16.4)
References (HD-16)

Multiple Sclerosis (MS) (HD-16.1)

HD.MS.0016.1.A
v3.0.2024

Establishing a New Diagnosis of Multiple Sclerosis

Indication	Supported Imaging
<p>Establishing a new diagnosis of Multiple Sclerosis is based on the following:</p> <ul style="list-style-type: none"> Clinical suspicion based on recurrent episodes of variable neurological signs and/or symptoms <p>AND</p> <ul style="list-style-type: none"> Baseline exclusion of appropriate alternative conditions that can mimic MS 	<ul style="list-style-type: none"> MRI Brain without and with contrast (CPT[®] 70553) (preferred study) OR MRI Brain without contrast (CPT[®] 70551) if there is a contraindication to gadolinium <p>If optic neuritis** is suspected the following imaging is ALSO indicated:</p> <ul style="list-style-type: none"> MRI Orbit without and with contrast (CPT[®] 70543) OR MRI Orbit without contrast (CPT[®] 70540) <p>**For additional information related to optic neuritis see <u>Eye Disorders and Visual Loss (HD-32.1)</u></p> <p>AND/OR</p> <ul style="list-style-type: none"> MRI Cervical Spine without and with contrast (CPT[®] 72156) OR MRI Cervical Spine without contrast (CPT[®] 72141) <p>AND/OR</p> <ul style="list-style-type: none"> MRI Thoracic Spine without and with contrast (CPT[®] 72157) OR MRI Thoracic Spine without contrast (CPT[®] 72146)

Unclear Diagnosis

Indication	Supported Imaging
<p>Diagnosis of Multiple Sclerosis remains unclear or equivocal after initial MRI</p> <ul style="list-style-type: none"> • May repeat imaging 3- 6 months after initial MRI Brain 	<ul style="list-style-type: none"> • MRI Brain without contrast (CPT[®] 70551) OR • MRI Brain without and with contrast (CPT[®] 70553)

Clinically Isolated Syndrome (CIS)

Indication	Supported Imaging
<p>Clinically Isolated Syndrome (CIS)* based on ALL of the following:</p> <ul style="list-style-type: none"> • First episode of neurologic symptoms and neurologic deficits concerning for possible demyelinating disease. • Symptoms last \geq 24 hours⁴³ • Initial episode of neurologic symptoms and neurologic deficits • Baseline exclusion of appropriate alternative conditions that can mimic MS <p>*For more information about CIS, see <u>Background and Supporting Information</u></p>	<ul style="list-style-type: none"> • MRI Brain without and with contrast (CPT[®] 70553) (preferred study) OR • MRI Brain without contrast (CPT[®] 70551) if there is a contraindication to gadolinium <p>If optic neuritis is suspected **, the following imaging is ALSO indicated:</p> <ul style="list-style-type: none"> • MRI Orbit without and with contrast (CPT[®] 70543) OR • MRI Orbit without contrast (CPT[®] 70540) <p>**For additional information related to optic neuritis, see <u>Eye Disorders and Visual Loss (HD-32.1)</u></p> <p>AND/OR</p> <ul style="list-style-type: none"> • MRI Cervical Spine without and with contrast (CPT[®] 72156) OR • MRI Cervical Spine without contrast (CPT[®] 72141) <p>AND/OR</p> <ul style="list-style-type: none"> • MRI Thoracic Spine without and with contrast (CPT[®] 72157) OR • MRI Thoracic Spine without contrast (CPT[®] 72146)

Radiologically Isolated Syndrome (RIS)

Indication	Supported Imaging
<p>Radiologically Isolated Syndrome (RIS)* based on ALL of the following:</p> <ul style="list-style-type: none"> Individual with brain MRI obtained for unrelated reason with findings conspicuous for demyelinating disease⁴¹ No history of recurrent neurologic symptoms suggestive of CIS or RRMS Baseline exclusion of appropriate alternative conditions that can mimic MS <p>*For more information about RIS, see <u>Background and Supporting Information</u></p>	<ul style="list-style-type: none"> MRI Brain without and with contrast (CPT[®] 70553) OR MRI Brain without contrast (CPT[®] 70551) <p>AND/OR</p> <ul style="list-style-type: none"> MRI Cervical Spine without and with contrast (CPT[®] 72156) OR MRI Cervical Spine without contrast (CPT[®] 72141) <p>AND/OR</p> <ul style="list-style-type: none"> MRI Thoracic Spine without and with contrast (CPT[®] 72157) OR MRI Thoracic Spine without contrast (CPT[®] 72146)

New Episode of Neurological Deficit in an Individual with Multiple Sclerosis and/or Concern for Possible Diagnosis of Demyelinating Disease

Indication	Supported Imaging
<p>New episode of neurological deficit in an individual with Multiple Sclerosis and/or concern for a possible diagnosis of demyelinating disease</p>	<ul style="list-style-type: none"> • MRI Brain without contrast (CPT[®] 70551) OR • MRI Brain without and with contrast (CPT[®] 70553) <p>If optic neuritis is suspected**, the following imaging is ALSO indicated:</p> <ul style="list-style-type: none"> • MRI Orbit without and with contrast (CPT[®] 70543) OR • MRI Orbit without contrast (CPT[®] 70540) <p>**For additional information related to optic neuritis, see Eye Disorders and Visual Loss (HD-32.1)</p> <p>If there are new or worsening symptoms concerning for spinal cord involvement, the following imaging is ALSO indicated:</p> <ul style="list-style-type: none"> • MRI Cervical Spine without contrast (CPT[®] 72141) OR • MRI Cervical Spine without and with contrast (CPT[®] 72156) <p>AND/OR</p> <ul style="list-style-type: none"> • MRI Thoracic Spine without contrast (CPT[®] 72146) OR • MRI Thoracic Spine without and with contrast (CPT[®] 72157)

Baseline Imaging with Disease Modifying Therapy (DMT)

Indication	Supported Imaging
<ul style="list-style-type: none"> Before starting or changing disease modifying therapy (DMT)¹ <p>AND/OR</p> <ul style="list-style-type: none"> 3-6 months after starting or changing DMT to establish a new MRI treatment baseline <p>AND/OR</p> <ul style="list-style-type: none"> If new abnormal MRI Brain findings without clinical symptoms, an additional follow up MRI Brain is supported after 6 months¹ 	<ul style="list-style-type: none"> MRI Brain without contrast (CPT[®] 70551) OR MRI Brain without and without contrast (CPT[®] 70553)

Current Treatment with Disease Modifying Therapy (DMT)

Indication	Supported Imaging Every 6 Months	Supported Imaging Annually
<p>Individuals treated with DMT* associated with either the risk progressive multifocal leukoencephalopathy (PML) AND/OR other CNS opportunistic infections</p> <p>* For list of medications, see <u>Background and Supporting Information</u></p>	<ul style="list-style-type: none"> MRI Brain without contrast (CPT[®] 70551) OR MRI Brain without and with contrast (CPT[®] 70553) 	<ul style="list-style-type: none"> MRI Cervical Spine without contrast (CPT[®] 72141) OR MRI Cervical Spine without and with contrast (CPT[®] 72156) <p>AND/OR</p> <ul style="list-style-type: none"> MRI Thoracic Spine without contrast (CPT[®] 72146) OR MRI Thoracic Spine without and with contrast (CPT[®] 72157)

Annual Supported Imaging

Indication	Supported Imaging <i>Annually</i>
<p>Individuals with diagnosed Multiple Sclerosis with EITHER of the following:</p> <ul style="list-style-type: none"> Not treated with disease modifying therapy (DMT)* <p>OR</p> <ul style="list-style-type: none"> Treated with beta interferon or glatiramer acetate medications <p>* For list of DMT medications, see <u>Background and Supporting Information</u></p>	<ul style="list-style-type: none"> MRI Brain without contrast (CPT[®] 70551) OR MRI Brain without and with contrast (CPT[®] 70553) <p>AND/OR</p> <ul style="list-style-type: none"> MRI Cervical Spine without contrast (CPT[®] 72141) OR MRI Cervical Spine without and with contrast (CPT[®] 72156) <p>AND/OR</p> <ul style="list-style-type: none"> MRI Thoracic Spine without contrast (CPT[®] 72146) OR MRI Thoracic Spine without and with contrast (CPT[®] 72157)

Treatment with Tysabri[®] (natalizumab)

Indication	Supported Imaging <i>Every 3-6 Months</i>	Supported Imaging <i>Annually</i>
<p>Individuals treated with Tysabri[®] (natalizumab) with the following medical history:</p> <ul style="list-style-type: none"> ≥ 18 months of treatment <ul style="list-style-type: none"> During Tysabri[®] (natalizumab) treatment and up to 9-12 months after transitioning off Tysabri[®] (natalizumab)¹ <p>AND</p> <ul style="list-style-type: none"> JC virus antibody positive 	<ul style="list-style-type: none"> MRI Brain without contrast (CPT[®] 70551) OR MRI Brain without and with contrast (CPT[®] 70553) 	<ul style="list-style-type: none"> MRI Cervical Spine without contrast (CPT[®] 72141) OR MRI Cervical Spine without and with contrast (CPT[®] 72156) <p>AND/OR</p> <ul style="list-style-type: none"> MRI Thoracic Spine without contrast (CPT[®] 72146) OR MRI Thoracic Spine without and with contrast (CPT[®] 72157)

PML Symptoms during Treatment with Tysabri® (natalizumab) or other Medication with Similar Risk

Indication	Supported Imaging
Symptoms suggestive of Progressive Multifocal Leukoencephalopathy (PML)* during treatment with Tysabri® (natalizumab) or other medication with similar risk * For more information about PML, see <u>Background and Supporting Information</u>	<ul style="list-style-type: none"> • MRI Brain without contrast (CPT® 70551) OR • MRI Brain without and without contrast (CPT® 70553)

History of Clinically Isolated Syndrome (CIS) or Radiologically Isolated Syndrome (RIS)

Indication	Supported Imaging <i>Annually</i>
Patient with history of Clinically Isolated Syndrome* (CIS) ¹ OR Patient with history of Radiologically Isolated Syndrome* (RIS) ¹ *For more information about CIS or RIS, see <u>Background and Supporting Information</u>	<ul style="list-style-type: none"> • MRI Brain without contrast (CPT® 70551) OR • MRI Brain without and with contrast (CPT® 70553)

- MRI Lumbar Spine is not needed since Cervical and Thoracic studies will usually visualize the entire spinal cord. If the clinical concern is for lumbosacral radiculopathy, See **Lower Extremity Pain with Neurological Features (Radiculopathy, Radiculitis, or Plexopathy and Neuropathy) with or without Low Back (Lumbar Spine) Pain (SP-6.1)** in the Spine Imaging Guidelines
- Family members need not be screened, unless they exhibit suspicious signs or symptoms suggestive of MS.

- 3D FLAIR sequences are useful in improving lesion detection for the diagnosis and monitoring of multiple sclerosis. 3D FLAIR sequences do not require an additional CPT[®] for 3D rendering (CPT[®] 76376 and CPT[®] 76377).¹
- Quantitative Magnetic Resonance Image (MRI) Analysis of the Brain
 - Volumetric analysis of the temporal lobes and hippocampus or Neuro Quant may be ordered as 3D rendering (CPT[®] 76376 and CPT[®] 76377) or quantitative analysis of the brain (CPT[®] 0865T or CPT[®] 0866T). These studies lack sufficient specificity and sensitivity to be clinically useful in the evaluation or follow up of individuals with Multiple Sclerosis. Their use is limited to research studies and are otherwise considered to be not medically necessary in routine clinical practice.

Background and Supporting Information

- Multiple sclerosis is an autoimmune disease that is associated with inflammation, demyelination, and neurodegenerative changes within the optic nerves, brain and spinal cord (i.e. central nervous system (CNS)).
- A diagnosis of multiple sclerosis can be established after an individual has at least one clinical attack suggestive of central nervous system (CNS) demyelination with evidence of separation of space and time as well as reasonably excluding other possible conditions that could account for the clinical and imaging findings.^{1,45}
 - MRI lesions in multiple sclerosis are round or ovoid T2-hyperintense lesions that are well circumscribed and 3mm² or greater in size.
 - MRI findings that can establish dissemination of space include:
 - Involvement in two or more of the following locations:
 - ≥ 1 brainstem lesion
 - ≥ 1 juxtacortical (abutting the cortex) or cortical lesion
 - ≥ 1 periventricular lesion (abutting the ventricle)
 - ≥ 1 spinal cord lesion
 - MRI findings that can establish dissemination of time:
 - New T2-hyperintense lesion irrespective of timing
 - Presence of simultaneous enhancing and non-enhancing lesions on MRI
 - Multiple sclerosis commonly begins with a relapsing-remitting course with partial or complete neurologic recovery following attacks.
 - An acute attack lasts at least 24 hours or longer
 - Common types of MS attacks include:
 - Unilateral optic neuritis
 - Brainstem or cerebellar syndrome (i.e. trigeminal neuralgia, diplopia or intranuclear ophthalmoplegia (INO), and/or ataxia)
 - Partial transverse myelitis

- Females are more frequently diagnosed with relapsing-remitting multiple sclerosis (RRMS) compared to males.
 - Individuals are most often diagnosed during their twenties or thirties.
 - Individuals with relapsing multiple sclerosis may later transition into a more progressive phase of the disease that is characterized by insidious cognitive and/or physical decline.
- Primary progressive multiple sclerosis (PPMS) is characterized by progressive neurologic decline in the absence of acute attacks.
 - The incidence of primary progressive multiple sclerosis is equal among males and females.
 - It is often diagnosed at 45-50 years of age.
- The first event concerning for demyelinating disease without meeting criteria for separation of time is known as a clinically isolated syndrome (CIS).⁴³
 - A diagnosis of multiple sclerosis can occur when an individual with CIS has a second attack and/or develops a new lesion on MRI.
- Natural history studies and clinical trials of disease modifying therapies (DMT) have shown that individuals with CIS with characteristic MRI brain lesions carry a high risk for meeting diagnostic criteria for multiple sclerosis.⁴³
- Clinical trials of MS disease modifying therapy in CIS show that fewer individuals treated with a disease modifying therapy develop a second attack and have reduced MRI activity.⁴³
- Individuals who undergo a brain MRI for other indications (i.e. headaches, trauma, seizure) which incidentally reveals abnormalities that are characteristic for demyelination in the absence of clinical symptoms is known as radiologically isolated syndrome (RIS).^{41,43,45}
 - A diagnosis of RIS is established by the following:⁴⁵
 - Absence of a clinical attack suggestive of demyelination.
 - MRI abnormalities not related to the effects of substances (recreational drugs, toxic exposure) or other medical condition.
 - The central nervous system (CNS) MRI abnormalities cannot be accounted for by another disease process.
 - MRI white matter abnormalities associated with a vascular pattern of disease.
 - Factors associated with a higher risk for transitioning to multiple sclerosis include⁴¹
 - Younger age at diagnosis
 - Male patients
 - Individuals with spinal cord and/or brain stem lesions
 - Presence of oligoclonal bands in the cerebrospinal fluid (CSF)

- A recent randomized, placebo-controlled trial for individuals with radiologically isolated syndrome (RIS) using dimethyl fumarate showed potential benefit in delaying clinical events and MRI activity.
- Recent studies on radiologically isolated syndrome suggests that this is likely a pre-clinical phase for individuals with multiple sclerosis.
- Progressive Multifocal Leukoencephalopathy (PML) is a progressive multi-focal disease of the central nervous system that can occur in individuals with treated with immunosuppressive or immunomodulatory medications.⁴⁶
 - There is a relatively high incidence of PML in individuals treated with natalizumab although other disease modifying therapies have been associated with PML.^{1,46}
 - Increased risk of developing PML has been associated with individuals treated with natalizumab who received prior immunosuppressive medication, have a high JC virus antibody index, and/or have received natalizumab for ≥ 18 months.¹
 - More frequent MRI monitoring has been associated with lower PML lesion volume at diagnosis and a better outcome than annual monitoring.¹
 - Frequent MRI surveillance is recommended after discontinuing natalizumab due to the potential of carry-over PML that can occur.¹
 - A diagnosis of PML is established by neurological symptoms, characteristic MRI abnormalities and positive PCR for the JC virus in cerebrospinal fluid (CSF).
 - Common symptoms of PML may include but are not limited to hemiparesis, ataxia, gait disorder, visual deficits (i.e. homonymous hemianopia), and/or seizures.⁴⁶
- Sagittal MRI Spinal Cord with phased array detector coil (CPT[®] 72156 or CPT[®] 72157) is an alternative spinal imaging.
- Interferon beta medications include (but are not limited to): Avonex[®], Betaseron[®], Extavia[®], Plegridy[®], Rebif[®]
- Glatiramer acetate medications include (but are not limited to): Copaxone, Glatopa[®]
- Medications with high risks of PML as Tysabri[®] (natalizumab) and/or other CNS opportunistic infections (i.e. herpes encephalitis, cryptococcal meningitis) include (but are not limited to): Tecfidera[®] (dimethyl fumarate), Gilenya[®] (fingolimod), Tascenso[®] ODT (fingolimod), Aubagio[®] (teriflunomide), Ocrevus[®] (ocrelizumab), Kesimpta[®] (ofatumumab), Mavenclad[®] (cladribine), Mayzent[®] (siponimod), Ponvory[®] (ponesimod), Vumerity[®] (diroximel fumarate), Zeposia[®] (ozanimod), Lemtrada[®] (alemtuzumab), Bafiertam[®] (monomethyl fumarate), Briumvi[®] (ublituximab), Rituxan[®] (rituximab)

Neuromyelitis Optica and NMO Spectrum Disorders (HD-16.2)

HD.MS.0016.2.A

v3.0.2024

Initial evaluation of Neuromyelitis Optica Spectrum Disorders (NMOSD) with any of the following:

Indication	Supported Imaging
Clinical concern for optic neuritis when requested by a neurologist, neuro-ophthalmologist, ophthalmologist or any provider in consultation with a neurologist, neuro-ophthamologist, or ophthalmologist	MRI Orbit without and with contrast (CPT [®] 70543) OR MRI Orbit without contrast (CPT [®] 70540)
Recurrent hiccups or intractable nausea and/or vomiting (clinical concern for area postrema syndrome)	MRI Brain without and with contrast (CPT [®] 70553) OR MRI Brain without contrast (CPT [®] 70551)
Other neurologic signs or symptoms concerning for brain involvement ordered by a neurologist or any provider in consultation with a neurologist	MRI Brain without and with contrast (CPT [®] 70553) OR MRI Brain without contrast (CPT [®] 70551)

Indication	Supported Imaging
<p>Clinical concern for transverse myelitis when ordered by a neurologist or any provider in consultation with a neurologist</p>	<ul style="list-style-type: none"> • MRI Cervical Spine without and with contrast (CPT[®] 72156) OR • MRI Cervical Spine without contrast (CPT[®] 72141) <p>AND/OR</p> <ul style="list-style-type: none"> • MRI Thoracic Spine without and with contrast (CPT[®] 72157) OR • MRI Thoracic Spine without contrast (CPT[®] 72146) <p>AND/OR</p> <p>Due to potential for conus involvement,</p> <ul style="list-style-type: none"> • MRI Lumbar spine without and with contrast (CPT[®] 72158) OR • MRI Lumbar spine without contrast (CPT[®] 72148)
<p>Positive NMO antibody test when ordered by a neurologist or any provider in consultation with a neurologist³⁷</p>	<ul style="list-style-type: none"> • MRI Brain without and with contrast (CPT[®] 70553) OR • MRI Brain without contrast (CPT[®] 70551) <p>AND/OR</p> <ul style="list-style-type: none"> • MRI Orbit without and with contrast (CPT[®] 70543) OR • MRI Orbit without contrast (CPT[®] 70540) <p>AND/OR</p> <ul style="list-style-type: none"> • MRI Cervical Spine without and with contrast (CPT[®] 72156) OR • MRI Cervical Spine without contrast (CPT[®] 72141) <p>AND/OR</p> <ul style="list-style-type: none"> • MRI Thoracic Spine without and with contrast (CPT[®] 72157) OR • MRI Thoracic Spine without contrast (CPT[®] 72146)

Patient with established diagnosis of (NMOSD) with any of the following:

Indication	Supported Imaging
<p>Clinical concern for optic neuritis when requested by a neurologist, neuro-ophthalmologist, ophthalmologist or any provider in consultation with a neurologist, neuro-ophthalmologist, or ophthalmologist</p>	<p>MRI Orbit without and with contrast (CPT[®] 70543) OR MRI Orbit without contrast (CPT[®] 70540)</p>
<p>New neurologic signs or symptoms concerning for brain involvement when requested by a neurologist or any provider in consultation with a neurologist</p>	<p>MRI Brain without and with contrast (CPT[®] 70553) OR MRI Brain without contrast (CPT[®] 70551)</p>
<p>Clinical concern for transverse myelitis when ordered by a neurologist or any provider in consultation with a neurologist</p>	<ul style="list-style-type: none"> • MRI Cervical Spine without and with contrast (CPT[®] 72156) OR • MRI Cervical Spine without contrast (CPT[®] 72141) <p>AND/OR</p> <ul style="list-style-type: none"> • MRI Thoracic Spine without and with contrast (CPT[®] 72157) OR • MRI Thoracic Spine without contrast (CPT[®] 72146) <p>AND/OR</p> <p>Due to potential for conus involvement,</p> <ul style="list-style-type: none"> • MRI Lumbar spine without and with contrast (CPT[®] 72158) OR • MRI Lumbar spine without contrast (CPT[®] 72148)

Indication	Supported Imaging
<p>Repeat imaging may be supported for ANY of the following:</p> <ul style="list-style-type: none"> • Re-establish baseline after starting treatment (typically 3-6 months after last MRI) • Changing disease modifying therapy (DMT) • As requested when ordered by a neurologist, neuro-ophthalmologist, ophthalmologist or any provider in consultation with a neurologist, neuro-ophthalmologist or ophthalmologist³⁷ 	<ul style="list-style-type: none"> • MRI Brain without and with contrast (CPT[®] 70553) OR • MRI Brain without contrast (CPT[®] 70551) <p>AND/OR</p> <ul style="list-style-type: none"> • MRI Orbit without and with contrast (CPT[®] 70543) OR • MRI Orbit without contrast (CPT[®] 70540) <p>AND/OR</p> <ul style="list-style-type: none"> • MRI Cervical Spine without and with contrast (CPT[®] 72156) OR • MRI Cervical Spine without contrast (CPT[®] 72141) <p>AND/OR</p> <ul style="list-style-type: none"> • MRI Thoracic Spine without and with contrast (CPT[®] 72157) OR • MRI Thoracic Spine without contrast (CPT[®] 72146)

- Quantitative Magnetic Resonance Image (MRI) Analysis of the Brain
 - Volumetric analysis of the temporal lobes and hippocampus or Neuro Quant may be ordered as 3D rendering (CPT[®] 76376 and CPT[®] 76377) or quantitative analysis of the brain (CPT[®] 0865T or CPT[®] 0866T). These studies lack sufficient specificity and sensitivity to be clinically useful in the evaluation or follow up of individuals with NMOSD. Their use is limited to research studies and are otherwise considered to be not medically necessary in routine clinical practice.

Background and Supporting Information

- Neuromyelitis optica spectrum disorder (NMOSD, Devic’s disease) is a chronic inflammatory autoimmune disease that involves the optic nerves, spinal cord and brain.
- Accrual of disability occurs during acute attacks in patients with NMOSD.
 - Even after a single attack, severe permanent disability can occur, especially if the attack is not treated immediately and appropriately.
 - Unlike multiple sclerosis, it is rare for individuals with NMOSD to develop asymptomatic lesions within the brain, optic nerves and/or spinal cord.³⁴

- Diagnosis is based on the clinical presentation, MRI findings, and the presence of auto-antibodies.
- Core clinical characteristics of NMOSD include⁷
 - Optic neuritis
 - Frequently bilateral optic nerve involvement with severe vision loss
 - Long unilateral and/or bilateral lesion on MRI (more than half of the distance from the orbit to the chiasm and those involving the posterior aspects of the optic chiasm)
 - Longitudinally extensive transverse myelitis
 - ≥ 3 complete, contiguous vertebral segments of the spinal cord are involved
 - More than 70% of the lesion resides within the central gray matter of the spinal cord
 - Area postrema syndrome
 - Otherwise unexplained episode of recurrent hiccups or intractable nausea and vomiting
 - Brainstem or cerebral syndrome with NMOSD typical brain lesions⁷
 - Lesions involve periependymal surfaces of the 3rd and 4th ventricles in the brainstem and cerebellum
 - Hypothalamic or thalamic lesions
 - Large, confluent unilateral or bilateral subcortical or deep white matter lesions⁷
 - Long ($\geq 1/2$ the length of the corpus callosum) with diffuse, heterogeneous or edematous corpus callosum lesions
 - Long corticospinal tract lesions, involving unilateral or bilateral, contiguously involving internal capsule and cerebral peduncle
 - Extensive periependymal lesions, often with gadolinium enhancement
 - Rarely paraneoplastic syndromes occur with NMO spectrum disorder
 - Medications used for the treatment of NMO spectrum disorders include (but are not limited to) azathioprine, Encoring[®] (satralizumab), mycophenolate, Soliris[®] (eculizumab), rituximab³⁷, and Uplizna[®] (inebilizumab)
 - Possible adverse reactions associated with treatment include risk of PML and meningococcal infections
 - Several medications that are effective in multiple sclerosis, including interferon β , fingolimod, alemtuzumab, and natalizumab are associated with severe outcomes, including catastrophic exacerbations in patients with NMOSD.³⁵

MOG Antibody-Associated Disease (MOGAD) (HD-16.3)

HD.MS.0016.3.A

v3.0.2024

Initial evaluation of MOG (myelin oligodendrocyte glycoprotein) antibody-associated diseases (MOGAD) with any of the following:

Indication	Supported Imaging
Clinical concern for optic neuritis when requested by a neurologist, ophthalmologist or any provider in consultation with a neurologist or ophthalmologist	<ul style="list-style-type: none"> • MRI Orbit without and with contrast (CPT[®] 70543) OR • MRI Orbit without contrast (CPT[®] 70540)
Neurologic signs or symptoms concerning for brain involvement when ordered by a neurologist or any provider in consultation with a neurologist	<ul style="list-style-type: none"> • MRI Brain without and with contrast (CPT[®] 70553) OR • MRI Brain without contrast (CPT[®] 70551)
Clinical concern for transverse myelitis when ordered by a neurologist or any provider in consultation with a neurologist	<ul style="list-style-type: none"> • MRI Cervical Spine without and with contrast (CPT[®] 72156) OR • MRI Cervical Spine without contrast (CPT[®] 72141) <p>AND/OR</p> <ul style="list-style-type: none"> • MRI Thoracic Spine without and with contrast (CPT[®] 72157) OR • MRI Thoracic Spine without contrast (CPT[®] 72146) <p>AND/OR</p> <p>Due to potential for conus involvement:</p> <ul style="list-style-type: none"> • MRI Lumbar spine without and with contrast (CPT[®] 72158) OR • MRI Lumbar spine without contrast (CPT[®] 72148)

Indication	Supported Imaging
Positive MOG antibody test when ordered by a neurologist or any provider in consultation with a neurologist ³⁴	<ul style="list-style-type: none"> • MRI Brain without and with contrast (CPT[®] 70553) OR • MRI Brain without contrast (CPT[®] 70551) <p>AND/OR</p> <ul style="list-style-type: none"> • MRI Orbit without and with contrast (CPT[®] 70543) OR • MRI Orbit without contrast (CPT[®] 70540) <p>AND/OR</p> <ul style="list-style-type: none"> • MRI Cervical Spine without and with contrast (CPT[®] 72156) and MRI Thoracic Spine without and with contrast (CPT[®] 72157) <p>OR</p> <ul style="list-style-type: none"> • MRI Cervical Spine without contrast (CPT[®] 72141) and MRI Thoracic Spine without contrast (CPT[®] 72146)

Patients with established diagnosis of (MOGAD) with any of the following:

Indication	Supported Imaging
Clinical concern for optic neuritis when requested by a neurologist, ophthalmologist or any provider in consultation with a neurologist or ophthalmologist	<ul style="list-style-type: none"> • MRI Orbit without and with contrast (CPT[®] 70543) OR • MRI Orbit without contrast (CPT[®] 70540)
Neurologic signs or symptoms concerning for brain involvement when ordered by a neurologist or any provider in consultation with a neurologist	<ul style="list-style-type: none"> • MRI Brain without and with contrast (CPT[®] 70553) OR • MRI Brain without contrast (CPT[®] 70551)

Indication	Supported Imaging
<p>Clinical concern for transverse myelitis when ordered by a neurologist or any provider in consultation with a neurologist</p>	<ul style="list-style-type: none"> • MRI Cervical Spine without and with contrast (CPT[®] 72156) OR • MRI Cervical Spine without contrast (CPT[®] 72141) <p>AND/OR</p> <ul style="list-style-type: none"> • MRI Thoracic Spine without and with contrast (CPT[®] 72157) OR • MRI Thoracic Spine without contrast (CPT[®] 72146) <p>AND/OR</p> <p>Due to potential for conus involvement:</p> <ul style="list-style-type: none"> • MRI Lumbar spine without and with contrast (CPT[®] 72158) OR • MRI Lumbar spine without contrast (CPT[®] 72148)
<p>Repeat imaging may be supported for ANY of the following:</p> <ul style="list-style-type: none"> • Re-establish baseline after starting treatment (typically 3-6 months after last MRI) • Changing disease modifying therapy (DMT) • As requested when ordered by a neurologist, neuro-ophthalmologist, ophthalmologist or any provider in consultation with a neurologist, neuro-ophthalmologist or ophthalmologist³⁴ 	<ul style="list-style-type: none"> • MRI Brain without and with contrast (CPT[®] 70553) OR • MRI Brain without contrast (CPT[®] 70551) <p>AND/OR</p> <ul style="list-style-type: none"> • MRI Orbit without and with contrast (CPT[®] 70543) OR • MRI Orbit without contrast (CPT[®] 70540) <p>AND/OR</p> <ul style="list-style-type: none"> • MRI Cervical Spine without and with contrast (CPT[®] 72156) and MRI Thoracic Spine without and with contrast (CPT[®] 72157) <p>OR</p> <ul style="list-style-type: none"> • MRI Cervical Spine without contrast (CPT[®] 72141) and MRI Thoracic Spine without contrast (CPT[®] 72146)

- Acute relapse is considered when an individual with MOGAD develops new neurologic signs or symptoms at least 30 days following the onset of a previous attack.³⁴

Background and Supporting Information

- MOG (myelin oligodendrocyte glycoprotein)-IgG disorders are CNS inflammatory diseases, distinct from multiple sclerosis and NMO-spectrum disorders.
- Unlike multiple sclerosis and neuromyelitis optica spectrum disorder (NMOSD), individuals with MOG antibody-associated disease (MOGAD) can have a monophasic or relapsing course.³⁴
- Diagnosis is based on the clinical presentation, MRI findings, and the presence of auto-antibodies
- Clinical features of individuals with MOGAD include³⁴
 - Optic neuritis
 - Bilateral optic neuritis is common at onset, and seems to be more frequent in individuals with MOGAD than with those with multiple sclerosis or neuromyelitis optica spectrum disorder (NMOSD).³⁴
 - Vision returns quickly with return to normal or near normal visual acuity following treatment with intravenous corticosteroids.³⁴
 - Transverse myelitis
 - May be short segment
 - Longitudinally extensive transverse myelitis (≥ 3 vertebral segments of the spinal cord)
 - Cauda equine and peripheral nerve root involvement can occur (lumbar spine imaging is indicated)⁴⁵
 - Can occur as an isolated episode of transverse myelitis, as a component of ADEM or in conjunction with optic neuritis.³⁴
 - T2 spinal cord lesions often are centrally located and can be restricted to the grey matter producing the “H sign” on MRI
 - 20%-25% of spinal cord lesions in individuals with MOGAD do not involve the grey matter.³⁴
 - Most T2 lesions resolve or reduce in size substantially on follow up MRI
 - Brainstem encephalitis
 - Encephalitis with seizures
 - May be associated with cortical edema and leptomeningeal enhancement⁴⁵
 - Acute disseminated encephalomyelitis (ADEM)
 - Occurs mainly in children but can occur in adults.
 - Tumefactive brain lesions
 - Cranial neuropathies

Relapses are more common in the first six months after the first attack.

- Unlike multiple sclerosis and neuromyelitis optica spectrum disorder (NMOSD), individuals with MOG antibody-associated disease (MOGAD) can have a monophasic or relapsing course.³⁴

- Unlike multiple sclerosis, it is rare for individuals with MOGAD to develop asymptomatic lesions within the brain, optic nerves and/or spinal cord.³⁴
- An acute relapse is considered when an individual with MOGAD develops new neurologic signs or symptoms at least 30 days following the onset of a previous attack.
 - Relapses are more common in the first six months after the first attack.³⁴
 - New symptoms or signs in an individual with known MOGAD may include
 - Blurred vision, vision loss and/or loss of color vision
 - Motor weakness of a limb or limbs, including paraparesis or complete paralysis
 - Motor weakness may include:
 - Loss and/or worsening of manual dexterity
 - New or worsening foot drag
 - Change in sensation in a limb or limbs that may be associated with paresthesias and/or dysesthesias
 - Urinary urgency, incontinence and/or urinary retention
 - Worsening constipation and/or bowel urgency/incontinence
 - Sexual dysfunction
 - Lhermitte's phenomenon
 - New or worsening spasticity
 - New or worsening gait difficulties (i.e. spastic and/or ataxic gait) and/or sexual dysfunction
 - Seizures

Transverse Myelitis (HD-16.4)

HD.MS.0016.4.A

v3.0.2024

An initial assessment, to include a pertinent history and neurologic exam, should be performed prior to imaging requests.

Clinical Concern for Transverse Myelitis

Indication	Supported Imaging
<p>Clinical concern for transverse myelitis when ordered by a neurologist or radiologist or any provider in consultation with a neurologist or radiologist</p>	<ul style="list-style-type: none"> • MRI Cervical Spine without and with contrast (CPT[®] 72156) OR • MRI Cervical Spine without contrast (CPT[®] 72141) <p>AND/OR</p> <ul style="list-style-type: none"> • MRI Thoracic Spine without and with contrast (CPT[®] 72157) OR • MRI Thoracic Spine without contrast (CPT[®] 72146) <p>AND/OR</p> <p>Due to potential for conus involvement,</p> <ul style="list-style-type: none"> • MRI Lumbar spine without and with contrast (CPT[®] 72158) OR • MRI Lumbar spine without contrast (CPT[®] 72148) <p>AND/OR</p> <ul style="list-style-type: none"> • MRI Brain without and with contrast (CPT[®] 70553) OR • MRI Brain without contrast (CPT[®] 70551) <p>If optic neuritis is suspected*, the following imaging is ALSO indicated:</p> <ul style="list-style-type: none"> • MRI Orbit without and with contrast (CPT[®] 70543) OR • MRI Orbit without contrast (CPT[®] 70540) <p>*For additional information related to optic neuritis see Eye Disorders and Visual Loss (HD-32.1)</p>

New Neurologic Signs or Symptoms

Indication	Supported Imaging
New neurologic signs or symptoms	<ul style="list-style-type: none"> • MRI Cervical Spine without and with contrast (CPT[®] 72156) OR • MRI Cervical Spine without contrast (CPT[®] 72141) <p>AND/OR</p> <ul style="list-style-type: none"> • MRI Thoracic Spine without and with contrast (CPT[®] 72157) OR • MRI Thoracic Spine without contrast (CPT[®] 72146) <p>AND/OR</p> <ul style="list-style-type: none"> • MRI Brain without and with contrast (CPT[®] 70553) OR • MRI Brain without contrast (CPT[®] 70551) <p>If optic neuritis is suspected*, the following imaging is ALSO indicated:</p> <ul style="list-style-type: none"> • MRI Orbit without and with contrast (CPT[®] 70543) OR • MRI Orbit without contrast (CPT[®] 70540) <p>*For additional information related to optic neuritis, see <u>Eye Disorders and Visual Loss (HD-32.1)</u></p>

History of Transverse Myelitis

Indication	Supported Imaging <i>Annually for 5 years</i> ⁴⁴
Individual with a history of transverse myelitis <ul style="list-style-type: none"> Ordered by a neurologist or any provider in consultation with a neurologist 	<ul style="list-style-type: none"> MRI Cervical Spine without and with contrast (CPT[®] 72156) OR MRI Cervical Spine without contrast (CPT[®] 72141) <p>AND/OR</p> <ul style="list-style-type: none"> MRI Thoracic Spine without and with contrast (CPT[®] 72157) OR MRI Thoracic Spine without contrast (CPT[®] 72146) <p>AND/OR</p> <ul style="list-style-type: none"> MRI Brain without and with contrast (CPT[®] 70553) OR MRI Brain without contrast (CPT[®] 70551)

- Individuals with transverse myelitis present with various symptoms of sensory, motor and/or autonomic dysfunction.
 - Bilateral signs and/or symptoms (although not necessarily symmetrical)⁴²
 - Examination findings may include but are not limited to any of the following:
 - Bilateral limb weakness
 - Loss of manual dexterity
 - New or worsening foot drop
 - Sensory abnormalities
 - Sensory level
 - Hyperreflexia (including upgoing toes, positive Babinski, Hoffman’s sign, clonus)
 - Gait abnormality (spastic or ataxic gait)
 - See also: **Background and Supporting Information**
 - If inflammation is identified within the spinal cord suggestive of transverse myelitis, a brain MRI is recommended to evaluate for a multifocal inflammatory process⁴²
- See **Multiple Sclerosis (MS) (HD-16.1)**, **Neuromyelitis Optica and NMO Spectrum Disorders (HD-16.2)**, **MOG Antibody-Associated Diseases (MOGAD) (HD-16.3)**

Background and Supporting Information

- Symptoms may include but are not limited to the following:
 - Motor weakness of a limb or limbs, including paraparesis and/or complete paralysis

- Change in sensation in a limb or limbs that may be associated with paresthesias and/or dyesthesias.
- Urinary urgency, incontinence and/or urinary retention
- Worsening constipation and/or bowel urgency/incontinence
- Sexual dysfunction
- Lhermitte's sign
- New or worsening spasticity
- Acute transverse myelitis is defined as an acute inflammatory syndrome leading to motor and/or sensory impairment, with or without sphincter dysfunction, secondary to a variety of autoimmune or inflammatory diseases.⁴²
- Diagnosed by spinal MRI and/or cerebrospinal fluid.
- Individuals typically progress to maximal neurological deficits within 4 weeks.
- Longitudinally extensive transverse myelitis (≥ 3 vertebral segments) is more commonly associated with neuromyelitis optica spectrum disorders (NMOSD) and/or MOG antibody-associated diseases (MOGAD)^{34,44}
- Transverse myelitis:
 - May be idiopathic
 - Initial event of multiple sclerosis (see **Multiple Sclerosis (MS) (HD-16.1)**)
 - Initial event of neuromyelitis optica spectrum disorder (NMOSD) (see **Neuromyelitis Optica and NMO Spectrum Disorders (HD-16.2)**)
 - Initial event of MOG antibody-associated disease (MOGAD) (see **MOG Antibody-Associated Diseases (MOGAD) (HD-16.3)**)
 - May be associated with connective tissue disease
 - Systemic lupus erythematosus (SLE)
 - Rheumatoid Arthritis (RA)
 - Sjögren's syndrome
 - Systemic sclerosis
 - Manifestation of neurosarcoidosis (see **Autoimmune/Paraneoplastic Encephalitis & Neuroinflammatory Disorders (HD-14.3)**)
 - Post-infectious and/or post-vaccination related
 - COVID-19 and COVID-19 post-vaccination myelitis cases have been reported (see **Neuro-COVID-19 and Sars-COV-2 Vaccines (HD-14.2)**)
 - May have a prodromal syndrome with fever, respiratory and/or gastrointestinal symptoms⁴⁰
 - Neurologic symptoms may be associated with headache, neck stiffness or recurrence of fever⁴⁰

References (HD-16)

v3.0.2024

1. Wattjes MP, Ciccarelli O, Reich DS, et al. 2021 MAGNIMS-CMSC-NAIMS consensus recommendations on the use of MRI in patients with multiple sclerosis. *The Lancet Neurology*. 2021;20(8):653-670. doi:10.1016/S1474-4422(21)00095-8
2. Thompson AJ, Banwell BL, Barkhof F, et al. Diagnosis of multiple sclerosis: 2017 revisions of the McDonald criteria. *The Lancet Neurology*. 2018;17(2):162-173. doi:10.1016/s1474-4422(17)30470-2
3. Kaunzner UW, Gauthier SA. MRI in the assessment and monitoring of multiple sclerosis: an update on best practice. *Therapeutic Advances in Neurological Disorders*. 2017;10(6):247-261. doi:10.1177/1756285617708911
4. FDA Drug Safety Communication: New risk factor for Progressive Multifocal Leukoencephalopathy (PML) associated with Tysabri (natalizumab). Originally issued February 13, 2018. U S Food and Drug Administration Home Page. <https://www.fda.gov/drugs/drug-safety-and-availability/fda-drug-safety-communication-new-risk-factor-progressive-multifocal-leukoencephalopathy-pml>
5. Rae-Grant A, Day GS, Marrie RA, et al. Comprehensive systematic review summary: Disease-modifying therapies for adults with multiple sclerosis. *Neurology*. 2018;90(17):789-800. doi:10.1212/wnl.0000000000005345
6. Shosha E, Dubey D, Palace J, et al. Area postrema syndrome. *Neurology*. 2018;91(17). doi:10.1212/wnl.0000000000006392
7. Wingerchuk DM, Banwell B, Bennett JL, et al. International consensus diagnostic criteria for neuromyelitis optica spectrum disorders. *Neurology*. 2015;85(2):177-189. doi:10.1212/wnl.0000000000001729
8. Kaunzner UW, Gauthier SA. MRI in the assessment and monitoring of multiple sclerosis: an update on best practice. *Therapeutic Advances in Neurological Disorders*. 2017;10(6):247-261. doi:10.1177/1756285617708911
9. Expert Panel on Neurologic Imaging; Kennedy TA, Corey AS, et al. ACR Appropriateness Criteria® Orbits Vision and Visual Loss. *J Am Coll Radiol*. 2018;15(5S):S116-S131. doi:10.1016/j.jacr.2018.03.023
10. Hornby PJ. Central neurocircuitry associated with emesis. *The American Journal of Medicine*. 2001;111(8):106-112. doi:10.1016/s0002-9343(01)00849-x
11. Ciccarelli O, Cohen JA, Reingold SC, et al. Spinal cord involvement in multiple sclerosis and neuromyelitis optica spectrum disorders. *The Lancet Neurology*. 2019;18(2):185-197. doi:10.1016/s1474-4422(18)30460-5
12. Ciron J, Audoin B, Bourre B, et al. Recommendations for the use of Rituximab in neuromyelitis optica spectrum disorders. *Revue Neurologique*. 2018;174(4):255-264. doi:10.1016/j.neurol.2017.11.005
13. Rudie JD, Mattay RR, Schindler M, et al. An Initiative to Reduce Unnecessary Gadolinium-Based Contrast in Multiple Sclerosis Patients. *Journal of the American College of Radiology*. 2019;16(9):1158-1164. doi:10.1016/j.jacr.2019.04.005
14. Major EO. Progressive Multifocal Leukoencephalopathy Lesions and JC Virus. *JAMA Neurology*. 2018;75(7):789. doi:10.1001/jamaneurol.2018.0004
15. Vukusic S, Rollot F, Casey R, et al. Progressive Multifocal Leukoencephalopathy Incidence and Risk Stratification Among Natalizumab Users in France. *JAMA Neurology*. 2020;77(1):94. doi:10.1001/jamaneurol.2019.2670
16. Rae-Grant A, et al. Practice guideline: Disease-modifying therapies for adults with multiple sclerosis. . Report of the Guideline Development, Dissemination, and Implementation Subcommittee of the American Academy of Neurology. https://download.lww.com/wolterskluwer_vitalstream_com/PermaLink/WNL/A/WNL_2018_04_19_RAEGRANT_NEUROLOGY2017835181R1_SDC3.pdf
17. Wattjes MP, Barkhof F. Diagnosis of natalizumab-associated progressive multifocal leukoencephalopathy using MRI. *Current Opinion in Neurology*. 2014;27(3):260-270. doi:10.1097/wco.0000000000000099
18. Bloomgren G, Richman S, Hotermans C, et al. Risk of Natalizumab-Associated Progressive Multifocal Leukoencephalopathy. *New England Journal of Medicine*. 2012;366(20):1870-1880. doi:10.1056/nejmoa1107829
19. Hegen H, Reindl M. Recent developments in MOG-IgG associated neurological disorders. *Ther Adv Neurol Disord*. 2020 Jul 31;13:1756286420945135. doi: 10.1177/1756286420945135

20. De Stefano N, Battaglini M, Pareto D, et al. MAGNIMS recommendations for harmonization of MRI data in MS multicenter studies. *Neuroimage Clin.* 2022;34:102972. doi:10.1016/j.nicl.2022.102972
21. Reich DS, Lucchinetti CF, Calabresi PA. Multiple Sclerosis. *N Engl J Med.* 2018;378(2):169-180. doi:10.1056/NEJMr1401483
22. Lopez Chiriboga S, Flanagan EP. Myelitis and Other Autoimmune Myelopathies. *CONTINUUM: Lifelong Learning in Neurology.* 2021;27(1):62-92. doi:10.1212/con.0000000000000900
23. Genovese AV, Hagemeyer J, Bergsland N, et al. Atrophied Brain T2 Lesion Volume at MRI Is Associated with Disability Progression and Conversion to Secondary Progressive Multiple Sclerosis. *Radiology.* 2019;293(2):424-433. doi:10.1148/radiol.2019190306
24. Jakimovski D, Zivadinov R, Bergsland N, Ramasamy DP, Hagemeyer J, Genovese AV, Hojnacki D, Weinstock-Guttman B, Dwyer MG. Clinical feasibility of longitudinal lateral ventricular volume measurements on T2-FLAIR across MRI scanner changes. *Neuroimage Clin.* 2021;29:102554. doi: 10.1016/j.nicl.2020.102554
25. Saslow L, Li DKB, Halper J, et al. An International Standardized Magnetic Resonance Imaging Protocol for Diagnosis and Follow-up of Patients with Multiple Sclerosis. *International Journal of MS Care.* 2020;22(5):226-232. doi:10.7224/1537-2073.2020-094
26. Berger B, Hottenrott T, Rauer S, Stich O. Screening for onconeural antibodies in neuromyelitis optica spectrum disorders. *BMC Neurology.* 2017;17(1). doi:10.1186/s12883-016-0779-9
27. Carnero Contentti E, Correale J. Neuromyelitis optica spectrum disorders: from pathophysiology to therapeutic strategies. *Journal of Neuroinflammation.* 2021;18(1). doi:10.1186/s12974-021-02249-1
28. Juryńczyk M, Weinschenker B, Akman-Demir G, et al. Status of diagnostic approaches to AQP4-IgG seronegative NMO and NMO/MS overlap syndromes. *Journal of Neurology.* 2015;263(1):140-149. doi:10.1007/s00415-015-7952-8
29. Winkelmann A, Loebermann M, Reisinger EC, Hartung H-P, Zettl UK. Disease-modifying therapies and infectious risks in multiple sclerosis. *Nature Reviews Neurology.* 2016;12(4):217-233. doi:10.1038/nrneurol.2016.21
30. Gastaldi M, Marchioni E, Banfi P, et al. Predictors of outcome in a large retrospective cohort of patients with transverse myelitis. *Mult Scler.* 2018;24(13):1743-1752. doi:10.1177/1352458517731911
31. Lavi ES, Pal A, Bleicher D, Kang K, Sidani C. MR Imaging of the Spine: Urgent and Emergent Indications. *Semin Ultrasound CT MR.* 2018;39(6):551-569. doi:10.1053/j.sult.2018.10.006
32. Sarbu N, Lolli V, Smirniotopoulos JG. Magnetic resonance imaging in myelopathy: a pictorial review. *Clin Imaging.* 2019;57:56-68. doi:10.1016/j.clinimag.2019.05.002 29
33. Stern BJ, Royal W 3rd, Gelfand JM, et al. Definition and Consensus Diagnostic Criteria for Neurosarcoidosis: From the Neurosarcoidosis Consortium Consensus Group. *JAMA Neurol.* 2018;75(12):1546-1553. doi:10.1001/jamaneurol.2018.2295
34. Banwell B, Bennett JL, Marignier R, et al. Diagnosis of myelin oligodendrocyte glycoprotein antibody-associated disease: International MOGAD Panel proposed criteria. *Lancet Neurol.* 2023;22(3):268-282. doi:10.1016/S1474-4422(22)00431-8
35. Holmoy T, Høglund RA, Illes Z, Myhr KM, Torkildsen Ø. Recent progress in maintenance treatment of neuromyelitis optica spectrum disorder. *J Neurol.* 2021;268(12):4522-4536. doi:10.1007/s00415-020-10235-5
36. Ismail II, Salama S. Association of CNS demyelination and COVID-19 infection: an updated systematic review. *J Neurol.* 2022;269(2):541-576. doi:10.1007/s00415-021-10752-x
37. Jarius S, Aktas O, Azenberg I, et al. Update on the diagnosis and treatment of neuromyelitis optica spectrum disorders (NMOSD)- revised recommendations of the Neuromyelitis Optica Study Group (NEMOS). Part I: Diagnosis and differential diagnosis. (published online ahead of print, 2023 Apr 6). *J Neurol.* 2023;10.1007/s00415-023-11634-0. doi:10.1007/s00415-023-11634-0
38. Khan E, Shrestha AK, Colantonio MA, Liberio RN, Sriwastava S. Acute transverse myelitis following SARS-CoV-2 vaccination: a case report and review of the literature. *J Neurol.* 2022.269(3):1121-1132. doi:10.1007/s00415-021-10785-2
39. Marrodan M, Hernandez MA, Kohler AA, Correale J. Differential diagnosis in acute inflammatory myelitis. *Multi Scler Relat Disord* 2020;46:102481. doi doi:10.1016/j.msard.2020.102481
40. Murphy OC, Messacar K, Benson L, et al. Acute flaccid myelitis: cause, diagnosis, and management. *Lancet.* 2021;397(10271):334-346. doi:10.1016/S0140-6736(20)32723-9
41. Okuda DT, Kantarci O, Lebrun-Fréney C, et al. Dimethyl Fumarate Delays Multiple Sclerosis in Radiologically Isolated Syndrome. *Ann Neurol.* 2023;93(3):604-614. doi:10.1002/ana.26555

42. Transverse Myelitis Consortium Working Group. Proposed diagnostic criteria and nosology of acute transverse myelitis. *Neurology*. 2002;59(4):499-505. doi:10.1212/wnl.59.4.499
43. Lublin FD, Reingold SC, Cohen JA, et al. Defining the clinical course of multiple sclerosis: the 2013 revisions. *Neurology*. 2014;83(3):278-286. doi:10.1212/WNL.0000000000000560
44. Bulut E, Shoemaker T, Karakaya J, et al. MRI Predictors of Recurrence and Outcome after Acute Transverse Myelitis of Unidentified Etiology. *AJNR Am J Neuroradiol*. 2019;40(8):1427-1432. doi:10.3174/ajnr.A6121
45. Tillema JM. Imaging of Central Nervous System Demyelinating Disorders. *Continuum (Minneapolis)*. 2023;29(1):292-323. doi:10.1212/CON.0000000000001246
46. Kartau M, Sipilä JO, Auvinen E, Palomäki M, Verkkoniemi-Ahola A. Progressive Multifocal Leukoencephalopathy: Current Insights. *Degener Neurol Neuromuscul Dis*. 2019;9:109-121. Published 2019 Dec 2. doi:10.2147/DNND.S203405

Papilledema/Pseudotumor Cerebri (HD-17)

Guideline

Papilledema/Pseudotumor Cerebri (HD-17.1)
References (HD-17)

Papilledema/Pseudotumor Cerebri (HD-17.1)

HD.PP.0017.1.A

v3.0.2024

- See **Eye Disorders and Visual Loss (HD-32.1)**
- Papilledema and Pseudotumor Cerebri (Idiopathic Intracranial Hypertension):
 - MRI Orbits/Face/Neck without contrast (CPT[®] 70540) **OR** MRI Orbits/Face/Neck without and with contrast (CPT[®] 70543) **OR** CT Orbits/Temporal bone with contrast (CPT[®] 70481) **OR** CT Orbit/Temporal bone without contrast (CPT[®] 70480) **AND/OR** MRI Brain without contrast (CPT[®] 70551) **OR** MRI Brain with and without contrast (CPT[®] 70553):
 - Suspected elevated intracranial pressure **AND/OR** papilledema
 - CT Head without contrast (CPT[®] 70450) can be approved when MRI is contraindicated or for urgent evaluation
 - See **General Guidelines – CT Head (HD-1.4)** regarding required use of CT Head prior to lumbar puncture and/or spinal tap.
 - See **Eye Disorders and Visual Loss (HD-32.1)** regarding concern for orbital pseudotumor or primary orbital disorder.
 - Repeat imaging to evaluate either:
 - Shunt dysfunction in those individuals who have had ventriculoperitoneal (VP) or lumboperitoneal (LP) shunts (See **Hydrocephalus Shunts (HD-11.14)**)
 - Clinical deterioration (with worsening or new neurological signs and symptoms)
 - MRA Head (CPT[®] 70544, CPT[®] 70545, or CPT[®] 70546) or CTA Head (CPT[®] 70496) may be added for venogram when requested.²
 - CT and MR Venography (CTV and MRV) are reported with the same codes as the CTA/MRA counterpart. If arterial and venous CT or MR studies are both performed in the same session, only one CPT[®] code should be used to report both procedures
 - See **Stroke/TIA (HD-21.1)**

References (HD-17)

HD.PP.0017.2.A

v3.0.2024

1. Friedman DI. Papilledema and Idiopathic Intracranial Hypertension. CONTINUUM: Lifelong Learning in Neurology. 2014;20:857-876. doi:10.1212/01.con.0000453314.75261.66
2. Expert Panel on Neurologic Imaging, Whitehead MT, Cardenas AM, et al. ACR Appropriateness Criteria® Headache. J Am Coll Radiol. 2019;16(11S):S364-S377. doi:10.1016/j.jacr.2019.05.030
3. Thurtell MJ. Idiopathic Intracranial Hypertension. CONTINUUM: Lifelong Learning in Neurology. 2019;25(5):1289-1309. doi:10.1212/con.0000000000000770
4. Wall M. Update on Idiopathic Intracranial Hypertension. *Neurologic Clinics*. 2017;35(1):45-57. doi:10.1016/j.ncl.2016.08.004
5. Costello F, Scott JN. Imaging in Neuro-ophthalmology. CONTINUUM: Lifelong Learning in Neurology. 2019;25(5):1438-1490. doi:10.1212/con.0000000000000783
6. Aylward SC, Reem RE. Pediatric Intracranial Hypertension. *Pediatr Neurol*. 2017 Jan;66:32-43. doi: 10.1016/j.pediatrneurol.2016.08.010

Paresthesias and/ or Weakness (HD-18)

Guideline

Sensory/Weakness Complaints (HD-18.1)

References (HD-18)

Sensory/Weakness Complaints (HD-18.1)

HD.PS.0018.1.A
v3.0.2024

Advanced imaging for complaints of sensory loss and/or paresthesias (see **Background and Supporting Information**) and/or weakness that are unaccompanied by other symptoms and not preceded by trauma must have the following: a thorough clinical history and a detailed neurological exam (including the symptomatic area).

Imaging for sensory and weakness complaints may be indicated with the following findings:

Findings Specific to the Brain and/or Spinal Cord	Supported Imaging
<p>ANY of the following:</p> <ul style="list-style-type: none"> • Hyperreflexia • Babinski/Hoffman sign* • Increased tone in affected limb • Bladder and/or bowel dysfunction⁴ • Motor symptoms in ANY of the following patterns: <ul style="list-style-type: none"> ◦ Two limbs on same side of body ◦ Face and limb involvement • Sensory symptoms in ANY of the following patterns: <ul style="list-style-type: none"> ◦ Two limbs on same side of body ◦ Face and limb involvement <p>*See Background and Supporting Information</p>	<ul style="list-style-type: none"> • MRI Brain without contrast (CPT[®] 70551) OR • MRI Brain without and with contrast (CPT[®] 70553) <p>AND/OR</p> <ul style="list-style-type: none"> • MRI Cervical Spine without contrast (CPT[®] 72141) OR • MRI Cervical Spine without and with contrast (CPT[®] 72156) <p>AND/OR</p> <ul style="list-style-type: none"> • MRI Thoracic Spine without contrast (CPT[®] 72146) OR • MRI Thoracic Spine without and with contrast (CPT[®] 72157)

Findings Specific to the Spinal Cord	Supported Imaging
<p>ANY of the following:</p> <ul style="list-style-type: none"> • Decreased pinprick sensation on one side of the body with weakness and decreased proprioception on the other side • Sensory level (also called spinal cord level) on the trunk with sensory loss in both legs • Tight band around the trunk or torso⁴ • Pure sensory symptoms with proximal and distal involvement and a symmetric pattern • Decreased or absent reflexes AND noted concern for spinal cord shock or acute spinal cord injury*⁴ <p>*See Background and Supporting Information</p>	<ul style="list-style-type: none"> • MRI Cervical Spine without contrast (CPT[®] 72141) OR • MRI Cervical Spine without and with contrast (CPT[®] 72156) <p>AND/OR</p> <ul style="list-style-type: none"> • MRI Thoracic Spine without contrast (CPT[®] 72146) OR • MRI Thoracic Spine without and with contrast (CPT[®] 72157)

Findings Specific to the Terminal End of the Spinal Cord	Supported Imaging
<p>Concern for conus medullaris syndrome.*</p> <ul style="list-style-type: none"> • Symptoms may include, but are not limited to: <ul style="list-style-type: none"> ◦ Saddle anesthesia ◦ Urinary retention ◦ Bowel incontinence ◦ Lower limb paresthesias ◦ Lower limb weakness <p>*See Background and Supporting Information</p>	<ul style="list-style-type: none"> • MRI Lumbar Spine without contrast (CPT[®] 72148) OR • MRI Lumbar Spine without and with contrast (CPT[®] 72158)

- MRI Lumbar Spine is not typically indicated to visualize the spinal cord except in the clinical scenarios noted above. MRI Cervical Spine and MRI Thoracic Spine will image the entire spinal cord.
- Findings NOT consistent with central nervous system localization and NOT supporting brain or spinal cord imaging include:
 - Sensory loss that involves the hands and feet and not the trunk
 - Limb pain
- For symptoms after trauma, refer to **Head Trauma (HD-13.1)** and/or the appropriate level in the Spine Imaging Guidelines
- For generalized weakness, polyneuropathy, and/or other patterns of sensory and/or motor symptoms not referenced above, refer to the following guidelines:
 - Myopathy or myositis, see **Muscle Diseases (PN-6.2)** and **Gaucher Disease (Storage Disorders) (PN-6.3)**
 - Motor Neuron Disease or Amyotrophic Lateral Sclerosis (ALS), see **Motor Neuron Disease/Amyotrophic Lateral Sclerosis (ALS) (PN-8.1)**
 - Neuromuscular Junction Disorders, see **Neuromuscular Junction Disorders (PN-6.1)**
 - Multifocal Motor Neuropathy (MMN) and Chronic Inflammatory Demyelinating Polyneuropathy (CIDP), see **Polyneuropathy (PN-3.1)**
 - Polyneuropathy, see **Polyneuropathy (PN-3.1)**
 - Neuropathy with concern for malignancy, see **Paraneoplastic Syndromes (ONC-30.3)** in the Oncology Imaging Guidelines
 - Proximal asymmetric and concern for plexopathy, see **Brachial Plexus (PN-4.1)** and/or **Lumbar and Lumbosacral Plexus (PN-5.1)**
 - Sensory and/or motor symptoms localized to a single nerve, see **Focal Neuropathy (PN-2.1)**
 - Thoracic Outlet Syndrome, see **Thoracic Outlet Syndrome (CH-31.1)** in the Chest Imaging Guidelines
 - Radiculopathy, see appropriate level in the Spine Imaging Guidelines
 - Cauda Equina Syndrome, see **Red Flag Indications (SP-1.2)** in the Spine Imaging Guidelines

Background and Supporting Information

- Paresthesia refers to an abnormal sensation that is associated with nervous system dysfunction and may be described as a tingling, pricking, pins and needles, or a burning sensation. The priority is to determine whether the etiology is due to pathology of the peripheral nervous system (PNS) or central nervous system (CNS).
- A thorough clinical history, including symptom location and time course, can be helpful to differentiate PNS pathologies from CNS. For example, paresthesia affecting one side of the face and/or body (i.e. hemisensory deficit) points strongly towards

central nervous system dysfunction. Therefore, brain and/or spinal cord imaging may be supported based on the location of symptoms. Typically, lumbar spine imaging is not supported unless there is sphincter involvement, saddle anesthesia, and/or cauda equina syndrome is suspected. In contrast, an insidious course of distal, symmetric limb paresthesia is more commonly associated with peripheral nerve abnormalities. In such cases, NCS/EMG testing results should be completed prior to advanced imaging. (See **Peripheral Nerve Imaging Guidelines**).

- Upper motor neuron signs (e.g. increased tone, hyperreflexia, presence of Babinski or Hoffman signs) may support a need for central nervous system imaging.
- Lower motor neuron signs (e.g. decreased tone, hypo- or areflexia, muscle atrophy) may support evaluation for peripheral nervous system diseases. Nerve conduction and needle EMG testing should be completed prior to advanced imaging.
- It is important to note that both peripheral and central nervous system disease can co-exist. As a result, if both upper and lower motor neuron signs are observed simultaneously, advanced imaging may be supported regardless of NCS/EMG testing results (see **Polyneuropathy (PN-3.1)** in the Peripheral Nerve Disorders (PND) Imaging Guidelines).
- Babinski sign - presence of an upgoing big toe with stimulation of the lateral plantar region of the foot.¹⁴
- Hoffman sign - involuntary flexion of the fingers, particularly the thumb and index fingers, triggered by flicking the distal segment of the middle finger.¹⁴
- Spinal cord shock/acute spinal cord injury - occurs after hyperacute or acute injury to the cord and presents with flaccid areflexia below the level of injury. May be associated with hypotension and/or bradycardia if loss of sympathetic tone occurs. Signs may last from days to weeks before upper motor neuron findings develop.⁴
- Conus Medullaris Syndrome - compressive damage to the spinal cord from T12-L2. Symptoms suggestive of conus medullaris syndrome include saddle anesthesia, urinary retention, bowel incontinence, and/or lower extremity motor or sensory changes.¹³

References (HD-18)

HD.PS.0018.2.A

v3.0.2024

1. Paresthesia Information Page. National Institute of Neurological Disorders and Stroke. <https://www.ninds.nih.gov/Disorders/All-Disorders/Paresthesia-Information-Page>
2. Levin MC, By, Professional.Manuals.TopicPage.LastRevisionDate| Content last modified Jan 2019. Numbness - Neurologic Disorders. Merck Manuals Professional Edition. <https://www.merckmanuals.com/professional/neurologic-disorders/symptoms-of-neurologic-disorders/numbness>
3. London ZN. A Structured Approach to the Diagnosis of Peripheral Nervous System Disorders. CONTINUUM: Lifelong Learning in Neurology. 2020;26(5):1130-1160. doi:10.1212/con.0000000000000922
4. Hardy TA. Spinal Cord Anatomy and Localization. CONTINUUM: Lifelong Learning in Neurology. 2021;27(1):12-29. doi:10.1212/con.0000000000000899
5. Larson ST and Wilbur J. Muscle Weakness in Adults: Evaluation and Differential Diagnosis. Am Fam Physician. 2020;101(2):95-108
6. Filippakis A, Jara J, Ventura N, Scala S, Scopa C, Ruthazer R, Karakis I, Srinivasan J, Russell JA, Ho DT. A prospective study of benign fasciculation syndrome and anxiety. Muscle & nerve. 2018 Dec;58(6):852-4
7. Callaghan BC, Price RS, Feldman EL. Distal Symmetric Polyneuropathy. JAMA. 2015;314(20):2172. doi:10.1001/jama.2015.13611
8. Hughes R. Investigation of peripheral neuropathy. BMJ. 2010;341(nov05 1):c6100-c6100. doi:10.1136/bmj.c6100.6
9. Campbell WW. DeJong's The Neurologic Examination, 7th ed, Lippincott Williams & Wilkins, Philadelphia 2013
10. Wattjes MP, Ciccarelli O, Reich DS, et al. 2021 MAGNIMS-CMSC-NAIMS consensus recommendations on the use of MRI in patients with multiple sclerosis. The Lancet Neurology. 2021;20(8):653-670. doi:10.1016/S1474-4422(21)00095-8
11. Roth CJ, Angevine PD, Aulino JM, et. al. Expert Panel on Neurologic Imaging. ACR Appropriateness Criteria®: Myelopathy. American College of Radiology (ACR); Date of Origin: 1996. Last Review: 2020. <https://acsearch.acr.org/docs/69484/Narrative/>
12. Bykowski J, Aulino JM, Berger KL, et al. (2016). ACR Appropriateness Criteria® Plexopathy. American College of Radiology (ACR).
13. Rider LS, Marra EM. Cauda Equina and Conus Medullaris Syndromes. 2022 Aug 8. In: StatPearls [Internet]. Treasure Island (FL): StatPearls Publishing; 2023 Jan-.
14. Shahrokhi M, Asuncion RMD. Neurologic Exam. 2023 Jan 16. In: StatPearls [Internet]. Treasure Island (FL): StatPearls Publishing; 2023 Jan-.

Pituitary (HD-19)

Guideline

Pituitary (HD-19.1)

Post-Operative and Repeat Imaging Indications (HD-19.2)

Empty Sella Turcica (HD-19.3)

Craniopharyngioma and Other Hypothalamic/Pituitary Region Tumors (HD-19.4)

References (HD-19)

Pituitary (HD-19.1)

HD.PT.0019.1.A

v3.0.2024

- Endocrine laboratory studies should be performed prior to considering advanced imaging, except in the cases of stable, non-functioning microadenomas or macroadenomas, cysts and/or for incidentally found lesions.
- MRI Brain without and with contrast (CPT[®] 70553) or MRI Brain without contrast (CPT[®] 70551) with a specific pituitary protocol that includes fine cuts through the sella is the primarily performed pituitary imaging:
 - MRI Orbit/Face/Neck without and with contrast (CPT[®] 70543) or CT Head without and with contrast (CPT[®] 70470) are alternatives
 - CT Head without contrast (CPT[®] 70450) or without and with contrast (CPT[®] 70470) **AND/OR** CT Maxillofacial without contrast (CPT[®] 70486) in addition to MRI to visualize perisellar bony structures in the pre-operative evaluation of certain sellar tumors and for pre-operative planning for transphenoidal approaches
 - See **General Guidelines – Anatomic Issues (HD-1.1)** as CT Temporal bone (CPT[®] 70480) is supported instead of CT Maxillofacial per surgeon's preference and contrast level
 - CTA Head (CPT[®] 70496) or MRA Head (CPT[®] 70544, CPT[®] 70545, or CPT[®] 70546) for surgical planning
 - MRI Brain without and with contrast (CPT[®] 70553) covers both brain and dedicated pituitary if performed at the same time; no additional CPT[®] codes are needed
- Repeat imaging for incidentally found lesions on other studies:
 - MRI Brain without and with contrast (CPT[®] 70553) or MRI Orbit/Face/Neck without and with contrast (CPT[®] 70543) follow-up dedicated pituitary study obtained if a pituitary abnormality is reported incidentally on a MRI Brain or CT Head performed for other reasons (MRI Brain without and with contrast [CPT[®] 70553] covers both brain and dedicated pituitary if performed at the same time; no additional CPT[®] codes are needed); further evaluation and subsequent imaging dependent on specific imaging and biochemical laboratory evaluation findings.
- Repeat Imaging in the setting of worsening clinical status or new neurologic symptoms
- See **Secondary Amenorrhea (PV-3.1)** in the Pelvic Imaging Guidelines for initial lab and imaging work up to exclude other causes. See Female Hypogonadism or Prolactinoma or other relevant sections in the grid if suspicion for pituitary tumor/disease.

Pituitary Imaging

Indication	Initial Imaging	Repeat Imaging
<p>Microadenoma: Nonfunctioning, unexplained pituitary asymmetries, or incidentally found small tumors (<10 mm)</p>	<ul style="list-style-type: none"> MRI Brain without and with contrast (CPT[®] 70553) or MRI Brain without contrast (CPT[®] 70551) 	<ul style="list-style-type: none"> MRI Brain without and with contrast (CPT[®] 70553) or MRI Brain without contrast (CPT[®] 70551) at 12 months and then (if stable in size), every 1-2 years for 3 years, and less frequently thereafter based on clinical status
<p>Macroadenoma (≥10 mm): Nonfunctioning and/or not surgically removed including those with a post-operative remnant</p>	<ul style="list-style-type: none"> MRI Brain without and with contrast (CPT[®] 70553) or MRI Brain without contrast (CPT[®] 70551) 	<ul style="list-style-type: none"> MRI Brain without and with contrast (CPT[®] 70553) or MRI Brain without contrast (CPT[®] 70551) every 6 months for the first year and then (if stable in size), every year for 3 years, and less frequently thereafter based on clinical status (longer if craniopharyngioma)
<p>Acromegaly* (Elevated IGF-1 confirmed by lack of suppression of growth hormone on glucose suppression testing)</p>	<ul style="list-style-type: none"> MRI Brain without and with contrast (CPT[®] 70553) or MRI Brain without contrast (CPT[®] 70551) 	<ul style="list-style-type: none"> MRI Brain without and with contrast (CPT[®] 70553) or MRI Brain without contrast (CPT[®] 70551) <ul style="list-style-type: none"> At least 12 weeks after surgery to evaluate for residual tumor If treated with Pegvisomant, 6 to 12 months after treatment initiated, then annually if stable Long-term follow-up imaging based on clinical and biochemical status at the request of a specialist or any provider in consultation with a specialist

Indication	Initial Imaging	Repeat Imaging
<p>Cushing’s Disease** (Pituitary ACTH excess leading to hypercortisolism)</p>	<ul style="list-style-type: none"> • MRI Brain without and with contrast (CPT[®] 70553) or MRI Brain without contrast (CPT[®] 70551) 	<ul style="list-style-type: none"> • MRI Brain without and with contrast (CPT[®] 70553) or MRI Brain without contrast (CPT[®] 70551) <ul style="list-style-type: none"> ◦ At least 12 weeks after surgery as new baseline ◦ Annually after bilateral adrenalectomy for Cushing’s disease or ectopic ACTH production ◦ Long-term follow-up imaging based on clinical and biochemical status at the request of a specialist or any provider in consultation with a specialist
<p>Rathke’s cleft cyst/ Simple cyst</p>	<ul style="list-style-type: none"> • MRI Brain without and with contrast (CPT[®] 70553) or MRI Brain without contrast (CPT[®] 70551) 	<ul style="list-style-type: none"> • MRI Brain without and with contrast (CPT[®] 70553) or MRI Brain without contrast (CPT[®] 70551) in one year; if stable and without mass effect or invasion into surrounding structures, no further imaging is required.

Indication	Supported Imaging
<p>Prolactinomas***</p>	<ul style="list-style-type: none"> • MRI Brain without and with contrast (CPT[®] 70553) or MRI Brain without contrast (CPT[®] 70551) with: <ul style="list-style-type: none"> ◦ Diagnosis: <ul style="list-style-type: none"> ▪ Unexplained prolactin level above the normal range ◦ On Dopamine Agonist (DA) therapy with good response: <ul style="list-style-type: none"> ▪ Macroadenomas 3 months after start of DA therapy ▪ Microadenomas 1 year after start of DA therapy ▪ To decide on stoppage of therapy after ~2 years if in “remission” (normal PRL and no visible tumor on MRI) ◦ On Dopamine Agonist therapy with suboptimal response: <ul style="list-style-type: none"> ▪ PRL levels rise ▪ New symptoms develop (galactorrhea, vision changes, headaches, pituitary deficiency) ▪ If on high dose maximal DA and no plans for surgery/radiation therapy use guideline for microadenoma or macroadenoma ◦ After Dopamine Agonist therapy: <ul style="list-style-type: none"> ▪ Rise in PRL level ▪ For DA stoppage at menopause, use guideline for microadenoma or macroadenoma ◦ Not on therapy – refer to recommendations for repeat imaging for microadenoma or macroadenoma ◦ Galactorrhea/nipple discharge with normal prolactin and thyroid function levels: See <u>Nipple Discharge/ Galactorrhea (BR-6.1)</u> in the Breast Imaging Guidelines
<p>Medication-induced Prolactinemia****</p>	<ul style="list-style-type: none"> • To differentiate between medication-induced hyperprolactinemia and hyperprolactinemia due to a pituitary or hypothalamic mass if the medication cannot be discontinued or hyperprolactinemia persists after medication discontinuation²²

Indication	Supported Imaging
<p>TSH, FSH, or LH producing adenomas (inappropriate pituitary hypersecretion of TSH, FSH or LH)*****</p>	<ul style="list-style-type: none"> • MRI Brain without and with contrast (CPT[®] 70553) or MRI Brain without contrast (CPT[®] 70551) when hormone levels are inappropriately elevated and there is a concern for a pituitary lesion. • Refer to appropriate post-operative, or Microadenoma/Macroadenoma guidelines based on the size of the lesion and initial management. <ul style="list-style-type: none"> ◦ Long-term follow-up imaging based on clinical and biochemical status at the request of a specialist or any provider in consultation with a specialist
<p>Male Hypogonadism*****</p>	<ul style="list-style-type: none"> • MRI Brain without and with contrast (CPT[®] 70553) or MRI Brain without contrast (CPT[®] 70551) if ONE of the following: <ul style="list-style-type: none"> ◦ Severe secondary hypogonadism (as indicated by morning serum testosterone level <150 ng/dl and low or normal LH and FSH levels) (See Background and Supporting Information) ◦ Below normal testosterone level (serum total testosterone, free testosterone and/or bioavailable morning testosterone) AND low or normal LH and FSH levels, in an individual with either: <ul style="list-style-type: none"> ▪ Panhypopituitarism ▪ Hyperprolactinemia ▪ Signs of tumor mass effect (headache, visual impairment, or visual field deficit) ▪ Elevated sex hormone binding globulin (SHBG)
<p>Female Hypogonadism (Secondary Amenorrhea may be a feature)²⁵</p>	<ul style="list-style-type: none"> • MRI Brain without and with contrast (CPT[®] 70553) or MRI Brain without contrast (CPT[®] 70551) for normal or low FSH with low estradiol (LH may be normal or low also)

Indication	Supported Imaging
<p>Growth Hormone Deficiency (Adult onset)²⁵</p>	<p>MRI Brain without and with contrast (CPT[®] 70553) or MRI Brain without contrast (CPT[®] 70551) for the following:</p> <ul style="list-style-type: none"> • Low Growth Hormone (GH) <p>OR</p> <ul style="list-style-type: none"> • Low IGF-1 <p>AND</p> <ul style="list-style-type: none"> • One abnormal provocative test (likely will be Glucagon Stimulation test as GNRH is unavailable and Insulin Tolerance test poses risks) • If 3 or more pituitary hormones are deficient (including GH), then provocative test is not needed.
<p>Secondary (Central) Adrenal Insufficiency²⁵</p>	<p>MRI Brain without and with contrast (CPT[®] 70553) or MRI Brain without contrast (CPT[®] 70551) for the following:</p> <ul style="list-style-type: none"> • ACTH is low or normal at 10 or lower <p>AND</p> <ul style="list-style-type: none"> • Low baseline cortisol level < 3 µg/dL <p>OR</p> <ul style="list-style-type: none"> • abnormal ACTH stimulation test with suboptimal cortisol stimulation where cortisol does not reach above 18 µg/dL
<p>Central Hypothyroidism²⁵</p>	<ul style="list-style-type: none"> • MRI Brain without and with contrast (CPT[®] 70553) or MRI Brain without contrast (CPT[®] 70551) for the following: <ul style="list-style-type: none"> ◦ Low free T4 with normal, low or mildly elevated TSH
<p>Hypopituitarism (deficiency of one or more pituitary hormones)</p>	<ul style="list-style-type: none"> • MRI Brain without and with contrast (CPT[®] 70553) or MRI Brain without contrast (CPT[®] 70551)

Indication	Initial Imaging	Repeat Imaging for Non-Operative Care
Diabetes Insipidus (DI) - ADH Deficiency	<ul style="list-style-type: none"> MRI Brain without and with contrast (CPT[®] 70553) or MRI Brain without contrast (CPT[®] 70551) if: <ul style="list-style-type: none"> Laboratory testing consistent with DI (serum osmolality should be high and urine osmolality should be low) and etiology uncertain 	NA
Syndrome of Inappropriate ADH (SIADH)	<ul style="list-style-type: none"> MRI Brain without and with contrast (CPT[®] 70553) or MRI Brain without contrast (CPT[®] 70551) if: <ul style="list-style-type: none"> Etiology remains uncertain or is thought to be in the nervous system; Urine osmolality should be high and serum osmolality low 	NA
Other Pituitary Region Tumors	<ul style="list-style-type: none"> Evaluation may require CT in addition to MRI to evaluate for hyperostosis. 	

Background and Supporting Information

- ***Acromegaly:** A serum level of growth hormone greater than 1ng/mL when measured two hours following an oral glucose load confirms acromegaly.
- ****Cushing's Disease:** It is important to differentiate Cushing's syndrome (hypercortisolism from any source) from Cushing's disease which is ACTH hypersecretion from the pituitary gland. Hypercortisolism is quantified by 24hour urine cortisol collection, low dose dexamethasone suppression test and/or late night salivary cortisol measurement. ACTH is elevated or inappropriately normal in Cushing's disease and ectopic sources of ACTH production, but suppressed in other causes of hypercortisolism²⁶. A high dose dexamethasone suppression test can help determine if the elevated ACTH is from a pituitary or ectopic source. Petrosal sinus sampling may be required for tumor localization pre-operatively in the setting of a normal pituitary MRI or a small adenoma. These tumors may be managed with surgery, medical therapy, radiation and/or bilateral adrenalectomy.
- *****Prolactinoma:** To establish the diagnosis of hyperprolactinemia, a single measurement of serum prolactin is recommended; a level above the upper limit of normal confirms the diagnosis as long as the serum sample was obtained without excessive venipuncture stress. Pregnancy and primary hypothyroidism should be excluded as physiologic causes of prolactin elevation and medications that may be contributing to prolactin elevation should be considered. Dopamine agonist therapy

is typically stopped during pregnancy, monitoring of prolactin levels ceases. Routine imaging surveillance during pregnancy is not recommended due to risk to fetus. Repeat imaging with MRI without gadolinium can be performed however for new or worsening symptoms, such as headaches or visual symptoms.

- **** **Medication-induced prolactin elevation:** Medication induced hyperprolactinemia is seen most commonly with antipsychotics/neuroleptics and antidepressants, but may also be seen with some anti-emetics and antihypertensive agents. In individuals on prolactin elevating drugs, a prolactin level should be repeated after withdrawal of medications for 72 h, however, this approach may not be safe if this treatment is offered for psychiatric indications. If stopping the drug is not feasible, pituitary MRI is advised to rule out a sellar/parasellar tumor.²²
- *******TSH, FSH, or LH producing adenomas:** These are the least common of all hormonally active pituitary tumors. Individuals with TSH secreting adenomas have inappropriate TSH elevation in the setting of hyperthyroidism (elevated thyroid hormone levels). Almost all gonadotroph adenomas are clinically non-functioning. The infrequent presentation of a functioning gonadotroph adenoma should be differentiated clinically from appropriate FSH and LH elevation seen in low estrogen states (including menopause) as well as primary hypogonadism (testicular failure). Functioning TSH, FSH or LH pituitary adenomas may be managed with surgical, radiation and/or medical therapies.
- *******Male Hypogonadism:** Alterations in sex hormone-binding globulin (SHBG) can impact testosterone levels. Free or bioavailable testosterone concentrations should be measured when total testosterone concentrations are close to the lower limit of the normal range and when altered SHBG levels are suspected (e.g. moderate obesity, nephrotic syndrome, hypo- and hyperthyroidism, use of glucocorticoids, progestins, estrogens, and androgenic steroids, anticonvulsants, acromegaly, diabetes mellitus, aging, HIV disease, liver cirrhosis, hepatitis). LH and FSH should be obtained to evaluate for secondary (central) hypogonadism, once low testosterone level is confirmed. Morning testosterone level is drawn anytime before 10 am for a typical sleep-wake cycle.
- Central hypothyroidism is an anatomic or functional disorder of the pituitary gland or the hypothalamus, resulting in altered TSH secretion. Diagnosis is usually made biochemically with low circulating free T4 (FT4) concentrations associated with low/normal serum TSH levels.²⁴

Post-Operative and Repeat Imaging Indications (HD-19.2)

HD.PT.0019.2.A

v3.0.2024

- For imaging in the immediate post-operative period or for acute surgical complications
 - See **Primary Central Nervous System Tumors (ONC-2.1)** in the Oncology Imaging Guidelines.
- A routine post-operative MRI is generally done at 3 months and/or at the discretion of, or in consultation with an Endocrinologist, Neurologist, Neurosurgeon, ENT, Ophthalmologist, Neuro-Ophthalmologist or Radiation Oncologist.
- Frequency of follow-up imaging depends on the post-operative size and/or functional status of the pituitary adenoma. Refer to the grid sections for Microadenoma/ Macroadenoma as well as those for disorders of pituitary hormone excess.
- Individuals with hyper-functioning tumors such as acromegaly, Cushing's disease, and excess TSH secretion may be treated with a combination of surgery, medical therapy and radiation. Long-term monitoring of clinical status and repeat imaging at the discretion of, or in consultation with an Endocrinologist, Neurologist, Neurosurgeon, ENT, Ophthalmologist, Neuro-Ophthalmologist or Radiation Oncologist.

Empty Sella Turcica (HD-19.3)

HD.DPT.0019.3.A

v3.0.2024

- Enlarged/Empty Sella Turcica: An enlarged sella turcica without evident tumor is an incidental finding on MRI Brain or CT Head from a defect in the dural diaphragm of the sella (especially if there is elevated intracranial pressure from another cause), pituitary surgery, or as a result of a pituitary tumor which has expanded the sella and then infarcted (pituitary apoplexy).
- MRI Brain with and without contrast (pituitary protocol) (CPT[®] 70553) with thin sections of pituitary or MRI Brain without contrast (CPT[®] 70551) is supported. CT Head with and without contrast (CPT[®] 70470) – If MRI is contraindicated.
 - Primary Empty Sella:
 - Incidentally found on other studies, asymptomatic and no related abnormalities: follow up at 2 years. No further imaging unless clinical symptoms develop (neuro-/ophthalmological symptoms, intracranial hypertension, or endocrine/hormonal abnormalities).
 - Following medical or surgical treatment of related endocrine, neurological, or ophthalmological problems: follow-up imaging every 6 months in the year after treatment and/or at the request of a specialist or any provider in consultation with a specialist (see **Papilledema/Pseudotumor Cerebri (HD-17.1)** for additional imaging recommendations)
 - Secondary Empty Sella
 - Imaging according to the cause or if clinical disease progression (such as adenomas, infiltrative or malignant disorders, hormonal abnormalities, neuro-/ophthalmological symptoms)

Craniopharyngioma and Other Hypothalamic/Pituitary Region Tumors (HD-19.4)

HD.DPT.0019.4.A

v3.0.2024

- See Craniopharyngioma and Other Hypothalamic/Pituitary Region Tumors (PEDONC-4.10)

References (HD-19)

v3.0.2024

1. American Association of Clinical Endocrinologists Medical Guidelines for Clinical Practice for the Evaluation and Treatment of Hypogonadism in Adult Male Patients—2002 Update. *Endocrine Practice*. 2002;8(6):439-456. doi:10.4158/ep.8.6.439
2. Katznelson L, Laws ER, Melmed S, et al. Acromegaly: An Endocrine Society Clinical Practice Guideline. *The Journal of Clinical Endocrinology & Metabolism*. 2014;99(11):3933-3951. doi:10.1210/jc.2014-2700
3. Melmed S, Casanueva FF, Hoffman AR, et al. Diagnosis and Treatment of Hyperprolactinemia: An Endocrine Society Clinical Practice Guideline. *The Journal of Clinical Endocrinology & Metabolism*. 2011;96(2):273-288. doi:10.1210/jc.2010-1692
4. Hoang JK, Hoffman AR, González RG, et al. Management of Incidental Pituitary Findings on CT, MRI, and 18 F-Fluorodeoxyglucose PET: A White Paper of the ACR Incidental Findings Committee. *Journal of the American College of Radiology*. 2018;15(7):966-972. doi:10.1016/j.jacr.2018.03.037
5. Marinis LD, Bonadonna S, Bianchi A, Maira G, Giustina A. Primary Empty Sella. *The Journal of Clinical Endocrinology & Metabolism*. 2005;90(9):5471-5477. doi:10.1210/jc.2005-0288
6. Chiloiro S, Giampietro A, Bianchi A, et al. DIAGNOSIS OF ENDOCRINE DISEASE: Primary empty sella: a comprehensive review. *European Journal of Endocrinology*. 2017;177(6). doi:10.1530/eje-17-0505
7. Freda PU, Beckers AM, Katznelson L, et al. Pituitary Incidentaloma: An Endocrine Society Clinical Practice Guideline. *The Journal of Clinical Endocrinology & Metabolism*. 2011;96(4):894-904. doi:10.1210/jc.2010-1048
8. Expert Panel on Neurologic Imaging, Burns J, Policeni B, et al. ACR Appropriateness Criteria® Neuroendocrine Imaging. *J Am Coll Radiol*. 2019;16(5S):S161-S173. doi:10.1016/j.jacr.2019.02.017
9. Thompson CJ et al.eds. Melmed S et al. Chapter 10: Posterior Pituitary. In: *Williams Textbook of Endocrinology*, 14th ed., 2019: 303-330
10. Cooke DW et al.eds. Melmed S et al. Chapter 25: Normal and Aberrant Growth in Children. In: *Williams Textbook of Endocrinology*, 14th ed. 2019: 937-1022
11. Styne DM. eds. Melmed S et al. Chapter 26: Physiology and Disorders of Puberty. In: *Williams Textbook of Endocrinology*, 14th ed. 2019: 1023-1164
12. Bhasin S, Brito JP, Cunningham GR, et al. Testosterone Therapy in Men With Hypogonadism: An Endocrine Society* Clinical Practice Guideline. *The Journal of Clinical Endocrinology & Metabolism*. 2018;103(5):1715-1744. doi:10.1210/jc.2018-00229
13. Chen CC, Carter BS, Wang R, et al. Congress of Neurological Surgeons Systematic Review and Evidence-Based Guideline on Preoperative Imaging Assessment of Patients With Suspected Nonfunctioning Pituitary Adenomas. *Neurosurgery*. 2016;79(4). Pp E524-526. doi:10.1227/neu.0000000000001391
14. Nieman LK, Biller BMK, Findling JW, et al. Treatment of Cushing's Syndrome: An Endocrine Society Clinical Practice Guideline. *The Journal of Clinical Endocrinology & Metabolism*. 2015;100(8):2807-2831. doi:10.1210/jc.2015-1818
15. Woodmansee WW, Carmichael J, Kelly D, Katznelson L. American Association Of Clinical Endocrinologists And American College Of Endocrinology Disease State Clinical Review: Postoperative Management Following Pituitary Surgery. *Endocrine Practice*. 2015;21(7):832-838. doi:10.4158/ep14541.dscr
16. Ziu M, Dunn IF, Hess C, et al. Congress of Neurological Surgeons Systematic Review and Evidence-Based Guideline on Posttreatment Follow-up Evaluation of Patients With Nonfunctioning Pituitary Adenomas. *Neurosurgery*. 2016;79(4):E541-E543. doi:10.1227/neu.0000000000001392
17. Jane JA, Jr. Surgical Treatment of Pituitary Adenomas. (Updated 10/4/2019). In: Feingold KR, Anawalt B, Boyce A, et al. eds. Endotext [Internet]. South Dartmouth (MA): MD Text com, Inc; 2000
18. Cardinale F, Pero G, Quilici L, et al. Cerebral Angiography for Multimodal Surgical Planning in Epilepsy Surgery: Description of a New Three-Dimensional Technique and Literature Review. *World Neurosurgery*. 2015;84(2):358-367. doi:10.1016/j.wneu.2015.03.028
19. Prevedello D, Otto B, Carrau R, de Lara D, Ditzel Filho LF. Application of Image Guidance in Pituitary Surgery. *Surgical Neurology International*. 2012;3(3):73. doi:10.4103/2152-7806.95418

20. Guo Z, Liu C, Hou H, et al. Preoperative Computed Tomography (CT) Evaluation of Anatomical Abnormalities in Endonasal Transsphenoidal Approach in Pituitary Adenoma. *Medical Science Monitor*. 2018;24:1268-1275. doi:10.12659/msm.904402
21. Aghi MK, Chen CC, Fleseriu M, et al. Congress of Neurological Surgeons Systematic Review and Evidence-Based Guidelines on the Management of Patients With Nonfunctioning Pituitary Adenomas. *Neurosurgery*. 2016;79(4):521-523. doi:10.1227/neu.0000000000001386
22. Samperi I, Lithgow K, Karavitaki N. Hyperprolactinaemia. *Journal of Clinical Medicine*. 2019;8(12):2203. doi:10.3390/jcm8122203
23. Esposito D, Olsson DS, Ragnarsson O, Buchfelder M, Skoglund T, Johannsson G. Non-functioning pituitary adenomas: indications for pituitary surgery and post-surgical management. *Pituitary*. 2019;22(4):422-434. doi:10.1007/s11102-019-00960
24. Persani L. Central Hypothyroidism: Pathogenic, Diagnostic, and Therapeutic Challenges. *The Journal of Clinical Endocrinology & Metabolism*. 2012;97(9):3068-3078. doi:10.1210/jc.2012-1616
25. Fleseriu M, Hashim IA, Karavitaki N, et al. Hormonal Replacement in Hypopituitarism in Adults: An Endocrine Society Clinical Practice Guideline. *J Clin Endocrinol Metab*. 2016;101(11):3888-3921. doi:10.1210/jc.2016-2118
26. Sharma ST; AACE Adrenal Scientific Committee. AN INDIVIDUALIZED APPROACH TO THE EVALUATION OF CUSHING SYNDROME. *Endocr Pract*. 2017;23(6):726-737. doi:10.4158/EP161721.RA

Scalp and Skull (HD-20)

Guideline

Scalp and Skull Lesions (HD-20.1)
Skull Base Osteomyelitis (SBO) (HD-20.2)
References (HD-20)

Scalp and Skull Lesions (HD-20.1)

HD.SK.0020.1.A

v3.0.2024

The majority of these are benign soft tissue or bony lesions easily defined by physical examination or with skull x-rays or ultrasound.

- Ultrasound is initial imaging of scalp or skull lesions
- CT Head without or without and with contrast (CPT[®] 70450 or CPT[®] 70470) is indicated for the following scenarios:
 - Any lesion on physician examination and skull x-ray or ultrasound which is not clearly benign.
 - In cases where surgical planning is in progress, x-rays and/or ultrasound are not required.
 - Langerhans' cell histiocytosis, myeloma, and metastatic cancer, when symptoms suggest bony lesions.
- MRI Brain without contrast (CPT[®] 70551) or with and without contrast (CPT[®] 70553) if there is concern for intracranial extension.
- See **Dental/Periodontal/Maxillofacial Imaging (HD-30.2)** for mandibular masses
- The following imaging is indicated for children and adults with Pott Puffy Tumor:
 - MRI Brain without and with contrast (CPT[®]70553) or CT Head without and with contrast (CPT[®] 70470)⁴
 - Repeat imaging is supported if requested by a neurologist, neurosurgeon, otolaryngologist (ENT) and/or oromaxillofacial surgery (OMS) or any provider coordinating care with a neurologist, neurosurgeon, otolaryngologist (ENT) and/or oromaxillofacial surgery (OMS)

Background and Supporting Information

Pott Puffy Tumor is an abscess involving the frontal bone with adjacent osteomyelitis as the result of a frontal sinus infection that spreads contiguously through the wall of the sinus or through hematogenous spread via the veins that drain sinus mucosa.⁴

Skull Base Osteomyelitis (SBO) (HD-20.2)

HD.SK.0020.2.A

v3.0.2024

- Note: SBO may occur from the temporal bones or paranasal sinuses and imaging should be of the region of origin
- Neuroimaging is indicated in the diagnosis and treatment of skull base osteomyelitis and necrotizing external otitis. The following advanced imaging studies for the diagnosis of skull base osteomyelitis and necrotizing external otitis:
 - MRI Brain without and with contrast (CPT[®] 70553)
 - Will be positive earliest in disease
 - CT Head without contrast (CPT[®] 70450), CT Temporal bone without contrast (CPT[®] 70480), CT Temporal bone with contrast (CPT[®] 70481), CT Maxillofacial without contrast (CPT[®] 70486), CT Maxillofacial with contrast (CPT[®] 70487) or CT Neck with (CPT[®] 70491)
 - Will best define bony destruction, but is positive later in disease
 - Gallium-67 Scan
 - Bone Scan
 - Skull base osteomyelitis: + Gallium and + Bone scan
 - Necrotizing otitis externa: + Gallium and - Bone scan
 - Indium WBC may be substituted for or used in addition to Gallium scanning to evaluate response to therapy and especially in cases that have undergone surgical debridement.
- Treatment response: Gallium-67 Scan every 4-6 weeks till scan is negative
- Surveillance Scanning: Gallium-67 Scan at 4 weeks and 3 months post treatment

Background and Supporting Information

Skull based osteomyelitis is a rare complication of otitis externa. It occurs most commonly among the immunocompromised, older members (greater than 65 years of age) and members with diabetes.⁵

References (HD-20)

v3.0.2024

1. ACR-ASNR-SPR Practice Parameter for the Performance of Computed Tomography (CT) of the Extracranial Head and Neck Revised 2021. (Resolution 5). <https://www.acr.org/-/media/ACR/Files/Practice-Parameters/CT-Head-Neck>
2. Khan M, Quadri SQ, Kazmi A, et al. A comprehensive review of skull base osteomyelitis: Diagnostic and therapeutic challenges among various presentations. *Asian Journal of Neurosurgery*. 2018;13(4):959. doi:10.4103/ajns.ajns_90_17
3. Expert Panel on Neurologic Imaging:, Kirsch CFE, Bykowski J, et al. ACR Appropriateness Criteria® Sinusoidal Disease. *J Am Coll Radiol*. 2017;14(11S):S550-S559. doi:10.1016/j.jacr.2017.08.041
4. Barnett RR, Piazza MG, Elton SW. Pediatric Neurosurgery in Primary Care: Masses of the Scalp and Skull in Children. *Pediatr Clin North Am*. 2021;68(4):743-757. doi:10.1016/j.pcl.2021.04.003
5. Treviño González JL, Reyes Suárez LL, Hernández de León JE. Malignant otitis externa: An updated review. *Am J Otolaryngol*. 2021 Mar-Apr;42(2):102894. doi: 10.1016/j.amjoto.2020.102894. Epub 2021 Jan 5. PMID: 33429178

Stroke/TIA (HD-21)

Guideline

Stroke/TIA (HD-21.1)

Risk Assessment for Extracranial Carotid Disease (HD-21.2)

Cryptogenic Stroke (HD-21.3)

Transient Global Amnesia (HD-21.4)

Moyamoya Syndrome/Disease (HD-21.5)

Sickle Cell Disease⁸ (HD-21.6)

Multisystemic Smooth Muscle Syndrome (MSMS)/Smooth Muscle Dysfunction

Syndrome (SMDS)/ACTA2 Mutations⁴⁹ (HD-21.7)

References (HD-21)

Stroke/TIA (HD-21.1)

HD.HL.0021.1.A

v3.0.2024

Indication	Supported Imaging
<ul style="list-style-type: none"> Acute ischemic stroke (within the first 24 hours) Transient ischemic attacks (TIA) Hemorrhagic stroke Subdural hemorrhage 	<p>ANY or ALL may be approved:</p> <ul style="list-style-type: none"> CT head without contrast (CPT[®] 70450) CTA head (CPT[®] 70496) CTA Neck (CPT[®] 70498) CT Perfusion (CPT[®] 0042T)
<p>Concern for new stroke or TIA</p> <p>(MRI is preferred for evaluation of stroke/TIA, with or without a previous CT head)</p>	<ul style="list-style-type: none"> MRI Brain without contrast (CPT[®] 70551) OR MRI Brain without and with contrast (CPT[®] 70553)
<p>Contraindication to MRI</p>	<ul style="list-style-type: none"> CT head without contrast (CPT[®] 70450) OR CT head without and with contrast (CPT[®] 70470)
<p>Arterial Vascular Imaging supported for TIA/Stroke evaluation including dissection:</p> <ul style="list-style-type: none"> Supported concurrently with brain imaging Both MRA or CTA Head and Neck are needed to visualize the posterior vertebrobasilar circulation for evaluation of vertebrobasilar stroke/TIA 	<ul style="list-style-type: none"> MRA head (CPT[®] 70544, CPT[®] 70545, or CPT[®] 70546) OR CTA head (CPT[®] 70496) <p>AND/OR</p> <ul style="list-style-type: none"> MRA Neck (CPT[®] 70547, CPT[®] 70548, or CPT[®] 70549) OR CTA Neck (CPT[®] 70498)
<p>Venous vascular imaging for evaluation of venous infarcts</p>	<ul style="list-style-type: none"> MR or CT Venography (MRA Head [CPT[®] 70544, CPT[®] 70545, or CPT[®] 70546]) OR CTA Head (CPT[®] 70496)
<p>Cerebral Angiography for stroke evaluation</p>	<ul style="list-style-type: none"> 3D Rendering (CPT[®] 76377 or CPT[®] 76376)

Indication	Supported Imaging
<p>Stroke in Pregnancy and other hypercoagulable states⁴³</p> <ul style="list-style-type: none"> • See arterial and venous vascular imaging studies above for vascular imaging requests • See also <u>Background and Supporting Information</u> 	<ul style="list-style-type: none"> • MRI Brain without contrast (CPT[®] 70551) OR • CT head without contrast (CPT[®] 70450)
<p>Amaurosis Fugax or Ocular Microembolism</p> <ul style="list-style-type: none"> • May include optic nerve/retinal arterial or Hollenhorst plaques on exam 	<p>See above for TIA or New Stroke brain imaging options and vascular imaging</p>
<p>Repeat imaging for follow up and resolution of stroke or hemorrhage</p>	<p>As requested by a neurologist, neurosurgeon, or physiatrist (PM&R) or any provider in consultation with a neurologist, neurosurgeon or physiatrist</p>
<p>Reversible Cerebral Vasoconstriction Syndrome</p>	<p>See <u>Sudden Onset of Headache (HD-11.3)</u></p>
<p>Neurologic signs and/or symptoms, including headaches, associated with COVID-19 infection and/or COVID-19 vaccination</p> <p>(Strokes may be arterial or venous)</p>	<ul style="list-style-type: none"> • MRI Brain without contrast (CPT[®] 70551) OR • MRI Brain without and with contrast (CPT[®] 70553) <p>See also <u>General Guidelines-CT head (HD-1.4)</u>, <u>Abnormal Blood Clotting (HD-11.9)</u> and <u>Neuro-Covid-19 (HD-14.2)</u></p>
<p>Adults with HbSS (Sickle cell disease) or HbSb Thalassemia</p>	<p>One time MRI brain without contrast (CPT[®] 70551) or without and with contrast (CPT[®] 70553) for screening to deter silent cerebral infarcts</p> <p>Follow up or repeat testing per Neurologist or Hematologist or in consultation with a Neurologist or Hematologist</p> <p>See also <u>Sickle Cell Disease (HD-21.6)</u></p>

Indication	Supported Imaging
Documented Stroke or TIA	Transcranial Doppler Studies See Transcranial Doppler CPT[®] 93886 (HD 24.8)
Moyamoya Disease, when surgery or other vascular intervention is being considered	<ul style="list-style-type: none"> • Radiopharmaceutical Localization Imaging SPECT (CPT[®] 78803 or CPT[®] 78830) with vasodilating agent acetazolamide (Diamox) Follow up or repeat testing per Neurologist or Neurosurgeon or in consultation with a Neurologist or Neurosurgeon See also Moyamoya Syndrome/Disease (HD-21.5)
Evaluation of paradoxical venous thromboembolism in cryptogenic stroke with PFO	See Acute Limb Swelling (PVD-12.2) and Cryptogenic Stroke (HD-21.3)
Cerebral Amyloid Angiopathy (CAA) (31,32,38)	<ul style="list-style-type: none"> • MRI Brain without contrast (CPT[®] 70551) OR • MRI Brain without and with contrast (CPT[®] 70553) OR • CT head without contrast (CPT[®] 70450) Amyloid-PET Brain (CPT [®] 78811 or CPT [®] 78814) is considered not medically necessary for stroke evaluation. See Dementia PET (HD-8.2)
Multisystem Smooth Muscle Syndrome/ Smooth Muscle Dysfunction Syndrome	See Multisystem Smooth Muscle Syndrome/Smooth Muscle Dysfunction Syndrome (HD-21.7)

Background and Supporting Information

- Pregnancy is an independent risk factor for stroke. Additional risk factors are not required for assessment of a stroke/TIA with acute focal neurological deficits.

- Additional arterial and venous hypercoaguable states that impose a stroke risk include:
 - Antiphospholipid syndrome
 - Hyperhomocysteinemia
 - Factor V Leiden mutation
 - Prothrombin gene mutation
 - Protein S deficiency
 - Protein C deficiency
 - Anti-thrombin deficiency

Risk Assessment for Extracranial Carotid Disease (HD-21.2)

HD.HL.0021.2.A

v3.0.2024

- Duplex Ultrasound Carotid Arteries (CPT[®] 93880 or CPT[®] 93882) for the following:
 - Asymptomatic or symptomatic cervical bruits;
 - Clinical suspicion of extracranial carotid occlusion and the rationale is included
 - Pulsatile neck mass
 - Evaluation of blunt or penetrating neck trauma
 - Amaurosis fugax or ocular microembolism (optic nerve/retinal arterial or Hollenhorst plaques seen on exam)
 - Recent history of focal cerebral or ocular transient ischemic attacks
- Follow-up with CTA or contrast enhanced MRA
 - CTA and contrast enhanced MRA are comparable non-invasive imaging alternatives each with their own advantages and disadvantages
- For additional indications for Duplex Ultrasound Carotid Arteries
 - See **Initial Imaging (PVD-3.1)** in the Peripheral Vascular Disease (PVD) Imaging Guidelines
- For repeat (Surveillance) Duplex Ultrasound Carotid Arteries (CPT[®] 93880 or CPT[®] 93882)
 - See **Surveillance Imaging with NO History of Carotid Surgery or Intervention (PVD-3.2)** and **Surveillance Imaging WITH History of Carotid Surgery or Intervention (PVD-3.3)** in the Peripheral Vascular Disease (PVD) Imaging Guidelines.

Cryptogenic Stroke (HD-21.3)

HD.ST.0021.3.A

v3.0.2024

- 25% of individuals with ischemic stroke have no probable cause and is considered cryptogenic after a standard workup including an echocardiogram, inpatient cardiac telemetry or 24-Holter monitoring, CT or MRI Brain and vessel imaging of the brain or neck arteries and hematologic tests.
- A stroke may also be considered cryptogenic after a standard evaluation fails to yield an etiology in a person <50 years of age without risk factors with more extensive testing.
- Most cryptogenic sources are embolic in etiology from venous or arterial sources with investigations from disturbances in coagulation and sources of embolism including patent foramen ovale (PFO) and paroxysmal atrial fibrillation.
- Specialized evaluation with the following documentation:
 - MRI/CT Brain with results of stroke
 - Results of MRA/CTA Head and Neck
 - TTE or TEE
 - 24-Hr Holter monitor or Inpatient cardiac telemetry and 12-Lead ECG
- Hematologic testing to include: CBC, Platelet count, INR, PT, PTT, D-Dimer and Arterial and Venous Hypercoagulability tests
 - MRA or CTA Pelvis for the evaluation of paradoxical venous thromboembolism with PFO
 - See **Acute Limb Swelling (PVD-12)** in the Peripheral Vascular Disease (PVD) Imaging Guidelines.
 - Workup for occult cancer, CT Chest Abdomen and/or Pelvis with contrast after the previously indicated tests with results are provided.
 - See **Paraneoplastic Syndromes (ONC-30.3)** in the Oncology Imaging Guidelines.
 - Cardiac CT (CPT[®] 75574 or CPT[®] 75572) instead of TEE if TTE is inconclusive

Transient Global Amnesia (HD-21.4)

HD.ST.0021.4.A

v3.0.2024

- Transient Global Amnesia (TGA) is a clinical diagnosis with the differential diagnosis including, but not exclusive to: ischemic events, migraine headaches, and transient epileptic amnesia.
- Characteristics of TGA may include the following:
 - Inability to retain new information, lasting for several hours with preservation of alertness and all other cognitive functions with repetitive queries and amnesia³⁹
 - Witnessed episode
 - There must be anterograde amnesia during the attack
 - Cognitive impairment is limited to amnesia
 - No clouding of consciousness or loss of personal identity
 - No focal neurological signs/symptoms
 - No epileptic features
 - Attack must resolve within 24 hours
 - No recent head injury or active epilepsy
- Head and vessel imaging for ischemic etiology work-up should follow **Stroke/TIA (HD-21.1)**
- For suspected seizure, see **Epilepsy/Seizures (HD-9.1)**

Moyamoya Syndrome/Disease (HD-21.5)

HD.ST.0021.5.A

v3.0.2024

Initial imaging for Moyamoya Syndrome/Disease

- Below are indicated for initial evaluation of Moyamoya Syndrome/Disease³⁶:
 - MRI Brain without contrast (CPT[®] 70551) **OR**
 - MRI Brain without and with contrast (CPT[®] 70553) **AND/OR**
 - MRA Head (CPT[®] 70544, CPT[®] 70545, **OR** CPT[®] 70546) **AND/OR**
 - MRA Neck (CPT[®] 70547, CPT[®] 70548 **OR** CPT[®] 70549)
 - If MRA is contraindicated or not readily available, then CTA Head (CPT[®] 70496) **AND/OR** CTA Neck (CPT[®] 70498) is/are supported

Repeat imaging for Moyamoya Syndrome/Disease³⁶

- MRA Head (CPT[®] 70544, CPT[®] 70545, or OR CPT[®] 70546) every 12 months **AND/OR**
- MRA Neck (CPT[®] 70547, CPT[®] 70548 **OR** CPT[®] 70549)
 - If MRA is contraindicated or not readily available, then CTA Head (CPT[®] 70496) **AND/OR** CTA Neck (CPT[®] 70498) is/are supported
- MRI Brain without contrast (CPT[®] 70551) **OR** MRI Brain without and with contrast (CPT[®] 70553) every 12 months^{33,36}
- Radiopharmaceutical Localization Imaging SPECT (CPT[®] 78803) with vasodilating agent acetazolamide (Diamox) challenge is supported when surgery or other vascular intervention is considered.
- 3D Rendering (CPT[®] 76377 or CPT[®] 76376) with cerebral angiography to define the presence, location, and anatomy of intracranial and cervical vascular malformations.²²
 - See **General Guidelines - Other Imaging Situations (HD-1.7)** and **3D Rendering (Preface-4.1)** in the Preface Imaging Guidelines³⁷
- CT Perfusion (CPT[®] 0042T) **OR** MRI Perfusion (CPT[®] 70551 OR CPT[®] 70552 OR CPT[®] 70553)⁵¹ indicated:
 - When requested by neurologist and/or neurosurgeon
 - Prior to change in treatment
 - Post-surgical^{33,36}

Screening imaging for Moyamoya Disease^{34,35}

- Screening not indicated for Moyamoya Syndrome

- See **Background and Supporting Information**
- Screening for Moyamoya Disease is indicated for:
 - First degree relatives (biological parent, full sibling, or biological child) of individuals with Moyamoya Disease when requested by, or any provider in consultation with a neurologist, geneticist or neurosurgeon
- Below are indicated for screening evaluation of Moyamoya Disease:
 - MRA Head (CPT[®] 70544, CPT[®] 70545, **OR** CPT[®] 70546) **OR** Transcranial Doppler (TCD) Ultrasound (CPT[®] 93886 or CPT[®] 93888) (see **Transcranial Doppler (CPT[®] 93886) (HD-24.8)** in the Head Imaging Guidelines)
 - If MRA is contraindicated or not readily available, then CTA Head (CPT[®] 70496) is supported

CT Perfusion (CPT[®] 0042T)

- Is supported if requested by a neurologist, neurosurgeon or any provider coordinating care with a neurologist or neurosurgeon.³⁶

MRI Perfusion

- MRI Perfusion may be obtained with MRI Brain (CPT[®] 70551 OR CPT[®] 70552 OR CPT[®] 70553)
 - No additional CPT[®] codes are necessary or appropriate to perform MRI perfusion.³³

Background and Supporting Information

Moyamoya disease (MMD) is a rare cerebrovascular disease characterized by progressive spontaneous bilateral occlusion of the intracranial internal carotid arteries (ICA) and their major branches (middle cerebral artery, MCA, and anterior cerebral artery, ACA) with compensatory capillary collaterals as an expression of pathologically increased angiogenic activity resembling a "puff of smoke" (Japanese: Moyamoya) on cerebral angiography.⁴¹ Moyamoya Disease is most prevalent individuals with East Asian ancestry. Up to 15% of individuals with Moyamoya Disease may have a family history of Moyamoya Disease.^{34,35}

Moyamoya Disease is distinguished from Moyamoya Syndrome (MMS). MMD is a primary disease process. MMS is a secondary process that occurs in response to another underlying pathological process that causes stenosis of intracranial blood vessels.⁴⁰ There are two peaks of incidence with different clinical presentations, at around 10 years and 30-40 years. The peak appears to occur later in women than men. In children, ischemic symptoms, especially transient ischemic attacks, are predominant. Intellectual decline, seizures, and involuntary movements are also more common in this

age group. In contrast, adult patients present with intracranial hemorrhage more often than pediatric patients.³⁵

Sickle Cell Disease⁸ (HD-21.6)

HD.ST.0021.6.A

v3.0.2024

- MRI Brain without contrast (CPT[®] 70551) **OR** MRI Brain without and with contrast (CPT[®] 70553) indications:
 - Screening to detect silent cerebral infarcts
 - New symptoms or cognitive impairment occurs or a change in academic performance
 - Prior to any change in therapy^{42, 44, 45, 46,52}
- MRA Head (CPT[®] 70544, CPT[®] 70545 **OR** CPT[®] 70546) **OR** CTA Head (CPT[®] 70496) indications:
 - Any new, indeterminate or equivocal findings on MRI Brain
 - Prior to any change in therapy^{42, 44, 45, 46,52}

Background and Supporting Information

Individuals with sickle cell disease are at significantly increased risk for stroke and silent infarction, beginning at a very young age. Recent advances allow physicians to identify individuals at high risk for stroke and begin a primary stroke prevention program.

Identification of silent cerebral infarction is important because treatment with prophylactic red cell transfusions to maintain hemoglobin S levels at <30% of total hemoglobin may reduce recurrent stroke and extent of neurologic damage.

- TCD for children aged 17 years old may be appropriate on a case-by-case basis.
- See **Transcranial Doppler (CPT[®] 93886)(HD-24.8)** in the Head Imaging Guidelines for other indications for this modality and **Stroke/TIA (HD-21.1)** in the Head Imaging Guidelines.
- After 17 years old, for individuals with a history of abnormal TCDs, TCDs may be repeated every 3 months.⁴⁷
- TCD is not indicated for individuals with other phenotypes (Hgb SC, Hgb Sβ⁺).⁸

Multisystemic Smooth Muscle Syndrome (MSMS)/Smooth Muscle Dysfunction Syndrome (SMDS)/ACTA2 Mutations⁴⁹ (HD-21.7)

HD.ST.0021.7.A
v3.0.2024

Indications	Supported Imaging
Initial evaluation for confirmed ACTA2 mutation	<ul style="list-style-type: none">• MRI Brain without and with contrast (CPT[®] 70553) with OR without MRI perfusion <p>AND/OR</p> <ul style="list-style-type: none">• MRA Head (CPT[®] 70544, CPT[®] 70545, or CPT[®] 70546) <p>AND/OR</p> <ul style="list-style-type: none">• MRA Neck (CPT[®] 70547, CPT[®] 70548, or CPT[®] 70549)
Repeat imaging if requested by neurologist and/or neurosurgeon and/or geneticist and/or provider coordinating care with a neurologist and/or neurosurgeon and/or geneticist	<ul style="list-style-type: none">• MRI Brain without and with contrast (CPT[®] 70553) with OR without MRI perfusion <p>AND/OR</p> <ul style="list-style-type: none">• MRA Head (CPT[®] 70544, CPT[®] 70545, or CPT[®] 70546) <p>AND/OR</p> <ul style="list-style-type: none">• MRA Neck (CPT[®] 70547, CPT[®] 70548, or CPT[®] 70549)

- MRI Perfusion may be obtained with MRI Brain (CPT[®] 70551 OR CPT[®] 70552 OR CPT[®] 70553)
 - No additional CPT[®] codes are necessary or appropriate to perform MRI perfusion.⁵¹
- Because radiation is a known risk factor for development of moyamoya, MRI/MRA Head is recommended instead of Computed Tomography (CT)/CTA.⁴⁹
 - See **Background and Supporting Information**
- Conventional catheter angiogram 3D rendering (CPT[®] 76376 or CPT[®] 76377) should be reserved for patients with focal neurologic symptoms or evidence on MRA or transcranial Doppler (TCD) of critical or progressive narrowing of the cerebral arteries.⁴⁹
 - See **Screening for Suspected Peripheral Artery Disease/Aneurysmal Disease (PVD-2)**

Background and Supporting Information

Smooth muscle dysfunction syndrome (SMDS)/Multisystemic Smooth Muscle Syndrome (MSMS) presents with a recognizable pattern of complications, including congenital mydriasis, patent ductus arteriosus (PDA), pulmonary arterial hypertension, aortic and other arterial aneurysms, moyamoya-like cerebrovascular disease, intestinal hypoperistalsis and malrotation, and hypotonic bladder.⁴⁹

SMDS/MSMS is caused by heterozygous mutations of the ACTA2 altering arginine 179, most commonly p.Arg179His. With a single exception, all cases are due to de novo mutations.⁴⁹

References (HD-21)

v3.0.2024

1. Expert Panel on Neurologic Imaging.; Salmela MB, Mortazavi S, et al. ACR Appropriateness Criteria® Cerebrovascular Disease. *J Am Coll Radiol*. 2017;14(5S):S34-S61. doi:10.1016/j.jacr.2017.01.051
2. Kovacs MJ. Letter by Kovacs Regarding Article, "Diagnosis and Management of Cerebral Venous Thrombosis: A Statement for Healthcare Professionals From the American Heart Association/American Stroke Association." *Stroke*. 2011;42(7). doi:10.1161/strokeaha.111.619437
3. Stam J. Thrombosis of the Cerebral Veins and Sinuses. *New England Journal of Medicine*. 2005;352(17):1791-1798. doi:10.1056/nejmra042354
4. Schievink WI. Spontaneous dissection of the carotid and vertebral arteries. *The New England Journal of Medicine*. 2001;344(12):898-906. doi:10.1056/NEJM200103223441206
5. Arnold M, Bousser M-G. Carotid and vertebral artery dissection. *Practical Neurology*. 2005;5(2):100-109. doi:10.1111/j.1474-7766.2005.00292.x
6. Powers WJ, Rabinstein AA, Ackerson T, et al. Guidelines for the Early Management of Patients With Acute Ischemic Stroke: 2019 Update to the 2018 Guidelines for the Early Management of Acute Ischemic Stroke: A Guideline for Healthcare Professionals From the American Heart Association/American Stroke Association. *Stroke*. 2019;50(12). doi:10.1161/str.0000000000000211
7. Burton TM, Bushnell CD. Reversible Cerebral Vasoconstriction Syndrome. *Stroke*. 2019;50(8):2253-2258. doi:10.1161/strokeaha.119.024416
8. Debaun MR, Jordan LC, King AA, et al. American Society of Hematology 2020 guidelines for sickle cell disease: prevention, diagnosis, and treatment of cerebrovascular disease in children and adults. *Blood Advances*. 2020;4(8):1554-1588. doi:10.1182/bloodadvances.2019001142
9. Osgood M, Budman E, Carandang R, Goddeau JRP, Henninger N. Prevalence of Pelvic Vein Pathology in Patients with Cryptogenic Stroke and Patent Foramen Ovale Undergoing MRV Pelvis. *Cerebrovascular Diseases*. 2015;39(3-4):216-223. doi:10.1159/000376613
10. Messé SR, Gronseth GS, Kent DM, et al. Practice advisory update summary: Patent foramen ovale and secondary stroke prevention. *Neurology*. 2020;94(20):876-885. doi:10.1212/wnl.00000000000009443
11. Demeestere J, Wouters A, Christensen S, Lemmens R, Lansberg MG. Review of Perfusion Imaging in Acute Ischemic Stroke. *Stroke*. 2020;51(3):1017-1024. doi:10.1161/strokeaha.119.028337
12. Belani P, Schefflein J, Kihira S, et al. COVID-19 Is an Independent Risk Factor for Acute Ischemic Stroke. *American Journal of Neuroradiology*. 2020. doi:10.3174/ajnr.a6650
13. Merkle AE, Parikh NS, Mir S, et al. Risk of Ischemic Stroke in Patients With Coronavirus Disease 2019 (COVID-19) vs Patients With Influenza. *JAMA Neurology*. 2020. doi:10.1001/jamaneurol.2020.2730
14. Guzik A, Bushnell C. Stroke Epidemiology and Risk Factor Management. *CONTINUUM: Lifelong Learning in Neurology*. 2017;23(1):15-39. doi:10.1212/con.0000000000000416
15. Tsvigoulis G, Alexandrov AV. Ultrasound in Neurology. *CONTINUUM: Lifelong Learning in Neurology*. 2016;22(5):1655-1677. doi:10.1212/con.0000000000000374
16. Meschia JF, Bushnell C, Boden-Albala B, et al. Guidelines for the Primary Prevention of Stroke. *Stroke*. 2014;45(12):3754-3832. doi:10.1161/str.0000000000000046
17. Lawton MT and Vates GE. Subarachnoid Hemorrhage. *N Engl J Med* 2017;377:257-66. doi: 10.1056/NEJMcp1605827
18. ACR AIUM SPR SRU Practice Parameter for the Performance of an Ultrasound Examination of the Extracranial Cerebrovascular System. 2016
19. ACR-ASNR-SPR Practice Parameter for the Performance of Computed Tomography (CT) of the Extracranial Head and Neck Revised 2021. (Resolution 5). <https://www.acr.org/-/media/ACR/Files/Practice-Parameters/CT-Head-Neck>
20. Kamel H, et al. Tailoring the Approach to Embolic Stroke of Undetermined Source. A Review. *JAMA Neurol*;76(7):855-861. doi:10.1001/jamaneurol.2019.0591
21. Navi BB and Iadecola C. Ischemic Stroke in Cancer Patients: A Review of an Underappreciated Pathology. *Ann Neurol*. 2018 May ; 83(5): 873–883. doi:10.1002/ana.25227
22. Saver, JL. Cryptogenic Stroke. *N Engl J Med* 2016;374:2065-74. doi:10.1056/NEJMcp1503946

23. Swarzbach CJ, et al. Stroke and Cancer. The Importance of Cancer-Associated Hypercoagulation as a Possible Stroke Etiology. *Stroke*. 2012;43:3029-3034. doi: 10.1161/STROKEAHA.112.658625
24. Mangla A, Navi BB, Layton K, Kamel H. Transient global amnesia and the risk of ischemic stroke. *Stroke*. 2014;45(2):389-393. doi:10.1161/STROKEAHA.113.003916
25. Spiegel DR, Smith J, Wade RR, et al. Transient global amnesia: current perspectives. *Neuropsychiatric Disease and Treatment*. 2017;Volume 13:2691-2703. doi:10.2147/ndt.s130710
26. Chandra A, Stone CR, Du X, Li WA, Huber M, Bremer R, Geng X, Ding Y. The cerebral circulation and cerebrovascular disease III: Stroke. *Brain circulation*. 2017 Apr;3(2):66
27. Hakimi R, Sivakumar S. Imaging of Carotid Dissection. *Current Pain and Headache Reports*. 2019;23(1). doi:10.1007/s11916-019-0741-9
28. Ghoneim A, Straiton J, Pollard C, Macdonald K, Jampana R. Imaging of cerebral venous thrombosis. *Clinical Radiology*. 2020;75(4):254-264. doi:10.1016/j.crad.2019.12.009
29. Dmytriw AA, Song JSA, Yu E, Poon CS. Cerebral venous thrombosis: state of the art diagnosis and management. *Neuroradiology*. 2018;60(7):669-685. doi:10.1007/s00234-018-2032-2
30. ACR-ASNR-SIR-SNIS Practice Parameter for the Performance of Diagnostic Cervicocerebral Catheter Angiography in Adults. Revised 2016. (Resolution 13) <https://www.acr.org/-/media/ACR/Files/Practice-Parameters/CervicoCerebralCathAngio.pdf>
31. McCarter SJ, Lesnick TG, Lowe V et al. Cerebral Amyloid Angiopathy Pathology and Its Association With Amyloid- β PET Signal. *Neurology* 2021;97 (18) :e1799-e1808. doi:10.1212/WNL.00000000000012770
32. Baron JC, Farid K, Dolan E, et al. Diagnostic utility of amyloid PET in cerebral amyloid angiopathy-related symptomatic intracerebral hemorrhage. *J Cereb Blood Flow Metab*. 2014;34(5):753-758. doi:10.1038/jcbfm.2014.43
33. ACR-ASNR- SPR Practice Parameters for the performance of Computed Tomography (CT) perfusion in neuroradiologic imaging. Revised 2017. Resolution 18. <https://www.acr.org/-/media/ACR/Files/Practice-Parameters/CT-Perfusion.pdf>
34. Han C, Feng H, Han YQ, et al. Prospective screening of family members with moyamoya disease patients. *PLoS One*. 2014;9(2):e88765. Published 2014 Feb 19. doi:10.1371/journal.pone.0088765
35. Kim JS. Moyamoya Disease: Epidemiology, Clinical Features, and Diagnosis. *J Stroke*. 2016;18(1):2-11. doi:10.5853/jos.2015.01627
36. Choudri A, Zaza A, Auschwitz T, Mossa-Basha M. Noninvasive vascular imaging of moyamoya: Diagnosis, followup, and surgical planning. *Journal of Pediatric Neuroradiology* 3 (2014) 13–20. doi:10.3233/PNR-14082
37. Expert Panel on Neurological Imaging, Ledbetter LN, Burns J, et al. ACR Appropriateness Criteria[®] Cerebrovascular Diseases-Aneurysm, Vascular Malformation, and Subarachnoid Hemorrhage. *J Am Coll Radiol*. 2021;18(11S):S283-S304. doi:10.1016/j.jacr.2021.08.012
38. Szidonya L, Nickerson JP. Cerebral Amyloid Angiopathy. *Radiol Clin North Am*. 2023;61(3):551-562. doi:10.1016/j.rcl.2023.01.009
39. Ropper AH. Transient Global Amnesia. *N Engl J Med*. 2023;388(7):635-640. doi:10.1056/NEJMr2213867
40. Berry JA, Cortez V, Toor H, Saini H, Siddiqi J. Moyamoya: An Update and Review. *Cureus*. 2020;12(10):e10994. Published 2020 Oct 16. doi:10.7759/cureus.10994
41. Mertens R, Graupera M, Gerhardt H, et al. The Genetic Basis of Moyamoya Disease. *Transl Stroke Res*. 2022;13(1):25-45. doi:10.1007/s12975-021-00940-2
42. Krishnamurti L. Hematopoietic Cell Transplantation for Sickle Cell Disease. *Front Pediatr*. 2021;8:551170. Published 2021 Jan 5. doi:10.3389/fped.2020.551170
43. Roeder HJ, Lopez JR, Miller EC. Ischemic stroke and cerebral venous sinus thrombosis in pregnancy. *Handb Clin Neurol*. 2020;172:3-31. doi:10.1016/B978-0-444-64240-0.00001-5
44. Kanter J, Liem RI, Bernaudin F, et al. American Society of Hematology 2021 guidelines for sickle cell disease: stem cell transplantation. *Blood Adv*. 2021;5(18):3668-3689. doi:10.1182/bloodadvances.2021004394C
45. Jordan LC, Kassim AA, Wilkerson KL, Lee CA, Waddle SL, Donahue MJ. Using novel magnetic resonance imaging methods to predict stroke risk in individuals with sickle cell anemia. *Hematol Oncol Stem Cell Ther*. 2020;13(2):76-84. doi:10.1016/j.hemonc.2019.12.009
46. Hirtz D, Kirkham FJ. Sickle Cell Disease and Stroke. *Pediatr Neurol*. 2019;95:34-41. doi:10.1016/j.pediatrneurol.2019.02.018

47. Bernaudin F, Verlhac S, Arnaud C, et al. Long-term treatment follow-up of children with sickle cell disease monitored with abnormal transcranial Doppler velocities. *Blood*. 2016;127(14):1814-1822. doi:10.1182/blood-2015-10-675231.
48. Kirkham FJ, Lagunju IA. Epidemiology of Stroke in Sickle Cell Disease. *J Clin Med*. 2021;10(18):4232. Published 2021 Sep 18. doi:10.3390/jcm10184232
49. Regalado ES, Mellor-Crummey L, De Backer J, et al. Clinical history and management recommendations of the smooth muscle dysfunction syndrome due to ACTA2 arginine 179 alterations. *Genet Med*. 2018;20(10):1206-1215. doi:10.1038/gim.2017.245
50. Cuoco JA, Busch CM, Klein BJ, et al. ACTA2 Cerebral Arteriopathy: Not Just a Puff of Smoke. *Cerebrovasc Dis*. 2018;46(3-4):161-171. doi:10.1159/000493863.
51. ACR–ASNR–SPR PRACTICE PARAMETER FOR THE PERFORMANCE OF INTRACRANIAL MAGNETIC RESONANCE PERFUSION IMAGING. Revised 2022 (Resolution 24). *PRACTICE PARAMETER MR_Perfusion*. <https://www.acr.org/-/media/ACR/Files/Practice-Parameters/mr-perfusion.pdf? la=en>.
52. Nickel RS, Kamani NR. Ethical Challenges in Hematopoietic Cell Transplantation for Sickle Cell Disease. *Biol Blood Marrow Transplant*. 2018;24(2):219-227. doi:10.1016/j.bbmt.2017.08.034

Cerebral Vasculitis (HD-22)

Guideline

Cerebral Vasculitis (HD-22.1)
References (HD-22)

Cerebral Vasculitis (HD-22.1)

HD.CV.0022.1.A

v3.0.2024

- When CNS vasculitis is suspected, MRI Brain without and with contrast (CPT[®] 70553) is supported
 - MRA Head (CPT[®] 70544, CPT[®] 70545, or CPT[®] 70546) **AND**
 - MRA Neck (CPT[®] 70547, CPT[®] 70548, or CPT[®] 70549); **OR**
 - CTA Head (CPT[®] 70496) **AND**
 - CTA Neck (CPT[®] 70498) are supported concurrently with brain imaging
- Primary CNS vasculitis includes Giant Cell Arteritis also known as Temporal Arteritis (see **New Headache Onset Older than Age 50 (HD-11.7)**)
- If initial vascular imaging is suspicious for vasculitis, 3D rendering (CPT[®] 76377 or CPT[®] 76376) with cervicocerebral angiography/arteriography (see **General Guidelines- Other Imaging Situations (HD-1.7)**)
- Transcranial Doppler Studies for individuals with documented vasculitis or concern for vasospasm (see **Transcranial Doppler (CPT[®] 93886) (HD-24.8)**)
- FDG-PET is not supported due to lack of peer reviewed literature or expert consensus supporting the study for vasculitis.
- For extra-cranial giant cell arteritis evaluation (see **Giant Cell Arteritis (PVD-6.9.2)**)

Background and Supporting Information

The diagnosis of primary central nervous system vasculitis is challenging because of its nonspecific and varied symptoms. Central nervous system vasculitis typically presents with headache, followed by encephalopathy and behavioral changes. Focal neurologic deficits, including but not limited to, visual loss, unilateral weakness, language impairment, sensory loss, incoordination, occurs in 20% to 30% of individuals. Seizures and intracranial hemorrhage may also occur. With a strong clinical suspicion, brain imaging is important for supporting the diagnostic process and directing biopsy.⁶

Classification of vasculitides based on vessel size adapted from Younger. MRA and CTA are useful for the evaluation of the large proximal arteries; evaluation of a possible small vessel vasculitis may be beyond the resolution of routine MRA and CTA Head. However, other abnormalities, such as atherosclerotic disease, arterial dissection, Moyamoya disease, or reversible cerebral vasoconstriction may be demonstrated. Conventional angiogram is superior to MRA and CTA in demonstrating abnormalities in smaller vessels and is considered the "gold standard" in the evaluation of primary small vessel CNS vasculitis.

Dominant Vessel Involved	Primary	Secondary
Large arteries	<ul style="list-style-type: none">• Giant cell arteritis• Takayasu's arteritis	Aortitis with rheumatoid disease; Infection (e.g. syphilis)
Medium arteries	<ul style="list-style-type: none">• Classical polyarteritis nodosa• Kawasaki disease	Infection (e.g. hepatitis B)
Small vessels and medium arteries	<ul style="list-style-type: none">• Wegener's granulomatosis• Churg–Strauss syndrome• Microscopic polyangiitis	Vasculitis with rheumatoid disease, systemic lupus erythematosus (lupus cerebritis), Sjögren's syndrome, drugs, infection (e.g. HIV)
Small vessels	<ul style="list-style-type: none">• Henoch-Schönlein purpura• Essential cryoglobulinemia• Cutaneous leukocytoclastic vasculitis	Drugs (e.g. sulphonamides, etc.) Infection (e.g. hepatitis C)

References (HD-22)

HD.CV.0022.2.A

v3.0.2024

1. Younger DS. Epidemiology of Neurovasculitis. *Neurologic Clinics*. 2016;34(4):887-917. doi:10.1016/j.ncl.2016.06.006
2. Soun JE, Song JW, Romero JM, Schaefer PW. Central Nervous System Vasculopathies. *Radiologic Clinics of North America*. 2019;57(6):1117-1131. doi:10.1016/j.rcl.2019.07.005
3. Salmela MB, Mortazavi S, Jagadeesan BD, et al. ACR Appropriateness Criteria® Cerebrovascular Disease. *Journal of the American College of Radiology*. 2017;14(5). doi:10.1016/j.jacr.2017.01.051
4. Okazaki T, Shinagawa S, Mikage H. Vasculitis syndrome-diagnosis and therapy. *Journal of General and Family Medicine*. 2017;18(2):72-78. doi:10.1002/jgf2.4
5. Ikeda T, Furukawa F, Kawakami T, et al. Outline of guidelines for the management of vasculitis and vascular disorders in Japan, 2016 revised edition. *The Journal of Dermatology*. 2017;45(2):122-127. doi:10.1111/1346-8138.14086
6. Expert Panel on Neurological Imaging, Ledbetter LN, Burns J, et al. ACR Appropriateness Criteria® Cerebrovascular Diseases-Aneurysm, Vascular Malformation, and Subarachnoid Hemorrhage. *J Am Coll Radiol*. 2021;18(11S):S283-S304. doi:10.1016/j.jacr.2021.08.012

Dizziness, Vertigo and Syncope (HD-23)

Guideline

Dizziness/Vertigo (HD-23.1)
Syncope (HD-23.2)
References (HD-23)

Dizziness/Vertigo (HD-23.1)

HD.DZ.0023.1.A

v3.0.2024

Indications	Supported Imaging
<p>Red Flags:</p> <ul style="list-style-type: none"> • History of malignancy • Associated symptoms: <ul style="list-style-type: none"> ◦ Headache ◦ Hearing loss ◦ Unilateral tinnitus ◦ Visual disturbances ◦ Drop attacks ◦ Vestibular migraine ◦ Weakness • Duration of episode: <ul style="list-style-type: none"> ◦ Episodes lasting hour(s) or ◦ Continuous • Exam findings: <ul style="list-style-type: none"> ◦ Inconclusive positional testing or equivocal or unusual nystagmus findings (Negative Dix-Hallpike) ◦ Visual disturbances including loss and diplopia ◦ Hearing loss ◦ Abnormal cranial nerve findings ◦ Ataxia ◦ Positive Romberg sign ◦ Absent head thrust sign ◦ Focal neurologic deficits ◦ Dysarthria ◦ Weakness, including unilateral or hemibody weakness • Failed treatment: <ul style="list-style-type: none"> ◦ Failure to respond to vestibular therapy or unable to participate due to clinical condition • Abnormal test results: <ul style="list-style-type: none"> ◦ ENG/VNG results support central cause 	<ul style="list-style-type: none"> • MRI Brain without contrast (CPT 70551) OR • MRI Brain without and with contrast (CPT 70553) OR • CT head without contrast (CPT 70450) <p>If MRI contraindicated:</p> <ul style="list-style-type: none"> • CT head without contrast (CPT 70450) OR • CT head without and with contrast (CPT 70470) <p>See also:</p> <ul style="list-style-type: none"> • <u>Headaches with Red Flags (HD-11.2)</u> • <u>Multiple Sclerosis and Related Conditions (HD-16)</u> • <u>Brain Metastases (ONC-31.3)</u>

Indications	Supported Imaging
Stroke/TIA	See <u>Stroke/TIA (HD-21.1)</u>
Acoustic Neuroma/Vestibular Schwannoma	<ul style="list-style-type: none"> • MRI Brain without and with contrast (with IAC views) (CPT[®] 70553) OR without contrast (CPT[®] 70551) • Limited MRI Brain with attention to internal auditory canals (CPT[®] 70540, CPT[®] 70542, OR CPT[®] 70543) when requested by the provider in place of a complete MRI Brain <p>See also</p> <ul style="list-style-type: none"> • <u>Acoustic Neuroma (HD-33.1)</u> • <u>Peripheral Nerve Sheath Tumors (PN-9.1)</u>
Head trauma / Temporal Bone Fracture / Post-traumatic vertigo	<ul style="list-style-type: none"> • CT Head without contrast (CPT[®] 70450) <ul style="list-style-type: none"> ◦ See <u>Head Trauma (HD-13.1)</u> <p>AND/OR</p> <ul style="list-style-type: none"> • CT Orbit/Temporal bone without contrast (CPT[®] 70480)

Indications	Supported Imaging
Vertebrobasilar disease/ Vertebrobasilar Insufficiency/ Dissection	<ul style="list-style-type: none"> • CTA Head (CPT[®] 70496 AND/OR) • CTA Neck (CPT[®] 70498) <p>OR</p> <ul style="list-style-type: none"> • MRA Head (CPT[®] 70544, CPT[®] 70545, OR CPT[®] 70546) AND/OR • MRA Neck (CPT[®] 70547, CPT[®] 70548, or CPT[®]70549) <p>See also:</p> <ul style="list-style-type: none"> • <u>General Guidelines - CT and MR Angiography (CTA and MRA) (HD-1.5)</u> • <u>Headache and Suspected Vascular Dissection (HD-11.1)</u> • <u>Intracranial Aneurysms (HD-12.1)</u>
Semicircular canal dehiscence	<ul style="list-style-type: none"> • CT Orbit/Temporal bone without contrast (CPT[®] 70480)
Meniere's Disease	<ul style="list-style-type: none"> • MRI Brain without and with contrast (with IAC views) (CPT[®] 70553) OR without contrast (CPT[®] 70551) • Limited MRI Brain with attention to internal auditory canals (CPT[®] 70540, CPT[®] 70542, OR CPT[®] 70543) when requested by the provider in place of a complete MRI Brain

Background and Supporting Information

- Dizziness, a common complaint, with benign and dangerous causes, may be continuous, triggered, or spontaneous.
- For the continuously dizzy individual with nystagmus at the time of evaluation, a head impulse test and a test of skew should be performed to determine if dizziness is due to a peripheral cause or a posterior circulation stroke. Abnormalities on exam may be indications for imaging as detailed below.
- For triggered dizziness, positional testing such as the Dix-Hallpike maneuver, and/or orthostatic blood pressure measurements, should be performed. If symptoms are reproduced on examination, triggered dizziness is confirmed. Imaging as indicated in the relevant sections below.
- Spontaneous dizziness may be due to vestibular migraine, TIA, or Meniere's disease, among other causes. A detailed neurologic examination should be performed, and imaging as detailed below.
- The Dix-Hallpike maneuver should be performed or the individual should be referred to a clinician who could perform the procedure if Benign Paroxysmal Positional Vertigo (BPPV) is suspected.
- The Head Impulse Test (HIT) is also known as the Head thrust test. It is designed to evaluate the vestibular-ocular reflex in an individual with concern for a peripheral vestibulopathy due to ACUTE spontaneous vertigo. The individual is instructed to look at the examiner during the entire test. The individual's head is then quickly turned or rotated to one side and then the other. If normal, the individual's eyes should remain locked on the examiner. If abnormal, the eyes will move in the direction of the head rotation and then quickly correct. This saccade indicates peripheral vestibular hypofunction on the side of the direction that the head is turned. The HIT test is abnormal in individuals with vestibular neuronitis, and normal in individuals with a posterior circulation stroke.
- Posterior Canal BPPV (85%-95% of BPPV cases) is defined as:
 - Individual reports repeated episodes of vertigo with changes in head position relative to gravity.
 - Each of the following criteria is fulfilled on physical exam:
 - Vertigo associated with torsional (rotatory), upbeating (toward the forehead) nystagmus is provoked by the Dix-Hallpike test.
 - There is a latency period between the completion of the Dix-Hallpike maneuver and the onset of vertigo and nystagmus.
 - The provoked vertigo and nystagmus increase and then resolve within 60 seconds from the onset of the nystagmus.
- Lateral or Horizontal Canal BPPV (5%-15% of BPPV cases) will have horizontal or no nystagmus to which a supine roll test assess for this condition.
- Exclusions for Dix-Hallpike maneuver

- Individual previously diagnosed with BPPV and who on date of encounter in calendar year does not have positional dizziness or vertigo consistent with active BPPV
- Individual has declined Dix-Hallpike maneuver
- Individual has cervical spinal disease (i.e., cervical stenosis, severe kyphoscoliosis, limited cervical range of motion, Down's syndrome, severe rheumatoid arthritis, cervical radiculopathies, Paget's disease, ankylosing spondylitis, low back dysfunction, spinal cord injuries, spinal fractures)
- Individual unable to lay flat (i.e., severe heart disease)
- Individual has severe atherosclerotic disease or recent dissection involving the anterior or posterior cerebral circulation Unable to be seated in exam chair (i.e., morbidly obese), or maneuver cannot be safely performed given morbid obesity
- Ehlers Danlos/Marfans/Connective tissue disorder due to risk of cranio spinal instability/dissection
- Triggered episodic vestibular syndrome (t-EVS) usually last seconds to minutes with the most common triggers (vs. exacerbating factors) are head motion or change in body position. In the Emergency Department, benign paroxysmal positional vertigo (BPPV) is the second most common cause of t-EVS after orthostatic hypotension. Far lateral rotation of the neck leads to mechanical occlusion of one or both vertebral arteries causing temporary symptoms of vertigo and nystagmus when this position is maintained and may occur with the individual upright.
- Diagnoses or conditions associated with OH or nOH include: Parkinson Disease (PD), Multiple System Atrophy (MSA), Pure Autonomic Failure (PAF) or Dementia with Lewy Bodies (DLB), unexplained fall or syncope, peripheral neuropathies secondary to diabetes, amyloidosis and HIV), individuals ≥ 70 years of age and frail and on multiple medications and individuals with postural (orthostatic) dizziness or nonspecific symptoms that occur when standing. Symptoms may include: lightheadedness or dizziness, the sensation of blacking out, cognitive dysfunction, mental dulling, generalized weakness, neck pain or discomfort in the suboccipital and paracervical region (coat hanger) or playpnea (dyspnea while standing)
- Secondary or advanced laboratory testing is considered for use in select individuals for paraneoplastic syndromes (paraneoplastic panel) and serum and urine protein electrophoresis for monoclonal gammopathy for peripheral neuropathy.
 - See **Polyneuropathy (PN-3.1)** in the Peripheral Nerve Disorders Imaging Guidelines, **Multiple Myeloma and Plasmacytomas (ONC-25)** in the Oncology Imaging Guidelines, and **Paraneoplastic Syndromes (ONC-30.3)** in the Oncology Imaging Guidelines.
- Semicircular canal dehiscence (SCD) is a rare syndrome caused by dehiscence in the boney covering of the affected superior, posterior or lateral semicircular canal. When present, it can result in vestibular symptoms of vertigo associated with auditory

symptoms including oscillopsia evoked by noise and conductive hearing loss. The vestibular symptoms in SCD can be debilitating. Individuals may note that loud noises cause them to see things moving or that they experience a similar sensation when they cough, sneeze, or strain to lift something heavy. The signs of vestibular abnormalities in SCD relate directly to the effect of the dehiscence which has created a third mobile window of the inner ear. Some individuals have a conductive hearing loss for low-frequency sounds that can resemble the pattern in otosclerosis.

- Occlusive carotid artery disease does not cause fainting but rather causes focal neurologic deficits such as unilateral weakness. Thus, carotid imaging will not identify the cause of the fainting and increases cost. Fainting is a frequent complaint, affecting 40% of people during their lifetime.

Syncope (HD-23.2)

HD.DZ.0023.2.A

v3.0.2024

Indications	Supported Imaging
<p>Syncope with focal signs of a neurologic deficit</p> <p>OR</p> <p>Syncope without focal signs of a neurological deficit AND negative or inconclusive Electrocardiogram (EKG)</p>	<ul style="list-style-type: none"> • MRI Brain without contrast (CPT[®] 70551) OR • MRI Brain without and with contrast (CPT[®] 70553) OR • CT head without contrast (CPT[®] 70450) <p>AND/OR</p> <ul style="list-style-type: none"> • CTA head (CPT[®] 70496) OR • MRA head (CPT[®] 70544, CPT[®] 70545, or CPT[®] 70546) <p>AND/OR</p> <ul style="list-style-type: none"> • CTA neck (CPT[®] 70498) OR • MRA neck (CPT[®] 70547, CPT[®] 70548, or CPT[®] 70549)
<p>Recurrent syncope with risk of head injury or head trauma related to syncope^{6,15}</p>	<p>See Head Trauma (HD-13.1)</p>
<p>Situational syncope, including precipitating factors to syncope such as coughing, defecation, eating, laughing, or urination</p> <p>Myoclonic jerks without symptoms or signs associated with seizure, including but not limited to prolonged amnesia/confusion, tongue biting.</p>	<p>Advanced imaging is not indicated</p>
<p>Loss of consciousness with other symptoms or signs of seizure, including but not limited to, prolonged amnesia/ confusion, tongue biting, and/or urinary incontinence.</p>	<p>See Epilepsy/Seizure (HD-9.1)</p>

References (HD-23)

v3.0.2024

1. Runser LA, Gauer RL and Houser A. Syncope: Evaluation and Differential Diagnosis. *Am Fam Physician*. 2017;95(5):303-312
2. Expert Panel on Neurologic Imaging:, Sharma A, Kirsch CFE, et al. ACR Appropriateness Criteria® Hearing Loss and/or Vertigo. *J Am Coll Radiol*. 2018;15(11S):S321-S331. doi:10.1016/j.jacr.2018.09.020
3. Cheshire WP. Syncope. *CONTINUUM: Lifelong Learning in Neurology*. 2017;23(2):335-358. doi:10.1212/con.0000000000000444
4. Bhattacharyya N, Gubbels SP, Schwartz SR, et al. Clinical Practice Guideline: Benign Paroxysmal Positional Vertigo (Update). *Otolaryngology–Head and Neck Surgery*. 2017;156(3_suppl). doi:10.1177/0194599816689667
5. ACR-ASNR-SPR Practice Parameter for the Performance of Computed Tomography (CT) of the Extracranial Head and Neck Revised 2021. (Resolution 5). <https://www.acr.org/-/media/ACR/Files/Practice-Parameters/CT-Head-Neck>
6. Shen W-K, Sheldon RS, Benditt DG, et al. 2017 ACC/AHA/HRS Guideline for the Evaluation and Management of Patients With Syncope: A Report of the American College of Cardiology/American Heart Association Task Force on Clinical Practice Guidelines and the Heart Rhythm Society. *Circulation*. 2017;136(5). doi:10.1161/cir.0000000000000499
7. Basura GJ, Adams ME, Monfared A, et al. Clinical Practice Guideline: Ménière’s Disease. *Otolaryngology–Head and Neck Surgery*. 2020;162(2_suppl). doi:10.1177/0194599820909438
8. Gibbons CH, Schmidt P, Biaggioni I, et al. The recommendations of a consensus panel for the screening, diagnosis, and treatment of neurogenic orthostatic hypotension and associated supine hypertension. *Journal of Neurology*. 2017;264(8):1567-1582. doi:10.1007/s00415-016-8375-x
9. Choosing Wisely. An initiative of the ABIM Foundation. *American Academy of Neurology*. Released February 21, 2013; Last reviewed 2019
10. Choosing Wisely. An initiative of the ABIM Foundation. *American College of Emergency Physicians*. October 27, 2014
11. Scott JW, Schwartz AL, Gates JD, Gerhard#Herman M, Havens JM. Choosing Wisely for Syncope: Low#Value Carotid Ultrasound Use. *Journal of the American Heart Association*. 2014;3(4). doi:10.1161/jaha.114.001063
12. Dix-Hallpike maneuver performed for patients with BPPV. www.aan.com. <https://www.aan.com/policy-and-guidelines/quality/quality-measures2/quality-measures/other/dix-hallpike-maneuver-performed-for-patients-with-BPPV>
13. Baloh RW. Vestibular Migraine I: Mechanisms, Diagnosis, and Clinical Features. *Seminars in Neurology*. 2020;40(01):076-082. doi:10.1055/s-0039-3402735
14. Tehrani ASS, Kattah JC, Kerber KA, et al. Diagnosing Stroke in Acute Dizziness and Vertigo. *Stroke*. 2018;49(3):788-795. doi:10.1161/strokeaha.117.016979
15. Expert Panels on Cardiac Imaging and Neurological Imaging, Kligerman SJ, Bykowski J, et al. ACR Appropriateness Criteria® Syncope. *J Am Coll Radiol*. 2021;18(5S):S229-S238. doi:10.1016/j.jacr.2021.02.021
16. Shmueli S, et al. Differentiating Motor Phenomena in Tilt-Induced Syncope and Convulsive Seizures. *Neurology*. 2018;90:e1339-e1346. doi:10.1212/WNL.0000000000005301
17. Henderson FC, Austin C, Benzel E, et al. Neurological and spinal manifestations of the Ehlers-Danlos syndromes. *American journal of medical genetics Part C, Seminars in medical genetics*. 2017;175(1):195-211. doi:10.1002/ajmg.c.31549
18. Edlow JA, Gurley KL, Newman-Toker DE. A New Diagnostic Approach to the Adult Patient with Acute Dizziness. *The Journal of Emergency Medicine*. 2018;54(4):469-483. doi:10.1016/j.jemermed.2017.12.024
19. Edlow JA. The timing-and-triggers approach to the patient with acute dizziness. *Emerg Med Pract*. 2019 Dec;21(12):1-24. Epub 2019 Dec 1. PMID: 31765116
20. Krishnan K, Bassilious K, Eriksen E, et al. Posterior circulation stroke diagnosis using HINTS in patients presenting with acute vestibular syndrome: A systematic review. *European Stroke Journal*. Published online April 10, 2019;239698731984370. doi:10.1177/2396987319843701

21. Fife TD. Approach to the History and Evaluation of Vertigo and Dizziness. *CONTINUUM: Lifelong Learning in Neurology*. 2021;27(2):306-329. doi:10.1212/con.0000000000000938
22. Hain TC, Cherchi M. Vestibular Testing. *CONTINUUM: Lifelong Learning in Neurology*. 2021;27(2):330-347. doi:10.1212/con.0000000000000978
23. Steenerson KK. Acute Vestibular Syndrome. *CONTINUUM: Lifelong Learning in Neurology*. 2021;27(2):402-419. doi:10.1212/con.0000000000000958

Other Imaging Studies (HD-24)

Guideline

Transcranial Magnetic Stimulation (TMS) (HD-24.1)
Functional MRI (fMRI) (HD-24.2)
Magnetic Resonance Spectroscopy (MRS) (HD-24.3)
CSF Flow Imaging (HD-24.4)
CT or MRI Perfusion (HD-24.5)
Magnetic Resonance Neurography (MRN) (HD-24.6)
Cone Beam Computed Tomography (CBCT) (HD-24.7)
Transcranial Doppler (CPT[®] 93886) (HD-24.8)
References (HD-24)

Transcranial Magnetic Stimulation (TMS) (HD-24.1)

HD.OI.0024.1.U

v3.0.2024

In TMS, an electromagnetic coil placed on the surface of the skull overlying the motor cortex depolarizes the motor axons, creating a motor evoked potential (MEP), which is recorded via superficial skin electrodes as it passes through the upper and lower motor pathways to an innervated muscle.

TMS is currently considered not medically necessary.

Functional MRI (fMRI) (HD-24.2)

HD.OI.0024.2.A

v3.0.2024

- fMRI is useful in pre-operative scenarios to define the “eloquent” areas of brain
 - The ordering physician must be a neurologist, neurosurgeon or radiation oncologist or any provider in consultation with one of these specialists.
- Primary indications for fMRI include, but are not limited to, the following:
 - Assessment of intracranial neoplasm and other targeted lesions
 - Presurgical planning and operative risk assessment
 - Assessment of eloquent cortex (e.g., language, sensory, motor, visual centers) in relation to a tumor or another focal lesion
 - Surgical planning (biopsy or resection)
 - Therapeutic follow-up, as a one-time, post-operative, follow up study
 - Evaluation of preserved eloquent cortex
 - Assessment of eloquent cortex for epilepsy surgery
 - Assessment of radiation treatment planning and post-treatment evaluation of eloquent cortex
- fMRI is indicated with PET Brain in epilepsy surgery planning
- Procedure codes for functional MRI:
 - CPT[®] 70554 MRI Brain, functional MRI, including test selection and administration of repetitive body part movement and/or visual stimulation, not requiring physician or psychologist administration
 - CPT[®] 70555 MRI Brain, functional MRI; requiring physician or psychologist administration of entire neurofunctional testing
 - If MRA Head (CPT[®] 70544) is indicated but Functional MRI (CPT[®] 70554 or CPT[®] 70555) was erroneously ordered, then CPT[®] 70544 may be substituted when appropriate
- MRI Brain (CPT[®] 70551 or CPT[®] 70553) and/or fMRI (CPT[®] 70554 or CPT[®] 70555) are appropriate concurrently.
 - See **Unlisted Procedures/Therapy Treatment Planning (Preface-4.3)** in the Preface Imaging Guidelines if MRI Unlisted is requested for surgical planning

Magnetic Resonance Spectroscopy (MRS) (HD-24.3)

HD.OI.0024.3.A

v3.0.2024

- MRS (CPT[®] 76390) involves analysis of the levels of certain chemicals in a pre-selected voxels (small regions) on an MRI scan done at the same time.
- When conventional imaging by magnetic resonance imaging (MRI) or computed tomography (CT) provides limited information regarding specific clinical questions, indications for MRS in adults and children include, but are not limited to, the following and is evaluated on a case-by-case basis:
 - Distinguish recurrent brain tumor from radiation necrosis as an alternative to PET (CPT[®] 78608)
 - Diagnosis of certain rare inborn errors of metabolism affecting the CNS (primarily pediatric individuals)
 - Evidence or suspicion of primary or secondary neoplasm (pretreatment and posttreatment)
 - Grading of primary glial neoplasm, particularly high-grade versus low-grade glioma
 - Evidence or suspicion of brain infection, especially cerebral abscess (pretreatment and posttreatment) and HIV-related infections
 - Seizures, especially temporal lobe epilepsy

Background and Supporting Information

- Evaluation of certain primary brain tumors where diagnostic accuracy has been established in peer-reviewed literature.
 - See **Primary Central Nervous System Tumors – General Considerations (ONC-2.1)**, **Low Grade Gliomas (ONC-2.2)**, and **High Grade Gliomas (ONC-2.3)** in the Oncology Imaging Guidelines

CSF Flow Imaging (HD-24.4)

HD.OI.0024.4.A

v3.0.2024

- Pulse-gated MRI imaging or MRI CINE is generally performed as a part of a MRI Brain study. It is not coded separately for pre-operative evaluation of hydrocephalus, Chiari syndromes, Normal Pressure Hydrocephalus, Idiopathic Intracranial Hypertension (also known as pseudotumor cerebri), and spontaneous intracranial hypotension.
- There is no specific or unique procedure code for this study; it is done as a special sequence of a routine MRI Brain without contrast (CPT[®] 70551).
- If not previously performed as part of recent study, a second study for the purpose of evaluating CSF flow may be performed.

CT or MRI Perfusion (HD-24.5)

HD.OI.0024.5.A

v3.0.2024

- Performed as part of a CT Head or MRI Brain examination in the evaluation of individuals with very new strokes or brain tumors.
- CT perfusion study, if performed in conjunction with a CT angiogram of the intracranial and/or cervical vessels, can be performed before, after, or concurrent with the CT angiogram.
 - CTA Head and/or Neck is indicated in conjunction with the CT Perfusion study (CPT[®] 0042T).
- CPT[®] 0042T - “cerebral perfusion analysis using CT”.
 - To evaluation of acute stroke (<24 hours) to help identify individuals with stroke-like symptoms and to help identify those most likely to benefit from thrombolysis or thrombectomy
 - Follow up fo acute cerebral ischemic or infarction and/or reperfusion in the subacute or chronic phase of recovery
 - To assist in planning and evaluating the effectiveness of therapy for cervical or intracranial arterial occlusive disease (as an isolated test or in combination with a cerebrovascular reserve challenge) and/or chronic cerebral ischemia
 - Identifying cerebral hypoperfusion syndrome following revascularization
 - Evaluation of the vascular status of solid tumors where MRI is degraded due to susceptibility artifact from air-containing spaces, surgical clips, or dental work
 - Follow up of tumor response to therapy
- MRI Perfusion may be obtained with MRI Brain (CPT[®] 70551 OR CPT[®] 70552 OR CPT[®] 70553).
 - No additional CPT[®] codes are necessary or appropriate to perform MRI perfusion.⁹
- Indications for perfusion magnetic resonance imaging (MRI) MRI Perfusion (CPT[®] 70551 OR CPT[®] 70552 OR CPT[®] 70553)⁹ include the following:
 - Diagnosis and Characterization of Mass Lesions
 - Differential diagnosis (tumor versus tumor mimic)
 - Diagnosis of primary neoplasms (may include grading)
 - Surgical planning (biopsy or resection)
 - Targeting locations for biopsy
 - Guiding resection extent
 - Therapeutic follow-up
 - Radiation necrosis versus recurrent or residual tumor
 - Chemonecrosis versus recurrent or residual tumor

- Pseudoprogression and pseudoresponse
- Monitor potential transformation of non-resectable low grade neoplasms to higher grade
- Assessment of Neurovascular Disease
 - Acute stroke (assessment of ischemic penumbra)
 - Assessment of the hemodynamic significance of cervical or intracranial vascular stenosis
 - Assessment of cervical or intracranial revascularization efficacy
 - Assessment of vasospasm
- Other indications are usually regarded as not medically necessary.

Magnetic Resonance Neurography (MRN) (HD-24.6)

HD.OI.0024.6.A

v3.0.2024

- See **Magnetic Resonance Neurography (MRN) (PN-7.1)** in the Peripheral Nerve Disorders (PND) Imaging Guidelines.

Cone Beam Computed Tomography (CBCT) (HD-24.7)

HD.OI.0024.7.A

v3.0.2024

- CPT® Codes: CPT® 70486, CPT® 70487, CPT® 70488, CPT® 70480, CPT® 70482 (No separate 3-D rendering codes should be reported)
- An alternative to traditional CT imaging is in-office cone beam testing and possible decreased radiation dosage. The indications for office-based CT imaging are the same as for traditional scanners, and they should not be used for diagnosing or managing uncomplicated acute bacterial rhinosinusitis (ABRS).
- See **Temporomandibular Joint Disease (TMJ) (HD-30.1)** and **Dental/Periodontal/Maxillofacial Imaging (HD-30.2)**

Transcranial Doppler (CPT[®] 93886) (HD-24.8)

HD.OI.0024.8.A

v3.0.2024

- Transcranial Doppler (TCD) is a non-invasive ultrasonic technique that measures local blood flow velocity and direction in the proximal portions of intracranial and extracranial arteries

CPT Code	Description	Additional Notes
93886	Transcranial Doppler study of the intracranial arteries; complete study	
93888	Transcranial Doppler study of the intracranial arteries; limited study	
93890	Transcranial Doppler study of the intracranial arteries; vasoreactivity study	
93892	Transcranial Doppler study of the intracranial arteries; emboli detection without intravenous microbubble injection	
93893	Transcranial Doppler study of the intracranial arteries; emboli detection with intravenous microbubble injection	Report 93893 if the study is performed with intravenous microbubble injection. Transcranial Doppler studies described as “with contrast” are performed with intravenous microbubble injection. The bubbles serve to enhance ultrasound thus enabling better visualization of the intracranial arteries.

- Transcranial Doppler studies are ordered either as a single complete or limited study or as a combination of the complete or limited study with additional studies for further evaluation of the condition being investigated.
- Evaluation of Stroke/TIA usually includes CPT[®] 93886 and CPT[®] 93890 (Vasoreactivity study) and either CPT[®] 93892 or CPT[®] 93893 (Emboli detection).
 - Examples include:
 - Evaluation of right to left cardiac shunts: Detection of microemboli in individuals with stroke or TIA. (CPT[®] 93892 or CPT[®] 93893 added to CPT[®] 93886)
 - Evaluation of intracranial occlusive disease in individuals with documented stroke or TIA (CPT[®] 93890 added to CPT[®] 93886)
 - Evaluation of hemodynamic effects of known severe extra-cranial occlusive disease (CPT[®] 93890 added to CPT[®] 93886)
- TCD studies are indicated for the following:
 - Evaluation of severe stenosis or occlusion of the extracranial ($\geq 60\%$ diameter reduction) and major basal intracranial arteries ($\geq 50\%$ diameter reduction)
 - Detection and serial evaluation of cerebral vasospasm in subarachnoid hemorrhage
 - Evaluation of cerebral embolization including in COVID-19 and refractory encephalopathy
 - Assessing the extent of collateral circulation in individuals with known regions of severe stenosis or occlusion
 - To detect residual right to left shunting after repair/closure of an intracardiac or intrapulmonary shunt
 - Evaluation of AVM both pre- and post-surgical intervention.
 - Periprocedural monitoring to detect cerebral thrombosis, embolization, hypoperfusion, and hyperperfusion
 - Assessing the stroke risk in children aged two to sixteen with homozygous sickle cell disease
 - Annual screening for individuals with Sickle Cell Anemia (Hb-SS) and Sickle Beta Thalassemia (S β) (CPT[®] 93886) up to the age of 16.
- TCD studies are not indicated for evaluation of:
 - Brain tumors
 - Familial and degenerative disease of the brain
 - Psychiatric disorders
 - Epilepsy
 - Migraine or other primary headache disorders
 - Infectious and inflammatory conditions

Background and Supporting Information

- Transcranial Doppler (TCD) ultrasound provides rapid, non-invasive, real time measure of cerebrovascular function.
- TCD can be used to measure flow velocity in the proximal cerebral arteries to assess relative changes in flow, diagnose focal vascular stenosis, or to detect embolic signals within these arteries.
- TCD can be used to measure blood flow responses to changes in blood pressure (cerebral autoregulation), changes in end-tidal CO₂ (cerebral vasoreactivity), or cognitive and motor activation (neurovascular coupling or functional hyperemia).
- A technical limitation of TCD includes inadequate temporal bone acoustic windows due to a thickened skull which limits ultrasound penetration
- Studies are ongoing regarding the use of TCD in the evaluation of dementia and psychiatric conditions such as depression.
- CPT[®] 93890, CPT[®] 93892, CPT[®] 93893 represent add on services that require additional expertise, lab time, and equipment not included in the complete and limited codes. These additional codes may be appropriate during the same encounter if medical necessity is documented.
- CPT[®] 93890 Vasoreactivity Study: Measures response of cerebral blood flow to increased CO₂ levels (following breath holding or administration of acetazolamide); It is used to evaluate risk of stroke and significance of carotid stenosis; individuals with loss of normal reactive changes are likely to be at increased risk of stroke.
- CPT[®] 93892/CPT[®] 93893: Identification of right to left shunts (microembolic signals may be detected during TCD monitoring) and may indicate source of emboli in individuals with stroke or TIA. TCD bubble test is very sensitive and may be superior to transthoracic and transesophageal echocardiography in detection of right to left shunts.
- Transcranial Doppler (TCD) is considered not medically necessary for the following indications:
 - Assessing individuals with migraine;
 - Monitoring during cardiopulmonary bypass and other cerebrovascular and cardiovascular interventions, and surgical procedures (except during carotid endarterectomy, as noted above);
 - Evaluation of individuals with dilated vasculopathies such as fusiform aneurysms;
 - Assessing autoregulation, physiologic, and pharmacological responses of cerebral arteries; and/or
 - Evaluating children with various vasculopathies, such as moyamoya disease and neurofibromatosis.

References (HD-24)

v3.0.2024

1. Tsvigoulis G, Alexandrov AV. Ultrasound in Neurology. *CONTINUUM: Lifelong Learning in Neurology*. 2016;22(5):1655-1677. doi:10.1212/con.0000000000000374
2. *PRACTICE PARAMETER CT_Perfusion*. <https://www.acr.org/-/media/ACR/Files/Practice-Parameters/ct-perfusion.pdf>
3. Connolly ES, Rabinstein AA, Carhuapoma JR, et al. Guidelines for the Management of Aneurysmal Subarachnoid Hemorrhage. *Stroke*. 2012;43(6):1711-1737. doi:10.1161/str.0b013e3182587839
4. ACR-ASNR-SPR Practice Parameter for the Performance of Computed Tomography (CT) of the Extracranial Head and Neck Revised 2021. (Resolution 5). <https://www.acr.org/-/media/ACR/Files/Practice-Parameters/CT-Head-Neck>
5. Demeestere J, Wouters A, Christensen S, Lemmens R, Lansberg MG. Review of Perfusion Imaging in Acute Ischemic Stroke. *Stroke*. 2020;51(3):1017-1024. doi:10.1161/strokeaha.119.028337
6. *PRACTICE PARAMETER Transcranial Doppler Ultrasound*. <https://www.acr.org/-/media/ACR/Files/Practice-Parameters/us-transcranial.pdf?la=en>
7. *PRACTICE PARAMETER FMRI*. <https://www.acr.org/-/media/ACR/Files/Practice-Parameters/fmr-brain.pdf?la=en>
8. *PRACTICE PARAMETER 1 MR Spectroscopy*. <https://www.acr.org/-/media/ACR/Files/Practice-Parameters/mr-spectroscopy.pdf?la=en>
9. ACR-ASNR-SPR PRACTICE PARAMETER FOR THE PERFORMANCE OF INTRACRANIAL MAGNETIC RESONANCE PERFUSION IMAGING. Revised 2022 (Resolution 24). *PRACTICE PARAMETER MR_Perfusion*. <https://www.acr.org/-/media/ACR/Files/Practice-Parameters/mr-perfusion.pdf?la=en>
10. Bradley WG. Magnetic Resonance Imaging of Normal Pressure Hydrocephalus. *Seminars in Ultrasound, CT and MRI*. 2016;37(2):120-128. doi:10.1053/j.sult.2016.01.005
11. Farb R, Rovira À. Chapter 2: Hydrocephalus and CSF Disorders. In: Hodler J, Kubik-Huch RA, von Schulthess GK, eds. *Hydrocephalus and CSF Disorders--Diseases of the Brain, Head and Neck, Spine 2020-2023: Diagnostic Imaging*. 2020 Feb 15
12. Antipova D, Eadie L, Macaden AS, Wilson P. Diagnostic value of transcranial ultrasonography for selecting subjects with large vessel occlusion: a systematic review. *The Ultrasound Journal*. 2019;11(1). doi:10.1186/s13089-019-0143-6
13. Batra A, Clark JR, LaHaye K, et al. Transcranial Doppler Ultrasound Evidence of Active Cerebral Embolization in COVID-19. *Journal of Stroke and Cerebrovascular Diseases*. 2021;30(3):105542. doi:10.1016/j.jstrokecerebrovasdis.2020.105542
14. Purkayastha S, Sorond F. Transcranial Doppler Ultrasound: Technique and Application. *Seminars in neurology*. 2012;32(4):411-420. doi:10.1055/s-0032-1331812
15. Feng Y, Su X, Zheng C, Lu Z. The Noninvasive Diagnostic Value of MRN for CIDP: A Research from Qualitative to Quantitative. *Spine*. 2020;45(21):1506-1512. doi:10.1097/brs.0000000000003599
16. AIUM Practice Guideline for the Performance of a Transcranial Doppler Ultrasound Examination for Adults and Children. *Journal of Ultrasound in Medicine*. 2012;31(9):1489-1500. doi:10.7863/jum.2012.31.9.1489
17. Expert Panel on Pediatric Imaging, Robertson RL, Palasis S, et al. ACR Appropriateness Criteria® Cerebrovascular Disease-Child. *J Am Coll Radiol*. 2020;17(5S):S36-S54. doi:10.1016/j.jacr.2020.01.036
18. McGirr A, Vila-Rodriguez F, Cole J, et al. Efficacy of Active vs Sham Intermittent Theta Burst Transcranial Magnetic Stimulation for Patients With Bipolar Depression. *JAMA Network Open*. 2021;4(3):e210963. doi:10.1001/jamanetworkopen.2021.0963
19. Lacomis D, Gooch C. Upper motor neuron assessment and early diagnosis in ALS. *Neurology*. 2019;92(6):255-256. doi:10.1212/wnl.0000000000006867
20. Rosenfeld RM, Piccirillo JF, Chandrasekhar SS, et al. Clinical Practice Guideline (Update): Adult Sinusitis. *Otolaryngology-Head and Neck Surgery*. 2015;152(2_suppl):S1-S39. doi:10.1177/0194599815572097

Epistaxis (HD-25)

Guideline

Epistaxis (HD-25.1)

References (HD-25)

Epistaxis (HD-25.1)

HD.EX.0025.1.A

v3.0.2024

- After initial nasal endoscopy by ENT, if there are findings suspicious for a mass lesion:
 - CT Maxillofacial without or with contrast (CPT[®] 70486 or CPT[®] 70487) **AND/OR**
 - MRI Orbit, Face, and/or Neck without and with contrast (CPT[®] 70543)
- Patients who have failed initial management with cauterization and packing and have persistent or recurrent epistaxis despite primary interventions, should be referred to a clinician who can evaluate for candidacy for surgical ligation or endovascular embolization.³
- Prior to embolization with surgical or endovascular technique, CT Maxillofacial (without contrast CPT[®] 70486 or without contrast CPT[®] 70487), is supported when requested by the clinician performing embolization or referring for embolization. If endovascular embolization is planned, CTA Head (CPT[®] 70496) **AND/OR** CTA Neck (CPT[®] 70498) may be requested ahead of the interventional radiologic procedure.⁵

Background and Supporting Information

The American Academy of Otolaryngology Head and Neck Surgery recommend, in its most recent 2020 Clinical Practice Guidelines on Epistaxis, that the clinician should perform, or should refer to a clinician who can perform, nasal endoscopy to identify the site of bleeding and guide further management in patients with recurrent nasal bleeding, despite prior treatment with packing or cautery, or with recurrent unilateral nasal bleeding. No recommendations for advanced imaging are outlined in this Guideline without the exam findings (anterior rhinoscopy and/or nasal endoscopy) or the procedural needs of the patient indicating the need for such studies. If anterior rhinoscopy does not reveal the source of bleeding, it is recommended that the clinician perform nasal endoscopy, or refer to a clinician who can perform nasal endoscopy, first.³

Embolization procedures have shown an average nosebleed control rate of 87%, with minor transient complications in 20% (transient nasal ischemia, temporal-facial pain or numbness, headache, swelling, jaw claudication, trismus, and access site complications not requiring additional therapy) and major complications in up to 2.1% to 3.8% (skin/nasal necrosis, permanent facial nerve paralysis, monocular blindness, and stroke).

Detailed angiography, including internal and external carotid angiography, and precise embolization techniques are required. Despite use of meticulous techniques and knowledge of external carotid-internal carotid anastomoses, blindness and stroke are the most feared complications of endovascular embolization. These complications are rare but are more frequent than in patients undergoing surgical arterial ligation. In one

study, similar transient ischemic attacks are demonstrated across all groups but there is increased risk of stroke in the groups who underwent endovascular embolization alone (0.9%) or combined with surgical ligation (1.6%) as compared with surgical ligation alone (0.1%).^{3,4,5}

References (HD-25)

v3.0.2024

1. Expert Panel on Neurologic Imaging.; Kirsch CFE, Bykowski J, et al. ACR Appropriateness Criteria® Sinusoidal Disease. *J Am Coll Radiol*. 2017;14(11S):S550-S559. doi:10.1016/j.jacr.2017.08.041
2. ACR-ASNR-SPR Practice Parameter for the Performance of Computed Tomography (CT) of the Extracranial Head and Neck Revised 2021. (Resolution 5). <https://www.acr.org/-/media/ACR/Files/Practice-Parameters/CT-Head-Neck>
3. Tunkel DE, Anne S, Payne SC, et al. Clinical Practice Guideline: Nosebleed (Epistaxis). *Otolaryngology–Head and Neck Surgery*. 2020;162(1_suppl). doi:10.1177/0194599819890327
4. Strach K, Schröck A, Wilhelm K, et al. Endovascular treatment of epistaxis: indications, management, and outcome. *Cardiovasc Intervent Radiol*. 2011;34(6):1190-1198. doi:10.1007/s00270-011-0155-5
5. Brinjikji W, Kallmes DF, Cloft HJ. Trends in epistaxis embolization in the United States: a study of the Nationwide Inpatient Sample 2003-2010. *J Vasc Interv Radiol*. 2013;24(7):969-973. doi:10.1016/j.jvir.2013.02.035

Mastoid Disease or Ear Pain (HD-26)

Guideline

Mastoid Disease or Ear Pain (HD-26.1)

References (HD-26)

Mastoid Disease or Ear Pain (HD-26.1)

HD.MA.026.1.A

v3.0.2024

A pertinent clinical evaluation including a detailed history, physical examination (including otoscopic examination), must be performed on any individual with ear pain prior to considering advanced imaging. Common causes of ear pain include external and middle ear infections, dental problems, sinus infection, neck problems, tonsillitis, and pharyngitis.

Indications (Any one of the following)	Supported Imaging
<ul style="list-style-type: none"> • Persistent ear pain without obvious cause • Clinical suspicion for complicated or invasive infection such as mastoiditis • Clinical suspicion for complications from otitis media • Clinical suspicion of mass lesion causing ear pain • Significant trauma with concern for hematoma formation • Pre-operative planning 	<ul style="list-style-type: none"> • CT Orbits/Temporal Bone without contrast (CPT[®] 70480) OR • CT Orbits/Temporal Bone without and with contrast (CPT[®] 70482) OR • MRI Brain without and with contrast with attention to internal auditory canals (CPT[®] 70553) OR • MRI Orbits/Face/Neck without and with contrast (CPT[®] 70543)

- Advanced imaging is not indicated in the overwhelming majority of individuals with ear pain.
- Advanced imaging for the diagnosis and management of suspected cholesteatoma, in particular, should be reserved for the otolaryngologist or in consultation with the otolaryngologist
- Imaging indicated for pre-operative evaluation for cholesteatoma surgery:
 - CT Orbits/Temporal Bone without contrast (CPT[®] 70480) **OR**
 - CT Orbits/Temporal Bone without and with contrast (CPT[®] 70482) **AND/OR**
 - MRI Brain without and with contrast with attention to internal auditory canals (CPT[®] 70553) **OR**
 - MRI Orbits/Face/Neck without and with contrast (CPT[®] 70543)
- Indicated one time post-operatively to exclude residual or regrown cholesteatoma to avoid the need for a second-look surgery:
 - CT Orbits/Temporal Bone without contrast (CPT[®] 70480) **OR**
 - CT Orbits/Temporal Bone without and with contrast (CPT[®] 70482) **AND/OR**

- MRI Brain without and with contrast with attention to internal auditory canals (CPT[®] 70553), **OR**
- MRI Orbits/Face/Neck without and with contrast (CPT[®] 70543)
- Eustachian Tube Dilation:(endoscopic balloon dilatation of the Eustachian Tube, to treat persistent Eustachian tube dysfunction)^{3,4}
 - CT Orbit/Temporal Bone without contrast (CPT[®] 70480) can be approved for pre-operative evaluation of possible aberrant carotid
- Concern for Petrous Apex Lesions when requested by the Otolaryngologist or in consultation with the Otolaryngologist, the following are supported⁶ :
 - CT Orbit/Temporal bone without contrast (CPT[®] 70480) **OR**
 - CT Orbit/Temporal bone without and with contrast (CPT[®] 70482) **AND/OR**
 - MRI Brain without and with contrast (CPT[®] 70553) **OR**
 - MRI Orbits/Face/Neck without or with contrast (CPT[®] 70543)
- For concern related to non-resolving otalgia with chronic otorrhea:
 - See **Skull Base Osteomyelitis (SBO) (HD-20.2)**

Background and Supporting Information

- Common causes of ear pain include external and middle ear infections, dental problems, sinus infection, neck problems, and referred pain from the oral pharynx.
- Clinical suspicion for complications from otitis media such as coalescent mastoiditis, resulting in: subperiosteal abscess formation/Bezold's abscess, acute facial nerve paralysis, and intracranial abscess formation.
- Cholesteatomas are expansive cysts of the middle ear filled with cellular debris. They can be congenital or arise from recurrent middle ear infections or trauma to the tympanic membrane. Hearing loss is usually conductive, although if the lesion is large enough combined conductive and sensorineural hearing loss may be present. Otoscopic exam findings and symptoms may include a white mass in the middle ear cleft, painless drainage from the ear or chronic/recurrent ear infections.
- Petrous apex lesions/infections may include: cholesteatoma, cephalocele, mucocele, and cholesterol granuloma and can present with symptoms of pain, hearing loss, headache, vertigo, and Cranial nerve insults(including CN V VI, VII, IX, X, XI).

References (HD-26)

v3.0.2024

1. ACR-ASNR-SPR Practice Parameter for the Performance of Computed Tomography (CT) of the Extracranial Head and Neck Revised 2021. (Resolution 5). <https://www.acr.org/-/media/ACR/Files/Practice-Parameters/CT-Head-Neck>
2. Rosenfeld RM, Shin JJ, Schwartz SR, et al. Clinical Practice Guideline: Otitis Media with Effusion (Update). *Otolaryngology–Head and Neck Surgery*. 2016;154(1_suppl):S1-S41. doi:10.1177/0194599815623467
3. Micucci S, Keschner DB, Liang J. Eustachian Tube Balloon Dilation: Emerging Practice Patterns for a Novel Procedure. *Ann Otol Rhinol Laryngol*. 2018 Nov;127(11):848-855. doi: 10.1177/0003489418798858.
4. Tucci DL, McCoul ED, Rosenfeld RM, Tunkel DE, Batra PS, Chandrasekhar SS, Cordes SR, Eshraghi AA, Kaylie D, Lal D, Lee J, Setzen M, Sindwani R, Syms CA 3rd, Bishop C, Poe DS, Corrigan M, Lambie E. Clinical Consensus Statement: Balloon Dilation of the Eustachian Tube. *Otolaryngol Head Neck Surg*. 2019 Jul;161(1):6-17. doi: 10.1177/0194599819848423.
5. Treviño González JL, Reyes Suárez LL, Hernández de León JE. Malignant otitis externa: An updated review. *Am J Otolaryngol*. 2021 Mar-Apr;42(2):102894. doi: 10.1016/j.amjoto.2020.102894. Epub 2021 Jan 5. PMID: 33429178
6. Potter GM, Siripurapu R. Imaging of Petrous Apex Lesions. *Neuroimaging Clin N Am*. 2021;31(4):523-540. doi:10.1016/j.nic.2021.06.005

Hearing Loss and Tinnitus (HD-27)

Guideline

Hearing Loss (HD-27.1)

Tinnitus (HD-27.2)

References (HD-27)

Hearing Loss (HD-27.1)

HD.HL.0027.1.A

v3.0.2024

- An initial evaluation including hearing tests, by bedside testing or by formal audiology, is necessary to determine whether an individual's hearing loss is conductive (external or middle ear structures) or sensorineural (inner ear structures, such as cochlea or auditory nerve) hearing loss. See **General Guidelines (HD-1.0)**
- CT Orbits/Temporal Bone without (CPT[®] 70480) **OR** MRI Brain without and with contrast (with IAC views) (CPT[®] 70553) **OR** MRI Brain without contrast (CPT[®] 70551):
 - Mixed conductive (MC)/Sensorineural (SN) hearing loss or any sensorineural hearing loss (MRI generally preferred for SN - See **Background and Supporting Information**)
 - Unilateral fluctuating or asymmetric hearing loss
 - Cholesteatoma (see **Mastoid Disease or Ear Pain (HD-26.1)**)
 - Congenital hearing loss
 - Surgical planning, including cochlear implants (both CT Temporal Bone and MRI Brain for surgical planning if requested by surgeon or any provider in consultation with the surgeon)
 - Hearing loss with vertigo (see **Dizziness/Vertigo (HD-23.1)**)
- CT Orbits/Temporal Bone without contrast (CPT[®] 70480):
 - Conductive hearing loss should have a CT Temporal Bone initially in the absence of an evident mass in the middle ear
- CT Orbits/Temporal Bone with contrast (CPT[®] 70481):
 - Glomus tumors or other vascular tumors of the middle ear, and/or surgical planning
 - Acquired sensorineural hearing loss if MRI unavailable or contraindicated
- Limited MRI Brain with attention to internal auditory canals (CPT[®] 70540, CPT[®] 70542, or CPT[®] 70543) when requested by the provider in place of a complete MRI Brain. Note: Limited MRI codes should not be used in addition to MRI Brain codes; IAC views are performed as additional sequences as part of the brain study (see **General Guidelines – Anatomic Issues (HD-1.1)**)

Background and Supporting Information

- Sensorineural (SN) hearing loss – MRI is generally preferable to CT. CT Temporal bone is indicated in post-traumatic SN hearing loss, to evaluate for bony remodeling of the IAC due to vestibular schwannoma and labyrinthine ossification resulting from prior infection and for consideration of otospongiosis, a common cause of MC and SN hearing loss.

Tinnitus (HD-27.2)

HD.HL.0027.2.A

v3.0.2024

- A hearing evaluation is not required prior to imaging for tinnitus.
- The history in individuals with tinnitus should include a description of the tinnitus (episodic or constant, pulsatile or non-pulsatile, rhythmicity, pitch, quality of the sound), as well as inciting or alleviating factors. Continuous and pulsatile tinnitus are more concerning for an underlying and significant disorder. Audiometric assessment can be used as initial diagnostic testing particularly in individuals with tinnitus that is unilateral, persistent (>6 months) or associated with hearing difficulties (see **General Guidelines (HD-1.0)**)

Indications (Any one of the following) ^{1,5,6}	Supported Imaging
<ul style="list-style-type: none"> • Clinical suspicion of mass lesion causing tinnitus • Asymmetric or unilateral non-pulsatile tinnitus (i.e tinnitus that localizes to one ear) • Tinnitus associated with focal neurologic abnormalities, including asymmetric hearing loss • Persistent tinnitus after recent significant trauma. • Pulsatile tinnitus with or without concern for vascular lesion 	<ul style="list-style-type: none"> • CT Orbits/Temporal Bone without contrast (CPT[®] 70480) OR • CT Orbits/Temporal Bone without and with contrast (CPT[®] 70482) OR • MRI Brain without and with contrast with attention to internal auditory canals (CPT[®] 70553) OR • MRI Brain without contrast with attention to internal auditory canals (CPT[®] 70551) OR • MRI Orbits/Face/Neck without contrast (CPT[®] 70540), with contrast CPT[®] 70542, or without and with contrast (CPT[®] 70543)
<ul style="list-style-type: none"> • Pulsatile tinnitus • Suspicion for vascular lesions 	<ul style="list-style-type: none"> • MRA Head (CPT[®] 70544, CPT[®] 70545 OR CPT[®] 70546) OR • CTA Head (CPT[®] 70496) AND/OR • MRA Neck (CPT[®] 70547, CPT[®] 70548 or CPT[®] 70549) OR • CTA Neck (CPT[®] 70498)

- Imaging not supported for bilateral non-pulsatile tinnitus without other neurologic signs or symptoms⁶
- Limited MRI Brain with attention to internal auditory canals (CPT[®] 70540, CPT[®] 70542, or CPT[®] 70543) when requested by the provider in place of a complete MRI

Brain. Note: Limited MRI codes should not be used in addition to MRI Brain codes; IAC views are performed as additional sequences as part of the brain study (see **General Guidelines – Anatomic Issues (HD-1.1)**)

- CT and MR Venography (CTV and MRV) are reported with the same codes as the CTA/MRA counterpart. If arterial and venous CT or MR studies are both performed in the same session, only one CPT[®] code should be used to report both procedures.

Background and Supporting Information

- Non-pulsatile tinnitus may be described as ringing, buzzing, or clicking sensations which is constant and non-synchronous.
- Pulsatile tinnitus is a repetitive sound coinciding with the individual's heartbeat. The symptom may be subjective or objective.

References (HD-27)

HD.HL.0027.3.A

v3.0.2024

1. Expert Panel on Neurologic Imaging: Sharma A, Kirsch CFE, et al. ACR Appropriateness Criteria® Hearing Loss and/or Vertigo. *J Am Coll Radiol*. 2018;15(11S):S321-S331. doi:10.1016/j.jacr.2018.09.020
2. Isaacson J, Vora NM. Differential diagnosis and treatment of hearing loss. *American Family Physician*. 2003 Sep 15;68(6):1125-32
3. Chandrasekhar SS, Do BST, Schwartz SR, et al. Clinical Practice Guideline: Sudden Hearing Loss (Update). *Otolaryngology–Head and Neck Surgery*. 2019;161(1_suppl). doi:10.1177/0194599819859885
4. ACR-ASNR-SPR Practice Parameter for the Performance of Computed Tomography (CT) of the Extracranial Head and Neck Revised 2021. (Resolution 5). <https://www.acr.org/-/media/ACR/Files/Practice-Parameters/CT-Head-Neck>
5. Expert Panel on Neurologic Imaging: Jain, V, Policeni B, et al. ACR Appropriateness Criteria® Tinnitus. 2023 <https://acsearch.acr.org/docs/3094199/Narrative/>
6. Tunkel DE, Bauer CA, Sun GH, Rosenfeld RM, Chandrasekhar SS, Cunningham ER Jr, Archer SM, Blakley BW, Carter JM, Granieri EC, Henry JA, Hollingsworth D, Khan FA, Mitchell S, Monfared A, Newman CW, Omole FS, Phillips CD, Robinson SK, Taw MB, Tyler RS, Waguespack R, Whamond EJ. Clinical practice guideline: tinnitus executive summary. *Otolaryngol Head Neck Surg*. 2014 Oct;151(4):533-41. doi: 10.1177/0194599814547475

Neurosurgical Imaging (HD-28)

Guideline

Neurosurgical Imaging (HD-28.1)
Neuronavigation (HD-28.2)
Post Operative Imaging (HD-28.3)
References (HD-28)

Neurosurgical Imaging (HD-28.1)

HD.NI.0028.1.A

v3.0.2024

- Typically advanced imaging for monitoring disease for mass lesions occurs after biopsy (histologic) confirmation. This ensures appropriate determination related to phase of oncology imaging and alignment to appropriate diagnosis-specified guideline section.
 - However, repeat imaging by neurosurgeons or others of the management team for areas of the central nervous system (CNS) where permanent neurologic damage would be excessive with even a limited biopsy attempt is supported.
 - Examples would include, but are not exclusive to: medically fragile individual, and tumors of the brainstem, eloquent areas of the brain, deep gray matter areas of the brain (ex. thalamus), and cavernous sinus.
- Repeat diagnostic head imaging:
 - Previous diagnostic head imaging is determined to be inadequate or additional imaging sequences/protocols are required by the neurosurgeon or the treatment team
 - Prior imaging is greater than 6 months old

Neuronavigation (HD-28.2)

HD.NI.0028.2.U

v3.0.2024

- Neurosurgical navigation is "image-based" meaning that the necessary pre-operative CT and MRI images are used for navigation in the operating room (image acquisition). Accurate registration (a process to match the pre-operative images to the individual position) of pre-operative images is necessary to guide surgery regardless of the navigation system that is used. Registration can be point-based or surface matched routines to allow the surgeon to view the overlapping data sets and the current situation to allow navigation.
- The process of registration for neuronavigation via the acquisition of pre-operative CT and MRI images does not require a radiologist interpretation.
 - Diagnostic imaging codes are not indicated for the purpose of registration for neuronavigation.
 - Can be referenced by proprietary brand systems such as Brainlab or Stealth imaging procedures
 - See **Unlisted Procedures/Therapy Treatment Planning (Preface-4.3)** in the Preface Imaging Guidelines and **Unlisted Procedure Codes (ONC-1.5)** in Oncology in the Oncology Imaging Guidelines
- Advanced imaging for neuronavigation (image acquisition for registration for surgery) with one of each of the following as unlisted codes apply:
 - Unlisted MRI procedure code (CPT[®] 76498)
 - Unlisted CT procedure code (CPT[®] 76497)
 - Due to variances with techniques currently available for neuronavigation, the following are indicated:
 - CTA Head without and with contrast (CPT[®] 70496) or MRA Head (CPT[®] 70544, CPT[®] 70545 or CPT[®] 70546) (to avoid arterial and venous structures)
 - 3D (CPT[®] 76377 or CPT[®] 76376) (see **General Guidelines - Other Imaging Situations (HD-1.7)**)
 - Diagnostic imaging codes are only indicated if radiological supervision and interpretation of imaging is necessary with supporting documentation
 - MRI Brain without contrast (CPT[®] 70551), or MRI Brain with contrast (CPT[®] 70552), or MRI Brain without and with contrast (CPT[®] 70553) (contrast as requested) **AND/OR** CT Head without contrast (CPT[®] 70450), or CT Head with contrast (CPT[®] 70460), or CT Head without and with contrast (CPT[®] 70470) (contrast as requested)

Post Operative Imaging (HD-28.3)

HD.NI.0028.3.A

v3.0.2024

- Post-operative imaging including MRI Brain without contrast (CPT[®] 70551), or MRI Brain with contrast (CPT[®] 70552), or MRI Brain without and with contrast (CPT[®] 70553) (contrast as request) or CT Head without contrast (CPT[®] 70450), or CT Head with contrast (CPT[®] 70460), or CT Head without and with contrast (CPT[®] 70470) (contrast as request) per neurosurgeon's or in concert with management team's request that includes, but not exclusive to:
 - Within 24-72 hours following brain surgery including to document the need for repeat surgery or if adjuvant intervention is necessary, concern or rule out for complication(s), evaluation if incomplete resection vs. consideration for plan for gross resection
 - Signs or symptoms indicating concern of clinical deterioration
 - Development of new neurological signs or symptoms
 - Follow-up on blood products, edema, and/or concern of cerebrospinal fluid leak
 - Follow up imaging per condition-based guideline
- See additional condition-based guidelines:
 - Pediatric Neurosurgeries
 - See **Special Imaging Studies in Evaluation for Epilepsy Surgery (PEDHD-6.3)** in the Pediatric Head Imaging Guidelines
 - See **Modality General Considerations (PEDONC-1.3)** and **Pediatric CNS Tumors (PEDONC-4)** in the Pediatric Oncology Guidelines
 - Epilepsy.
 - See **Presurgical Work-Up for Drug-Resistant Epilepsy (HD-9.2)**
 - Movement Disorders
 - See **Movement Disorders (HD-15.1)**
 - Pituitary or Sella Surgery.
 - See **Pituitary (HD-19.1)**
 - Acoustic Neuroma and Other Cerebellopontine Angle Tumors
 - See **Acoustic Neuroma and Other Cerebellopontine Angle Tumors (HD-33.1)**
 - Central Nervous System Tumors
 - See **Primary Central Nervous System Tumors (ONC-2)** and **Brain Metastases (ONC-31.3)** in the Oncology Imaging Guidelines

References (HD-28)

v3.0.2024

1. Orringer DA, Golby A, Jolesz F. Neuronavigation in the surgical management of brain tumors: current and future trends. *Expert Review of Medical Devices*. 2012;9(5):491-500. doi:10.1586/erd.12.42
2. Rughani A, Schwalb JM, Sidiropoulos C, et al. Congress of Neurological Surgeons Systematic Review and Evidence-Based Guideline on Subthalamic Nucleus and Globus Pallidus Internus Deep Brain Stimulation for the Treatment of Patients With Parkinson's Disease: Executive Summary. *Neurosurgery*. 2018;82(6):753-756. doi:10.1093/neuros/nyy037
3. Kotecha R, Sahgal A, Rubens M, et al. Stereotactic radiosurgery for non-functioning pituitary adenomas: meta-analysis and International Stereotactic Radiosurgery Society practice opinion. *Neuro-Oncology*. 2019;22(3):318-332. doi:10.1093/neuonc/noz225
4. Xiao Y, Lau JC, Hemachandra D, Gilmore G, Khan AR, Peters TM. Image Guidance in Deep Brain Stimulation Surgery to Treat Parkinson's Disease: A Comprehensive Review. *IEEE Transactions on Biomedical Engineering*. 2021;68(3):1024-1033. doi:10.1109/tbme.2020.3006765
5. Delev D, Quesada CM, Grote A, et al. A multimodal concept for invasive diagnostics and surgery based on neuronavigated voxel-based morphometric MRI postprocessing data in previously nonlesional epilepsy. *Journal of Neurosurgery*. 2018;128(4):1178-1186. doi:10.3171/2016.12.jns161676
6. Yang I, Udawatta M, Prashant GN, et al. Stereotactic Radiosurgery for Neurosurgical Patients: A Historical Review and Current Perspectives. *World Neurosurgery*. 2019;122:522-531. doi:10.1016/j.wneu.2018.10.193
7. ACR-ASNR-SPR Practice Parameter for the Performance of Computed Tomography (CT) of the Extracranial Head and Neck Revised 2021. (Resolution 5). <https://www.acr.org/-/media/ACR/Files/Practice-Parameters/CT-Head-Neck>
8. Fitzpatrick JM. The role of registration in accurate surgical guidance. *Proceedings of the Institution of Mechanical Engineers, Part H: Journal of Engineering in Medicine*. 2009;224(5):607-622. doi:10.1243/09544119jeim589
9. Maurer CR, Fitzpatrick JM, Wang MY, Galloway RL, Maciunas RJ, Allen GS. Registration of head volume images using implantable fiducial markers. *IEEE Transactions on Medical Imaging*. 1997;16(4):447-462. doi:10.1109/42.611354
10. Pfisterer WK, Papadopoulos S, Drumm DA, Smith K, Preul MC. Fiducial Versus Nonfiducial Neuronavigation Registration Assessment and Considerations of Accuracy. *Operative Neurosurgery*. 2008;62(suppl_1):ONS201-ONS208. doi:10.1227/01.neu.0000317394.14303.99
11. Gumprecht HK, Widenka DC, Lumenta CB. Brain Lab VectorVision Neuronavigation System: Technology and Clinical Experiences in 131 Cases. *Neurosurgery*. 1999;44(1):97-104. doi:10.1097/00006123-199901000-00056
12. Grunert P, Darabi K, Espinosa J, Filippi R. Computer-aided navigation in neurosurgery. *Neurosurgical Review*. 2003;26(2):73-99. doi:10.1007/s10143-003-0262-0
13. Mezger U, Jendrewski C, Bartels M. Navigation in surgery. *Langenbeck's Archives of Surgery*. 2013;398(4):501-514. doi:10.1007/s00423-013-1059-4
14. Omay SB, Barnett GH. Surgical navigation for meningioma surgery. *Journal of Neuro-Oncology*. 2010;99(3):357-364. doi:10.1007/s11060-010-0359-6
15. Maciunas R. Computer-assisted neurosurgery. *Clin Neurosurg*. 2006;(53):267-271
16. Kelly PJ, Kall BA, Goerss SJ. Results of Computed Tomography-based Computer-assisted Stereotactic Resection of Metastatic Intracranial Tumors. *Neurosurgery*. 1988;22(1):7-17. doi:10.1227/00006123-198801000-00002
17. Wang MY, Maurer CR, Fitzpatrick JM, Maciunas RJ. An automatic technique for finding and localizing externally attached markers in CT and MR volume images of the head. *IEEE Transactions on Biomedical Engineering*. 1996;43(6):627-637. doi:10.1109/10.495282
18. American College of Radiology. ACR Practice Parameter for the performance of brain stereotactic radiosurgery
19. American College of Radiology. ACR-ASNR-SPR practice parameter for the performance and interpretation of magnetic resonance imaging (MRI) of the brain
20. PRACTICE PARAMETER 1 Cervicocerebral MRA. <https://www.acr.org/-/media/ACR/Files/Practice-Parameters/cervicocerebralmra.pdf?la=en>

21. PRACTICE PARAMETER 1 Cervicocerebral CTA. <https://www.acr.org/-/media/ACR/Files/Practice-Parameters/CervicoCerebralCTA.pdf?la=en>

Sinus and Facial Imaging (HD-29)

Guideline

Sinus and Facial Imaging (HD-29.1)
References (HD-29)

Sinus and Facial Imaging (HD-29.1)

HD.SI.0029.1.U

v3.0.2024

- CT Maxillofacial without contrast (CPT[®] 70486) or limited CT Sinus without contrast (CPT[®] 76380) is supported for ANY of the following:³
 - Acute sinusitis without resolution of symptoms after a minimum of 4 weeks of treatment (Treatment can include an appropriate course and duration of empiric oral antibiotic, topical intranasal steroid, and/or nasal saline rinses.)
 - Concern for potential or suspected complicated sinusitis, which is sinusitis with actual or threatened orbital or intracranial extension (See **Background and Supporting Information** below)
 - Recurrent sinusitis (4 or more episodes of acute bacterial rhinosinusitis within the past 12 months without symptoms or signs between episodes)
 - In practice, recurrent acute exacerbations of chronic rhinosinusitis are seen as well as recurrent acute rhinosinusitis with disease free intervals between the acute episodes. CT Maxillofacial without contrast (CPT[®] 70486) may still be indicated under chronic sinusitis definitions.⁶
 - Chronic sinusitis (≥12 weeks sinusitis) with at least two of the following signs and symptoms:
 - Mucopurulent drainage
 - Nasal obstruction or congestion
 - Facial pain, pressure, and/or fullness (may involve the anterior face, periorbital region, or manifest with headache that is localized or diffuse)
 - Decreased sense of smell (see **Taste and Smell Disorders (HD-2.1)** if anosmia, hyposmia, or dysosmia is an isolated symptom)
 - (**Note:** A trial of antibiotic therapy is not required prior to imaging if individual meets criteria for chronic sinusitis)
 - Sinus surgery is being considered (including Balloon Sinus Ostial Dilation or Functional Endoscopic Sinus Surgery)
 - Follow up on incidentally noted sinus pathology (i.e. mucosal thickening, partial opacification of a sinus, or other indeterminate finding in incompletely visualized sinuses) on other studies not performed for the purpose of evaluating sinus pathology, such as MRI Brain for headache, when requested by ENT for clinical correlation.
- Surgical candidate (see **Unlisted Procedures/Therapy Treatment Planning (Preface-4.3)** in the Preface Imaging Guidelines if unlisted code is requested for surgical planning).
- Studies requested for the purpose of navigation for sinus surgery should be coded CPT[®] 77011 (CT guidance for stereotactic localization).

- It is not appropriate to report both CPT[®] 70486 and CPT[®] 77011 for the same CT stereotactic localization imaging session (see **CT-, MR-, or Ultrasound-Guided Procedures (Preface-4.2)** in the Preface Imaging Guidelines.
- For unexplained cough as the main symptom, and suspected Upper Airway Cough Syndrome (UACS) as the etiology, see **Cough (CH-3.1)** in the Chest Imaging Guidelines.
- CT Maxillofacial with contrast (CPT[®] 70487) if any of the following is present:
 - Orbital or facial cellulitis
 - Proptosis
 - Abnormal visual examination
 - Ophthalmoplegia
 - Immunocompromised individual
 - Fungal or vascular lesions visualized in nasal cavity
- CT Maxillofacial without contrast (CPT[®] 70486) **OR** CT Maxillofacial with contrast (CPT[®] 70487) **OR** MRI Orbits/Face/Neck without and with contrast (CPT[®] 70543):
 - Sinonasal obstruction, polyp, or suspected mass
 - Suspected orbital complication
 - Suspected invasive fungal sinusitis
 - Cystic fibrosis
 - Osteomyelitis (MRI is the preferred modality) and odontogenic infections, see **Skull Base Osteomyelitis (SBO) (HD-20.2)** and **Dental/Periodontal/Maxillofacial Imaging (HD-30.2)** for additional imaging modalities
- MRI Brain with and without contrast (CPT[®] 70553) for suspected intracranial complication
- CT Orbits/Temporal bone without contrast (CPT[®] 70480) or CT Orbits/Temporal bone without and with contrast (CPT[®] 70482) performed alone or added to CT Maxillofacial for:
 - Suspected orbital complications
- For Skull Base Osteomyelitis (SBO), see **Skull Base Osteomyelitis (SBO) (HD-20.2)**
- Repeat imaging for ANY of the following scenarios:
 - An ENT specialist or any provider in consultation with an ENT specialist requests the imaging **and** ONE or more of the following:
 - There has been a follow-up visit since the previous imaging and there is no improvement after an additional 3 weeks of conservative treatment after initial imaging was completed
 - There is a new abnormality on exam such as obstructing mass
 - Planned sinus surgery (including but not limited to Balloon Sinus Ostial Dilation or Functional Endoscopic Sinus Surgery)

- If the most recent CT maxillofacial scan is greater than 6 months old or there is a change in clinical status as described above, a repeat diagnostic CT Maxillofacial without contrast (CPT[®] 70486) is supported for surgical planning.
- Repeat CT Maxillofacial solely for the use of navigation during the sinus surgery (i.e. the most recent diagnostic CT Maxillofacial was not adequate due to lacking anatomic landmarks or insufficient thinness of cuts) should be requested with CPT 77011, not the diagnostic CPT code 70486.
- 3D Rendering (CPT[®] 76376 or CPT[®] 76377) should not be reported in conjunction with CPT[®] 77011 (or CPT[®] 70486 if used). The procedure inherently generates a 3D dataset.
- Complication of ABRS (acute bacterial rhinosinusitis) is suspected based on:
 - Any constellation of symptoms worrisome for intracranial extension of infection or meningitis (i.e. severe headache, photophobia, fever, neck stiffness)
 - Severe headache
 - Facial swelling
 - Cranial nerve palsies
 - Orbital signs (cellulitis, impaired extraocular motility, decrease in vision or proptosis)
- CT findings that correlate with ABRS include opacification, air-fluid level, and moderate to severe mucosal thickening.
 - Complications of ABRS are best assessed using iodine contrast-enhanced CT or gadolinium based MR imaging to identify extra-sinus extension or involvement.
 - Suspected complications are the only indication for MR imaging of the paranasal sinuses in the setting of ABRS.

For Cone Beam Imaging, see **Cone Beam Computed Tomography (CBCT) (HD-24.7)** and **Dental/Peridontal/Maxillofacial Imaging (HD-30.2)**

Background and Supporting Information

- Rhinosinusitis is defined as inflammation of the nasal cavity and adjacent paranasal sinuses. Acute sinusitis refers to symptom duration <4 weeks, subacute 4 to 12 weeks, and chronic >12 weeks. Complicated sinusitis refers to symptoms suggesting spread of disease into adjacent structures, including orbital or intracranial complications.
- There is no evidence to support advanced imaging of acute (<4 weeks) and subacute (4 to 12 weeks) uncomplicated rhinosinusitis.
- There is no evidence to support routine follow-up advanced imaging after treatment with clinical improvement of sinusitis.

References (HD-29)

v3.0.2024

1. Rosenfeld RM, Piccirillo JF, Chandrasekhar SS, et al. Clinical Practice Guideline (Update): *Adult Sinusitis*. *Otolaryngology–Head and Neck Surgery*. 2015;152(2_suppl):S1-S39. doi:10.1177/0194599815572097
2. Desrosiers M, Evans GA, Keith PK, et al. Canadian clinical practice guidelines for acute and chronic rhinosinusitis. *Allergy, Asthma & Clinical Immunology*. 2011;7(1). doi:10.1186/1710-1492-7-2
3. Expert Panel on Neurologic Imaging; Kirsch CFE, Bykowski J, et al. ACR Appropriateness Criteria® Sinonasal Disease. *J Am Coll Radiol*. 2017;14(11S):S550-S559. doi:10.1016/j.jacr.2017.08.041
4. ACR-ASNR-SPR Practice Parameter for the Performance of Computed Tomography (CT) of the Extracranial Head and Neck Revised 2021. (Resolution 5). <https://www.acr.org/-/media/ACR/Files/Practice-Parameters/CT-Head-Neck>
5. Abdalkader M, Xie J, Cervantes-Arslanian A, Takahashi C, Mian AZ. Imaging of Intracranial Infections. *Seminars in Neurology*. 2019;39(03):322-333. doi:10.1055/s-0039-1693161
6. Wu D, Bleier B, Wei Y. Definition and characteristics of acute exacerbation in adult patients with chronic rhinosinusitis: a systematic review. *J Otolaryngol Head Neck Surg*. 2020;49(1):62. Published 2020 Aug 18. doi:10.1186/s40463-020-00459-w

Temporomandibular Joint Disease (TMJ) and Dental/ Periodontal/Maxillofacial Imaging (HD-30)

Guideline

Temporomandibular Joint Disease (TMJ) (HD-30.1)
Dental/Periodontal/Maxillofacial Imaging (HD-30.2)
References (HD-30)

Temporomandibular Joint Disease (TMJ) (HD-30.1)

HD.TJ.0030.1.A

v3.0.2024

- MRI TMJ (CPT[®] 70336) is the diagnostic study of choice and should be reserved for those who fail a minimum of 6 weeks of non-surgical treatment **AND** who are actively being considered for TMJ surgery
- CT Maxillofacial without contrast (CPT[®] 70486) or without and with contrast (CPT[®] 70488) when there is suspicion of bony involvement based on prior x-ray or MRI
- Ultrasound (CPT[®] 76536) can be used to look for the presence of a joint effusion and to evaluate cartilage and disk displacement with open and closed mouth imaging and to guide injections
- For TMJ imaging in patients with Juvenile Idiopathic Arthritis (see **Temporomandibular Joint (TMJ) Imaging in Children (PEDHD-25)** in the Pediatric Head Imaging Guidelines)
 - MRI TMJ (CPT[®] 70336) is indicated annually for detecting silent TMJ arthritis in children and young adults with juvenile idiopathic arthritis as requested by a rheumatologist and/or oral/maxillofacial surgeon (OMS) and/or any provider in consultation with a rheumatologist or OMS.
 - Repeat imaging with MRI TMJ (CPT[®] 70336) in patients with JIA is indicated for any of the following:
 - Change in signs or symptoms suggesting progression of disease
 - To monitor the effects of treatment¹¹
 - Bone Scintigraphy/Bone Scan 3 Phase Study (CPT[®] 78315) in individuals over 12 years of age is indicated in anticipation or consideration of surgery.
- Jaw Asymmetry - Unilateral condylar hyperplasia is manifested by slow growth in areas of the mandible causing facial asymmetry. It is usually a self-limiting condition seen predominantly in 12–30 year olds. CPT[®] 78315 Bone Scan 3 Phase Study is indicated in anticipation or consideration of surgery¹³

Dental/Periodontal/Maxillofacial Imaging (HD-30.2)

HD.TJ.0030.2.U

v3.0.2024

- Cone beam CT for surgical planning when plain x-rays alone are insufficient. Potential indications include but are not limited to:
 - Impacted teeth
 - Supernumerary teeth
 - Dentoalveolar trauma
 - Root resorption
 - Foreign body
 - Odontogenic cysts, tumors, or other jaw pathology
 - Cleft pathology
 - Orthognathic surgery for dentofacial anomalies
 - Osteomyelitis and odontogenic infections (X-ray not required)
 - Bisphosphonate-related osteonecrosis of the jaw (X-ray not required)
 - Salivary gland stones
 - Maxillofacial bone graft planning
 - Dental implants related to tooth loss from injury, trauma, or jaw pathology such as cysts, tumors, or cancer
 - Post-operative imaging, including dental implants^{14,15}
- Cone Beam CT: Report with CPT[®] Codes: CPT[®] 70486, CPT[®] 70487, CPT[®] 70488, CPT[®] 70480, CPT[®] 70482 (see **Cone Beam Computed Tomography (CBCT) (HD-24.7)**)
- 3-D rendering (CPT[®] 76376 or CPT[®] 76377) should NOT be reported separately
- Cone beam CT (CBCT) may also be called i-CAT scanner or mini-CAT scanner

References (HD-30)

v3.0.2024

1. De Vos W, Casselman J, Swennen GRJ. Cone-beam computerized tomography (CBCT) imaging of the oral and maxillofacial region: A systematic review of the literature. *International Journal of Oral and Maxillofacial Surgery*. 2009;38(6):609-625. doi:10.1016/j.ijom.2009.02.028
2. Scrivani SJ, Keith DA, Kaban LB. Temporomandibular Disorders. *New England Journal of Medicine*. 2008;359(25):2693-2705. doi:10.1056/nejmra0802472
3. Bag AK. Imaging of the temporomandibular joint: An update. *World Journal of Radiology*. 2014;6(8):567. doi:10.4329/wjr.v6.i8.567
4. Horner K, O'Malley L, Taylor K, Glennly A-M. Guidelines for clinical use of CBCT: a review. *Dentomaxillofacial Radiology*. 2015;44(1):20140225. doi:10.1259/dmfr.20140225
5. ACR-ASNR-SPR Practice Parameter for the Performance of Computed Tomography (CT) of the Extracranial Head and Neck Revised 2021. (Resolution 5). <https://www.acr.org/-/media/ACR/Files/Practice-Parameters/CT-Head-Neck> <https://www.acr.org/-/media/ACR/Files/Practice-Parameters/CT-Head-Neck.pdf>
6. Guidelines for Diagnosis and Management of Disorders Involving the Temporomandibular Joint and Related Musculoskeletal Structures. *Cranio*[®]. 2003;21(1):68-76. doi:10.1080/08869634.2003.11746234
7. Mercuri LG. Management of temporomandibular joint disorders. *Journal of Oral Biology and Craniofacial Research*. 2012;2(3):141-142. doi:10.1016/j.jobcr.2012.10.010
8. Gauer R, Semidey M. Diagnosis and Treatment of Temporomandibular Disorders. *Am Fam Physician*. 2015 Mar 15;91(6):378-386
9. National Academies of Sciences. Temporomandibular Disorders: Priorities for Research and Care. Priorities for Research and Care | The National Academies Press. <https://doi.org/10.17226/25652>. Published March 12, 2020
10. Whyte A, Boeddinghaus R, Bartley A, Vijayaendra R. Imaging of the temporomandibular joint. *Clin Radiol*. 2021 Jan;76(1):76.e21-76.e35. doi: 10.1016/j.crad.2020.06.020
11. Schmidt C, Ertel T, Arbogast M, et al. The Diagnosis and Treatment of Rheumatoid and Juvenile Idiopathic Arthritis of the Temporomandibular Joint. *Dtsch Arztebl Int*. 2022;119(4):47-54. doi:10.3238/arztebl.m2021.0388
12. Kim IH, Singer SR, Mupparapu M. Review of cone beam computed tomography guidelines in North America. *Quintessence Int*. 2019 Jan 25;50(2):136-145. doi: 10.3290/j.qi.a41332
13. Almeida FT, Pacheco-Pereira C, Flores-Mir C, Le LH, Jaremko JL, Major PW. Diagnostic ultrasound assessment of temporomandibular joints: a systematic review and meta-analysis. *Dentomaxillofac Radiol*. 2019 Feb;48(2):20180144. doi: 10.1259/dmfr.20180144 9
14. Weiss R 2nd, Read-Fuller A. Cone Beam Computed Tomography in Oral and Maxillofacial Surgery: An Evidence-Based Review. *Dent J (Basel)*. 2019;7(2):52. Published 2019 May 2. doi:10.3390/dj7020052
15. Jacobs R, Salmon B, Codari M, Hassan B, Bornstein MM. Cone beam computed tomography in implant dentistry: recommendations for clinical use. *BMC Oral Health*. 2018;18(1):88. Published 2018 May 15. doi:10.1186/s12903-018-0523-5
16. Liu P, Shi J. Growth trends analysis of unilateral condylar hyperplasia followed up with planar scintigraphy: Retrospective overview of 249 cases. *Medicine (Baltimore)*. 2021;100(51):e28226. doi:10.1097/MD.00000000000028226

Eye Disorders and Visual Loss (HD-32)

Guideline

Eye Disorders and Visual Loss (HD-32.1)

Pupillary Abnormalities Including Horner's Syndrome (HD-32.2)

References (HD-32)

Eye Disorders and Visual Loss (HD-32.1)

HD.VL.0032.1.A

v3.0.2024

- For specific conditions - See **Background and Supporting Information** that include table of abbreviations
- Examination of ocular complaints and visual loss may include evaluation of pupillary responses, extraocular motility, visual acuity, visual field testing, intraocular pressures, external examination, slit lamp examination, and/or fundoscopic exam of retinae. An exam performed by a Neuro-Ophthalmologist, Neurologist, or an Optometrist meets this requirement.
- MRI Orbits/Face/Neck without contrast (CPT[®] 70540) **OR** MRI Orbits/Face/Neck without and with contrast (CPT[®] 70543) **OR** CT Orbits/Temporal bone with contrast (CPT[®] 70481) **OR** CT Orbits/Temporal bone without contrast (CPT[®] 70480) **AND/OR** MRI Brain without contrast (CPT[®] 70551) **OR** MRI Brain with and without contrast (CPT[®] 70553):¹
 - Unexplained vision loss
 - Optic atrophy (Cranial Nerve II)
 - Optic neuropathy (Cranial Nerve II)
 - Papilledema/optic disc swelling (Cranial Nerve II) (see **Cranial Neuropathies (HD-1.1)** and **Papilledema/Pseudotumor Cerebri (HD-17.1)**)
 - Afferent Pupillary Defect (APD) or Relative Afferent Pupillary Defect (RAPD)
 - Chiasmal symptoms/signs (including bitemporal field deficit)
 - Ophthalmoplegia, Diplopia, and/or Cranial nerve palsy (Specifically CN III, IV, and VI, see **Cranial Neuropathies HD-1.1)**)
 - Nystagmus²¹
- For optic disc edema/papilledema, CT Head without contrast (CPT[®] 70450) is helpful to assess for space-occupying processes such as intracranial hemorrhage, mass effect and hydrocephalus.¹⁶
- For suspected optic neuritis, MRI is the preferred modality (see **Multiple Sclerosis (MS) (HD-16.1)** and **Neuromyelitis Optica and NMO Spectrum Disorders (HD-16.2)**)
- Visual field defects are associated with retrochiasmal pathology (see **Stroke/TIA (HD-21.1)** or **Primary Central Nervous System Tumors (ONC-2)** in the Oncology Imaging Guidelines or **Brain Metastasis (ONC- 31.3)** in the Oncology Imaging Guidelines)
- MRI Orbits/Face/Neck without contrast (CPT[®] 70540) or MRI Orbits/Face/Neck without and with contrast (CPT[®] 70543) or CT Orbits/Temporal bone with contrast (CPT[®] 70481):

- Exophthalmos (including thyroid eye disease), enophthalmos or non-traumatic orbital asymmetry
- Suspected orbital cellulitis or atypical pre-septal cellulitis, uveitis or scleritis
- Orbital mass or metastasis
- Orbital inflammatory syndrome (orbital pseudotumor) and dacryocystitis or dacryoadenitis
- CT Orbits/Temporal bone without contrast (CPT[®] 70480) and/or CT Head without contrast (CPT[®] 70450):
 - Orbital trauma with visual defect
 - Exophthalmos (including thyroid eye disease)
- CT Maxillofacial without and with contrast (CPT[®] 70488) or CT Maxillofacial without contrast (CPT[®] 70486) or CT Maxillofacial with contrast (CPT[®] 70487)^{22,23}
 - For pre-operative planning for procedures including dacryocystorhinostomy (DCR) to correct nasolacrimal duct obstruction (NLDO)^{22,23}
- When requested by the surgeon or in consultation with surgeon, contrast level as requested. This includes requests from Ophthalmologists and Oculoplastic surgeons. Contrast level preference may vary per institutional protocol.
- MRA Head (CPT[®] 70544, CPT[®] 70545, or CPT[®] 70546) or CTA Head (CPT[®] 70496) for suspicion of intracranial aneurysm, including Third nerve palsy with pupillary involvement (see **Intracranial Aneurysms (HD-12.1)**)
- MRA Head (CPT[®]70544, CPT[®]70545, or CPT[®]70546) or CTA Head (CPT[®]70496) **AND/OR** MRA Neck (CPT[®]70547, CPT[®]70548, or CPT[®]70549) or CTA Neck (CPT[®] 70498) for evaluation of diplopia due to suspected stroke or TIA (see **Intracranial Aneurysms (HD-12.1)**)
- Amaurosis Fugax (see **Stroke/TIA (HD-21.1)**)
 - Individuals describe a transient darkening or loss of vision, typically monocular
- Central Retinal Artery Occlusion, Branch Retinal Artery Occlusion, and Ophthalmic Artery Occlusion (see **Stroke/TIA (HD-21.1)**)
 - Individuals describe a sudden monocular loss of vision or visual field. Etiology is usually embolic and is considered a stroke to the retina
- There is currently no data to support advanced imaging while on Tepezza[®] (teprotumumab) unless there are neurologic symptoms or ophthalmologic symptoms.^{19,20} Any one of the following are supported when additional imaging is indicated:
 - MRI Orbits/Face/Neck without contrast (CPT[®] 70540)
 - MRI Orbits/Face/Neck without and with contrast (CPT[®] 70543)
 - CT Orbits/Temporal bone with contrast (CPT[®] 70481)
 - CT Orbits/Temporal bone without contrast (CPT[®] 70480)
 - CT head without contrast (CPT[®] 70450)

- Additional imaging indications include:
 - To reassess compressive optic neuropathy (Symptoms/Signs of compressive optic neuropathy include APD, decreased visual acuity, and/ or visual field defects)
 - For non-response to Tepezza (Teprotumumab), relapses, worsening proptosis, diplopia, lid retraction, or optic neuropathy
 - For surgical planning for orbital decompression, strabismus surgery or lid surgery
- Autoimmune Retinopathy
 - Suspicion for CAR (Cancer associated retinopathy) or MAR (melanoma associated retinopathy) syndromes (see **Paraneoplastic Syndromes (ONC-30.3)** in the Oncology Imaging Guidelines)
- Oncologic conditions
 - Retinoblastoma (see **Retinoblastoma (PEDONC-12)** in the Pediatric Oncology Imaging Guidelines)
 - Uveal (choroidal) melanoma -(see **Ocular Melanoma (ONC-5.9)** in the Oncology Imaging Guidelines)
 - Biopsy results are not required before initial staging
- Vasculitis including Temporal Arteritis (Giant Cell Arteritis) (see **Cerebral Vasculitis (HD-22.1)**)

Background and Supporting Information

- Imaging Non-Indications
 - Imaging is not necessary if visual loss or ocular symptom/sign is due to known intrinsic eye disease, such as refractive errors, amblyopia, pterygium, subconjunctival hemorrhage, conjunctivitis, cataracts, macular degeneration, central serous retinopathy, retinal vein occlusion, retinal detachment, etc. Monocular diplopia is not an indication for imaging. Physiologic anisocoria (difference in pupil diameter between the two eyes of 2 mm or less) and surgically distorted pupils are not indications for imaging.
 - Imaging is not typically necessary in cases of ptosis without concern for Horner's or 3rd nerve palsy
- Advanced imaging of the brain and orbit are not routinely paired.
 - Suspicion for disorders involving both regions is needed to image both regions.
 - Orbital imaging alone may be sufficient unless other signs or symptoms suggest brain involvement.
- Thyroid function and iodine contrast: thyroid dysfunction can occur in susceptible individuals after iodine exposure.

List of Abbreviations and Meanings:

Abbreviation	Meaning
AC	Anterior chamber
APD	Afferent pupillary defect (see RAPD)
BCVA	Best-corrected visual acuity
C3F8	Gas bubble injected into vitreous cavity during retina surgery
cc	With correction (current new or old glasses or contact lenses)
CP	Color plates
C/S	Conjunctiva/sclera
CSME	Clinically significant macular edema
CVF	Confrontation visual field (testing of gross field of view)
D	Disc, optic nerve head
DBH	Dot blot hemorrhages
DCR	Dacryocystorhinostomy
DFE	Dilated fundus exam
E	Esophoria at distance
E'	Esophoria at near
EOM	Extraocular movements
ERM	Epiretinal membrane
ET	Esotropia at distance
E(T)	Intermittent esotropia at distance
ET'	Esotropia at near
E(T)'	Intermittent esotropia at near
GVF	Goldmann visual field test

Abbreviation	Meaning
HT	Hypertropia
HVF	Humphrey visual field test (automated perimetry)
I	Iris
Ishihara	Commonly used color plates
IOP	Intraocular pressure
K	Cornea
LF	Levator function
LFH	Lid fissure height
LLL	Lids, lashes, lacrimal gland
M	Macula
ME	Macular edema
MH	Macular hole
MP	Membrane peel
MRD1	Margin-reflex distance from upper lid margin to pupillary light reflex
MRx	Manifest refraction
NI	No improvement
NLDO	Nasolacrimal duct obstruction
NSC or NS	Nuclear sclerotic cataract
OD	Right eye
OS	Left eye
ortho	Eyes are aligned on the same target
OCT	Optical Coherence Tomography
P	Periphery

Abbreviation	Meaning
PD	Prism diopter
ph or PH	Pinhole (crude assessment of best-corrected visual acuity)
PPV or PPVx	Pars plana vitrectomy
PVD	Posterior vitreous detachment
RAPD	Relative Afferent Pupillary Defect (see APD)
RD	Retinal detachment
RT	Retinal tear
SB	Scleral buckle
sc	Without correction
SF6	Gas bubble injected into vitreous cavity during retina surgery
SLE	Slit lamp examination
SO	Silicone oil
SRF	Subretinal fluid
Ta	Applanation tonometry (intraocular pressure measurement)
Tp	Tonopen tonometry (intraocular pressure measurement)
V	Vessels
Va	Visual acuity
VF	Visual field testing (formal automated perimetry versus confrontation visual field testing)
X	Exophoria at distance
X'	Exophoria at near
XT	Exotropia
X(T)	Intermittent exotropia at distance
XT'	Exotropia at near

Abbreviation	Meaning
X(T)	Intermittent exotropia at near

Pupillary Abnormalities Including Horner's Syndrome (HD-32.2)

HD.VL.0032.2.A

v3.0.2024

- Anisocoria and Other Pupillary Disorders
 - Physiologic anisocoria (difference in pupil diameter between the two eyes of typically 2 mm or less) and surgically distorted pupils are not indications for advanced imaging.
 - Dilated pupil from suspected Third nerve palsy (see **Eye Disorders and Visual Loss (HD-32.1)**)
 - Horner's Syndrome (See below)
- Horner's Syndrome (anisocoria, ptosis, and ipsilateral anhidrosis) is caused by disruption of sympathetic innervation to the eye and face. Definitive diagnosis may be established by pharmacologic testing of the pupillary response with eye drops. Evaluation and imaging depends on determining whether the cause is a central lesion (brainstem or cervical spinal cord), preganglionic lesion (spinal cord or sympathetic chain in the chest), or postganglionic lesion (neck or carotid artery).
- MRI Brain without contrast (CPT[®] 70551) or MRI Brain without and with contrast (CPT[®] 70553) for suspected intracranial or brainstem lesions
- MRI Cervical Spine without contrast (CPT[®] 72141) or MRI Cervical Spine without and with contrast (CPT[®] 72156) for suspected spinal cord abnormality
- CT Chest with contrast (CPT[®] 71260) for suspected chest mass
- CT Neck with contrast (CPT[®] 70491) for suspected neck mass
- CTA Neck without and with contrast (CPT[®] 70498) or MRA Neck (CPT[®] 70547, CPT[®] 70548, or CPT[®] 70549) for suspected carotid injury or dissection
- MRI Orbits/Face/Neck without contrast (CPT[®] 70540), MRI Orbits/Face/Neck without and with contrast (CPT[®] 70543) or CT Orbits/Temporal bone with contrast (CPT[®] 70481) for suspected orbital lesion or mass

References (HD-32)

HD.VL.0032.3.A

v3.0.2024

1. Expert Panel on Neurologic Imaging; Kennedy TA, Corey AS, et al. ACR Appropriateness Criteria® Orbits Vision and Visual Loss. *J Am Coll Radiol*. 2018;15(5S):S116-S131. doi:10.1016/j.jacr.2018.03.023
2. Lee JH, Lee HK, Lee DH, Choi CG, Kim SJ, Suh DC. Neuroimaging Strategies for Three Types of Horner Syndrome with Emphasis on Anatomic Location. *American Journal of Roentgenology*. 2007;188(1):W74-W81. doi:10.2214/ajr.05.1588
3. Szatmáry G. Imaging in Patients With Visual Symptoms. *CONTINUUM: Lifelong Learning in Neurology*. 2016;22(5):1499-1528. doi:10.1212/con.0000000000000375
4. Kawasaki AK. Diagnostic Approach to Pupillary Abnormalities. *CONTINUUM: Lifelong Learning in Neurology*. 2014;20:1008-1022. doi:10.1212/01.con.0000453306.42981.94
5. Prasad S. Diagnostic Neuroimaging in Neuro-ophthalmic Disorders. *CONTINUUM: Lifelong Learning in Neurology*. 2014;20:1023-1062. doi:10.1212/01.con.0000453305.65851.1c
6. ACR-ASNR-SPR Practice Parameter for the Performance of Computed Tomography (CT) of the Extracranial Head and Neck Revised 2021. (Resolution 5). <https://www.acr.org/-/media/ACR/Files/Practice-Parameters/CT-Head-Neck>
7. Tamhankar MA, Volpe NJ. Management of acute cranial nerve 3, 4 and 6 palsies: role of neuroimaging. *Curr Opin Ophthalmol*. 2015;26(6):464-468. doi:10.1097/ICU.0000000000000200
8. Tamhankar MA, Biousse V, Ying GS, et al. Isolated third, fourth, and sixth cranial nerve palsies from presumed microvascular versus other causes: a prospective study. *Ophthalmology*. 2013;120(11):2264-2269. doi:10.1016/j.ophtha.2013.04.009
9. Pineles SL, Velez FG. Isolated Ocular Motor Nerve Palsies. *J Binocul Vis Ocul Motil*. 2018;68(3):70-77. doi:10.1080/2576117X.2018.1481266
10. Flaxel CJ, Adelman RA, Bailey ST, et al. Retinal and Ophthalmic Artery Occlusions Preferred Practice Pattern®. *Ophthalmology*. 2020;127(2):P259-P287. doi:10.1016/j.ophtha.2019.09.028
11. Dagi LR, Velez FG, Archer SM, et al. Adult Strabismus Preferred Practice Pattern®. *Ophthalmology*. 2020;127(1):P182-P298. doi:10.1016/j.ophtha.2019.09.023
12. Sadaka A, Schockman SL, Golnik KC. Evaluation of Horner Syndrome in the MRI Era. *Journal of Neuro-Ophthalmology*. 2017;37(3):268-272. doi:10.1097/wno.0000000000000503
13. Glisson CC. Approach to Diplopia. *CONTINUUM: Lifelong Learning in Neurology*. 2019;25(5):1362-1375. doi:10.1212/con.0000000000000786
14. Gross JR, McClelland CM, Lee MS. An approach to anisocoria. *Current Opinion in Ophthalmology*. 2016;27(6):486-492. doi:10.1097/icu.0000000000000316
15. Costello F, Scott JN. Imaging in Neuro-ophthalmology. *CONTINUUM: Lifelong Learning in Neurology*. 2019;25(5):1438-1490. doi:10.1212/con.0000000000000783
16. Expert Panel on Neurologic Imaging, Whitehead MT, Cardenas AM, et al. ACR Appropriateness Criteria® Headache. *J Am Coll Radiol*. 2019;16(11S):S364-S377. doi:10.1016/j.jacr.2019.05.030
17. Lee SY, Rhee CM, Leung AM, Braverman LE, Brent GA, Pearce EN. A review: Radiographic iodinated contrast media-induced thyroid dysfunction. *J Clin Endocrinol Metab*. 2015;100(2):376-383. doi:10.1210/jc.2014-3292
18. van der Molen AJ, Thomsen HS, Morcos SK; Contrast Media Safety Committee, European Society of Urogenital Radiology (ESUR). Effect of iodinated contrast media on thyroid function in adults. *Eur Radiol*. 2004 May;14(5):902-7. doi: 10.1007/s00330-004-2238-z
19. Teo HM, Smith TJ, Joseph SS Efficacy and Safety of Teprotumumab in Thyroid Eye Disease *Ther Clin Risk Manag*. 2021 17:1219-1230. doi: 10.2147/TCRM.S303057
20. Bednarczuk Z, Pearce, SH The knowns and unknowns of teprotumumab for thyroid eye disease *Lancet Diabetes Endocrinol*. 2021 9:323-325. doi: 10.1016/S2213-8587(21)00076-0
21. Lee AG, Brazis PW. Localizing forms of nystagmus: symptoms, diagnosis, and treatment. *Curr Neurol Neurosci Rep*. 2006;6(5):414-420. doi:10.1007/s11910-996-0022-y

22. Freitag SK, Roos JC. Preoperative imaging should be performed prior to surgery in all cases of acquired nasolacrimal obstruction-Yes.*Eye (Lond)*. 2017;31(3):351-352. doi:10.1038/eye.2016.237
23. Choi SC, Lee S, Choi HS, Jang JW, Kim SJ, Lee JH. Preoperative Computed Tomography Findings for Patients with Nasolacrimal Duct Obstruction or Stenosis.*Korean J Ophthalmol*. 2016;30(4):243-250. doi:10.3341/kjo.2016.30.4.243

Acoustic Neuroma and Other Cerebellopontine Angle Tumors (HD-33)

Guideline

Acoustic Neuroma and Other Cerebellopontine Angle Tumors (HD-33.1)
References (HD-33)

Acoustic Neuroma and Other Cerebellopontine Angle Tumors (HD-33.1)

HD.AC.0033.1.A

v3.0.2024

- Acoustic neuroma and vestibular schwannoma may be used interchangeably
- Initial diagnosis is usually made during evaluation for asymmetric hearing loss and/or vertigo (see **Dizziness, Vertigo and Syncope (HD-23)** and **Hearing Loss and Tinnitus (HD-27)**) for evaluation of those problems
- MRI Brain without and with contrast (CPT[®] 70553) which should be done with attention to the internal auditory canals for initial diagnosis.
- MRI Brain without contrast (CPT[®] 70551) if performed with FIESTA protocol
- MRI Orbits/Face/Neck without and with contrast (CPT[®] 70543) with audiologic or clinical features of retrocochlear hearing loss and a negative MRI Brain and in the rare individual in whom a detailed search is indicated for both a lesion of the cerebellopontine angle **and** lesions of the cerebral hemispheres
- Repeat MRI Brain (contrast as requested) 6 months after diagnosis, then annually for 5 years and thereafter per specialist or any provider in consultation with a specialist.⁷
- MRI Brain without and with contrast with attention to the internal auditory canals (CPT[®] 70553) is performed after surgical resection and following stereotactic radiation therapy at 6 to 12 months to document the completeness of tumor removal and to serve as a baseline for further follow-up. Additional follow up is done annually for 5 years and every 2 years thereafter.
- See **Primary Central Nervous System Tumors- General Considerations (ONC-2.1)** in the Oncology Imaging Guidelines for additional imaging requests for surgery

References (HD-33)

v3.0.2024

1. Kesavadas C, Thomas B, Kapilamoorthy T, Hingwala D, Chatterjee S. Applications of 3D CISS sequence for problem solving in neuroimaging. *Indian Journal of Radiology and Imaging*. 2011;21(2):90. doi:10.4103/0971-3026.82283
2. Camelio S, Schmid UD, Horsfield MA, et al. Visualization of cranial nerves I-XII: value of 3D CISS and T2-weighted FSE sequences. *European Radiology*. 2000;10(7):1061-1067. doi:10.1007/s003300000452
3. Olson JJ, Kalkanis SN, Ryken TC. Congress of Neurological Surgeons Systematic Review and Evidence-Based Guidelines on the Treatment of Adults With Vestibular Schwannomas: Executive Summary. *Neurosurgery*. 2017;82(2):129-134. doi:10.1093/neuros/nyx586
4. Zou J, Hirvonen T. "Wait and scan" management of patients with vestibular schwannoma and the relevance of non-contrast MRI in the follow-up. *Journal of Otology*. 2017;12(4):174-184. doi:10.1016/j.joto.2017.08.002
5. Lin EP, Crane BT. The Management and Imaging of Vestibular Schwannomas. *American Journal of Neuroradiology*. 2017;38(11):2034-2043. doi:10.3174/ajnr.a5213
6. Goldbrunner R, Weller M, Regis J, et al. EANO guideline on the diagnosis and treatment of vestibular schwannoma. *Neuro-Oncology*. 2019;22(1):31-45. doi:10.1093/neuonc/noz153
7. Somers T, Kania R, Waterval J, Havenbergh TV. What is the Required Frequency of MRI Scanning in the Wait and Scan Management? *J Int Adv Otol* 2018; 14(1): 85-9. doi: 10.5152/iao.2018.5348

Pineal/Colloid Cysts (HD-34)

Guideline

Pineal/Colloid Cysts (HD-34.1)
References (HD-34)

Pineal/Colloid Cysts (HD-34.1)

HD.PT.0034.1.A

v3.0.2024

Pineal cysts are generally discovered incidentally and do not require surgical intervention.

- MRI Brain without contrast (CPT[®] 70551) or without and with contrast (CPT[®] 70553) is indicated for initial evaluation of pineal cysts if not already completed.
- Repeat MRI Brain is not indicated for most individuals with pineal cysts, but MRI Brain without contrast (CPT[®] 70551) or without and with contrast (CPT[®] 70553) for the following:
 - New or worsening headache or focal neurologic deficits suggesting progression of cyst
 - Pre-operative planning
- Repeat MRI Brain without contrast (CPT[®] 70551) or without and with contrast (CPT[®] 70553) for colloid cysts for the following:
 - In the presence of symptoms including syncope
 - Evaluation of CSF flow (CPT[®] 70551)
 - When requested by a specialist or any provider in consultation with a specialist

References (HD-34)

v3.0.2024

1. Ajtai B, Bertelson JA. Imaging of Intracranial Cysts. *CONTINUUM: Lifelong Learning in Neurology*. 2016;22(5):1553-1573. doi:10.1212/con.0000000000000372
2. Tanaka T, Arnold L, Gabriela Mazuru D, Golzy M, Carr SB, Litofsky NS. Pineal cysts: Does anyone need long-term follow up? *Journal of Clinical Neuroscience*. 2021;83:146-151. doi:10.1016/j.jocn.2020.10.051
3. Jussila M-P, Olsén P, Salokorpi N, Suo-Palosaari M. Follow-up of pineal cysts in children: is it necessary? *Neuroradiology*. 2017;59(12):1265-1273. doi:10.1007/s00234-017-1926-8

Arachnoid Cysts (HD-35)

Guideline

Arachnoid Cysts (HD-35.1)
References (HD-35)

Arachnoid Cysts (HD-35.1)

HD.AR.0035.1.A

v3.0.2024

Arachnoid cysts arise in the middle or posterior fossa, and the majority of lesions are discovered incidentally and do not require surgical intervention.

- MRI Brain without contrast (CPT[®] 70551) or without and with contrast (CPT[®] 70553) is indicated for initial evaluation of arachnoid cysts if not already completed.
- Repeat MRI Brain is not indicated for most individuals with arachnoid cysts, except in the following scenarios:
 - New or worsening headache or focal neurologic deficits suggesting progression of cyst
 - Pre-operative planning
 - When requested by a specialist or any provider in consultation with a specialist

References (HD-35)

v3.0.2024

1. Ajtai B, Bertelson JA. Imaging of Intracranial Cysts. *CONTINUUM: Lifelong Learning in Neurology*. 2016;22(5):1553-1573. doi:10.1212/con.0000000000000372
2. Hall S, Smedley A, Sparrow O, Mathad N, Waters R, Chakraborty A, Tsitouras V. Natural History of Intracranial Arachnoid Cysts. *World Neurosurg*. 2019 Jun;126:e1315-e1320. doi: 10.1016/j.wneu.2019.03.087

Nuclear Medicine (HD-36)

Guideline

Nuclear Medicine (HD-36.1)

References (HD-36)

Nuclear Medicine (HD-36.1)

HD.NM.0036.1.A

v3.0.2024

Nuclear medicine studies used in the evaluation of some head/brain disorders, and other rare indications as well.

- Brain Scintigraphy with or without vascular flow (any one of CPT[®] 78600, CPT[®] 78601, CPT[®] 78605, or CPT[®] 78606)
- Brain Imaging Radiopharmaceutical Localization SPECT (CPT[®] 78803)¹
 - Immunocompromised individuals with mass lesion detected on CT or MRI for differentiation between lymphoma and infection
 - In distinguishing recurrent brain tumor from radiation necrosis
 - Can be performed with vasodilating agent acetazolamide (Diamox) to assess functional reserve capacity to predict critically reduced perfusion in individuals with chronic cerebrovascular disease (for example, in Moya-Moya disease) and identify individuals who might benefit from an extracranial-to-intracranial (EC-IC) bypass to augment Cerebral Blood Flow, and to assess pre-operatively the potential for ischemia following carotid artery sacrifice.
- Brain Imaging Vascular Flow (CPT[®] 78610)
 - Cerebral ischemia
 - Establish brain death
- CSF Leakage Detection (CPT[®] 78650)
 - Evaluation of CSF rhinorrhea, otorrhea, or refractory post-lumbar puncture headache
 - Suspected normal pressure hydrocephalus with gait disturbance and either dementia or urinary incontinence
- Radiopharmaceutical Dacryocystography (CPT[®] 78660)
 - Suspected obstruction of nasolacrimal duct due to excessive tearing
- Cisternogram (CPT[®] 78630) for the following:
 - Known hydrocephalus with worsening symptoms
 - Suspected obstructive hydrocephalus
 - CSF Leak⁵ See **Low Pressure Headache and CSF Leak (HD-11.15)** and **Facial Trauma (HD-13.2)**
- Cerebrospinal Ventriculography (CPT[®] 78635) for the following:
 - Evaluation of internal shunt, pencephalic cyst, or posterior fossa cyst
- Nuclear Medicine Shunt Evaluation (CPT[®] 78645) and CSF Flow SPECT (CPT[®] 78803) for the following:
 - Suspected malfunction of ventriculoperitoneal, ventriculopleural, or ventriculovenous shunts.

- Imaging Radiopharmaceutical Localization SPECT with Ioflupane I-23 (CPT[®] 78803 or CPT[®] 78830, DAT-SPECT) OR Fluorodopa F (F-DOPA) PET Brain (CPT[®] 78606)^{7,8,9,10,11} (see **Lewy Body Dementia (LBD) – SPECT Brain Scan (HD-8.3)** and **Movement Disorders (HD-15.1)**)
- Jaw Asymmetry - Unilateral condylar hyperplasia is manifested by slow growth in areas of the mandible causing facial asymmetry. It is usually a self-limiting condition seen predominantly in 12–30 year olds.
 - CPT[®] 78315 Bone Scan 3 Phase Study is indicated in anticipation or consideration of surgery.⁶

References (HD-36)

HD.NM.0036.2.A

v3.0.2024

1. Bega D, Gonzalez-Latapi P, Zadikoff C, Spies W, Simuni T. Is There a Role for DAT-SPECT Imaging in a Specialty Movement Disorders Practice? *Neurodegenerative Diseases*. 2015;15(2):81-86. doi:10.1159/000370116
2. Vagal A, Leach J, Fernandez-Ulloa M, Zuccarello M. The Acetazolamide Challenge: Techniques and Applications in the Evaluation of Chronic Cerebral Ischemia. *American Journal of Neuroradiology*. 2009;30(5):876-884. doi:10.3174/ajnr.a1538
3. Subramaniam RM, Frey KA, Hunt CH, et al. ACR-ACNM Practice Parameter for the Performance of Dopamine Transporter (DaT) Single Photon Emission Computed Tomography (SPECT) Imaging for Movement Disorders. *Clinical Nuclear Medicine*. 2017;42(11):847-852. doi:10.1097/rlu.0000000000001815
4. Giacino JT, Katz DI, Schiff ND, et al. Practice guideline update recommendations summary: Disorders of consciousness. *Neurology*. 2018;91(10):450-460. doi:10.1212/wnl.0000000000005926
5. Expert Panel on Neurological Imaging, Shih RY, Burns J, et al. ACR Appropriateness Criteria® Head Trauma: 2021 Update. *J Am Coll Radiol*. 2021;18(5S):S13-S36. doi:10.1016/j.jacr.2021.01.006
6. Liu P, Shi J. Growth trends analysis of unilateral condylar hyperplasia followed up with planar scintigraphy: Retrospective overview of 249 cases. *Medicine (Baltimore)*. 2021;100(51):e28226. doi:10.1097/MD.00000000000028226
7. Fluorodopa F18 Injection Package Insert. Highlights of prescribing information. U.S. Food and Drug Administration Website. https://www.accessdata.fda.gov/drugsatfda_docs/label/2019/200655s000lbl.pdf. Revised 10/2019.
8. Dhawan V, Niethammer MH, Lesser ML, et al. Prospective F-18 FDOPA PET Imaging Study in Human PD. *Nucl Med Mol Imaging*. 2022;56(3):147-157. doi:10.1007/s13139-022-00748-4
9. Thaler A, Alcalay RN. Diagnosis and Medical Management of Parkinson Disease. *Continuum (Minneapolis)*. 2022;28(5):1281-1300. doi:10.1212/CON.0000000000001152
10. Maiti B, Perlmutter JS. Imaging in Movement Disorders. *Continuum (Minneapolis)*. 2023;29(1):194-218. doi:10.1212/CON.0000000000001210
11. Morbelli S, Esposito G, Arbizu J, et al. EANM practice guideline/SNMMI procedure standard for dopaminergic imaging in Parkinsonian syndromes 1.0. *Eur J Nucl Med Mol Imaging*. 2020;47(8):1885-1912. doi:10.1007/s00259-020-04817-8

Sleep-Related Imaging (HD-37)

Guideline

General Guidelines Sleep-Related Imaging (HD-37.1)
References (HD-37)

General Guidelines Sleep-Related Imaging (HD-37.1)

HD.SL.0037.1.A

v3.0.2024

- Hypersomnolence:
 - When there are focal neurologic signs or suspicion for an inflammatory neurologic process as the etiology. Recognition and treatment of a comorbid sleep disorders is paramount, and a complete neurologic history and examination should precede any request for advanced imaging.
 - MRI Brain with and without contrast (CPT[®] 70553) **OR**
 - MRI Brain without contrast (CPT[®] 70551)
- Central Sleep Apnea:
 - For unexplained central sleep apnea syndrome when a primary CNS etiology is suspected; i.e., unassociated with CHF, COPD or other potential etiology. Specific etiologies should be stated for imaging requests, including but not limited to, suspected Chiari malformation, stroke, CNS demyelinating disease, posterior fossa lesion, anoxia or infection.
 - MRI Brain with and without contrast (CPT[®] 70553) **OR**
 - MRI Brain without contrast (CPT[®] 70551)
- Oral Appliance:
 - There is a lack of published case-controlled clinical studies in Sleep literature validating the use of advanced imaging with respect to oral appliance therapy (pretreatment assessment).
 - Previous literature has demonstrated support for cephalometric studies (x-ray)¹ in predicting treatment success.
 - Nasoendoscopy (sedated and non-sedated with provocative maneuvers such as Mueller maneuver) has been helpful as well in this regard.²
 - Routine use of advanced imaging is not supported at this time.
- For suspected sleep-related seizures (see **Epilepsy and Other Seizure Disorders (HD-9)**)

References (HD-37)

HD.SL.0037.2.A

v3.0.2024

1. Guarda-Nardini L, Manfredini D, Mion M, Heir G, Marchese-Ragona R. Anatomically Based Outcome Predictors of Treatment for Obstructive Sleep Apnea with Intraoral Splint Devices: A Systematic Review of Cephalometric Studies. *Journal of Clinical Sleep Medicine*. 2015;11(11):1327-1334. doi:10.5664/jcsm.5198
2. Sutherland K, Vanderveken OM, Tsuda H, et al. Oral Appliance Treatment for Obstructive Sleep Apnea: An Update. *Journal of Clinical Sleep Medicine*. Published online February 15, 2014. doi:10.5664/jcsm.3460
3. Deak MC, Kirsch DB. Sleep-Disordered Breathing in Neurologic Conditions. *Clinics in Chest Medicine*. 2014;35(3):547-556. doi:10.1016/j.ccm.2014.06.009
4. Trotti LM, Bliwise DL. Brain MRI findings in patients with idiopathic hypersomnia. *Clin Neurol Neurosurg*. 2017;157:19-21. doi:10.1016/j.clineuro.2017.03.010
5. Kotuła J, Kuc AE, Lis J, Kawala B, Sarul M. New Sagittal and Vertical Cephalometric Analysis Methods: A Systematic Review. *Diagnostics (Basel)*. 2022;12(7):1723. Published 2022 Jul 15. doi:10.3390/diagnostics12071723
6. Ramar K, Dort LC, Katz SG, et al. Clinical Practice Guideline for the Treatment of Obstructive Sleep Apnea and Snoring with Oral Appliance Therapy: An Update for 2015. *J Clin Sleep Med*. 2015;11(7):773-827. Published 2015 Jul 15. doi:10.5664/jcsm.4858
7. Chen H, Eckert DJ, van der Stelt PF, Guo J, Ge S, Emami E, Almeida FR, Huynh NT (2020) Phenotypes of responders to mandibular advancement device therapy in obstructive sleep apnea patients: a systematic review and meta-analysis. *Sleep Med Rev*. 49:101229

Table of Contents

Guideline

- General Guidelines (MS-1)
- Imaging Techniques (MS-2)
- 3D Rendering (MS-3)
- Avascular Necrosis (AVN)/Osteonecrosis (MS-4)
- Fractures (MS-5)
- Foreign Body (MS-6)
- Ganglion Cysts (MS-7)
- Gout/Calcium Pyrophosphate Deposition Disease (CPPD)/
Pseudogout/Chondrocalcinosis (MS-8)
- Infection/Osteomyelitis (MS-9)
- Soft Tissue Mass or Lesion of Bone (MS-10)
- Muscle/Tendon Unit Injuries/Diseases (MS-11)
- Osteoarthritis (MS-12)
- Chondral/Osteochondral Lesions (MS-13)
- Osteoporosis (MS-14)
- Rheumatoid Arthritis (RA) and Inflammatory Arthritis (MS-15)
- Post-Operative Joint Replacement Surgery (MS-16)
- Limb Length Discrepancy (MS-17)
- Anatomical Area Tables – General Information (MS-18)
- Shoulder (MS-19)
- Elbow (MS-20)
- Wrist (MS-21)
- Hand (MS-22)
- Pelvis (MS-23)
- Hip (MS-24)
- Knee (MS-25)
- Ankle (MS-26)
- Foot (MS-27)
- Nuclear Medicine (MS-28)

General Guidelines (MS-1)

Guideline

Procedure Codes Associated with Musculoskeletal Imaging (MS)

General Guidelines (MS-1.0)

References (MS-1)

Procedure Codes Associated with Musculoskeletal Imaging (MS)

MS.GG.ProcedureCodes.A
v1.0.2024

MRI/MRA	CPT®
MRI Upper Extremity, other than joint, without contrast	73218
MRI Upper Extremity, other than joint, with contrast	73219
MRI Upper Extremity, other than joint, without and with contrast	73220
MRI Upper Extremity, any joint, without contrast	73221
MRI Upper Extremity, any joint, with contrast	73222
MRI Upper Extremity, any joint, without and with contrast	73223
MR Angiography Upper Extremity without or with contrast	73225
MRI Lower Extremity, other than joint, without contrast	73718
MRI Lower Extremity, other than joint, with contrast	73719
MRI Lower Extremity, other than joint, without and with contrast	73720
MRI Lower Extremity, any joint, without contrast	73721
MRI Lower Extremity, any joint, with contrast	73722
MRI Lower Extremity, any joint, without and with contrast	73723
MR Angiography Lower Extremity without or with contrast	73725
MRI Pelvis without contrast	72195
MRI Pelvis with contrast	72196
MRI Pelvis without and with contrast	72197

CT/CTA	CPT®
CT Upper Extremity without contrast	73200
CT Upper Extremity with contrast	73201
CT Upper Extremity without and with contrast	73202
CT Angiography Upper Extremity without and with contrast	73206
CT Lower Extremity without contrast	73700
CT Lower Extremity with contrast	73701
CT Lower Extremity without and with contrast	73702
CT Angiography Lower Extremity without and with contrast	73706
CT Pelvis without contrast	72192

CT/CTA	CPT®
CT Pelvis with contrast	72193
CT Pelvis without and with contrast	72194
Bone Mineral Density CT, one or more sites, axial skeleton	77078

Ultrasound	CPT®
Ultrasound, complete joint (ie, joint space and peri-articular soft tissue structures) real-time with image documentation	76881
Ultrasound, limited, joint or other nonvascular extremity structure(s) (e.g., joint space, peri-articular tendon[s], muscle[s], nerve[s], other soft tissue structure[s], or soft tissue mass[es]), real-time with image documentation	76882
Ultrasound, pelvic (nonobstetric), real time with image documentation	76857

Nuclear Medicine	CPT®
Bone Marrow Imaging, Limited	78102
Bone Marrow Imaging, Multiple	78103
Bone Marrow Imaging, Whole Body	78104
Bone or Joint Imaging Limited	78300
Bone or Joint Imaging Multiple	78305
Bone Scan Whole Body	78306
Bone Scan 3 Phase Study	78315
Radiopharmaceutical localization of tumor, inflammatory process or distribution of radiopharmaceutical agent(s) (includes vascular flow and blood pool imaging, when performed); planar, single area (e.g., head, neck, chest, pelvis), single day imaging	78800
Radiopharmaceutical localization of tumor, inflammatory process or distribution of radiopharmaceutical agent(s) (includes vascular flow and blood pool imaging, when performed); planar, 2 or more areas (eg, abdomen and pelvis, head and chest), 1 or more days imaging or single area imaging over 2 or more days	78801
Radiopharmaceutical localization of tumor, inflammatory process or distribution of radiopharmaceutical agent(s) (includes vascular flow and blood pool imaging, when performed); planar, whole body, single day imaging	78802

Nuclear Medicine	CPT [®]
Radiopharmaceutical localization of tumor, inflammatory process or distribution of radiopharmaceutical agent(s) (includes vascular flow and blood pool imaging, when performed); tomographic (SPECT), single area (e.g., head, neck, chest, pelvis), single day imaging	78803
Radiopharmaceutical localization of tumor, inflammatory process or distribution of radiopharmaceutical agent(s) (includes vascular flow and blood pool imaging, when performed); tomographic (SPECT) with concurrently acquired computed tomography (CT) transmission scan for anatomical review, localization and determination/detection of pathology, single area (e.g., head, neck, chest, pelvis), single day imaging	78830
Radiopharmaceutical localization of tumor, inflammatory process or distribution of radiopharmaceutical agent(s) (includes vascular flow and blood pool imaging, when performed); tomographic (SPECT), minimum 2 areas (e.g., pelvis and knees, abdomen and pelvis), single day imaging, or single area imaging over 2 or more days	78831
Radiopharmaceutical localization of tumor, inflammatory process or distribution of radiopharmaceutical agent(s) (includes vascular flow and blood pool imaging, when performed); tomographic (SPECT) with concurrently acquired computed tomography (CT) transmission scan for anatomical review, localization and determination/detection of pathology, minimum 2 areas (e.g., pelvis and knees, abdomen and pelvis), single day imaging, or single area imaging over 2 or more days	78832

General Guidelines (MS-1.0)

MS.GG.0001.0.A

v1.0.2024

- Before advanced diagnostic imaging can be considered, there must be an in-person clinical evaluation as well as a clinical re-evaluation after a trial of failed conservative treatment; the clinical re-evaluation may consist of an in-person evaluation or other meaningful contact with the provider's office such as email, web or telephone communications.
- An in-person clinical evaluation for the current episode of the condition is required to have been performed before advanced imaging can be considered. This may have been either the initial clinical evaluation or the clinical re-evaluation.
- The in-person clinical evaluation should include a relevant history and physical examination, appropriate laboratory studies, and non-advanced imaging modalities. Other forms of meaningful contact (e.g., telephone call, electronic mail, telemedicine, or messaging) are not acceptable as an in-person evaluation.
- Prior to advanced imaging consideration, the results of plain x-rays performed after the current episode of symptoms started or changed need to be available to the requesting provider of the advanced imaging study for all musculoskeletal conditions, unless otherwise noted in the guidelines.
 - Initial plain x-ray can rule out those situations that do not often require advanced imaging, such as osteoarthritis, acute/healing fracture, dislocation, osteomyelitis, acquired/congenital deformities, and tumors of bone amenable to biopsy or radiation therapy (in known metastatic disease), etc.
 - X-ray may provide complementary clinical information regarding detailed bony anatomy, and may assist with preoperative planning when surgery is being contemplated.
 - X-ray may provide clinically significant details for soft tissue masses, such as soft tissue calcification, presence or absence of phleboliths, radiographic density, and effect on adjacent bone.
 - X-ray often has a larger field of view than MRI or CT and has the potential to identify more proximal or distal pathology in an extremity.
- Clinical re-evaluation is required prior to consideration of advanced diagnostic imaging to document failure of significant clinical improvement following a recent (within 3 months) six week trial of provider-directed conservative treatment. Clinical re-evaluation can include documentation of an in-person encounter or documentation of other meaningful contact with the requesting provider's office by the individual (e.g. telephone call, electronic mail, telemedicine, or messaging).
- Provider-directed conservative treatment may include rest, ice, compression, and elevation (R.I.C.E.), non-steroidal anti-inflammatories (NSAIDs), narcotic and non-narcotic analgesic medications, oral or injectable corticosteroids, viscosupplementation injections, a provider-directed home exercise program, cross-training, and/or physical/occupational therapy or immobilization by splinting/casting/bracing.

- Orthopedic specialist evaluation can be helpful in determining the need for advanced imaging.
 - The need for repeat advanced imaging should be carefully considered and may not be indicated if prior imaging has been performed.
 - Serial advanced imaging, whether CT or MRI, for surveillance of healing or recovery from musculoskeletal disease is not supported by the medical evidence in the majority of musculoskeletal conditions.

References (MS-1)

v1.0.2024

1. Reinus WR. Clinician's guide to diagnostic imaging. New York, NY: Springer Science; 2014.
2. Visconti AJ, Biddle J, Solomon M. Follow-up imaging for vertebral osteomyelitis a teachable moment. *JAMA*. 2014;174(2):184. doi: 10.1001/jamainternmed.2013.12742.
3. Fabiano V, Franchino G, Napolitano M, Ravelli A, Dilillo D, Zuccotti GV. Utility of magnetic resonance imaging in the follow-up of children affected by acute osteomyelitis. *Curr Pediatr Res*. 2017;21(2):354-358.

Imaging Techniques (MS-2)

Guideline

Plain X-Ray (MS-2.1)

MRI or CT (MS-2.2)

Ultrasound (MS-2.3)

Contrast Issues (MS-2.4)

Positron Emission Tomography (PET/CT) (MS-2.5)

Nuclear Medicine (MS-2.6)

References (MS-2)

Plain X-Ray (MS-2.1)

MS.IM.0002.1.A

v1.0.2024

- The results of plain x-rays performed after the current episode of symptoms started or changed need to be available to the requesting provider of the advanced imaging study for all musculoskeletal conditions, unless otherwise noted in the guidelines, to rule out those situations that do not often require advanced imaging, such as: osteoarthritis, acute/healing fracture, dislocation, osteomyelitis, acquired/congenital deformities, and tumors of bone amenable to biopsy or radiation therapy (in known metastatic disease), etc.

MRI or CT (MS-2.2)

MS.IM.0002.2.A

v1.0.2024

- Magnetic Resonance Imaging (MRI) is often the preferred advanced imaging modality in musculoskeletal conditions because it is superior in imaging the soft tissues and can also define physiological processes in some instances [e.g. edema, loss of circulation (AVN), and increased vascularity (tumors)].
- Computed Tomography (CT) is preferred for imaging cortical bone anatomy; thus, it is useful for studying complex fractures (particularly of the joints), dislocations, and assessing delayed union or non-union of fractures, if plain X-rays are equivocal. CT may be the procedure of choice in individuals who cannot undergo an MRI, such as those with pacemakers.
- Bilateral Imaging
 - Coding for bilateral imaging may vary from health care plan to health care plan. Not all coding options may be available for all health care plans.

Positional MRI

- Positional MRI is also referred to as dynamic, standing, weight-bearing, or kinetic MRI. Currently, there is inadequate scientific evidence to support the medical necessity of this study. As such, it should be considered experimental or investigational.

Positional CT

- Positional CT, also referred to as weight-bearing or cone beam CT, may be useful in imaging of the foot and ankle.
 - If a request for foot or ankle imaging with positional CT meets medical necessity criteria for standard CT imaging (as defined in the condition-specific guidelines), the request may be approved.
 - Positional CT of anatomic areas other than the foot and ankle are considered experimental or investigational.

dGEMRIC Evaluation of Cartilage

- Delayed gadolinium enhanced Magnetic Resonance Imaging of Cartilage (dGEMRIC) is a technique where an MRI estimates joint cartilage glycosaminoglycan content after penetration of the contrast agent in order to detect cartilage breakdown. Currently, there is inadequate scientific evidence to support the medical necessity of this study. As such, it should be considered experimental or investigational for the diagnosis and surveillance of, or preoperative planning related to chondral pathology.

Ultrasound (MS-2.3)

MS.IM.0002.3.A

v1.0.2024

- Ultrasound (US) uses sound waves to produce images that can be used to evaluate a variety of musculoskeletal disorders. As with US in general, musculoskeletal US is highly operator-dependent, and proper training and experience are required to perform consistent, high quality evaluations.

Contrast Issues (MS-2.4)

MS.IM.0002.4.A

v1.0.2024

- Most musculoskeletal imaging (MRI or CT) is without contrast; however, the following examples may be considered with contrast:
 - Tumors, osteomyelitis, and soft tissue infection (without and with contrast)
 - MRI arthrography (with contrast only)
 - MRI for rheumatoid arthritis and inflammatory arthritis (contrast as requested)
 - For individuals with a contrast contraindication, if the advanced imaging recommendation specifically includes contrast, the corresponding advanced imaging study without contrast may be approved as an alternative, although the non-contrast study may not provide an adequate evaluation of the condition of concern.

Positron Emission Tomography (PET/CT) (MS-2.5)

MS.IM.0002.5.A

v1.0.2024

- PET/CT is a nuclear medicine/computed tomography (CT) fusion study that uses a positron emitting radiotracer to create cross-sectional and volumetric images based on tissue metabolism. PET imaging fusion with CT allows for better anatomic localization of the areas of abnormal increased tissue activity seen on PET.
- PET/CT is indicated for imaging of certain musculoskeletal conditions when MRI or CT is equivocal or cannot be performed. See: **Nuclear Medicine (MS-28)** for specific indications.
 - At this time, FDG is the only indicated radiotracer for use with PET/CT in the imaging of musculoskeletal conditions.

Nuclear Medicine (MS-2.6)

MS.IM.0002.6.A

v1.0.2024

- A bone scan is a nuclear medicine imaging study in which an amount of radioactive material is injected and images are obtained at different time intervals, depending on the condition. A bone scan is done to reveal problems with bone metabolism. Areas where bone cells are repairing themselves show the most activity. It can help diagnose a number of bone conditions, including cancer of the bone or metastasis, location of bone inflammation, fracture, and bone infection.
- Nuclear Medicine WBC Scan is performed using radioactive material which is tagged to the white blood cells. When injected into the body, the material attaches to sites of inflammation/infection. Once distributed in these areas, the sites of suspected infection/inflammation can be seen on nuclear imaging equipment. These can be imaged as a planar study, SPECT study, or SPECT/CT study.
- Bone Marrow Imaging is used in combination with a WBC Scan to help differentiate between true infection and physiological marrow uptake. The bone marrow scan provides a map of the normal physiological white cell uptake that is then compared to the white blood cell scan. Any discordance in white cell uptake (e.g., more WBC uptake than marrow uptake) between the two studies indicates a focus of infection.
- See: **Nuclear Medicine (MS-28)** and condition-specific guidelines for specific indications.

References (MS-2)

v1.0.2024

1. DeMuro JP, Simmons S, Smith K, et al. Utility of MRI in blunt trauma patients with a normal cervical spine CT and persistent midline neck pain on palpation. *Global Journal of Surgery*. 2013;1(1):4-7. doi:10.12691/js-1-1-2.
2. Hsu W, Hearty TM. Radionuclide imaging in the diagnosis and management of orthopaedic disease. *J Am Acad Orthop Surg*. 2012;20(3):151-159. doi:10.5435/JAAOS-20-03-151.
3. Kayser R, Mahlfeld K, Heyde CE. Partial rupture of the proximal Achilles tendon: a differential diagnostic problem in ultrasound imaging. *Br J Sports Med*. 2005;9(11):838-842. doi:10.1136/bjsm.2005.018416.
4. Ward RJ, Weissman BN, Kransdorf MJ, et al. Expert Panel on Musculoskeletal Imaging. ACR Appropriateness Criteria® Acute hip pain-suspected fracture. *Am Coll Radiol (ACR)*; Date of Origin: 2013. Revised: 2018. <https://acsearch.acr.org/docs/3082587/Narrative/>.
5. Mosher TJ, Kransdorf MJ, Adler R, et al. Expert Panel on Musculoskeletal Imaging. ACR Appropriateness Criteria® Acute trauma to the ankle. *Am Coll Radiol (ACR)*; Date of Origin: 2013. Revised: 2020. <https://acsearch.acr.org/docs/69436/Narrative/>.
6. Small KM, Adler RS, Shah SH, et al. Expert Panel on Musculoskeletal Imaging. ACR Appropriateness Criteria® Shoulder Pain - Atraumatic. *Am Coll Radiol (ACR)*; New 2018. <https://acsearch.acr.org/docs/3101482/Narrative/>.
7. Amini B, Beckmann NM, Beaman FD, et al. Expert Panel on Musculoskeletal Imaging. ACR Appropriateness Criteria® Shoulder Pain - Traumatic. *Am Coll Radiol (ACR)*; Revised 2017. <https://acsearch.acr.org/docs/69433/Narrative/>.
8. Hayes CW, Roberts CC, Bencardino JT, et al. Expert Panel on Musculoskeletal Imaging. ACR Appropriateness Criteria® chronic elbow pain. *Am Coll Radiol (ACR)*; Date of Origin:1998. Revised: 2022. <https://acsearch.acr.org/docs/69423/Narrative/>.
9. Wise JN, Weissman BN, Appel M, et al. Expert Panel on Musculoskeletal Imaging. ACR Appropriateness Criteria® chronic foot pain. *Am Coll Radiol (ACR)*; Date of Origin:1998. Revised: 2020. <https://acsearch.acr.org/docs/69424/Narrative/>.
10. Mintz DN, Roberts CC, Bencardino JT, et al. Expert Panel on Musculoskeletal Imaging. ACR Appropriateness Criteria® chronic hip pain. *Am Coll Radiol (ACR)*; Revised: 2016. <https://acsearch.acr.org/docs/69425/Narrative/>.
11. Rubin DA, Roberts CC, Bencardino JT, et al. Expert Panel on Musculoskeletal Imaging. ACR Appropriateness Criteria® chronic wrist pain. *Am Coll Radiol (ACR)*; Revised: 2017. <https://acsearch.acr.org/docs/69427/Narrative/>.
12. Bennett DL, Nelson JW, Weissman BN, et al. Expert Panel on Musculoskeletal Imaging. ACR Appropriateness Criteria® nontraumatic knee pain. *Am Coll Radiol (ACR)*;1995. Revised: 2018. <https://acsearch.acr.org/docs/69432/Narrative/>.
13. Murphey MD, Roberts CC, Bencardino JT, et al. Expert Panel on Musculoskeletal Imaging. ACR Appropriateness Criteria® osteonecrosis of the hip. *Am Coll Radiol (ACR)*;Date of Origin: 1995. Revised: 2022. <https://acsearch.acr.org/docs/69420/Narrative/>.
14. Bruno MA, Weissman BN, Kransdorf MJ, et al. Expert Panel on Musculoskeletal Imaging. ACR Appropriateness Criteria® acute hand and wrist trauma. *Am Coll Radiol (ACR)*; Date of Origin: 1995. Revised: 2018. <https://acsearch.acr.org/docs/69418/Narrative/>.
15. Bencardino JT, Stone TJ, Roberts CC, et al. Expert Panel on Musculoskeletal Imaging. ACR Appropriateness Criteria® stress (fatigue/insufficiency) fracture, including sacrum, excluding other vertebrae. *Am Coll Radiol (ACR)*; Revised: 2016. <https://acsearch.acr.org/docs/69435/Narrative/>.
16. Luchs JS, Flug JA, Weissman BN, et al. Expert Panel on Musculoskeletal Imaging. ACR Appropriateness Criteria® chronic ankle pain. *Am Coll Radiol (ACR)*; Date of Origin: 1998. Revised: 2017. <https://acsearch.acr.org/docs/69422/Narrative/>.
17. Beaman FD, von Herrmann PF, Kransdorf MJ, et al. Expert Panel on Musculoskeletal Imaging. ACR Appropriateness Criteria® suspected osteomyelitis, septic arthritis, or soft tissue infection (excluding spine and diabetic foot. *Am Coll Radiol (ACR)*; Date of Origin: 2016. Revised: 2022. <https://acsearch.acr.org/docs/%203094201/Narrative/>.
18. Kransdorf MJ, Weissman BN, Appel M, et al. Expert Panel on Musculoskeletal Imaging. ACR Appropriateness Criteria® suspected osteomyelitis of the foot in patients with diabetes mellitus. *Am Coll Radiol (ACR)*; Date of Origin: 1995. Revised: 2019. <https://acsearch.acr.org/docs/69340/Narrative/>.
19. Zoga AC, Weissman BN, Kransdorf MJ, et al. Expert Panel on Musculoskeletal Imaging. ACR Appropriateness Criteria® soft-tissue masses. *Am Coll Radiol (ACR)*; Date of Origin: 1995. Revised: 2017. <https://acsearch.acr.org/docs/69434/Narrative/>.

20. Morrison WB, Weissman BN, Kransdorf MJ, et al. Expert Panel on Musculoskeletal Imaging. ACR Appropriateness Criteria® primary bone tumors. *Am Coll Radiol (ACR)*; Date of Origin: 1995. Revised: 2019. <https://acsearch.acr.org/docs/69421/Narrative/>.
21. Weissman BN, Palestro CJ, Appel M, et al. Expert Panel on Musculoskeletal Imaging. ACR Appropriateness Criteria® imaging after total hip arthroplasty. *Am Coll Radiol (ACR)*; Date of Origin:1998. Revised: 2015. <https://acsearch.acr.org/docs/3094200/Narrative/>.
22. Hochman MG, Melenevsky YV, Metter DF, et al. Expert Panel on Musculoskeletal Imaging. ACR Appropriateness Criteria® imaging after total knee arthroplasty. *Am Coll Radiol (ACR)*; Revised: 2017. <https://acsearch.acr.org/docs/69430/Narrative/>.
23. Gyftopoulos S, Rosenberg ZS, Roberts CC, et al. Expert Panel on Musculoskeletal Imaging. ACR Appropriateness Criteria® imaging after shoulder arthroplasty. *Am Coll Radiol (ACR)*; Date of Origin: 2016. Revised: 2021<https://acsearch.acr.org/docs/3097049/Narrative/>.
24. Patel ND, Broderick DF, Burns J, et al. Expert Panel on Neurologic Imaging. ACR Appropriateness Criteria®: low back pain. *Am Coll Radiol (ACR)*; Date of Origin:1996. Last Review: 2021. <https://acsearch.acr.org/docs/69483/Narrative/>.
25. Shetty VS, Reis MN, Aulino JM, et al. Expert Panel on Neurologic Imaging. ACR Appropriateness Criteria®: head trauma. *Am Coll Radiol (ACR)*; Date of Origin:1996. Last Review: 2020. <https://acsearch.acr.org/docs/69481/Narrative/>.
26. Li X, Yi P, Curry EJ, Murakami AM. Ultrasonography as a diagnostic, therapeutic, and research tool in orthopaedic surgery. *J Am Acad Orthop Surg*. 2018;26(6):187-196. doi: 10.5435/JAAOS-D-16-00221.
27. de Cesar Netto C, Myerson MS, Day J, et. al. Consensus for the use of weightbearing CT in the assessment of progressive collapsing foot deformity. *Foot Ankle Int*. 2020;41(10):1277-1282.
28. Conti MS, Ellis SJ. Weight-bearing ct scans in foot and ankle surgery. *J Am Acad Orthop Surg*. 2020;28(14):e595-e603.
29. de Cesar Netto C, Schon LC, Thawait GK, et. al. Flexible adult acquired flatfoot deformity: comparison between weight-bearing and non-weight-bearing measurements using cone-beam computed tomography. *J Bone Joint Surg Am*. 2017;99(18):e98.

3D Rendering (MS-3)

Guideline

3D Rendering (MS-3)

Reference (MS-3)

3D Rendering (MS-3)

MS.TD.0003.U

v1.0.2024

- Indications for musculoskeletal 3-D image post-processing for preoperative planning when conventional imaging is insufficient for:
 - Complex fractures (comminuted or displaced)/dislocations of any joint.
 - Spine fractures, pelvic/acetabulum fractures, intra-articular fractures.
 - Preoperative planning for other complex surgical cases.
- The code assignment for 3-D rendering depends upon whether the 3-D post-processing is performed on the scanner workstation (CPT® 76376) or on an independent workstation (CPT® 76377).
 - 2-D reconstruction (i.e. reformatting axial images into the coronal plane) is considered part of the tomography procedure, is not separately reportable, and does not meet the definition of 3-D rendering.
 - It is not appropriate to report 3-D rendering in conjunction with CTA and MRA because those procedure codes already include the post-processing.
 - In addition to the term "3-D," the following terms may also be used to describe 3-D post-processing:
 - Maximum intensity projection (MIP)
 - Shaded surface rendering
 - Volume rendering
 - Additionally - If multiple CPT codes are performed for the same indication on the same day, one 3D rendering code is required. If they are performed on separate days, 3D rendering codes are required for each study on each day.
- The 3-D rendering codes require concurrent supervision of image post-processing 3-D manipulation of volumetric data set and image rendering.

Reference (MS-3)

v1.0.2024

1. Bruno MA, Weissman BN, Kransdorf MJ, et al. Expert Panel on Musculoskeletal Imaging. ACR Appropriateness Criteria® acute hand and wrist trauma. Am Coll Radiol (ACR); Date of Origin:1995. Revised: 2018. <https://acsearch.acr.org/docs/69418/Narrative/>.

Avascular Necrosis (AVN)/Osteonecrosis (MS-4)

Guideline

AVN (MS-4.1)

References (MS-4)

AVN (MS-4.1)

MS.AN.0004.1.A

v1.0.2024

- MRI without contrast, MRI without and with contrast, or CT without contrast of the area of interest can be performed when plain x-ray findings are negative or equivocal and clinical symptoms warrant further investigation for suspected avascular necrosis.
- Advanced imaging for AVN confirmed by plain x-ray is appropriate for treatment planning in the following situations:
 - Femoral head:
 - MRI Hip without contrast (CPT® 73721) or CT Hip without contrast (CPT® 73700)
 - Distal Femur:
 - MRI Knee without contrast (CPT® 73721) or CT Knee without contrast (CPT® 73700)
 - Talus:
 - MRI Ankle without contrast (CPT® 73721) or CT Ankle without contrast (CPT® 73700)
 - Tarsal navicular (Kohler Disease):
 - MRI Foot without contrast (CPT® 73718) or CT Foot without contrast (CPT® 73700)
 - Metatarsal head (Frieberg's Infraction):
 - MRI Foot without contrast (CPT® 73718) or CT Foot without contrast (CPT® 73700)
 - Humeral head:
 - MRI Shoulder without contrast (CPT® 73221) or CT Shoulder without contrast (CPT® 73200)
 - Lunate (Kienbock's Disease)/Scaphoid (Preiser's Disease):
 - CT Wrist without contrast (CPT® 73200) or MRI Wrist without contrast (CPT® 73221)
- Individuals with acute lymphoblastic leukemia and known or suspected osteonecrosis should be imaged according to guidelines in **Acute Lymphoblastic Leukemia (PEDONC-3.2)**
- Known or suspected osteonecrosis in long-term cancer survivors should be imaged according to guidelines in **Osteonecrosis in Long Term Cancer Survivors (PEDONC-19.4)**

Background and Supporting Information

- Classification systems use a combination of plain radiographs, MRI, and clinical features to stage avascular necrosis.

References (MS-4)

v1.0.2024

1. Calder JD, Hine AL, Pearse MF, Revell PA. The relationship between osteonecrosis of the proximal femur identified by MRI and lesions proven by histological examination. *J Bone Joint Surg Br.* 2008;90(2):154-158.
2. Karantanas AH, Drakonaki EE. The role of MR imaging in avascular necrosis of the femoral head. *Semin Musculoskelet Radiol.* 2011;15(3):281-300. doi:10.1055/s-0031-1278427.
3. Karim AR, Cherian JJ, Jauregui JJ, et al. Osteonecrosis of the knee: review. *Ann Transl Med.* 2015;3(1). doi:10.3978/j.issn.2305-5839.2014.11.13.
4. Mintz DN, Roberts CC, Bencardino JT, et al. Expert Panel on Musculoskeletal Imaging. ACR Appropriateness Criteria® chronic hip pain. *Am Coll Radiol (ACR)*; Revised:2016. <https://acsearch.acr.org/docs/69425/Narrative/>.
5. Rubin DA, Roberts CC, Bencardino JT, et al. Expert Panel on Musculoskeletal Imaging. ACR Appropriateness Criteria® chronic wrist pain. *Am Coll Radiol (ACR)*; Revised:2017. <https://acsearch.acr.org/docs/69427/Narrative/>.
6. Bennett DL, Nelson JW, Weissman BN, et al. Expert Panel on Musculoskeletal Imaging. ACR Appropriateness Criteria® nontraumatic knee pain. *Am Coll Radiol (ACR)*; Date of Origin:1995. Revised: 2018. <https://acsearch.acr.org/docs/69432/Narrative/>.
7. Murphey MD, Roberts CC, Bencardino JT, et al. Expert Panel on Musculoskeletal Imaging. ACR Appropriateness Criteria® Osteonecrosis. *Am Coll Radiol (ACR)*; Date of Origin:1995. Revised: 2022. <https://acsearch.acr.org/docs/69420/Narrative/>.

Fractures (MS-5)

Guideline

Acute Fracture (MS-5.1)

Suspected Occult/Stress/Insufficiency Fracture/Stress Reaction and Shin Splints (MS-5.2)

Other Indications (MS-5.3)

References (MS-5)

Acute Fracture (MS-5.1)

MS.FX.0005.1.A

v1.0.2024

- CT or MRI without contrast if **ANY** of the following:
 - Complex (comminuted or displaced) fracture with or without dislocation on plain x-ray.
 - CT is preferred unless it is associated with neoplastic disease when MRI without/with contrast is preferred unless MRI contraindicated.
 - Individual presents initially to the requesting provider with a documented history of an acute traumatic event at least two weeks prior with a negative plain x-ray at the time of this face-to-face encounter and a clinical suspicion for an occult/stress/insufficiency fracture see: **Suspected Occult/ Stress/ Insufficiency Fracture/ Stress Reaction and Shin Splints (MS-5.2)**.
- For osteochondral fracture or osteochondral injury, see: **Chondral/Osteochondral Lesions, Including Osteochondritis Dissecans and Fractures (MS-13.1)**

Suspected Occult/Stress/Insufficiency Fracture/Stress Reaction and Shin Splints (MS-5.2)

MS.FX.0005.2.A

v1.0.2024

- MRI without contrast can be performed for suspected hip/femoral neck, tibia, pelvis/sacrum, tarsal navicular, proximal fifth metatarsal, or scaphoid occult/stress/insufficiency fractures, and suspected atypical femoral shaft fractures related to bisphosphonate use if the initial evaluation of history, physical exam and plain x-ray fails to establish a definitive diagnosis.
 - CT without contrast can be performed as an alternative to MRI for suspected occult/insufficiency fractures of the pelvis/hip and suspected atypical femoral shaft fractures related to bisphosphonate see: **Pelvis (MS-23)** and **Hip (MS-24)**, and suspected occult fractures of the scaphoid see: **Wrist (MS-21)**.
 - For suspected fractures, when MRI cannot be performed, any one of the following is indicated:
 - Tc-99m Bone scan whole body (CPT[®] 78306) with SPECT of the area of interest (CPT[®] 78803) OR
 - Bone scan (CPT[®] 78315, 78300) OR
 - SPECT/CT (CPT[®] 78830)
 - See: **Nuclear Medicine (MS-28)**
- MRI or CT without contrast can be performed for all other suspected occult/stress/insufficiency fractures with either of the following:
 - Repeat plain x-rays remain non-diagnostic for fracture after a minimum of 10 days of provider-directed conservative treatment, or
 - Initial plain x-rays obtained a minimum of 14 days after the onset of symptoms are non-diagnostic for fracture
 - For suspected fractures, when MRI cannot be performed, any one of the following is indicated:
 - Tc-99m Bone scan whole body (CPT[®] 78306) with SPECT of the area of interest (CPT[®] 78803) OR
 - Bone scan (CPT[®] 78315, 78300) OR
 - SPECT/CT (CPT[®] 78830)
 - See: **Nuclear Medicine (MS-28)**
- MRI of the lower leg without contrast (CPT[®] 73718) for suspected shin splints when **BOTH** of the following are met:
 - Initial plain x-ray
 - Failure of a 6-week trial of provider-directed conservative treatment

- For stress reaction, advanced imaging is not medically necessary for surveillance or “return to play” decisions regarding a stress reaction identified on an initial imaging study.
- MRI without contrast of the area of interest for stress fracture follow-up imaging for “return to play” evaluation at least 3 months after the initial imaging study for stress fracture.
- For periprosthetic fractures related to joint replacement see: **Post-Operative Joint Replacement Surgery (MS-16.1)**, **Shoulder (MS-19)**, **Elbow (MS-20)**, **Hip (MS-24)**, **Knee (MS-25)**, and **Ankle (MS-26)**.

Other Indications (MS-5.3)

MS.FX.0005.3.A

v1.0.2024

- CT or MRI without contrast after recent (within 30 days) plain x-ray if **ONE** of the following is present:
 - Concern for delayed union or non-union of fracture, osteotomy, or joint fusions.
 - Part of preoperative evaluation for a planned surgery of a complex fracture with or without dislocation.

References (MS-5)

v1.0.2024

1. Bencardino JT, Stone TJ, Roberts CC, et al. Expert Panel on Musculoskeletal Imaging. ACR Appropriateness Criteria® Stress (Fatigue/Insufficiency) Fracture, Including Sacrum, Excluding Other Vertebrae. *Am Coll Radiol (ACR)*; Revised: 2016. <https://acsearch.acr.org/docs/69435/Narrative/>.
2. Mintz DN, Roberts CC, Bencardino JT, et al. Expert Panel on Musculoskeletal Imaging. ACR Appropriateness Criteria® Chronic Hip Pain. *Am Coll Radiol (ACR)*; Revised: 2016. <https://acsearch.acr.org/docs/69425/Narrative/>.
3. Bruno MA, Weissman BN, Kransdorf MJ, et al. Expert Panel on Musculoskeletal Imaging. ACR Appropriateness Criteria® Acute Hand and Wrist Trauma. *Am Coll Radiol (ACR)*; Date of Origin: 1995. Revised: 2018. <https://acsearch.acr.org/docs/69418/Narrative/>.
4. Luchs JS, Flug JA, Weissman BN, et al. Expert Panel on Musculoskeletal Imaging. ACR Appropriateness Criteria® Chronic Ankle Pain. *Am Coll Radiol (ACR)*; Date of Origin: 1998. Revised: 2017. <https://acsearch.acr.org/docs/69422/Narrative/>.
5. Ward RJ, Weissman BN, Kransdorf MJ, et al. Expert Panel on Musculoskeletal Imaging. ACR Appropriateness Criteria® Acute Hip Pain-Suspected Fracture. *Am Coll Radiol (ACR)*; Date of Origin: 2013. Revised: 2018. <https://acsearch.acr.org/docs/3082587/Narrative/>.
6. Mosher TJ, Kransdorf MJ, Adler R, et al. Expert Panel on Musculoskeletal Imaging. ACR Appropriateness Criteria® Acute Trauma to the Ankle. *Am Coll Radiol (ACR)*; Date of Origin: 2013. Revised: 2020. <https://acsearch.acr.org/docs/69436/Narrative/>.
7. Hayes CW, Roberts CC, Bencardino JT, et al. Expert Panel on Musculoskeletal Imaging. ACR Appropriateness Criteria® Chronic Elbow Pain. *Am Coll Radiol (ACR)*; Date of Origin: 1998. Revised: 2022. <https://acsearch.acr.org/docs/69423/Narrative/>.
8. Wise JN, Weissman BN, Appel M, et al. Expert Panel on Musculoskeletal Imaging. ACR Appropriateness Criteria® Chronic Foot Pain. *Am Coll Radiol (ACR)*; Date of Origin: 1998. Revised: 2020. <https://acsearch.acr.org/docs/69424/Narrative/>.
9. Greene WB. *Essentials of Musculoskeletal Care*. 3rd edition. Rosemont, IL: American Academy of Orthopaedic Surgeons; 2005:568-570.
10. Galbraith RM, Lavalley ME. Medial tibial stress syndrome: conservative treatment options. *Curr Rev Muscuolskelet Med*. 2009;2:127-133. doi:10.1007/s12178-009-9055-6.
11. Boks SS, Vroegindewij D, Kroes BW, et al. MRI follow-up of posttraumatic bone bruises of the knee in general practice. *AJR Am J Roentgenol*. 2007;189 556-562. doi:10.2214/AJR.07.2276.
12. Kaeding CC, Yu JR, Wright R, et al. Management and return to play of stress fractures. *Clin J Sport Med*. 2005;15:442-7.
13. Sormaala MJ, Niva MH, Kiuru MJ, et al. Stress injuries of the calcaneus detected with magnetic resonance imaging in military recruits. *J Bone Joint Surg Am*. 2006;88:2237-42. doi:10.2106/JBJS.E.01447.
14. Shin AY, Morin WD, Gorman JD, et al. The superiority of magnetic resonance imaging in differentiating the cause of hip pain in endurance athletes. *Am J Sports Med*. 1996;24:168-76. doi:10.1177/036354659602400209.
15. Slocum KA, Gorman JD, Puckett ML, et al. Resolution of abnormal MR signal intensity in patients with stress fractures of the femoral neck. *AJR Am J Roentgenol*. 1997;168:1295-9. doi:10.2214/ajr.168.5.9129429.
16. Fredericson M, Bergman AG, Hoffman KL, et al. Tibial stress reaction in runners. Correlation of clinical symptoms and scintigraphy with a new magnetic resonance imaging grading system. *Am J Sports Med*. 1995;23(4):472-81. doi:10.1177/036354659502300418.
17. Bernstein EM, Kelsey TJ, Cochran GK, Deafenbaugh BK, Kuhn KM. Femoral neck stress fractures: An updated review. *J Am Acad Orthop Surg*. 2022;30:302-311. doi:10.5435/JAAOS-D-21-00398.

Foreign Body (MS-6)

Guideline

Foreign Body – General (MS-6.1)

References (MS-6)

Foreign Body – General (MS-6.1)

MS.FB.0006.1.A

v1.0.2024

- Ultrasound (CPT® 76881 or CPT® 76882) or CT without contrast or MRI without and with contrast or MRI without contrast of the area of interest can be approved after plain x-rays rule out the presence of radiopaque foreign bodies.
 - Ultrasound (CPT® 76881 or CPT® 76882) is the preferred imaging modality for radiolucent (non-radiopaque) foreign bodies (e.g. wood, plastic).
 - CT without contrast is recommended when plain x-rays are negative and a radiopaque foreign body is still suspected, as CT is favored over MRI for the identification of foreign bodies
 - MRI without and with contrast is an alternative to US and CT for assessing the extent of infection associated with a suspected foreign body

References (MS-6)

v1.0.2024

1. Bancroft LW, Kransdorf MJ, Adler R, et al. Expert Panel on Musculoskeletal Imaging. ACR Appropriateness Criteria® Acute Trauma to the Foot. *Am Coll Radiol (ACR)*; Date of Origin: 2010. Revised: 2019. <https://acsearch.acr.org/docs/70546/Narrative/>.
2. Beaman FD, von Herrmann PF, Kransdorf MJ, et al. Expert Panel on Musculoskeletal Imaging. ACR Appropriateness Criteria® Suspected Osteomyelitis, Septic Arthritis, or Soft Tissue Infection (Excluding Spine and Diabetic Foot). *Am Coll Radiol (ACR)*; Date of Origin: 2016. Revised: 2022. <https://acsearch.acr.org/docs/%203094201/Narrative>.
3. Chan C, Salam GA. Splinter removal. *Am Fam Physician*. 2003;67(12):2557-2562.
4. Peterson JJ, Bancroft LW, Kransdorf MJ. Wooden foreign bodies: imaging appearance. (*AJR*) *Am J Roentgenol*. 2002;178(3):557-562. doi:10.2214/ajr.178.3.1780557.
5. Jarraya M, Hayashi D, de Villiers RV, et al. Multimodality imaging of foreign bodies of the musculoskeletal system. (*AJR*) *Am J Roentgenol*. 2014;203(1):W92-102. doi:10.2214/AJR.13.11743.

Ganglion Cysts (MS-7)

Guideline

Ganglion Cysts – General (MS-7.1)

References (MS-7)

Ganglion Cysts – General (MS-7.1)

MS.GC.0007.1.A

v1.0.2024

- Plain x-ray is the initial imaging study for ganglion cysts.
 - Results of plain x-rays performed after the current episode of symptoms started or changed need to be available to the requesting provider
- MRI without contrast or MRI without and with contrast or US (CPT® 76881 or CPT® 76882) is appropriate for surgical planning.
- Advanced imaging is not indicated for ganglions that can be diagnosed by history and physical examination.

References (MS-7)

v1.0.2024

1. Rubin DA, Roberts CC, Bencardino JT, et al. Expert Panel on Musculoskeletal Imaging ACR Appropriateness Criteria® Chronic wrist pain. *Am Coll Radiol (ACR)*; Revised: 2017. <https://acsearch.acr.org/docs/69427/Narrative/>.
2. Rubin DA, Roberts CC, Bencardino JT, et al. Expert Panel on Musculoskeletal Imaging. ACR Appropriateness Criteria® Soft-Tissue Masses. *Am Coll Radiol (ACR)*; Date of Origin: 1995. Revised: 2017. <https://acsearch.acr.org/docs/69434/Narrative/>.
3. Freire V, Guerini H, Campagna R, et al. Imaging of hand and wrist cysts: a clinical approach. (*AJR Am J R Roentgenol.* 2012;199(5):W618-W628. doi:10.2214/AJR.11.8087.
4. Vo P, Wright T, Hayden F, Dell P, et al. Evaluating dorsal wrist pain: MRI diagnosis of occult dorsal wrist ganglion. *J Hand Surg Am.* 1995;20(4):667-670. doi:10.1016/S0363-5023(05)80288-6.
5. Teefey SA, Dahiya N, Middleton WD, et al. Ganglia of the hand and wrist: a sonographic analysis. *AJR Am J Roentgenol.* 2008;191(3):716-720. doi:10.2214/AJR.07.3438.

Gout/Calcium Pyrophosphate Deposition Disease (CPPD)/ Pseudogout/Chondrocalc inosis (MS-8)

Guideline

Gout – General (MS-8.1)

CPPD (Pseudogout/Chondrocalcinosis) – General (MS-8.2)

References (MS-8)

Gout – General (MS-8.1)

MS.GD.0008.1.A

v1.0.2024

- CT without contrast, MRI without contrast, or MRI without and with contrast of the area of interest is indicated when **BOTH** of the following are met:
 - Initial plain x-ray to rule out other potential disease processes
 - Infection or neoplasm is in the differential diagnosis for soft-tissue tophi

Background and Supporting Information

- Early stages of gout can be diagnosed clinically since radiographic findings are not present early in the disease course.

CPPD (Pseudogout/Chondrocalcinosis) – General (MS-8.2)

MS.GD.0008.2.A

v1.0.2024

- Calcium pyrophosphate deposition disease (CPPD), also called pseudogout, can often be diagnosed from plain x-rays; advanced diagnostic imaging is generally not medically necessary.

References (MS-8)

v1.0.2024

1. Hsu CY, Shih TT, Huang KM, et al. Tophaceous gout of the spine: MR imaging features. *Clin Radiol*. 2002;57(10):919.
2. Schumacher HR Jr, Becker MA, Edwards NL, et al. Magnetic resonance imaging in the quantitative assessment of gouty tophi. *Int J Clin Pract*. 2006;60(4):408. doi:10.1111/j.1368-5031.2006.00853.x.
3. McQueen FM, Doyle A, Reeves Q, Gao A. Bone erosions in patients with chronic gouty arthropathy are associated with tophi but not bone oedema or synovitis: new insights from a 3 T MRI study. *Rheumatology*. 2014;53(1):95-103. doi:10.1093/rheumatology/ket329.
4. Dore RK. Gout: What primary care physicians want to know. *J Clin Rheumatol*. 2008;14(5S):S47-S54. doi:10.1097/RHU.0b013e3181896c35.
5. Eggebeen AT. Gout: an update. *Am Fam Physician*. 2007;76(6):801-808.
6. Burns C, Wortmann RL. Gout. In: Imboden JB, Hellmann DB, Stone JH, eds. *CURRENT Diagnosis & Treatment: Rheumatology*. 3rd edition. New York: McGraw-Hill; 2013:332-338.
7. Jacobson JA, Roberts CC, Bencardino JT, et al. Expert Panel on Musculoskeletal Imaging. ACR Appropriateness Criteria® Chronic extremity joint pain-suspected inflammatory arthritis. *Am Coll Radiol (ACR)*; 2017;14(5):S81-S89. [http://www.jacr.org/article/S1546-1440\(17\)30183-7/fulltext](http://www.jacr.org/article/S1546-1440(17)30183-7/fulltext).

Infection/Osteomyelitis (MS-9)

Guideline

Infection – General (MS-9.1)

Septic Joint (MS-9.2)

References (MS-9)

Infection – General (MS-9.1)

MS.OI.0009.1.A

v1.0.2024

- MRI without contrast, MRI without and with contrast, CT without contrast, CT with contrast, or Ultrasound (CPT® 76881 or 76882) of the affected area is appropriate after plain x-ray(s) in the following scenarios:
 - Plain x-ray(s) do not demonstrate infection, **AND**
 - Plain x-ray(s) do not suggest alternative diagnoses such as neuropathic arthropathy or fracture, **AND**
 - Soft tissue or bone infection (osteomyelitis) is suspected **OR**
 - Plain x-ray(s) are positive for infection, **AND**
 - The extent of infection into the soft tissues and any skip lesions require evaluation
- Individuals with suspected spinal infections
 - See: **Red Flag Indications (SP-1.2)** for advanced imaging guidelines
- Individuals with diabetic foot infections after plain x-ray(s)
 - See: **Foot (MS-27)** for advanced imaging guidelines
- For nuclear medicine studies appropriate in specific scenarios, see: **Nuclear Medicine (MS-28)**

Septic Joint (MS-9.2)

MS.OI.0009.2.A

v1.0.2024

- MRI without and with contrast, MRI without contrast, CT without contrast, CT with contrast, or Ultrasound (CPT® 76881 or CPT® 76882) of the affected joint is appropriate when standard or image-guided arthrocentesis is contraindicated, unsuccessful, or non-diagnostic, and the clinical documentation satisfies ALL of the following criteria:
 - History and physical examination findings [One of the following]:
 - Development of an acutely hot and swollen joint (< 2 weeks)
 - Decreased range of motion due to pain
 - Documented fever
 - Laboratory tests [One of the following]:
 - Leukocytosis
 - Elevated ESR or C-reactive protein
 - Analysis of the joint fluid is non-diagnostic
 - Plain x-ray of the joint
 - Results of plain x-rays performed after the current episode of symptoms started or changed need to be available to the requesting provider
- MRI without and with contrast, MRI without contrast, CT without contrast, or CT with contrast of the affected joint is appropriate after plain x-rays if the arthrocentesis is diagnostic and if there is a confirmed septic joint, to evaluate the extent of infection into the soft tissues and any skip lesions that would require evaluation.
 - Results of plain x-rays performed after the current episode of symptoms started or changed need to be available to the requesting provider

Background and Supporting Information

- Analysis of joint fluid is most often sufficient to diagnose a septic joint.

References (MS-9)

v1.0.2024

1. Coakley G, Mathews C, Field M, et al. BSR & BHPR, BOA, RCGP and BSAC guidelines for management of the hot swollen joints in adults. *Rheumatology*. 2006;45(8):1039-1041. doi:10.1093/rheumatology/kel163a.
2. Karchevsky M, Schweitzer ME, Morrison WB, et al. MRI findings of septic arthritis and associated osteomyelitis in adults. (*AJR Am J Roentgenol*. 2004;182(1):119-122. doi:10.2214/ajr.182.1.1820119.
3. Griffin LY. *Essentials of Musculoskeletal Care*. 3rd edition. Rosemont, IL: American Academy of Orthopaedic Surgeons; 2005:918.
4. Staheli LT. Septic arthritis. In: Staheli LT, ed. *Fundamentals of Pediatric Orthopedics*. 4th edition. Philadelphia, PA: Lippincott Williams & Wilkins; 2008:110-111.
5. Kransdorf MJ, Weissman BN, Appel M, et al. Expert Panel on Musculoskeletal Imaging. ACR Appropriateness Criteria® Suspected osteomyelitis of the foot in patients with diabetes mellitus. *Am Coll Radiol (ACR)*. 2012. <https://acsearch.acr.org/docs/69340/Narrative/>.
6. Beaman FD, von Herrmann PF, Kransdorf MJ, et al. Expert Panel on Musculoskeletal Imaging. ACR Appropriateness Criteria® Suspected osteomyelitis, septic arthritis, or soft tissue infection (excluding spine and diabetic foot). *Am Coll Radiol (ACR)*; Date of Origin: 2016. Revised: 2022. <https://acsearch.acr.org/docs/3094201/Narrative/>.
7. Rubin DA, Roberts CC, Bencardino JT, et al. Expert Panel on Musculoskeletal Imaging. ACR Appropriateness Criteria® Chronic wrist pain. *Am Coll Radiol (ACR)*; Revised: 2017. <https://acsearch.acr.org/docs/69427/Narrative/>.
8. Small KM, Adler RS, Shah SH, et al. Expert Panel on Musculoskeletal Imaging. ACR Appropriateness Criteria® Shoulder Pain - Atraumatic. *Am Coll Radiol (ACR)*; New 2018. <https://acsearch.acr.org/docs/3101482/Narrative/>.
9. Amini B, Beckmann NM, Beaman FD, et al. Expert Panel on Musculoskeletal Imaging. ACR Appropriateness Criteria® Shoulder Pain - Traumatic. *Am Coll Radiol (ACR)*; Revised 2017. <https://acsearch.acr.org/docs/69433/Narrative/>.
10. Mintz DN, Roberts CC, Bencardino JT, et al. Expert Panel on Musculoskeletal Imaging. ACR Appropriateness Criteria® Chronic hip pain. *Am Coll Radiol (ACR)*; Revised: 2016. <https://acsearch.acr.org/docs/69425/Narrative/>.
11. Reinus WR. *Clinician's Guide to Diagnostic Imaging*. 2014. Springer-Verlag New York.
12. Visconti AJ, Biddle J, Solomon M. Follow-up imaging for vertebral osteomyelitis a teachable moment. *JAMA Intern Med*. 2014;174(2):184. doi:10.1001/jamainternmed.2013.12742.
13. Fabiano V, Franchino G, Napolitano M, et al. Utility of magnetic resonance imaging in the follow-up of children affected by acute osteomyelitis. *Curr Pediatr Res*. 2017;21(2):354-358.
14. Patel ND, Broderick DF, Burns J, et al. Expert Panel on Neurologic Imaging. ACR Appropriateness Criteria®: Low back pain. *Am Coll Radiol (ACR)*. 2015; Revised: 2021. <https://acsearch.acr.org/docs/69483/Narrative/>.

Soft Tissue Mass or Lesion of Bone (MS-10)

Guideline

Soft Tissue Mass (MS-10.1)

Lesion of Bone (MS-10.2)

References (MS-10)

Soft Tissue Mass (MS-10.1)

MS.ST.0010.1.A

v1.0.2024

- History and physical exam should include documentation of: location, size, duration, growing or stable, solid/cystic, fixed/not fixed to the bone, discrete or ill-defined, and an association with pain.
- Plain x-ray is indicated as the initial imaging study, with the exception of individuals with cancer predisposition syndrome.
 - Results of plain x-rays performed after the current episode of symptoms started or changed need to be available to the requesting provider
- MRI without and with contrast or without contrast or US of the area of interest (CPT® 76881 or 76882) is appropriate when ANY of the following are met after plain x-ray:
 - Soft tissue mass(es)
 - Surgical planning
- Known or suspected soft tissue mass in an individual with a cancer predisposition syndrome, see **Screening Imaging in Cancer Predisposition Syndromes (PEDONC-2)** in the Pediatric and Special Populations Oncology Imaging Guidelines.
- CT with contrast or CT without and with contrast is appropriate when MRI is contraindicated or after a metal limiting MRI evaluation.
- Advanced imaging is not indicated for:
 - Subcutaneous lipoma with no surgery planned
 - Ganglia, see: **Ganglion Cysts (MS-7)**
 - Sebaceous cyst

Background and Supporting Information

- Plain x-rays can determine if an advanced imaging procedure is indicated, and if so, which modality is most appropriate. If non-diagnostic, these initial plain x-rays can provide complementary information if advanced imaging is indicated.

Lesion of Bone (MS-10.2)

MS.ST.0010.2.A

v1.0.2024

- History and physical exam should include documentation of: location, size, duration, growing or stable, discrete or poorly defined, and an association with pain.
- Complete radiograph of the entire bone containing the lesion of bone is required prior to consideration of advanced imaging. Many benign bone tumors have a characteristic appearance on plain x-ray and advanced imaging is not necessary.
- MRI without and with contrast, MRI without contrast, or CT without contrast may be indicated if ONE of the following applies:
 - Diagnosis uncertain based on plain x-ray appearance
 - Imaging requested for preoperative planning
- MRI without and with contrast or without contrast is appropriate when plain x-ray reveals an osteochondroma with clinical concern of malignant transformation.
- For Paget's Disease:
 - Bone scan (See: **Nuclear Medicine (MS-28)**) OR
 - MRI (contrast as requested) can be considered if the diagnosis (based on plain x-rays and laboratory studies) is in doubt.
 - MRI (contrast as requested) can be considered if malignant degeneration, which occurs in up to 10% of cases, is suspected.

References (MS-10)

v1.0.2024

1. Peterson JJ, Beaman FD, Fox MG, et al. ACR Practice Guideline. ACR-SSR Practice Guideline for the Performance and Interpretation of Magnetic Resonance Imaging (MRI) of bone and soft tissue tumors. *Am Coll Radiol*. Revised 2020. <https://www.acr.org/-/media/ACR/Files/Practice-Parameters/MR-SoftTissue-Tumors.pdf>.
2. Zoga AC, Weissman BN, Kransdorf MJ, et. al. Expert Panel on Musculoskeletal Imaging. ACR Appropriateness Criteria® Soft-tissue masses. *Am Coll Radiol (ACR)*; Revised 2017. <https://acsearch.acr.org/docs/69434/Narrative/>.
3. Hayes CW, Roberts CC, Bencardino JT, et. al. Expert Panel on Musculoskeletal Imaging. ACR Appropriateness Criteria® chronic elbow pain. *Am Coll Radiol (ACR)*; Revised 2022. <https://acsearch.acr.org/docs/69423/Narrative/>.
4. Musculoskeletal Tumor Society: Systematic Literature Review on the Use of Imaging Prior to Referral to a Musculoskeletal Oncologist. Rosemont, IL, Musculoskeletal Tumor Society, February 2018.
5. Schneider D, Hofmann MR, and Peterson JA. Diagnosis and treatment of Paget's Disease of Bone. *Am Fam Physician*. 2002;65(10):2069-2072. <https://www.aafp.org/afp/2002/0515/p2069.html>.
6. Theodorou DJ, Theodorou SJ, and Kakitsubata Y. Imaging of Paget Disease of bone and its musculoskeletal complications: review. (*AJR*) *Am J Roentgenol*. 2012;196(6):S64-S75.
7. Sinha S and Peach AH. Diagnosis and management of soft tissue sarcoma. *BMJ*. 2010;341:c7170. doi:10.1136/bmj.c7170.
8. Wu JS, Hochman MG. Soft-tissue tumors and tumorlike lesions: a systematic imaging approach. *Radiology*. 2009;253(2):297-316. doi:10.1148/radiol.2532081199.

Muscle/Tendon Unit Injuries/Diseases (MS-11)

Guideline

Muscle/Tendon Unit Injuries/Diseases (MS-11.1)

Acute Compartment Syndrome (MS-11.2)

Chronic Exertional Compartment Syndrome (MS-11.3)

References (MS-11)

Muscle/Tendon Unit Injuries/Diseases (MS-11.1)

MS.MI.0011.1.A

v1.0.2024

- Plain x-ray is the initial imaging study for muscle/tendon unit injuries.
 - Results of plain x-rays performed after the current episode of symptoms started or changed need to be available to the requesting provider
- MRI without contrast or US (CPT® 76881 or CPT® 76882) is supported for **EITHER** of the following:
 - Suspected partial tendon rupture of a specific (named) tendon
 - Complete tendon rupture of a specific named tendon for preoperative planning
- MRI is not medically necessary for muscle belly strains/muscle tears
- See: **Shoulder (MS-19)** for clinical suspicion of a partial or complete rotator cuff tear
- See: **Inflammatory Muscle Diseases (PN-6.2)** in the Peripheral Nerve Disorders Imaging Guidelines and **Inflammatory Muscle Diseases (PEDMS-10.3)** in the Pediatric Musculoskeletal Imaging Guidelines

Acute Compartment Syndrome (MS-11.2)

MS.MI.0011.2.A

v1.0.2024

- Advanced imaging is not indicated. Diagnosis is made clinically and by direct measurement of compartment pressure and is a surgical emergency.

Background and Supporting Information

- Noninvasive methods of measuring compartment pressures and diagnosing acute compartment syndrome are under study, but are currently experimental, investigational, and unproven.

Chronic Exertional Compartment Syndrome (MS-11.3)

MS.MI.0011.3.A

v1.0.2024

- Advanced imaging should only be considered when ruling out other potential causes of extremity pain following a plain x-ray and conservative treatment as indicated.
 - Results of plain x-rays performed after the current episode of symptoms started or changed need to be available to the requesting provider

Background and Supporting Information

- Direct measurement of compartment pressure remains the diagnostic standard. Noninvasive methods of measuring compartment pressures and diagnosing chronic exertional compartment syndrome are under study, but are currently experimental, investigational, and unproven.

References (MS-11)

v1.0.2024

1. Luchs JS, Flug JA, Weissman BN, et al. Expert Panel on Musculoskeletal Imaging. ACR Appropriateness Criteria® chronic ankle pain. *Am Coll Radiol (ACR)*; Date of Origin: 1998. Revised: 2017. <https://acsearch.acr.org/docs/69422/Narrative/>.
2. Griffin LY. *Essentials of Musculoskeletal Care*. 3rd edition. Rosemont, IL: American Academy of Orthopaedic Surgeons; 2005:452.
3. Kayser R, Mahlfeld K, Heyde CE. Partial rupture of the proximal Achilles tendon: a differential diagnostic problem in ultrasound imaging. *Br J Sports Med*. 2005;39:838-842. doi:10.1136/bjism.2005.018416.
4. Rominger MB, Lukosch CJ, Bachmann GF. MR imaging of compartment syndrome of the lower leg: a case control study. *Eur Radiol*. 2004;14:1432-1439. doi:10.1007/s00330-004-2305-5.
5. McDonald S, Bearcroft P. Compartment syndromes. *Semin Musculoskelet Radiol*. 2010;14(2):236-244. doi:10.1055/s-0030-1253164.
6. Ringler MD, Litwiller DV, Felmlee JP, et al. MRI accurately detects chronic exertional compartment syndrome: a validation study. *Skeletal Radiology*. 2013;42:385-392. doi:10.1007/s00256-012-1487-1.
7. van den Brand JG, Nelson T, Verleisdonk EJ, van der Werken C. The diagnostic value of intracompartmental pressure measurement, magnetic resonance imaging, and near-infrared spectroscopy in chronic exertional compartment syndrome: a prospective study in 50 patients. *Am J Sports Med*. 2005;33:699-704. doi:10.1177/0363546504270565.
8. Heer ST, Callander JW, Kraeutler MJ, Mei-Dan O, Mulcahey MK. Hamstring Injuries. *The Journal of Bone and Joint Surgery*. 2019;101(9):843-853. doi:10.2106/jbjs.18.00261.

Osteoarthritis (MS-12)

Guideline

Osteoarthritis (MS-12.1)

Treatment Planning (Non-Surgical and Surgical, Other Than Joint Replacement) (MS-12.2)

Imaging Prior to Non-Customized-to-Patient Joint Replacement Surgery/Not for Intraoperative Navigation (MS-12.3)

Customized-to-Patient Joint Replacement Surgery/Intraoperative Navigation (MS-12.4)

References (MS-12)

Osteoarthritis (MS-12.1)

MS.OT.0012.1.A

v1.0.2024

- Plain x-ray is the initial imaging study for osteoarthritis.
 - Results of plain x-rays performed after the current episode of symptoms started or changed need to be available to the requesting provider

Background and Supporting Information

- Plain x-rays are performed initially and will reveal characteristic joint space narrowing, osteophyte formation, cyst formation, and subchondral sclerosis.

Treatment Planning (Non-Surgical and Surgical, Other Than Joint Replacement) (MS-12.2)

MS.OT.0012.2.A

v1.0.2024

- Results of plain x-rays performed after the current episode of symptoms started or changed need to be available to the requesting provider, unless otherwise specified below.
- CT without contrast is appropriate when ALL of the following apply:
 - Requested for treatment planning, AND
 - Congenital or significant atypical post-traumatic arthritic deformities are identified on plain x-ray, AND
 - The aforementioned deformities require further evaluation of their clinical significance, AND
 - The request is related to the shoulder, elbow, wrist, hip, knee, or ankle
- MRI Knee without contrast (CPT® 73721) is appropriate in an individual with osteoarthritis for clinical suspicion of a symptomatic degenerative meniscus tear following plain x-rays and conservative treatment. See: **Knee (MS-25)**
- MRI arthrogram or CT arthrogram is appropriate when joint sparing/salvage reconstructive surgery is planned for the following:
 - Suspected concomitant rotator cuff tear of the shoulder - See: **Shoulder (MS-19)**
 - Suspected concomitant labral tear of the shoulder - See: **Shoulder (MS-19)**
 - Suspected concomitant labral tear of the hip - See: **Hip (MS-24)**
 - Suspected concomitant internal derangement of the knee - See: **Knee (MS-25)**

Imaging Prior to Non-Customized-to-Patient Joint Replacement Surgery/Not for Intraoperative Navigation (MS-12.3)

MS.OT.0012.3.A

v1.0.2024

- The following imaging studies are appropriate per the listed criteria after plain x-ray has been performed
 - Results of plain x-rays performed after the current episode of symptoms started or changed need to be available to the requesting provider
 - CT without contrast is appropriate when ALL of the following apply:
 - Requested for treatment planning, **AND**
 - Congenital or significant atypical post-traumatic arthritic deformities are identified on plain x-ray, **AND**
 - The aforementioned deformities require further evaluation of their clinical significance, **AND**
 - The request is related to the shoulder, elbow, wrist, hip, knee, or ankle
 - CT Shoulder without contrast (CPT® 73200) and/or MRI Shoulder without contrast (CPT® 73221) are appropriate for preoperative planning prior to shoulder replacement
 - For the clinical imaging criteria regarding preoperative joint replacement surgery for each anatomic area, refer to the anatomic area tables:
 - **Shoulder (MS-19)**
 - **Elbow (MS-20)**
 - **Wrist (MS-21)**
 - **Hip (MS-24)**
 - **Knee (MS-25)**
 - **Ankle (MS-26)**

Customized-to-Patient Joint Replacement Surgery/Intraoperative Navigation (MS-12.4)

MS.OT.0012.4.U

v1.0.2024

- The following imaging studies are appropriate per the listed criteria after plain x-ray has been performed.
 - Results of plain x-rays performed after the current episode of symptoms started or changed need to be available to the requesting provider
- CT without contrast or MRI without contrast of the shoulder, elbow, wrist, hip, knee, or ankle is appropriate* when the request is for:
 - Treatment planning for customized-to-patient joint replacement surgery, OR
 - Surgical planning using intraoperative navigation for joint replacement surgery (e.g. MAKOplasty) AND
 - The joint replacement surgery has been approved or does not require prior authorization
- *The preoperative imaging listed above is considered **not medically necessary** if any of the following are deemed not medically necessary, not a covered benefit, or experimental, investigational, or unproven by the health plan:
 - Joint replacement surgery
 - Customized-to-patient implant
 - Computer assisted surgical navigation (e.g. MAKOplasty)
- See: **Unlisted Procedures/Therapy Treatment Planning (Preface-4.3)** in the Preface Imaging Guidelines

References (MS-12)

v1.0.2024

1. Mintz DN, Roberts CC, Bencardino JT, et al. Expert Panel on Musculoskeletal Imaging. ACR Appropriateness Criteria® Chronic Hip Pain. *Am Coll Radiol (ACR)*; Revised: 2016. <https://acsearch.acr.org/docs/69425/Narrative/>.
2. Bennett DL, Nelson JW, Weissman BN, et. al. Expert Panel on Musculoskeletal Imaging. ACR Appropriateness Criteria® Nontraumatic Knee Pain. *Am Coll Radiol (ACR)*; Date of Origin: 1995. Last Review: 2018. <https://acsearch.acr.org/docs/69432/Narrative/>.
3. Manek NJ, Lane NE. Osteoarthritis: Current concepts in diagnosis and management. *Am Fam Physician* 2000 March;61(6):1795-1804. <https://www.aafp.org/afp/2000/0315/p1795.html>.
4. Griffin LY. *Essentials of Musculoskeletal Care*. 3rd edition. Rosemont, IL: American Academy of Orthopaedic Surgeons; 2005:84.
5. Quatman CE, Hettrich CM, Schmitt LC, et. al. The Clinical Utility and Diagnostic Performance of MRI for Identification of Early and Advanced Knee Osteoarthritis: A Systematic Review. *Am J Sports Med*. 2011;39(7):1557–1568. doi:10.1177/0363546511407612.
6. Braun HJ, Gold GE. Diagnosis of osteoarthritis: imaging. *Bone*. 2012;51(2):278–288. doi:10.1016/j.bone.2011.11.019.

Chondral/Osteochondral Lesions (MS-13)

Guideline

Chondral/Osteochondral Lesions, Including Osteochondritis Dissecans and Fractures (MS-13.1)

References (MS-13)

Chondral/Osteochondral Lesions, Including Osteochondritis Dissecans and Fractures (MS-13.1)

MS.OD.0013.1.A

v1.0.2024

- MRI without contrast, MRI with contrast (arthrogram), or CT with contrast (arthrogram) of the joint or area of interest is indicated when **EITHER** of the following are met:
 - Plain x-rays are negative and an osteochondral fracture is still suspected
 - Plain x-ray and clinical exam suggest an unstable osteochondral injury
- If plain x-rays show a non-displaced osteochondral fragment, follow-up imaging should be with plain x-rays. Advanced imaging is not necessary.
- MRI without contrast or CT without contrast is indicated when healing (including post-operative fixation) cannot be adequately assessed on follow-up plain x-rays.
- See anatomical table sections for recommendations on anatomy-specific osteochondral injuries
 - See: **Ankle (MS-26)** for suspected osteochondral injury of the ankle
 - See: **Elbow (MS-20)** for suspected osteochondral injury of the elbow

References (MS-13)

v1.0.2024

1. Bridges MD, Berland LL, Cernigliaro JG, et al. ACR Practice Guideline. ACR-SSR Practice Guideline for the Performance and Interpretation of Magnetic Resonance Imaging (MRI). *Am Coll Radiol (ACR)*. 2017. <https://www.acr.org/-/media/ACR/Files/Practice-Parameters/mr-perf-interpret.pdf?la=en>.
2. Bennett DL, Nelson JW, Weissman BN, et al. Expert Panel on Musculoskeletal Imaging. ACR Appropriateness Criteria® Nontraumatic Knee Pain. *Am Coll Radiol (ACR)*; 2012. Last Review: 2018. <https://acsearch.acr.org/docs/69432/Narrative/>.
3. Rubin DA, Anderson MW, Hastreiter DM, et al. ACR Practice Guideline. ACR-SSR Practice Guideline for the Performance and Interpretation of Magnetic Resonance Imaging (MRI) of the elbow. *Am Coll Radiol (ACR)*. Revised 2021. <https://www.acr.org/-/media/ACR/Files/Practice-Parameters/mr-elbow.pdf?la=en>.

Osteoporosis (MS-14)

Guideline

Osteoporosis (MS-14)

References (MS-14)

Osteoporosis (MS-14)

MS.OP.0014.A

v1.0.2024

- Plain x-ray is not required.
- Quantitative CT (CPT® 77078) can be approved for screening when DXA scanner is unavailable or known to be inaccurate for ANY of the following populations:
 - Women age ≥65 years
 - Men age >70 years
 - Women age <65 years who have additional risk factors for osteoporosis based on medical history and other findings:
 - Estrogen deficiency
 - A history of maternal hip fracture that occurred after age 50 years
 - Low body mass (<127 lb. or 57.6 kg)
 - History of amenorrhea (>1 year before age 42 years)
 - Women age <65 years or men age <70 years who have additional risk factors:
 - Current use of cigarettes
 - Loss of height, thoracic kyphosis
 - Individuals of any age with bone mass osteopenia or fragility fractures on imaging studies such as radiographs, CT, or MRI
 - Individuals age 50 years and older who develop a wrist, hip, spine, or proximal humerus fracture with minimal or no trauma, excluding pathologic fractures
 - Individuals of any age who develop 1 or more insufficiency fractures
 - Premenopausal females or males age 20 to 50 years with risk factors:
 - Individuals with medical conditions that could alter bone mineral density
 - Chronic renal failure
 - Rheumatoid arthritis and other inflammatory arthritides
 - Eating disorders, including anorexia nervosa and bulimia
 - Organ transplantation
 - Prolonged immobilization
 - Conditions associated with secondary osteoporosis, such as gastrointestinal malabsorption or malnutrition, sprue, osteomalacia, vitamin D deficiency, endometriosis, acromegaly, chronic alcoholism or established cirrhosis, and multiple myeloma
 - Individuals who have had gastric bypass for obesity
 - Individuals with an endocrine disorder known to adversely affect bone mineral density (e.g., hyperparathyroidism, hyperthyroidism, or Cushing syndrome)
 - Individuals receiving (or expected to receive) glucocorticoid therapy for >3 months
 - Hypogonadal men older than 18 years and men with surgically or chemotherapeutically-induced castration

- Individuals beginning or receiving long-term therapy with medications known to adversely affect BMD (e.g., anti-convulsant drugs, androgen deprivation therapy, aromatase inhibitor therapy, or chronic heparin)

Note: Repeat screening quantitative computed tomography (QCT) can be approved no sooner than every two years.

- Quantitative CT scan (CPT® 77078) can be approved for non-screening/monitoring when DXA scanner is unavailable or known to be inaccurate for ANY of the following circumstances:
 - Follow-up in cases where QCT was the original study
 - Multiple healed vertebral compression fractures
 - Significant scoliosis
 - Advanced arthritis of the spine due to increased cortical sclerosis often with large marginal osteophytes. Obese individual over the weight limit of the dual-energy x-ray absorptiometry (DXA) exam table
 - Severely obese individuals (BMI >35kg/m²)
 - Extremes in body height (i.e. very large and very small individuals)
 - Individuals with extensive degenerative disease of the spine
 - A clinical scenario that requires sensitivity to small changes in trabecular bone density (parathyroid hormone and glucocorticoid treatment monitoring).

Note: Repeat non-screening/monitoring QCT can be approved no earlier than one year following a change in treatment regimen, and only when the results will directly impact a treatment decision.

References (MS-14)

v1.0.2024

1. American Association of Clinical Endocrinologists (AACE) Menopause Guidelines Revision Task Force. American Association of Clinical Endocrinologists medical guidelines for clinical practice for the diagnosis and treatment of postmenopausal osteoporosis. *Endocr Pract.* 2016;22(Suppl 4):1-42. <https://www.aace.com/files/postmenopausal-guidelines.pdf>.
2. Coleman F, de Buer SJ, LeBoff MS, et al. National Osteoporosis Foundation (NOF). Clinician's guide to prevention and treatment of osteoporosis. *Osteoporos Int.* 2014;25(10):2359–2381. doi:10.1007/s00198-014-2794-2.
3. U.S. Preventive Services Task Force (USPSTF). Final Recommendation Statement Osteoporosis: Screening. January 2011.
4. Ward RJ, Roberts CC, Bencardino JT, et. al. Expert Panel on Musculoskeletal Imaging. ACR Appropriateness Criteria® Osteoporosis and Bone Mineral Density. *Am Coll Radiol (ACR)*; Revised 2022. <https://acsearch.acr.org/docs/69358/Narrative/>.

Rheumatoid Arthritis (RA) and Inflammatory Arthritis (MS-15)

Guideline

Rheumatoid Arthritis (RA) and Inflammatory Arthritis (MS-15.1)

Pigmented Villonodular Synovitis (PVNS) (MS-15.2)

References (MS-15)

Rheumatoid Arthritis (RA) and Inflammatory Arthritis (MS-15.1)

MS.RA.0015.1.A

v1.0.2024

- Plain x-ray, physical exam and appropriate laboratory studies* are required prior to advanced imaging.
 - Results of plain x-rays performed after the current episode of symptoms started or changed need to be available to the requesting provider
- MRI without contrast OR MRI without and with contrast or US (CPT® 76881 or CPT® 76882) is appropriate for the most symptomatic joint, or of the dominant hand or wrist, in **ALL** of the following situations:
 - When diagnosis is uncertain prior to initiation of drug therapy.
 - To study the effects of treatment with disease modifying anti-rheumatic drug (DMARD) therapy.
 - To identify seronegative RA individuals that might benefit from early DMARD therapy.
 - To determine change in treatment, such as:
 - Switching from standard DMARD therapy to tumor necrosis factor (TNF) therapy.
 - Changing to a different TNF drug therapy, then one MRI (contrast as requested) of a single joint can be performed.
 - Addition of other treatments, including joint injections
- MRI or US should NOT be considered for routine follow-up of treatment.

Background and Supporting Information

- * Examples of appropriate laboratory studies may include: Lyme titers, rheumatoid factor (RF), anti-cyclic citrullinated peptide (anti-CCP), sedimentation rate (ESR), C-reactive protein (CRP), and antinuclear antibody (ANA), joint fluid analysis

Pigmented Villonodular Synovitis (PVNS) (MS-15.2)

MS.RA.0015.2.A

v1.0.2024

- MRI of the affected joint without contrast or CT of the affected joint with contrast (arthrogram) if MRI contraindicated is supported following plain x-rays.
 - Results of plain x-rays performed after the current episode of symptoms started or changed need to be available to the requesting provider

References (MS-15)

v1.0.2024

1. Rubin DA, Roberts CC, Bencardino JT, et. al. Expert Panel on Musculoskeletal Imaging. ACR Appropriateness Criteria® Chronic Wrist Pain. *Am Coll Radiol (ACR)*; Revised: 2017. <https://acsearch.acr.org/docs/69427/Narrative/>.
2. Luchs JS, Flug JA, Weissman BN, et. al. Expert Panel on Musculoskeletal Imaging. ACR Appropriateness Criteria® Chronic Ankle Pain. *Am Coll Radiol (ACR)*; Date of Origin: 1998. Revised: 2017. <https://acsearch.acr.org/docs/69422/Narrative/>.
3. Hayes CW, Roberts CC, Bencardino JT, et. al. Expert Panel on Musculoskeletal Imaging. ACR Appropriateness Criteria® Chronic Elbow Pain. *Am Coll Radiol (ACR)*; Date of Origin: 1998. Revised: 2022. <https://acsearch.acr.org/docs/69423/Narrative/>.
4. Jacobson JA, Roberts CC, Bencardino JT, et. al. Expert Panel on Musculoskeletal Imaging. ACR Appropriateness Criteria® Chronic Extremity Joint Pain-Suspected Inflammatory Arthritis. *Am Coll Radiol (ACR)*; New: 2016. <https://acsearch.acr.org/docs/3097211/Narrative/>.
5. Wise JN, Weissman BN, Appel M, et. al. Expert Panel on Musculoskeletal Imaging. ACR Appropriateness Criteria® Chronic Foot Pain. *Am Coll Radiol (ACR)*; Date of Origin: 1998. Revised: 2020. <https://acsearch.acr.org/docs/69424/Narrative/>.
6. Mintz DN, Roberts CC, Bencardino JT, et. al. Expert Panel on Musculoskeletal Imaging. ACR Appropriateness Criteria® Chronic Hip Pain. *Am Coll Radiol (ACR)*; Revised: 2016. <https://acsearch.acr.org/docs/69425/Narrative/>.
7. Boutry N, Morel M, Flipo RM, et al. Early rheumatoid arthritis: a review of MRI and sonographic findings. *AJR Am J Roentgenol*. 2007;189:1502-1509. doi:10.2214/AJR.07.2548.
8. Murphey MD, Rhee JH, Lewis RB, et al. Pigmented villonodular synovitis: radiologic-pathologic correlation. *Radiographics*. 2008;28:1493-1518. doi:10.1148/rg.285085134.
9. Conaghan P, Edmonds J, Emery P, et al. Magnetic resonance imaging in rheumatoid arthritis: summary of OMERACT activities, current status, and plans. *Journal of Rheumatology*. 2001;28(5):1158-1161. <http://www.jrheum.org/content/28/5/1158.long>.
10. Ostergaard M, McQueen FM, Bird P, et al. Magnetic resonance imaging in rheumatoid arthritis--advances and research priorities. *Journal of Rheumatology*. 2005;32(12):2462-2464. <http://www.jrheum.org/content/32/12/2462.long>.
11. Mcqueen FM. The use of MRI in early RA. *Rheumatology*. 2008;47(11):1597-1599. doi:10.1093/rheumatology/ken332.
12. Gossec L, Fautrel B, Pham T, et al. Structural evaluation in the management of patients with rheumatoid arthritis: development of recommendations for clinical practice based on published evidence and expert opinion. *Joint Bone Spine*. 2005;72(3):229-234. doi:10.1016/j.jbspin.2004.10.011.
13. Cohen SB, Potter H, Deodhar A, et al. Extremity magnetic resonance imaging in rheumatoid arthritis: updated literature review. *Arthritis Care & Research*. 2011;63(5):660-665. doi:10.1002/acr.20413.
14. Singh JA, Furst DE, Bharat A, et al. 2012 update of the 2008 American College of Rheumatology recommendations for the use of disease-modifying antirheumatic drugs and biologic agents in the treatment of rheumatoid arthritis. *Arthritis Care & Research*. 2012;64(5):625-639. doi:10.1002/acr.21641.
15. Saag KG, Teng GG, Patkar NM, et al. American College of Rheumatology 2008 recommendations for the use of nonbiologic and biologic disease-modifying antirheumatic drugs in rheumatoid arthritis. *Arthritis & Rheumatism (Arthritis Care & Research)*. 2008;59:762-784. doi:10.1002/art.23721.

Post-Operative Joint Replacement Surgery (MS-16)

Guideline

Post-Operative Joint Replacement Surgery – General (MS-16.1)
References (MS-16)

Post-Operative Joint Replacement Surgery – General (MS-16.1)

MS.PS.0016.1.A

v1.0.2024

- CT without contrast, MRI without contrast, or nuclear medicine studies (see: **MS-28** for nuclear medicine studies) with **ALL** of the following:
 - Recent plain x-ray is nondiagnostic
 - Suspected aseptic loosening of orthopaedic joint replacements
 - CT shoulder without contrast (CPT® 73200) can be performed as additional imaging following plain x-rays regardless of plain x-ray findings. See: **Shoulder (MS-19)**
 - Results of plain x-rays performed after the current episode of symptoms started or changed need to be available to the requesting provider
- CT without contrast or MRI without contrast with **ALL** of the following:
 - Negative plain x-ray
 - High suspicion for a periprosthetic fracture
 - CT Shoulder without contrast (CPT® 73200) can be performed as additional imaging following plain x-rays regardless of plain x-ray findings. See: **Shoulder (MS-19)**
 - Results of plain x-rays performed after the current episode of symptoms started or changed need to be available to the requesting provider
- Joint aspiration is the initial evaluation after plain x-ray for a painful joint replacement when periprosthetic infection is suspected.
 - Results of plain x-rays performed after the current episode of symptoms started or changed need to be available to the requesting provider
 - For suspected infection with negative or inconclusive joint aspiration culture see: **Nuclear Medicine (MS-28)**
- MRI Hip without contrast (CPT® 73721) or Ultrasound (CPT® 76881 or CPT® 76882) are both appropriate for **EITHER** of the following:
 - Diagnosis of ALVAL (aseptic lymphocytic-dominated vasculitis-associated lesion) pseudotumors surrounding metal-on-metal (MoM) hip prostheses. One of these two imaging modalities can be approved but not both. See: **Soft Tissue Mass or Lesion of Bone (MS-10)**
 - Metal-On-Metal (MoM) Hip Prostheses that are considered high risk for implant performance issues from THA (Total hip arthroplasty) cup-neck impingement and subsequent ALTR (adverse local tissue reaction) with Co and Cr ion levels greater than 10 ppb.
- CT Hip without contrast (CPT® 73700) **OR** MRI Hip without contrast (CPT® 73721):
 - Evaluate suspected particle disease (aggressive granulomatous disease) of the hip when infection has been excluded.

- For specific joints post-operative from replacement surgery:
 - See: **Shoulder (MS-19)**
 - See: **Elbow (MS-20)**
 - See: **Hip (MS-24)**
 - See: **Knee (MS-25)**
 - See: **Ankle (MS-26)**

Background and Supporting Information

- Complications following joint replacement surgery include (not limited to) periprosthetic fracture, infection, aseptic loosening, failure of fixation/component malposition, and wear.

References (MS-16)

v1.0.2024

1. Mintz DN, Roberts CC, Bencardino JT, et al. Expert Panel on Musculoskeletal Imaging. ACR Appropriateness Criteria® Chronic Hip Pain. *Am Coll Radiol (ACR)*; Revised: 2016. <https://acsearch.acr.org/docs/69425/Narrative/>.
2. Hochman MG, Melenevsky YV, Metter DF, et al. Expert Panel on Musculoskeletal Imaging. ACR Appropriateness Criteria® Imaging After Total Knee Arthroplasty. *Am Coll Radiol (ACR)*; Revised: 2017. <https://acsearch.acr.org/docs/69430/Narrative/>.
3. Gyftopoulos S, Rosenberg ZS, Roberts CC, et al. Expert Panel on Musculoskeletal Imaging. ACR Appropriateness Criteria® Imaging After Shoulder Arthroplasty. *Am Coll Radiol (ACR)*; Date of Origin: 2016. Revised: 2021. <https://acsearch.acr.org/docs/3097049/Narrative/>.
4. Weissman BN, Palestro CJ, Fox MG, et al. Expert Panel on Musculoskeletal Imaging. ACR Appropriateness Criteria® Imaging After Total Hip Arthroplasty. *Am Coll Radiol (ACR)*; Revised: 2023. Available at: <https://acsearch.acr.org/docs/3094200/Narrative>
5. Toms AD, Davidson D, Masri BA, et al. Management of peri-prosthetic infection in total joint arthroplasty. *J Bone Joint Surg Br*. 2006;88(2):149-155. doi:10.1302/0301-620X.88B2.17058.
6. Love C, Marwin SE, Tomas MB, et al. Diagnosing infection in the failed joint replacement: A comparison of coincidence detection 18F-FDG and 111In-labeled leukocyte/99mTc-sulfur colloid marrow imaging. *J Nucl Med*. 2004;45(11):1864-1871.
7. Nawabi DH, Gold S, Lyman SL, et al. MRI predicts ALVAL and tissue damage in metal-on-metal hip arthroplasty. *Clin Orthop Relat Res*. 2014;472(2):471-481. doi:10.1007/s11999-013-2788-y.
8. Verberne SJ, Raijmakers PG, Temmerman OP. The accuracy of imaging techniques in the assessment of periprosthetic hip infection: a systematic review and meta-analysis. *J Bone Joint Surg Am*. 2016;98(19):1638-45. doi:10.2106/JBJS.15.00898.
9. Fritz J, Meshram P, Stern SE, Fritz B, Srikumaran U, McFarland EG. Diagnostic performance of advanced metal artifact reduction MRI for periprosthetic shoulder infection. *J Bone Joint Surg Am*. 2022;104:1352-1361. doi:10.2106/JBJS.21.00912.

Limb Length Discrepancy (MS-17)

Guideline

Limb Length Discrepancy (MS-17.1)

Reference (MS-17)

Limb Length Discrepancy (MS-17.1)

MS.LL.0017.1.A

v1.0.2024

- Either plain radiographic or “CT scanogram,” both reported with CPT® 77073, is appropriate to radiographically evaluate limb length discrepancy due to congenital anomalies, acquired deformities, growth plate (physeal injuries or surgery), or inborn errors of metabolism.
 - A diagnostic advanced imaging CPT code (e.g., CPT® 73700, CPT® 73701, or CPT® 73702) is not indicated for evaluation of limb length discrepancy.

Reference (MS-17)

v1.0.2024

1. Leitzes A, Potter HG, Amaral T, et al. Reliability and accuracy of MRI scanogram in the evaluation of limb length discrepancy. *J Pediatr Orthop*. 2005;25(6):747-749.

Anatomical Area Tables – General Information (MS-18)

Guideline

Anatomical Area Tables – General Information (MS-18)

Anatomical Area Tables – General Information (MS-18)

MS.AA.0018.A

v1.0.2024

The imaging guidelines for each anatomical area are presented in table format. The table below includes a description of how each column header should be utilized for each guideline **Shoulder (MS-19)** through **Foot (MS-27)**.

After an initial plain x-ray has been obtained, and results are available to the provider, the following advanced imaging is indicated (as described in General Guidelines [MS-1.0])

Condition	Conservative Treatment	Advanced Imaging	Comments
(Individual's condition)	(Is failure of 6 weeks of provider-directed conservative treatment within the past 12 weeks with clinical re-evaluation required?) (Yes or No)	(The appropriate advanced imaging indicated for this condition. In some scenarios, advanced imaging may not be indicated.)	(Additional comments related to the condition.)

Shoulder (MS-19)

Guideline

Shoulder (MS-19)

References (MS-19)

Shoulder (MS-19)

MS.SH.0019.A

v1.0.2024

After an initial plain x-ray has been obtained, and results are available to the provider, the following advanced imaging is indicated (as described in General Guidelines [MS-1.0])

Condition (Individual's Condition)	Conservative Treatment (Is failure of 6 weeks of provider-directed conservative treatment within the past 12 weeks with clinical re-evaluation required?) (Yes or No)	Advanced Imaging (The appropriate advanced imaging indicated for this condition. In some scenarios, advanced imaging may not be indicated.)	Comments (Additional comments related to the condition.)
General Shoulder Pain	Yes	<ul style="list-style-type: none"> MRI Shoulder without contrast (CPT® 73221) OR US Shoulder (CPT® 76881 or CPT® 76882) OR CT Shoulder with contrast (arthrogram) (CPT® 73201) if MRI contraindicated 	
Symptomatic Loose Bodies	No	<ul style="list-style-type: none"> MRI Shoulder without contrast (CPT® 73221) 	
Impingement	Yes	<ul style="list-style-type: none"> MRI Shoulder without contrast (CPT® 73221) OR MRI Shoulder with contrast (arthrogram) (CPT® 73222) OR US Shoulder (CPT® 76881 or CPT® 76882) CT Shoulder with contrast (CPT® 73201) if MRI is contraindicated 	
Tendonitis/ Bursitis	Yes	<ul style="list-style-type: none"> MRI Shoulder without contrast (CPT® 73221) OR US Shoulder (CPT® 76881 or CPT® 76882) 	

After an initial plain x-ray has been obtained, and results are available to the provider, the following advanced imaging is indicated (as described in General Guidelines [MS-1.0])

Condition (Individual's Condition)	Conservative Treatment (Is failure of 6 weeks of provider-directed conservative treatment within the past 12 weeks with clinical re-evaluation required?) (Yes or No)	Advanced Imaging (The appropriate advanced imaging indicated for this condition. In some scenarios, advanced imaging may not be indicated.)	Comments (Additional comments related to the condition.)
Tendon Rupture (Biceps Long Head)	No		<ul style="list-style-type: none"> When clinical exam is inconclusive due to inability to visualize a "Popeye" sign clinically, or for preoperative planning: <ul style="list-style-type: none"> MRI Shoulder without contrast (CPT® 73221) OR US Shoulder (CPT® 76881 or CPT® 76882)
Tendon Rupture (Pectoralis Major/Minor)	No		<ul style="list-style-type: none"> When clinical exam is inconclusive, or for preoperative planning: <ul style="list-style-type: none"> MRI Shoulder without contrast (CPT® 73221) OR MRI Chest without contrast (CPT® 71550) OR US Shoulder (CPT® 76881 or CPT® 76882)

After an initial plain x-ray has been obtained, and results are available to the provider, the following advanced imaging is indicated (as described in General Guidelines [MS-1.0])

Condition (Individual's Condition)	Conservative Treatment (Is failure of 6 weeks of provider-directed conservative treatment within the past 12 weeks with clinical re-evaluation required?) (Yes or No)	Advanced Imaging (The appropriate advanced imaging indicated for this condition. In some scenarios, advanced imaging may not be indicated.)	Comments (Additional comments related to the condition.)
<p>Shoulder Rotator Cuff Tear (Complete and Partial)</p>	<p>Yes*</p>	<ul style="list-style-type: none"> • MRI Shoulder without contrast (CPT® 73221) OR • MRI Shoulder with contrast (arthrogram) (CPT® 73222) OR • US Shoulder (CPT® 76881 or CPT® 76882) OR • CT Shoulder with contrast (arthrogram) (CPT® 73201) if MRI is contraindicated 	<p>*Conservative treatment is not required with an acute shoulder injury prior to the onset of symptoms and consideration of surgery.</p> <p>If surgery is being considered, MRI without contrast, MRI with contrast (arthrogram), or CT arthrogram are required per <u>Shoulder Surgery-Arthroscopic and Open Procedure (CMM-315)</u></p>

After an initial plain x-ray has been obtained, and results are available to the provider, the following advanced imaging is indicated (as described in General Guidelines [MS-1.0])

Condition (Individual's Condition)	Conservative Treatment (Is failure of 6 weeks of provider-directed conservative treatment within the past 12 weeks with clinical re-evaluation required?) (Yes or No)	Advanced Imaging (The appropriate advanced imaging indicated for this condition. In some scenarios, advanced imaging may not be indicated.)	Comments (Additional comments related to the condition.)
Partial Tendon Rupture (Excluding Partial Rotator Cuff Tears)	No	<ul style="list-style-type: none"> • For a suspected partial tendon rupture of a specific named tendon not otherwise specified: <ul style="list-style-type: none"> • MRI Shoulder without contrast (CPT® 73221) OR • US Shoulder (CPT® 76881 or CPT® 76882) 	MRI is <i>NOT</i> needed for muscle belly strains/ muscle tears.
Complete Rupture – Tear of a Specific Named Tendon	No	<ul style="list-style-type: none"> • For preoperative planning: <ul style="list-style-type: none"> • MRI Shoulder without contrast (CPT® 73221) OR • US Shoulder (CPT® 76881 or CPT® 76882) 	

After an initial plain x-ray has been obtained, and results are available to the provider, the following advanced imaging is indicated (as described in General Guidelines [MS-1.0])

Condition (Individual's Condition)	Conservative Treatment (Is failure of 6 weeks of provider-directed conservative treatment within the past 12 weeks with clinical re-evaluation required?) (Yes or No)	Advanced Imaging (The appropriate advanced imaging indicated for this condition. In some scenarios, advanced imaging may not be indicated.)	Comments (Additional comments related to the condition.)
Shoulder Labral Tear (e.g., SLAP, ALPSA, HAGL)	Yes	<ul style="list-style-type: none"> • MRI Shoulder with contrast (arthrogram) (CPT® 73222) OR • MRI Shoulder without contrast (CPT® 73221) OR • CT Shoulder with contrast (arthrogram) (CPT® 73201) 	For surgery criteria, see: <u>Shoulder Surgery- Arthroscopic and Open Procedures (CMM-315)</u>

After an initial plain x-ray has been obtained, and results are available to the provider, the following advanced imaging is indicated (as described in General Guidelines [MS-1.0])

Condition (Individual's Condition)	Conservative Treatment (Is failure of 6 weeks of provider-directed conservative treatment within the past 12 weeks with clinical re-evaluation required?) (Yes or No)	Advanced Imaging (The appropriate advanced imaging indicated for this condition. In some scenarios, advanced imaging may not be indicated.)	Comments (Additional comments related to the condition.)
<p>Shoulder Dislocation/ Subluxation/ Instability, or Bankart/ Hill-Sachs Lesions</p>	<p>Yes*</p>	<ul style="list-style-type: none"> • Individuals 40 years of age or younger with a first time dislocation, and in individuals with recurrent dislocations, conservative treatment not required: <ul style="list-style-type: none"> • MRI Shoulder with contrast (arthrogram) (CPT® 73222) or • MRI Shoulder without contrast (CPT® 73221) • CT Shoulder with contrast (arthrogram) (CPT® 73201) or CT Shoulder without contrast (CPT® 73200) if MRI is contraindicated 	<p>*Conservative treatment is required in individuals over age 40 with a first time dislocation.</p> <p>For surgery criteria, see: <u>Shoulder Surgery- Arthroscopic and Open Procedures (CMM-315)</u></p>

After an initial plain x-ray has been obtained, and results are available to the provider, the following advanced imaging is indicated (as described in General Guidelines [MS-1.0])

Condition (Individual's Condition)	Conservative Treatment (Is failure of 6 weeks of provider-directed conservative treatment within the past 12 weeks with clinical re-evaluation required?) (Yes or No)	Advanced Imaging (The appropriate advanced imaging indicated for this condition. In some scenarios, advanced imaging may not be indicated.)	Comments (Additional comments related to the condition.)
Frozen Shoulder/ Adhesive Capsulitis	Yes	<ul style="list-style-type: none"> MRI Shoulder without contrast (CPT® 73221) 	For surgery criteria, see: <u>Manipulation Under Anesthesia (CMM-310)</u> and <u>Shoulder Surgery-Arthroscopic (CMM-315)</u>
Avascular Necrosis (AVN) of the Humeral Head	No	<ul style="list-style-type: none"> See: <u>AVN (MS-4.1)</u> 	
Acromio-clavicular (AC) Separation	No	<ul style="list-style-type: none"> MRI Shoulder without contrast (CPT® 73221) to rule out possible rotator cuff tear following AC separation 	
Sterno-clavicular (SC) Dislocation	No	<ul style="list-style-type: none"> CT Chest without contrast (CPT® 71250) if posterior SC dislocation is evident or suspected 	

After an initial plain x-ray has been obtained, and results are available to the provider, the following advanced imaging is indicated (as described in General Guidelines [MS-1.0])

Condition (Individual's Condition)	Conservative Treatment (Is failure of 6 weeks of provider-directed conservative treatment within the past 12 weeks with clinical re-evaluation required?) (Yes or No)	Advanced Imaging (The appropriate advanced imaging indicated for this condition. In some scenarios, advanced imaging may not be indicated.)	Comments (Additional comments related to the condition.)
<p>Post-Operative Shoulder Surgery for Impingement, Rotator Cuff Tear, and/or Labral Tear</p>	<p>Yes</p>	<ul style="list-style-type: none"> • In symptomatic individuals: <ul style="list-style-type: none"> • MRI Shoulder without contrast (CPT® 73221) OR • MRI Shoulder with contrast (arthrogram) (CPT® 73222) • US Shoulder (CPT® 76881 or CPT® 76882) is also appropriate in symptomatic individuals following rotator cuff repair • CT Shoulder with contrast (arthrogram) (CPT® 73201) if MRI contraindicated 	
<p>Preoperative Shoulder (Glenohumeral) Replacement Surgery</p>	<p>Yes</p>	<ul style="list-style-type: none"> • CT Shoulder without contrast (CPT® 73200) and/or MRI Shoulder without contrast (CPT® 73221) for preoperative planning prior to shoulder replacement 	<p>See also: <u>Osteoarthritis (MS-12)</u> For joint surgery criteria, see: <u>Shoulder Arthroplasty/ Arthrodesis (CMM-318)</u></p>

After an initial plain x-ray has been obtained, and results are available to the provider, the following advanced imaging is indicated (as described in General Guidelines [MS-1.0])

Condition (Individual's Condition)	Conservative Treatment (Is failure of 6 weeks of provider-directed conservative treatment within the past 12 weeks with clinical re-evaluation required?) (Yes or No)	Advanced Imaging (The appropriate advanced imaging indicated for this condition. In some scenarios, advanced imaging may not be indicated.)	Comments (Additional comments related to the condition.)
<p>Post-Operative Shoulder (Glenohumeral) Replacement Surgery</p>	<p>No</p>	<ul style="list-style-type: none"> • For suspected aseptic loosening or fracture as additional imaging following plain x-rays: <ul style="list-style-type: none"> • CT Shoulder without contrast (CPT® 73200) OR • MRI Shoulder without contrast (CPT® 73221) OR • US Shoulder (CPT® 76881 or CPT® 76882) OR • Bone scan (CPT® 78315) OR • Distribution Of Radiopharmaceutical Agent SPECT (CPT® 78803 or CPT® 78831) OR • Hybrid SPECT/CT (CPT® 78830) 	<p>See also: <u>Post-Operative Joint Replacement (MS-16)</u></p>

After an initial plain x-ray has been obtained, and results are available to the provider, the following advanced imaging is indicated (as described in General Guidelines [MS-1.0])

Condition (Individual's Condition)	Conservative Treatment (Is failure of 6 weeks of provider-directed conservative treatment within the past 12 weeks with clinical re-evaluation required?) (Yes or No)	Advanced Imaging (The appropriate advanced imaging indicated for this condition. In some scenarios, advanced imaging may not be indicated.)	Comments (Additional comments related to the condition.)
<p>Post-Operative Shoulder (Glenohumeral) Replacement Surgery</p>	<p>No</p>	<ul style="list-style-type: none"> • For suspected infection with negative or inconclusive joint aspiration culture: <ul style="list-style-type: none"> ○ MRI Shoulder without contrast (CPT® 73321) OR ○ MRI Shoulder without and with contrast (CPT® 73223) OR ○ CT Shoulder with contrast (CPT® 73201) OR ○ US Shoulder (CPT® 76881 or CPT® 76882) OR ○ See also: <u>Nuclear Medicine (MS-28)</u> 	<p>See also: <u>Post-Operative Joint Replacement (MS-16)</u></p>

After an initial plain x-ray has been obtained, and results are available to the provider, the following advanced imaging is indicated (as described in General Guidelines [MS-1.0])

Condition (Individual's Condition)	Conservative Treatment (Is failure of 6 weeks of provider-directed conservative treatment within the past 12 weeks with clinical re-evaluation required?) (Yes or No)	Advanced Imaging (The appropriate advanced imaging indicated for this condition. In some scenarios, advanced imaging may not be indicated.)	Comments (Additional comments related to the condition.)
<p>Post-Operative Shoulder (Glenohumeral) Replacement Surgery</p>	<p>No</p>	<ul style="list-style-type: none"> • For possible rotator cuff tear: <ul style="list-style-type: none"> • CT Shoulder with contrast (arthrogram) (CPT® 73201) OR • MRI Shoulder without contrast (CPT® 73221) OR • US Shoulder (CPT® 76881 or CPT® 76882) • For possible nerve injury: <ul style="list-style-type: none"> • MRI Shoulder without contrast (CPT® 73221) OR • US Shoulder (CPT® 76881 or CPT® 76882) 	<p>See also: <u>Post-Operative Joint Replacement (MS-16)</u></p>

References (MS-19)

v1.0.2024

1. Amini B, Beckmann NM, Beaman FD, et al. Expert Panel on Musculoskeletal Imaging. ACR Appropriateness Criteria® Shoulder Pain - Traumatic. *Am Coll Radiol (ACR)*; Revised 2017. <https://acsearch.acr.org/docs/69433/Narrative/>.
2. Neviaser RJ, Neviaser TJ. Recurrent instability of the shoulder after age 40. *J Shoulder Elbow Surg*. 1995;4(6):416-418.
3. Bradley M, Tung G, Green A. Overutilization of shoulder magnetic resonance imaging as a diagnostic screening tool in patients with chronic shoulder pain. *J Shoulder Elbow Surgery*. 2005;14(3):233-237. doi:10.1016/j.jse.2004.08.002.
4. Fongemie AE, Buss DD, and Rolnick SJ. Management of shoulder impingement syndrome and rotator cuff tears. *Am Fam Physician*. 1998;57(4):667-674. <https://www.aafp.org/afp/1998/0215/p667.html>.
5. Griffin LY. *Essentials of Musculoskeletal Care*. 3rd edition. Rosemont, IL: American Academy of Orthopaedic Surgeons; 2005:212.
6. Gyftopoulos S, Rosenberg ZS, Roberts CC, ET. Al. Expert Panel on Musculoskeletal Imaging. ACR Appropriateness Criteria® Imaging After Shoulder Arthroplasty. *Am Coll Radiol (ACR)*; Date of Origin: 2016. <https://acsearch.acr.org/docs/3097049/Narrative/>.
7. Hovelius L, Olofsson A, Sandstrom B, et al. Nonoperative treatment of primary anterior shoulder dislocation in patients forty years of age and younger: a prospective twenty-five year follow-up. *J Bone Joint Surg*. 2008;90:945-52. doi:10.2106/JBJS.G.00070.
8. Lin A, Gasbarro G, Sakr M. Clinical Applications of Ultrasonography in the Shoulder and Elbow. *J Am Acad Orthop Surg*. 2018;26:303-312.
9. Magee T. 3-T MRI of the shoulder: is MR arthrography necessary? *AJR J Am Roentgenol*. 2009;192:86-92. doi:10.2214/AJR.08.1097.
10. Major NM, Browne J, Domzalski T, Cothran RL, Helms CA. Evaluation of the glenoid labrum with 3-T MRI: is intraarticular contrast necessary. *AJR Am J Roentgenol*. 2011;196:1139-1144. doi:10.2214/AJR.08.1734.
11. McDonald LS, Dewing CB, Shupe PG, et al. Disorders of the proximal and distal aspects of the biceps muscle. *J Bone Joint Surg*. 2013;95:1235-1245. doi:10.2106/JBJS.L.00221.
12. Petersen SA, Murphy TP. The timing of rotator cuff repair for the restoration of function. *Journal of Shoulder and Elbow Surgery*. 2011;20(1):62-68. doi:10.1016/j.jse.2010.04.045.
13. Rehman A, Robinson P. Sonographic evaluation of injuries of the pectoralis muscles. *AJR Am J Roentgenol*. 2005;184:1205-1211. doi:10.2214/ajr.184.4.01841205.
14. Small KM, Adler RS, Shah SH, et al. Expert Panel on Musculoskeletal Imaging. ACR Appropriateness Criteria® Shoulder Pain - Atraumatic. *Am Coll Radiol (ACR)*; New 2018. <https://acsearch.acr.org/docs/3101482/Narrative/>.
15. Steinbach LS, Chung CB, Yoshioka H. Technical Considerations for MRI of Upper Extremity Joints. In: Chung CB, Steinbach LS, eds. *MRI of the Upper Extremity Shoulder, Elbow, Wrist and Hand* Philadelphia, PA: Lippincott Williams & Wilkins 2010:211.
16. Streubel PN, Krych AJ, Simone JP, et al. Anterior glenohumeral instability: a pathology-based surgical treatment strategy. *J Am Acad Orthop Surg*. 2014;22:283-294. doi:10.5435/JAAOS-22-05-283.
17. Werner BC, Brockmeier SF, and Miller MD. Etiology, diagnosis, and management of failed SLAP repair. *J Am Acad Orthop Surg*. 2014;22(9):554-565. doi:10.5435/JAAOS-22-09-554.
18. Woodward TW and Best TM. The painful shoulder: Part II. Acute and chronic disorders. *Am Fam Physician*. 2000;61(11):3291-3300. <https://www.aafp.org/afp/2000/0601/p3291.html>.
19. Zappia M, Di Pietto F, Aliprandi A, et al. Multi-modal imaging of adhesive capsulitis of the shoulder. *Insights Imaging*. 2016;7:365-371.
20. Frankle MA, Teramoto A, Luo Z-P, Levy JC, Pupello D. Glenoid morphology in reverse shoulder arthroplasty: Classification and surgical implications. *Journal of Shoulder and Elbow Surgery*. 2009;18(6):874-885. doi:10.1016/j.jse.2009.02.013.
21. Beaman FD, von Herrmann PF, Kransdorf MJ, et. al. Expert Panel on Musculoskeletal Imaging. ACR Appropriateness Criteria® Suspected osteomyelitis, septic arthritis, or soft tissue infection (excluding spine and diabetic foot). *Am Coll Radiol (ACR)*; Date of Origin: 2016. Revised: 2022.
22. Kowalczyk M, Elmaraghy A. Pectoralis major rupture: Evaluation and management. *J Am Acad Orthop Surg*. 2022;30:e617-e627. doi:10.5435/JAAOS-D-21-00541.
23. Fritz J, Meshram P, Stern SE, Fritz B, Srikumaran U, McFarland EG. Diagnostic performance of advanced metal artifact reduction MRI for periprosthetic shoulder infection. *J Bone Joint Surg Am*. 2022;104:1352-1361. doi:10.2106/JBJS.21.00912.

Elbow (MS-20)

Guideline

Elbow (MS-20)

References (MS-20)

Elbow (MS-20)

MS.EB.0020.A

v1.0.2024

After an initial plain x-ray has been obtained, and results are available to the provider, the following advanced imaging is indicated (as described in General Guidelines [MS-1.0])

Condition (Individual's condition)	Conservative Treatment (Is failure of 6 weeks of provider-directed conservative treatment within the past 12 weeks with clinical re-evaluation required?) (Yes or No)	Advanced Imaging (The appropriate advanced imaging indicated for this condition. In some scenarios, advanced imaging may not be indicated.)	Comments (Additional comments related to the condition.)
General Elbow Pain	Yes	<ul style="list-style-type: none"> MRI Elbow without contrast (CPT® 73221) OR US Elbow (CPT® 76881 or CPT® 76882) 	
Symptomatic Loose Bodies	No	<ul style="list-style-type: none"> MRI Elbow without contrast (CPT® 73221) OR MRI Elbow with contrast (arthrogram) (CPT® 73222) OR CT Elbow without contrast (CPT® 73200) OR CT Elbow with contrast (arthrogram) (CPT® 73201) 	
Tendonitis	Yes	<ul style="list-style-type: none"> MRI Elbow without contrast (CPT® 73221) OR US Elbow (CPT® 76881 or CPT® 76882) 	
Bursitis	Yes	<ul style="list-style-type: none"> MRI Elbow without and with contrast (CPT® 73223) OR MRI Elbow without contrast (CPT® 73221) OR US Elbow (CPT® 76881 or CPT® 76882) 	

After an initial plain x-ray has been obtained, and results are available to the provider, the following advanced imaging is indicated (as described in General Guidelines [MS-1.0])

Condition (Individual's condition)	Conservative Treatment (Is failure of 6 weeks of provider-directed conservative treatment within the past 12 weeks with clinical re-evaluation required?) (Yes or No)	Advanced Imaging (The appropriate advanced imaging indicated for this condition. In some scenarios, advanced imaging may not be indicated.)	Comments (Additional comments related to the condition.)
<p>Lateral (tennis elbow) or Medial (golfer's elbow) Epicondylitis</p>	<p>Yes</p>	<ul style="list-style-type: none"> • To confirm clinical diagnosis of epicondylitis if symptoms persist for longer than 6 months despite at least 6 weeks conservative treatment in the last 3 months: <ul style="list-style-type: none"> • MRI Elbow without contrast (CPT® 73221) OR • US Elbow (CPT® 76881 or CPT® 76882) 	<p>Epicondylitis, caused by tendon degeneration and tear of the common extensor tendon laterally or of the common flexor tendon medially, is a common clinical diagnosis for which imaging is not medically necessary except as noted.</p>

After an initial plain x-ray has been obtained, and results are available to the provider, the following advanced imaging is indicated (as described in [General Guidelines \[MS-1.0\]](#))

Condition (Individual's condition)	Conservative Treatment (Is failure of 6 weeks of provider-directed conservative treatment within the past 12 weeks with clinical re-evaluation required?) (Yes or No)	Advanced Imaging (The appropriate advanced imaging indicated for this condition. In some scenarios, advanced imaging may not be indicated.)	Comments (Additional comments related to the condition.)
Suspected Osteochondral Injury	No	<ul style="list-style-type: none"> • If plain x-rays are negative and an osteochondral fracture is still suspected: <ul style="list-style-type: none"> • MRI Elbow without contrast (CPT® 73221) OR • MRI Elbow with contrast (arthrogram) (CPT® 73222) OR • CT Elbow without contrast (CPT® 73200) OR • CT Elbow with contrast (arthrogram) (CPT® 73201) 	See: <u>Chondral/ Osteochondral Lesions (MS-13)</u> for other osteochondral injury scenarios

After an initial plain x-ray has been obtained, and results are available to the provider, the following advanced imaging is indicated (as described in General Guidelines [MS-1.0])

Condition (Individual's condition)	Conservative Treatment (Is failure of 6 weeks of provider-directed conservative treatment within the past 12 weeks with clinical re-evaluation required?) (Yes or No)	Advanced Imaging (The appropriate advanced imaging indicated for this condition. In some scenarios, advanced imaging may not be indicated.)	Comments (Additional comments related to the condition.)
Ruptured Biceps Insertion at Elbow	No	<ul style="list-style-type: none"> When clinical exam is inconclusive or for preoperative planning: <ul style="list-style-type: none"> MRI Elbow without contrast (CPT® 73221) OR US Elbow (CPT® 76881 or CPT® 76882) 	
Ruptured Triceps Insertion at Elbow	No	<ul style="list-style-type: none"> When clinical exam is inconclusive or for preoperative planning: <ul style="list-style-type: none"> MRI Elbow without contrast (CPT® 73221) OR US Elbow (CPT® 76881 or CPT® 76882) 	
Partial Tendon Rupture	No	<ul style="list-style-type: none"> For a suspected partial tendon rupture of a specific named tendon not otherwise specified: <ul style="list-style-type: none"> MRI Elbow without contrast (CPT® 73221) OR US Elbow (CPT® 76881 or CPT® 76882) 	MRI is <i>NOT</i> needed for muscle belly strains/muscle tears.

After an initial plain x-ray has been obtained, and results are available to the provider, the following advanced imaging is indicated (as described in General Guidelines [MS-1.0])

Condition (Individual's condition)	Conservative Treatment (Is failure of 6 weeks of provider-directed conservative treatment within the past 12 weeks with clinical re-evaluation required?) (Yes or No)	Advanced Imaging (The appropriate advanced imaging indicated for this condition. In some scenarios, advanced imaging may not be indicated.)	Comments (Additional comments related to the condition.)
Complete Rupture – Tear of a Specific Named Tendon	No	<ul style="list-style-type: none"> For preoperative planning: <ul style="list-style-type: none"> MRI Elbow without contrast (CPT® 73221) OR US Elbow (CPT® 76881 or CPT® 76882) 	
Trauma	No	<ul style="list-style-type: none"> When surgery is being considered: <ul style="list-style-type: none"> MRI Elbow without contrast (CPT® 73221) OR CT Elbow without contrast (CPT® 73200) 	
Ulnar Collateral Ligament (UCL) Tear	No	<ul style="list-style-type: none"> Following acute or repetitive (including overhead throwing athletes) elbow trauma: <ul style="list-style-type: none"> MRI Elbow with contrast (arthrogram) (CPT® 73222) OR MRI Elbow without contrast (CPT® 73221) OR US Elbow (CPT® 76881 or CPT® 76882) OR CT Elbow with contrast (arthrogram) (CPT® 73201) 	
Suspected Nerve Abnormality	NA	<ul style="list-style-type: none"> This condition is imaged according to the criteria found in the Peripheral Nerve Disorder Guidelines. See: Focal Neuropathy (PN-2) in the Peripheral Nerve Disorders Imaging Guidelines 	

After an initial plain x-ray has been obtained, and results are available to the provider, the following advanced imaging is indicated (as described in General Guidelines [MS-1.0])

Condition (Individual's condition)	Conservative Treatment (Is failure of 6 weeks of provider-directed conservative treatment within the past 12 weeks with clinical re-evaluation required?) (Yes or No)	Advanced Imaging (The appropriate advanced imaging indicated for this condition. In some scenarios, advanced imaging may not be indicated.)	Comments (Additional comments related to the condition.)
Post-Operative	Yes	<ul style="list-style-type: none"> • CT Elbow without contrast (CPT® 73200) in symptomatic post-operative individuals following surgical treatment of complex fractures; OR • MRI Elbow without contrast (CPT® 73221) in symptomatic post-operative individuals following soft-tissue surgery 	
Preoperative Elbow Replacement Surgery	Yes	<ul style="list-style-type: none"> • CT Elbow without contrast (CPT® 73200) for preoperative planning prior to elbow replacement when congenital or post-traumatic deformities exist 	See: <u>Osteoarthritis (MS-12)</u>

After an initial plain x-ray has been obtained, and results are available to the provider, the following advanced imaging is indicated (as described in General Guidelines [MS-1.0])

Condition (Individual's condition)	Conservative Treatment (Is failure of 6 weeks of provider-directed conservative treatment within the past 12 weeks with clinical re-evaluation required?) (Yes or No)	Advanced Imaging (The appropriate advanced imaging indicated for this condition. In some scenarios, advanced imaging may not be indicated.)	Comments (Additional comments related to the condition.)
<p>Post-Operative Elbow Replacement Surgery</p>	<p>No</p>	<ul style="list-style-type: none"> • For suspected aseptic loosening or periprosthetic fracture when recent plain x-ray is nondiagnostic: <ul style="list-style-type: none"> • CT Elbow without contrast (CPT® 73200) OR • Bone scan (CPT® 78315) OR • Distribution Of Radiopharmaceutical Agent SPECT (CPT® 78803 or 78831) OR • Hybrid SPECT/CT (CPT® 78830) • For suspected infection with negative or inconclusive joint aspiration culture: <ul style="list-style-type: none"> • MRI Elbow without contrast (CPT® 73221) OR • MRI Elbow without and with contrast (CPT® 73223) OR • CT Elbow with contrast (CPT® 73201) OR • US Elbow (CPT® 76881 or CPT® 76882) OR • See also: <u>Nuclear Medicine (MS-28)</u> 	

References (MS-20)

v1.0.2024

1. McDonald LS, Dewing CB, Shupe PG, et al. Disorders of the proximal and distal aspects of the biceps muscle. *J Bone Joint Surg*. 2013;95:1235-1245. doi:10.2106/JBJS.L.00221.
2. Torp-Pedersen TE, Torp-Pedersen ST, Qvistgaard E, et al. Effect of glucocorticosteroid injections in tennis elbow verified on colour Doppler ultrasonography: evidence of inflammation. *Br J Sports Med*. 2008;42(12):978-982. doi:10.1136/bjsm.2007.041285.
3. Johnson GW, Cadwallader K, Scheffel SB, et al. Treatment of lateral epicondylitis. *Am Fam Physician*. 2007;76(6):843-848. <https://www.aafp.org/afp/2007/0915/p843.html>.
4. Griffin LY. *Essentials of Musculoskeletal Care*. 3rd edition. Rosemont, IL: American Academy of Orthopaedic Surgeons; 2005:279-280.
5. Hayes CW, Roberts CC, Bencardino JT, et. al. Expert Panel on Musculoskeletal Imaging. ACR Appropriateness Criteria® Chronic Elbow Pain. *Am Coll Radiol (ACR)*; Date of Origin: 1998. Last Review: 2022. <https://acsearch.acr.org/docs/69423/Narrative/>.
6. Bruce JR, Andrews JR. Ulnar collateral ligament injuries in the throwing athlete. *J Am Acad Orthop Surg*. 2014;22:315-325.
7. Beltran J, Rosenberg ZS. Diagnosis of compressive and entrapment neuropathies of the upper extremity: value of MR imaging. *AJR Am J Roentgenol*. 1994;163(3):525-531. doi:10.2214/ajr.163.3.8079837.
8. Lin A, Gasbarro G, Sakr M. Clinical Applications of Ultrasonography in the Shoulder and Elbow. *J Am Acad Orthop Surg*. 2018;26:303-312.
9. Stanborough RO, Wessell DE, Elhassan BT, Schoch BS. MRI of the elbow: Interpretation of common orthopaedic injuries. *J Am Acad Orthop Surg*. 2022;30:e573-e583. doi:10.5435/JAAOS-D-21-00193.
10. Beaman FD, von Herrmann PF, Kransdorf MJ, et. al. Expert Panel on Musculoskeletal Imaging. ACR Appropriateness Criteria® Suspected Osteomyelitis, Septic Arthritis, or Soft Tissue Infection (Excluding Spine and Diabetic Foot). *Am Coll Radiol (ACR)*; Date of Origin: 2016. Revised: 2022. <https://acsearch.acr.org/docs/3094201/Narrative/>.

Wrist (MS-21)

Guideline

Wrist (MS-21)

References (MS-21)

Wrist (MS-21)

MS.WR.0021.A

v1.0.2024

After an initial plain x-ray has been obtained, and results are available to the provider, the following advanced imaging is indicated (as described in General Guidelines [MS-1.0])

Condition (Individual's condition)	Conservative Treatment (Is failure of 6 weeks of provider-directed conservative treatment within the past 12 weeks with clinical re-evaluation required?) (Yes or No)	Advanced Imaging (The appropriate advanced imaging indicated for this condition. In some scenarios, advanced imaging may not be indicated.)	Comments (Additional comments related to the condition.)
General Wrist Pain	Yes	<ul style="list-style-type: none"> MRI Wrist without contrast (CPT® 73221) OR US Wrist (CPT® 76881 or CPT® 76882) 	
Tendonitis	Yes	<ul style="list-style-type: none"> MRI Wrist without contrast (CPT® 73221) OR US Wrist (CPT® 76881 or CPT® 76882) 	
Kienbock's Disease (Avascular Necrosis (AVN) of the Lunate)/ Preiser's Disease (Avascular Necrosis (AVN) of the Scaphoid)	No	See AVN (MS-4.1)	

After an initial plain x-ray has been obtained, and results are available to the provider, the following advanced imaging is indicated (as described in General Guidelines [MS-1.0])

Condition (Individual's condition)	Conservative Treatment (Is failure of 6 weeks of provider-directed conservative treatment within the past 12 weeks with clinical re-evaluation required?) (Yes or No)	Advanced Imaging (The appropriate advanced imaging indicated for this condition. In some scenarios, advanced imaging may not be indicated.)	Comments (Additional comments related to the condition.)
Suspected Navicular/ Scaphoid Fracture	No	<ul style="list-style-type: none"> When suspected based on history and physical exam: <ul style="list-style-type: none"> MRI Wrist without contrast (CPT® 73221) OR CT Wrist without contrast (CPT® 73200) 	See also: <u>Suspected Occult/ Stress/ Insufficiency Fracture/ Stress Reaction and Shin Splints (MS-5.2)</u>
Distal Radioulnar Joint (DRUJ) Instability	No	<ul style="list-style-type: none"> CT of both wrists without contrast (CPT® 73200) (should include wrists in supination and pronation) 	
Complex Distal Radius/ Ulna Fracture	No	<ul style="list-style-type: none"> CT Wrist without contrast (CPT® 73200) 	
Carpal Tunnel Syndrome/ Ulnar Tunnel Syndrome	NA	<ul style="list-style-type: none"> This condition is imaged according to the criteria found in the Peripheral Nerve Disorder Guidelines. See <u>Focal Neuropathy (PN-2)</u> in the Peripheral Nerve Disorders Imaging Guidelines 	

After an initial plain x-ray has been obtained, and results are available to the provider, the following advanced imaging is indicated (as described in General Guidelines [MS-1.0])			
Condition (Individual's condition)	Conservative Treatment (Is failure of 6 weeks of provider-directed conservative treatment within the past 12 weeks with clinical re-evaluation required?) (Yes or No)	Advanced Imaging (The appropriate advanced imaging indicated for this condition. In some scenarios, advanced imaging may not be indicated.)	Comments (Additional comments related to the condition.)
Intrinsic Ligament (e.g. scapholunate)/ Triangular Fibrocartilage Complex (TFCC) Injuries	Yes	<ul style="list-style-type: none"> MRI Wrist with contrast (arthrogram) (CPT® 73222) OR CT Wrist with contrast (arthrogram) (CPT® 73201) 	
Complete Rupture - Tear of a Specific Named Tendon	No	<ul style="list-style-type: none"> For preoperative planning: <ul style="list-style-type: none"> MRI Wrist without contrast (CPT® 73221) OR US Wrist (CPT® 76881 or CPT® 76882) 	
Partial Tendon Rupture	No	<ul style="list-style-type: none"> For a suspected partial tendon rupture of a specific named tendon not otherwise specified: <ul style="list-style-type: none"> MRI Wrist without contrast (CPT® 73221) OR US Wrist (CPT® 76881 or CPT® 76882) 	MRI is <i>NOT</i> needed for muscle belly strains/muscle tears.

After an initial plain x-ray has been obtained, and results are available to the provider, the following advanced imaging is indicated (as described in General Guidelines [MS-1.0])			
Condition (Individual's condition)	Conservative Treatment (Is failure of 6 weeks of provider-directed conservative treatment within the past 12 weeks with clinical re-evaluation required?) (Yes or No)	Advanced Imaging (The appropriate advanced imaging indicated for this condition. In some scenarios, advanced imaging may not be indicated.)	Comments (Additional comments related to the condition.)
Post-Operative	Yes	<ul style="list-style-type: none"> CT Wrist without contrast (CPT® 73200) in symptomatic individuals following surgery for navicular/scaphoid fractures and complex distal radius/ulna fractures OR MRI Wrist with contrast (arthrogram) (CPT® 73222) in symptomatic individuals following DRUJ or TFCC surgery 	
Preoperative Wrist Replacement Surgery	Yes	<ul style="list-style-type: none"> CT Wrist without contrast (CPT® 73200) for preoperative planning prior to wrist replacement when congenital or post-traumatic deformities exist 	See also: <u>Osteoarthritis (MS-12)</u>

After an initial plain x-ray has been obtained, and results are available to the provider, the following advanced imaging is indicated (as described in General Guidelines [MS-1.0])			
Condition (Individual's condition)	Conservative Treatment (Is failure of 6 weeks of provider-directed conservative treatment within the past 12 weeks with clinical re-evaluation required?) (Yes or No)	Advanced Imaging (The appropriate advanced imaging indicated for this condition. In some scenarios, advanced imaging may not be indicated.)	Comments (Additional comments related to the condition.)
Post-Operative Wrist Replacement Surgery	No	<ul style="list-style-type: none"> For suspected aseptic loosening or periprosthetic fracture when recent plain x-ray is nondiagnostic: <ul style="list-style-type: none"> CT Wrist without contrast (CPT® 73200) OR Bone scan (CPT® 78315, 78300, or 78306) OR Distribution Of Radiopharmaceutical Agent SPECT (CPT® 78803 or CPT® 78831) OR Hybrid SPECT/CT (CPT® 78830) For suspected infection with negative or inconclusive joint aspiration culture: <ul style="list-style-type: none"> MRI Wrist without contrast (CPT® 73221) OR MRI Wrist without and with contrast (CPT® 73223) OR CT Wrist with contrast (CPT® 73201) OR US Wrist (CPT® 76881 or CPT® 76882) OR See also: <u>Nuclear Medicine (MS-28)</u> 	

One Study/Area Only

In hand and wrist advanced imaging, studies are frequently ordered of both areas. This is unnecessary since wrist MRI will image from above the wrist to the mid-metacarpal area. **Only one CPT[®] code should be reported.**

References (MS-21)

v1.0.2024

1. Bruno MA, Weissman BN, Kransdorf MJ, et. al. Expert Panel on Musculoskeletal Imaging. ACR Appropriateness Criteria® Acute Hand and Wrist Trauma. *Am Coll Radiol (ACR)*; Date of Origin: 1995. Revised: 2018. <https://acsearch.acr.org/docs/69418/Narrative/>.
2. Rubin DA, Roberts CC, Bencardino JT, et. al. Expert Panel on Musculoskeletal Imaging. ACR Appropriateness Criteria® Chronic Wrist Pain. *Am Coll Radiol (ACR)*; Revised: 2017. <https://acsearch.acr.org/docs/69427/Narrative/>.
3. Hayter CL, Gold SL, Potter HG. Magnetic resonance imaging of the wrist: bone and cartilage injury. *J Magn Reson Imaging*. 2013;37(5):1005-19. doi:10.1002/jmri.23845.
4. Pruitt DL, Gilula LA, Manske PR, et al. Computed tomography scanning with image reconstruction in evaluation of distal radius fractures. *J Hand Surg Am*.1994;19(5):720-727. doi:10.1016/0363-5023(94)90174-0.
5. Magee T. Comparison of 3-T MRI and arthroscopy of intrinsic wrist ligament and TFCC tears. *AJR Am J Roentgenol*. 2009;192:80-85. doi:10.2214/AJR.08.1089.
6. Lee RK, Ng AW, Tong CS, et al. Intrinsic ligament and triangular fibrocartilage complex tears of the wrist: comparison of MDCT arthrography, conventional 3-T MRI, and MR arthrography. *Skeletal Radiol*. 2013;42:1277-85. doi:10.1007/s00256-013-1666-8.
7. Pahwa S, Srivastava DN, Sharma R, et al. Comparison of conventional MRI and MR arthrography in the evaluation wrist ligament tears: A preliminary experience. *Indian J Radiol Imaging*. 2014;3:259-67. doi:10.4103/0971-3026.137038.
8. Beaman FD, von Herrmann PF, Kransdorf MJ, et. al. Expert Panel on Musculoskeletal Imaging. ACR Appropriateness Criteria® Suspected Osteomyelitis, Septic Arthritis, or Soft Tissue Infection (Excluding Spine and Diabetic Foot). *Am Coll Radiol (ACR)*; Date of Origin: 2016. Revised: 2022. <https://acsearch.acr.org/docs/3094201/Narrative/>.

Hand (MS-22)

Guideline

Hand (MS-22)

References (MS-22)

Hand (MS-22)

MS.HA.0022.A

v1.0.2024

After an initial plain x-ray has been obtained, and results are available to the provider, the following advanced imaging is indicated (as described in General Guidelines [MS-1.0])

Condition (Individual's condition)	Conservative Treatment (Is failure of 6 weeks of provider-directed conservative treatment within the past 12 weeks with clinical re-evaluation required?) (Yes or No)	Advanced Imaging (The appropriate advanced imaging indicated for this condition. In some scenarios, advanced imaging may not be indicated.)	Comments (Additional comments related to the condition.)
General Hand Pain	Yes	<ul style="list-style-type: none"> MRI Hand or Finger without contrast (CPT® 73218) OR US Hand (CPT® 76881 or CPT® 76882) 	
Tendonitis	Yes	<ul style="list-style-type: none"> MRI Hand or Finger without contrast (CPT® 73218) OR US Hand or Finger (CPT® 76881 or CPT® 76882) 	
Occult Fracture	No	<ul style="list-style-type: none"> Advanced imaging guided by: <u>Suspected Occult/ Stress/ Insufficiency Fracture/ Stress Reaction and Shin Splints (MS-5.2)</u> 	
Complex Fracture	No	<ul style="list-style-type: none"> CT Hand or Finger without contrast (CPT® 73200) when plain x-ray shows a complex fracture 	

After an initial plain x-ray has been obtained, and results are available to the provider, the following advanced imaging is indicated (as described in General Guidelines [MS-1.0])			
Condition (Individual's condition)	Conservative Treatment (Is failure of 6 weeks of provider-directed conservative treatment within the past 12 weeks with clinical re-evaluation required?) (Yes or No)	Advanced Imaging (The appropriate advanced imaging indicated for this condition. In some scenarios, advanced imaging may not be indicated.)	Comments (Additional comments related to the condition.)
Ulnar Collateral Ligament (UCL) Thumb Injury	No	<ul style="list-style-type: none"> If rule out for Stener lesion or complete tear of UCL of the thumb MCP joint: <ul style="list-style-type: none"> MRI Thumb without contrast (CPT® 73218) OR US Thumb (CPT® 76881 or CPT® 76882) 	Also called "Gamekeeper's Thumb" or "Skier's Thumb"
Complete Rupture – Tear of a Specific Named Tendon	No	<ul style="list-style-type: none"> For preoperative planning: <ul style="list-style-type: none"> MRI Hand or Finger without contrast (CPT® 73218) OR US Hand or Finger (CPT® 76881 or CPT® 76882) 	

After an initial plain x-ray has been obtained, and results are available to the provider, the following advanced imaging is indicated (as described in General Guidelines [MS-1.0])			
Condition (Individual's condition)	Conservative Treatment (Is failure of 6 weeks of provider-directed conservative treatment within the past 12 weeks with clinical re-evaluation required?) (Yes or No)	Advanced Imaging (The appropriate advanced imaging indicated for this condition. In some scenarios, advanced imaging may not be indicated.)	Comments (Additional comments related to the condition.)
Partial Tendon Rupture	No	<ul style="list-style-type: none"> For a suspected partial tendon rupture of a specific named tendon not otherwise specified: <ul style="list-style-type: none"> MRI Hand or Finger without contrast (CPT® 73218) OR US Hand or Finger (CPT® 76881 or CPT® 76882) 	MRI is <i>NOT</i> needed for muscle belly strains/muscle tears.
Post-Operative	Yes	<ul style="list-style-type: none"> In symptomatic post-operative individuals following surgical treatment for complex hand or finger fractures or following soft-tissue surgery: <ul style="list-style-type: none"> CT Hand or Finger without contrast (CPT® 73200) OR MRI Hand or Finger without contrast (CPT® 73218) 	

One Study/Area Only

In hand and wrist advanced imaging, studies are frequently ordered of both areas. This is unnecessary since wrist MRI will image from above the wrist to the mid-metacarpal area. **Only one CPT[®] code should be reported.**

References (MS-22)

v1.0.2024

1. Bruno MA, Weissman BN, Kransdorf MJ, et. al. Expert Panel on Musculoskeletal Imaging. ACR Appropriateness Criteria® Acute Hand and Wrist Trauma. *Am Coll Radiol (ACR)*; Date of Origin: 1995. Revised: 2018. <https://acsearch.acr.org/docs/69418/Narrative/>.
2. Hayter CL, Gold SL, Potter HG. Magnetic resonance imaging of the wrist: Bone and cartilage injury. *J Magn Reson Imaging*. 2013;37(5):1005-19. doi:10.1002/jmri.23845.

Pelvis (MS-23)

Guideline

Pelvis (MS-23)

References (MS-23)

Pelvis (MS-23)

MS.PE.0023.A

v1.0.2024

After an initial plain x-ray has been obtained, and results are available to the provider, the following advanced imaging is indicated (as described in General Guidelines [MS-1.0])

Condition (Individual's condition)	Conservative Treatment (Is failure of 6 weeks of provider-directed conservative treatment within the past 12 weeks with clinical re-evaluation required?) (Yes or No)	Advanced Imaging (The appropriate advanced imaging indicated for this condition. In some scenarios, advanced imaging may not be indicated.)	Comments (Additional comments related to the condition.)
General Pain-Pelvis	Yes	<ul style="list-style-type: none"> MRI Pelvis without contrast (CPT® 72195) OR MRI RT and/or LT Hip without contrast (CPT® 73721) 	
Tendonitis	Yes	<ul style="list-style-type: none"> MRI Pelvis without contrast (CPT® 72195) OR MRI RT and/or LT Hip without contrast (CPT® 73721) 	
Occult/ Insufficiency Fracture	No	<ul style="list-style-type: none"> MRI Pelvis without contrast (CPT® 72195) OR CT Pelvis without contrast (CPT® 72192) 	See also: <u>Suspected Occult/ Stress/ Insufficiency Fracture/ Stress Reaction and Shin Splints (MS-5.2)</u> for occult and stress fractures of the pelvis

After an initial plain x-ray has been obtained, and results are available to the provider, the following advanced imaging is indicated (as described in General Guidelines [MS-1.0])			
Condition (Individual's condition)	Conservative Treatment (Is failure of 6 weeks of provider-directed conservative treatment within the past 12 weeks with clinical re-evaluation required?) (Yes or No)	Advanced Imaging (The appropriate advanced imaging indicated for this condition. In some scenarios, advanced imaging may not be indicated.)	Comments (Additional comments related to the condition.)
Complex Fracture/ Dislocation - Pelvis, Sacrum and Acetabulum	No	<ul style="list-style-type: none"> CT Pelvis without contrast (CPT® 72192) 	Additionally, 3D rendering may be appropriate for preoperative planning. See: <u>3D Rendering (MS-3)</u>
Sacro-iliac (SI) Joint Pain, Sacroiliitis, Coccydynia	Yes	<ul style="list-style-type: none"> Advanced imaging guided by: <ul style="list-style-type: none"> <u>Sacroiliac (SI) Joint Pain/ Sacroiliitis (SP-10.1)</u> in the Spine Imaging Guidelines <u>Coccydynia without Neurological Features (SP-5.2)</u> in the Spine Imaging Guidelines 	
Piriformis Syndrome	NA	<ul style="list-style-type: none"> This condition is imaged according to the criteria found in the Peripheral Nerve Disorder Guidelines. See: <u>Focal Neuropathy (PN-2)</u> in the Peripheral Nerve Disorders Imaging Guidelines 	

After an initial plain x-ray has been obtained, and results are available to the provider, the following advanced imaging is indicated (as described in General Guidelines [MS-1.0])			
Condition (Individual's condition)	Conservative Treatment (Is failure of 6 weeks of provider-directed conservative treatment within the past 12 weeks with clinical re-evaluation required?) (Yes or No)	Advanced Imaging (The appropriate advanced imaging indicated for this condition. In some scenarios, advanced imaging may not be indicated.)	Comments (Additional comments related to the condition.)
Partial Tendon Rupture	No	<ul style="list-style-type: none"> MRI Pelvis without contrast (CPT® 72195) for a suspected partial tendon rupture of a specific named tendon not otherwise specified 	MRI is <i>NOT</i> needed for muscle belly strains/muscle tears.
Osteitis Pubis/ Symphysis Pubis Diastasis	Yes	<ul style="list-style-type: none"> MRI Pelvis without contrast (CPT® 72195) 	
Athletic Pubalgia (Sports Hernia)	Yes	<ul style="list-style-type: none"> To evaluate for the cause of suspected athletic pubalgia: <ul style="list-style-type: none"> MRI Pelvis without contrast (athletic pubalgia protocol) (CPT® 72195) OR Dynamic pelvic ultrasound (CPT® 76857) 	
Post-Operative	Yes	<ul style="list-style-type: none"> CT Pelvis without contrast (CPT® 72192) in symptomatic individuals following surgery for complex pelvic ring/acetabular fractures 	

References (MS-23)

v1.0.2024

1. Bencardino JT, Stone TJ, Roberts CC, et al. Expert Panel on Musculoskeletal Imaging. ACR Appropriateness Criteria® Stress (Fatigue/Insufficiency) Fracture, Including Sacrum, Excluding Other Vertebrae. *Am Coll Radiol (ACR)*; Revised: 2016. <https://acsearch.acr.org/docs/69435/Narrative/> .
2. Mehta S, Auerbach JD, Born CT, et al. Sacral fractures. *J Am Acad Orthop Surg*. 2006;14:656-665.
3. Omar IM, Zoga AC, Kavanagh EC, et al. Athletic Pubalgia and "Sports Hernia": Optimal MR Imaging Technique and Findings. *RadioGraphics*. 2008;28:1415-1438. doi:10.1148/rg.285075217.
4. Khan W, Zoga AC, Meyers WC. Magnetic Resonance Imaging of Athletic Pubalgia and the Sports Hernia - Current Understanding and Practice. *Magn Reson Imaging Clin N Am*. 2013;21:97-110. doi:10.1016/j.mric.2012.09.008.
5. Morley N, Grant T, Blount K, et al. Sonographic evaluation of athletic pubalgia. *Skeletal Radiol*. 2016 May;45(5):689-99. doi:10.1007/s00256-016-2340-8.
6. Caudill P, Nyland J, Smith C, et al. Sports hernias: a systematic literature review. *British Journal of Sports Medicine*. 2008;42(12):954-964. doi:10.1136/bjsm.2008.047373.
7. Suarez JC, Ely EE, Mutnal AB, et al. Comprehensive approach to the evaluation of groin pain. *Journal of the American Academy of Orthopaedic Surgeons*. 2013;21:558-570. doi:10.5435/JAAOS-21-09-558.
8. Heer ST, Callander JW, Kraeutler MJ, Mei-Dan O, Mulcahey MK. Hamstring Injuries. *The Journal of Bone and Joint Surgery*. 2019;101(9):843-853. doi:10.2106/jbjs.18.00261.

Hip (MS-24)

Guideline

Hip (MS-24)

References (MS-24)

Hip (MS-24)

MS.HI.0024.A

v1.0.2024

After an initial plain x-ray has been obtained, and results are available to the provider, the following advanced imaging is indicated (as described in [General Guidelines \[MS-1.0\]](#))

Condition (Individual's condition)	Conservative Treatment (Is failure of 6 weeks of provider-directed conservative treatment within the past 12 weeks with clinical re-evaluation required?) (Yes or No)	Advanced Imaging (The appropriate advanced imaging indicated for this condition. In some scenarios, advanced imaging may not be indicated.)	Comments (Additional comments related to the condition.)
General Hip Pain	Yes	<ul style="list-style-type: none"> MRI Hip without contrast (CPT® 73721) OR US Hip (CPT® 76881 or CPT® 76882) 	
Symptomatic Loose Bodies	No	<ul style="list-style-type: none"> MRI Hip without contrast (CPT® 73721) 	
Tendonitis/ Bursitis	Yes	<ul style="list-style-type: none"> MRI Hip without contrast (CPT® 73721) OR US Hip (CPT® 76881 or CPT® 76882) 	
Hip Abductor Tendon Tear/ Avulsion	No	<ul style="list-style-type: none"> MRI Hip without contrast (CPT® 73721) OR US Hip (CPT® 76881 or CPT® 76882) 	
Complete Rupture – Tear of a Specific Named Tendon	No	<ul style="list-style-type: none"> For preoperative planning: <ul style="list-style-type: none"> MRI Hip without contrast (CPT® 73721) OR US Hip (CPT® 76881 or CPT® 76882) 	

After an initial plain x-ray has been obtained, and results are available to the provider, the following advanced imaging is indicated (as described in General Guidelines [MS-1.0])			
Condition (Individual's condition)	Conservative Treatment (Is failure of 6 weeks of provider-directed conservative treatment within the past 12 weeks with clinical re-evaluation required?) (Yes or No)	Advanced Imaging (The appropriate advanced imaging indicated for this condition. In some scenarios, advanced imaging may not be indicated.)	Comments (Additional comments related to the condition.)
Partial Tendon Rupture	No	<ul style="list-style-type: none"> For a suspected partial tendon rupture of a specific named tendon not otherwise specified: <ul style="list-style-type: none"> MRI Hip without contrast (CPT® 73721) OR US Hip (CPT® 76881 or CPT® 76882) 	MRI is <i>NOT</i> needed for muscle belly strains/ muscle tears.
Occult/ Insufficiency Fracture	No	<ul style="list-style-type: none"> MRI Hip without contrast (CPT® 73721) OR CT Hip without contrast (CPT® 73700) 	See also: <u>Suspected Occult/ Stress/ Insufficiency Fracture/ Stress Reaction and Shin Splints (MS-5.2)</u> for occult and stress fractures of the hip
Avascular Necrosis (AVN) of the Femoral Head	No	<ul style="list-style-type: none"> See: <u>AVN (MS-4.1)</u> 	

After an initial plain x-ray has been obtained, and results are available to the provider, the following advanced imaging is indicated (as described in General Guidelines [MS-1.0])			
Condition (Individual's condition)	Conservative Treatment (Is failure of 6 weeks of provider-directed conservative treatment within the past 12 weeks with clinical re-evaluation required?) (Yes or No)	Advanced Imaging (The appropriate advanced imaging indicated for this condition. In some scenarios, advanced imaging may not be indicated.)	Comments (Additional comments related to the condition.)
Labral Tear	Yes	<ul style="list-style-type: none"> • MRI Hip with contrast (arthrogram) (CPT® 73722) OR • CT Hip with contrast (arthrogram) (CPT® 73701) OR • MRI Hip without contrast (CPT® 73721) 	For surgery criteria, see: <u>Hip Surgery- Arthroscopic and Open Procedures (CMM-314)</u>

After an initial plain x-ray has been obtained, and results are available to the provider, the following advanced imaging is indicated (as described in General Guidelines [MS-1.0])			
Condition (Individual's condition)	Conservative Treatment (Is failure of 6 weeks of provider-directed conservative treatment within the past 12 weeks with clinical re-evaluation required?) (Yes or No)	Advanced Imaging (The appropriate advanced imaging indicated for this condition. In some scenarios, advanced imaging may not be indicated.)	Comments (Additional comments related to the condition.)
Femoroacetabular Impingement	Yes	<ul style="list-style-type: none"> For preoperative planning for femoroacetabular impingement: <ul style="list-style-type: none"> MRI Hip without contrast (CPT® 73721) OR MRI Hip with contrast (arthrogram) (CPT® 73722) <p>IN ADDITION TO:</p> <ul style="list-style-type: none"> CT Hip without contrast (CPT® 73700) OR CT Pelvis without contrast (CPT® 72192) 	For surgery criteria, see: <u>Hip Surgery- Arthroscopic and Open Procedures (CMM-314)</u>
Piriformis Syndrome	NA	<ul style="list-style-type: none"> This condition is imaged according to the criteria found in the Peripheral Nerve Disorder Guidelines. See <u>Focal Neuropathy (PN-2)</u> in the Peripheral Nerve Disorders Imaging Guidelines 	

After an initial plain x-ray has been obtained, and results are available to the provider, the following advanced imaging is indicated (as described in General Guidelines [MS-1.0])			
Condition (Individual's condition)	Conservative Treatment (Is failure of 6 weeks of provider-directed conservative treatment within the past 12 weeks with clinical re-evaluation required?) (Yes or No)	Advanced Imaging (The appropriate advanced imaging indicated for this condition. In some scenarios, advanced imaging may not be indicated.)	Comments (Additional comments related to the condition.)
Post-Operative	Yes	<ul style="list-style-type: none"> Symptomatic individuals following surgery for labral tears and femoroacetabular impingement: <ul style="list-style-type: none"> MRI Hip with contrast (arthrogram) (CPT® 73722) Symptomatic individuals following surgery for hip fracture and/or hip avascular necrosis: <ul style="list-style-type: none"> CT Hip without contrast (CPT® 73700) OR MRI Hip without contrast (CPT® 73721) 	
Preoperative Hip Replacement Surgery	Yes	<ul style="list-style-type: none"> CT Hip without contrast (CPT® 73700) or CT Pelvis without contrast (CPT® 72192) for preoperative planning prior to hip replacement when congenital or post-traumatic deformities exist 	<p>See also: <u>Osteoarthritis (MS-12)</u></p> <p>For surgery criteria, see: <u>Hip Arthroplasty-Total and Partial (CMM-313)</u></p>

After an initial plain x-ray has been obtained, and results are available to the provider, the following advanced imaging is indicated (as described in General Guidelines [MS-1.0])			
Condition (Individual's condition)	Conservative Treatment (Is failure of 6 weeks of provider-directed conservative treatment within the past 12 weeks with clinical re-evaluation required?) (Yes or No)	Advanced Imaging (The appropriate advanced imaging indicated for this condition. In some scenarios, advanced imaging may not be indicated.)	Comments (Additional comments related to the condition.)
Post-Operative Hip Replacement Surgery	No*	<ul style="list-style-type: none"> For suspected aseptic loosening of hip replacement when recent plain x-ray is nondiagnostic: <ul style="list-style-type: none"> CT Hip without contrast (CPT® 73700) OR Bone scan (CPT® 78315) OR Distribution Of Radiopharmaceutical Agent SPECT (CPT® 78803 or CPT® 78831) OR Hybrid SPECT/CT (CPT® 78830) 	See: <u>Post-Operative Joint Replacement Surgery (MS-16)</u>

After an initial plain x-ray has been obtained, and results are available to the provider, the following advanced imaging is indicated (as described in General Guidelines [MS-1.0])			
Condition (Individual's condition)	Conservative Treatment (Is failure of 6 weeks of provider-directed conservative treatment within the past 12 weeks with clinical re-evaluation required?) (Yes or No)	Advanced Imaging (The appropriate advanced imaging indicated for this condition. In some scenarios, advanced imaging may not be indicated.)	Comments (Additional comments related to the condition.)
Post-Operative Hip Replacement Surgery	No*	<ul style="list-style-type: none"> • For suspected infection with negative or inconclusive joint aspiration culture: <ul style="list-style-type: none"> ○ MRI Hip without contrast (CPT® 73721) OR ○ MRI Hip without and with contrast (CPT® 73723) OR ○ CT Hip with contrast (CPT® 73701) OR ○ US Hip (CPT® 76881 or CPT® 76882) OR See also: <u>Nuclear Medicine (MS-28)</u> 	See: <u>Post-Operative Joint Replacement Surgery (MS-16)</u>

After an initial plain x-ray has been obtained, and results are available to the provider, the following advanced imaging is indicated (as described in General Guidelines [MS-1.0])			
Condition (Individual's condition)	Conservative Treatment (Is failure of 6 weeks of provider-directed conservative treatment within the past 12 weeks with clinical re-evaluation required?) (Yes or No)	Advanced Imaging (The appropriate advanced imaging indicated for this condition. In some scenarios, advanced imaging may not be indicated.)	Comments (Additional comments related to the condition.)
Post-Operative Hip Replacement Surgery	No*	<ul style="list-style-type: none"> For suspicion of a periprosthetic fracture when recent plain x-ray is nondiagnostic: <ul style="list-style-type: none"> CT Hip without contrast (CPT® 73700) OR Bone scan (CPT® 78315) OR Distribution Of Radiopharmaceutical agent SPECT (CPT® 78803 or CPT® 78831) OR Hybrid SPECT/CT (CPT® 78830) 	See: <u>Post-Operative Joint Replacement Surgery (MS-16)</u>

After an initial plain x-ray has been obtained, and results are available to the provider, the following advanced imaging is indicated (as described in General Guidelines [MS-1.0])			
Condition (Individual's condition)	Conservative Treatment (Is failure of 6 weeks of provider-directed conservative treatment within the past 12 weeks with clinical re-evaluation required?) (Yes or No)	Advanced Imaging (The appropriate advanced imaging indicated for this condition. In some scenarios, advanced imaging may not be indicated.)	Comments (Additional comments related to the condition.)
Post-Operative Hip Replacement Surgery	No*	<ul style="list-style-type: none"> • To evaluate component malposition or heterotopic bone after plain x-ray: <ul style="list-style-type: none"> ○ CT Hip without contrast (CPT® 73700) • For possible nerve injury: <ul style="list-style-type: none"> ○ MRI Hip without contrast (CPT® 73721) • For suspected tendinitis/bursitis, abductor injury, or other soft tissue abnormality (*requires conservative treatment): <ul style="list-style-type: none"> ○ MRI Hip without contrast (CPT® 73721) OR ○ US Hip (CPT® 76881 or CPT® 76882) 	See: <u>Post-Operative Joint Replacement Surgery (MS-16)</u>

References (MS-24)

v1.0.2024

1. Greene WB (Ed.). *Essentials of Musculoskeletal Care*. 2nd Ed. Rosemont, IL, American Academy of Orthopaedic Surgeons, 2001.
2. Manek NJ and Lane NE. Osteoarthritis: Current concepts in diagnosis and management. *Am Fam Physician*. 2000;61(6):1795-1804. <https://www.aafp.org/afp/2000/0315/p1795.html> .
3. Papadopoulos EC and Kahn SN. Piriformis syndrome and low back pain: a new classification and review of the literature. *Orthop Clin North Am*. 2004;35(1):65-71. doi:10.1016/S0030-5898(03)00105-6.
4. Reurink G, Sebastian, Bisselink JM, et al. Reliability and Validity of Diagnostic Acetabular Labral Lesions with Magnetic Resonance Arthrography. *J Bone Joint Surg A*. 2012;94(181):1643-1648. doi:10.2106/JBJS.K.01342.
5. Steinbach LS, Palmer WE, and Schweitzer ME. Special Focus Session MR Arthrography1. *RadioGraphics*. 2002;22(5):1223-1246.
6. Redmond JM, Chen AW, and Domb BG. Greater Trochanteric Pain Syndrome. *J Am Acad Orthop Surg*. 2016;24(4):231-240. doi:10.5435/JAAOS-D-14-00406.
7. Center for Devices and Radiological Health. Metal-on-Metal Hip Implants - Information for Orthopaedic Surgeons. U S Food and Drug Administration Home Page.
8. Ward RJ, Weissman BN, Kransdorf MJ, et. al. Expert Panel on Musculoskeletal Imaging. ACR Appropriateness Criteria® Acute Hip Pain-Suspected Fracture. *Am Coll Radiol (ACR)*; Date of Origin: 2013. Revised: 2018. <https://acsearch.acr.org/docs/3082587/Narrative/> .
9. Weissman BN, Palestro CJ, Appel M, et. al. Expert Panel on Musculoskeletal Imaging. ACR Appropriateness Criteria® Imaging After Total Hip Arthroplasty. *Am Coll Radiol (ACR)*; Date of Origin: 1998. Last Review: 2023. <https://acsearch.acr.org/docs/3094200/Narrative/> .
10. Mintz DN, Roberts CC, Bencardino JT, et. al. Expert Panel on Musculoskeletal Imaging. ACR Appropriateness Criteria® Chronic Hip Pain. *Am Coll Radiol (ACR)*; Revised: 2016. <https://acsearch.acr.org/docs/69425/Narrative/> .
11. Murphey MD, Roberts CC, Bencardino JT, et. al. Expert Panel on Musculoskeletal Imaging. ACR Appropriateness Criteria® Osteonecrosis of the Hip. *Am Coll Radiol (ACR)*; Date of Origin: 1995. Revised: 2022. <https://acsearch.acr.org/docs/69420/Narrative/> .
12. Bencardino JT, Stone TJ, Roberts CC, et. al. Expert Panel on Musculoskeletal Imaging. ACR Appropriateness Criteria® Stress (Fatigue/Insufficiency) Fracture, Including Sacrum, Excluding Other Vertebrae. *Am Coll Radiol (ACR)*; Revised: 2016. <https://acsearch.acr.org/docs/69435/Narrative/> .
13. Verberne SJ, Raijmakers PG, and Temmerman OP. The Accuracy of Imaging Techniques in the Assessment of Periprosthetic Hip Infection. A Systematic Review and Meta-Analysis. *J Bone Joint Surg Am*. 2016;98(19):1638-45. doi:10.2106/JBJS.15.00898.
14. Shin AY, Morin WD, Gorman JD, et al. The superiority of magnetic resonance imaging in differentiating the cause of hip pain in endurance athletes. *Am J Sports Med*. 1996;24:168-76. doi:10.1177/036354659602400209.
15. Slocum KA, Gorman JD, Puckett ML, et al. Resolution of abnormal MR signal intensity in patients with stress fractures of the femoral neck. *AJR Am J Roentgenol*. 1997;168:1295-9. doi:10.2214/ajr.168.5.9129429.
16. Lee EY, Margherita AJ, Gierada DS, et al. MRI of Piriformis Syndrome. *American Journal of Roentgenology*. 2004;183:63-64. doi:10.2214/ajr.183.1.1830063.
17. Jankiewicz JJ, Hennrikus WL, and Houkom JA. The appearance of the piriformis muscle syndrome in computed tomography and magnetic resonance imaging: a case report and review of the literature. *Clin Orthop*. 1991;262:205-09.
18. Rossi P, Cardinali P, Serrao M, et al.. Magnetic resonance imaging findings in piriformis syndrome: a case report. *Arch Phys Med Rehabil*. 2001;82(4):519-21. doi:10.1053/apmr.2001.21971.
19. Heer ST, Callander JW, Kraeutler MJ, Mei-Dan O, Mulcahey MK. Hamstring Injuries. *The Journal of Bone and Joint Surgery*. 2019;101(9):843-853. doi:10.2106/jbjs.18.00261.
20. Beaman FD, von Herrmann PF, Kransdorf MJ, et. al. Expert Panel on Musculoskeletal Imaging. ACR Appropriateness Criteria® Suspected Osteomyelitis, Septic Arthritis, or Soft Tissue Infection (Excluding Spine and Diabetic Foot). *Am Coll Radiol (ACR)*; Date of Origin: 2016. Revised: 2022. <https://acsearch.acr.org/docs/3094201/Narrative/> .

Knee (MS-25)

Guideline

Knee (MS-25)

References (MS-25)

Knee (MS-25)

MS.KN.0025.A

v1.0.2024

After an initial plain x-ray has been obtained, and results are available to the provider, the following advanced imaging is indicated (as described in General Guidelines [MS-1.0])

Condition (Individual's condition)	Conservative Treatment (Is failure of 6 weeks of provider-directed conservative treatment within the past 12 weeks with clinical re-evaluation required?) (Yes or No)	Advanced imaging (The appropriate advanced imaging indicated for this condition. In some scenarios, advanced imaging may not be indicated.)	Comments (Additional comments related to the condition.)
General Knee Pain	Yes	<ul style="list-style-type: none"> MRI Knee without contrast (CPT® 73721) OR US Knee (CPT® 76881 or CPT® 76882) 	
Symptomatic Loose Bodies	No	<ul style="list-style-type: none"> MRI Knee without contrast (CPT® 73721) CT Knee with contrast (arthrogram) (CPT® 73701) if MRI cannot be performed 	
Tendonitis	Yes	<ul style="list-style-type: none"> MRI Knee without contrast (CPT® 73721) OR US Knee (CPT® 76881 or CPT® 76882) 	
Complex Knee Fracture	No	<ul style="list-style-type: none"> MRI Knee without contrast (CPT® 73721) OR CT Knee without contrast (CPT® 73700) 	See also: Fractures (MS-5)

After an initial plain x-ray has been obtained, and results are available to the provider, the following advanced imaging is indicated (as described in General Guidelines [MS-1.0])			
Condition (Individual's condition)	Conservative Treatment (Is failure of 6 weeks of provider-directed conservative treatment within the past 12 weeks with clinical re-evaluation required?) (Yes or No)	Advanced imaging (The appropriate advanced imaging indicated for this condition. In some scenarios, advanced imaging may not be indicated.)	Comments (Additional comments related to the condition.)
Meniscus Tear	Yes*	<ul style="list-style-type: none"> MRI Knee without contrast (CPT® 73721) OR CT Knee with contrast (arthrogram) (CPT® 73701) if MRI cannot be performed <p>*Conservative treatment is not required if at least 2 of following 4 criteria are met:</p> <ol style="list-style-type: none"> 1) Positive McMurray's, positive Thessaly, or positive Apley's Compression Test 2) twisting or acute injury of the knee 3) locked knee/inability to fully extend the knee on exam in comparison to the opposite knee 4) knee effusion <ul style="list-style-type: none"> MRI Knee without contrast (CPT® 73721) for clinical suspicion of a symptomatic degenerative meniscus tear in an individual with osteoarthritis following conservative treatment 	For surgery criteria, see: <u>Knee Surgery-Arthroscopic and Open Procedures (CMM-312)</u>

After an initial plain x-ray has been obtained, and results are available to the provider, the following advanced imaging is indicated (as described in [General Guidelines \[MS-1.0\]](#))

Condition (Individual's condition)	Conservative Treatment (Is failure of 6 weeks of provider-directed conservative treatment within the past 12 weeks with clinical re-evaluation required?) (Yes or No)	Advanced imaging (The appropriate advanced imaging indicated for this condition. In some scenarios, advanced imaging may not be indicated.)	Comments (Additional comments related to the condition.)
Ligament Tear	Yes*	<ul style="list-style-type: none"> • MRI Knee without contrast (CPT® 73721) <p>*Conservative treatment is not required if any of the following signs are positive in comparison to the opposite knee:</p> <ul style="list-style-type: none"> • Anterior drawer • Lachman • Pivot shift • Posterior drawer • Posterior sag • Valgus stress • Varus stress 	For surgery criteria, see: Knee Surgery-Arthroscopic and Open Procedures (CMM-312)

After an initial plain x-ray has been obtained, and results are available to the provider, the following advanced imaging is indicated (as described in General Guidelines [MS-1.0])			
Condition (Individual's condition)	Conservative Treatment (Is failure of 6 weeks of provider-directed conservative treatment within the past 12 weeks with clinical re-evaluation required?) (Yes or No)	Advanced imaging (The appropriate advanced imaging indicated for this condition. In some scenarios, advanced imaging may not be indicated.)	Comments (Additional comments related to the condition.)
Knee Joint Dislocation	No	<ul style="list-style-type: none"> Following significant trauma to evaluate for ligament and vascular injury: <ul style="list-style-type: none"> MRI Knee without contrast (CPT® 73721) AND <i>EITHER</i> MR Angiography lower extremity without and with contrast (CPT® 73725) OR CT Angiography lower extremity without and with contrast (CPT® 73706) 	
Patellar Dislocation/ Subluxation	No	<ul style="list-style-type: none"> MRI Knee without contrast (CPT® 73721) OR CT Knee without contrast (CPT® 73700) when there is an acute knee injury, consideration of surgery, AND concern for osteochondral fracture or loose osteochondral fracture fragment 	For surgery criteria, see: <u>Knee Surgery- Arthroscopic and Open Procedures (CMM-312)</u>

After an initial plain x-ray has been obtained, and results are available to the provider, the following advanced imaging is indicated (as described in General Guidelines [MS-1.0])			
Condition (Individual's condition)	Conservative Treatment (Is failure of 6 weeks of provider-directed conservative treatment within the past 12 weeks with clinical re-evaluation required?) (Yes or No)	Advanced imaging (The appropriate advanced imaging indicated for this condition. In some scenarios, advanced imaging may not be indicated.)	Comments (Additional comments related to the condition.)
Recurrent Patellar Instability	Yes	<ul style="list-style-type: none"> MRI Knee without contrast (CPT® 73721) OR CT Knee without contrast (CPT® 73700) if consideration for surgery 	For surgery criteria, see: <u>Knee Surgery-Arthroscopic and Open Procedures (CMM-312)</u>
Patellofemoral Pain Syndrome/ Anterior Knee Pain/ Tracking Disorder	Yes	<ul style="list-style-type: none"> MRI Knee without contrast (CPT® 73721) OR CT Knee without contrast (CPT® 73700) if consideration for surgery 	

After an initial plain x-ray has been obtained, and results are available to the provider, the following advanced imaging is indicated (as described in General Guidelines [MS-1.0])			
Condition (Individual's condition)	Conservative Treatment (Is failure of 6 weeks of provider-directed conservative treatment within the past 12 weeks with clinical re-evaluation required?) (Yes or No)	Advanced imaging (The appropriate advanced imaging indicated for this condition. In some scenarios, advanced imaging may not be indicated.)	Comments (Additional comments related to the condition.)
Suspected Osteochondral Injury	No	<ul style="list-style-type: none"> If plain x-rays are negative and an osteochondral fracture is still suspected: <ul style="list-style-type: none"> MRI Knee without contrast (CPT® 73721) OR MRI Knee with contrast (arthrogram) (CPT® 73722) OR CT Knee with contrast (arthrogram) (CPT® 73701) 	<p>See: <u>Chondral/ Osteochondral Lesions (MS-13)</u> for other osteochondral injury scenarios.</p> <p>For surgery criteria, see: <u>Knee Surgery- Arthroscopic and Open Procedures (CMM-312)</u></p>
Avascular Necrosis (AVN) of the Distal Femur	No	<ul style="list-style-type: none"> See: <u>AVN (MS-4.1)</u> 	

After an initial plain x-ray has been obtained, and results are available to the provider, the following advanced imaging is indicated (as described in General Guidelines [MS-1.0])			
Condition (Individual's condition)	Conservative Treatment (Is failure of 6 weeks of provider-directed conservative treatment within the past 12 weeks with clinical re-evaluation required?) (Yes or No)	Advanced imaging (The appropriate advanced imaging indicated for this condition. In some scenarios, advanced imaging may not be indicated.)	Comments (Additional comments related to the condition.)
Baker's Cyst (Popliteal Cyst)	Yes	<ul style="list-style-type: none"> US Knee (CPT® 76881 or CPT® 76882) is the initial imaging study MRI Knee without contrast (CPT® 73721) for preoperative planning 	See also: Acute Limb Swelling (PVD-12) in the Peripheral Vascular Disease Imaging Guidelines
Plica (Symptomatic Synovial Plica/ Medial Synovial Shelf)	Yes	<ul style="list-style-type: none"> MRI Knee without contrast (CPT® 73721) 	
Hemarthrosis	No	<ul style="list-style-type: none"> MRI Knee without contrast (CPT® 73721) for clinical suspicion of cruciate ligament tear (requires a positive objective sign for ACL/PCL tear) or patellar dislocation (requires a positive apprehension sign) CT Knee without contrast (CPT® 73700) for clinical suspicion of non-displaced intra-articular fracture 	

After an initial plain x-ray has been obtained, and results are available to the provider, the following advanced imaging is indicated (as described in General Guidelines [MS-1.0])			
Condition (Individual's condition)	Conservative Treatment (Is failure of 6 weeks of provider-directed conservative treatment within the past 12 weeks with clinical re-evaluation required?) (Yes or No)	Advanced imaging (The appropriate advanced imaging indicated for this condition. In some scenarios, advanced imaging may not be indicated.)	Comments (Additional comments related to the condition.)
Complete Rupture of the Distal Quadriceps Tendon or Patellar Ligament/ Tendon	No	<ul style="list-style-type: none"> For preoperative planning: <ul style="list-style-type: none"> MRI Knee without contrast (CPT® 73721) OR US Knee (CPT® 76881 or CPT® 76882) 	
Partial Tendon Rupture	No	<ul style="list-style-type: none"> For a suspected partial tendon rupture of a specific named tendon not otherwise specified: <ul style="list-style-type: none"> MRI Knee without contrast (CPT® 73721) OR US Knee (CPT® 76881 or CPT® 76882) 	MRI is <i>NOT</i> needed for muscle belly strains/ muscle tears.
Complete Rupture – Tear of a Specific Named Tendon	No	<ul style="list-style-type: none"> For preoperative planning: <ul style="list-style-type: none"> MRI Knee without contrast (CPT® 73721) OR US Knee (CPT® 76881 or CPT® 76882) 	

After an initial plain x-ray has been obtained, and results are available to the provider, the following advanced imaging is indicated (as described in General Guidelines [MS-1.0])			
Condition (Individual's condition)	Conservative Treatment (Is failure of 6 weeks of provider-directed conservative treatment within the past 12 weeks with clinical re-evaluation required?) (Yes or No)	Advanced imaging (The appropriate advanced imaging indicated for this condition. In some scenarios, advanced imaging may not be indicated.)	Comments (Additional comments related to the condition.)
Post-Operative	Yes	<ul style="list-style-type: none"> In symptomatic individuals following surgery for meniscus tears and reconstruction of the anterior cruciate ligament: <ul style="list-style-type: none"> MRI Knee with contrast (arthrogram) (CPT® 73722) OR MRI Knee without contrast (CPT® 73721) In symptomatic individuals following surgery for fracture/dislocation: <ul style="list-style-type: none"> CT Knee without contrast (CPT® 73700) 	
Preoperative Knee Replacement Surgery	Yes	<ul style="list-style-type: none"> CT Knee without contrast (CPT® 73700) for preoperative planning prior to knee replacement when congenital or post-traumatic deformities exist of the patella, distal femur and/ or proximal tibia 	<p>See also:</p> <p><u>Osteoarthritis (MS-12)</u></p> <p>For surgery criteria, see:</p> <p><u>Knee Arthroplasty- Total and Partial (CMM-311)</u></p>

After an initial plain x-ray has been obtained, and results are available to the provider, the following advanced imaging is indicated (as described in General Guidelines [MS-1.0])			
Condition (Individual's condition)	Conservative Treatment (Is failure of 6 weeks of provider-directed conservative treatment within the past 12 weeks with clinical re-evaluation required?) (Yes or No)	Advanced imaging (The appropriate advanced imaging indicated for this condition. In some scenarios, advanced imaging may not be indicated.)	Comments (Additional comments related to the condition.)
Post-Operative Knee Replacement Surgery	No*	<ul style="list-style-type: none"> For suspected aseptic loosening when recent plain x-ray is nondiagnostic: <ul style="list-style-type: none"> CT Knee without contrast (CPT® 73700) OR MRI Knee without contrast (CPT® 73721) OR See also: <u>Nuclear Medicine (MS-28)</u> For suspected infection with negative or inconclusive joint aspiration culture: <ul style="list-style-type: none"> MRI Knee without contrast (CPT® 73721) OR 	See also: <u>Post-Operative Joint Replacement Surgery (MS-16)</u>

After an initial plain x-ray has been obtained, and results are available to the provider, the following advanced imaging is indicated (as described in General Guidelines [MS-1.0])			
Condition (Individual's condition)	Conservative Treatment (Is failure of 6 weeks of provider-directed conservative treatment within the past 12 weeks with clinical re-evaluation required?) (Yes or No)	Advanced imaging (The appropriate advanced imaging indicated for this condition. In some scenarios, advanced imaging may not be indicated.)	Comments (Additional comments related to the condition.)
Post-Operative Knee Replacement Surgery	No*	<ul style="list-style-type: none"> MRI Knee without and with contrast (CPT® 73723) OR CT Knee with contrast (CPT® 73701) OR US Knee (CPT® 76881 or 76882) See also: <u>Nuclear Medicine (MS-28)</u> Following plain x-ray for suspected periprosthetic fracture: <ul style="list-style-type: none"> CT Knee without contrast (CPT® 73700) OR MRI Knee without contrast (CPT® 73721) 3-phase bone scan (CPT®78315) 	See also: <u>Post-Operative Joint Replacement Surgery (MS-16)</u>

After an initial plain x-ray has been obtained, and results are available to the provider, the following advanced imaging is indicated (as described in General Guidelines [MS-1.0])			
Condition (Individual's condition)	Conservative Treatment (Is failure of 6 weeks of provider-directed conservative treatment within the past 12 weeks with clinical re-evaluation required?) (Yes or No)	Advanced imaging (The appropriate advanced imaging indicated for this condition. In some scenarios, advanced imaging may not be indicated.)	Comments (Additional comments related to the condition.)
Post-Operative Knee Replacement Surgery	No*	<ul style="list-style-type: none"> For suspected osteolysis or component instability, rotation, or wear: <ul style="list-style-type: none"> CT Knee without contrast (CPT® 73700) OR MRI Knee without contrast (CPT® 73721) For suspected periprosthetic soft tissue abnormality unrelated to infection (e.g., tendinopathy, arthrofibrosis, patellar clunk syndrome, impingement of nerves or other soft tissue) *requires conservative treatment: <ul style="list-style-type: none"> MRI Knee without contrast (CPT® 73721) OR US Knee (CPT® 76881 or CPT® 76882) 	See also: <u>Post-Operative Joint Replacement Surgery (MS-16)</u>

References (MS-25)

v1.0.2024

1. Harrison BK, Abell BE, Gibson TW. The Thessaly test for detection of meniscal tears: validation of a new physical examination technique for primary care medicine. *Clin J Sport Med*. 2009;19:9-12. doi:10.1097/JSM.0b013e31818f1689.
2. Landewé RBM, Günther KP, Lukas C, et al. EULAR/EFFORT recommendations for the diagnosis and initial management of patients with acute or recent onset swelling of the knee. *Ann Rheum Dis*. 2010;69:12-19. doi:10.1136/ard.2008.104406.
3. Johnson MW. Acute knee effusions: a systematic approach to diagnosis. *Am Fam Physician*. 2000;61(8):2391-2400. <https://www.aafp.org/afp/2000/0415/p2391.html>.
4. ACR Appropriateness Criteria, Nontraumatic knee pain, 2008.
5. Sung-Jae Kim, Byoung-Yoon Hwang, Choi DH, et al. *J Bone Joint Surg A*. 2012;94(16):e118 1-7.
6. Kannus P, Järvinen M. Nonoperative treatment of acute knee ligament injuries. A review with special reference to indications and methods. *Sports Med*. 1990;9(4):244-260. doi:10.2165/00007256-199009040-00005.
7. Manek NJ and Lane NE. Osteoarthritis: Current concepts in diagnosis and management. *Am Fam Physician*. 2000;61(6):1795-1804. <https://www.aafp.org/afp/2000/0315/p1795.html>.
8. Griffin LY. *Essentials of Musculoskeletal Care*. 3rd edition. Rosemont, IL: American Academy of Orthopaedic Surgeons; 2005:84, 541-545.
9. Lee IS, Choi JA, Kim TK, et al. Reliability analysis of 16-MDCT in preoperative evaluation of total knee arthroplasty and comparison with intraoperative measurements. *Am J Roentgenol*. 2006;186(6):1778-1782. doi:10.2214/AJR.05.1191.
10. Morrissey RT, Weinstein SL (Eds.). *Lovell and Winter's Pediatric Orthopaedics*. 6th Ed. Philadelphia, PA: Lippincott Williams and Wilkins; 2005:1413.
11. Woolson ST, Harris AHS, Wagner DW, et al; Component alignment during total knee arthroplasty with use of standard or custom instrumentation: A Randomized Clinical Trial Using Computed Tomography for Postoperative Alignment Measurement. *Journal of Bone and Joint Surgery*. 2014;96:366-372. doi:10.2106/JBJS.L.01722.
12. Vance K, Meredick R, Schweitzer ME, et al. Magnetic resonance imaging of the postoperative meniscus. *Arthroscopy*. 2009;25:522-30. doi:10.1016/j.arthro.2008.08.013.
13. Magee T, Shapiro M, and Williams D. Prevalence of meniscal radial tears of the knee revealed by MRI after surgery. *Am J Roentgenol*. 2004;184:931-936. doi:10.2214/ajr.182.4.1820931.
14. Meyers AB, Haims AH, Menn K, et al. Imaging of anterior cruciate ligament repair and its complications. *Am J Roentgenol*. 2010;194:476-484. doi:10.2214/AJR.09.3200.
15. Tuite, MJ, Kransdorf MJ, Beaman FD, et. al. Expert Panel on Musculoskeletal Imaging. ACR Appropriateness Criteria® Acute Trauma to the Knee. *Am Coll Radiol (ACR)*; Date of Origin: 1998. Revised: 2019. <https://acsearch.acr.org/docs/69419/Narrative/>.
16. Bennett DL, Nelson JW, Weissman BN, et. al. Expert Panel on Musculoskeletal Imaging. ACR Appropriateness Criteria® Nontraumatic Knee Pain. *Am Coll Radiol (ACR)*; Date of Origin: 1995. Revised: 2018. <https://acsearch.acr.org/docs/69432/Narrative/>.
17. Zoga AC, Weissman BN, Kransdorf MJ, et. al. Expert Panel on Musculoskeletal Imaging. ACR Appropriateness Criteria® Soft-Tissue Masses. *Am Coll Radiol (ACR)*; Date of Origin: 1995. Revised: 2017. <https://acsearch.acr.org/docs/69434/Narrative/>.
18. Hochman MG, Melenevsky YV, Metter DF, et. al. Expert Panel on Musculoskeletal Imaging. ACR Appropriateness Criteria® Imaging After Total Knee Arthroplasty. *Am Coll Radiol (ACR)*; Revised: 2023. Available at: <https://acsearch.acr.org/docs/69430/Narrative/>.
19. Kurosaka M, Yagi M, Yoshiya S, Muratsu H, Mizuno K. Efficacy of the axially loaded pivot shift test for the diagnosis of a meniscal tear. *Int Orthop*. 1999;23:271-274. doi:10.1007/s002640050369.
20. Fowler PJ, Lubliner JA. The predictive value of five clinical signs in the evaluation of meniscal pathology. *Arthroscopy*. 1989;5(3):184-186. doi:10.1016/0749-8063(89)90168-0.
21. Beaman FD, von Herrmann PF, Kransdorf MJ, et. al. Expert Panel on Musculoskeletal Imaging. ACR Appropriateness Criteria® Suspected Osteomyelitis, Septic Arthritis, or Soft Tissue Infection (Excluding Spine and Diabetic Foot). *Am Coll Radiol (ACR)*; Date of Origin: 2016. Revised: 2022. <https://acsearch.acr.org/docs/3094201/Narrative/>.
22. Pauyo T, Park JP, Bozzo I, Bernstein M. Patellofemoral instability part I: evaluation and nonsurgical treatment. *J Am Acad Orthop Surg*. 2022;30:e1431-e1442. doi:10.5435/JAAOS-D-22-00254.

Ankle (MS-26)

Guideline

Ankle (MS-26)

References (MS-26)

Ankle (MS-26)

MS.AL.0026.A

v1.0.2024

After an initial plain x-ray has been obtained, and results are available to the provider, the following advanced imaging is indicated (as described in General Guidelines [MS-1.0])

Condition (Individual's condition)	Conservative Treatment (Is failure of 6 weeks of provider-directed conservative treatment within the past 12 weeks with clinical re-evaluation required?) (Yes or No)	Advanced Imaging (The appropriate advanced imaging indicated for this condition. In some scenarios, advanced imaging may not be indicated.)	Comments (Additional comments related to the condition.)
General Ankle Pain	Yes	<ul style="list-style-type: none"> MRI Ankle without contrast (CPT® 73721) OR US Ankle (CPT® 76881 or CPT® 76882) 	
Symptomatic Loose Bodies	No	<ul style="list-style-type: none"> MRI Ankle without contrast (CPT® 73721) 	
Complex Fracture	No	<ul style="list-style-type: none"> MRI Ankle without contrast (CPT® 73721) OR CT Ankle without contrast (CPT® 73700) 	
Ankle Sprain, Including Avulsion Fracture	Yes	<ul style="list-style-type: none"> MRI Ankle Without Contrast (CPT® 73721) OR CT Ankle without contrast (CPT® 73700) 	
High Ankle Sprain (Syndesmosis Injury)	No	<ul style="list-style-type: none"> MRI Ankle without contrast (CPT® 73721) OR CT Ankle without contrast (CPT® 73700) 	

After an initial plain x-ray has been obtained, and results are available to the provider, the following advanced imaging is indicated (as described in General Guidelines [MS-1.0])			
Condition (Individual's condition)	Conservative Treatment (Is failure of 6 weeks of provider-directed conservative treatment within the past 12 weeks with clinical re-evaluation required?) (Yes or No)	Advanced Imaging (The appropriate advanced imaging indicated for this condition. In some scenarios, advanced imaging may not be indicated.)	Comments (Additional comments related to the condition.)
Suspected Osteochondral Injury	No	<ul style="list-style-type: none"> If plain x-rays are negative and an osteochondral fracture is still suspected, ONE of the following: <ul style="list-style-type: none"> MRI Ankle without contrast (CPT® 73721) OR CT Ankle without contrast (CPT® 73700) 	See: <u>Chondral/ Osteochondral Lesions (MS-13)</u> for other osteochondral injury scenarios
Avascular Necrosis (AVN) of the Talus	No	<ul style="list-style-type: none"> See: <u>AVN (MS-4.1)</u> 	
Anterior Impingement Anterior-Lateral Impingement Posterior Impingement (e.g., Os Trigonum Syndrome)	Yes	<ul style="list-style-type: none"> MRI Ankle with contrast (arthrogram) (CPT® 73722) OR CT Ankle with contrast (arthrogram) (CPT® 73701) OR MRI Ankle without contrast (CPT® 73721) 	

After an initial plain x-ray has been obtained, and results are available to the provider, the following advanced imaging is indicated (as described in General Guidelines [MS-1.0])			
Condition (Individual's condition)	Conservative Treatment (Is failure of 6 weeks of provider-directed conservative treatment within the past 12 weeks with clinical re-evaluation required?) (Yes or No)	Advanced Imaging (The appropriate advanced imaging indicated for this condition. In some scenarios, advanced imaging may not be indicated.)	Comments (Additional comments related to the condition.)
Tendonitis	Yes	<ul style="list-style-type: none"> For suspected posterior tibial dysfunction, peroneal tendon or subluxation, Achilles tendonitis: <ul style="list-style-type: none"> MRI Ankle without contrast (CPT® 73721) OR US Ankle (CPT® 76881 or CPT® 76882) 	
Complete Rupture of Achilles Tendon	No	<ul style="list-style-type: none"> For preoperative evaluation: <ul style="list-style-type: none"> MRI Ankle without contrast (CPT® 73721) OR US Ankle (CPT® 76881 or CPT® 76882) 	
Complete Rupture -Tear of a Specific Named Tendon	No	<ul style="list-style-type: none"> For preoperative planning: <ul style="list-style-type: none"> MRI Ankle without contrast (CPT® 73721) OR US Ankle (CPT® 76881 or CPT® 76882) 	

After an initial plain x-ray has been obtained, and results are available to the provider, the following advanced imaging is indicated (as described in General Guidelines [MS-1.0])			
Condition (Individual's condition)	Conservative Treatment (Is failure of 6 weeks of provider-directed conservative treatment within the past 12 weeks with clinical re-evaluation required?) (Yes or No)	Advanced Imaging (The appropriate advanced imaging indicated for this condition. In some scenarios, advanced imaging may not be indicated.)	Comments (Additional comments related to the condition.)
Partial Tendon Rupture	No	<ul style="list-style-type: none"> For a suspected partial tendon rupture of a specific named tendon not otherwise specified: <ul style="list-style-type: none"> MRI Ankle without contrast (CPT® 73721) OR US Ankle (CPT® 76881 or CPT® 76882) 	MRI is <i>NOT</i> needed for muscle belly strains/ muscle tears.
Instability	Yes	<ul style="list-style-type: none"> For preoperative evaluation: <ul style="list-style-type: none"> MRI Ankle without contrast (CPT® 73721) OR MRI Ankle with contrast (arthrogram) (CPT® 73722) 	
Charcot Ankle	Yes	<ul style="list-style-type: none"> MRI Ankle without contrast (CPT® 73721) 	

After an initial plain x-ray has been obtained, and results are available to the provider, the following advanced imaging is indicated (as described in General Guidelines [MS-1.0])			
Condition (Individual's condition)	Conservative Treatment (Is failure of 6 weeks of provider-directed conservative treatment within the past 12 weeks with clinical re-evaluation required?) (Yes or No)	Advanced Imaging (The appropriate advanced imaging indicated for this condition. In some scenarios, advanced imaging may not be indicated.)	Comments (Additional comments related to the condition.)
Post-Operative	Yes	<ul style="list-style-type: none"> In symptomatic individuals following surgery for ligament/tendon injuries, <i>one of the following</i>: <ul style="list-style-type: none"> MRI Ankle without contrast (CPT® 73721) OR US Ankle (CPT® 76881 or CPT® 76882) For symptomatic individuals following surgery for complex fractures: <ul style="list-style-type: none"> CT Ankle without contrast (CPT® 73700) 	
Preoperative Ankle Replacement Surgery	Yes	<ul style="list-style-type: none"> CT Ankle without contrast (CPT® 73700) for preoperative planning prior to ankle replacement when congenital or post-traumatic deformities exist 	See: <u>Osteoarthritis (MS-12)</u>

After an initial plain x-ray has been obtained, and results are available to the provider, the following advanced imaging is indicated (as described in General Guidelines [MS-1.0])			
Condition (Individual's condition)	Conservative Treatment (Is failure of 6 weeks of provider-directed conservative treatment within the past 12 weeks with clinical re-evaluation required?) (Yes or No)	Advanced Imaging (The appropriate advanced imaging indicated for this condition. In some scenarios, advanced imaging may not be indicated.)	Comments (Additional comments related to the condition.)
Post-Operative Ankle Replacement Surgery	No	<ul style="list-style-type: none"> For suspected aseptic loosening or periprosthetic fracture when recent plain x-ray is nondiagnostic: <ul style="list-style-type: none"> CT Ankle without contrast (CPT® 73700) OR Bone scan (CPT® 78315, 78300, or 78306) OR Distribution Of Radiopharmaceutical Agent SPECT (CPT® 78803 or 78831) OR Hybrid SPECT/CT (CPT® 78830) 	See: <u>Post-Operative Joint Replacement Surgery (MS-16)</u>

After an initial plain x-ray has been obtained, and results are available to the provider, the following advanced imaging is indicated (as described in General Guidelines [MS-1.0])			
Condition (Individual's condition)	Conservative Treatment (Is failure of 6 weeks of provider-directed conservative treatment within the past 12 weeks with clinical re-evaluation required?) (Yes or No)	Advanced Imaging (The appropriate advanced imaging indicated for this condition. In some scenarios, advanced imaging may not be indicated.)	Comments (Additional comments related to the condition.)
Post-Operative Ankle Replacement Surgery	No	<ul style="list-style-type: none"> • For suspected infection with negative or inconclusive joint aspiration culture: <ul style="list-style-type: none"> ○ MRI ankle without contrast (CPT® 73721) OR ○ MRI ankle without and with contrast (CPT® 73723) OR ○ CT ankle with contrast (CPT® 73701) OR ○ US ankle (CPT® 76881 or CPT® 76882) OR See also: <u>Nuclear Medicine (MS-28)</u> 	See: <u>Post-Operative Joint Replacement Surgery (MS-16)</u>

One Study/Area Only

In foot and ankle advanced imaging, studies are frequently ordered of both areas. This is unnecessary since ankle MRI will image from above the ankle to the mid-metatarsal area. **Only one CPT® code should be reported.**

References (MS-26)

v1.0.2024

1. Donovan A, Rosenberg ZS. MRI of ankle and lateral hindfoot impingement syndromes. *AJR*. 2010;195: 595-604.
2. Wolfe MW, Uhl TL, and McClusky LC. Management of ankle sprains. *Am Fam Physician* 2001;63(1):93-104. <https://www.aafp.org/afp/2001/0101/p93.html>.
3. Griffin LY. *Essentials of Musculoskeletal Care*. 3rd edition. Rosemont, IL: American Academy of Orthopaedic Surgeons; 2005:593-596; 606-609; 683.
4. Bergkvist D, Astrom I, Josefsson PO, et al. Acute Achilles Tendon Rupture: A Questionnaire Follow-up of 487 Patients. *J Bone Joint Surg Am*. 2012;94(13):1229-1233. doi:10.2106/JBJS.J.01601.
5. Hartgerink P, Fessell DP, Jacobson JA, et al. Full- versus partial-thickness Achilles tendon tears: sonographic accuracy and characterization in 26 cases with surgical correlation. *Radiology* 2001;220:406-412. doi: 10.1148/radiology.220.2.r01au41406.
6. Jones MP, Riaz JK, Smith RLC. Surgical Interventions for Treating Acute Achilles Tendon Rupture: Key Findings from a Recent Cochrane Review. *J Bone Joint Surg Am*. 2012;94(12):e88 1-6. doi:10.2106/jbjs.j.01829.
7. Vaseenon T, Amendola A. Update on anterior ankle impingement. *Current Reviews in Musculoskeletal Medicine*. 2012;5:140-150. doi:10.1007/s12178-012-9117-z.
8. Talusan PG, Toy J, Perez J, Milewski MD, et al. Anterior ankle impingement: diagnosis and treatment. *J Am Acad Orthop Surg*. 2014;22:333-339. doi:10.5435/JAAOS-22-05-333.
9. Nault ML, Kocher MS, Micheli LJ. Os Trigonum Syndrome. *J Am Acad Orthop Surg*. 2014;22:545-553. doi:10.5435/JAAOS-22-09-545.
10. Peace KAL, Jillier JC, Hulme A, et al. MRI features of posterior ankle impingement syndrome in ballet dancers: a review 25 cases. *Clinical Radiology*. 2004;59:1025-1033. doi:10.1016/j.crad.2004.02.010.
11. J Kane and R Zell. Achilles Tendon Rupture. Physician Resource Center. *American Orthopaedic Foot & Ankle Society*. Last reviewed July 2015.
12. Garras DN, et al. MRI is Unnecessary for Diagnosing Acute Achilles Tendon Ruptures. *Clinical Orthopaedics and Related Research*. 2012;470:2268–2273 Retrospective Analysis with finding. doi:10.1007/s11999-012-2355-y.
13. Mosher TJ, Kransdorf MJ, Adler R, et. al. Expert Panel on Musculoskeletal Imaging. ACR Appropriateness Criteria® Acute Trauma to the Ankle. *Am Coll Radiol (ACR)*; Date of Origin: 2013. Revised: 2020. <https://acsearch.acr.org/docs/69436/Narrative/>.
14. Luchs JS, Flug JA, Weissman BN, et. al. Expert Panel on Musculoskeletal Imaging. ACR Appropriateness Criteria® Chronic Ankle Pain. *Am Coll Radiol (ACR)*; Date of Origin: 1998. Revised: 2017. <https://acsearch.acr.org/docs/69422/Narrative/>.
15. Dodd A, Daniels TR. Charcot Neuroarthropathy of the Foot and Ankle. *J Bone Joint Surg Am*. 2018;100:696-711. doi:10.2106/JBJS.17.00785.
16. Beaman FD, von Herrmann PF, Kransdorf MJ, et. al. Expert Panel on Musculoskeletal Imaging. ACR Appropriateness Criteria® Suspected Osteomyelitis, Septic Arthritis, or Soft Tissue Infection (Excluding Spine and Diabetic Foot). *Am Coll Radiol (ACR)*; Date of Origin: 2016. Revised: 2022. <https://acsearch.acr.org/docs/3094201/Narrative/>.

Foot (MS-27)

Guideline

Foot (MS-27)

References (MS-27)

Foot (MS-27)

MS.FT.0027.A

v1.0.2024

After an initial plain x-ray has been obtained, and results are available to the provider, the following advanced imaging is indicated (as described in [General Guidelines \[MS-1.0\]](#))

Condition (Individual's condition)	Conservative Treatment (Is failure of 6 weeks of provider-directed conservative treatment within the past 12 weeks with clinical re-evaluation required?) (Yes or No)	Advanced imaging (The appropriate advanced imaging indicated for this condition. In some scenarios, advanced imaging may not be indicated.)	Comments (Additional comments related to the condition.)
General Foot Pain	Yes	<ul style="list-style-type: none"> MRI Foot without contrast (CPT® 73718) 	
Complex Fractures	No	<ul style="list-style-type: none"> CT Foot without contrast (CPT® 73700) 	
Plantar Plate Disorders, Including Turf Toe Injuries	Yes	<ul style="list-style-type: none"> MRI Foot without contrast (CPT® 73718) 	
Sesamoid Disorders	Yes	<ul style="list-style-type: none"> MRI Foot without contrast (CPT® 73718) OR CT Foot without contrast (CPT® 73700) 	
Lisfranc Tarsometatarsal Fracture or Dislocation	No	<ul style="list-style-type: none"> MRI Foot without contrast (CPT® 73718) OR CT Foot without contrast (CPT® 73700) 	

After an initial plain x-ray has been obtained, and results are available to the provider, the following advanced imaging is indicated (as described in General Guidelines [MS-1.0])			
Condition (Individual's condition)	Conservative Treatment (Is failure of 6 weeks of provider-directed conservative treatment within the past 12 weeks with clinical re-evaluation required?) (Yes or No)	Advanced imaging (The appropriate advanced imaging indicated for this condition. In some scenarios, advanced imaging may not be indicated.)	Comments (Additional comments related to the condition.)
Tarsal Navicular Stress/Occult Fracture	No	<ul style="list-style-type: none"> MRI Foot without contrast (CPT® 73718) Tc-99m bone scan foot (CPT® 78315) if MRI cannot be performed CT Foot without contrast (CPT® 73700) for follow-up of healing fractures 	See also: <u>Suspected Occult/ Stress/ Insufficiency Fracture/ Stress Reaction and Shin Splints (MS-5.2)</u>
Avascular Necrosis (AVN) of the Tarsal Navicular (Kohler Disease) or Metatarsal Head (Frieberg's Infraction)	No	<ul style="list-style-type: none"> See: <u>AVN (MS-4.1)</u> 	
Tendonitis	Yes	<ul style="list-style-type: none"> MRI Foot without contrast (CPT® 73718) OR US Foot (CPT® 76881 or CPT® 76882) 	

After an initial plain x-ray has been obtained, and results are available to the provider, the following advanced imaging is indicated (as described in General Guidelines [MS-1.0])			
Condition (Individual's condition)	Conservative Treatment (Is failure of 6 weeks of provider-directed conservative treatment within the past 12 weeks with clinical re-evaluation required?) (Yes or No)	Advanced imaging (The appropriate advanced imaging indicated for this condition. In some scenarios, advanced imaging may not be indicated.)	Comments (Additional comments related to the condition.)
Complete Rupture – Tear of a Specific Named Tendon	No	<ul style="list-style-type: none"> For preoperative planning: <ul style="list-style-type: none"> MRI Foot without contrast (CPT® 73718) OR US Foot (CPT® 76881 or CPT® 76882) 	
Partial Tendon Rupture	No	<ul style="list-style-type: none"> For a suspected partial tendon rupture of a specific named tendon not otherwise specified: <ul style="list-style-type: none"> MRI Foot without contrast (CPT® 73718) OR US Foot (CPT® 76881 or CPT® 76882) 	MRI is <i>NOT</i> needed for muscle belly strains/muscle tears.

After an initial plain x-ray has been obtained, and results are available to the provider, the following advanced imaging is indicated (as described in General Guidelines [MS-1.0])			
Condition (Individual's condition)	Conservative Treatment (Is failure of 6 weeks of provider-directed conservative treatment within the past 12 weeks with clinical re-evaluation required?) (Yes or No)	Advanced imaging (The appropriate advanced imaging indicated for this condition. In some scenarios, advanced imaging may not be indicated.)	Comments (Additional comments related to the condition.)
Morton's Neuroma	Yes	<ul style="list-style-type: none"> For preoperative planning: <ul style="list-style-type: none"> MRI Foot without contrast (CPT® 73718) OR MRI Foot without and with contrast (CPT® 73720) OR US Foot (CPT® 76881 or CPT® 76882) 	
Plantar Fasciitis	Yes*	<ul style="list-style-type: none"> For preoperative planning: <ul style="list-style-type: none"> MRI Foot without contrast (CPT® 73718) OR US Foot (CPT® 76881 or CPT® 76882) 	*Provider-directed conservative treatment must be for 6 months or more.
Suspected Plantar Fascia Rupture or Tear	Yes	<ul style="list-style-type: none"> MRI Foot without contrast (CPT® 73718) OR US Foot (CPT® 76881 or CPT® 76882) 	

After an initial plain x-ray has been obtained, and results are available to the provider, the following advanced imaging is indicated (as described in General Guidelines [MS-1.0])			
Condition (Individual's condition)	Conservative Treatment (Is failure of 6 weeks of provider-directed conservative treatment within the past 12 weeks with clinical re-evaluation required?) (Yes or No)	Advanced imaging (The appropriate advanced imaging indicated for this condition. In some scenarios, advanced imaging may not be indicated.)	Comments (Additional comments related to the condition.)
Diabetic Foot Infection	No	<ul style="list-style-type: none"> For suspected osteomyelitis or soft tissue infection as a complement to plain x-ray (both plain x-ray and MRI are indicated): <ul style="list-style-type: none"> MRI Foot without and with contrast (CPT® 73720) OR MRI Foot without contrast (CPT® 73718) 	See also: <u>Infection-General (MS-9.1)</u>
Tarsal Tunnel Syndrome including Baxter's Neuropathy	Yes	<ul style="list-style-type: none"> For preoperative planning if mass/lesion is suspected as etiology of entrapment: <ul style="list-style-type: none"> MRI Foot without contrast (CPT® 73718) OR US Foot (CPT® 76881 or CPT® 76882) 	

After an initial plain x-ray has been obtained, and results are available to the provider, the following advanced imaging is indicated (as described in General Guidelines [MS-1.0])			
Condition (Individual's condition)	Conservative Treatment (Is failure of 6 weeks of provider-directed conservative treatment within the past 12 weeks with clinical re-evaluation required?) (Yes or No)	Advanced imaging (The appropriate advanced imaging indicated for this condition. In some scenarios, advanced imaging may not be indicated.)	Comments (Additional comments related to the condition.)
Tarsal Coalition	Yes	<ul style="list-style-type: none"> For preoperative planning: <ul style="list-style-type: none"> MRI Ankle without contrast (CPT® 73721) OR CT Ankle without contrast (CPT® 73700) 	
Sinus Tarsi Syndrome	Yes	<ul style="list-style-type: none"> MRI Ankle without contrast (CPT® 73721) if diagnosis is unclear or for preoperative evaluation 	
Charcot Foot	Yes	<ul style="list-style-type: none"> MRI Foot without contrast (CPT® 73718) OR MRI Foot without and with contrast (CPT® 73720) 	
CRPS Type I	Yes	<ul style="list-style-type: none"> Triple phase bone scan (CPT® 78315) OR MRI Foot without contrast (CPT® 73718) 	

After an initial plain x-ray has been obtained, and results are available to the provider, the following advanced imaging is indicated (as described in General Guidelines [MS-1.0])			
Condition (Individual's condition)	Conservative Treatment (Is failure of 6 weeks of provider-directed conservative treatment within the past 12 weeks with clinical re-evaluation required?) (Yes or No)	Advanced imaging (The appropriate advanced imaging indicated for this condition. In some scenarios, advanced imaging may not be indicated.)	Comments (Additional comments related to the condition.)
Post-Operative	Yes	<ul style="list-style-type: none"> In symptomatic individuals following surgery for conditions including the tendons, ligaments, and plantar plate, ONE of the following: <ul style="list-style-type: none"> MRI Foot without contrast (CPT® 73718) OR US Foot (CPT® 76881 or CPT® 76882) In symptomatic individuals following surgery for complex fractures, sesamoid fractures, and subtalar arthrodesis: <ul style="list-style-type: none"> CT Foot without contrast (CPT® 73700) 	

One Study/Area Only

In foot and ankle advanced imaging, studies are frequently ordered of both areas. This is unnecessary since ankle MRI will image from above the ankle to the mid- metatarsal area. **Only one CPT® code should be reported.**

References (MS-27)

v1.0.2024

1. Griffin LY. *Essentials of Musculoskeletal Care*. 3rd edition. Rosemont, IL: American Academy of Orthopaedic Surgeons; 2005:619-622;667-671;681-684;697-699;700-702.
2. Needell S, Cutler J. Morton neuroma imaging. eMedicine, April 11, 2011
3. Morton's Neuroma. MDGuidelines™.
4. Berquist TH. *Radiology of the Foot and Ankle*. 2nd Ed. Philadelphia, Lippincott, 2000, pp.155-156.
5. Bouche R. Sinus Tarsi Syndrome. What is Sinus Tarsi Syndrome, Testing and Treatment. http://www.aapsm.org/sinus_tarsi_syndrome.html.
6. D Resnick. Internal Derangements of Joints 2006: Imaging-Arthroscopic Correlation. Washington, DC.Oct.31- Nov. 4, 2006.
7. Doty JF, Coughlin MJ. Metatarsophalangeal joint instability of the lesser toes and plantar plate deficiency. *J Am Acad Orthop Surg*. 2014;22(4):235-245. doi:10.5435/JAAOS-22-04-235.
8. Lareau CR, Sawyer GA, Wang JH, et al. Plantar and medial heel pain: diagnosis and management. *J Am Acad Orthop Surg*. 2014;22:372-380. doi:10.5435/JAAOS-22-06-372.
9. Sung, W, Weil L Jr, Weill LS Sr, et al. Diagnosis of plantar plate injury by magnetic resonance imaging with reference to Intraoperative findings. *Journal of Foot Ankle Surgery*. 2012;51(5):570-574. doi:10.1053/j.jfas.2012.05.009.
10. Bancroft LW, Kransdorf MJ, Adler R, et. al. Expert Panel on Musculoskeletal Imaging. ACR Appropriateness Criteria® Acute Trauma to the Foot. *Am Coll Radiol (ACR)*; Date of Origin: 2010. Revised: 2019. <https://acsearch.acr.org/docs/70546/Narrative/>.
11. Wise JN, Weissman BN, Appel M, et. al. Expert Panel on Musculoskeletal Imaging. ACR Appropriateness Criteria® Chronic Foot Pain. *Am Coll Radiol (ACR)*; Date of Origin: 1998. Revised: 2020. <https://acsearch.acr.org/docs/69424/Narrative/>.
12. Bencardino JT, Stone TJ, Roberts CC, et. al. Expert Panel on Musculoskeletal Imaging. ACR Appropriateness Criteria® Stress (Fatigue/Insufficiency) Fracture, Including Sacrum, Excluding Other Vertebrae. *Am Coll Radiol (ACR)*; Revised: 2016. <https://acsearch.acr.org/docs/69435/Narrative/>.
13. Kransdorf MJ, Weissman BN, Appel M, et. al. Expert Panel on Musculoskeletal Imaging. ACR Appropriateness Criteria® Suspected Osteomyelitis of the Foot in Patients with Diabetes Mellitus. *Am Coll Radiol (ACR)*; Date of Origin: 1995. Revised: 2019. <https://acsearch.acr.org/docs/69340/Narrative/>.
14. Thomas JL, Christensen JC, Kravitz SR, et al. The Diagnosis and Treatment of Heel Pain: A Clinical Practice Guideline - Revision 2010. *J Foot Ankle Surg*. 2010;49:S1-S19. doi: 10.1053/j.jfas.2010.01.001.
15. Goff JD, Crawford R. Diagnosis and Treatment of Plantar Fasciitis. *Am Fam Physician*. 2011 Sep;84(6):676-682. <https://www.aafp.org/afp/2011/0915/p676.html>.
16. Baxter D, Pfeffer G. Treatment of chronic heel pain by surgical release of the first branch of the lateral plantar nerve. *Clin Orthop*. 1992;279:229-236.
17. Schepsis A, Leach R, Gorzyca J. Plantar fasciitis: etiology, treatment, surgical results, and review of the literature. *Clin Orthop* 1991;266:185-196.
18. Neufeld SK, Cerato R. Plantar fasciitis: evaluation and treatment. *J Am Acad Orthop Surg*. 2008;16:338-46. doi:10.5435/00124635-200806000-00006.
19. Dodd A, Daniels TR. Charcot Neuroarthropathy of the Foot and Ankle. *J Bone Joint Surg Am*. 2018;100:696-711. doi:10.2106/JBJS.17.00785.

Nuclear Medicine (MS-28)

Guideline

Nuclear Medicine (MS-28)

References (MS-28)

Nuclear Medicine (MS-28)

MS.NM.0028.A

v1.0.2024

Results of plain x-rays performed after the current episode of symptoms started or changed need to be available to the requesting provider, unless otherwise specified below.

- SPECT scan may be approved for any of the indications for which a bone scan can be approved.
 - If the request is for CPT® 78300 and CPT® 78803, then only CPT® 78803 is to be approved if medical necessity is established.
 - If the request is for CPT® 78305 or CPT® 78306 and CPT® 78803, then two CPT® codes may be approved if medical necessity is established.
- Nuclear Medicine may be used in the evaluation of some musculoskeletal disorders, and other rare indications exist as well.
 - Evaluation of suspected aseptic loosening of orthopedic prostheses when recent plain x-ray is nondiagnostic:
 - Bone scan (CPT® 78315) **OR**
 - Distribution Of Radiopharmaceutical Agent SPECT (CPT® 78803, or 78831) **OR**
 - Hybrid SPECT/CT (CPT® 78830)
 - See also: **Post-Operative Joint Replacement Surgery (MS-16)** and anatomic tables
 - For detection of ischemic or infarcted regions in sickle cell disease:
 - Nuclear medicine bone marrow imaging (CPT® 78102, 78103,78104) **OR**
 - SPECT (CPT® 78803) **OR**
 - Hybrid SPECT/CT (CPT® 78830)
 - See also: **Modality General Considerations (PEDMS-1.3)**
 - Evaluation of complex regional pain syndrome or reflex sympathetic dystrophy, after failure of six weeks provider-directed conservative treatment (per **General Guidelines [MS-1.0]**):
 - Triple phase bone scan (CPT® 78315)
 - See: **Foot (MS-27)** for imaging criteria of CRPS of the foot
 - For interventional pain criteria see: **Regional Sympathetic Blocks (CMM-209)** and **Spinal Cord Stimulators (CMM-211)**
 - Evaluation of Paget's disease
 - Bone scan (CPT® codes: 78300, 78305, 78306) **OR**
 - Distribution Of Radiopharmaceutical Agent SPECT (CPT® 78803) **OR**
 - Hybrid SPECT/CT (CPT® 78830)
 - See also: **Soft Tissue Mass or Lesion of Bone (MS-10)**
 - Suspected fractures

- If criteria per **Suspected Occult/Stress/Insufficiency Fracture/Stress Reaction and Shin Splints (MS-5.2)** are met, but MRI cannot be performed:
 - Tc-99m bone scan whole body (CPT® 78306) with SPECT of the area of interest (CPT® 78803) **OR**
 - Hybrid SPECT/CT (CPT® 78830) **OR**
 - Bone scan (CPT® 78315, 78305, or 78300)
- Evaluation of suspected bone infection if MRI or CT cannot be done and when infection is multifocal, or when the infection is associated with orthopedic hardware or chronic bone alterations from trauma or surgery
 - FDG PET/CT (CPT® 78815 for multifocal infection, or CPT® 78811 for unifocal/limited area of interest) if MRI or CT is equivocal or cannot be done
 - At this time, FDG is the only indicated radiotracer for use with PET/CT in the imaging of musculoskeletal conditions.
 - Bone scan (CPT® 78315, 78300, 78305, or 78306) **OR**
 - Distribution Of Radiopharmaceutical Agent SPECT (CPT® 78803 or 78831) **OR**
 - Hybrid SPECT/CT (CPT® 78830 or 78832)
 - A labeled leukocyte scan (radiopharmaceutical inflammatory imaging - one of CPT® codes: 78800, 78801, 78802, or 78803) in concert with Tc-99m sulfur colloid marrow imaging (one of CPT® codes: 78102, 78103, or 78104)
 - See also: **Post-Operative Joint Replacement Surgery (MS-16)**
 - For specific joints post-operative from replacement surgery:
 - See: **Shoulder (MS-19)**
 - See: **Elbow (MS-20)**
 - See: **Hip (MS-24)**
 - See: **Knee (MS-25)**
 - See: **Ankle (MS-26)**

References (MS-28)

v1.0.2024

1. Beaman FD, von Herrmann PF, Kransdorf MJ, et. al. Expert Panel on Musculoskeletal Imaging. ACR Appropriateness Criteria® Suspected Osteomyelitis, Septic Arthritis, or Soft Tissue Infection (Excluding Spine and Diabetic Foot). *Am Coll Radiol (ACR)*; Date of Origin: 2016. Revised: 2022. <https://acsearch.acr.org/docs/3094201/Narrative/>.
2. Kransdorf MJ, Weissman BN, Appel M, et. al. Expert Panel on Musculoskeletal Imaging. ACR Appropriateness Criteria® Suspected Osteomyelitis of the Foot in Patients with Diabetes Mellitus. *Am Coll Radiol (ACR)*; Date of Origin: 1995. Revised: 2019. <https://acsearch.acr.org/docs/69340/Narrative/>.
3. Wise JN, Weissman BN, Appel M, et. al. Expert Panel on Musculoskeletal Imaging. ACR Appropriateness Criteria® Chronic Foot Pain. *Am Coll Radiol (ACR)*; Date of Origin: 1998. Revised: 2020. <https://acsearch.acr.org/docs/69424/Narrative/>.
4. Bencardino JT, Stone TJ, Roberts CC, et. al. Expert Panel on Musculoskeletal Imaging. ACR Appropriateness Criteria® Stress (Fatigue/Insufficiency) Fracture, Including Sacrum, Excluding Other Vertebrae. *Am Coll Radiol (ACR)*; Revised: 2016. <https://acsearch.acr.org/docs/69435/Narrative/>.
5. Hochman MG, Melenevsky YV, Metter DF, et. al. Expert Panel on Musculoskeletal Imaging. ACR Appropriateness Criteria® Imaging After Total Knee Arthroplasty. *Am Coll Radiol (ACR)*; Revised: 2023. <https://acsearch.acr.org/docs/69430/Narrative/>.
6. Weissman BN, Palestro CJ, Fox MG, et. al. Expert Panel on Musculoskeletal Imaging. ACR Appropriateness Criteria® Imaging After Total Hip Arthroplasty. *Am Coll Radiol (ACR)*; Revised: 2023. Available at: <https://acsearch.acr.org/docs/3094200/Narrative/>.

Table of Contents

Guideline

- General (Neck-1)
- Cerebrovascular and Carotid Disease (Neck-2)
- Dysphagia and Esophageal Disorders (Neck-3)
- Neck Mass/Swelling/ Adenopathy (Neck-5)
- Recurrent Laryngeal Nerve Palsy (Neck-7)
- Thyroid and Parathyroid (Neck-8)
- Trachea and Bronchus (Neck-9)
- Neck Pain (Neck-10)
- Salivary Gland Disorders (Neck-11)
- Sore Throat, Odynophagia, and Hoarseness (Neck-12)

General (Neck-1)

Guideline

Abbreviations for Neck Imaging Guidelines

General Guidelines (Neck-1.0)

References (Neck-1)

Abbreviations for Neck Imaging Guidelines

NK.GG.Abbreviations.A

v1.0.2024

Abbreviations for Neck Imaging Guidelines	
ALS	amyotrophic lateral sclerosis
CT	computed tomography
ENT	Ear, Nose, Throat
FNA	fine needle aspiration
GERD	gastroesophageal reflux disease
GI	gastrointestinal
HIV	human immunodeficiency virus
MRI	magnetic resonance imaging

General Guidelines (Neck-1.0)

NK.GG.0001.0.A

v1.0.2024

- A pertinent clinical evaluation since the onset or change in symptoms including a detailed history, physical examination, appropriate laboratory studies, and basic imaging such as plain radiography or ultrasound should be performed prior to considering advanced imaging (CT, MR, Nuclear Medicine), unless the individual is undergoing guideline-supported scheduled imaging evaluation. A meaningful technological contact (telehealth visit, telephone call, electronic mail or messaging) since the onset or change in symptoms can serve as a pertinent clinical evaluation.
- Advanced imaging of the neck covers the following areas:
 - Skull base (thus, a separate CPT® code for head imaging in order to visualize the skull base is not necessary)
 - Nasopharynx
 - Upper oral cavity to the head of the clavicle
 - Parotid glands and the supraclavicular region
- Ultrasound of neck soft tissues including thyroid, parathyroid, parotid and other salivary glands, lymph nodes, cysts, etc. is coded as CPT® 76536. This can be helpful in more ill-defined masses or fullness and differentiating adenopathy from mass or cyst, to define further advanced imaging.
- CT Neck
 - CT Neck is usually obtained with contrast only (CPT® 70491).
 - With the exception of 4D CT Neck without and with contrast (CPT® 70492) for parathyroid adenoma localization, little significant information is added by performing a CT Neck without and with contrast (CPT® 70492), and there is the risk of added radiation exposure, especially to the thyroid.
 - CT Neck without contrast (CPT® 70490) can be difficult to interpret due to difficulty identifying the blood vessels.
 - Exceptions include:
 - Contrast is generally not required when evaluating known or suspected tracheal anomalies with CT.
 - Additionally, noncontrast CT may be supported for the evaluation of salivary duct stones in the appropriate clinical circumstance where intravenous contrast may obscure high attenuation stones. Dual-phase CT imaging (without and with IV contrast) is not supported in this situation.⁴
 - Contrast enhanced CT is helpful in the assessment of cervical adenopathy and preoperative planning, including in the setting of thyroid carcinomas.
 - Contrast may cause intense and prolonged enhancement of the thyroid gland which interferes with radioactive iodine nuclear medicine studies.
 - Use of IV contrast is an important adjunct, however, because it helps to delineate the anatomic relationship between the primary tumor and

metastatic disease. Iodine is generally cleared within four to eight weeks in most individuals, so concern about iodine burden from IV contrast causing a clinically significant delay in subsequent whole-body scans (WBSs) or radioactive iodine (RAI) treatment after the imaging followed by surgery is generally unfounded. The benefit gained from improved anatomic imaging generally outweighs any potential risk of a several week delay in RAI imaging or therapy. Where there is concern, a urinary iodine to creatinine ratio can be measured.

- MRI Neck
 - MRI Neck is used less frequently than CT Neck.
 - MRI Neck without and with contrast (CPT® 70543) is appropriate if CT suggests the need for further imaging or if ultrasound or CT suggests any of the following:
 - Neurogenic tumor (schwannoma, neurofibroma, glomus tumor, etc.)
 - Vascular malformations
 - Deep neck masses
 - Angiofibromas
 - Cystic neck mass⁵
 - Concern for malignancy (see **Squamous Cell Carcinomas of the Head and Neck (ONC-3)**, **Salivary Gland Cancers (ONC-4)**, or **Thyroid Cancer (ONC-6)** as appropriate)
 - MRI Neck without and with contrast (CPT® 70543) is also directly supported if the head and neck surgeon or neurosurgeon, or the provider in consultation with the head and neck surgeon or neurosurgeon, has reasonable clinical concern:
 - For a skull base or nasopharyngeal neoplasm, or potential perineural invasion/cranial nerve involvement.²
 - That extensive dental amalgam may obscure the anatomy on CT in individuals with oral cavity neoplasm.

References (Neck-1)

v1.0.2024

1. Haugen BR, Alexander EK, Bible KC, et al. 2015 American Thyroid Association Management Guidelines for adult patients with thyroid nodules and differentiated thyroid cancer: The American Thyroid Association Guidelines Task Force on Thyroid Nodules and Differentiated Thyroid Cancer. *Thyroid*. 2016 Jan;26(1):1-133
2. Pynnonen MA, Gillespie MB, et al Clinical practice guideline: evaluation of the neck mass in adults. *Otolaryngology–Head and Neck Surgery*. 2017 Sep;157(2_suppl):S1-S30
3. National Comprehensive Cancer Network® (NCCN®) Guidelines® Version 2.2023 – May 15, 2023. Head and Neck Cancers. https://www.nccn.org/professionals/physician_gls/pdf/head-and-neck.pdf. Referenced with permission from the NCCN Clinical Practice Guidelines in Oncology (NCCN Guidelines®) for Head and Neck Cancers Version 2.2023. © 2023 National Comprehensive Cancer Network® (NCCN®). All rights reserved. NCCN Guidelines® and illustrations herein may not be reproduced in any form for any purpose without the express written permission of the NCCN. To view the most recent and complete version of the NCCN Guidelines®, go online to NCCN.org.
4. Purcell YM, Kavanagh RG, Cahalane AM, Carroll AG, Khoo SG, Killeen RP. The Diagnostic Accuracy of Contrast-Enhanced CT of the Neck for the Investigation of Sialolithiasis. *American Journal of Neuroradiology*. 2017;38(11):2161-2166. doi:10.3174/ajnr.a5353
5. Yunusova L, Rizaev J, Aoyama T, et al. Magnetic resonance imaging in the diagnosis of cystic lesions of the neck. *Ann Cancer Res Ther*. 2021;29(1):102-109. doi:10.4993/acrt.29.102

Cerebrovascular and Carotid Disease (Neck-2)

Guideline

Cerebrovascular and Carotid Disease (Neck-2.1)

Cerebrovascular and Carotid Disease (Neck-2.1)

NK.CC.0002.A

v1.0.2024

- See these related topics in the Head Imaging Guidelines:
 - [General Guidelines – CT and MR Angiography \(CTA and MRA\) \(HD-1.5\)](#)
 - [Aneurysm and AVM \(HD-12\)](#)
 - [Stroke/TIA \(HD-21.1\)](#)
 - [Cerebral Vasculitis \(HD-22.1\)](#)
 - [Dizziness, Vertigo and Syncope \(HD-23\)](#)
 - [Hearing Loss and Tinnitus \(HD-27\)](#)
 - [Eye Disorders and Visual Loss \(HD-32\)](#)
- See [Cerebrovascular and Carotid Disease \(PVD-3\)](#) in Peripheral Vascular Disease Imaging Guidelines.
- See [Eagle Syndrome \(Neck-10.3\)](#)

Dysphagia and Esophageal Disorders (Neck-3)

Guideline

Dysphagia and Esophageal Disorders (Neck-3.1)

References (Neck-3)

Dysphagia and Esophageal Disorders (Neck-3.1)

NK.ED.0003.1.A

v1.0.2024

- **General considerations**
 - A detailed history of the dysphagia symptoms is important to distinguish neurogenic, pharyngeal and esophageal disorders.
 - Dysphagia (difficulty swallowing) can be the result of a wide range of benign and malignant processes that affects the body's ability to move food or liquid from the mouth to the pharynx and into the esophagus.
 - A short duration (weeks to months) of rapidly progressive esophageal dysphagia with associated weight loss is highly suggestive of esophageal cancer.
 - Advanced imaging for individuals presenting with isolated globus rarely impacts clinical management. In a study of 148 neck CTs and 104 barium esophagrams done for the evaluation of globus sensation, there were no malignancies detected.²⁰
- **Gastroesophageal reflux disease (GERD)**^{5,14}
 - Advanced imaging is generally not indicated for the evaluation of GERD, the diagnosis of which is usually made on the basis of clinical history, in conjunction with endoscopy, pH monitoring, Upper GI Barium Studies, and occasionally manometry. Exceptions would include the following:
 - Non-cardiac chest pain suspected of being GERD should be evaluated first to exclude cardiac and other etiologies. See **Non-Cardiac Chest Pain-Imaging (CH-4.1)** in the Chest Imaging Guidelines.
 - Gastric emptying study (CPT[®] 78264) for individuals with refractory GERD symptoms, and gastroparesis is being considered.
- **Suspected foreign body impaction and ingested foreign bodies**¹⁻³
 - Plain x-rays initial imaging.
 - If imaging is negative, and there is suspicion of a radiolucent foreign body (such as fish or chicken bones, wood, plastic, thin metal objects, aluminum can pop-ups, etc.):¹⁹
 - CT Neck and/or Chest with or without contrast
 - 3-D reconstruction (CPT[®] 76377 or CPT[®] 76376) is indicated in this setting
 - The use of oral contrast is discouraged (to avoid the aspiration of contrast material) for acute dysphagia or foreign body impaction, as the contrast may not pass, may be aspirated, and can interfere with subsequent endoscopic intervention.

- **Oropharyngeal dysphagia** ^{4,10,11}
 - Oropharyngeal dysphagia (difficulty in transferring food from the mouth to the pharynx)
 - Suspected neurologic causes: See appropriate sections in **Head Imaging Guidelines**
 - Initial evaluation is with direct visualization with laryngoscopy and/or upper endoscopy and a swallow study.
 - Video fluoroscopic swallowing study – (Dynamic radiographic evaluation of swallowing during speech pathologist-guided oral intake of various consistencies)
 - Flexible fiberoptic laryngoscopy and/or FEES (Fiberoptic Endoscopic Evaluation of Swallowing. FEES is a dynamic evaluation of swallowing via direct visualization using transnasal laryngoscopy during speech pathologist-guided oral intake of various consistencies.
 - CT Neck with contrast (CPT[®] 70491) is indicated for any documented anatomic abnormalities suggested by direct visualization—ie, on exam with flexible laryngoscopy or rigid video stroboscopy or FEES.
 - Completion of a radiographic swallow study, though potentially helpful, is NOT necessary prior to the requested advanced imaging in such a case.
- **Esophageal dysphagia** ^{4,6,10,11}
 - Esophageal dysphagia (difficulty in transferring food down the esophagus in the retrosternal region, e.g. food sticking in the neck or chest)
 - Initial evaluation is with barium esophagram or upper gastrointestinal endoscopy
 - Esophageal manometry if indicated, though not required
 - Advanced imaging is supported for the evaluation of structural abnormalities demonstrated on either esophagram or direct visualization (ie, laryngoscopy/ upper GI endoscopy), such as an external compression, tumor, stricture, diverticulum, etc.
 - Contrast CT Neck (CPT[®] 70491), CT Chest (CPT[®] 71260), **and/or** CT Abdomen (CPT[®] 74160) depending on the location of the abnormality identified.
- **Suspected perforation, abscess, or fistula**
 - CT Neck, Chest, **and/or** Abdomen, contrast as requested (preferably with contrast- CPT[®] 70491, CPT[®] 71260, CPT[®] 74160), depending on location
- **Hiatal hernia**
 - See **Hiatal Hernia (AB-12.3)** in the Abdomen Imaging Guidelines
- **Globus sensation** ^{7-9, 20}
 - Globus sensation is a feeling of a lump or foreign body in the throat. In general, laryngoscopy, endoscopy, and physical examination will rule out malignant causes and advanced imaging is usually not needed for evaluation. It is considered a mild form of dysphagia.
 - Direct visualization with laryngoscopy and/or upper endoscopy should be performed prior to advanced imaging.

- Unremarkable laryngoscopy and/or upper endoscopy does not preclude advanced imaging if **red flag** symptoms are also present:
 - weight loss
 - odynophagia/throat pain
 - referred otalgia
 - hoarseness
 - hemoptysis, **AND/OR**
 - other unilateral presentation of concerning symptoms.
- CT Neck with contrast (CPT® 70491) for ANY of the following:
 - Negative or equivocal findings on laryngoscopy and/or upper endoscopy with any **red flag** present
 - Known history of upper aerodigestive or esophageal malignancy
 - Known history of lymphoma
 - History of previous neck, esophageal, or gastric surgery—see below, and see **Background and Supporting Information** for post-operative oropharyngeal dysphagia associated with Anterior Cervical Spine Surgery (ACSS)
 - Palpable abnormality on physical examination such as neck mass
- **Post-operative dysphagia**
 - Dysphagia following surgery on the oropharynx, soft tissues of the neck, cervical spine, esophagus, or stomach:
 - In the immediate post-operative period the concern is for fluid collections, anastomotic leaks, perforations, and abscess. Prior laryngoscopy/upper endoscopy and barium esophagram are not required initially.
 - CT Neck with contrast (CPT® 70491) **AND/OR** CT Chest with contrast (CPT® 71260)
 - In the delayed post-operative period (ie, >3 months)¹⁸ the primary modalities for evaluation are history, physical, endoscopy (laryngoscopy or EGD) and/or barium esophagram/videofluoroscopic swallow study (VFSS) to direct any additional advanced imaging. See also **Background and Supporting Information**.
- **Suspected vascular ring** ^{8,9,12,13,15,16,17} (See **Dysphagia (PEDNECK-5)**)
 - Advanced imaging can be performed if a vascular ring is suspected by, or in consultation with, the treating specialty, i.e., cardiothoracic surgery, cardiology, otolaryngology, and/or pulmonology. More commonly, this congenital pathology would be suspected in a much younger population, however, dysphagia lusoria is a relatively rare condition involving a vascular ring (usually an aberrant right subclavian artery). As children these individuals are asymptomatic but develop worsening dysphagia later in adulthood, presumably secondary to increasing calcification and blood pressure.
 - CTA Chest (CPT® 71275) **OR** MRA Chest (CPT® 71555) are the preferred imaging studies in the evaluation of a suspected vascular ring.

- CT Chest with contrast (CPT® 71260) **OR** MRI Chest without contrast (CPT® 71550) **OR** MRI Chest without and with contrast (CPT® 71552) can be performed as alternative exams in the evaluation of suspected vascular ring.

Background and Supporting Information

- Postoperative oropharyngeal dysphagia is one of the most common complications following anterior cervical spine surgery (ACSS), and is considered by some to be an inevitable result of this surgery, rather than a surgical complication.¹⁸
- Severe dysphagia after ACSS should prompt immediate evaluation to exclude any potentially reversible surgical complication such as bone graft dislodgement, hematoma or retropharyngeal abscess.¹⁸
- In general, history, exam, plain films, laryngoscopy, and videofluoroscopic swallow studies are considered the primary modalities for evaluation. The videofluoroscopic swallow study, in fact, is the gold standard in evaluation, and is very sensitive in patients post-ACSS, and should be considered the initial evaluation in patients who are status post ACSS with globus sensation, or mild dysphagia.¹⁸

References (Neck-3)

v1.0.2024

1. Guelfguat M. Clinical Guidelines for Imaging and Reporting Ingested Foreign Bodies. *American Journal of Roentgenology*, 2014, 203;37-53
2. Takada, M. et. al. 3D-CT diagnosis for ingested foreign bodies. *Am J Emerg Med* 2000;18:192-3.
3. ASGE Guideline: Management of Ingested Foreign Bodies and Food Impactions. 2011. *Gastrointestinal Endoscopy* Vol. 73, No. 6.
4. ASGE Guideline: The Role of Endoscopy in the Evaluation and Management of Dysphagia. *Gastrointestinal Endoscopy* Vol. 79, No. 2. 2014.
5. Katz PO, Gerson LB, Vela MF. Guidelines for the Diagnosis and Management of Gastroesophageal Reflux Disease. *Amer. J. Gastroenterology*, 2013; 108:308-328.
6. Liu LWC, Andrews CN, Armstrong D, et al. Clinical Practice Guidelines for the Assessment of Uninvestigated Esophageal Dysphagia. *Canadian Association of Gastroenterology. Journal of the Canadian Association of Gastroenterology*. Vol. 1. Issue 1, 13 April 2018.
7. Lee BE. Globus pharyngeus: A review of its etiology, diagnosis and treatment. *World Journal of Gastroenterology*. 2012;18(20):2462. doi:10.3748/wjg.v18.i20.2462
8. ACR Appropriateness Criteria Nontraumatic Aortic Disease. Rev. 2013.
9. ACR Appropriateness Criteria. Known or Suspected Congenital Heart Disease in Adults. Rev. 2016.
10. ACR Appropriateness Criteria Dysphagia. Rev. 2018.
11. Pasha SF, Acosta RD, Chandrasekhara V, et al. The role of endoscopy in the evaluation and management of dysphagia. *Gastrointest Endoscopy*. 2014 Feb;79(2):191-201
12. Poletto E, Mallon MG, Stevens RM, Avitabile CM. Imaging Review of Aortic Vascular Rings and Pulmonary Sling. *J Am Osteopath Coll Radiol*. 2017;6(2):5-14
13. Hellinger JC, Daubert M, Lee EY, Epelman M. Congenital Thoracic Vascular Anomalies: Evaluation with State-of-the-Art MR Imaging and MDCT. *Radiologic Clinics of North America*. 2011;49(5):969-996. doi:10.1016/j.rcl.2011.06.013
14. Manning MA, Shafa S, Mehrotra AK, Grenier RE, Levy AD. Role of Multimodality Imaging in Gastroesophageal Reflux Disease and Its Complications, with Clinical and Pathologic Correlation. *RadioGraphics*. 2020;40(1):44-71. doi:10.1148/rg.2020190029
15. Yoshimura N, Fukahara K, Yamashita A, et al. Congenital vascular ring. *Surgery Today*. 2019;50(10):1151-1158. doi:10.1007/s00595-019-01907-5
16. Hanneman, Kate, et al. "Congenital Variants and Anomalies of the Aortic Arch." *RadioGraphics*, vol. 37, no. 1, 2017, pp. 32–51., doi:10.1148/rg.2017160033
17. Poletto E, Mallon MG, Stevens RM, Avitabile CM. Imaging Review of Aortic Vascular Rings and Pulmonary Sling. *J Am Osteopath Coll Radiol*. 2017;6(2):5-14
18. Anderson KK, Arnold PM. Oropharyngeal dysphagia after anterior cervical spine surgery: a review. *Global Spine J*. 2013;3(4):273-286. doi:10.1055/s-0033-1354253
19. Leinwand K, Brumbaugh DE, Kramer RE. Button Battery Ingestion in Children: A Paradigm for Management of Severe Pediatric Foreign Body Ingestions. *Gastrointest Endosc Clin N Am*. 2016;26(1):99-118. doi:10.1016/j.giec.2015.08.003
20. Alhilali L, Seo SH, Branstetter BF 4th, Fakhran S. Yield of neck CT and barium esophagram in patients with globus sensation. *AJNR Am J Neuroradiol*. 2014;35(2):386-389. doi:10.3174/ajnr.A3683

Neck Mass/Swelling/ Adenopathy (Neck-5)

Guideline

Neck Mass/Swelling/Adenopathy (Neck-5.1)

References (Neck-5)

Neck Mass/Swelling/Adenopathy (Neck-5.1)

NK.NM.0005.1.A

v1.0.2024

- Cervical lymphadenitis is common and follows most viral or bacterial infections of the ears, nose and throat. Painful acute lymphadenopathy should be treated with a trial of conservative therapy for 2-weeks, including antibiotics if appropriate. If there is improvement with conservative treatment, advanced imaging is not indicated. If the adenopathy persists, it can be imaged as per below.^{1,2,4}
- Ultrasound (CPT[®] 76536) can be considered for **ANY** of the following:^{1,2,4}
 - Cervical adenopathy/lymphadenitis or an inflammatory, infective, or reactive mass that has failed a 2-week trial of treatment (including antibiotics if appropriate) or observation^{1,2}
 - Anterior neck masses²
 - Any ill-defined mass, fullness or asymmetry²
- CT Neck with contrast (CPT[®] 70491) can be initially considered if:^{2,4}
 - Neck mass with any ONE of the following:
 - Size $\geq 1.5\text{cm}^4$
 - Mass present ≥ 2 weeks or of uncertain duration⁴
 - Non-tender neck masses⁴
 - Firm texture or fixation of the mass⁴
 - Suspected peritonsillar, retropharyngeal or other cervical space abscess²
 - Ulceration of skin overlying the neck mass^{4,7}
 - Ear pain ipsilateral to the neck mass⁴
 - Associated onset of hoarseness persistent for greater than 3-weeks¹⁰
 - Associated onset of throat pain, tonsil asymmetry, oral or oropharyngeal ulceration, weight loss, or hemoptysis^{4,7}
 - History of malignancy that would be primary or metastatic to the neck⁴
 - Prior ultrasound results, if performed, are suspicious or indeterminate for malignancy²
 - Carcinoma found in a lymph node or other neck mass²
 - Suspected or known sarcoidosis⁵
 - Preoperative evaluation of any neck mass²
- MRI Orbit/Face/Neck without and with contrast (CPT[®] 70543) is supported if:²
 - CT suggests the need for further imaging²
 - Ultrasound or CT suggests neurogenic tumor (schwannoma, neurofibroma, glomus tumor, etc.), vascular malformations, cystic neck mass^{7,9}, deep neck masses², or angiofibroma².
- MRI Orbit/Face/Neck without and with contrast (CPT[®] 70543) is also directly supported without prior CT Neck or ultrasound requirement, if the head and neck

specialist, or the provider in consultation with the head and neck specialist, has reasonable clinical concern for:

- Skull base or nasopharyngeal neoplasm, **OR**
- Potential perineural invasion/cranial nerve involvement, **AND/OR**
- Extensive dental amalgam which may obscure the anatomy on CT in individuals with oral cavity neoplasm.

Background and Supporting Information

- Inflammatory neck adenopathy is often associated with upper respiratory infection, pharyngitis, dental infection, HIV and toxoplasmosis. Occasionally it is associated with sarcoidosis and tuberculosis.
- Malignancy is a greater possibility in adults that are heavy drinkers and smokers, but HPV associated disease is on the rise and there can be a high suspicion for malignancy even without these traditional risk factors.
- ENT evaluation can be helpful in determining the need for advanced imaging.
- Although CT and MRI can have characteristic appearances for certain entities, biopsy and histological diagnosis are the only way to obtain a definitive diagnosis. The preferred initial method of biopsy is Ultrasound guided core needle biopsy of the mass.^{5,6}
- The most common causes of neoplastic cervical adenopathy are metastasis from head and neck tumors or lymphoma.
- MRI has great specificity for determining the boundaries and prevalence of developmental neck cysts. It may thus be considered optimal to use only MRI, which leads to a correct diagnosis in more than 90% of cases.⁹

References (Neck-5)

v1.0.2024

1. Ferrer R. Lymphadenopathy: differential diagnosis and evaluation. *Am Fam Physician*. 1998 Oct;58(6):1313-1320
2. Wippold II F, Cornelius RS, Berger KL, et al. ACR Appropriateness Criteria® Neck mass/adenopathy. American College of Radiology (ACR). Date or origin: 2009. Revised 2018.
3. Shulman ST, Bisno AL, Clegg HW, et al. Clinical Practice Guideline for the Diagnosis and Management of Group A Streptococcal Pharyngitis: 2012 Update by the Infectious Diseases Society of America. *Clinical Infectious Diseases*. 2012;55(10). doi:10.1093/cid/cis629
4. Pynnonen MA, Gillespie MB, Roman B, et al. Clinical Practice Guideline: Evaluation of the Neck Mass in Adults Executive Summary. *Otolaryngology–Head and Neck Surgery*. 2017;157(3):355-371. doi:10.1177/0194599817723609
5. Chapman MN, Fujita A, Sung EK, et al. Sarcoidosis in the Head and Neck: An Illustrative Review of Clinical Presentations and Imaging Findings. *American Journal of Roentgenology*. 2017;208(1):66-75. doi:10.2214/ajr.16.16058
6. McKnight CD, Glastonbury CM, Ibrahim M, Rivas-Rodriguez F, Srinivasan A. Techniques and Approaches for Safe, High-Yield CT-Guided Suprahyoid Head and Neck Biopsies. *American Journal of Roentgenology*. 2017;208(1):76-83. doi:10.2214/ajr.16.16558
7. Pynnonen MA, Gillespie MB, et al. Clinical practice guideline: evaluation of the neck mass in adults. *Otolaryngology–Head and Neck Surgery*. 2017 Sep;157(2_suppl):S1-S30.
8. National Comprehensive Cancer Network® (NCCN®) Guidelines® Version 2.2023 – May 15, 2023. Head and Neck Cancers. https://www.nccn.org/professionals/physician_gls/pdf/head-and-neck.pdf. Referenced with permission from the NCCN Clinical Practice Guidelines in Oncology (NCCN Guidelines®) for Head and Neck Cancers Version 2.2023. © 2023 National Comprehensive Cancer Network® (NCCN®). All rights reserved. NCCN Guidelines® and illustrations herein may not be reproduced in any form for any purpose without the express written permission of the NCCN. To view the most recent and complete version of the NCCN Guidelines®, go online to NCCN.org.
9. Yunusova L, Rizaev J, Aoyama T, et al. Magnetic resonance imaging in the diagnosis of cystic lesions of the neck. *Ann Cancer Res Ther*. 2021;29(1):102-109. doi:10.4993/acrt.29.102
10. Stachler RJ, Francis DO, Schwartz SR, et al. Clinical Practice Guideline: Hoarseness (Dysphonia) (Update) [published correction appears in *Otolaryngol Head Neck Surg*. 2018 Aug;159(2):403]. *Otolaryngol Head Neck Surg*. 2018;158(1_suppl):S1-S42. doi:10.1177/0194599817751030

Recurrent Laryngeal Nerve Palsy (Neck-7)

Guideline

Recurrent Laryngeal Nerve Palsy (Neck-7.1)

References (Neck-7)

Recurrent Laryngeal Nerve Palsy (Neck-7.1)

NK.PA.0007.1.A

v1.0.2024

- The following are supported with new diagnosis⁶ of idiopathic unilateral vocal fold paralysis/immobility or weakness, as identified on videostroboscopy or laryngoscopy by an Otolaryngologist—Head and Neck surgeon, or a clinician in consultation with such a specialist^{1,4,8,9}:
 - MRI Brain without and with contrast (CPT[®] 70553) **OR** MRI Brain without contrast (CPT[®] 70551) **AND**
 - MRI Orbit/Face/Neck with and without contrast (CPT[®] 70543) **OR** CT Neck with contrast (CPT[®] 70491) **AND**
 - CT Chest with contrast (CPT[®] 71260) (Strongly recommended for left vocal fold paralysis, and may be indicated for right vocal fold paralysis, if requested, see **Background and Supporting Information**)^{1,2,3,4,7,8,9,10}

Background and Supporting Information ¹⁻¹⁰

- The right and left recurrent laryngeal nerves supply the motor innervation of the right and left vocal folds/cords, respectively. They are branches off of the Vagus Nerve, CN X. The entire pathway from origin to endpoint of this nerve must be visualized in cases of presumed idiopathic vocal fold paralysis, newly identified by laryngoscopy, to search for a possible cause. From the origin of the vagus at the medulla oblongata to the looping down into the superior mediastinum and back to the neck of its branching nerve (the recurrent laryngeal nerve)—advanced imaging is required to screen for a cause for otherwise idiopathic vocal fold paralysis/paresis. The greater the degree of motion impairment, the more likely it is to find a cause on imaging.
- The superior mediastinum is most noteworthy for containing the take-off point of the three great branches of the aortic arch: the brachiocephalic trunk (also known as the innominate artery), the left common carotid artery, and the left subclavian artery.
- The extent of the CT Neck with contrast, to be inclusive of the entirety of the course of the recurrent laryngeal nerve in question, would have to extend to the "thoracic inlet" portion of the superior mediastinum on the right, and the "aortic triangle" portion of the superior mediastinum on the left.
- Contrast CT Chest is strongly supported with left vocal cord palsy due to the lower course of the recurrent laryngeal nerve branch on the left side of the body. It curves inferior to the aortic arch and ascends in the groove between the trachea and the esophagus. However, the course of the recurrent laryngeal nerve on the right side may be as low as the level at which the brachiocephalic artery meets the subclavian artery, and this area of the thoracic inlet may or may not be contained within the anatomic extent of a CT neck at all institutions.

- Repeat imaging for a pre-existing diagnosis of idiopathic unilateral vocal cord paralysis may be considered on a case by case basis. Recommendations include possibly repeating advanced imaging as above within 5 years after initial diagnosis and workup, or performing regular (annual) clinical evaluations with imaging reserved for the development of new symptoms or exam findings.⁶

References (Neck-7)

v1.0.2024

1. Merati AL, Halum SL, Smith TL. Diagnostic testing for vocal fold paralysis: survey of practice and evidence-based medicine review. *Laryngoscope*. 2006;116(9):1539-1552. doi:10.1097/01.mlg.0000234937.46306.c2
2. Paddle PM, Mansor MB, Song PC, Franco RA Jr. Diagnostic Yield of Computed Tomography in the Evaluation of Idiopathic Vocal Fold Paresis. *Otolaryngol Head Neck Surg*. 2015;153(3):414-419. doi:10.1177/0194599815593268
3. Chew HS, Goh JCG, Tham DYA. Diagnostic yield of computed tomography in the evaluation of unilateral vocal fold palsy. *J Laryngol Otol*. 2021;135(3):255-258. doi:10.1017/S0022215121000463
4. Misono S, Merati AL. Evidence-based practice: evaluation and management of unilateral vocal fold paralysis. *Otolaryngol Clin North Am*. 2012;45(5):1083-1108. doi:10.1016/j.otc.2012.06.011
5. Stachler RJ, Francis DO, Schwartz SR, et al. Clinical Practice Guideline: Hoarseness (Dysphonia) (Update) [published correction appears in *Otolaryngol Head Neck Surg*. 2018 Aug;159(2):403]. *Otolaryngol Head Neck Surg*. 2018;158(1_suppl):S1-S42. doi:10.1177/0194599817751030
6. Noel JE, Jeffery CC, Damrose E. Repeat Imaging in Idiopathic Unilateral Vocal Fold Paralysis: Is It Necessary?. *Ann Otol Rhinol Laryngol*. 2016;125(12):1010-1014. doi:10.1177/0003489416670654
7. Paquette CM, Manos DC, Psooy BJ. Unilateral vocal cord paralysis: a review of CT findings, mediastinal causes, and the course of the recurrent laryngeal nerves [published correction appears in *Radiographics*. 2012 Nov-Dec;32(7):2166]. *Radiographics*. 2012;32(3):721-740. doi:10.1148/rg.323115129
8. Rubin AD, Sataloff RT. Vocal fold paresis and paralysis. *Otolaryngol Clin North Am*. 2007;40(5):1109-1131. doi:10.1016/j.otc.2007.05.012
9. Ivey CM. Vocal Fold Paresis. *Otolaryngol Clin North Am*. 2019;52(4):637-648. doi:10.1016/j.otc.2019.03.008
10. Politano S, Morell F, Calamari K, DeSilva B, Matrka L. Yield of Imaging to Evaluate Unilateral Vocal Fold Paralysis of Unknown Etiology. *Laryngoscope*. 2021;131(8):1840-1844. doi:10.1002/lary.29152

Thyroid and Parathyroid (Neck-8)

Guideline

Thyroid Nodule (Neck-8.1)

Hyperthyroidism and Hypothyroidism (Neck-8.2)

Parathyroid Imaging (Neck-8.3)

Parathyroid Incidentaloma (Neck-8.4)

References (Neck-8)

Thyroid Nodule (Neck-8.1)

NK.PT.0008.1.A

v1.0.2024

- Serum thyrotropin (TSH) should be measured in the initial evaluation of thyroid nodule/mass/asymmetry/goiter but is not required for follow-up imaging.^{1,3,6,8}
- Nuclear scan (CPT® 78013 or CPT® 78014) is indicated if the serum TSH is subnormal and ANY of the following:
 - Single or multiple thyroid nodules^{1,3,6,8}
 - Suspicion of ectopic thyroid tissue³
 - Presence of thyroid nodule in the setting of Grave’s disease.^{3,8}
- Ultrasound (US) Neck (CPT® 76536) is indicated for evaluation of a palpable thyroid nodule/mass/asymmetry/goiter regardless of TSH level:^{3,5}
 - Incidentally found on CT, MRI, or PET (focal activity)^{2,3,6}
 - Nodules ≤1 cm with very low suspicion US pattern including spongiform pattern (>50% small cystic spaces) and pure cysts do not require repeat US.^{6,10}
- ACR Thyroid Imaging, Reporting, and Data System (TI-RADS), consisting of five levels, is utilized for recommendations in determining US follow-up vs FNA of thyroid nodule(s).¹⁰
 - TI-RADS 1 (Benign) and TI-RADS 2 (Not Suspicious): Follow-up US is not indicated
 - Additional sonograms are indicated for more suspicious thyroid nodules that do not meet size criteria for FNA, such as TI-RADS 3 (Mildly Suspicious), TI-RADS 4 (Moderately Suspicious and TI-RADS 5 (Highly Suspicious) as follows:

ACR TI-RADS Levels for Thyroid Nodule Follow-Up Ultrasound or FNA			
TI-RADS 3 Mildly Suspicious	≥1.5 to 2.4 cm - US at 1, 3, and 5 years ≥2.5 cm - FNA	No further imaging if stable and no increase at 5 years*	TI-Rads level increases but is still below FNA range: Re-image with US in 1 year.
TI-RADS 4 Moderately Suspicious	≥1.0 to 1.4 cm - US at 1, 2, 3, and 5 years ≥1.5 cm - FNA	No further imaging if stable and no increase at 5 years*	TI-Rads level increases but is still below FNA range: Re-image with US in 1 year.
TI-RADS 5 Highly Suspicious	≥0.5 to 0.9 cm – US annually for 5 years ≥1.0 cm - FNA	No further imaging if stable and no increase at 5 years*	

- *If nodule enlarges on follow-up US but remains below the FNA size threshold for their ACR TI-RADS level at 5 years, additional follow-up US

imaging at the discretion of Thyroid Specialist, Endocrinologist, Neck/Thyroid Surgeon.

- If a TIRADS classification is not stated on a thyroid US report, clinical judgment should be used to determine appropriateness of follow-up imaging interval.
- The American Thyroid Association (ATA) guidelines from 2015 also use imaging characteristics and size for thyroid nodule risk stratification however size cutoffs are slightly more generous when compared to ACR-TIRADs. Sonographic imaging and/or biopsy requests in accordance with ATA criteria are appropriate³. See below for ATA's criteria:
 - **FNA requirements based on thyroid ultrasound pattern:**
 - Nodules \geq 1cm with high or intermediate suspicion pattern
 - Nodules \geq 1.5 cm with low suspicion pattern
 - Nodules \geq 2cm with very low suspicion pattern
 - Benign pattern: FNA not required
 - **Nodules with previously benign FNA:**
 - Nodules with high suspicion US pattern: repeat US and US-guided FNA within 12 months.
 - Nodules with low to intermediate suspicion US pattern: repeat US at 12–24 months; if 20% growth or new suspicious features, can repeat FNA or continue to observe with repeat US.
 - Nodules with very low suspicion US pattern (including spongiform nodules):
 - The utility of surveillance US and assessment of nodule growth as an indicator for repeat FNA to detect a missed malignancy is limited. If US is repeated, it should be done at 24 months.
 - **Nodules which do not meet FNA criteria:**
 - Nodules with high suspicion US pattern: repeat US in 6–12 months.
 - Nodules with low to intermediate suspicion US pattern: consider repeat US at 12–24 months.
 - Nodules $>$ 1 cm with very low suspicion US pattern (including spongiform nodules) and pure cysts which do not meet FNA criteria: the utility and time interval of surveillance US for risk of malignancy is not known. If US is repeated, it should be at \geq 24 months.
 - Nodules \leq 1 cm with very low suspicion US pattern (including spongiform nodules) and pure cysts do not require routine sonographic follow-up.
 - See **Background and Supporting Information** section below for links to a diagram of ATA's thyroid nodule risk related to ultrasound appearance and also a link to a diagram of ATA's FNA criteria.
- See **Thyroid Cancer-Surveillance/Follow-up (ONC-6.4)** for thyroid nodules that are biopsy proven thyroid cancer but are being monitored on active surveillance.
- Nuclear medicine thyroid scan (CPT[®] 78013 or CPT[®] 78014) is considered for ANY of the following (TSH is not required prior to imaging in the below settings):

- Evaluate eligibility for radioiodine therapy³
- Select nodules to biopsy in multinodular goiter even if TSH not low^{1,6,8}
- Substernal goiter with compressive symptoms (e.g. dyspnea, stridor, cough, dysphonia, dysphagia)
- Non-diagnostic or indeterminate FNA of thyroid nodule, (e.g. follicular lesion of undetermined significance) to see if hot (functioning) nodule that may be benign vs cold nodule.
- CT Neck with contrast (CPT® 70491), or CT Neck without contrast (CPT® 70490), or MRI Orbit/Face/Neck without contrast (CPT® 70540), or MRI Orbit/Face/Neck without and with contrast (CPT® 70543). CT is preferred since there is less motion artifact than with MRI. MRI and CT **are not** indicated for routine thyroid nodule evaluation and should only be considered for:⁵
 - Evaluation of extent of known substernal goiter^{3,8}
 - Suspected airway compression, ie, subjective sense of dyspnea or choking sensation in the clinical history with known multinodular goiter.^{3,8}
 - Presence of pathologic lymph nodes in cervical regions not visualized on ultrasound³
 - Clinically suspected advanced thyroid disease, including invasive primary tumor^{3,6,8}
 - Any preoperative planning for thyroid disease^{3,5,9,10}
- CT Chest without contrast (CPT® 71250) or with contrast (CPT® 71260) is also indicated for:
 - Preoperative planning for individuals with substernal extension of the thyroid, pulmonary symptoms, or abnormalities on recent chest x-ray, and should be ordered by a surgeon or in consultation with a surgeon.¹⁰
- A thyroid nodule detected for the first time during pregnancy should be managed in the same way as in non-pregnant individuals, except for avoiding the use of radioactive agents for diagnostic and therapeutic purposes.³
- Thyroglossal duct cysts (TGDC) are the most common type of congenital neck cyst of the midline neck, and may be first diagnosed in adulthood, though more commonly in early childhood.^{8,9}
 - A physical exam feature includes the rise and fall of the midline mass with protrusion and retraction of the tongue, due to its embryonal connection to the foramen cecum.^{8,9}
 - There is a small risk (about 1%) of incidental malignant degeneration within the TGDC, particularly within adults, and therefore, it is uniformly managed surgically. The Sistrunk procedure, which involves resection of the TGDC and its complete tract within the surrounding midline tissues—to include the middle third of the hyoid bone, is considered the gold standard in surgical management with a less than 5% risk of recurrence.^{8,9}
 - Advanced imaging, per surgeon's request—or a provider in consultation with the head and neck surgeon, to include Neck Ultrasound (CPT® 76536) or CT Neck with contrast (CPT® 70491) or MRI Neck with and without contrast (CPT®

70543), is generally supported pre-operatively, or for the evaluation of a suspected recurrence.^{8,9}

Background and Supporting Information

- TI-RADS levels are determined based on the ultrasound appearance of the nodule. Grading criteria are available at <https://www.acr.org/-/media/ACR/Files/RADS/TI-RADS/TI-RADS-chart.pdf?la=en>.
- Link to ATA's thyroid nodule risk related to ultrasound appearance:³
 - <https://www.liebertpub.com/cms/10.1089/thy.2015.0020/asset/images/large/figure2.jpeg>
- Link to ATA's FNA criteria:³
 - https://www.ncbi.nlm.nih.gov/core/lw/2.0/html/tileshop_pmc/tileshop_pmc_inline.html?title=Click%20on%20image%20to%20zoom&p=PMC3&id=4739132_fig-1.jpg
- Ultrasonography (US) is preferred over CT and MRI^{1,2,3,6,8} for thyroid nodule assessment. Thyroid nodule management relies on ultrasound characteristics, TSH level and FNA biopsy, together with clinical findings.
- Fine-Needle Aspiration (FNA) biopsy is indicated for suspicious and/or large thyroid nodules prior to CT or MRI imaging³
- A thyroid nodule is distinct either on palpation or radiologically (incidentaloma). Nonpalpable nodules have the same risk of cancer as palpable. Nodules >1 cm are evaluated, while smaller nodules are generally evaluated if there are suspicious sonographic features, co-existing adenopathy or a history of radiation or cancer exists.
- Ultrasound is not used to screen: 1) the general population, 2) individuals with normal thyroid on palpation with a low risk of thyroid cancer, 3) individuals with hyperthyroidism, 4) individuals with hypothyroidism or 5) individuals with thyroiditis. Conversely, US can be considered in individuals who have no symptoms but are high-risk as a result of: history of head and neck irradiation, total body irradiation for bone marrow transplant, exposure to fallout from radiation during childhood or adolescence, as well as family history of thyroid cancer syndromes such as MEN2, medullary or papillary thyroid cancer, Cowden's disease, familial adenomatous polyposis, Carney complex, Werner syndrome/progeria.
- There is insufficient evidence supporting the use of PET to distinguish indeterminate thyroid nodules that are benign from those that are malignant.
- 18FDG-PET imaging is not routinely recommended for the evaluation of thyroid nodules with indeterminate cytology. Routine preoperative 18FDG-PET scanning is not recommended.
- Incidental focal FDG-PET uptake often corresponds to a clinically relevant thyroid nodule and ultrasound is recommended in individuals with a normal life expectancy¹. Incidentally noted diffuse thyroid FDG-PET uptake most often corresponds to inflammatory uptake, however, ultrasound should be done to ensure that there is no evidence of clinically relevant nodularity.

- Elastography provides information about nodule stiffness that is complementary to gray scale ultrasound findings in nodules with indeterminate cytology or ultrasound findings. It should not be used as a substitute for gray scale ultrasound.
- Use of ultrasound contrast medium is not recommended for the diagnostic evaluation of thyroid nodules and its current use is restricted to definition of size and limits of necrotic zones after minimally invasive nodule ablation techniques.

Hyperthyroidism and Hypothyroidism (Neck-8.2)

NK.PT.0008.2.A

v1.0.2024

- Hyperthyroidism suspected^{4,7}
 - Thyroid Uptake Study (CPT[®] 78012 or CPT[®] 78014) if ONE of the following:
 - TSH below normal range and elevated free T4 and/or free T3, OR
 - Subclinical hyperthyroidism with TSH <0.1 mU/L and normal free T4 and free T3, OR
 - Subclinical hyperthyroidism with TSH below the lower limit of normal but ≥0.1 and normal free T4 and free T3 in the setting of any of the following:
 - Age ≥65
 - Symptoms of hyperthyroidism
 - Presence of cardiac disease or osteoporosis
 - Ultrasound (US) Neck (CPT[®] 76536) if any of the following:
 - Palpable nodule on examination
 - Nuclear scanning is suggestive of thyroid nodular disease
 - Diagnostic uncertainty regarding the etiology of hyperthyroidism based on clinical presentation and initial biochemical evaluation.
 - To evaluate thyroid dimensions for planning RAI treatment
 - Nuclear scanning is contraindicated (ie. pregnancy, breastfeeding etc).
- Hyperthyroidism on therapy---For individuals with thyroid hormone levels (TSH, free T4 and free T3) within the normal, hypothyroid, or hyperthyroid range while receiving treatment with an anti-thyroid medication (methimazole or propylthiouracil/PTU)⁹
 - Nuclear Scan (CPT[®] 78013 or CPT[®] 78014) if ONE of the following:
 - To determine the cause of hyperthyroidism if there was no diagnostic scan prior to the start of medical therapy.
 - To characterize the uptake in a thyroid nodule(s) to properly triage the nodule for FNA if there was no diagnostic scan prior to the start of medical therapy.
 - Thyroid Uptake Study (CPT[®] 78012 or CPT[®] 78014) if:
 - Plan is for radioactive iodine therapy as definitive hyperthyroidism treatment.
- Hypothyroidism: There is no role for thyroid imaging in the workup of hypothyroidism in adults. Imaging for thyroid morphology does not help differentiate among causes of hypothyroidism, and all causes of hypothyroidism will have decreased radioiodine uptake.

Parathyroid Imaging (Neck-8.3)

NK.PT.0008.3.A

v1.0.2024

- Classic primary hyperparathyroidism
 - Parathyroid Planar Imaging (CPT® 78070), Parathyroid Planar Imaging with SPECT (CPT® 78071), or Parathyroid Planar Imaging with SPECT/CT (preferred study) (CPT® 78072)^{2,3,5} AND/OR Ultrasound (CPT® 76536)^{1,2} AND/OR 4D CT Neck without and with contrast (CPT® 70492) are appropriate if BOTH of the following conditions are met:^{1,2,3}
 - PTH and Calcium levels are elevated (See **Background and Supporting Information**).
 - Intention of the study is preoperative localization.
 - All parathyroid nuclear scan codes (CPT® 78070, CPT® 78071, CPT® 78072) include thyroid subtraction when performed and no additional thyroid nuclear scan CPT codes are required unless otherwise indicated in **Thyroid Nodule (Neck-8.1)** or **Hyperthyroidism and Hypothyroidism (Neck 8.2)**.
 - Reporting or billing CPT® 78800 for the purpose of intraoperative parathyroid localization using a gamma probe is not supported if performed along with a parathyroid nuclear scan (CPT® 78070, CPT® 78071, CPT® 78072)
 - Ultrasound (CPT® 76536) can be ordered independently to evaluate the thyroid per criteria in **Thyroid Nodule (Neck-8.1)** or **Hyperthyroidism and Hypothyroidism (Neck 8.2)**
 - 3D Imaging (CPT® 76376 or CPT® 76377) is indicated with a 4D CT Neck
 - MRI Neck without and with contrast (CPT® 70543) for cases of re-operation, difficult localization or ionizing radiation contraindication^{1,6} as ordered by an Endocrinologist, Parathyroid surgeon, or Radiologist or any provider in consultation with one of these specialists.
 - CT Chest with contrast (CPT® 71260) in rare circumstances in the evaluation of ectopic mediastinal parathyroid adenomas¹⁴ as ordered by an Endocrinologist, Parathyroid surgeon, or Radiologist or any provider in consultation with one of these specialists.
 - Choline PET/CT (CPT® 78815 or CPT® 78816) is considered experimental and investigational for preoperative localization in cases of primary hyperparathyroidism.¹⁵⁻¹⁷
 - Repeat imaging is supported both in individuals with prior non-localizing imaging who have not yet undergone parathyroid exploration OR in cases of hyperparathyroidism that recurs or persists after parathyroid surgery if reimaging is being ordered by a surgeon or any provider after consultation with a surgeon with expertise in parathyroidectomy¹.
- Primary hyperparathyroidism variants

- Primary hyperparathyroidism with non-elevated serum calcium. (Serum Calcium level normal and PTH elevated).
 - Confirmatory study is elevated ionized calcium, elevated albumin corrected calcium or elevated historic calcium levels.^{1,4}
- Hypercalcemia with inappropriately non-suppressed PTH (Calcium level elevated and PTH normal).
 - PTH level ≥ 25 pg/mL is consistent with primary hyperparathyroidism.
 - See **Background and Supporting Information** for more information.
- Intention of parathyroid imaging should be for pre-operative localization.
- Use the same guidance on imaging modalities as described in “classic” primary hyperparathyroidism.

Primary Hyperparathyroidism variants:

	Calcium	PTH	Confirms/strongly suggests primary hyperparathyroidism
Classic primary hyperparathyroidism	High	High	Yes
Primary hyperparathyroidism with non-elevated serum calcium	Normal	High	Elevated ionized albumin corrected or historic calcium levels*
Hypercalcemia with inappropriately non-suppressed PTH	High	Normal	PTH ≥ 25 pg/ml

- Normocalcemic hyperparathyroidism
 - Serum calcium levels (including ionized calcium levels) are always normal and PTH levels are elevated.
 - Secondary causes of PTH elevation are excluded. See **Background and Supporting Information** for differential diagnosis of secondary hyperparathyroidism.
 - Calcium, PTH and clinical status should be monitored annually.
 - In the event of laboratory progression to hypercalcemia, refer to “classic” primary hyperparathyroidism for imaging guidance.
 - In the event of clinical progression (decline in bone mineral density or new fracture/renal stone/nephrocalcinosis), imaging for the intent of preoperative localization is as requested by or after consultation with a specialist or any provider in consultation with a specialist¹⁸.
- Secondary renal hyperparathyroidism
 - Serum calcium levels are low or normal (but may also be elevated in more advanced disease) and PTH levels are very elevated.

- Imaging for the intent of preoperative localization as requested by or after consultation with a specialist if all of the following are met:
 - Individuals has stage 3a-stage 5 chronic kidney disease (GFR<60).
 - PTH level is >9x upper limit of normal reference range for the lab testing facility (~585 pg/mL) despite standard medical or pharmacologic therapy (calcimimetics, calcitriol and/or vitamin D analogs)¹⁹.
 - Tertiary hyperparathyroidism
 - Serum calcium and PTH levels are elevated as a result of long standing secondary hyperparathyroidism in individuals on renal replacement therapy or after renal transplant.
 - Imaging for the intent of preoperative localization as requested by or in consultation with a specialist.
- Hyperparathyroidism subtypes:

	Calcium	PTH	Clinical Hallmarks
Normocalcemic Hyperparathyroidism	Normal	High	Calcium never elevated
Secondary renal Hyperparathyroidism	Low/Normal/High	Very High	Stage 3a-5 CKD, PTH >9x ULN
Tertiary Hyperparathyroidism	High	High	ESRD/renal transplant

Background and Supporting Information

- Hypercalcemia in individuals with primary hyperparathyroidism may be determined by elevated serum calcium, elevated serum ionized calcium, elevated serum calcium level corrected for albumin, or historic calcium elevation. A comparison of serial measurements of calcium is helpful in determining the presence of true hypercalcemia as calcium levels may be variable over time.
- Parathyroidectomy candidacy should be determined by the provider, however national guidelines recognize the following criteria for surgery^{1,4}
 - All individuals <50 years of age, regardless of whether objective features are present or absent.
 - All symptomatic individuals, including those with kidney stones, hypercalcemic crises, pathologic fractures or other associated symptoms.
 - Individuals with findings concerning for parathyroid cancer (very high calcium >13).
 - All asymptomatic individuals with the following:
 - Serum calcium >1.0 mg/dl (0.25 mmol/l) above the normal range
 - BMD by DEXA: T-score ≤2.5 at the lumbar spine, total hip femoral neck or distal 1/3 radius. (The forearm i.e. distal 1/3 radius is preferentially impacted by primary hyperparathyroidism as this area is rich in cortical bone.)

- Vertebral fracture by x-ray, CT, MRI and vertebral fracture assessment
- Estimated glomerular filtration rate of less than 60 ml/min
- Urinary calcium excretion >400 mg in 24 hours
- Nephrolithiasis or nephrocalcinosis by x-ray, ultrasound or CT
- Asymptomatic individuals who cannot participate in appropriate medical surveillance
- Asymptomatic individuals desiring definitive surgical management
- For cases of “normocalcemic hyperparathyroidism” in which primary hyperparathyroidism is not confirmed, additional investigation for secondary causes of hyperparathyroidism (renal insufficiency, hypercalciuria as a primary renal abnormality, vitamin D deficiency and gastrointestinal malabsorption problems such as short gut syndrome, celiac disease, Crohn's disease or a prior Roux-en-Y bypass surgery) is indicated^{1,18}.
- For cases of hypercalcemia in which primary hyperparathyroidism is not confirmed, additional consideration for other causes of hypercalcemia (malignancy including PTH-RP mediated and myeloma, granulomatous disease, FHH, medications including thiazide diuretics, excessive calcium/vitamin D supplementation and the history of or present lithium use) is indicated¹.

Parathyroid Incidentaloma (Neck-8.4)

NK.PT.0008.4.A

v1.0.2024

- A mass incidentally found on neck imaging that may represent an enlarged parathyroid gland, should prompt laboratory testing including calcium and PTH levels.^{1,2,3,4,5}
 - If laboratory abnormalities suggest hyperparathyroidism, i.e. "functioning parathyroid incidentaloma," see **Hyperparathyroidism (NECK- 8.3)** for imaging recommendations.
 - If there are no laboratory abnormalities and diagnoses other than parathyroid incidentaloma are suspected, see **Neck Mass/Swelling/Adenopathy (NECK- 5.1)** for imaging recommendations.
 - Parathyroid nuclear scans are commonly requested for an evaluation of a PTI however the sensitivity of these scans are low in individuals with normal calcium/PTH and no clinical symptoms of primary hyperparathyroidism.^{5,6} Reliance on either a positive scan or negative scan to decide if surgery is indicated is not supported by current literature.
- If a parathyroid incidentaloma is suspected on imaging prior to planned thyroid surgery or other head/neck surgery⁴, the following studies are indicated if ordered by the surgical team or any provider in consultation with the surgical team:
 - Parathyroid Planar Imaging (CPT® 78070), Parathyroid Planar Imaging with SPECT (CPT® 78071), or Parathyroid Planar Imaging with SPECT/CT (CPT® 78072) AND/OR Ultrasound (CPT® 76536) AND/OR 4D CT Neck without and with contrast (CPT® 70492)
- Ultrasound (US) Neck (CPT® 76536) annually if the mass was not removed surgically.³

Background and Supporting Information

- "Parathyroid incidentalomas" include parathyroid adenomas found unexpectedly at the time of surgery or seen on ultrasound.^{1,2,3,4,5,6}
- Normal sized parathyroid glands (~6mm) are not usually identified by most imaging modalities, so enlargement warrants laboratory evaluation to rule out pathologic causes such as primary hyperparathyroidism or rarely parathyroid carcinoma.^{1,2,3,4}
- Sonographic imaging features of a parathyroid incidentaloma (ovoid, hypoechoic, well circumscribed and adjacent to but separate from the thyroid either posteriorly or inferiorly) may have overlap with perithyroidal lymph nodes and exophytic thyroid nodules in a multinodular goiter.^{1,2,3,4}
- The literature does report cases of pathologically confirmed parathyroid adenomas/hyperplasia in individuals with normal serum calcium and PTH levels, so these enlarged parathyroid glands, may represent an early stage of hyperparathyroidism. It is unclear what percentage of non-functioning PTIs become hyper-secreting over time, but many of these masses are surgically managed.^{2,3,4,6}

- Normally sized and normally functioning parathyroid glands do not take up sestamibi or tetrofosmin.⁷ The likelihood of a positive parathyroid nuclear scan is low in the setting of normal calcium and PTH levels.^{5,6}
- Parathyroid fine needle aspiration biopsy has been used historically however its diagnostic use is limited, due to the potential for hemorrhage and fibrosis which make eventual surgical dissection and pathologic interpretation more difficult.^{1,4}

References (Neck-8)

v1.0.2024

Thyroid

1. Hoang JK, Langer JE, Middleton WD, et al. Managing incidental thyroid nodules detected on imaging: white paper of the ACR incidental thyroid findings committee. *J Am Coll Radiol*. 2015 Feb;12(2):143-150.
2. Gharib H, Papini E, Garber JR, et al. American Association Of Clinical Endocrinologists, American College Of Endocrinology, And Associazione Medici Endocrinologi medical guidelines for clinical practice for the diagnosis and management of thyroid nodules—2016 update. *Endocr Pract*. 2016 May;22(Suppl 1):1-60.
3. Haugen BR, Alexander EK, Bible KC, et al. 2015 American Thyroid Association Management Guidelines for adult patients with thyroid nodules and differentiated thyroid cancer: The American Thyroid Association Guidelines Task Force on Thyroid Nodules and Differentiated Thyroid Cancer. *Thyroid*. 2016 Jan;26(1):1-133.
4. Donangelo I and Suh SY. Subclinical hyperthyroidism: when to consider treatment. *Am Fam Physician*. 2017 Jun;95(11):710-716
5. Hoang JK, Oldan JD, Mandel SJ, et al. ACR Appropriateness Criteria® Thyroid Disease. *Journal of the American College of Radiology*. 2019;16(5). doi:10.1016/j.jacr.2019.02.004
6. Ross DS, Burch HB, Cooper DS, et al. 2016 American Thyroid Association Guidelines for Diagnosis and Management of Hyperthyroidism and Other Causes of Thyrotoxicosis. *Thyroid*. 2016;26(10):1343-1421. doi:10.1089/thy.2016.0229
7. Tessler FN, Middleton WD, Grant EG, et al. ACR Thyroid Imaging, Reporting and Data System (TI-RADS): White Paper of the ACR TI-RADS Committee. *Journal of the American College of Radiology*. 2017;14(5):587-595. doi:10.1016/j.jacr.2017.01.046
8. Corvino A, Pignata S, Campanino MR, et al. Thyroglossal duct cysts and site-specific differential diagnoses: imaging findings with emphasis on ultrasound assessment. *J Ultrasound*. 2020;23(2):139-149. doi:10.1007/s40477-020-00433-2
9. Chou J, Walters A, Hage R, et al. Thyroglossal duct cysts: anatomy, embryology and treatment. *Surg Radiol Anat*. 2013;35(10):875-881. doi:10.1007/s00276-013-1115-3
10. Hanson MA, Shaha AR, Wu JX. Surgical approach to the substernal goiter. *Best Pract Res Clin Endocrinol Metab*. 2019;33(4):101312. doi:10.1016/j.beem.2019.101312

Parathyroid

1. Wilhelm SM, Wang TS, Ruan DT, et al. The American Association of Endocrine Surgeons Guidelines for Definitive Management of Primary Hyperparathyroidism. *JAMA Surgery*. 2016;151(10):959. doi:10.1001/jamasurg.2016.2310
2. Bilezikian JP, Brandi ML, Eastell R, et al. Guidelines for the Management of Asymptomatic Primary Hyperparathyroidism: Summary Statement from the Fourth International Workshop. *The Journal of Clinical Endocrinology & Metabolism*. 2014;99(10):3561-3569. doi:10.1210/jc.2014-1413
3. Udelsman R, Åkerström G, Biagini C, et al. The Surgical Management of Asymptomatic Primary Hyperparathyroidism: Proceedings of the Fourth International Workshop. *The Journal of Clinical Endocrinology & Metabolism*. 2014;99(10):3595-3606. doi:10.1210/jc.2014-2000
4. Parnell KE, Oltmann SC. The surgical management of primary hyperparathyroidism: an updated review. *International Journal of Endocrine Oncology*. 2018;5(1). doi:10.2217/ije-2017-0019
5. ACR—SPR PRACTICE PARAMETER FOR THE PERFORMANCE OF PARATHYROID SCINTIGRAPHY—White paper, revised 2019
6. Kunstman JW, Kirsch JD, Mahajan A, Udelsman R. Parathyroid Localization and Implications for Clinical Management. *The Journal of Clinical Endocrinology & Metabolism*. 2013;98(3):902-912. doi:10.1210/jc.2012-3168
7. Orr LE, Mckenzie TJ, Thompson GB, Farley DR, Wermers RA, Lyden ML. Surgery for Primary Hyperparathyroidism with Normal Non-suppressed Parathyroid Hormone can be Both Challenging and Successful. *World Journal of Surgery*. 2017;42(2):409-414. doi:10.1007/s00268-017-4323-x
8. Bahl M. Preoperative Parathyroid Imaging. *Journal of Computer Assisted Tomography*. 2019;43(2):264-268. doi:10.1097/rct.0000000000000821
9. Kukar M, Platz TA, Schaffner TJ, et al. The Use of Modified Four-Dimensional Computed Tomography in Patients with Primary Hyperparathyroidism: An Argument for the Abandonment of Routine Sestamibi Single-Positron Emission Computed Tomography (SPECT). *Annals of Surgical Oncology*. 2014;22(1):139-145. doi:10.1245/s10434-014-3940-y
10. Kelly H, Hamberg L, Hunter G. 4D-CT for Preoperative Localization of Abnormal Parathyroid Glands in Patients with Hyperparathyroidism: Accuracy and Ability to Stratify Patients by Unilateral versus Bilateral

- Disease in Surgery-Naïve and Re-Exploration Patients. *American Journal of Neuroradiology*. 2013;35(1):176-181. doi:10.3174/ajnr.a3615
11. Solorzano CC, Carneiro-Pla D. Minimizing Cost and Maximizing Success in the Preoperative Localization Strategy for Primary Hyperparathyroidism. *Surgical Clinics of North America*. 2014;94(3):587-605. doi:10.1016/j.suc.2014.02.006
 12. Wang TS, Cheung K, Farrokhyar F, Roman SA, Sosa JA. Would scan, but which scan? A cost-utility analysis to optimize preoperative imaging for primary hyperparathyroidism. *Surgery*. 2011;150(6):1286-1294. doi:10.1016/j.surg.2011.09.016
 13. Lubitz CC, Stephen AE, Hodin RA, Pandharipande P. Preoperative Localization Strategies for Primary Hyperparathyroidism: An Economic Analysis. *Annals of Surgical Oncology*. 2012;19(13):4202-4209. doi:10.1245/s10434-012-2512-2
 14. Mortenson MM, Evans DB, Lee JE, et al. Parathyroid Exploration in the Reoperative Neck: Improved Preoperative Localization with 4D-Computed Tomography. *Journal of the American College of Surgeons*. 2008;206(5):888-895. doi:10.1016/j.jamcollsurg.2007.12.044
 15. Boccalatte LA, Higuera F, Gómez NL, et al. Usefulness of 18F-Fluorocholine Positron Emission Tomography-Computed Tomography in Locating Lesions in Hyperparathyroidism. *JAMA Otolaryngology-Head & Neck Surgery*. 2019;145(8):743. doi:10.1001/jamaoto.2019.0574
 16. Broos WA, Zant FMVD, Knol RJ, Wondergem M. Choline PET/CT in parathyroid imaging. *Nuclear Medicine Communications*. 2019;40(2):96-105. doi:10.1097/mnm.0000000000000952
 17. Parvinian A, Martin-Macintosh EL, Goenka AH, et al. 11C-Choline PET/CT for Detection and Localization of Parathyroid Adenomas. *American Journal of Roentgenology*. 2018;210(2):418-422. doi:10.2214/ajr.17.18312
 18. Cusano NE, Silverberg SJ, Bilezikian JP. Normocalcemic Primary Hyperparathyroidism. *Journal of Clinical Densitometry*. 2013;16(1):33-39. doi:10.1016/j.jocd.2012.12.001
 19. Kidney Disease: Improving Global Outcomes (KDIGO) CKD-MBD Update Work Group. KDIGO 2017 Clinical Practice Guideline Update for the Diagnosis, Evaluation, Prevention, and Treatment of Chronic Kidney Disease-Mineral and Bone Disorder (CKD-MBD). *Kidney Int Suppl*. 2017;7:1-59. *Kidney International Supplements*. 2017;7(3). doi:10.1016/j.kisu.2017.10.001
 20. ACR Appropriateness Criteria Parathyroid Adenoma, New 2021. <https://acsearch.acr.org/docs/3158171/Narrative/>.

Parathyroid Incidentaloma

1. Patel KN, Yip L, Lubitz CC, et al. The American Association of Endocrine Surgeons Guidelines for the Definitive Surgical Management of Thyroid Disease in Adults. *Annals of Surgery*. 2020;271(3):e21. doi:10.1097/SLA.0000000000003580
2. Sung JY. Parathyroid ultrasonography: the evolving role of the radiologist. *Ultrasonography*. 2015;34(4):268-274. doi:10.14366/usg.14071
3. Ghervan, C., Silaghi, C. A., & Nemes, C. (2012). Parathyroid incidentaloma detected during thyroid sonography-prevalence and significance beyond images. *Medical ultrasonography*, 14(3), 187-191.
4. Shroff P, McGrath GA, Pezzi CM. Incidentalomas of The Parathyroid Gland: Multiple Presentations, Variable Function, and Review of the Literature. *Endocrine Practice*. 2005;11(6):363-369. doi:10.4158/ep.11.6.363
5. Khanna S, Singh S, Khanna AK. Parathyroid Incidentaloma. *Indian Journal of Surgical Oncology*. 2012;3(1):26-29. doi:10.1007/s13193-012-0143-5
6. Frasoldati A, Pesenti M, Toschi E, Azzarito C, Zini M, Valcavi R. Detection and diagnosis of parathyroid incidentalomas during thyroid sonography. *Journal of Clinical Ultrasound*. 1999;27(9):492-498. doi:10.1002/(sici)1097-0096(199911/12)27:9<492::aid-jcu2>3.0.co;2-h
7. Kannan S. Parathyroid nuclear scan. A focused review on the technical and biological factors affecting its outcome. *Clinical Cases in Mineral and Bone Metabolism*. Published online 2014. doi:10.11138/ccmbm/2014.11.1.025

Trachea and Bronchus (Neck-9)

Guideline

Trachea and Bronchus – Imaging (Neck-9.1)

References (Neck-9)

Trachea and Bronchus – Imaging (Neck-9.1)

NK.TR.0009.1.A

v1.0.2024

- Initial evaluation for suspected laryngotracheal pathology:
 - Direct visualization of the upper airway (via laryngoscopy, with or without bronchoscopy), and can also include
 - Plain x-rays of the neck with or without chest x-ray
- To further evaluate definite abnormalities found on either of the above, including laryngotracheal, tracheal, or bronchial anomalies, foreign bodies or persistent segmental or lobar lung collapse:
 - CT Neck with contrast (CPT® 70491) **OR** CT Neck without contrast (CPT® 70490) **AND/OR**
 - CT Chest with contrast (CPT® 71260) **OR** CT Chest without contrast (CPT® 71250), depending on the anatomic level of the lesion
 - See **Squamous Cell Carcinomas of the Head and Neck—Suspected/Diagnosis (ONC-3.1)** for suspected laryngotracheal tumor
- For suspected subglottic stenosis (SGS) after evaluation by a specialist or in consultation with a specialist who has directly visualized the upper airway:
 - CT Neck with contrast (CPT® 70491) **OR** CT Neck without contrast (CPT® 70490) is supported
- For obstructive physiology in the setting of tracheomalacia:
 - Expiratory HRCT (CPT® 71250) is supported¹

Background and Supporting Information

- Bronchoscopy can further evaluate the distal endobronchial tree.
- Suspected laryngotracheal disease can be identified by inspiratory or biphasic stridor and a characteristic flow-volume loop of PFTs.¹
- The visualization of tracheal or bronchial "inspissation" or thickening of secretions without an abnormality, is not a risk for malignancy.³
- CT with multiplanar reformatting has proven comparable to rigid bronchoscopy with a 100% sensitivity and specificity of detecting SGS and for measuring length and grade of stenosis.⁵

References (Neck-9)

v1.0.2024

1. Dyer DS, Mohammed T-LH, Kirsch J, et al. ACR appropriateness Criteria® Chronic dyspnea: suspected pulmonary origin. Am Coll Radiol (ACR). Date of origin: 1995. Last review date: 2012. <https://acsearch.acr.org/docs/69448/Narrative/>.
2. Obusez EC, Jamjoom L, Kirsch J, et al. Computed tomography correlation of airway disease with bronchoscopy: part I—nonneoplastic large airway diseases. Curr Probl Diagn Radiol. 2014 Sep-Oct;43(5):268-277. [http://www.cpdjournal.com/article/S0363-0188\(14\)00038-3/fulltext](http://www.cpdjournal.com/article/S0363-0188(14)00038-3/fulltext).
3. Gould MK, Donington J, Lynch WR, et al. Evaluation of individuals with pulmonary nodules: when is it lung cancer? Diagnosis and management of lung cancer, 3rd ed: American College of Chest Physicians evidence-based clinical practice guidelines. Chest. 2013 May;143(5):e93S-e120S. [http://journal.chestnet.org/article/S0012-3692\(13\)60291-3/fulltext](http://journal.chestnet.org/article/S0012-3692(13)60291-3/fulltext).
4. American College of Radiology ACR Appropriateness Criteria® Chronic Dyspnea-Noncardiovascular Origin. Revised 2018. <https://acsearch.acr.org/docs/69448/Narrative/>.
5. Pasick LJ, Anis MM, Rosow DE. An Updated Review of Subglottic Stenosis: Etiology, Evaluation, and Management. *Current Pulmonology Reports*. Published online March 3, 2022. doi:10.1007/s13665-022-00286

Neck Pain (Neck-10)

Guideline

Neck Pain (Cervical) (Neck-10.1)

Torticollis and Dystonia (Neck-10.2)

Eagle's Syndrome (Neck-10.3)

References (Neck-10)

Neck Pain (Cervical) (Neck-10.1)

NK.NP.0010.1.A

v1.0.2024

- Neck pain is usually related to a specific process including pharyngitis, radiculopathy, adenopathy, mass, carotid dissection and torticollis, and therefore found elsewhere in these guidelines.¹
- For the evaluation of neck pain or other symptoms which may involve the cervical spine, including myelopathy and cervical radiculopathy¹, see **Spine Imaging Guidelines**.

Torticollis and Dystonia (Neck-10.2)

NK.NP.0010.2.A

v1.0.2024

Older Child (beyond infancy) or Adult ¹

- To identify fracture or malalignment in cases of trauma:
 - Initial evaluation with recent trauma (without a high-risk mechanism of injury—see **SP-3.2 Neck (Cervical Spine) Trauma**) is by plain radiographs of the cervical spine.^{10,11,12} If inconclusive:
 - CT Neck with contrast (CPT[®] 70491) **AND/OR**
 - CT Cervical Spine without contrast (CPT[®] 72125)
- In the clinical setting of cervical spine trauma with an associated neurologic deficit:
 - MRI Cervical Spine without contrast (CPT[®] 72141) is supported
- To evaluate for soft tissue or neurological cause in cases with no trauma history:
 - CT Neck with contrast (CPT[®] 70491), **AND/OR**
 - MRI Cervical Spine without contrast (CPT[®] 72141), **OR**
 - CT Cervical Spine without contrast (CPT[®] 72125)
 - Positive→ Further advanced imaging is not required if CT Neck or CT/MRI Cervical Spine has identified local cause.
 - Negative→ MRI Brain without and with contrast (CPT[®] 70553) to exclude CNS cause.

Eagle's Syndrome (Neck-10.3)

NK.NP.0010.3.A

v1.0.2024

Also known as "Calcified stylohyoid ligament," "elongation of styloid process," or "stylo-carotid artery syndrome."

- **"Classic Eagle Syndrome"**
 - Typically seen in individuals after pharyngeal trauma or tonsillectomy^{4,5}
 - Characterized by ipsilateral dull, persistent pharyngeal pain, centered in the ipsilateral tonsillar fossa, that can be referred to the ear, and exacerbated by rotation of the head
 - Other symptoms may include dysphagia, sensation of foreign body in the throat, tinnitus, or cervicofacial pain
 - If Eagle Syndrome is suspected on exam and/or lateral neck x-ray:^{4,5}
 - CT Maxillofacial with contrast (CPT® 70487) **OR** CT Maxillofacial without contrast (CPT® 70486) **AND/OR**
 - CT Neck with contrast (CPT® 70491) **OR** CT Neck without contrast (CPT® 70490)
- **"Stylo-carotid Artery Syndrome"** (ie, the anterior circulation equivalent of "bow hunter syndrome"—rotational vertebral artery occlusion syndrome, see also **General Guidelines - CT and MR Angiography (CTA and MRA) (HD-1.5)⁹**)
 - Characterized by the compression of the internal or external carotid artery (with their peri-vascular sympathetic fibers) by a laterally or medially deviated styloid process
 - It is related to a pain along the distribution of the artery, which is provoked and exacerbated by rotation and compression of the neck
 - Not correlated with tonsillectomy
 - In cases of impingement of the internal carotid artery, there may be referred supraorbital pain and parietal headache. In cases of external carotid artery irritation, the pain radiates to the infraorbital region.
 - Dynamic/Positional CTA (CPT® 70498) is supported to assess for vascular compression (see also **General Guidelines - CT and MR Angiography (CTA and MRA) (HD-1.5)⁹** and **General Guidelines - Other Imaging Situations (HD-1.7)⁶**)
- CT scanning (and in particular, 3-D CT scanning) represents an extremely valuable imaging tool in patients with Eagle syndrome. 3-D rendering (CPT® 76376 or CPT® 76377) is supported as an add on to CT Neck (CPT® 70491 **or** CPT® 70490), if requested, for accurate evaluation of the styloid process in relation to its anatomic relationship with the other head and neck structures, in surgical planning.⁷ See **3D Rendering (Preface-4.1)**.

Background and Supporting Information

- Torticollis or cervical dystonia is an abnormal twisting of the neck resulting in head rotation. Its causes are many and may be congenital or acquired and caused by trauma, infection/inflammation, neoplasm and/or idiopathic. It occurs more frequently in children and on the right side (75%).
- Eagle syndrome is characterized by recurrent pain in the oropharynx and face due to an elongated styloid process or calcified stylohyoid ligament. The styloid process is a slender outgrowth at the base of the temporal bone, immediately posterior to the mastoid apex.^{4,8}

References (Neck-10)

v1.0.2024

1. ACR Appropriateness Criteria® Cervical Neck Pain or Cervical Radiculopathy. *Am Coll Radiol (ACR)*. Date of origin: 1998. Last review date: 2018.
2. Haque S, Shafi BBB, Kaleem M. Imaging of torticollis in children. *Radiographics*, 2012;32(2):557-571.
3. Boyko N, Eppinger MA, Straka-DeMarco D, Mazzola CA. Imaging of congenital torticollis in infants: a retrospective study of an institutional protocol. *Journal of Neurosurgery*, 2017;20(2):111-212.
4. Badhey A, Jategaonkar A, Anglin Kovacs AJ, et al. Eagle syndrome: A comprehensive review. *Clinical Neurology and Neurosurgery*. 2017;159:34-38. doi:10.1016/j.clineuro.2017.04.021
5. Jamal B, Jalisi S, Grillone G. Surgical management of long-standing eagle's syndrome. *Annals of Maxillofacial Surgery*. 2017;7(2):232. doi:10.4103/ams.ams_53_17
6. ACR ASNR SPR Practice Parameter for the Performance and Interpretation of Cervicocerebral Computed Tomography Angiography (CTA) Revised 2020
7. Kent DT, Rath TJ, Snyderman C. Conventional and 3-Dimensional Computerized Tomography in Eagle's Syndrome, Glossopharyngeal Neuralgia, and Asymptomatic Controls. *Otolaryngol Head Neck Surg*. 2015;153(1):41-47. doi:10.1177/0194599815583047
8. Elimairi I, Baur DA, Altay MA, Quereshy FA, Minisandram A. Eagle's Syndrome. *Head Neck Pathol*. 2015; (4):492-495. doi:10.1007/s12105-014-0599-4
9. Chuang WC, Short JH, McKinney AM, Anker L, Knoll B, McKinney ZJ. Reversible left hemispheric ischemia secondary to carotid compression in Eagle syndrome: surgical and CT angiographic correlation. *AJNR Am J Neuroradiol*. 2007;28(1):143-145.
10. Expert Panel on Neurological Imaging and Musculoskeletal Imaging; Beckmann NM, West OC, et al. ACR Appropriateness Criteria® Suspected Spine Trauma. *J Am Coll Radiol*. 2019;16(5S):S264-S285. doi:10.1016/j.jacr.2019.02.002
11. Hoffman JR, Mower WR, Wolfson AB, Todd KH, Zucker MI. Validity of a set of clinical criteria to rule out injury to the cervical spine in patients with blunt trauma. National Emergency X-Radiography Utilization Study Group [published correction appears in *N Engl J Med* 2001 Feb 8;344(6):464]. *N Engl J Med*. 2000;343(2):94-99. doi:10.1056/NEJM200007133430203
12. Thompson WL, Stiell IG, Clement CM, Brison RJ; Canadian C-Spine Rule Study Group. Association of injury mechanism with the risk of cervical spine fractures. 2009;11(1):14-22. doi:10.1017/s1481803500010873

Salivary Gland Disorders (Neck-11)

Guideline

Salivary Gland Disorders (Neck-11.1)

References (Neck-11)

Salivary Gland Disorders (Neck-11.1)

NK.SG.0011.1.A

v1.0.2024

- **Xerostomia (Dry Mouth)**
 - Salivary Gland Nuclear Imaging (one of CPT® 78230, CPT® 78231, or CPT® 78232) can be considered for any one of the following:
 - Dry mouth and either:
 - Sjögren's syndrome
 - Sialadenitis
 - History of head or neck radiation therapy
 - History of cerebral palsy
 - Parotid mass to allow preoperative diagnosis of Warthin's tumor
- **Salivary Gland Stones, Sialadenitis or Stenosis:**¹
 - Sialography (contrast dye injection) under fluoroscopy, can be performed to rule out a salivary duct stone or stricture, using
 - Post-sialography CT (CT Maxillofacial without contrast [CPT® 70486] for Stensen's duct of the parotid gland, which would be most common; **or** CT Neck without contrast [CPT® 70490] for the level of the Wharton's Duct); **or** post-sialography MRI (MRI Orbit/Face/Neck without contrast [CPT® 70540])
OR
 - CT Maxillofacial area with contrast (CPT® 70487) **OR**
 - CT Neck with contrast (CPT® 70491)
 - CT performed only without IV contrast (CPT® 70490) may be helpful in a small minority of cases, such as cases of follow-up for known salivary stones, or for post-sialography imaging, as described above **OR**
 - MRI Orbit/Face/Neck without and with contrast (CPT® 70543)
- **Parotid or Other Salivary Gland Mass**
 - The following are appropriate:²
 - Ultrasound (CPT® 76536) is supported as initial or additional imaging and does not need to be completed prior to the performance of advanced imaging.
 - MRI Orbit/Face/Neck without and with contrast preferred (CPT® 70543) **or** MRI Orbit/Face/Neck without contrast (CPT® 70540) **OR**
 - CT Neck with contrast (CPT® 70491) preferred **or** CT Maxillofacial area with contrast (CPT® 70487)
- **Repeat Imaging (CT or MRI, as above)** ⁴
 - There is currently no standard timeframe for repeat advanced imaging to follow known benign pathology of the salivary gland that has been resected—partially or completely, or only observed. This holds true even if the salivary lesion has the potential for recurrence or malignant transformation (i.e., pleomorphic adenoma).

- Repeat advanced imaging, as requested by the surgeon or those in consultation with the surgical team, is indicated if recent history and exam demonstrate signs:
 - Concerning for complications of surgery, or
 - Recurrence or progression of neoplasm/lesion

Background and Supporting Information

- CT Neck
 - CT should be performed with IV contrast to distinguish vessels from lymph nodes and to confirm if a mass is hypervascular. *Dual-phase CT imaging (without and with IV contrast) is not supported.* CT performed only without IV contrast may be helpful in a small minority of cases including cases of follow-up for known salivary stones or post-sialography studies.
 - A recent study in the American Journal of Neuroradiology comparing contrast enhanced and non-contrast enhanced CT in the evaluation of sialolithiasis demonstrated excellent sensitivity and specificity with no false-positive results using contrast-enhanced CT alone (without the addition of non-contrasted images for comparison). Benefits of initial only contrast-enhanced CT include better evaluation of the ductal system, improved soft tissue contrast in assessing salivary masses and decreased radiation dose (compared to dual phase CT imaging (without and with IV contrast)).³

References (Neck-11)

v1.0.2024

1. Wilson KF, Meier JD, and Ward PD. Salivary gland disorders. *Am Fam Physician*. 2014 Jun;89(11):882-888
2. ACR Appropriateness Criteria® Neck mass/adenopathy. American College of Radiology (ACR). Date of origin: 2009. Last review date: 2018.
3. Purcell YM, Kavanagh RG, Cahalane AM, Carroll AG, Khoo SG, Killeen RP. The Diagnostic Accuracy of Contrast-Enhanced CT of the Neck for the Investigation of Sialolithiasis. *American Journal of Neuroradiology*. 2017;38(11):2161-2166. doi:10.3174/ajnr.a5353
4. Wittekindt C, Streubel K, Arnold G, Stennert E, Guntinas-Lichius O. Recurrent pleomorphic adenoma of the parotid gland: analysis of 108 consecutive patients. *Head Neck*. 2007;29(9):822-828. doi:10.1002/hed.20613

Sore Throat, Odynophagia, and Hoarseness (Neck-12)

Guideline

Definitions (Neck-12.0)

Sore Throat/Throat Pain/Odynophagia (Neck-12.1)

Hoarseness (Neck-12.2)

References (Neck-12)

Definitions (Neck-12.0)

NK.ST.0012.0.A

v1.0.2024

- Hoarseness – Altered voice quality reported by the individual
- Dysphagia – Disordered or impaired swallowing ie. food impactions, globus sensation, choking/aspiration, regurgitation (See **Dysphagia and Esophageal Disorders (Neck-3.1)**)
- Odynophagia – Painful swallowing

Sore Throat/Throat Pain/Odynophagia (Neck-12.1)

NK.ST.0012.1.A

v1.0.2024

- See **Dysphagia and Esophageal Disorders (Neck-3.1)** for dysphagia as the primary symptom.
- Sore Throat/Throat Pain/Odynophagia
 - Uncomplicated viral or streptococcal pharyngitis with sore throat³
 - Imaging studies are not indicated. See **Neck Mass/Swelling/Adenopathy (Neck-5.1)** for suspected complications of pharyngitis/tonsillitis, such as a cervical space abscess.
 - Postoperative throat pain or odynophagia after head and neck procedure with suspected complication of procedure.⁴
 - CT Neck with contrast (CPT® 70491)
 - Sore throat/throat pain/odynophagia that is persistent or progressive for two or more weeks, in spite of any treatment measures or observation:
 - Initial evaluation is laryngoscopy
 - If the initial laryngoscopy is abnormal, or if it is negative, and if there is a continued suspicion of submucosal lesion of the pharynx^{2,4} due to any red flag symptoms (weight loss, referred otalgia, hoarseness, hemoptysis, and/or unilateral presentation of symptoms):
 - CT Neck with contrast (CPT® 70491) **OR**
 - MRI Orbit/Face/Neck without and with contrast (CPT® 70543)
 - Alarm symptoms of persistent unilateral throat pain or odynophagia with ipsilateral referred otalgia is especially suspicious for a submucosal tumor of the head and neck (versus more distal esophageal pathology).⁵
 - If subjective dysphagia AND odynophagia are both present and the initial laryngoscopy and neck exam are normal (i.e. no cervical space abscess or post-surgical complication is suspected), and no red flag symptoms are present, then barium esophagram (or GI upper endoscopy) is indicated prior to the advanced imaging studies of the neck listed above.^{5,6}

Hoarseness (Neck-12.2)

NK.ST.0012.2.A

v1.0.2024

- Laryngoscopy is the primary diagnostic modality for evaluating individuals with hoarseness. Imaging studies, including CT and MRI, are unnecessary in most individuals with hoarseness because most hoarseness is self-limited or caused by pathology that can be identified by laryngoscopy alone.
- The need for advanced imaging is based upon abnormal findings upon laryngoscopy,¹ such as:
 - Immobile or partially mobile vocal cord [See [Recurrent Laryngeal Nerve Palsy \(NECK-7.1\)](#)]
 - Any growth, asymmetry, ulceration, or other suspected neoplasm of the glottis or supraglottis [See [Neck Mass/Swelling/Adenopathy \(Neck 5.1\)](#). See also [ONC-3.0-3.4](#)].

References (Neck-12)

v1.0.2024

1. Stachler RJ, Francis DO, Schwartz SR, et al. Clinical Practice Guideline: Hoarseness (Dysphonia) (Update). *Otolaryngology–Head and Neck Surgery*. 2018;158(1_suppl). doi:10.1177/0194599817751030
2. Pynnonen MA, Gillespie MB, Roman B, et al. Clinical Practice Guideline: Evaluation of the Neck Mass in Adults. *Otolaryngology–Head and Neck Surgery*. 2017;157(2_suppl). doi:10.1177/0194599817722550
3. Shulman ST, Bisno AL, Clegg HW, et al. Clinical Practice Guideline for the Diagnosis and Management of Group A Streptococcal Pharyngitis: 2012 Update by the Infectious Diseases Society of America. *Clinical Infectious Diseases*. 2012;55(10). doi:10.1093/cid/cis629
4. ACR Appropriateness Criteria Dysphagia. Rev. 2018. <https://acsearch.acr.org/docs/69471/Narrative/>.
5. Belafsky, PC. Odynophagia a Warning Sign and Indication for Timely Endoscopy. August 1, 2014
6. Hwang C, Desai B, Desai A. Dysphagia and Odynophagia. *Primary Care for Emergency Physicians*. Published online December 1, 2016:89-98. doi:10.1007/978-3-319-44360-7_8

Table of Contents

Guideline

Obstetrical Ultrasound Imaging General Guidelines (OB-1)

Abbreviations and Glossary for OB Ultrasound Imaging Guidelines

General Guidelines (OB-1.0)

Inappropriate Use of OB Ultrasound (OB-1.2)

Ultrasound Code Selection (OB-1.3)

References (OB-1)

Uncertain Dates (OB-2)

Uncertain Dates/Unknown Last Menstrual Period (LMP) (OB-2.1)

References (OB-2)

Intrauterine Device (IUD) (OB-3)

Locate an Intrauterine Device (IUD) (OB-3.1)

References (OB-3)

Infertility (OB-4)

History of Infertility (OB-4.1)

Present Pregnancy with ART Treatment (IVF) (OB-4.2)

Recurrent Pregnancy Loss (OB-4.3)

References (OB-4)

Vaginal Bleeding and/or Abdominal/Pelvic Pain/Cramping (OB-5)

Acute Abdominal/Pelvic Pain (OB-5.1)

Vaginal Bleeding (OB-5.2)

Ectopic Pregnancy (OB-5.3)

Spontaneous Abortion/Threatened/Missed Abortion (OB-5.4)

Hydatidiform Mole (OB-5.5)

References (OB-5)

Fetal Aneuploidy and Anomaly Screening (OB-6)

First Trimester Screening (OB-6.1)

Second Trimester Screening (OB-6.2)

References (OB-6)

Fetal Anatomic Scan/Cervical Length Screening (OB-7)

Fetal Anatomic Scan (OB-7.1)

Fetal Anatomic Scan – Follow-up (OB-7.2)

Cervical Length Screening (OB-7.3)

References (OB-7)

Third Trimester Imaging (OB-8)

Third Trimester Imaging – Ultrasound (OB-8.1)

Reference (OB-8)

High Risk Pregnancy (OB-9)

High Risk General Information (OB-9.0)

High Risk Group One – Risk Factors (OB-9.1)

High Risk Group Two - Ultrasound Findings (OB-9.2)

High Risk Group Three – Pre-pregnancy BMI ≥ 30 kg/m² (OB-9.3)

High Risk Group Four – Macrosomia (OB-9.4)

High Risk Group Five – Zika and COVID-19 Virus (OB-9.5)

High Risk Group Six - Pre-Gestational or Early Diagnosed (≤ 20 weeks)

Diabetes (OB-9.6)

High Risk Group Seven Gestational Diabetes (OB-9.7)

Hypertensive Disorders in Pregnancy (OB-9.8)

History of Spontaneous Pre-Term Delivery/History of PPRM (OB-9.9)

History of Stillbirth (OB-9.10)

Short Interval Pregnancy (≤ 18 months between last delivery and conception of current pregnancy) (OB-9.11)

Detailed First Trimester Fetal Anatomic Scan (OB-9.12)

References (OB-9)

High Risk Medications and Substances (OB-10)

Potentially Teratogenic Medications/Substances (OB-10.1)

Medications/ Exposures Associated with Poor Pregnancy Outcome (OB-10.2)

References (OB-10)

Multiple Gestations (OB-11)

Suspected Multiple Gestations (OB-11.1)

Known Dichorionic Multiple Gestations (OB-11.2)

Known Monochorionic-Diamniotic or Monochorionic-Monoamniotic Multiple Gestations (OB-11.3)

References (OB-11)

Fetal Echocardiography (ECHO) (OB-12)

Fetal Echocardiography – Coding (OB-12.1)

Fetal Echocardiography - Indications for Fetal Conditions (OB-12.2)

Fetal Echocardiography - Indications for Maternal Conditions (OB-12.3)

Fetal Echocardiography - Indications for Medication or Drug Exposure (OB-12.4)

References (OB-12)

Fetal MRI (OB-13)

Indications for Fetal MRI (OB-13.1)

References (OB-13)

Abnormal Fetal Position/ Presentation and Pelvimetry (OB-14)

Abnormal Fetal Position or Presentation (OB-14.1)

Pelvimetry (OB-14.2)

References (OB-14)

Adnexal Mass/Uterine Fibroids and Uterine Anomalies (OB-15)

Adnexal Mass (OB-15.1)

Uterine Fibroids in Pregnancy (OB-15.2)

Uterine Anomalies in Pregnancy (OB-15.3)

References (OB-15)

Alloimmunization/Rh Isoimmunization/Other Causes of Fetal Anemia/ Parvo/Hydrops (OB-16)

Alloimmunization/Rh Isoimmunization (OB-16.1)

Exposure to Parvovirus B-19 (OB-16.2)

Twin Anemia Polycythemia Sequence (OB-16.3)

Other Fetal Hydrops/Nonimmune Hydrops (OB-16.4)

Other Causes of Fetal Anemia (OB-16.5)

References (OB-16)

Amniotic Fluid Abnormalities/ Oligohydramnios/Polyhydramnios (OB-17)

Amniotic Fluid Abnormalities (OB-17.1)

References (OB-17)

Cervical Insufficiency/Current Preterm Labor (OB-18)

Cervical Insufficiency (OB-18.1)

Cerclage in Place in Current Pregnancy (OB-18.2)

Current Preterm Labor (OB-18.3)

References (OB-18)

No Fetal Heart Tones/Decreased Fetal Movement (OB-19)

No Fetal Heart Tones (OB-19.1)

Decreased Fetal Movement (OB-19.2)

References (OB-19)

Fetal Growth Problems (FGR and Macrosomia) (OB-20)

Fetal Growth Restriction Current Pregnancy (OB-20.1)

Macrosomia – Large for Dates Current Pregnancy (OB-20.2)

References (OB-20)

Placental and Cord Abnormalities (OB-21)

Single Umbilical Artery (Two Vessel Cord) (OB-21.1)

Persistent Right Umbilical Vein (PRUV) (OB-21.2)

Placental/Cord Abnormalities (OB-21.3)

Subchorionic Hematoma/Hemorrhage (Placental Hematoma) (OB-21.4)
Suspected Abruption Placentae (OB-21.5)
Previa (Placenta Previa and Vasa Previa) (OB-21.6)
Placenta Accreta Spectrum (PAS): Accreta, Increta, Percreta (OB-21.7)
References (OB-21)

Late-term/Post-term Pregnancy (OB-22)

Late-term/Post-term Pregnancy (OB-22.1)
References (OB-22)

Preterm/Prelabor Rupture of Membranes (OB-23)

Current Preterm/Prelabor Rupture of Membranes (PPROM) (OB-23.1)
Current Prelabor Rupture of Membranes (PROM) (OB-23.2)
References (OB-23)

Previous C-section or History of Uterine Scar (OB-24)

Previous C-section or History of Uterine Scar (OB-24.1)
References (OB-24)

Termination of Pregnancy – Imaging (OB-25)

Imaging for Planned Pregnancy Termination (OB-25.1)
References (OB-25)

Trauma (OB-26)

Trauma – Imaging (OB-26.1)
References (OB-26)

Unequal Fundal Size and Dates (OB-27)

Unequal Fundal Size and Dates (OB-27.1)
References (OB-27)

Procedure Coding Basics for Established Pregnancy (OB-28)

Procedure Coding Basics for Established Pregnancy General Considerations (OB-28.1)
Required Elements for Complete First Trimester Ultrasound (OB-28.2)
Required Elements for Second or Third Trimester Fetal Anatomic Evaluation Ultrasound (OB-28.3)
Required Elements for a Detailed Fetal Anatomic Evaluation Ultrasound (OB-28.4)
Fetal Nuchal Translucency (OB-28.5)
Limited and Follow-up Studies (OB-28.6)
Obstetric Transvaginal Ultrasound (OB-28.7)
Biophysical Profile (BPP) (OB-28.8)
Fetal Doppler (OB-28.9)
Duplex Scan (OB-28.10)
Fetal Echocardiography (OB-28.11)

3D and 4D Rendering (OB-28.12)
Required Elements for a Detailed First Trimester Fetal Anatomic
Evaluation Ultrasound (OB-28.13)
References (OB-28)

Obstetrical Ultrasound Imaging General Guidelines (OB-1)

Abbreviations and Glossary for OB Ultrasound Imaging Guidelines

OB.GG.0001.00.A

v1.0.2024

Abbreviations and Glossary for OB Ultrasound Imaging Guidelines	
ACOG	American College of Obstetricians and Gynecologists
AFI	amniotic fluid index
AFP	alpha-fetoprotein
ART	Assisted Reproductive Technology
B-mode (brightness)	two dimensional imaging procedure, B-mode ultrasound is the basis for all static and real time B-scan images
BPP	Biophysical Profile includes the ultrasound variables: fetal breathing, muscle tone, and movement as well as amniotic fluid volume. BPP can be performed with or without a non-stress test (NST) which involves fetal heart rate (FHR) monitoring.
CST	contraction stress test
D & C/D & E	dilatation and curettage/ Dilation and Evacuation
Dichorionic twins	twins having distinct chorions (membrane that forms the fetal part of the placenta), including monozygotic twins (from one oocyte [egg]) separated within 72 hours of fertilization and all dizygotic twins (from two oocytes fertilized at the same time
Doppler	involves measuring a change in frequency when the motion of vascular flow is measured
EDC	Estimated Date of Confinement; determined from the first day of the last menstrual cycle
EDD	Estimated Date of Delivery

Abbreviations and Glossary for OB Ultrasound Imaging Guidelines	
FGR	Fetal growth restriction; an estimated weight of the fetus at or below 10th percentile for gestational age; and/or abdominal circumference of the fetus at or below 10th percentile for gestational age
FHR	fetal heart rate
hCG	human chorionic gonadotropin
IDDM	insulin-dependent diabetes mellitus
M-mode	ultrasound imaging technique in which structure movement can be depicted in a wave-like manner; primarily used in cardiac and fetal cardiac imaging
Macrosomia	estimated fetal weight of greater than 4000 or 4500 grams
Monochorionic twins	twins developed from one oocyte (egg) developing with a single chorions (membrane that forms the fetal part of the placenta)
NICU	Neonatal Intensive Care Unit
NST	fetal non-stress test
Oligohydramnios	diminished amniotic fluid volume (AFV) for gestational age; definitions include: maximum deepest pocket of ≤ 2 cm and/or AFI of ≤ 5 cm or $<$ the 5 th percentile for gestational age if < 30 weeks.
PACS	Picture Archiving and Communications System
Polyhydramnios	AFI ≥ 24 cm or maximum vertical pocket of ≥ 8 cm
PROM	preterm rupture of membranes
Quad screen	alpha-fetoprotein (AFP), estriol, human chorionic gonadotropin (hCG), inhibin A

Abbreviations and Glossary for OB Ultrasound Imaging Guidelines

Real time scan	considered the most common type of ultrasound; a 2-dimensional scan that reflects structure and motion over time, scanning and display of images are run at a sufficiently rapid rate so that moving structures can be viewed moving at their natural rate; frame rates ≥ 15 frames per second are considered “real time”
-----------------------	--

General Guidelines (OB-1.0)

OB.GG.0001.0.A

v1.0.2024

- This document offers an in-depth, indication driven guide to obstetrical imaging
- The use of an obstetrical CPT code is only indicated with a positive pregnancy test or an otherwise confirmed pregnancy. It is not appropriate to report non-obstetrical, pelvic ultrasound procedure codes (CPT® 76830, CPT® 76856, and CPT® 76857) with a positive pregnancy test or a confirmed pregnancy
- An evaluation of pregnancy with a history and physical exam (an initial office visit) is necessary prior to obstetric ultrasound imaging requests
 - The following information must be submitted with each request:
 - Expected date of delivery
 - Gestational age at date of service
 - Results of prior ultrasound studies if available
- Ultrasound assessment is an accurate method of determining gestational age, fetal number, viability, and placental location, and it is recommended for all pregnant patients
 - Though fetal anatomy survey (CPT® 76805/CPT® 76811 if high-risk) can be performed as early as 14 weeks gestation, per ACOG, in the absence of other specific indications, the optimal time for a single ultrasound examination is at 18 to 22 weeks of gestation. This timing allows for a survey of fetal anatomy in most females and an accurate estimation of gestational age.²
 - For a Normal (Low Risk) Pregnancy report a fetal anatomy ultrasound CPT® 76805 if ≥ 16 weeks
 - If pregnancy is **High Risk** can report:
 - A detailed first-trimester obstetric ultrasound^{3,15} [requested as CPT® 76801 plus CPT® 76813 (and CPT® 76802 plus CPT® 76814 for each additional fetus)] between 12 weeks 0 days and 13 weeks 6 days (if indicated), See **Detailed First Trimester Fetal Anatomic Scan (OB-9.12)**, and
 - A detailed fetal anatomy ultrasound (CPT® 76811) if ≥ 16 weeks
 - These high risk scans are indication driven and are generally performed by a Maternal Fetal Medicine (MFM) specialist/Perinatologist, or a Radiologist at an AIUM or ACR accredited facility. See **High Risk Pregnancy (OB-9)**
 - Current ACOG and SMFM guidelines state that cervical length (CL) screening in singleton gestations without a prior spontaneous preterm birth (PTB) cannot yet be universally mandated.
 - Transvaginal ultrasound (CPT® 76817) can be performed if the transabdominal CL is ≤ 3.6 cm
 - Fetal Nuchal Translucency (CPT® 76813) can be performed if Cell-Free DNA (cfDNA) is not planned or has not already been performed, as they are both screening tools for fetal aneuploidy

Inappropriate Use of OB Ultrasound (OB-1.2)

OB.GG.0001.2.A

v1.0.2024

Obstetrical ultrasound studies cannot be authorized for payment for individuals who do not have a positive pregnancy test or clinical evidence of a pregnancy (fetal heart tones)

- Obstetrical ultrasound is **not** medically indicated for the following:
 - Sex determination only
 - To provide a keepsake or souvenir picture

Ultrasound Code Selection (OB-1.3)

OB.GG.0001.3.A

v1.0.2024

- See **Procedure Coding Basics for Established Pregnancy (OB-28)**
 - It is not appropriate to report non-obstetrical pelvic ultrasound procedure codes (CPT® 76830, CPT® 76856, and CPT® 76857) with a positive pregnancy test or confirmed pregnancy

CPT® Code Guidance

CPT® 76801 and CPT® 76802 (for each additional fetus) are reported for complete studies performed during the first trimester (<14 weeks). These codes should only be used once per pregnancy unless the mother changes to a new medical caregiver at a new office and there is a new medical indication for ultrasound.

CPT® 76813 and CPT® 76814 (each additional fetus) are used to report nuchal translucency screening: an ultrasound measurement of the clear (translucent) space at the back of the fetal neck to assess risk for Down Syndrome (Trisomy 21), Trisomy 18, and other genetic disorders.

CPT® 76801 plus CPT® 76813 (and CPT® 76802 **plus** CPT® 76814 for each additional fetus) when billed together, are used to report a detailed first-trimester obstetric ultrasound examination between 12 weeks 0 days and 13 weeks 6 days.^{3,15}

- This indication-driven detailed first trimester fetal anatomic evaluation is generally performed by those with special skills to perform this study, such as a Maternal Fetal Medicine specialist (Perinatologist), or a Radiologist with advanced training in fetal imaging.
- These codes should only be used once per pregnancy unless the mother changes to a new medical caregiver at a new office and there is a new medical indication for ultrasound. See **Detailed First Trimester Fetal Anatomic Scan (OB-9.12)**

CPT® 76805 and CPT® 76810 (for each additional fetus) are used to report complete studies (anatomy scan) performed during the second and third trimester, in a normal (low risk) pregnancy. These studies should only be used once per pregnancy unless the mother changes to a new medical caregiver at a new office and there is a new medical indication for ultrasound.

CPT® 76811 and CPT® 76812 (for each additional fetus) describe a detailed fetal anatomic survey and are used only when the study includes this service. These studies should only be used once per pregnancy unless the mother changes to a new medical caregiver at a new office and there is a new medical indication for ultrasound.

This detailed fetal anatomic evaluation is generally performed by those with special skills to perform this study, such as a Maternal Fetal Medicine specialist (Perinatologist), or a Radiologist with advanced training in fetal imaging.

In circumstances where a detailed fetal anatomy (CPT® 76811) is indicated but access is limited due to geographic or other constraints, a standard fetal anatomy survey (CPT® 76805) can be authorized instead at the appropriate gestational age.

CPT® Code Guidance

CPT® 76817 is used to report a transvaginal ultrasound. The other OB ultrasound codes are used for transabdominal studies.

CPT® 76816 is used to report a follow up study, such as a growth scan or follow up on anatomy when more than one area requires reexamination.

- CPT® 76816 [should not be performed prior to a CPT® 76801 or an anatomy scan CPT® 76805 (normal pregnancy) or Detailed anatomy scan CPT® 76811 (high risk pregnancy)]
- CPT® 76816 should not be done on same date of service as CPT® 76815

CPT® 76815 describes a limited or ‘quick look’ study

- It can be used at any gestational age for various indications, including quick look for AFI assessment, fetal heart-beat, fetal position, placental location etc.
- It can be used specifically for ‘dating’ (when indicated) in those that don’t meet gestational age criteria for dating with CPT® 76801 or are too early for anatomy scan (i.e. >14 weeks but <16 weeks)
- It is also used to report a modified BPP.
- Note: CPT® 76815 should never be reported with complete studies CPT® 76801/CPT® 76802, CPT® 76805/CPT® 76810, CPT® 76811/CPT® 76812, or with CPT® 76816 or BPP (CPT® 76818 and CPT® 76819).

CPT® 76818 (includes non-stress test) and CPT® 76819: are used to report a Biophysical profile (BPP), a test for antepartum fetal surveillance (A BPP is not typically performed before 26 weeks due to lack of fetal brain stem maturity prior to this gestational age).

CPT® 76820 describes Doppler velocimetry of the umbilical artery.

CPT® 76821 describes Doppler velocimetry of the middle cerebral artery.

CPT® 76825 describes fetal echocardiography and and CPT® 76827 describes the Doppler portion of the echocardiogram. These codes should only be used once per pregnancy unless the mother changes to a new medical caregiver at a new office or there is a new medical indication for ultrasound.

CPT® 76826 describes a follow up fetal echocardiography and CPT® 76828 describes a follow up Doppler portion of the echocardiogram.

CPT® 93325 can be added for color mapping in conjunction with fetal echocardiography procedures.

CPT® 93976 describes a limited duplex scan and is used during pregnancy for characterizing the pattern and direction of blood flow in arteries and veins. It can be used to report fetal umbilical-placental flow evaluation (accreta or other placental or cord abnormalities).

CPT® 74712 and CPT® 74713 (for each additional fetus) are used to report a fetal MRI (indicated for more in depth imaging of certain fetal abnormalities).

Background and Supporting Information

- ACOG recommendations for imaging during pregnancy and lactation:
 - Ultrasonography and magnetic resonance imaging (MRI) are not associated with risk and are the imaging techniques of choice for the pregnant patient, but they should be used prudently and only when use is expected to answer a relevant clinical question or otherwise provide medical benefit to the patient.
 - With few exceptions, radiation exposure through radiography (Xrays), computed tomography (CT) scan, or nuclear medicine imaging techniques is at a dose much lower than the exposure associated with fetal harm. If these techniques are necessary in addition to ultrasound or MRI or are more readily available for the diagnosis in question, they should not be withheld from a pregnant patient.
 - The use of gadolinium contrast with MRI should be limited; it should be used as a contrast agent in a pregnant female only if it significantly improves diagnostic performance and is expected to improve fetal or maternal outcome.
 - With regards to iodinated IV contrast media, “it is generally recommended that contrast only be used if absolutely required to obtain additional diagnostic information that will affect the care of the fetus or female during pregnancy.”
- In circumstances where the individual is deemed to have an increased risk for a fetal abnormality and does not have access to a provider who can perform a fetal anatomic ultrasound examination (CPT® 76811) **due to geographic or other constraints**, a standard (after first trimester) fetal anatomic ultrasound examination (CPT® 76805) can be authorized instead.
- CPT® 76816 [should not be performed prior to a CPT® 76801 or an anatomy scan CPT® 76805 (normal pregnancy) or Detailed anatomy scan CPT® 76811 (high risk pregnancy)], and is typically not performed prior to 14 weeks gestation.
- Typically all components of the BPP (CPT® 76818 and CPT® 76819), such as breathing, are not present until ≥ 26 weeks gestation. However, a modified BPP (CPT® 76815) can be utilized sooner in certain high risk cases but should not be done prior to 22 weeks.
- SMFM suggest that ductus venosus, middle cerebral artery, or uterine artery Doppler use for routine clinical management of early- or late-onset FGR *is not recommended*
- The minimal use of color Doppler alone (CPT® 93976), when performed for anatomical structure identification, during a standard ultrasound procedure, is not separately reimbursable.

References (OB-1)

v1.0.2024

1. Reddy UM, Abuhamad AZ, Levine D, Saade GR. Fetal Imaging: Executive Summary of a Joint Eunice Kennedy Shriver National Institute of Child Health and Human Development, Society for Maternal-Fetal Medicine, American Institute of Ultrasound in Medicine, American College of Obstetricians and Gynecologists, American College of Radiology, Society for Pediatric Radiology, and Society of Radiologists in Ultrasound Fetal Imaging Workshop. *Obstetrical & Gynecological Survey*. 2014;69(8):453-455. doi:10.1097/01.ogx.0000453817.62105.4a
2. Practice Bulletin No. 175: Ultrasound in Pregnancy. *Obstet Gynecol*. 2016;128(6):e241-e256. Reaffirmed 2022. doi:10.1097/AOG.0000000000001815
3. AIUM Practice Parameter for the Performance of Detailed Diagnostic Obstetric Ultrasound Examinations Between 12 Weeks 0 Days and 13 Weeks 6 Days. *Journal of Ultrasound in Medicine*. Published online August 27, 2020. doi:10.1002/jum.15477
4. AIUM-ACR-ACOG-SMFM-SRU Practice Parameter for the Performance of Standard Diagnostic Obstetric Ultrasound Examinations. *Journal of Ultrasound in Medicine*. 2018;37(11). doi:10.1002/jum.14831
5. AIUM Practice Parameter for the Performance of Detailed Second- and Third-Trimester Diagnostic Obstetric Ultrasound Examinations. *Journal of Ultrasound in Medicine*. 2019;38(12):3093-3100. doi:10.1002/jum.15163
6. AIUM Practice Parameter for the Performance of Limited Obstetric Ultrasound Examinations by Advanced Clinical Providers. *Journal of Ultrasound in Medicine*. 2018;37(7):1587-1596. doi:10.1002/jum.14677
7. AIUM Practice Parameter for the Performance of Fetal Echocardiography. *Journal of Ultrasound in Medicine*. 2019;39(1). doi:10.1002/jum.15188
8. Martins JG, Biggio JR, Abuhamad A. Society for Maternal-Fetal Medicine (SMFM) Consult Series #52: Diagnosis and Management of Fetal Growth Restriction. *American Journal of Obstetrics and Gynecology*. 2020. doi:10.1016/j.ajog.2020.05.010
9. ACOG Practice Bulletin No. 229: Antepartum Fetal Surveillance. *Obstetrics & Gynecology* 2021;137:e116-27. doi:10.1097/aog.0000000000004410
10. ACOG Committee Opinion No. 828. Indications for outpatient antenatal fetal surveillance. American College of Obstetricians and Gynecologists. *Obstetrics & Gynecology* 2021;137:e177-97. doi:10.1097/aog.0000000000004407
11. Society for Maternal and Fetal Medicine (SMFM), coding committee, December 2012. SMFM's white paper on Ultrasound Code 76811
12. Natale R, Nasello-Paterson C, Connors G. Patterns of fetal breathing activity in the human fetus at 24 to 28 weeks of gestation. *American Journal of Obstetrics and Gynecology*. 1988;158(2):317-321. doi:10.1016/0002-9378(88)90146-9
13. ACOG committee opinion Number 723. Guidelines for diagnostic imaging during pregnancy and lactation. *Obstetrics & Gynecology*. 2017;130(4):e210-e216. Reaffirmed 2021. doi:10.1097/aog.0000000000002355
14. ACOG Practice bulletin Number 226. Screening for Fetal Chromosomal Abnormalities. *Obstetrics & Gynecology*. 2020;136(4):e48-e69. doi:10.1097/aog.0000000000004084
15. SMFM Coding Committee White Paper: Coding for the "new" First Trimester Detailed Diagnostic Obstetric Ultrasound. Society for Maternal Fetal Medicine website. 6-2021
16. Cummings J; Committee on Fetus and Newborn. Antenatal Counseling Regarding Resuscitation and Intensive Care Before 25 Weeks of Gestation. *Pediatrics*. 2015 Sep;136(3):588-95. doi: 10.1542/peds.2015-2336. PMID: 26324869.

Uncertain Dates (OB-2)

Uncertain Dates/Unknown Last Menstrual Period (LMP) (OB-2.1)

OB.UD.0002.1.A

v1.0.2024

- If there is a difference in the clinical size of the uterus on pelvic exam and the estimated gestational age calculated by the LMP **or** there is an uncertain/unknown LMP **or** there have been irregular periods in the last year, one of the following can be performed:
 - If <14 weeks by pelvic exam CPT® 76801 one time (plus CPT® 76802 for each additional fetus) and/or CPT® 76817 one time if a complete ultrasound has not yet been performed
 - CPT®76801 is preferred for dating, but if this is unable to be completed then CPT® 76815 **and/or** CPT® 76817 for a transvaginal ultrasound is indicated
 - If ≥14 weeks by abdominal exam CPT® 76815 or CPT® 76805 (CPT® 76811 if high risk) if complete fetal anatomic scan has not yet been performed

Background and Supporting Information

- CPT® 76815 should never be reported with complete studies CPT® 76801/CPT® 76802, CPT® 76805/CPT® 76810 or CPT® 76811/CPT® 76812 or with CPT® 76816 or BPP (CPT® 76818 and CPT® 76819).
- Though a fetal anatomy survey (CPT® 76805/CPT® 76811) can be performed as early as 14 weeks gestation, per ACOG, in the absence of other specific indications, it is optimally performed at 18 to 22 weeks of gestation.¹

References (OB-2)

v1.0.2024

1. Practice Bulletin No. 175: Ultrasound in Pregnancy. Obstetrics & Gynecology. 2016;128(6):e241-e256. Reaffirmed 2022. doi:10.1097/AOG.0000000000001815
2. Reddy UM, Abuhamad AZ, Levine D, Saade GR. Fetal Imaging: Executive Summary of a Joint Eunice Kennedy Shriver National Institute of Child Health and Human Development, Society for Maternal-Fetal Medicine, American Institute of Ultrasound in Medicine, American College of Obstetricians and Gynecologists, American College of Radiology, Society for Pediatric Radiology, and Society of Radiologists in Ultrasound Fetal Imaging Workshop. Obstetrics & Gynecology. 2014;123(5):1070-1082. doi:10.1097/aog.0000000000000245
3. ACOG Committee Opinion No 700: Methods for Estimating the Due Date. Obstetrics & Gynecology. 2017;129(5):e150-e154. Reaffirmed 2022. doi:10.1097/AOG.0000000000002046
4. ACOG Committee Opinion Number 688: Management of Suboptimally Dated Pregnancies, Obstetrics & Gynecology. 2017;129(3). Reaffirmed 2021. doi:10.1097/AOG.0000000000001949

Intrauterine Device (IUD) (OB-3)

Locate an Intrauterine Device (IUD) (OB-3.1)

OB.ID.0003.1.A

v1.0.2024

- CPT® 76801 and/or CPT® 76817 if <14 weeks and a complete ultrasound has not yet been performed or
- CPT® 76815 and/or CPT® 76817 if complete ultrasound has already been performed or if ≥14 weeks.
- CPT® 76805 (CPT® 76811 if otherwise indicated), if ≥16 weeks when an anatomy ultrasound (CPT® 76805/CPT® 76811) has not yet been performed, and
- 3-D Rendering (CPT® 76376/CPT® 76377) can be added for suspected retained IUD
- For continued pregnancy with retained IUD⁴ image as per **High Risk Group One – Risk Factors (OB 9.1)**

Background and Supporting Information

- CPT® 76815 should never be reported with complete studies CPT® 76801/CPT® 76802, CPT® 76805/CPT® 76810 or CPT® 76811/CPT® 76812 or with CPT® 76816 or BPP (CPT® 76818 and CPT® 76819).
- Though fetal anatomy survey (CPT® 76805/CPT® 76811) can be performed as early as 14 weeks gestation, per ACOG, in the absence of other specific indications, it is optimally performed at 18 to 22 weeks of gestation.

References (OB-3)

v1.0.2024

1. Nowitzki KM, Hoimes ML, Chen B, Zheng LZ, Kim YH. Ultrasonography of intrauterine devices. *Ultrasonography*. 2015;34(3):183-194. doi:10.14366/usg.15010
2. ACOG Committee Opinion No 672 Clinical challenges of long-acting reversible contraceptive methods. *Obstetrics & Gynecology*. 2016;128(3):e69-e77. Reaffirmed 2020. doi:10.1097/aog.0000000000001644
3. Prabhakaran S and Chuang A. In-office retrieval of intrauterine contraceptive devices with missing strings. *Contraception*. 2011;83(2):102-106. doi:10.1016/j.contraception.2010.07.004
4. ACOG Practice Bulletin 186: Long-Acting Reversible Contraception: Implants and Intrauterine Devices. *Obstet Gynecol*. 2017 Nov;130(5):e251-e269. Reaffirmed 2021. doi: 10.1097/AOG

Infertility (OB-4)

History of Infertility (OB-4.1)

OB.IF.0004.1.A

v1.0.2024

- If the current or a prior pregnancy was conceived using an ovulation induction agent (for example Clomid) and/or by intrauterine insemination (IUI), **or**
- If there is a history of infertility or history of IVF in a **prior** pregnancy
- Report:
 - Complete first trimester ultrasound CPT® 76801 [plus CPT® 76802 for each additional fetus] if <14 weeks and a complete ultrasound has not yet been performed, **and/or** CPT® 76817 for a transvaginal ultrasound
 - CPT® 76801 is preferred for dating, but if this is unable to be completed then CPT® 76815 **and/or** CPT® 76817 for a transvaginal ultrasound is indicated
 - CPT® 76805 if ≥16 weeks, when complete fetal anatomic scan has not yet been performed
 - Then, follow normal/low risk imaging See **Fetal Anatomic Scan (OB-7.1)**
- Repeat ultrasound is not usually necessary unless there are new clinical indications

Background and Supporting Information

- CPT® 76815 should never be reported with complete studies CPT® 76801/CPT® 76802, CPT® 76805/CPT® 76810 or CPT® 76811/CPT® 76812 or with CPT® 76816 or BPP (CPT® 76818 and CPT® 76819).
- Though fetal anatomy survey (CPT® 76805/CPT® 76811) can be performed as early as 14 weeks gestation, per ACOG, in the absence of other specific indications, it is optimally performed at 18 to 22 weeks of gestation.

Present Pregnancy with ART Treatment (IVF) (OB-4.2)

OB.IF.0004.2.A
v1.0.2024

- If the **current** pregnancy was conceived by IVF, can perform
 - Complete first trimester ultrasound CPT® 76801 [plus CPT® 76802 for each additional fetus] if <14 weeks and a complete ultrasound has not yet been performed, **and/or** CPT® 76817 for a transvaginal ultrasound
 - CPT® 76801 is preferred for dating, but if this is unable to be completed then CPT® 76815 **and/or** CPT® 76817 for a transvaginal ultrasound is indicated
 - A detailed first-trimester obstetric ultrasound [requested as CPT® 76801 plus CPT® 76813 (and CPT® 76802 plus CPT® 76814 for each additional fetus)] between 12 weeks 0 days and 13 weeks 6 days⁶
 - Detailed Fetal Anatomic Scan CPT® 76811 ≥16 weeks
 - Initial Fetal echo CPT® 76825 **and/or** CPT® 76827 +/- CPT® 93325 at ≥16 weeks
 - A growth scan (CPT® 76816) is indicated in the third trimester (≥28 weeks)
 - If additional high risk factors are noted, imaging as per high risk factor (OB 9.0)
 - Starting at 36 weeks, weekly BPP (CPT® 76818 or CPT® 76819) or modified BPP (CPT® 76815)

Background and Supporting Information

- CPT® 76815 should never be reported with complete studies CPT® 76801/CPT® 76802, CPT® 76805/CPT® 76810 or CPT® 76811/CPT® 76812 or with CPT® 76816 or BPP (CPT® 76818 and CPT® 76819).
- Though fetal anatomy survey (CPT® 76805/CPT® 76811) can be performed as early as 14 weeks gestation, per ACOG, in the absence of other specific indications, it is optimally performed at 18 to 22 weeks of gestation.

Recurrent Pregnancy Loss (OB-4.3)

OB.IF.0004.3.A

v1.0.2024

- If there is a history of at least 2 consecutive or 3 non-consecutive clinical miscarriages/losses at <20 weeks gestation
 - Complete first trimester ultrasound CPT® 76801 [plus CPT® 76802 for each additional fetus] if <14 weeks and a complete ultrasound has not yet been performed, and/or CPT® 76817
 - CPT® 76801 is preferred for dating, but if this is unable to be completed then CPT® 76815 **and/or** CPT® 76817 for a transvaginal ultrasound is indicated
 - Detailed Fetal Anatomic Scan CPT® 76811 ≥16 weeks
 - Starting at 22 weeks follow-up growth scans (CPT® 76816) every 3 to 6 weeks
 - Starting at 36 weeks, weekly BPP (CPT® 76818 or CPT® 76819) or modified BPP (CPT® 76815)
- If history of one or more 2nd trimester loss (14 to 24 weeks gestation)
 - CPT® 76815 **and/or** CPT® 76817 every 2 weeks from 16 to 24 weeks.⁵ See **Cervical Insufficiency (OB 18.1)**

Background and Supporting Information

- CPT® 76815 should never be reported with complete studies CPT® 76801/CPT® 76802, CPT® 76805/CPT® 76810 or CPT® 76811/CPT® 76812 or with CPT® 76816 or BPP (CPT® 76818 and CPT® 76819).
- Though fetal anatomy survey (CPT® 76805/CPT® 76811) can be performed as early as 14 weeks gestation, per ACOG, in the absence of other specific indications, it is optimally performed at 18 to 22 weeks of gestation.

References (OB-4)

v1.0.2024

1. Kondapalli LA, Perales-Puchalt A. Low birth weight: is it related to assisted reproductive technology or underlying infertility? *Fertility and Sterility*. 2013;99(2):303-310. doi:10.1016/j.fertnstert.2012.12.035
2. Definitions of infertility and recurrent pregnancy loss: a committee opinion. *Fertility and Sterility*. 2020;113(3):533-535. doi:10.1016/j.fertnstert.2019.11.025
3. ACOG Practice Bulletin No. 200. Early pregnancy loss. *Obstetrics & Gynecology*. 2018;132(5). Reaffirmed 2021. doi:10.1097/aog.0000000000002899
4. ACOG Committee Opinion No. 828. Indications for outpatient antenatal fetal surveillance. American College of Obstetricians and Gynecologists. *Obstetrics & Gynecology*. 2021;137:e177-97. doi:10.1097/aog.0000000000004407
5. Mcintosh J, Feltovich H, Berghella V, Manuck T. The role of routine cervical length screening in selected high- and low-risk women for preterm birth prevention. Society for Maternal-Fetal Medicine (SMFM) Consult Series #40. *American Journal of Obstetrics and Gynecology*. 2016;215(3). doi:10.1016/j.ajog.2016.04.027
6. AIUM Practice Parameter for the Performance of Detailed Diagnostic Obstetric Ultrasound Examinations Between 12 Weeks 0 Days and 13 Weeks 6 Days. *Journal of Ultrasound in Medicine*. Published online August 27, 2020. doi:10.1002/jum.15477
7. Society for Maternal-Fetal Medicine (SMFM). Electronic address: pubs@smfm.org; Ghidini A, Gandhi M, McCoy J, Kuller JA; Publications Committee. Society for Maternal-Fetal Medicine Consult Series #60: Management of pregnancies resulting from in vitro fertilization. *Am J Obstet Gynecol*. 2022 Mar;226(3):B2-B12. doi: 10.1016/j.ajog.2021.11.001.

Vaginal Bleeding and/or Abdominal/Pelvic Pain/Cramping (OB-5)

Acute Abdominal/Pelvic Pain (OB-5.1)

OB.AP.0005.1.A

v1.0.2024

For acute abdominal/pelvic pain:

At the time of complaint, can perform:

- Complete first trimester ultrasound CPT® 76801 and/or CPT® 76817 if complete ultrasound has not yet been performed, and <14 weeks **or**
- CPT® 76815 and/or CPT® 76817 **or**
- CPT® 76805 (CPT® 76811 if otherwise indicated), if ≥14 weeks when an anatomy ultrasound (CPT® 76805/CPT® 76811) has not yet been performed **or**
- CPT® 76816 (if an anatomy ultrasound CPT® 76805 or CPT® 76811 has previously been performed and at least 2 weeks since anatomy ultrasound)
- Repeat ultrasound is not usually necessary unless there are new indications.
- Note: Above imaging for acute onset abdominal-pelvic pain, NOT for contraction pain/rule out labor. See **Current Preterm Labor (OB-18.3)**

Background and Supporting Information

- CPT® 76815 should never be reported with complete studies CPT® 76801/CPT® 76802, CPT® 76805/CPT® 76810 or CPT® 76811/CPT® 76812 or with CPT® 76816 or BPP (CPT® 76818 and CPT® 76819).
- Though fetal anatomy survey (CPT® 76805/CPT® 76811) can be performed as early as 14 weeks gestation, per ACOG, in the absence of other specific indications, it is optimally performed at 18 to 22 weeks of gestation.

Vaginal Bleeding (OB-5.2)

OB.AP.0005.2.A

v1.0.2024

First Trimester

At the time of complaint, can perform:

- Complete first trimester ultrasound CPT® 76801 and/or CPT® 76817 if complete ultrasound has not yet been performed, and <14 weeks **or**
- CPT® 76815 and/or CPT® 76817
- Repeat ultrasound is not usually necessary unless there are new indications.

Second and Third Trimesters

At the time of complaint, can perform:

- CPT® 76815 and/or CPT® 76817 **or**
- CPT® 76805/CPT® 76811 if indicated (plus CPT® 76812 for each additional fetus) if ≥14 weeks, if fetal anatomic scan has not yet been performed, and/or CPT® 76817 **or**
- CPT® 76816 and/or CPT® 76817 if fetal anatomy scan CPT® 76805/CPT® 76811 has been performed
- Plus CPT® 93976 (limited duplex scan) if requested [See **Placental and Cord Abnormalities (OB-21)**].
- BPP (CPT® 76818 or CPT® 76819) can be considered starting at 26 weeks.
- Repeat ultrasound is not usually necessary unless there are new indications
- For suspected placental abruption, See **Suspected Abruption Placentae (OB-21.5)**
- CPT® 76821 if vaginal bleeding with +KB (Kleihauer-Betke) (if fetomaternal hemorrhage – at risk for fetal anemia and hydrops)

Background and Supporting Information

- CPT® 76815 should never be reported with complete studies CPT® 76801/CPT® 76802, CPT® 76805/CPT® 76810 or CPT® 76811/CPT® 76812 or with CPT® 76816 or BPP (CPT® 76818 and CPT® 76819).
- Though fetal anatomy survey (CPT® 76805/CPT® 76811) can be performed as early as 14 weeks gestation, per ACOG, in the absence of other specific indications, it is optimally performed at 18 to 22 weeks of gestation.

Ectopic Pregnancy (OB-5.3)

OB.AP.0005.3.A

v1.0.2024

Ectopic Pregnancy

First Trimester

- If there is a history of an ectopic pregnancy or
- If there are abnormally rising hCG titers (non-doubling hCG), or
- If there are signs or symptoms of ectopic pregnancy, e.g. pain and/or bleeding.
- Report:
 - Complete first trimester ultrasound CPT® 76801 and/or CPT® 76817 if complete ultrasound has not yet been performed, and is <14 weeks **or**
 - CPT® 76815 and/or CPT® 76817
 - Plus Color Doppler ultrasonography (CPT® 93976) if an adnexal mass is confirmed
 - If a cornual (interstitial) ectopic or C-section scar ectopic pregnancy is suspected^{5,6}
 - CPT® 76376 or CPT® 76377, and/or CPT® 93976 as add-on codes
 - MRI Pelvis without contrast (CPT® 72195) if ultrasound is inconclusive.
 - See **3D and 4D Rendering (OB 28.12)** and **Previous C-section or History of Uterine Scar (OB 24.1)**
- If ectopic pregnancy is being treated non-surgically with Methotrexate:
 - If symptomatic, see **Vaginal Bleeding (OB-5.2)** and/or **Acute Abdominal/Pelvic Pain (OB-5.1)** or the imaging guidelines above for ectopic pregnancy
 - If bHCG is not declining appropriately with treatment, see the imaging guidelines above for ectopic pregnancy

Background and Supporting Information

- Cornual (interstitial) pregnancies pose a significant high morbidity/mortality risk due to massive intraperitoneal bleeding, and are often difficult to diagnose. Conventional sonography still remains the primary diagnostic tool, but 3D US and MRI are being utilized more frequently to aid in earlier detection and treatment.
- CPT® 76815 should never be reported with complete studies CPT® 76801/CPT® 76802, CPT® 76805/CPT® 76810 or CPT® 76811/CPT® 76812 or with CPT® 76816 or BPP (CPT® 76818 and CPT® 76819).
- Though fetal anatomy survey (CPT® 76805/CPT® 76811) can be performed as early as 14 weeks gestation, per ACOG, in the absence of other specific indications, it is optimally performed at 18 to 22 weeks of gestation

Spontaneous Abortion/Threatened/Missed Abortion (OB-5.4)

OB.AP.0005.4.A

v1.0.2024

Spontaneous Abortion/Threatened/Missed Abortion

- To evaluate for threatened or missed abortion:
 - Complete first trimester ultrasound CPT® 76801 and/or CPT® 76817 if complete ultrasound has not yet been performed, and is <14 weeks **or**
 - CPT® 76815 and/or CPT® 76817 **or**
 - CPT® 76805/CPT® 76811 if indicated (plus CPT® 76812 for each additional fetus), if ≥14 weeks when complete fetal anatomic scan has not yet been performed, and/or CPT® 76817
 - Repeat ultrasound (CPT® 76815 and/or CPT® 76817) can be repeated weekly if hCG is rising or not falling, or if unable to confirm a viable IUP (fetal pole with cardiac activity)
 - Ultrasound imaging can be repeated earlier than seven days if there are new symptoms
- For complete spontaneous abortion, ultrasound is generally not indicated if there is no pain, or ongoing bleeding, and hCG levels are decreasing.

Background and Supporting Information

- CPT® 76815 should never be reported with complete studies CPT® 76801/CPT® 76802, CPT® 76805/CPT® 76810 or CPT® 76811/CPT® 76812 or with CPT® 76816 or BPP (CPT® 76818 and CPT® 76819).
- Though fetal anatomy survey (CPT® 76805/CPT® 76811) can be performed as early as 14 weeks gestation, per ACOG, in the absence of other specific indications, it is optimally performed at 18 to 22 weeks of gestation

Hydatidiform Mole (OB-5.5)

OB.AP.0005.5.A

v1.0.2024

Hydatidiform Mole

First, Second and Third Trimester

- Ultrasound can be performed for diagnosis of hydatidiform mole
 - Complete first trimester ultrasound CPT® 76801 and/or CPT® 76817 if complete ultrasound has not yet been performed, and is <14 weeks, **or**
 - CPT® 76815 and/or CPT® 76817 **or**
 - CPT® 76805/CPT® 76811 if indicated (plus CPT® 76812 for each additional fetus) if ≥14 weeks, when complete fetal anatomic scan has not yet been performed, and/or CPT® 76817
 - CPT® 76830 and CPT® 76856 or CPT® 76857 if hCG titers are not decreasing as expected, or are increasing following treatment, or if there is onset of pain despite falling hCG titers. See **Molar Pregnancy and GTN (PV-16.1)** in the Pelvis Imaging Guidelines
- History of a molar pregnancy, can perform:
 - Complete first trimester ultrasound CPT® 76801 if <14 weeks, **or**
 - CPT® 76815 and/or CPT® 76817 **or**
 - CPT® 76805/CPT® 76811 if indicated (plus CPT® 76812 for each additional fetus) if ≥14 weeks, when complete fetal anatomic scan has not yet been performed, and/or CPT® 76817

Background and Supporting Information

- CPT® 76815 should never be reported with complete studies CPT® 76801/CPT® 76802, CPT® 76805/CPT® 76810 or CPT® 76811/CPT® 76812 or with CPT® 76816 or BPP (CPT® 76818 and CPT® 76819).
- Though fetal anatomy survey (CPT® 76805/CPT® 76811) can be performed as early as 14 weeks gestation, per ACOG, in the absence of other specific indications, it is optimally performed at 18 to 22 weeks of gestation.

References (OB-5)

v1.0.2024

1. ACOG Practice Bulletin No. 200. Early Pregnancy Loss. *Obstetrics & Gynecology*. 2018;132(5). Reaffirmed 2021. doi:10.1097/aog.0000000000002899
2. Mari G, Norton ME, Stone J, et al. Society for Maternal-Fetal Medicine (SMFM) Clinical Guideline #8: The fetus at risk for anemia—diagnosis and management. *American Journal of Obstetrics and Gynecology*. 2015;212(6):697-710. doi:10.1016/j.ajog.2015.01.059
3. ACOG Practice Bulletin No. 193. Tubal Ectopic Pregnancy. *Obstetrics & Gynecology*. 2018;131(3). Reaffirmed 2022. doi:10.1097/aog.0000000000002560
4. ACOG Practice Bulletin No. 174. Evaluation and Management of Adnexal Masses. *Obstetrics & Gynecology*. 2016;128(5). Reaffirmed 2021. doi:10.1097/aog.0000000000001768
5. Ramanathan S, Raghu V, Ladumor SB, Nagadi AN, Palaniappan Y, Dogra V, Schieda N. Magnetic resonance imaging of common, uncommon, and rare implantation sites in ectopic pregnancy. *Abdom Radiol (NY)*. 2018 Dec;43(12):3425-3435. doi: 10.1007/s00261-018-1604-2
6. Dibble EH, Lourenco AP. Imaging Unusual Pregnancy Implantations: Rare Ectopic Pregnancies and More. *AJR Am J Roentgenol*. 2016 Dec;207(6):1380-1392. doi: 10.2214/AJR.15.15290
7. Abu-Rustum NR, Yashar CM, Bean S, et al. Gestational Trophoblastic Neoplasia, Version 2.2019, NCCN Clinical Practice Guidelines in Oncology. *Journal of the National Comprehensive Cancer Network*. 2019;17(11):1374-1391. doi:10.6004/jnccn.2019.0053

Fetal Aneuploidy and Anomaly Screening (OB-6)

First Trimester Screening (OB-6.1)

OB.FA.0006.1.A

v1.0.2024

- First trimester screening includes the assessment of biochemical markers and fetal nuchal translucency (NT) (CPT® 76813). An increased Fetal Nuchal Translucency, defined as a NT ≥ 3.0 mm, or $>95^{\text{th}}$ percentile for the crown rump length (CRL), may indicate a fetus with aneuploidy (e.g. Down's syndrome, Trisomy 18) but may also indicate an increased risk for cardiac defects or other structural defects or genetic syndromes in euploid fetuses.
- Nuchal translucency can be performed if CRL 44-83 mm (typically between 10 4/7 and 14 weeks' gestation).
- Indications for a detailed first-trimester fetal anatomic ultrasound [requested as CPT® 76801 plus CPT® 76813 (and CPT® 76802 plus CPT® 76814 for each additional fetus)] See **Detailed First Trimester Fetal Anatomic Scan (OB-9.12)**

First Trimester Screening:

- Ultrasound CPT® 76813 (plus CPT® 76814 for each additional fetus) is the initial imaging for first trimester screening, to evaluate fetal nuchal translucency
- If increased Fetal Nuchal Translucency (NT ≥ 3.0 mm or $>95^{\text{th}}$ percentile for the CRL), perform:
 - A detailed first-trimester obstetric ultrasound [requested as CPT® 76801 **plus** CPT® 76813 (and CPT® 76802 **plus** CPT® 76814 for each additional fetus)] between 12 weeks 0 days and 13 weeks 6 days,⁹ **and/or**
 - Fetal anatomic ultrasound (CPT® 76811) at ≥ 16 weeks
 - Fetal echo (CPT® 76825 and/or CPT® 76827 and/or CPT® 93325) at ≥ 16 weeks
 - Cell-Free DNA (cfDNA), Amniocentesis or CVS can be performed
 - See **High Risk Pregnancy (OB-9)** and **Fetal Echocardiography - Indications for Fetal Conditions (OB-12.2)**
- Fetal NT (CPT® 76813) is NOT recommended if cfDNA has already been planned or performed, as they are both screening tools for fetal aneuploidy.
 - Twins and higher order multiples are an exception to this since the sensitivity of cfDNA screening may not be as accurate in this group.¹⁰
 - Fetal NT (CPT® 76813) can be performed in twins and higher order multiples even if cfDNA has already been planned or performed. See **Known Dichorionic Multiple Gestations (OB-11.2)** and **Known Monochorionic-Diamniotic or Monochorionic-Monoamniotic Multiple Gestations (OB-11.3)**
- Cell-Free DNA (cfDNA) can be performed any time after 10 weeks gestation and is currently the most sensitive screening test for Down's syndrome per the American College of Medical Genetics and Genomics (99% accurate).
- Those with a positive cfDNA should be offered diagnostic testing (amniocentesis or CVS) and a detailed first-trimester obstetric ultrasound [requested as CPT® 76801

plus CPT® 76813 (and CPT® 76802 **plus** CPT® 76814 for each additional fetus)] between 12 weeks 0 days and 13 weeks 6 days,⁹ and a detailed anatomy scan (CPT®76811) at ≥16 weeks. See **High Risk Group One – Risk Factors (OB-9.1)**.

- A “no call” or indeterminate result can occur (risk is higher with maternal obesity), which also has a higher risk of aneuploidy. These individuals should be managed as if positive.

Background and Supporting Information

- CPT® 76801 **plus** CPT® 76813 [and CPT® 76802 **plus** CPT® 76814 for each additional fetus)] when billed together, can also be used to report a detailed late first-trimester obstetric ultrasound examination – performed between 12 weeks 0 days and 13 weeks 6 days
 - This indication-driven detailed first trimester fetal anatomic evaluation is generally performed by those with special skills to perform this study, such as a Maternal Fetal Medicine specialist (Perinatologist), or a Radiologist with advanced training in fetal imaging. It can be performed even if cfDNA has been planned or performed.
- CPT® 76813/CPT® 76814 for first trimester screening alone, can be performed once per pregnancy, and should be performed only by those certified by the Fetal Medicine Foundation or Nuchal Translucency Quality Review Program (NTQR).
- The use of ultrasound codes (CPT® 76801/CPT® 76802) should be indication driven and should NOT be routinely done whenever an ultrasound for nuchal translucency (CPT® 76813/CPT® 76814) is requested. In cases where there is either a maternal and/or fetal indication, then the CPT® 76801/CPT® 76802 code can indeed be billed along with the nuchal translucency screening (CPT® 76813/CPT® 76814).
- CPT® 76815 should never be reported with complete studies CPT® 76801/CPT® 76802, CPT® 76805/CPT® 76810 or CPT® 76811/CPT® 76812 or with CPT® 76816 or BPP (CPT® 76818 and CPT® 76819).
- Though fetal anatomy survey (CPT® 76805/CPT® 76811) can be performed as early as 14 weeks gestation, per ACOG, in the absence of other specific indications, it is optimally performed at 18 to 22 weeks of gestation.

Second Trimester Screening (OB-6.2)

OB.FA.0006.2.A

v1.0.2024

Second Trimester Screening:

- A fetal anatomy ultrasound (CPT® 76805) and/or QUAD screen can be performed during the second trimester to detect fetal aneuploidy, neural tube defects, and other anatomical defects.
 - See **Fetal Anatomic Scan (OB-7.1)**
- If the quad screening is abnormal, a detailed anatomy ultrasound (CPT® 76811) can be performed.

Background and Supporting Information

Multiple marker screening is used in the second trimester (15 to 22 6/7 weeks) to screen for aneuploidy as well as open neural tube defects (ONTD).

- Maternal serum alpha-fetoprotein (MSAFP) can be done at 15 to 20 weeks to screen for neural tube defects in those that have had cfDNA or NT screen.
- The “quad” screen (AFP (alpha-fetoprotein), hCG (human chorionic gonadotropin), uE (Unconjugated estriol), dimeric inhibin-A) is the most commonly used test for the second trimester.
- A penta screen (quad screen markers + hyperglycosylated hCG) may be done in lieu of a quad screen.
- Combined, integrated or sequential screening (first and second trimester screening) may also be used and provides a higher detection rate than a single screening.
- Providers often wait for the results of the quad screen before ordering CPT® 76805. If the quad screen is abnormal, they may request CPT® 76811 in lieu of CPT® 76805.

References (OB-6)

v1.0.2024

1. ACOG Practice bulletin number 226. Screening for fetal chromosomal abnormalities. *Obstetrics & Gynecology*. 2020 Oct;136(4):e48-e69. doi: 10.1097/AOG.0000000000004084
2. ACOG Practice Bulletin No. 175: Ultrasound in Pregnancy. *Obstetrics & Gynecology*. 2016;128(6):e241-e256. Reaffirmed 2022 doi:10.1097/AOG.0000000000001815
3. Gregg AR, Skotko BG, Benkendorf JL, et al. Noninvasive prenatal screening for fetal aneuploidy, 2016 update: a position statement of the American College of Medical Genetics and Genomics. *Genetics in Medicine*. 2016;18(10):1056-1065. doi:10.1038/gim.2016.97
4. Norton ME, Biggio JR, Kuller JA, Blackwell SC. Society for Maternal-Fetal Medicine (SMFM) Consult Series | #42: The role of ultrasound in women who undergo cell-free DNA screening. *American Journal of Obstetrics and Gynecology*. 2017;216(3):B2-B7. doi:10.1016/j.ajog.2017.01.005
5. Society for Maternal and Fetal Medicine (SMFM), coding committee, October 2017. SMFM's white paper on billing combination of 76801 and 76813
6. ACOG Practice Bulletin No. 162 Prenatal diagnostic testing for genetic disorders. *Obstetrics & Gynecology*. 2016;127(5). Reaffirmed 2020. doi:10.1097/aog.0000000000001405
7. Donofrio MT, Moon-Grady AJ, Hornberger LK, et al. Diagnosis and Treatment of Fetal Cardiac Disease. *Circulation*. 2014;129(21):2183-2242. doi:10.1161/01.cir.0000437597.44550.5d
8. ACOG Practice Bulletin: No.187: Neural Tube Defects. *Obstetrics & Gynecology*. 2017 Dec;130(6):e279-e290. Reaffirmed 2021. doi: 10.1097/AOG.0000000000002412
9. AIUM Practice Parameter for the Performance of Detailed Diagnostic Obstetric Ultrasound Examinations Between 12 Weeks 0 Days and 13 Weeks 6 Days. *Journal of Ultrasound in Medicine*. Published online August 27, 2020. doi:10.1002/jum.15477
10. ACOG Practice Bulletin No. 231: Multifetal Gestations: Twin, Triplet, and Higher-Order Multifetal Pregnancies. *Obstet Gynecol*. 2021;137:e145-62

Fetal Anatomic Scan/Cervical Length Screening (OB-7)

Fetal Anatomic Scan (OB-7.1)

OB.AS.0007.1.A

v1.0.2024

- Though fetal anatomy survey (CPT® 76805/CPT® 76811) can be performed as early as 14 weeks gestation, per ACOG, in the absence of other specific indications, it is optimally performed at 18 to 22 weeks of gestation. This timing allows for a survey of fetal anatomy and an accurate estimation of gestational age.
 - For a **normal/low risk** pregnancy, report a fetal anatomy ultrasound CPT® 76805 if ≥16 weeks.
 - If **high risk** indication is met can report:
 - A detailed fetal anatomy ultrasound (CPT® 76811) if ≥16 weeks^{15,16}
 - These high risk scans indication driven and generally performed by a Maternal Fetal Medicine (MFM) specialist/Perinatologist, or a Radiologist at an AIUM or ACR accredited facility.
 - See **High Risk Pregnancy (OB-9)**
 - For a detailed first-trimester fetal anatomy ultrasound [requested as CPT® 76801 plus CPT® 76813 (and CPT® 76802 plus CPT® 76814 for each additional fetus)] between 12 weeks 0 days and 13 weeks 6 days See **Detailed First Trimester Fetal Anatomic Scan (OB-9.12)**

Fetal Anatomic Scan – Follow-up (OB-7.2)

OB.AS.0007.2.A
v1.0.2024

- Follow-up ultrasounds (CPT® 76815 to assess a single item or CPT® 76816 if multiple areas to be assessed) can be performed once for incomplete or equivocal finding on initial fetal anatomic scan. This can be performed at any time after incomplete anatomy scan.
- CPT® 76816 (should not be performed prior to a CPT® 76801 or an anatomy scan CPT® 76805 (normal pregnancy) or Detailed anatomy scan CPT® 76811 (high risk pregnancy))
- If pregnancy is high risk See **High Risk Pregnancy (OB-9)** or other applicable high risk guideline.
- Detailed anatomy ultrasound CPT® 76811 can be performed (if not previously performed) when initial fetal anatomic scan CPT® 76805 is abnormal. See **High Risk Pregnancy (OB-9)**
- CPT® 76815 should never be reported with complete studies CPT® 76801/CPT® 76802, CPT® 76805/CPT® 76810 or CPT® 76811/CPT® 76812 or with CPT® 76816 or BPP (CPT® 76818 and CPT® 76819).

Cervical Length Screening (OB-7.3)

OB.AS.0007.3.A

v1.0.2024

- Current ACOG and SMFM guidelines state that CL screening in singleton gestations without a prior spontaneous PTB cannot yet be universally mandated.
 - Transvaginal ultrasound (CPT® 76817) can be performed if the transabdominal cervical length (CL) is ≤ 3.6 cm. If documented transabdominal attempt fails to visualize cervix, then CPT® 76817 may be performed on a case by case basis.
 - If cervical shortening is identified – See **Cervical Insufficiency (OB-18.1)**

References (OB-7)

v1.0.2024

1. AIUM-ACR-ACOG-SMFM-SRU Practice Parameter for the Performance of Standard Diagnostic Obstetric Ultrasound Examinations. *Journal of Ultrasound in Medicine*. 2018;37(11). doi:10.1002/jum.14831
2. AIUM Practice Parameter for the Performance of Detailed Second- and Third-Trimester Diagnostic Obstetric Ultrasound Examinations. *Journal of Ultrasound in Medicine*. 2019;38(12):3093-3100. doi:10.1002/jum.15163
3. Practice Bulletin No. 175: Ultrasound in Pregnancy. *Obstetrics & Gynecology*. 2016;128(6):e241-e256. Reaffirmed 2022 doi:10.1097/AOG.0000000000001815
4. AIUM Practice Parameter for the Performance of Limited Obstetric Ultrasound Examinations by Advanced Clinical Providers. *Journal of Ultrasound in Medicine*. 2018;37(7):1587-1596. doi:10.1002/jum.14677
5. American Medical Association. CPT—Current Procedural Terminology. American Medical Association. <https://www.ama-assn.org/practice-management/cpt>. Published 2019. Copyright 1995 - 2019
6. ACOG Practice Bulletin No. 234: Prediction and Prevention of Spontaneous Preterm Birth. *Obstetrics & Gynecology*. 2021;138(2):e65-e90. doi:10.1097/aog.0000000000004479
7. Cho HJ, Roh H-J. Correlation Between Cervical Lengths Measured by Transabdominal and Transvaginal Sonography for Predicting Preterm Birth. *Journal of Ultrasound in Medicine*. 2016;35(3):537-544. doi:10.7863/ultra.15.03026
8. Esplin MS, Elovitz MA, Iams JD, et al. Predictive Accuracy of Serial Transvaginal Cervical Lengths and Quantitative Vaginal Fetal Fibronectin Levels for Spontaneous Preterm Birth Among Nulliparous Women. *JAMA*. 2017;317(10):1047. doi:10.1001/jama.2017.1373
9. Jain S, Kilgore M, Edwards RK, Owen J. Revisiting the cost-effectiveness of universal cervical length screening: importance of progesterone efficacy. *American Journal of Obstetrics and Gynecology*. 2016;215(1). doi:10.1016/j.ajog.2016.01.165
10. Blackwell SC, Gyamfi-Bannerman C, Biggio JR Jr, et al. 17-OHPC to Prevent Recurrent Preterm Birth in Singleton Gestations (PROLONG Study): A Multicenter, International, Randomized Double-Blind Trial. *Am J Perinatol*. 2020;37(2):127–136. doi:10.1055/s-0039-3400227
11. McIntosh J, Feltovich H, Berghella V, Manuck T. The role of routine cervical length screening in selected high- and low-risk women for preterm birth prevention. Society for Maternal-Fetal Medicine (SMFM) Consult Series #40. *American Journal of Obstetrics and Gynecology*. 2016;215(3). doi:10.1016/j.ajog.2016.04.027
12. Friedman AM, Schwartz N, Ludmir J, Parry S, Bastek JA, Sehdev HM. Can transabdominal ultrasound identify women at high risk for short cervical length? *Acta Obstetrica et Gynecologica Scandinavica*. 2013;92(6):637-641. doi:10.1111/aogs.12111
13. EPPPIC Group. Evaluating Progestogens for Preventing Preterm birth International Collaborative (EPPPIC): meta-analysis of individual participant data from randomised controlled trials. *Lancet*. 2021 Mar 27;397(10280):1183-1194
14. SMFM, 2021. SMFM Statement: Response to EPPPIC and considerations of the use of progestogens for the prevention of preterm birth
15. AIUM Practice Parameter for the Performance of Detailed Diagnostic Obstetric Ultrasound Examinations Between 12 Weeks 0 Days and 13 Weeks 6 Days. *Journal of Ultrasound in Medicine*. Published online August 27, 2020. doi:10.1002/jum.1547
16. 2SMFM Coding Committee White Paper: Coding for the "new" First Trimester Detailed Diagnostic Obstetric Ultrasound. Society for Maternal Fetal Medicine website. 6-2021

Third Trimester Imaging (OB-8)

Third Trimester Imaging – Ultrasound (OB-8.1)

OB.TI.0008.1.A

v1.0.2024

- Imaging in the third trimester is indicated for bleeding, pain, absent fetal heart tones, decreased fetal movement and/or other high-risk indications
 - See specific guidelines based on indication
- For suspected breech position, See **Abnormal Fetal Position/Presentation (OB-14)**

Reference (OB-8)

v1.0.2024

1. Practice Bulletin No. 175: Ultrasound in Pregnancy. *Obstetrics & Gynecology*. 2016;128(6):e241-e256. Reaffirmed 2022 doi:10.1097/AOG.0000000000001815

High Risk Pregnancy (OB-9)

High Risk General Information (OB-9.0)

OB.HR.0009.0.A

v1.0.2024

High Risk Pregnancy General Information:

- Though CPT® 76811 can be performed as early as 14 weeks gestation, per ACOG, in the absence of other specific indications, it is optimally performed at 18 to 22 weeks of gestation.
- The detailed first trimester ultrasound and the detailed fetal anatomic evaluation are indication driven and generally performed by those with special skills to perform this study, such as a Maternal Fetal Medicine specialist (Perinatologist), or a Radiologist with advanced training in fetal imaging. See **Detailed First Trimester Fetal Anatomic Scan (OB-9.12)**
- In circumstances where the individual is deemed to have an increased risk for a fetal abnormality and does not have access to a provider who can perform the a fetal anatomic ultrasound examination (CPT® 76811) **due to geographic or other constraints**, a standard (after first trimester) fetal anatomic ultrasound examination (CPT® 76805) can be authorized instead.
- CPT® 76805, CPT® 76810, CPT® 76811, and CPT® 76812 should only be used once per pregnancy unless the mother changes to a new medical caregiver at a new office and there is a new medical indication and/or change in condition.
- Current ACOG and SMFM guidelines state that CL screening in singleton gestations without a prior spontaneous PTB cannot yet be universally mandated
 - Transvaginal ultrasound (CPT® 76817) can be performed if the transabdominal cervical length (CL) is ≤ 3.6 cm. If documented transabdominal attempt fails to visualize cervix, then CPT® 76817 may be performed on a case by case basis. See **Cervical Length Screening (OB-7.3)**. If cervical shortening is identified – See **Cervical Insufficiency (OB-18.1)**
- CPT® 76816 (should not be performed prior to a CPT® 76801 or an anatomy scan CPT® 76805 (normal pregnancy) or Detailed anatomy scan CPT® 76811 (high risk pregnancy)
- Typically all components of the BPP (CPT® 76818 and CPT® 76819), such as breathing, are not present until ≥ 26 weeks gestation. However, a modified BPP (CPT® 76815) can be utilized sooner in certain high risk cases but should not be done prior to 22 weeks. .
- CPT® 76815 should never be reported with complete studies CPT® 76801/CPT® 76802, CPT® 76805/CPT® 76810 or CPT® 76811/CPT® 76812 or with CPT® 76816 or BPP (CPT® 76818 and CPT® 76819).
- SMFM suggest that ductus venosus, middle cerebral artery, or uterine artery Doppler use for routine clinical management of early- or late-onset FGR *is not recommended*

High Risk Group One – Risk Factors (OB-9.1)

OB.HR.0009.1.A
v1.0.2024

High Risk Pregnancy – Risk Factors:

Socio-Demographic Risk Factors (maternal age)

- Age ≥35 years of age at the estimated date of confinement (EDC)

Lifestyle Related Risk Factors (legal or illicit drug/alcohol use)

- Recreational drug (e.g. cocaine, amphetamines, opiates) or excessive alcohol use (≥5 drinks per week) during current pregnancy, or excessive (at least weekly) Marijuana/Cannabinoids/THC use in 2nd and/or 3rd trimesters
 - For 1st trimester marijuana exposure – See **Potentially Teratogenic Medications/ Substances (OB-10.1)**
- Nicotine (≥10 cigarettes a day)
- Other nicotine exposure in pregnancy (e-cigs, vaping, chewing, patch) are also high risk
- Current Maternal IV drug use
- Current use of Suboxone, Subutex, Methadone
- Other polysubstance use

See **Medications/ Exposures Associated with Poor Pregnancy Outcome (OB 10.2)** for imaging recommendations for other high-risk medication or substances not listed above

Health Condition Related Risk Factors (maternal diseases or conditions)

- Anemia severe, <8 grams Hgb or 24% HCT
- Antiphospholipid Syndrome
- Asthma (poorly controlled or steroid dependent)
- Autoimmune disease (e.g. Multiple Sclerosis, Immune Thrombocytopenic Purpura)
- Bariatric surgery
- Connective tissue disorders (lupus, RA, scleroderma, Sjogren’s, etc.)
- DVT/PE or Maternal thrombophilia (Antiphospholipid Syndrome, Factor V Leiden mutation, Antithrombin III deficiency, Protein C/Protein S deficiency, Prothrombin gene mutation etc.)

Health Condition Related Risk Factors (maternal diseases or conditions)

- Heart disease (Maternal) – World Health Organization (WHO) Class II or greater
- Hemoglobinopathies (e.g. sickle cell disease, Alpha and Beta thalassemia minor (trait) or major)
- History of endometrial ablation or Uterine Artery embolization
- Inflammatory Bowel Disease (Ulcerative colitis, Crohn’s Disease)
- Liver disease e.g. Hepatitis, Cholestasis of pregnancy (see imaging below)
- Malignancy complicating pregnancy
- Maternal malnutrition (BMI <18.5) or poor weight gain in pregnancy (1 lb per week in 2nd or 3rd trimester if BMI ≤24.9)
- PKU
- Renal disease e.g. glomerulonephritis, persistent protein in the urine, renal insufficiency
- Seizure disorders – on antiepileptic medication
- Thyroid disorder (e.g. hyperthyroidism, poorly controlled hypothyroidism)

Previous pregnancy related risk factors

- Prior pregnancy with adverse outcome (e.g. severe or early onset preeclampsia ≤34 weeks, abruption, accreta, previous uterine dehiscence or rupture, nonimmune hydrops).
- Prior pregnancy with SGA (baby weighing <2500 grams (5.5 pounds/5 lbs 8 oz) at term or less than the 10th percentile of expected weight) or FGR at any gestational age.
- For stillbirth See: **History of Stillbirth (OB-9.10)**

Current pregnancy related risk factors

- Abnormal 1st or 2nd trimester screen (e.g. Abnormal MSAFP; Low PAPP_A; Elevated inhibin A, elevated hCG³¹)
- Known chromosomal abnormalities or abnormal cfDNA
- Genetic Carrier status e.g., Cystic Fibrosis/Known carrier of Spinal Muscular Atrophy (SMA), CF, Tay-Sachs genetic diseases

Current pregnancy related risk factors

- Major Fetal anomaly such as gastroschisis, fetal ventriculomegaly, moderate or severe fetal urinary tract dilation defined as ≥ 7 mm at < 28 weeks or > 9 mm at ≥ 28 weeks³², achondroplasias, fetal congenital heart disease, neural tube defect, etc. For sustained fetal arrhythmias. See **Other Causes of Fetal Anemia (OB-16.5)** For Persistent Right Umbilical Vein (PRUV) - See **Persistent Right Umbilical Vein (PRUV) (OB-21.2)**.
- Grand multiparity: must have completed 5 or more pregnancies of greater than 20 weeks gestation, living or stillbirth (does not include current pregnancy; twins count as 1 pregnancy)
- Abnormal Fetal Nuchal Translucency ≥ 3.0 mm or above the 95th percentile for the CRL
- No prenatal care prior to the third trimester
- Short inter-pregnancy interval ≤ 6 months from delivery to conception.^{33,34} [For inter-pregnancy interval > 6 to 18 months – See **Short Interval Pregnancy (≤ 18 months between last delivery and conception of current pregnancy) (OB-9.11)]**
- Pregnancy with retained IUD

Maternal Infections (not exposure)

- Acquired Immune Deficiency Syndrome/HIV Positive
- Chicken Pox/Varicella
- Cytomegalovirus (CMV)
- Malaria
- Known parvovirus in current pregnancy post fetal treatment. See **Exposure to Parvovirus B-19 (OB-16.2)**
- Rubella
- Syphilis, untreated
- Toxoplasmosis
- Tuberculosis
- For Zika Virus and COVID-19 Virus See **High Risk Group Five: Zika and COVID-19 Virus (OB-9.5)**

Imaging For Above Conditions

- Complete first trimester ultrasound CPT® 76801 [plus CPT® 76802 for each additional fetus] if <14 weeks and a complete ultrasound has not yet been performed, **and/or** CPT® 76817 for a transvaginal ultrasound
 - CPT® 76801 is preferred for dating, but if this is unable to be completed then CPT® 76815 **and/or** CPT® 76817 for a transvaginal ultrasound is indicated
 - See **Detailed First Trimester Fetal Anatomic Scan (OB-9.12)** for indications for detailed first trimester fetal anatomic evaluation^{5,6}
- Detailed Fetal Anatomic Scan CPT® 76811 if ≥16 weeks
 - Though CPT® 76811 can be performed as early as 14 weeks gestation, per ACOG, in the absence of other specific indications, it is optimally performed at 18 to 22 weeks of gestation
- Starting at 22 weeks follow-up growth scans (CPT® 76816) every 3 to 6 weeks
- BPP (CPT® 76818 or CPT® 76819) or modified BPP (CPT® 76815), weekly starting at 32 weeks
- More frequent antepartum fetal surveillance can be performed as stipulated below:
 - Starting at 32 weeks, perform BPP (CPT® 76818 or CPT® 76819) or modified BPP (CPT® 76815) **up to 2x weekly** for the conditions below:
 - Antiphospholipid Syndrome
 - Maternal Renal Disease (moderate to severe with creatinine >1.4mg/dl)
 - Sickle cell disease
 - Starting **at diagnosis** perform BPP (CPT® 76818 or CPT® 76819) if ≥26 weeks, or modified BPP (CPT® 76815) if ≥22 weeks, **up to 2x weekly**:
 - Intra-hepatic cholestasis of pregnancy (IHCP)
 - Complicated Sickle cell disease (e.g. co-existing hypertension, vaso-occlusive crisis, fetal growth restriction)
 - Complicated SLE (e.g. active lupus nephritis, or recent flares)
 - Major fetal anomaly in the current pregnancy (e.g. gastroschisis, fetal ventriculomegaly, fetal hydronephrosis (>10mm), achondroplasias, fetal congenital heart disease, neural tube defect, sustained fetal arrhythmias)

Background and Supporting Information

Studies that note lower birth weights among offspring exposed to marijuana have noted that these findings were more pronounced among females who used more marijuana, particularly during the first and second trimesters (at least weekly during the pregnancy). CPT® 76811 can be performed, however, given the limited evidence for antenatally detected abnormal growth, serial growth ultrasounds is not indicated in the absence of other findings concerning for growth restriction.

Modified WHO Classification of Heart Disease in Pregnancy

WHO I: Uncomplicated pulmonary stenosis (PS), mitral valve prolapse (MVP), well repaired patent ductus arteriosus (PDA) or persistent anomalous pulmonary venous return (PAPVR)

WHO II: Unrepaired ASD/VSD, repaired tetralogy of fallot (TOF), most arrhythmias

WHO II-II: Mild LV impairment, hypertrophic cardiomyopathy (HCM), valvular heart disease, Marfan without aortic dilation, bicuspid aortic valve (BAV) with Ao <4.5 cm, repaired coarctation of the aorta

WHO III: Mechanical valves, systemic right ventricle (RV), Fontan, cyanotic heart disease, Marfan Aorta 4.0-4.5 cm, Bicuspid Aortic Valve Aorta 4.5-5.0 cm

WHO IV: **Pregnancy Contraindicated** – native severe coarctation of the aorta, Pulmonary Hypertension, LVEF <30%, NYHA III-IV, severe symptomatic mitral stenosis (MS), Marfan Aorta >4.5; Bicuspid aortic valves Ao >5.0; prior peripartum cardiomyopathy with residual LV impairment.

Recommended Weight Gain During Pregnancy

Pre-pregnancy weight Category	BMI	Total Wt Gain (lbs)	Recommended Rate of gain in 2 nd and 3 rd trimester (lb/wk)
Underweight	<18.5	28-40	1
Normal weight	18.5-24.9	25-35	1
Overweight	25-29.99	15-25	0.6
Obese	>30	11-20	0.5

Modified from. ACOG Practice Bulletin No 230. Obesity in Pregnancy, *Obstetrics & Gynecology*: June 2021

High Risk Group Two - Ultrasound Findings (OB-9.2)

OB.HR.0009.2.A
v1.0.2024

Soft Markers for Aneuploidy (OB-9.2.1)

- If the following ‘soft markers’ are found in fetus of current pregnancy on routine imaging:
 - Shortened long bones (femur and/or humerus),
 - Mild Pyelectasis^{28,32} (4 mm to <7 mm at 16 to 27 weeks; or 7 mm to <9 mm at ≥28 weeks)
 - For moderate or severe fetal urinary tract dilation (≥7mm at <28 weeks or >9 mm at ≥28 weeks) See **High Risk Group One - Risk factors (OB-9.1)**
 - Echogenic bowel
 - See **Other Ultrasound Findings (OB-9.2.2)** for Fetal Echogenic intra-cardiac focus and/or choroid plexus cyst
- Detailed Fetal anatomic scan ≥16 weeks (CPT® 76811).
- One follow-up scan (CPT® 76816) in third trimester

Other Ultrasound Findings (OB-9.2.2)

- If an isolated soft marker²⁸ is found in fetus of current pregnancy on routine imaging, including:
 - Choroid plexus cyst, or
 - Echogenic intra-cardiac foci, or
 - Thickened nuchal fold (≥6mm at 15 to 20 weeks), or
 - Absent or hypoplastic nasal bone
 - Report:
 - Detailed fetal anatomic scan (CPT® 76811) at ≥16 weeks
- If a Major fetal anomaly is found, or if abnormal cfDNA or amniocentesis results - See **High Risk Group One - Risk factors (OB-9.1)**
- If negative cfDNA or negative amniocentesis – Fetal echo or follow-up ultrasound are not warranted for these isolated findings

- If history of a prior pregnancy with a chromosomal and/or structural congenital anomaly, or
- Current pregnancy with suspected fetal anomaly on initial imaging
- Report:
 - A detailed first-trimester obstetric ultrasound^{5,6} [requested as CPT® 76801 **plus** CPT® 76813 (and CPT® 76802 **plus** CPT® 76814 for each additional fetus)] **between 12 weeks 0 days and 13 weeks 6 days, and/or**
 - Detailed fetal anatomic scan (CPT® 76811) at ≥16 weeks
- If a Major fetal anomaly is found - See High Risk Group One - Risk factors (OB-9.1) and/or **Fetal Echocardiography - Indications for Fetal Conditions (OB 12.2)**

High Risk Group Three – Pre-pregnancy BMI ≥ 30 kg/m² (OB-9.3)

OB.HR.0009.3.A

v1.0.2024

Pre-pregnancy BMI ≥ 30 kg/m²

- Complete first trimester anatomy ultrasound CPT® 76801 [plus CPT® 76802 for each additional fetus] if <14 weeks and a complete ultrasound has not yet been performed, **and/or** CPT® 76817 for a transvaginal ultrasound
 - CPT® 76801 is preferred for dating, but if this is unable to be completed then CPT® 76815 and/or CPT® 76817 for a transvaginal ultrasound is indicated
- A detailed first trimester fetal anatomic evaluation^{5,6} can be performed between 12 weeks 0 days and 13 weeks 6 days. (See **Detailed First Trimester Fetal Anatomic Scan (OB-9.12)** for indications)
 - Report: CPT® 76801 plus CPT® 76813 (and CPT® 76802 plus CPT® 76814 for each additional fetus) for a detailed first trimester fetal anatomy ultrasound.
 - A detailed first trimester fetal anatomic evaluation can be performed if indicated, even if cfDNA has been planned or performed
- A detailed fetal anatomic scan at ≥ 16 weeks (CPT® 76811)
 - Though CPT® 76811 can be performed as early as 14 weeks gestation, per ACOG, in the absence of other specific indications, it is optimally performed at 18 to 22 weeks of gestation

Class I Obesity - Pre-pregnancy BMI 30 to 34.9 (OB-9.3.1)

Class I Obesity (BMI 30-34.9)

- After first and second trimester imaging as outlined above, Report **One** follow-up scan (CPT® 76816) between 32 to 36 weeks
 - If unable to clinically assess fundal height due to body habitus a growth scan (CPT® 76816) can be considered in the early third trimester with follow up in 4 weeks

Class II Obesity - Pre-pregnancy BMI 35-39.9 (OB-9.3.2)

Class II Obesity (BMI 35-39.9)

- After first and second trimester imaging as outlined above, Report:
 - Growth scans (CPT® 76816) every 4 weeks starting in the third trimester (≥28 weeks)
 - BPP (CPT® 76818 or CPT® 76819) or a modified BPP (CPT® 76815) weekly starting at 36 weeks

Class III Obesity - Pre-pregnancy BMI ≥40 (OB-9.3.3)

Class III Obesity (BMI ≥40)

- After first and second trimester imaging as outlined above, Report:
 - Growth scans (CPT® 76816) every 4 weeks starting in the third trimester (>28 weeks)
 - BPP (CPT® 76818 or CPT® 76819) or modified BPP (CPT® 76815) weekly starting at 32 weeks

Background and Supporting Information

If pre-pregnancy or early pregnancy weight is over 200 pounds, it can be presumed that BMI is ≥30 kg/m².

Recommended Weight Gain During Pregnancy

Pre-pregnancy weight Category	BMI	Total Wt Gain (lbs)	Recommended Rate of gain in 2 nd and 3 rd trimester (lb/wk)
Underweight	<18.5	28-40	1
Normal weight	18.5-24.9	25-35	1
Overweight	25-29.99	15-25	0.6
Obese	>30	11-20	0.5

Modified from ACOG Practice Bulletin No 230. Obesity in Pregnancy, *Obstetrics & Gynecology*: June 2021

High Risk Group Four – Macrosomia (OB-9.4)

OB.HR.0009.4.A

v1.0.2024

Prior Pregnancy with Macrosomia (OB-9.4.1)

Prior pregnancy with macrosomia (baby weighing >4000 grams at term or greater than the 90th percentile of expected weight)

- Report one of the following in the first trimester to establish dates:
 - Complete first trimester ultrasound CPT® 76801 [plus CPT® 76802 for each additional fetus] if <14 weeks and a complete ultrasound has not yet been performed, **and/or** CPT® 76817 for a transvaginal ultrasound
 - CPT® 76801 is preferred for dating, but if this is unable to be completed then CPT® 76815 and/or CPT® 76817 for a transvaginal ultrasound is indicated
 - Detailed Fetal Anatomic Scan CPT® 76811 if ≥16 weeks
 - Though CPT® 76811 can be performed as early as 14 weeks gestation, per ACOG, in the absence of other specific indications, it is optimally performed at 18 to 22 weeks of gestation
- Follow-up scan (CPT® 76816) in the third trimester (28-32 weeks) and at ≥35 weeks to plan for delivery^{35,36}

Current Pregnancy with Suspected or Known Macrosomia (OB-9.4.2)

- See [Macrosomia – Large for Dates Current Pregnancy \(OB-20.2\)](#)
- See [Unequal Fundal Size and Dates \(OB-27\)](#)

High Risk Group Five – Zika and COVID-19 Virus (OB-9.5)

OB.HR.0009.5.A

v1.0.2024

Zika Virus (OB-9.5.1)

Zika Virus

Suspected exposure without symptoms³⁷

- Report one of the following:
 - Complete first trimester ultrasound CPT® 76801 [plus CPT® 76802 for each additional fetus] if <14 weeks and a complete ultrasound has not yet been performed, **and/or** CPT® 76817 for a transvaginal ultrasound
 - CPT® 76801 is preferred for dating, but if this is unable to be completed then CPT® 76815 and/or CPT® 76817 for a transvaginal ultrasound is indicated
 - CPT® 76805/CPT® 76811 if otherwise indicated (plus CPT® 76810/CPT® 76812 for each additional fetus) if anatomy ultrasound has not yet been performed, **or**
 - CPT® 76816 if anatomy ultrasound (CPT® 76805/CPT® 76811) previously performed
 - Though a fetal anatomy scan can be performed as early as 14 weeks gestation, per ACOG, in the absence of other specific indications, it is optimally performed at 18 to 22 weeks of gestation
- If test positive or if symptoms developed, See below

Zika Virus

Suspected exposure with symptoms or known infection³⁷

- Report one of the following:
 - Complete first trimester ultrasound CPT® 76801 [plus CPT® 76802 for each additional fetus] if <14 weeks and a complete ultrasound has not yet been performed, **and/or** CPT® 76817 for a transvaginal ultrasound
 - CPT® 76801 is preferred for dating, but if this is unable to be completed then CPT® 76815 and/or CPT® 76817 for a transvaginal ultrasound is indicated
 - CPT® 76811 if ≥16 weeks when an anatomy ultrasound (CPT® 76811) has not yet been performed
 - Though CPT® 76811 can be performed as early as 14 weeks gestation, per ACOG, in the absence of other specific indications, it is optimally performed at 18 to 22 weeks of gestation
 - Growth scan, (CPT® 76816) every 3 to 4 weeks to monitor for findings such as intracranial calcifications and microcephaly, starting at 16 weeks.
 - CPT® 76816 if anatomy ultrasound (CPT® 76805/CPT® 76811) previously performed
 - Though a fetal anatomy scan can be performed as early as 14 weeks gestation, per ACOG, in the absence of other specific indications, it is optimally performed at 18 to 22 weeks of gestation
 - If fetal anomaly suspected or diagnosed See **High Risk Group One – Risk Factors (OB-9.1)**, if FGR diagnosed, See **Fetal Growth Restriction Current Pregnancy (OB-20.1)**

COVID-19 Virus (OB-9.5.2)

COVID-19 Virus

COVID-19 infection in the current pregnancy³⁹

- Report one of the following:
 - Complete first trimester ultrasound CPT® 76801 [plus CPT® 76802 for each additional fetus] if <14 weeks and a complete ultrasound has not yet been performed, **and/or** CPT® 76817 for a transvaginal ultrasound
 - CPT® 76801 is preferred for dating, but if this is unable to be completed then CPT® 76815 and/or CPT® 76817 for a transvaginal ultrasound is indicated
 - CPT® 76805 (CPT® 76811 if otherwise indicated), if ≥16 weeks when an anatomy ultrasound (CPT® 76805/CPT® 76811) has not yet been performed
 - Though fetal anatomy survey (CPT® 76805/CPT® 76811) can be performed as early as 14 weeks gestation, per ACOG, in the absence of other specific indications, it is optimally performed at 18 to 22 weeks of gestation.
 - Growth scan (CPT® 76816) every 3 to 4 weeks starting at 22 weeks [See **High Risk Group One - Risk factors (OB-9.1)**]
 - Starting **at diagnosis** perform weekly BPP (CPT® 76818 or CPT® 76819) if ≥26 weeks, or modified BPP (CPT® 76815) if ≥22 weeks. (See **High Risk Group One - Risk factors (OB-9.1)**)
 - If FGR diagnosed then follow **FGR imaging Fetal Growth Restriction Current Pregnancy (OB-20.1)**

High Risk Group Six - Pre-Gestational or Early Diagnosed (≤ 20 weeks) Diabetes (OB-9.6)

OB.HR.0009.6.A

v1.0.2024

- If diabetes is diagnosed prior to pregnancy or in the first or early second trimester (typically before 20 weeks gestation) with standard diagnostic criteria of: HbA1C $\geq 6.5\%$, fasting plasma glucose ≥ 126 mg/dL, or 2-hour glucose ≥ 200 mg/dL on a 75-g oral glucose tolerance test, then image as below.

Test	When	Frequency	Codes
First Trimester (Dating) Ultrasound	<14 weeks	Once	CPT® 76801 is preferred for dating, but if this is unable to be completed then CPT® 76815 and/or CPT® 76817 for a transvaginal ultrasound is indicated
Detailed first-trimester obstetric ultrasound ^{5,6}	12 to 13+6 weeks	Once	CPT® 76801 plus CPT® 76813 (and CPT® 76802 plus CPT® 76814 for each additional fetus)
Fetal anatomic scan	≥ 16 weeks	Once	CPT® 76811
Initial Fetal echo	Starting at ≥ 16 weeks	Once	CPT® 76825 and/or CPT® 76827 and/or CPT® 93325
Ultrasound (for fetal growth)	Starting at 22 weeks	Every 2 to 4 weeks	CPT® 76816
Biophysical Profile (BPP) or modified BPP	Starting at 32 weeks (can start at ≥ 26 weeks if complicated by additional risk factors (e.g., FGR Oligohydramnios, HTN)	Up to twice weekly	CPT® 76818 (BPP) or CPT® 76819 (BPP) or CPT® 76815 (modified BPP)
Umbilical artery Doppler (if FGR diagnosed)	Upon diagnosis of FGR if ≥ 22 weeks	Weekly	CPT® 76820

High Risk Group Seven Gestational Diabetes (OB-9.7)

OB.HR.0009.7.A
v1.0.2024

Gestational Diabetes - Diet-Controlled (GDM-A1) (OB-9.7.1)

If patient has gestational diabetes and it is diet controlled:			
Test	When	Frequency	Codes
Fetal anatomic scan	≥16 weeks	Once	CPT® 76805
Ultrasound (for fetal growth)	Once at the time of diagnosis, then starting at 32 weeks	Every 4 weeks	CPT® 76816
Biophysical Profile (BPP) or modified BPP	Starting at 34 weeks	Once weekly if diet controlled.	CPT® 76818 (BPP) or CPT® 76819 (BPP) or CPT® 76815 (modified BPP)

Gestational Diabetes on Medications (GDM-A2) (OB-9.7.2)

If patient has gestational diabetes and is on oral medication or insulin:			
Test	When	Frequency	Codes
Fetal anatomic scan	≥16 weeks	Once	CPT® 76811
Fetal echo (if HbA1C >6%)	Once in the third trimester (≥32 weeks)	Once	CPT® 76825 and/or CPT® 76827 and/or CPT® 93325
Ultrasound (for fetal growth)	Starting at 22 weeks	Every 2 to 4 weeks	CPT® 76816
Biophysical Profile (BPP) or modified BPP	Starting at 32 weeks (can start at ≥26 if complicated by additional risk factors (e.g., FGR Oligohydramnios))	Up to twice weekly	CPT® 76818 (BPP) or CPT® 76819 (BPP) or CPT® 76815 (modified BPP)

If patient has gestational diabetes and is on oral medication or insulin:			
Test	When	Frequency	Codes
Umbilical artery Doppler (if FGR diagnosed)	Upon diagnosis of FGR if ≥ 22 weeks	Weekly	CPT® 76820

Background and Supporting Information

- If HbA1c levels are $>6\%$, in those with GDM-A2, fetal echocardiogram in the third trimester to assess for ventricular hypertrophy can be performed.

Hypertensive Disorders in Pregnancy (OB-9.8)

OB.HR.0009.8.A
v1.0.2024

Screening in High Risk Groups (OB-9.8.1)

Screening in High Risk Groups

- SMFM state that uterine artery Doppler has limited diagnostic accuracy and clinical utility in predicting FGR, SGA birth, and perinatal mortality. As such, its use for screening in high risk groups *is not recommended*.

Current Chronic Hypertension not on Medication (OB-9.8.2)

Test	When	Frequency	Codes
First Trimester (Dating) Ultrasound	<14 weeks	Once	CPT® 76801 is preferred for dating, but if this is unable to be completed then CPT® 76815 and/or CPT® 76817 for a transvaginal ultrasound is indicated
Fetal anatomic scan	≥16 weeks	Once	CPT® 76811
Ultrasound (for fetal growth)	In the third trimester (≥28 weeks)	Every 4-6 weeks	CPT® 76816
If blood pressure is elevated from baseline, See Gestational Hypertension (GH, preeclampsia, toxemia) (OB-9.8.4) below			

Current Chronic Hypertension on Medication (OB-9.8.3)

Test	When	Frequency	Codes
First Trimester (Dating) Ultrasounds	<14 weeks	Once	CPT® 76801 is preferred for dating, but if this is unable to be completed then CPT® 76815 and/or CPT® 76817 for a transvaginal ultrasound is indicated
Detailed Fetal Anatomic Scan	≥16 weeks	Once	CPT® 76811
Ultrasound (for fetal growth)	Starting at 22 weeks gestation	Every 3 to 4 weeks	CPT® 76816
Biophysical profile (BPP) or modified BPP	Starting at 32 weeks If complicated by other risk factors (e.g. DM, FGR Oligohydramnios) can start at ≥26 weeks)	Once weekly If complicated by other risk factors (e.g., FGR Oligohydramnios) twice weekly	CPT® 76818 (BPP) or CPT® 76819 (BPP) or CPT® 76815 (AFI)
Umbilical artery Doppler (if FGR diagnosed) See <u>Fetal Growth Restriction Current Pregnancy (OB-20.1)</u>	Upon diagnosis of FGR if ≥22 weeks	Twice weekly	CPT® 76820

Gestational Hypertension (GH, preeclampsia, toxemia) (OB-9.8.4)

Test	When	Frequency	Codes
Fetal anatomic scan	≥16 weeks	Once	CPT® 76805 or CPT 76811 if other high risk issues and if not previously completed

Test	When	Frequency	Codes
Growth US	Starting at time of diagnosis	Every 3 to 4 weeks If FGR, Oligohydramnios or severe preeclampsia (every 2 to 4 weeks)	CPT® 76816
BPP	Starting at time of diagnosis if ≥26 weeks	Up to twice weekly Hypertension/ pre-eclampsia with severe features - Daily	CPT® 76818 or CPT® 76819
Modified BPP	Starting at time of diagnosis if ≥22 weeks	Up to twice weekly Hypertension/ pre-eclampsia with severe features - Daily	CPT® 76815
Umbilical artery Doppler <u>Fetal Growth Restriction Current Pregnancy (OB-20.1)</u>	Starting at time of diagnosis of FGR or Oligohydramnios if ≥22 weeks	Twice weekly	CPT® 76820

Background and Supporting Information

Disorder	Definition
Hypertension in pregnancy	Systolic blood pressure ≥140 mm Hg or diastolic BP ≥90 mm Hg, or both, measured on two occasions at least 4 hours apart
Severe-range hypertension	Systolic blood pressure ≥160 mm Hg or diastolic BP ≥110 mm Hg, or both, measured on two occasions at least 4 hours apart

Disorder	Definition
Chronic hypertension	Hypertension diagnosed or present before pregnancy or before 20 weeks of gestation; or hypertension that is diagnosed for the first time during pregnancy and that does not resolve in the postpartum period
Chronic hypertension with superimposed preeclampsia	Preeclampsia in a female with a history of hypertension before pregnancy or before 20 weeks of gestation
Gestational hypertension	Hypertension diagnosed after 20 weeks of gestation, in a female with a previously normal blood pressure.
Preeclampsia	Disorder of pregnancy associated with new-onset hypertension, which occurs most often after 20 weeks of gestation and frequently near term. Although often accompanied by new-onset proteinuria, hypertension and other signs or symptoms of preeclampsia may present in some females in the absence of proteinuria.
Eclampsia	Convulsive manifestation of the hypertensive disorders of pregnancy and is among the more severe manifestations of the disease.

History of Spontaneous Pre-Term Delivery/History of PPROM (OB-9.9)

OB.HR.0009.9.A

v1.0.2024

Spontaneous Preterm Delivery <37 0/7 Weeks; History of PPROM <37 0/7 weeks (OB-9.9.1)

Initial Imaging

- For initial imaging:
 - Complete first trimester ultrasound CPT® 76801 [plus CPT® 76802 for each additional fetus] if <14 weeks and a complete ultrasound has not yet been performed, **and/or** CPT® 76817 for a transvaginal ultrasound
 - CPT® 76801 is preferred for dating, but if this is unable to be completed then CPT® 76815 and/or CPT® 76817 for a transvaginal ultrasound is indicated

- Fetal Anatomy Ultrasound CPT® 76811 [plus CPT® 76812 for each additional fetus] if ≥16 weeks and a complete fetal anatomic scan has not yet been performed during this pregnancy
 - Though fetal anatomy survey (CPT® 76805/CPT® 76811) can be performed as early as 14 weeks gestation, per ACOG, in the absence of other specific indications, it is optimally performed at 18 to 22 weeks of gestation.
- CPT® 76817 and/or CPT® 76815 every 1 to 4 weeks, starting at ≥16 0/7 weeks until 24 0/7 weeks
- Starting after the fetal anatomic scan at ≥22 weeks, ultrasound (CPT® 76816) can be performed every 3 to 6 weeks until delivery
- If history of Preterm Delivery or PPROM below 37 0/7 weeks in immediately preceding pregnancy starting at 32 weeks, weekly BBP CPT® 76818 or CPT® 76819 or modified BPP CPT® 76815
- If funneling or short cervix ≤25 mm (2.5 cm) is found on a transvaginal ultrasound in a singleton pregnancy See **Cervical Insufficiency (OB-18.1)**
- For current preterm labor See **Current Preterm Labor (OB-18.3)**
- **If additional risk factors present see OB 9.1 for indications for fetal monitoring**

History of Stillbirth (OB-9.10)

OB.HR.0009.10.A

v1.0.2024

Initial Imaging

- For initial imaging:
 - Complete first trimester ultrasound CPT® 76801 [plus CPT® 76802 for each additional fetus] if <14 weeks and a complete ultrasound has not yet been performed, and/or CPT® 76817 for a transvaginal ultrasound
 - CPT® 76801 is preferred for dating, but if this is unable to be completed then CPT® 76815 and/or CPT® 76817 for a transvaginal ultrasound is indicated
 - A detailed first trimester fetal anatomic evaluation^{5,6} can be performed between 12 weeks 0 days and 13 weeks 6 days. (See **Detailed First Trimester Fetal Anatomic Scan (OB-9.12)** for indications)
 - Report: CPT® 76801 **plus** CPT® 76813 (and CPT® 76802 **plus** CPT® 76814 for each additional fetus) for a detailed first trimester fetal anatomy ultrasound
 - A detailed first trimester fetal anatomic evaluation can be performed if indicated, even if cfDNA has been planned or performed
- Fetal anatomic scan at ≥16 weeks (CPT® 76811)
 - Though fetal anatomy survey (CPT® 76805/CPT® 76811) can be performed as early as 14 weeks gestation, per ACOG, in the absence of other specific indications, it is optimally performed at 18 to 22 weeks of gestation
- Follow up ultrasound (CPT® 76816) every 2 to 4 weeks to assess fetal growth starting at 22 weeks or two weeks before prior pregnancy loss.
- Twice weekly BPP (CPT® 76818 or CPT® 76819, if ≥26 weeks) **or** modified BPP CPT® 76815 (not to be performed prior to 22 weeks) starting at 32 weeks or two weeks before prior pregnancy loss

Background and Supporting Information

- A history of stillbirth is not an indication for fetal echo. Per 2020 ACOG bulletin – there is no mention of recommendation for echo – just a detailed anatomy US. If demised fetus had a confirmed cardiac anomaly on autopsy, or if the detailed anatomy scan on either the demised fetus or the current pregnancy had findings suspicious for cardiac anomaly, then echo may be indicated. See **Fetal Echocardiography - Indications for Fetal Conditions (OB 12.2)**

Short Interval Pregnancy (≤ 18 months between last delivery and conception of current pregnancy) (OB-9.11)

OB.HR.0009.11.A

v1.0.2024

If Inter-Pregnancy interval ≤ 6 months^{33,34}

- Follow imaging as per High Risk Group One – Risk Factors (OB 9.1)

If Inter-Pregnancy interval > 6 months but ≤ 18 months^{33,34}

- Report one of the following to establish dates:
 - Complete first trimester ultrasound CPT[®] 76801 [plus CPT[®] 76802 for each additional fetus] if < 14 weeks and a complete ultrasound has not yet been performed, **and/or** CPT[®] 76817 for a transvaginal ultrasound
 - CPT[®] 76801 is preferred for dating, but if this is unable to be completed then CPT[®] 76815 and/or CPT[®] 76817 for a transvaginal ultrasound is indicated
- For fetal anatomy scan report CPT[®] 76805 (CPT[®] 76811 if otherwise indicated), if ≥ 16 weeks
 - Though fetal anatomy survey (CPT[®] 76805/CPT[®] 76811) can be performed as early as 14 weeks gestation, per ACOG, in the absence of other specific indications, it is optimally performed at 18 to 22 weeks of gestation.
- One follow-up scan, CPT[®] 76816 in the third trimester (28-32 weeks) to assess fetal growth.

Background and Supporting Information

Inter-pregnancy intervals shorter than 18 months are associated with higher risks of adverse pregnancy outcomes, including preterm delivery, small-for-gestational-age (SGA) birth, and infant mortality. Per ACOG, females should be advised to avoid inter-pregnancy intervals shorter than 6 months due to even more significant risks.³³

Detailed First Trimester Fetal Anatomic Scan (OB-9.12)

OB.HR.0009.12.A

v1.0.2024

- A detailed first trimester fetal anatomic evaluation^{5,6} can be performed, if indicated, between 12 weeks 0 days and 13 weeks 6 days.
 - If indicated report: CPT® 76801 **plus** CPT® 76813 (and CPT® 76802 **plus** CPT® 76814 for each additional fetus) [requested together] for a detailed first trimester fetal anatomy ultrasound.
 - A detailed first trimester fetal anatomic scan can be requested even if cfDNA has been planned or performed.
- Indications for a detailed first trimester fetal anatomic ultrasound include but are not limited to conditions below

Detailed First-Trimester Fetal Anatomy Scan Indications

- Previous fetus or child with a congenital, genetic, or chromosomal anomaly
- Known or suspected fetal abnormality detected by ultrasound in the current pregnancy
- Fetus at increased risk for a congenital anomaly based on the following:
 - 35 years or older at delivery
 - Maternal pre-gestational diabetes
 - Pregnancy conceived via in vitro fertilization
 - Multiple gestation
 - Teratogen exposure
 - Enlarged nuchal translucency
 - Positive screening test results for aneuploidy, including cell-free DNA screening and serum-only or combined first-trimester screening
- Other conditions possibly affecting the pregnancy/fetus, including:
 - Maternal body mass index of 30 kg/m or higher
 - Placental implantation covering the internal cervical os under a cesarean scar site or cesarean scar pregnancy diagnosed in index gestation

References (OB-9)

v1.0.2024

1. Practice Bulletin No. 175: Ultrasound in Pregnancy. *Obstetrics & Gynecology*. 2016;128(6):e241-e256. Reaffirmed 2022. doi:10.1097/AOG.0000000000001815
2. ACOG Practice Bulletin No. 229: Antepartum Fetal Surveillance. *Obstetrics & Gynecology*. 2021;137:e116-27. doi:10.1097/aog.0000000000004410
3. ACOG Committee Opinion No. 828. Indications for outpatient antenatal fetal surveillance. American College of Obstetricians and Gynecologists. *Obstetrics & Gynecology*. 2021;137:e177-97. doi:10.1097/aog.0000000000004407
4. Reddy UM, Abuhamad AZ, Levine D, Saade GR. Fetal Imaging. *Obstetrical & Gynecological Survey*. 2014;69(8):453-455. doi:10.1097/01.ogx.0000453817.62105.4a
5. AIUM Practice Parameter for the Performance of Detailed Diagnostic Obstetric Ultrasound Examinations Between 12 Weeks 0 Days and 13 Weeks 6 Days. *Journal of Ultrasound in Medicine*. Published online August 27, 2020. doi:10.1002/jum.15477
6. SMFM Coding Committee White Paper: Coding for the "new" First Trimester Detailed Diagnostic Obstetric Ultrasound. Society for Maternal Fetal Medicine website. 6-2021
7. AIUM Practice Parameter for the Performance of Detailed Second- and Third-Trimester Diagnostic Obstetric Ultrasound Examinations. *Journal of Ultrasound in Medicine*. 2019;38(12):3093-3100. doi:10.1002/jum.15163
8. ACOG Practice Bulletin No. 200: Early Pregnancy Loss. *Obstetrics & Gynecology*. 2018;132(5):e197-e207. Reaffirmed 2021. doi:10.1097/AOG.0000000000002899
9. Mcintosh J, Feltovich H, Berghella V, Manuck T. The role of routine cervical length screening in selected high- and low-risk women for preterm birth prevention. *American Journal of Obstetrics and Gynecology*. 2016;215(3). doi:10.1016/j.ajog.2016.04.027
10. Donofrio MT, Moon-Grady AJ, Hornberger LK, et al. Diagnosis and Treatment of Fetal Cardiac Disease. *Circulation*. 2014;129(21):2183-2242. doi:10.1161/01.cir.0000437597.44550.5d
11. Cavazos-Rehg PA, Krauss MJ, Spitznagel EL, et al. Maternal Age and Risk of Labor and Delivery Complications. *Maternal and Child Health Journal*. 2014;19(6):1202-1211. doi:10.1007/s10995-014-1624-7
12. ACOG Committee Opinion No. 807: Tobacco and Nicotine Cessation During Pregnancy. *Obstetrics & Gynecology*. 2020;135(5). Reaffirmed 2023. doi:10.1097/aog.0000000000003822
13. Machado JDB, Filho PV, Petersen GO, Chatkin JM. Quantitative effects of tobacco smoking exposure on the maternal-fetal circulation. *BMC Pregnancy and Childbirth*. 2011;11(1). doi:10.1186/1471-2393-11-24
14. Hackshaw A, Rodeck C, Boniface S. Maternal smoking in pregnancy and birth defects: a systematic review based on 173 687 malformed cases and 11.7 million controls. *Human Reproduction Update*. 2011;17(5):589-604. doi:10.1093/humupd/dmr022
15. Regan, Annette K. PhD, MPH; Bombard, Jennifer M. MSPH; O'Hegarty, Michelle M. PhD; Smith, Ruben A. PhD; Tong, Van T. MPH Adverse Birth Outcomes Associated With Prepregnancy and Prenatal Electronic Cigarette Use, *Obstetrics & Gynecology*: July 2021 - Volume 138 - Issue 1 - p 85-94. doi: 10.1097/AOG.0000000000004432
16. Metz TD, Borgelt LM. Marijuana Use in Pregnancy and While Breastfeeding. *Obstetrics & Gynecology*. 2018;132(5):1198-1210. doi:10.1097/aog.0000000000002878
17. ACOG Committee Opinion No. 722: Marijuana Use During Pregnancy and Lactation. *Obstetrics & Gynecology*. 2017;130(4). Reaffirmed 2021. doi:10.1097/aog.0000000000002354
18. ACOG Committee Opinion No. 711: Opioid Use and Opioid Use Disorder in Pregnancy. *Obstetrics & Gynecology*. 2017;130(2). Reaffirmed 2021. doi:10.1097/aog.0000000000002235
19. ACOG Committee Opinion No. 479: Methamphetamine Abuse in Women of Reproductive Age. *Obstetrics & Gynecology*. 2011;117(3):751-755. Reaffirmed 2021. doi:10.1097/aog.0b013e318214784e
20. ACOG Practice Bulletin No. 90: Asthma in Pregnancy. *Obstetrics & Gynecology*. 2008;111(2, Part 1):457-464. Reaffirmed 2020. doi:10.1097/aog.0b013e3181665ff4
21. ACOG Practice Bulletin No. 212. Pregnancy and heart disease. *Obstetrics & Gynecology*. 2019;122:e320-56. Reaffirmed 2021.
22. ACOG Practice Bulletin No. 233: Anemia in Pregnancy. *Obstetrics & Gynecology*. 2021;138:e55-64. doi:10.1097/00006250-200701000-00055
23. ACOG Practice Bulletin No. 223: Thyroid Disease in Pregnancy. *Obstetrics & Gynecology*. 2020;135(6). Reaffirmed 2023. doi:10.1097/aog.0000000000003894
24. Lee, RH; Greenberg, M; Metz, TD; et al. Society for Maternal-Fetal Medicine (SMFM) Consult Series #53: Intrahepatic cholestasis of pregnancy. February 2021

25. Egan N, Bartels Å, Khashan A, et al. Reference standard for serum bile acids in pregnancy. *BJOG: An International Journal of Obstetrics & Gynaecology*. 2012;119(4):493-498. doi:10.1111/j.1471-0528.2011.03245.x
26. Getahun D, Fassett MJ, Longstreth GF, et al. Association between maternal inflammatory bowel disease and adverse perinatal outcomes. *Journal of Perinatology*. 2014;34(6):435-440. doi:10.1038/jp.2014.41
27. ACOG Committee Opinion No. 776. Immune modulating therapies in pregnancy and lactation. *Obstetrics & Gynecology*. 2019;133(4):846-849. Reaffirmed 2021. doi:10.1097/aog.0000000000003177
28. Prabhu M, Kuller JA, Biggio JR. Society for Maternal-Fetal Medicine Consult Series #57: Evaluation and management of isolated soft ultrasound markers for aneuploidy in the second trimester. October 2021
29. ACOG Practice Bulletin No 230. Obesity in Pregnancy. *Obstetrics & Gynecology*: June 2021 - Volume 137 - Issue 6 - p e128-e144 doi: 10.1097/AOG.0000000000004395
30. Schuster M, Madueke-Laveaux OS, Mackeen AD, Feng W, Paglia MJ. The effect of the MFM obesity protocol on cesarean delivery rates. *American Journal of Obstetrics and Gynecology*. 2016;215(4). doi:10.1016/j.ajog.2016.05.005
31. ACOG Practice Bulletin No. 226: Screening for Fetal Chromosomal Abnormalities. *Obstetrics & Gynecology*. 2020;136(4):e48-e69. doi:10.1097/aog.0000000000004084
32. Norton ME, Cheng Y, Chetty S, et al. SMFM Fetal Anomalies Consult Series #4: Genitourinary anomalies. *American Journal of Obstetrics and Gynecology*. 2021;225(5):B2-B35. doi:10.1016/j.ajog.2021.06.009
33. Obstetric Care Consensus No. 8: Interpregnancy Care. *Obstetrics & Gynecology*. 2019;133(1):e51-e72. doi:10.1097/aog.0000000000003025
34. Schummers L, Hutcheon JA, Hernandez-Diaz S, et al. Association of Short Interpregnancy Interval With Pregnancy Outcomes According to Maternal Age. *JAMA Intern Med*. 2018;178(12):1661-1670. doi:10.1001/jamainternmed.2018.4696
35. ACOG Practice Bulletin No. 216: Fetal Macrosomia. *Obstet Gynecol*. 2020; 135(1):246-248. Reaffirmed 2023. doi:10.1097/aog.0000000000003607
36. Frick AP, Syngelaki A, Zheng M, Poon LC, Nicolaides KH. Prediction of large-for-gestational-age neonates: screening by maternal factors and biomarkers in the three trimesters of pregnancy. *Ultrasound Obstet Gynecol*. 2016 Mar;47(3):332-9. doi: 10.1002/uog.15780
37. Viens LJ, Fleck-Derderian S, Baez-Santiago MA, Oduyebo T, Broussard CS, Khan S, Jones AM, Meaney-Delman D. Role of Prenatal Ultrasonography and Amniocentesis in the Diagnosis of Congenital Zika Syndrome: A Systematic Review. *Obstet Gynecol*. 2020 May;135(5):1185-1197. doi: 10.1097/AOG.0000000000003829.
38. Boelig RC, Saccone G, Bellussi F, Berghella V. MFM guidance for COVID-19. *American Journal of Obstetrics & Gynecology MFM*. 2020:100106. doi:10.1016/j.ajogmf.2020.100106
39. Giuliani F, Oros D, Gunier R, et al. Effects of prenatal exposure to maternal COVID-19 and perinatal care on neonatal outcome: results from the INTERCOVID Multinational Cohort Study Published online: April 19, 2022
40. Novoa RH, Quintana W, Llancarí P, Urbina-Quispe K, Guevara-Ríos E, Ventura W. Maternal clinical characteristics and perinatal outcomes among pregnant women with coronavirus disease 2019. A systematic review. *Travel Med Infect Dis*. 2021;39:101919. doi:10.1016/j.tmaid.2020.101919
41. ACOG Practice Bulletin No. 201: Pregestational Diabetes Mellitus. *Obstetrics & Gynecology*. 2018;132(6). Reaffirmed 2023. doi:10.1097/aog.0000000000002960
42. ACOG Practice Bulletin No. 190: Gestational Diabetes Mellitus. *Obstetrics & Gynecology*. 2018;131(2). Reaffirmed 2019. doi:10.1097/aog.0000000000002501
43. ACOG Practice Bulletin No. 203: Chronic Hypertension in Pregnancy. *Obstetrics & Gynecology*. 2019;133(1). doi:10.1097/aog.0000000000003020
44. ACOG Practice Bulletin No. 222: Gestational Hypertension and Preeclampsia. *Obstetrics & Gynecology*. 2020;135(6). Reaffirmed 2023. doi:10.1097/aog.0000000000003891
45. ACOG Practice Bulletin No. 227: Fetal Growth Restriction. *Obstetrics & Gynecology*. 2021;137(2):e16-e28 doi: 10.1097/AOG.0000000000004251
46. Sciscione AC, Hayes EJ. Uterine artery Doppler flow studies in obstetric practice. *American Journal of Obstetrics and Gynecology*. 2009;201(2):121-126. doi:10.1016/j.ajog.2009.03.027
47. Martins JG, Biggio JR, Abuhamad A. Society for Maternal-Fetal Medicine (SMFM) Consult Series #52: Diagnosis and Management of Fetal Growth Restriction. *American Journal of Obstetrics and Gynecology*. 2020. doi:10.1016/j.ajog.2020.05.010
48. ACOG Practice Bulletin No. 171: Management of Preterm Labor. *Obstetrics & Gynecology*. 2020;128(4). Reaffirmed 2022. doi:10.1097/aog.0000000000001711
49. Yang J, Baer RJ, Berghella V, et al. Recurrence of Preterm Birth and Early Term Birth. *Obstetrics & Gynecology*. 2016;128(2):364-372. doi:10.1097/aog.0000000000001506
50. Lengyel CS, Ehrlich S, Iams JD, Muglia LJ, Defranco EA. Effect of Modifiable Risk Factors on Preterm Birth: A Population Based-Cohort. *Maternal and Child Health Journal*. 2016;21(4):777-785. doi:10.1007/s10995-016-2169-8

51. ACOG Practice Bulletin No. 234: Prediction and Prevention of Spontaneous Preterm Birth. *Obstetrics & Gynecology*. 2021;138(2):e65-e90. doi:10.1097/aog.0000000000004479
52. SMFM Statement: Use of 17-alpha hydroxyprogesterone caproate for prevention of recurrent preterm birth. *American Journal of Obstetrics and Gynecology*. 2020. doi:10.1016/j.ajog.2020.04.001
53. Blackwell SC, Gyamfi-Bannerman C, Biggio JR Jr, et al. 17-OHPC to Prevent Recurrent Preterm Birth in Singleton Gestations (PROLONG Study): A Multicenter, International, Randomized Double-Blind Trial. *Am J Perinatol*. 2020;37(2):127–136. doi:10.1055/s-0039-3400227
54. EPPPIC Group. Evaluating Progestogens for Preventing Preterm birth International Collaborative (EPPPIC): meta-analysis of individual participant data from randomised controlled trials. *Lancet*. 2021 Mar 27;397(10280):1183-1194
55. SMFM, 2021. SMFM Statement: Response to EPPPIC and considerations of the use of progestogens for the prevention of preterm birth¹
56. Obstetric Care Consensus No. 10: Management of Stillbirth. *Obstetrics & Gynecology*. 2020;135(3). doi:10.1097/aog.0000000000003719
57. Gardosi J, Madurasinghe V, Williams M, Malik A, Francis A. Maternal and fetal risk factors for stillbirth: population based study. *Bmj*. 2013;346(jan24 3). doi:10.1136/bmj.f108
58. Cummings J; COMMITTEE ON FETUS AND NEWBORN. Antenatal Counseling Regarding Resuscitation and Intensive Care Before 25 Weeks of Gestation. *Pediatrics*. 2015 Sep;136(3):588-95. doi: 10.1542/peds.2015-2336. PMID: 26324869.

High Risk Medications and Substances (OB-10)

Potentially Teratogenic Medications/Substances (OB-10.1)

OB.MS.0010.1.A

v1.0.2024

- If maternal exposure to any of the below Potentially Teratogenic Medications/Substances report:
 - Complete first trimester anatomy ultrasound CPT® 76801 [plus CPT® 76802 for each additional fetus] if <14 weeks and a complete ultrasound has not yet been performed, **and/or** CPT® 76817 for a transvaginal ultrasound
 - CPT® 76801 is preferred for dating, but if this is unable to be completed then CPT® 76815 and/or CPT® 76817 for a transvaginal ultrasound is indicated
 - A detailed first trimester fetal anatomic evaluation can be performed between 12 weeks 0 days and 13 weeks 6 days. (See **Detailed First Trimester Fetal Anatomic Scan (OB-9.12)** for indications)
 - Report: CPT® 76801 **plus** CPT® 76813 (and CPT® 76802 **plus** CPT® 76814 for each additional fetus) for a detailed first trimester fetal anatomy ultrasound
 - A detailed first trimester fetal anatomic evaluation can be performed if indicated, even if cfDNA has been planned or performed
 - CPT® 76811 (detailed fetal anatomy) if ≥16 weeks
 - Though fetal anatomy survey (CPT® 76805/CPT® 76811) can be performed as early as 14 weeks gestation, per ACOG, in the absence of other specific indications, it is optimally performed at 18 to 22 weeks of gestation

Potentially Teratogenic Medications/Substances
Aminoglycosides (amikacin, gentamycin, kanamycin, tobramycin, and other mycins)
Aspirin – only if exposed less than 10 weeks gestation
Benzodiazepines [e.g., Diazepam (valium), Lorazepam (Ativan), Alprazolam (Xanax) etc.]
Codeine
Ergotamine (e.g. Methergine)
Fluconazole (Diflucan)
Lead (Exposure in early pregnancy)
Leflunomide (first trimester exposure)
Marijuana/Cannabinoids/THC Exposure
Methyl mercury
Oral contraceptives (combined and/or progestin only exposure in the first trimester)

Potentially Teratogenic Medications/Substances

Selective serotonin reuptake inhibitors (SSRI) (e.g., Sertraline (Zoloft), Citalopram (Celexa), Fluoxetine (Prozac) etc.)

Serotonin norepinephrine receptor inhibitors (SNRIs) SNRIs (e.g., Venlafexine (Effexor), Duloxetine (Cymbalta), etc.)

Serotonin modulators e.g. Trazadone, etc.

Tricyclics (e.g., Amitriptyline (Elavil), Imipramine (Tofranil) etc.)

Tetracyclines (e.g., Chlortetracycline, Doxycycline, Methacycline, Sumycin, etc.)

- This is **not** an all-inclusive list.
 - See **High Risk Group One – Risk Factors (OB 9.1)** Health Condition Related Risk Factors (maternal diseases or conditions) or other appropriate guideline for indicated imaging based on disease process being treated.
 - See **Medications/Exposures Associated with Poor Pregnancy Outcome (OB 10.2)**
- If documented excessive use (at least weekly) of Marijuana/Cannabinoids/THC in 2nd and/ or 3rd trimesters - See **High Risk Group One – Risk Factors (OB 9.1)**
- Other atypical antidepressants like Bupropion, Mirtazapine, Nefazodone and Duloxetine have **not** been linked to an increased risk of fetal anomalies or poor pregnancy outcomes.

Medications/ Exposures Associated with Poor Pregnancy Outcome (OB-10.2)

OB.MS.0010.2.A

v1.0.2024

- If maternal exposure to any of the Medications or Exposures noted below:
 - Complete first trimester anatomy ultrasound CPT® 76801 [plus CPT® 76802 for each additional fetus] if <14 weeks and a complete ultrasound has not yet been performed, **and/or** CPT® 76817 for a transvaginal ultrasound
 - CPT® 76801 is preferred for dating, but if this is unable to be completed then CPT® 76815 **and/or** CPT® 76817 for a transvaginal ultrasound is indicated
 - A detailed first trimester fetal anatomic evaluation can be performed between 12 weeks 0 days and 13 weeks 6 days. (See **Detailed First Trimester Fetal Anatomic Scan (OB-9.12)** for indications)
 - Report: CPT® 76801 **plus** CPT® 76813 (and CPT® 76802 **plus** CPT® 76814 for each additional fetus) for a detailed first trimester fetal anatomy ultrasound
 - A detailed first trimester fetal anatomic evaluation can be performed if indicated, even if cfDNA has been planned or performed
 - Further imaging as per **High Risk Group One – Risk Factors (OB 9.1)**

Medications/Substances associated with poor pregnancy outcome
Anti-convulsants (e.g., Dilantin, Lamictal, Phenobarbital, Tegretol, Valproate etc.)
Anti-hypertensive Agents (e.g. ACE inhibitors, Angiotensin II Antagonists, Beta Blockers, etc.)
Anti-neoplastic agents (e.g. Daunorubicin etc.)
Anti-psychotics (e.g. Abilify, Haldol, Latuda, Seroquel, Stelazine Thorazine Zyprexa, etc.)
Carbon monoxide
Corticosteroids (e.g. Prednisone, Cortisone, etc.)
Coumadin/ warfarin
Heparin/ Low Molecular Weight Heparin (ongoing use during pregnancy)
Immune Modulating Drugs (e.g. Azathioprine, Cyclophosphamide, Cyclosporin A, Hydroxychloroquine, Leflunomide, Mycophenolate mofetil, etc.)
Lithium
Methimazole
Methotrexate

Medications/Substances associated with poor pregnancy outcome
Mifepristone (RU486)
Misoprostol
Monoamine oxidase inhibitors e.g. Phenelzine (Nardil)
Penicillamine
Pregabalin/Lyrica
Quinine
Retinoic acid/retinoid medications
Stimulants (e.g. Ritalin, adderal, etc. and other stimulants used to treat ADHD)
Thalidomide

- This is **not** an all-inclusive list. See **High Risk Group One – Risk Factors (OB 9.1)** Health Condition Related (maternal diseases or conditions) or other appropriate guideline for indicated imaging based on disease process being treated.

Background and Supporting Information

- Studies that note lower birth weights among offspring exposed to marijuana have noted that these findings were more pronounced among females who used more marijuana, particularly during the first and second trimesters (at least weekly during the pregnancy). CPT® 76811 can be performed, however, given the limited evidence for antenatally detected abnormal growth, serial growth ultrasounds is not indicated in the absence of other findings concerning for growth restriction.
- In circumstances where the individual is deemed to have an increased risk for a fetal abnormality and does not have access to a provider who can perform a fetal anatomic ultrasound examination (CPT® 76811) due to geographic or other constraints, a standard (after first trimester) fetal anatomic ultrasound examination (CPT® 76805) can be authorized instead.
- CPT® 76815 should never be reported with complete studies CPT® 76801/CPT® 76802, CPT® 76805/CPT® 76810 or CPT® 76811/CPT® 76812 or with CPT® 76816 or BPP (CPT® 76818 and CPT® 76819)
- Though fetal anatomy survey (CPT® 76805/CPT® 76811) can be performed as early as 14 weeks gestation, per ACOG, in the absence of other specific indications, it is optimally performed at 18 to 22 weeks of gestation

References (OB-10)

v1.0.2024

1. Practice Bulletin No. 175: Ultrasound in Pregnancy. *Obstetrics & Gynecology*. 2016;128(6):e241-e256. Reaffirmed 2022. doi:10.1097/AOG.0000000000001815
2. ACOG Practice Bulletin No. 92: Use of Psychiatric Medications During Pregnancy and Lactation. *Obstetrics & Gynecology*. 2008;111(4):1001-1020. Reaffirmed 2018. doi:10.1097/AOG.0b013e31816fd910
3. Burkey BW, Holmes AP. Evaluating Medication Use in Pregnancy and Lactation: What Every Pharmacist Should Know. *The Journal of Pediatric Pharmacology and Therapeutics*. 2013;18(3):247-258. doi:10.5863/1551-6776-18.3.247
4. ACOG Committee Opinion No. 711: Opioid Use and Opioid Use Disorder in Pregnancy. *Obstetrics & Gynecology*. 2017;130(2):e81-e94. Reaffirmed 2021. doi:10.1097/aog.0000000000002235
5. Schaefer C, Peters PWJ, Miller RK. *Drugs during Pregnancy and Lactation: Treatment Options and Risk Assessment*. 3rd ed. London: Elsevier/Academic Press; 2015
6. ACOG Committee Opinion No. 776 Immune Modulating Therapies in Pregnancy and Lactation. *Obstetrics & Gynecology*. 2019;133(4):846-849. Reaffirmed 2021. doi:10.1097/aog.0000000000003177
7. ACOG Committee Opinion No. 722: Marijuana Use During Pregnancy and Lactation. *Obstetrics & Gynecology*. 2017;130(4). Reaffirmed 2021. doi:10.1097/aog.0000000000002354
8. Reprotox • Home Page. reprotox.org. <http://reprotox.org>

Multiple Gestations (OB-11)

Suspected Multiple Gestations (OB-11.1)

OB.MG.0011.1.A

v1.0.2024

For Suspected multiple pregnancies:

- Complete first trimester ultrasound CPT® 76801 [plus CPT® 76802 for each additional fetus] if <14 weeks and a complete ultrasound has not yet been performed, **and/or** CPT® 76817 for a transvaginal ultrasound
 - CPT® 76801 is preferred for dating, but if this is unable to be completed then CPT® 76815 and/or CPT® 76817 for a transvaginal ultrasound is indicated
- CPT® 76805 and CPT® 76810 for each additional fetus if ≥14 weeks if a dating ultrasound or a complete anatomy ultrasound has not yet been performed during this pregnancy

Known Dichorionic Multiple Gestations (OB-11.2)

OB.MG.0011.2.A

v1.0.2024

For Known dichorionic multiple pregnancies:

- Complete first trimester anatomy ultrasound CPT[®] 76801 [plus CPT[®] 76802 for each additional fetus] if <14 weeks and a complete ultrasound has not yet been performed, **and/or** CPT[®] 76817 for a transvaginal ultrasound
 - CPT[®] 76801 is preferred for dating, but if this is unable to be completed then CPT[®] 76815 and/or CPT[®] 76817 for a transvaginal ultrasound is indicated
- A detailed first trimester fetal anatomic evaluation^{3,4} can be performed between 12 weeks 0 days and 13 weeks 6 days. (See **Detailed First Trimester Fetal Anatomic Scan (OB-9.12)** for indications)
 - Report: CPT[®] 76801 **plus** CPT[®] 76813 (and CPT[®] 76802 **plus** CPT[®] 76814 for each additional fetus) for a detailed first trimester fetal anatomy ultrasound
 - A detailed first trimester fetal anatomic evaluation can be performed if indicated, even if cfDNA has been planned or performed
- Fetal NT (CPT[®] 76813) can be performed in twins and higher order multiples even if cfDNA has already been planned or performed.¹ See **First Trimester Screening (OB-6.1)**
- CPT[®] 76811 and CPT[®] 76812 for each additional fetus at ≥16 weeks if a complete detailed anatomic scan (CPT[®] 76811) has not yet been performed
 - Though fetal anatomy survey (CPT[®] 76805/CPT[®] 76811) can be performed as early as 14 weeks gestation, per ACOG, in the absence of other specific indications, it is optimally performed at 18 to 22 weeks of gestation
- Transvaginal ultrasound (CPT[®] 76817) can be performed if the transabdominal cervical length (CL) is ≤3.6 cm. If documented transabdominal attempt fails to visualize cervix, then CPT[®] 76817 may be performed on a case by case basis. See **Cervical Length Screening (OB-7.3)**. If cervical shortening is identified – See **Cervical Insufficiency (OB-18.1)**
- Growth ultrasound (CPT[®] 76816) can be done every 4 to 6 weeks at ≥14 weeks.
- If otherwise uncomplicated dichorionic twins, perform BPP (CPT[®] 76818 or CPT[®] 76819) **or** modified BPP (CPT[®] 76815) weekly starting at 36 weeks
- If additional risk factors (e.g. diabetes, or hypertensive disease), BPP (CPT[®] 76818 or CPT[®] 76819) **or** modified BPP (CPT[®] 76815) can be performed weekly starting at 32 weeks or sooner (See **High Risk Pregnancy (OB-9)**)

For Known dichorionic multiple pregnancies:

- Fetal loss of one twin during the first trimester does not appear to increase the risk of FGR or preterm delivery in the surviving twin, however, loss of one or more fetus(es) after the first trimester is associated with increased risk for FGR and PTB
 - Dichorionic twin gestations with loss of one fetus after the first trimester (≥ 14 weeks) should be imaged according to **High Risk Group (OB-9.1)**
- If FGR or growth discordance $\geq 20\%$ is diagnosed, can perform:
 - CPT[®] 76816 (growth ultrasound) every 2 to 4 weeks
 - Modified BPP (CPT[®] 76815) up to twice weekly starting at ≥ 22 weeks, or BPP (CPT[®] 76818 or CPT[®] 76819) up to twice weekly starting at ≥ 26 weeks
 - UA Doppler (CPT[®] 76820) weekly (starting at ≥ 22 weeks)
- If Severe FGR (EFW $\leq 3\%$, AC $\leq 3\%$), **OR** Abnormal UA Doppler studies (defined as a PI, RI, or S/D ratio greater than the 95th percentile for gestational age **OR** absent or reversed end-diastolic velocity (AEDV or REDV), **OR** confirmed oligohydramnios:
 - BPP (CPT[®] 76818 or CPT[®] 76819 or CPT[®] 76815) and/or umbilical artery (UA) Doppler (CPT[®] 76820) may be needed more frequently (2-3 times per week, or even daily).
- If IVF dichorionic twins, report an initial fetal echo as CPT[®] 76825 and/or CPT[®] 76827 with or without CPT[®] 93325. Trans-abdominal fetal echo is usually not performed prior to 16 weeks. See **Indications for Maternal Conditions (OB-12.3)**
- If other high risk factors, See **High Risk Pregnancy (OB-9)**

Known Monochorionic-Diamniotic or Monochorionic-Monoamniotic Multiple Gestations (OB-11.3)

OB.MG.0011.3.A

v1.0.2024

For Known monochorionic-diamniotic or monochorionic-monoamniotic multiple pregnancies

- Complete first trimester anatomy ultrasound CPT® 76801 [plus CPT® 76802 for each additional fetus] if <14 weeks and a complete ultrasound has not yet been performed, **and/or** CPT® 76817 for a transvaginal ultrasound
 - CPT® 76801 is preferred for dating, but if this is unable to be completed then CPT® 76815 and/or CPT® 76817 for a transvaginal ultrasound is indicated
- A detailed first trimester fetal anatomic evaluation^{3,4} can be performed between 12 weeks 0 days and 13 weeks 6 days. (See **Detailed First Trimester Fetal Anatomic Scan (OB-9.12)** for indications).
 - Report: CPT® 76801 **plus** CPT® 76813 (and CPT® 76802 **plus** CPT® 76814 for each additional fetus) for a detailed first trimester fetal anatomy ultrasound
 - A detailed first trimester fetal anatomic evaluation can be performed if indicated, even if cfDNA has been planned or performed
- Fetal NT (CPT® 76813) can be performed in twins and higher order multiples even if cfDNA has already been planned or performed.¹
- CPT® 76811 and CPT® 76812 for each additional fetus at ≥16 weeks if a complete detailed anatomic scan (CPT® 76811) has not yet been performed
 - Though fetal anatomy survey (CPT® 76805/CPT® 76811) can be performed as early as 14 weeks gestation, per ACOG, in the absence of other specific indications, it is optimally performed at 18 to 22 weeks of gestation
- Universal cervical length (CL) screening with transvaginal ultrasound (CPT® 76817) is NOT recommended in monochorionic twin gestations.
 - Transvaginal ultrasound (CPT® 76817) can be performed if the transabdominal cervical length (CL) is ≤3.6 cm. If documented transabdominal attempt fails to visualize cervix, then CPT® 76817 may be performed on a case by case basis. See **Cervical Length Screening (OB-7.3)**. If cervical shortening is identified – See **Cervical Insufficiency (OB-18.1)**

For Known monochorionic-diamniotic or monochorionic-monoamniotic multiple pregnancies

- CPT® 76816 (growth ultrasound) every 2 to 4 weeks starting at 14 weeks
 - Initial Fetal Echo (CPT® 76825 and/or CPT® 76827) with or without color Doppler (CPT® 93325) (usually not performed <16 weeks).
 - MCA Doppler (CPT® 76821) is indicated every 2 weeks starting at 16 weeks until delivery to monitor for Twin-Twin Transfusions Syndrome (TTTS) and/or Twin Anemia Polycythemia Sequence (TAPS). This can be performed with a limited ultrasound (CPT® 76815) or growth ultrasound (CPT® 76816).
-
- Perform BPP (CPT® 76818 or CPT® 76819) or modified BPP (CPT® 76815) weekly starting at 32 weeks or sooner if additional risk factors (eg. diabetes, or hypertensive disease - See **High Risk Pregnancy (OB-9)**)
-
- If TTTS is suspected or diagnosed, or if FGR or growth discordance ≥20% is diagnosed perform:
 - BPP (CPT® 76818 or CPT® 76819 (≥26 weeks) or CPT® 76815) and/or umbilical artery (UA) Doppler (CPT® 76820) and/or MCA Doppler (CPT® 76821) 2 to 3 times per week (May be needed more frequently on a case-by-case basis)
 - TTTS is diagnosed by the ultrasound findings of polyhydramnios in one twin (the recipient) and oligohydramnios in the other twin (the donor). If AFI is discordant between the twins (low but not <2 cm in one and/or high but not >8 cm in the other); weekly imaging (MCA and/or limited US) can be performed
 - If TTTS is diagnosed, follow-up fetal echo (CPT® 76826 and/or CPT® 76828) with or without color Doppler (CPT® 93325) can also be performed as requested. See **Fetal Echocardiography - Coding (OB-12.1)** and **Fetal Echocardiology - Indications for Fetal Conditions (OB-12.2)**
-
- Fetal loss of one twin during the first trimester does not appear to increase the risk of FGR or preterm delivery in the surviving twin, however, loss of one or more fetus(es) after the first trimester is associated with increased risk for FGR and PTB.
-
- Monochorionic gestations or higher order Multiple pregnancy with loss of one or more fetus(es) after the first trimester (≥14 weeks) should be imaged according to **Multiple Gestations (OB-11.3)**.
-
- If other high risk factors, See **High Risk Pregnancy (OB-9)**
-
- Triplets or higher order Multiple Pregnancy receive same imaging as monochorionic-diamniotic twins.

Background and Supporting Information

- The sensitivity of cfDNA screening may not be as accurate in twins and higher order multiples. First trimester screening in twins has a similar detection rate to singleton gestation.
- Birth weight discordance = (larger twin weight minus smaller twin weight) divided larger twin weight × 100.
- Universal CL screening with transvaginal ultrasound (CPT® 76817) is NOT recommended in twin gestations. In addition, Per ACOG - Cerclage placement (prophylactic or rescue) should be avoided in multifetal pregnancies. However, because several studies have shown that a one-time CL measurement ≤20 mm at 18-24 weeks may be an accurate predictor of preterm birth in multiple gestation, and because progesterone therapy might reduce the risk of neonatal morbidity and mortality associated with PTB, then a one-time transvaginal CL assessment can be performed if trans-abdominal CL measures ≤3.6 cm (as with singleton gestation- See **Cervical Length Screening (OB-7.3)**).
- TTTS is diagnosed by the ultrasound findings of polyhydramnios in one twin (the recipient) and oligohydramnios in the other twin (the donor). If AFI is discordant between the twins (low but not <2 cm in one and/or high but not >8 cm in the other); weekly imaging (MCA and/or limited US) can be performed to rule-out developing TTTS.
- There is no evidence that routine assessment with UA Doppler is beneficial in the absence of growth or fluid discordance.¹
- Fetal loss of one twin during the first trimester does not appear to increase the risk of FGR or preterm delivery in the surviving twin, however, loss of one or more fetus(es) after 17 weeks gestation is associated with increased risk for FGR and PTB and should be imaged according to **Multiple Gestations (OB-11)**. Monochorionic twin pregnancies with demise of one twin after 17 weeks have up to an 18% chance of major morbidity or mortality for the remaining fetus.
- Typically all components of the BPP (CPT® 76818 and CPT® 76819), such as breathing, are not present until ≥26 weeks gestation. However, a modified BPP (CPT® 76815) can be performed sooner in certain high risk cases but should not be done prior to 22 weeks.
- CPT® 76815 should never be reported with complete studies CPT® 76801/CPT® 76802, CPT® 76805/CPT® 76810 or CPT® 76811/CPT® 76812 or with CPT® 76816 or BPP (CPT® 76818 and CPT® 76819)
- Though fetal anatomy survey (CPT® 76805/CPT® 76811) can be performed as early as 14 weeks gestation, per ACOG, in the absence of other specific indications, it is optimally performed at 18 to 22 weeks of gestation
- In circumstances where CPT® 76811 cannot be performed See **Ultrasound Code Selection (OB-1.3)**

References (OB-11)

v1.0.2024

1. ACOG Practice Bulletin No. 231: Multifetal Gestations: Twin, Triplet, and Higher-Order Multifetal Pregnancies. *Obstetrics & Gynecology*. 2021;137:e145-62
2. ACOG Practice Bulletin No. 175: Ultrasound in Pregnancy. *Obstetrics & Gynecology*. 2016;128(6):e241-e256. Reaffirmed 2022. doi:10.1097/AOG.0000000000001815
3. AIUM Practice Parameter for the Performance of Detailed Diagnostic Obstetric Ultrasound Examinations Between 12 Weeks 0 Days and 13 Weeks 6 Days. *Journal of Ultrasound in Medicine*. Published online August 27, 2020. doi:10.1002/jum.15477
4. SMFM Coding Committee White Paper: Coding for the "new" First Trimester Detailed Diagnostic Obstetric Ultrasound. Society for Maternal Fetal Medicine website. 6-2021
5. Khalil A, Rodgers M, Baschat A, et al. ISUOG Practice Guidelines: role of ultrasound in twin pregnancy. *Ultrasound in Obstetrics & Gynecology*. 2016;47(2):247-263. doi:10.1002/uog.1582
6. ACOG Practice Bulletin No. 234: Prediction and Prevention of Spontaneous Preterm Birth. *Obstetrics & Gynecology*. 2021;138:e65-90
7. ACOG Practice Bulletin No. 142: Cerclage for the Management of Cervical Insufficiency. *Obstetrics & Gynecology*. 2014;123(2, PART 1):372-379. Reaffirmed 2020. doi:10.1097/01.aog.0000443276.68274.cc
8. Rafael TJ, Berghella V, Alfirevic Z. Cervical stitch (cerclage) for preventing preterm birth in multiple pregnancy. *Cochrane Database of Systematic Reviews*. September 2014. doi:10.1002/14651858.cd009166.pub2
9. Roman A, Rochelson B, Fox NS, Hoffman M, Berghella V, Patel V, Calluzzo I, Saccone G, Fleischer A. Efficacy of ultrasound-indicated cerclage in twin pregnancies. *Am J Obstet Gynecol*. 2015 Jun;212(6):788.e1-6. doi: 10.1016/j.ajog.2015.01.031
10. Razaz N, Avitan T, Ting J, Pressey T, Joseph K. Perinatal outcomes in multifetal pregnancy following fetal reduction. *Canadian Medical Association Journal*. 2017;189(18). doi:10.1503/cmaj.160722
11. Mcintosh J, Feltoich H, Berghella V, Manuck T. The role of routine cervical length screening in selected high- and low-risk women for preterm birth prevention. Society for Maternal-Fetal Medicine (SMFM) Consult Series #40. *American Journal of Obstetrics and Gynecology*. 2016;215(3). doi:10.1016/j.ajog.2016.04.027
12. EPPPIC Group. Evaluating Progestogens for Preventing Preterm birth International Collaborative (EPPPIC): meta-analysis of individual participant data from randomised controlled trials. *Lancet*. 2021 Mar 27;397(10280):1183-1194
13. SMFM, 2021. SMFM Statement: Response to EPPPIC and considerations of the use of progestogens for the prevention of preterm birth
14. Practice Committee of American Society for Reproductive Medicine: Multiple gestation associated with infertility therapy: an American Society for Reproductive Medicine Practice Committee opinion. *Fertility and Sterility*. 2012;97(4):825-834. doi:10.1016/j.fertnstert.2011.11.048
15. Slaghekke F, Pasman S, Veujoz M, et al. Middle cerebral artery peak systolic velocity to predict fetal hemoglobin levels in twin anemia-polycythemia sequence. *Ultrasound in Obstetrics & Gynecology*. 2015;46(4):432-436. doi:10.1002/uog.14925
16. Lopriore E, Slaghekke F, Oepkes D, Middeldorp JM, Vandenbussche FP, Walther FJ. Clinical outcome in neonates with twin anemia-polycythemia sequence. *American Journal of Obstetrics and Gynecology*. 2010;203(1). doi:10.1016/j.ajog.2010.02.032
17. Slaghekke F, Kist W, Oepkes D, et al. Twin Anemia-Polycythemia Sequence: Diagnostic Criteria, Classification, Perinatal Management and Outcome. *Fetal Diagnosis and Therapy*. 2010;27(4):181-190. doi:10.1159/000304512.
18. Tollenaar LSA, Slaghekke F, Middeldorp JM, et al. Twin Anemia Polycythemia Sequence: Current Views on Pathogenesis, Diagnostic Criteria, Perinatal Management, and Outcome. *Twin Research and Human Genetics*. 2016;19 (3):222-233. doi:10.1017/thg.2016.18
19. ACOG Practice Bulletin No. 227: Fetal Growth Restriction. *Obstetrics & Gynecology*. 2021;137(2):e16-e28 doi: 10.1097/AOG.0000000000004251
20. Martins JG, Biggio JR, Abuhamad A. Society for Maternal-Fetal Medicine (SMFM) Consult Series #52: Diagnosis and Management of Fetal Growth Restriction. *American Journal of Obstetrics and Gynecology*. 2020. doi:10.1016/j.ajog.2020.05.010
21. Simpson LL. Twin-twin transfusion syndrome. *American Journal of Obstetrics and Gynecology*. 2013;208(1):3-18. doi:10.1016/j.ajog.2012.10.880
22. Lanna MM, Consonni D, Faiola S, et al. Incidence of Cerebral Injury in Monochorionic Twin Survivors after Spontaneous Single Demise: Long-Term Outcome of a Large Cohort. *Fetal Diagnosis and Therapy*. 2019;47(1):66-73. doi:10.1159/000500774.Hoskins

23. SMFM Special Statement: Updated checklists for management of monochorionic twin pregnancy. *American Journal of Obstetrics and Gynecology*. 2020
24. ACOG Committee Opinion No. 828. Indications for outpatient antenatal fetal surveillance. American College of Obstetricians and Gynecologists. *Obstetrics & Gynecology*. 2021;137:e177–97. doi:10.1097/aog.0000000000004407
25. Roman A, Zork N, Haeri S, Schoen CN, Saccone G, Colihan S, Zelig C, Gimovsky AC, Seligman NS, Zullo F, Berghella V. Physical examination-indicated cerclage in twin pregnancy: a randomized controlled trial. *Am J Obstet Gynecol*. 2020 Jun 25:S0002-9378(20)30672-4. doi: 10.1016/j.ajog.2020.06.047. Epub ahead of print. PMID: 32592693
26. Society for Maternal-Fetal Medicine: Eighteen Things Physicians and Patients Should Question. Released February 3, 2014 (1–4); February 1, 2016 (5–9); May 1, 2019 (10–13); Revised January 14, 2021; March 10, 2021 (14–18); Revised December 15, 2022

Fetal Echocardiography (ECHO) (OB-12)

Fetal Echocardiography – Coding (OB-12.1)

OB.FE.0012.1.A
v1.0.2024

- Supported fetal echocardiography (echo) codes include:
 - Initial Fetal Echo, CPT® 76825 and Doppler Echo CPT® 76827 are performed only once per fetus/per facility (i.e. Maternal Fetal Medicine versus Pediatric Cardiology request)
 - Follow-up-Fetal echo and/or Follow-up Doppler echo (CPT® 76826/CPT® 76828)
 - CPT® 93325 for Doppler color flow velocity mapping
- An initial fetal echo is usually not performed prior to 16 weeks.
- Doppler echo procedure codes (CPT® 76827 or CPT® 76828) include the evaluation of veins, arteries, and valves. Guidelines do not support the billing of additional codes (CPT® 76820 and/or CPT® 76821)

Background and Supporting Information

- The minimal use of color Doppler (CPT® 93325) alone, when performed for anatomical structure identification during a standard ultrasound procedure, is not separately reimbursable

Fetal Echocardiography - Indications for Fetal Conditions (OB-12.2)

OB.FE.0012.2.A

v1.0.2024

Initial Fetal echocardiography (CPT® 76825) and/or Doppler echocardiography (CPT® 76827) with or without Doppler color flow velocity mapping (CPT® 93325) can be performed if ≥16 weeks, for the indications listed below (See **Fetal Echocardiography – Coding (OB-12.1)**):

Fetal Echocardiography - Indications for Fetal Conditions

- Known or suspected abnormal fetal cardiac evaluation on fetal anatomic scan.
 - Known or suspected abnormality must be documented as hard copy or acknowledged verbally by provider of known or suspected fetal cardiac evaluation
 - Suboptimal cardiac evaluation alone is not an indication for fetal echogram. If the 4-chamber view is adequate and there is no other suspicion of a cardiac abnormality, a fetal echocardiogram is not considered medically necessary. A follow up ultrasound (CPT® 76815 or CPT® 76816) is indicated for suboptimal visualization. If the follow-up ultrasound fails to show a 4-chamber view or there is suspicion of a cardiac abnormality, fetal echocardiogram is indicated.
- Fetal cardiac arrhythmia; persistent fetal tachycardia or bradycardia
- Major fetal extra-cardiac anomaly
- Fetal Echo is NOT indicated for an isolated soft marker found on routine imaging including:
 - Choroid plexus cyst, or
 - Echogenic intra-cardiac foci, or
 - Thickened nuchal fold (≥6mm at 15 to 20 weeks), or
 - Absent or hypoplastic nasal bone, or
 - Echogenic bowel, or
 - Shortened long bones, or
 - Pyelectasis
- Congenital heart disease (CHD) in a 1st degree relative of the fetus (i.e. CHD in the mother, father, or sibling of the fetus) or a half-sibling of the fetus
- Known fetal chromosomal abnormalities (fetal aneuploidy) or ultrasound findings of a suspected chromosomal abnormality (excluding soft markers as only ultrasound findings)
 - Early onset FGR (<32 weeks) may be a sign of fetal aneuploidy^{11,12}

Fetal Echocardiography - Indications for Fetal Conditions

- Single umbilical artery
- Chorioangioma or Umbilical cord varix (if suspicion of fetal hydrops)
- Fetal intra-abdominal venous anomaly (persistent right umbilical vein)
- Fetal effusion (pericardial, pleural effusion, ascites, etc.)
- Fetal hydrops, See **Alloimmunization/Rh Isoimmunization/Other Causes of Fetal Anemia/Parvo/Hydrops (OB-16)**
- Monochorionic twins/TTTS
- Abnormal Fetal Nuchal Translucency scan (NT ≥ 3.0 mm or above the 95th percentile for the CRL) during current pregnancy.
- Abnormal ductus venosus waveform⁵
- Fetal echocardiography may be indicated with severe or unexplained polyhydramnios, or if there are also other suspicious findings on an anatomy scan

Fetal Echocardiography - Indications for Maternal Conditions (OB-12.3)

OB.FE.0012.3.A

v1.0.2024

Initial Fetal echocardiography (CPT® 76825) and/or Doppler echocardiography (CPT® 76827) with or without Doppler color flow velocity mapping (CPT® 93325) can be performed if ≥16 weeks, for the indications listed below (See **Fetal Echocardiography – Coding (OB-12.1)**):

Maternal Conditions:

- Maternal pre-gestational DM or early diagnosed GDM (1st or early 2nd trimester)
- Maternal gestational diabetes mellitus, if HbA1C >6% [in the third trimester (≥32 weeks)]
- Maternal connective tissue disease (SLE, RA, Sjogrens) with Anti-Ro/SSA or anti-La/SSB antibodies present
 - Weekly follow-up Fetal echocardiography (CPT® 76826) and/or Doppler fetal echocardiography (CPT® 76828) or CPT® 76815 from the 18th through the 26th week of pregnancy and then every other week until 30 weeks
- Phenylketonuria
- Infections associated with cardiac anomalies (such as parvovirus, Rubella, Coxsackie virus)
- Genetic conditions associated with CHD in a first degree relative of the fetus (e.g. Marfan syndrome, 22q11.2 deletion syndrome (DiGeorge Syndrome) or Noonan syndrome)
- Prior child with CHD born to mother and/or father of the fetus⁵
- Pregnancy conceived by assisted reproductive technology:¹
 - In Vitro Fertilization (IVF)
 - Intracytoplasmic sperm injection (ICSI)¹

Background and Supporting Information

- If diabetes is diagnosed prior to pregnancy or in the first or early second trimester (typically before 20 weeks gestation) with standard diagnostic criteria of: HbA1C ≥6.5%, fasting plasma glucose ≥126 mg/dL, or 2-hour glucose ≥200 mg/dL on a 75-g oral glucose tolerance test, then image as above
- For those with GDM on medication, if HbA1c levels are >6%, fetal echocardiogram in the third trimester to assess for ventricular hypertrophy can be performed.
- With positive SSA/SSB antibodies, the most vulnerable period for the fetus is during the period from 18 to 24 weeks gestation. Normal sinus rhythm can progress to complete block in seven days during this high-risk period. New onset of heart block

is less likely during the 26th through the 30th week, and it rarely develops after 30 weeks of pregnancy.

Fetal Echocardiography - Indications for Medication or Drug Exposure (OB-12.4)

OB.FE.0012.4.A

v1.0.2024

Initial Fetal echocardiography (CPT® 76825) and/or Doppler echocardiography (CPT® 76827) with or without Doppler color flow velocity mapping (CPT® 93325) can be performed if ≥16 weeks, for the indications listed below (See **Fetal Echocardiography – Coding (OB-12.1)**):

- Ace inhibitors
- Alcohol (excessive quantities)
- Anti-seizure medication, e.g. carbamazepine, hydantoin, valproate
- Folate antagonists (methotrexate)
- Lithium
- NSAIDS (Ibuprofen, Indomethacin) 2nd and 3rd trimester
- Paroxetine (Paxil)
- Retinoids (e.g Isotretinoin, Retinoic acid, Vitamin A -over 10,000 IU per day, etc.)
- Thalidomide
- Venlafaxine (Effexor)
- This may not be an all-inclusive list, however, exposure to other potential teratogens associated with cardiac anomalies in the fetus are typically adequately assessed with a detailed fetal anatomy ultrasound. (CPT® 76811) (See **Potentially Teratogenic Medications/Substances (OB 10.1)**)

References (OB-12)

v1.0.2024

1. Donofrio MT, Moon-Grady AJ, Hornberger LK, et al. Diagnosis and Treatment of Fetal Cardiac Disease. *Circulation*. 2014;129(21):2183-2242. doi:10.1161/01.cir.0000437597.44550.5d
2. Brucato A. Prevention of congenital heart block in children of SSA-positive mothers. *Rheumatology*. 2008;47(Supplement 3):iii35-iii37. doi:10.1093/rheumatology/ken153
3. McBride KL, Garg V. Impact of Mendelian inheritance in cardiovascular disease. *Annals of the New York Academy of Sciences*. 2010;1214(1):122-137. doi:10.1111/j.1749-6632.2010.05791.x
4. Reddy UM, Abuhamad AZ, Levine D, et al. Fetal imaging: executive summary of a joint Eunice Kennedy Shriver National Institute Child Health and Human Development, Society for Maternal-Fetal Medicine, American Institute of Ultrasound in Medicine, American College of Obstetricians and Gynecologists, American College of Radiology, Society of Pediatric Radiology, and Society of Radiologists in Ultrasound Fetal Imaging Workshop. *Obstet Gynecol Survey*. 2014;69(8):453-455
5. Lee W, Allan L, Carvalho JS, et al. ISUOG consensus statement: what constitutes a fetal echocardiogram? *Ultrasound in Obstetrics and Gynecology*. 2008;32(2):239-242. doi:10.1002/uog.6115
6. Friedman DM, Kim MY, Copel JA, et al. Utility of Cardiac Monitoring in Fetuses at Risk for Congenital Heart Block. The PR Interval and Dexamethasone Evaluation (PRIDE) Prospective Study. *Circulation*. 2008;117(4):485-493. doi:10.1161/circulationaha.107.707661
7. AIUM Practice Parameter for the Performance of Fetal Echocardiography. *Journal of Ultrasound in Medicine*. 2019;39(1). doi:10.1002/jum.15188
8. Sammaritano LR, Bermas BL, Chakravarty EE, et al. 2020 American College of Rheumatology Guideline for the Management of Reproductive Health in Rheumatic and Musculoskeletal Diseases. *Arthritis Care & Research*. 2020;72(4):461-488. doi:10.1002/acr.24130
9. Jenkins KJ, Correa A, Feinstein JA, et al. Noninherited Risk Factors and Congenital Cardiovascular Defects: Current Knowledge. *Circulation*. 2007;115(23):2995-3014. doi:10.1161/circulationaha.106.183216
10. Anderson KN, Lind JN, Simeone RM, Bobo WV, Mitchell AA, Riehle-Colarusso T, Polen KN, Reefhuis. Maternal Use of Specific Antidepressant Medications During Early Pregnancy and the Risk of Selected Birth Defects. *JAMA Psychiatry*. 2020 Aug 5;77(12):1246-55. doi: 10.1001/jamapsychiatry.2020.2453
11. ACOG Practice Bulletin No. 227: Fetal Growth Restriction. *Obstet Gynecol*. 2021;137(2):e16-e28 doi: 10.1097/AOG.0000000000004251
12. Martins JG, Biggio, JR, Abuhamad, A. Society for Maternal-Fetal Medicine (SMFM) Consult Series #52: Diagnosis and Management of Fetal Growth Restriction. 2020 doi:10.1016/j.ajog.2015.01.059
13. Turan S, Asoglu MR, Ozdemir H, Seger L, Turan OM. Accuracy of the Standardized Early Fetal Heart Assessment in Excluding Major Congenital Heart Defects in High-Risk Population: A Single-Center Experience. *J Ultrasound Med*. 2022 Apr;41(4):961-969. doi: 10.1002/jum.15782. Epub 2021 Jul 20.

Fetal MRI (OB-13)

Indications for Fetal MRI (OB-13.1)

OB.MR.0013.1.A

v1.0.2024

ACOG recommendations for imaging during pregnancy and lactation:

- Ultrasonography and magnetic resonance imaging (MRI) are not associated with risk and are the imaging techniques of choice for the pregnant patient, but they should be used prudently and only when use is expected to answer a relevant clinical question or otherwise provide medical benefit to the patient.
- The use of gadolinium contrast with MRI should be limited; it should be used as a contrast agent in a pregnant female only if it significantly improves diagnostic performance and is expected to improve fetal or maternal outcome.

CPT® Code Guidance

- Fetal MRI (CPT® 74712); for each additional fetus (CPT® 74713)
- Do not report CPT® 74712 and CPT® 74713 in conjunction with CPT® 72195, CPT® 72196, CPT® 72197
- If only placenta or maternal pelvis is imaged without fetal imaging, use MRI Pelvis (CPT® 72195)

- Fetal MRI (CPT® 74712) [plus CPT® 74713 for each additional fetus] optimally performed after 18 to 22 weeks gestation, for assessment of known or suspected fetal abnormalities for counseling, surgical, or delivery planning.
 - There are cases when surgical planning may necessitate imaging earlier than 18 weeks. For those cases where surgery is to be performed prior to 18 weeks and they otherwise meet indications for imaging per this criteria, Fetal MRI may be approved.
- 3D-4D (CPT® 76376 or CPT® 76377) rendering can be added for surgical planning with diagnosis of complex CHD in the fetus or for surgical planning of other complex fetal malformations⁶.
- Repeat fetal MRI (CPT® 74712) [plus CPT® 74713 for each additional fetus] later in pregnancy for:
 - Delivery or perinatal surgical planning
- Fetal MRI indications include but may not be limited to the following:
 - Brain
 - Congenital anomalies
 - Ventriculomegaly
 - Agenesis of the corpus callosum
 - Abnormalities of the cavum septum pellucidum
 - Holoprosencephaly
 - Posterior fossa anomalies

- Malformations of cerebral cortical development
- Microcephaly
- Solid or cystic masses
- Cephalocele
- Screening fetuses with a family risk for brain anomalies
 - Tuberous sclerosis
 - Corpus callosal dysgenesis
 - Malformations of cerebral cortical development
- Vascular abnormalities
 - Vascular malformations
 - Hydranencephaly
 - Intra-uterine cerebrovascular accident (CVA)
- Spine
 - Congenital anomalies
 - Neural tube defects
 - Sacrococcygeal teratomas
 - Caudal regression/sacral agenesis
 - Syringomyelia
 - Vertebral anomalies
- Skull, face, and neck
 - Masses of the face and neck
 - Vascular or lymphatic malformations
 - Hemangiomas
 - Goiter
 - Teratomas
 - Facial clefts
 - Airway obstruction
 - Conditions that may impact parental counseling, prenatal management, delivery planning, and postnatal therapy
- Thorax
 - Masses
 - Congenital pulmonary airway malformations (congenital cystic adenomatoid malformation; sequestration, and congenital lobar emphysema);
 - Congenital diaphragmatic hernia
 - Effusion
 - Mediastinal masses
 - Assessment for esophageal atresia
 - Volumetric assessment of lung

- Cases at risk for pulmonary hypoplasia secondary to oligohydramnios, chest mass, or skeletal dysplasias
- Abdomen, retroperitoneal and pelvis
 - Bowel anomalies such as anorectal malformations, or complex bowel obstructions such as with megacystis microcolon hypoperistalsis syndrome
 - Abdominal wall defect
 - Mass
 - Abdominal–pelvic cyst
 - Tumors (e.g. hemangiomas, neuroblastomas, sacrococcygeal teratomas, and suprarenal or renal masses)
 - Complex genitourinary anomalies (e.g. cloaca, prune belly syndrome)
- Congenital Heart Disease (CHD)
- Skeletal dysplasia
- Multiple malformations
- Complications of monozygotic twins/TTTS (eg. Laser treatment of twins, demise of one twin, conjoined twins)
- Any suspected fetal anomaly associated with severe oligohydramnios or anhydramnios

References (OB-13)

v1.0.2024

1. Saleem SN. Fetal MRI: An approach to practice: A review. *Journal of Advanced Research*. 2014;5(5):507-523. doi:10.1016/j.jare.2013.06.001
2. Prayer D, Malinge G, Brugger PC, et al. ISUOG Practice Guidelines: performance of fetal magnetic resonance imaging. *Ultrasound in Obstetrics & Gynecology*. 2017;49(5):671-680. doi:10.1002/uog.17412
3. Reddy UM, Abuhamad AZ, Levine D, Saade GR. Fetal Imaging: Executive Summary of a Joint Eunice Kennedy Shriver National Institute of Child Health and Human Development, Society for Maternal-Fetal Medicine, American Institute of Ultrasound in Medicine, American College of Obstetricians and Gynecologists, American College of Radiology, Society for Pediatric Radiology, and Society of Radiologists in Ultrasound Fetal Imaging Workshop. *Obstetrics & Gynecology*. 2014;123(5):1070-1082. doi:10.1097/aog.0000000000000245
4. American College of Radiology (ACR) and the Society for Pediatric Radiology (SPR). Practice Parameters by Modality | American College of Radiology: Practice Parameter for the Safe And Optimal Performance of Fetal Magnetic Resonance Imaging (MRI). American College of Radiology | American College of Radiology. <https://www.acr.org/-/media/ACR/Files/Practice-Parameters/MR-Fetal.pdf>. Published 2015. (Resolution 11)
5. American College of Obstetricians and Gynecologists Committee Opinion No. 723. Guidelines for diagnostic imaging during pregnancy and lactation. *Obstetrics & Gynecology*. 2017;130(4). Reaffirmed 2021. doi:10.1097/aog.00000000000002355
6. Lloyd DFA, Pushparajah K, et. al. Three-dimensional visualisation of the fetal heart using prenatal MRI with motion-corrected slice-volume registration: a prospective, single-centre cohort study. *Lancet*. 2019 Apr 20;393(10181):1619-1627. doi: 10.1016/S0140-6736(18)32490-5

Abnormal Fetal Position/ Presentation and Pelvimetry (OB-14)

Abnormal Fetal Position or Presentation (OB-14.1)

OB.FP.0014.1.A

v1.0.2024

- To confirm suspected abnormal fetal position or presentation (transverse or breech presentation) at ≥ 36 weeks gestation, report one of the following:
 - CPT[®] 76805 (plus CPT[®] 76810 for each additional fetus) when complete anatomy scan has not yet been performed in the pregnancy **or**
 - CPT[®] 76815 for limited ultrasound to check fetal position **or**
 - CPT[®] 76816 if version is being considered and/or for delivery planning

Background and Supporting Information

- Fetal presentation should be assessed by abdominal palpation (Leopold's) at 36 weeks or later, when presentation is likely to influence the plans for the birth. Routine assessment of presentation by abdominal palpation before 36 weeks is not always accurate. Suspected fetal malpresentation should be confirmed by an ultrasound assessment. An ultrasound can be performed at ≥ 36 weeks gestation to determine fetal position to allow for external cephalic version. Ultrasound to determine fetal position is not necessary prior to 36 weeks gestation unless delivery is imminent.
- CPT[®] 76815 should never be reported with complete studies CPT[®] 76801/CPT[®] 76802, CPT[®] 76805/CPT[®] 76810 or CPT[®] 76811/CPT[®] 76812 or with CPT[®] 76816 or BPP (CPT[®] 76818 and CPT[®] 76819).

Pelvimetry (OB-14.2)

OB.FP.0014.2.A

v1.0.2024

- Pelvimetry (CT or MRI Pelvimetry CPT® 72192 or CPT® 72195) lacks sufficient evidence to be clinically useful. Current recommendations are that further randomized control studies be performed before it is adapted into routine clinical practice.^{3,4}

References (OB-14)

v1.0.2024

1. ACOG Practice Bulletin No. 221: External Cephalic Version. *Obstetrics & Gynecology*. 2020;135(5). Reaffirmed 2023. doi:10.1097/aog.0000000000003837
2. Safe Prevention of the Primary Cesarean Delivery. Obstetric Care Consensus No. 1. *Obstetrics & Gynecology*. 2014;123(3):693-711. Reaffirmed 2018. doi:10.1097/01.aog.0000444441.04111.1d
3. Pattinson RC, Cuthbert A, Vannevel V. Pelvimetry for fetal cephalic presentations at or near term for deciding on mode of delivery. *Cochrane Database of Systematic Reviews*. Published online March 30, 2017. doi:10.1002/14651858.cd000161.pub2
4. Salk I, Cetin A, Salk S, Cetin M. Pelvimetry by Three-Dimensional Computed Tomography in Non-Pregnant Multiparous Women Who Delivered Vaginally. *Polish Journal of Radiology*. 2016;81:219-227. doi:10.12659/pjr.896380

Adnexal Mass/Uterine Fibroids and Uterine Anomalies (OB-15)

Adnexal Mass (OB-15.1)

OB.AM.0015.1.A

v1.0.2024

Adnexal Mass

- For a known or suspected adnexal/pelvic mass, perform:
 - Complete first trimester ultrasound CPT® 76801 [plus CPT® 76802 for each additional fetus] if <14 weeks and a complete ultrasound has not yet been performed, **and/or** CPT® 76817 for a transvaginal ultrasound
 - CPT® 76801 is preferred for dating, but if this is unable to be completed then CPT® 76815 and/or CPT® 76817 for a transvaginal ultrasound is indicated
 - CPT® 76805 [plus CPT® 76810 if more than one fetus] if a complete fetal anatomic scan has not yet been performed and ≥14 weeks, **or**
 - CPT® 76816 if a complete anatomy scan was done previously and/or CPT® 76817 if poor visualization of the adnexal mass.
- Following the initial ultrasound, follow up can be done once in each trimester
 - CPT® 76805 [plus CPT® 76810 for each additional fetus] if a complete fetal anatomic scan has not yet been performed, **or**
 - CPT® 76815 or CPT® 76816 if a complete ultrasound was previously performed.
 - CPT® 76817 if poor visualization of the adnexal mass
- MRI Pelvis (CPT® 72195) without contrast can be done for indeterminate findings on ultrasound; for surgical planning and/or for suspected malignancy.
- See **Adnexal Mass/Ovarian Cysts (PV-5)** in the Pelvis Imaging Guidelines

Background and Supporting Information

- The majority of adnexal masses in pregnancy are benign, the most common diagnoses are mature teratomas and corpus luteum or paraovarian cysts. Malignancy is reported in only 1.2-6.8% of pregnant patients with persistent mass.
- Levels of CA-125 are elevated in pregnancy, a low-level elevation in pregnancy is not typically associated with malignancy.
- ACOG recommendations for imaging during pregnancy and lactation:
 - Ultrasonography and magnetic resonance imaging (MRI) are not associated with risk and are the imaging techniques of choice for the pregnant patient, but they should be used prudently and only when use is expected to answer a relevant clinical question or otherwise provide medical benefit to the patient.
 - The use of gadolinium contrast with MRI should be limited; it should be used as a contrast agent in a pregnant female only if it significantly improves diagnostic performance and is expected to improve fetal or maternal outcome.

Uterine Fibroids in Pregnancy (OB-15.2)

OB.AM.0015.2.A

v1.0.2024

- If more than one fibroid, total size of all fibroids should be used, i.e. one fibroid at 2 cm and one 3 cm is total of 5 cm and imaging would be indicated as below:
 - Moderate (>5 cm) and large (>10 cm) fibroid(s):
 - Complete first trimester ultrasound CPT® 76801 [plus CPT® 76802 for each additional fetus] if <14 weeks and a complete ultrasound has not yet been performed, **and/or** CPT® 76817 for a transvaginal ultrasound
 - CPT® 76801 is preferred for dating, but if this is unable to be completed then CPT® 76815 and/or CPT® 76817 for a transvaginal ultrasound is indicated
 - Fetal anatomic scan (CPT® 76805 or CPT® 76811 if other high risk indication. See **High Risk Pregnancy (OB-9)**) if ≥16 weeks.
 - Though fetal anatomy survey (CPT® 76805/CPT® 76811) can be performed as early as 14 weeks gestation, per ACOG, in the absence of other specific indications, it is optimally performed at 18 to 22 weeks of gestation.
 - If the fibroid is in the lower uterine segment or the cervix (cervical fibroid), can perform ultrasound (CPT® 76815) and/or transvaginal ultrasound (CPT® 76817) every 2 weeks between 16 to 24 weeks, and
 - Follow up ultrasound (CPT® 76816) every 3 to 6 weeks, starting at 22 weeks.
 - Submucosal fibroid(s) of any size:
 - Complete first trimester ultrasound CPT® 76801 [plus CPT® 76802 for each additional fetus] if <14 weeks and a complete ultrasound has not yet been performed, **and/or** CPT® 76817 for a transvaginal ultrasound
 - CPT® 76801 is preferred for dating, but if this is unable to be completed then CPT® 76815 and/or CPT® 76817 for a transvaginal ultrasound is indicated
 - Fetal anatomic scan [CPT® 76805 or CPT® 76811 if other high risk indication. See **High Risk Pregnancy (OB-9)**] if ≥16 weeks
 - If placentation is over a submucosal fibroid:
 - Follow up ultrasound (CPT® 76816) every 3 to 6 weeks, starting at 22 weeks

Background and Supporting Information

- Though pregnancy seems to have little or no effect on the overall size of fibroids, Fibroids affect pregnancy and delivery in several ways, with abdominal pain, miscarriage, fetal malpresentation, and difficult delivery being the most frequent complications. These complications relate to preterm labor, placental abruption, fetal growth restriction, and fetal compression syndromes. The risk of preterm labor appears to correlate with the size of the fibroid (over 600 cm³) and/or the presence

of multiple fibroids. Placental abruption has been reported to occur frequently in pregnancies complicated by fibroids, especially with placentation over a fibroid. Fibroid volumes $>200 \text{ cm}^3$ are more commonly associated with fetal growth restriction. Fetal compression syndrome is a direct result of large fibroids and is not commonly found with small fibroids. Finally, malposition or obstructed labor may be associated with fibroids of the lower uterine segment.

Uterine Anomalies in Pregnancy (OB-15.3)

OB.AM.0015.3.A

v1.0.2024

- For uterine septum, uterine didelphys, unicornuate uterus, bicornuate uterus:
 - Complete first trimester ultrasound CPT® 76801 [plus CPT® 76802 for each additional fetus] if <14 weeks and a complete ultrasound has not yet been performed, **and/or** CPT® 76817 for a transvaginal ultrasound
 - CPT® 76801 is preferred for dating, but if this is unable to be completed then CPT® 76815 and/or CPT® 76817 for a transvaginal ultrasound is indicated
 - CPT® 76805 or CPT® 76811 and/or CPT® 76817 at ≥16 weeks
 - Though fetal anatomy survey (CPT® 76805/CPT® 76811) can be performed as early as 14 weeks gestation, per ACOG, in the absence of other specific indications, it is optimally performed at 18 to 22 weeks of gestation.
 - CPT® 76817 and/or CPT® 76815 every 2 weeks at 16 to 24 weeks (See **Cervical Insufficiency (OB-18.1)**)
 - CPT® 76816 every 3 to 6 weeks starting at ≥22 weeks
 - Starting at 32 weeks, weekly BPP (CPT® 76818 or CPT® 76819) or modified BPP (CPT® 76815)

Background and Supporting Information

- CPT® 76815 should never be reported with complete studies CPT® 76801/CPT® 76802, CPT® 76805/CPT® 76810 or CPT® 76811/CPT® 76812 or with CPT® 76816 or BPP (CPT® 76818 and CPT® 76819).
- Though fetal anatomy survey (CPT® 76805/CPT® 76811) can be performed as early as 14 weeks gestation, per ACOG, in the absence of other specific indications, it is optimally performed at 18 to 22 weeks of gestation.
- In circumstances where the individual is deemed to have an increased risk for a fetal abnormality and does not have access to a provider who can perform a detailed fetal anatomic ultrasound examination (CPT® 76811) due to geographic or other constraints, a standard (after first trimester) fetal ultrasound examination (CPT® 76805) can be authorized instead.
- CPT® 76811 and CPT® 76812 should only be used once per pregnancy unless the mother changes to a new medical caregiver at a new office and there is a new medical indication and/or change in condition.

References (OB-15)

v1.0.2024

1. ACOG Practice Bulletin No. 174: Evaluation and Management of Adnexal Masses. *Obstet Gynecol.* 2016;128(5):e210-e226. Reaffirmed 2021. doi:10.1097/AOG.0000000000001768
2. Stout M, Odibo A, Graseck A, et al. Leiomyomas at Routine Second-trimester Ultrasound Examination and Adverse Obstetric Outcomes. *Obstetric Anesthesia Digest.* 2012;32(1):21-22. doi:10.1097/01.aoa.0000410780.41686.41
3. Lee HJ, Norwitz ER, Shaw J. Contemporary management of fibroids in pregnancy. *Reviews in obstetrics & gynecology.* <https://www.ncbi.nlm.nih.gov/pmc/articles/PMC2876319/>. Published 2010
4. Shavell VI, Thakur M, Sawant A, et al. Adverse obstetric outcomes associated with sonographically identified large uterine fibroids. *Fertility and Sterility.* 2012;97(1):107-110. doi:10.1016/j.fertnstert.2011.10.009
5. Kase BA, Blackwell SC. SMFM consult: Fibroids in pregnancy: Meaning and Management. *Contemporary OBGYN.* <http://www.contemporaryobgyn.net/modern-medicine-feature-articles/smfm-consult-fibroids-pregnancy-meaning-and-management>. Published December 5, 2014
6. Sei K, Masui K, Sasa H, Furuya K. Size of uterine leiomyoma is a predictor for massive haemorrhage during caesarean delivery. *European Journal of Obstetrics & Gynecology and Reproductive Biology.* 2018;223:60-63. doi:10.1016/j.ejogrb.2018.02.014
7. Penzias A, Bendikson K, Butts S, et al. Removal of myomas in asymptomatic patients to improve fertility and/or reduce miscarriage rate: a guideline. *Fertility and Sterility.* 2017;108(3):416-425. doi:10.1016/j.fertnstert.2017.06.034
8. ACOG Practice Bulletin No. 142: Cerclage for the Management of Cervical Insufficiency. *Obstet Gynecol.* 2014;123(2, PART 1):372-379. Reaffirmed 2020. doi:10.1097/01.aog.0000443276.68274.cc
9. Hua M, Odibo AO, Longman RE, Macones GA, Roehl KA, Cahill AG. Congenital uterine anomalies and adverse pregnancy outcomes. *American Journal of Obstetrics and Gynecology.* 2011;205(6). doi:10.1016/j.ajog.2011.07.022
10. Pfeifer S, Butts S, Dumesic D, et al. Uterine septum: a guideline. *Fertility and Sterility.* 2016;106(3):530-540. doi:10.1016/j.fertnstert.2016.05.014

Alloimmunization/Rh Isoimmunization/Other Causes of Fetal Anemia/ Parvo/Hydrops (OB-16)

Alloimmunization/Rh Isoimmunization (OB-16.1)

OB.AR.0016.1.A

v1.0.2024

Imaging for Alloimmunization/Rh Isoimmunization for any of the following indications:

- When any one of the following maternal antibody titers are $\geq 1:8$ (critical titer):
 - Rhesus antibodies (Cc/Dd/Ee)
 - Anti-Duffy (anti-fya) antibody
 - Anti-Kidd antibody
- If maternal antibody titers are $\geq 1:8$ for other atypical antigens that may be associated with hemolytic disease of the fetus and newborn, e.g. p antigen, MNS series, MSSsMT, Diego, Public antigens, Private antigens.
- Anti-Kell antibody (any antibody titer warrants additional evaluation)
- If evidence of fetal hydrops on previous imaging
- Prior pregnancy associated with HDFN (hemolytic disease of the fetus and newborn)

The following imaging is indicated:

- Complete first trimester ultrasound CPT[®] 76801 [plus CPT[®] 76802 for each additional fetus] if <14 weeks and a complete ultrasound has not yet been performed, **and/or** CPT[®] 76817 for a transvaginal ultrasound
 - CPT[®] 76801 is preferred for dating, but if this is unable to be completed then CPT[®] 76815 and/or CPT[®] 76817 for a transvaginal ultrasound is indicated
- Detailed Fetal Anatomic Scan (CPT[®] 76811) ≥ 16 weeks
 - Though fetal anatomy survey (CPT[®] 76805/CPT[®] 76811) can be performed as early as 14 weeks gestation, per ACOG, in the absence of other specific indications, it is optimally performed at 18 to 22 weeks of gestation.
- CPT[®] 76816 every 2 to 4 weeks to assess fetal growth starting after fetal anatomic scan (CPT[®] 76811)
- Fetal middle cerebral artery (MCA) Doppler (CPT[®] 76821) and CPT[®] 76815 every 1 to 2 weeks starting at 16 weeks
- BPP (CPT[®] 76818 or CPT[®] 76819) or modified BPP (CPT[®] 76815) weekly, starting at 32 weeks or sooner if suspected worsening fetal condition (≥ 26 weeks), e.g. abnormally trending MCA dopplers, suspected hydrops, or polyhydramnios.
- More frequent imaging (MCA Doppler and/or BPP) can be performed if suspected worsening fetal condition (up to 2x weekly), e.g. abnormally trending MCA dopplers, suspected hydrops, or polyhydramnios.

Background and Supporting Information

- Fetal anemia and hydrops may be a result of immune conditions, such as red-cell or Kell alloimmunization, non-immune hydrops caused by parvovirus B19 infection or any other known acquired or congenital causes of fetal anemia.
- Rhesus isoimmunization/alloimmunization is the process through which fetal Rh+ red blood cells enter the circulation of an Rh negative mother causing her to produce antibodies which can cross the placenta and destroy the red blood cells of the current Rh+ fetus and/or in subsequent Rh+ pregnancies.
- Atypical antigens not listed above, may be associated with hemolytic disease of the fetus and newborn and may require fetal assessment as in Alloimmunization/Rh Isoimmunization (OB-16.1) if maternal antibody titers are $\geq 1:8$. Atypical antigens include: MNSs series (M, N, S, s, U, Mi), MSSs-Mta, Diego (Di^a, Di^b), P- PPTj, Public antigen (Yt, En, Co2). Private antigens (Biles, Good, Heibel, Radin, Wright^a, and Z^d). PP1Pk, Far, Good, Lan, LW.
- Peak systolic velocity (PSV) of the fetal middle cerebral artery can be used as a substitute for amniocentesis to evaluate a fetus at risk for anemia due to Rhesus isoimmunization/alloimmunization. Measurements can be initiated as early as 16 weeks of gestation if there is a past history of early severe fetal anemia or very high titers. Because MCA-PSV increases across gestation, results are adjusted for gestational age.
- In circumstances where the individual is deemed to have an increased risk for a fetal abnormality and does not have access to a provider who can perform a detailed fetal anatomic ultrasound examination (CPT[®] 76811) due to geographic or other constraints, a standard (after first trimester) fetal ultrasound examination (CPT[®] 76805) can be authorized instead.
- CPT[®] 76811 and CPT[®] 76812 should only be used once per pregnancy unless the mother changes to a new medical caregiver at a new office **and** there is a new medical indication and/or change in condition.

Exposure to Parvovirus B-19 (OB-16.2)

OB.AR.0016.2.A

v1.0.2024

- Parvovirus B-19 Exposure (Fifth Disease):
 - Complete first trimester ultrasound CPT® 76801 [plus CPT® 76802 for each additional fetus] if <14 weeks and a complete ultrasound has not yet been performed, **and/or** CPT® 76817 for a transvaginal ultrasound
 - CPT® 76801 is preferred for dating, but if this is unable to be completed then CPT® 76815 and/or CPT® 76817 for a transvaginal ultrasound is indicated
 - CPT® 76811 if not yet performed and ≥16 weeks
 - Though fetal anatomy survey (CPT® 76805/CPT® 76811) can be performed as early as 14 weeks gestation, per ACOG, in the absence of other specific indications, it is optimally performed at 18 to 22 weeks of gestation.
 - CPT® 76816 if >2 weeks since performance of the fetal anatomic scan (CPT® 76811)
- Confirmed Parvovirus B-19 Infection (+IgM):
 - Ultrasound (CPT® 76816) every 2 to 4 weeks to assess fetal growth starting after performance of the fetal anatomic scan (CPT® 76811) and
 - Starting at time of confirmed infection weekly limited ultrasound (CPT® 76815) if >22 weeks or weekly BPP (CPT® 76818 or CPT® 76819) if ≥26 weeks gestation and
 - Fetal middle cerebral artery (MCA) Doppler (CPT® 76821) every 1 to 2 weeks, starting at time of confirmed infection (if ≥16 weeks)
 - Continue above imaging for 8 to 12 weeks after initial date of exposure

Twin Anemia Polycythemia Sequence (OB-16.3)

OB.AR.0016.3.A

v1.0.2024

- See **Known Monochorionic-Diamniotic or Monochorionic-Monoamniotic Multiple Gestations (OB-11.3)**

Other Fetal Hydrops/Nonimmune Hydrops (OB-16.4)

OB.AR.0016.4.A

v1.0.2024

- Suspected or known hydrops from any cause should be imaged according to **Alloimmunization/Rh Isoimmunization (OB-16.1)**

Other Causes of Fetal Anemia (OB-16.5)

OB.AR.0016.5.A

v1.0.2024

- MCA Doppler (CPT® 76821) assessment can be performed if there is suspected fetal anemia (e.g. fetus with heart failure, hydrops, alloimmunization), in a fetus at high risk for fetal anemia due to other pregnancy complications, e.g. chorioangioma, umbilical vein varix, or finding of sustained fetal tachyarrhythmia or bradyarrhythmia - See **Indications for Fetal Conditions (OB-12.2)**, **Alloimmunization/Rh Isoimmunization (OB-16.1)**, and **Placental and Cord Abnormalities (OB-21)**

Background and Supporting Information

- In circumstances where the individual is deemed to have an increased risk for a fetal abnormality and does not have access to a provider who can perform a fetal anatomic ultrasound examination (CPT® 76811) due to geographic or other constraints, a standard (after first trimester) fetal anatomic ultrasound examination (CPT® 76805) can be authorized instead.
- CPT® 76811 and CPT® 76812 should only be used once per pregnancy unless the mother changes to a new medical caregiver at a new office and there is a new medical indication and/or change in condition.
- Typically all components of the BPP (CPT® 76818 and CPT® 76819), such as breathing, are not present until ≥ 26 weeks gestation. However, a modified BPP (CPT® 76815) can be utilized sooner in certain high risk cases but should not be done prior to 22 weeks. .

References (OB-16)

v1.0.2024

1. ACOG Practice Bulletin No. 181. Prevention of Rh D alloimmunization. *Obstetrics & Gynecology* 2017(2); 130: 57-70. Reaffirmed 2021. doi:10.1097/aog.0000000000002232
2. ACOG Practice Bulletin No. 192. Management of Alloimmunization During Pregnancy. *Obstetrics & Gynecology*. 2018;131(3):e82-e90. Reaffirmed 2019. doi:10.1097/aog.0000000000002528
3. Mari G, Deter RL, Carpenter RL, et al. Noninvasive Diagnosis by Doppler Ultrasonography of Fetal Anemia Due to Maternal Red-Cell Alloimmunization. *New England Journal of Medicine*. 2000;342(1):9-14. doi:10.1056/nejm200001063420102
4. Mari G, Norton ME, Stone J, et al. Society for Maternal-Fetal Medicine (SMFM) Clinical Guideline #8: The fetus at risk for anemia—diagnosis and management. *American Journal of Obstetrics and Gynecology*. 2015;212(6):697-710. doi:10.1016/j.ajog.2015.01.059
5. Crane J, Mundle W, Boucoiran I, et al. Parvovirus B19 Infection in Pregnancy. *Journal of Obstetrics and Gynaecology Canada*. 2014;36(12):1107-1116. doi:10.1016/s1701-2163(15)30390-x
6. ACOG. Practice Bulletin No. 151: Cytomegalovirus, parvovirus B19, varicella zoster, and toxoplasmosis in pregnancy. *Obstetrics & Gynecology*. 2015;125(6):1510-1525. Reaffirmed 2020. doi:10.1097/01.aog.0000466430.19823.53
7. Norton ME, Chauhan SP, Dashe JS. Society for Maternal-Fetal Medicine (SMFM) Clinical Guideline #7: nonimmune hydrops fetalis. *American Journal of Obstetrics and Gynecology*. 2015;212(2):127-139. doi:10.1016/j.ajog.2014.12.018

Amniotic Fluid Abnormalities/ Oligohydramnios/Polyhy dramnios (OB-17)

Amniotic Fluid Abnormalities (OB-17.1)

OB.AF.0017.1.A
v1.0.2024

For suspected polyhydramnios or oligohydramnios:

- For example, unequal size and dates or suspected preterm/prelabor rupture of membranes. See **Unequal Fundal Size and Dates (OB-27)** and/or **Preterm/Prelabor Rupture of Membranes (OB-23)**
 - CPT® 76815 for quick look for AFI check

For **confirmed** diagnosis of **polyhydramnios**: AFI ≥ 24 cm or maximum vertical pocket (MVP) ≥ 8 cm.

- CPT® 76811 (Detailed Fetal Anatomy) at diagnosis, if not previously performed
- CPT® 76816 starting at ≥ 22 weeks
 - Every 3 - 4 weeks for mild polyhydramnios (AFI 24 - 29.9 cm or MVP 8 - 9.9 cm)
 - Every 2 weeks for severe polyhydramnios (AFI ≥ 30 cm or MVP ≥ 10 cm)
- CPT® 76815 weekly for antepartum fetal surveillance starting at ≥ 22 weeks
- BPP (CPT® 76818 or CPT® 76819) or modified BPP (CPT® 76815) for AFI with NST starting at 26 weeks
 - Weekly for mild polyhydramnios
 - Twice weekly for severe polyhydramnios

For **confirmed** diagnosis of **oligohydramnios**: AFI ≤ 5 cm or maximum vertical pocket ≤ 2 cm

- CPT® 76811 if not already performed; or
- CPT® 76816 every 2 to 4 weeks starting at ≥ 22 weeks
- CPT® 76815 weekly for antepartum fetal surveillance from 22 - 26 weeks
- CPT® 76818 or CPT® 76819 or a modified BPP (CPT® 76815), weekly, starting at 26 weeks
- CPT® 76820 weekly starting at time of diagnosis if ≥ 22 weeks

Background and Supporting Information

- Polyhydramnios can be an early presenting finding of fetal hydrops associated with fetal anemia. Middle cerebral artery Doppler is commonly used to diagnose whether this fetal anemia is present or not. See **Alloimmunization/Rh Isoimmunization (OB-16.1)**
- Polyhydramnios may also present as a finding of cardiac dysfunction, fetal arrhythmias or cardiac malformation. Fetal echocardiography may be indicated if

there are abnormal findings on an anatomy scan. See **Fetal Echocardiography (ECHO) (OB-12)**

- In circumstances where the individual is deemed to have an increased risk for a fetal abnormality and does not have access to a provider who can perform a fetal anatomic ultrasound examination (CPT® 76811) due to geographic or other constraints, a standard (after first trimester) fetal anatomic ultrasound examination (CPT® 76805) can be authorized instead.
- CPT® 76811 and CPT® 76812 should only be used once per pregnancy unless the mother changes to a new medical caregiver at a new office and there is a new medical indication and/or change in condition.
- Typically all components of the BPP (CPT® 76818 and CPT® 76819), such as breathing, are not present until ≥ 26 weeks gestation. However, a modified BPP (CPT® 76815) can be utilized sooner in certain high risk cases but should not be done prior to viability (22 weeks).
- CPT® 76815 should never be reported with complete studies CPT® 76801/CPT® 76802, CPT® 76805/CPT® 76810 or CPT® 76811/CPT® 76812 or with CPT® 76816 or BPP (CPT® 76818 and CPT® 76819).
- Though fetal anatomy survey (CPT® 76805/CPT® 76811) can be performed as early as 14 weeks gestation, per ACOG, in the absence of other specific indications, it is optimally performed at 18 to 22 weeks of gestation.

References (OB-17)

v1.0.2024

1. Practice Bulletin No. 175: Ultrasound in Pregnancy. *Obstetrics & Gynecology*. 2016;128(6):e241-e256. Reaffirmed 2022. doi:10.1097/AOG.0000000000001815
2. ACOG Practice Bulletin No. 229: Antepartum Fetal Surveillance. *Obstetrics & Gynecology*. 2021;137(6):e177-e197. doi:10.1097/aog.0000000000004407
3. ACOG Committee Opinion No. 828. Indications for outpatient antenatal fetal surveillance. American College of Obstetricians and Gynecologists. *Obstetrics & Gynecology*. 2021;137:e177–e197. doi:10.1097/aog.0000000000004407
4. AIUM Practice Parameter for the Performance of Detailed Second- and Third-Trimester Diagnostic Obstetric Ultrasound Examinations. *Journal of Ultrasound in Medicine*. 2019;38(12):3093-3100. doi:10.1002/jum.15163
5. Dashe JS, Pressman EK, Hibbard JU. SMFM Consult Series #46: Evaluation and management of polyhydramnios. *American Journal of Obstetrics and Gynecology*. 2018;219(4). doi:10.1016/j.ajog.2018.07.016
6. Guidelines for Perinatal Care, 8th Edition; By AAP Committee on Fetus and Newborn and ACOG Committee on Obstetric Practice; Edited by Sarah J. Kilpatrick, Lu-Ann Papile and George A. Macones; Published in 2017
7. Martins JG, Biggio JR, Abuhamad A. Society for Maternal-Fetal Medicine (SMFM) Consult Series #52: Diagnosis and Management of Fetal Growth Restriction. *American Journal of Obstetrics and Gynecology*. 2020. doi:10.1016/j.ajog.2020.05.010

Cervical Insufficiency/Current Preterm Labor (OB-18)

Cervical Insufficiency (OB-18.1)

OB.CI.0018.1.A

v1.0.2024

- For any of the following:
 - History of cervical insufficiency (defined as one or more 2nd trimester loss (14 to 24 weeks gestation) related to painless cervical dilation.)
 - History of cerclage in prior pregnancy
 - History of prior precipitous delivery
 - Surgical trauma to cervix, e.g.
 - Over dilation of cervix during a termination of pregnancy
 - Cervical obstetrical laceration from a previous delivery
 - History of extensive or multiple prior cold-knife conization or Loop Electrosurgical Excision Procedures (LEEP)
 - Complete first trimester ultrasound CPT[®] 76801 [plus CPT[®] 76802 for each additional fetus] if <14 weeks and a complete ultrasound has not yet been performed, **and/or** CPT[®] 76817 for a transvaginal ultrasound
 - CPT[®] 76801 is preferred for dating, but if this is unable to be completed then CPT[®] 76815 and/or CPT[®] 76817 for a transvaginal ultrasound is indicated
 - CPT[®] 76805 or CPT[®] 76811 if other high risk factors [plus CPT[®] 76810/CPT[®] 76812 for each additional fetus] **and/or** CPT[®] 76817 at ≥16 weeks if a complete fetal anatomic scan has not yet been performed during this pregnancy.
 - Though fetal anatomy survey (CPT[®] 76805/CPT[®] 76811) can be performed as early as 14 weeks gestation, per ACOG, in the absence of other specific indications, it is optimally performed at 18 to 22 weeks of gestation.
 - CPT[®] 76815 **and/or** CPT[®] 76817 every 1 to 4 weeks from 16 0/7 to 24 0/7 weeks
 - CPT[®] 76816 can be performed every 3 to 6 weeks starting after the fetal anatomic scan at 16 weeks
 - Note: Lower uterine segment or cervical fibroid may also require CL screening with (CPT[®] 76815) and/or transvaginal ultrasound (CPT[®] 76817) every 2 weeks between 16 to 24 weeks (See **Uterine Fibroids in Pregnancy (OB-15.2)**)
-
- If funneling or short cervix ≤25 mm (2.5 cm) is found on a transvaginal ultrasound
 - CPT[®] 76816 can be performed after a complete ultrasound every 3 to 4 weeks **and/or**
 - CPT[®] 76817 and/or CPT[®] 76815 every 1 to 2 weeks until 32 weeks
 - Note: CPT[®] 76815 should not be done on same date of service as CPT[®] 76816
 - Starting at 32 weeks, BPP (CPT[®] 76818 or CPT[®] 76819) or a modified BPP (CPT[®] 76815) can be performed once weekly.

Cerclage in Place in Current Pregnancy (OB-18.2)

OB.CI.0018.2.A

v1.0.2024

- Complete first trimester ultrasound CPT® 76801 [plus CPT® 76802 for each additional fetus] if <14 weeks and a complete ultrasound has not yet been performed, **and/or** CPT® 76817 for a transvaginal ultrasound
 - CPT® 76801 is preferred for dating, but if this is unable to be completed then CPT® 76815 and/or CPT® 76817 for a transvaginal ultrasound is indicated
- CPT® 76805 or CPT® 76811 if other high risk factors [plus CPT® 76810/CPT® 76812 for each additional fetus] and/or CPT® 76817 once if a complete detailed fetal anatomic scan has not been performed
- CPT® 76816 can be performed every 3 to 6 weeks starting after the fetal anatomic scan at 16 weeks.
- If a **prophylactic** (history-indicated) cerclage is placed in the current pregnancy (usually done early in the second trimester due to a prior 2nd trimester loss after painless cervical dilation at ≤24 weeks gestation)
 - CPT® 76815 **and/or** CPT® 76817 can be performed once between 16 to 24 weeks to determine if cervical shortening is present
 - If cervical shortening or funneling is noted See **Cervical Insufficiency (OB-18.1)**.
 - Further CL surveillance CPT® 76815 **and/or** CPT® 76817 every 2 weeks is not indicated.
- If a **rescue** cerclage (exam indicated) was placed due to cervical shortening or dilation found by ultrasound or physical exam in the current pregnancy
 - Transvaginal (CPT® 76817 and/or CPT® 76815) every 2 weeks, starting at ≥16 weeks until 32 weeks.
- If funneling or further shortening of the cervix is found See **Cervical Insufficiency (OB 18.1)**

Current Preterm Labor (OB-18.3)

OB.CI.0018.3.A

v1.0.2024

- Preterm labor in current pregnancy (contractions **PLUS** cervical change at <37 weeks gestation), can perform once when symptomatic
 - CPT® 76805 or CPT® 76811 if other high risk factors [plus CPT® 76810/CPT® 76812 for each additional fetus] if a complete fetal anatomic scan has not yet been performed during this pregnancy; **or**
 - CPT® 76815 **or** CPT® 76816, if a complete fetal anatomic scan was performed previously, (CPT® 76816 if more than 2 weeks since last growth), **and/or** CPT® 76817
- Biophysical profile (BPP) (CPT® 76818 **or** CPT® 76819) **or** modified BPP (CPT® 76815), once when symptomatic if ≥26 weeks.
- For history of pre-term labor, See **History of Spontaneous Pre-Term Delivery/History of PPRM (OB-9.9)**

Background and Supporting Information

- In circumstances where the individual is deemed to have an increased risk for a fetal abnormality and does not have access to a provider who can perform a fetal anatomic ultrasound examination (CPT® 76811) due to geographic or other constraints, a standard (after first trimester) fetal anatomic ultrasound examination (CPT® 76805) can be authorized instead.
- CPT® 76811 and CPT® 76812 should only be used once per pregnancy unless the mother changes to a new medical caregiver at a new office and there is a new medical indication and/or change in condition.
- Typically all components of the BPP (CPT® 76818 and CPT® 76819), such as breathing, are not present until ≥26 weeks gestation. However, a modified BPP (CPT® 76815) can be utilized sooner in certain high risk cases but should not be done prior to 22 weeks.
- CPT® 76815 should never be reported with complete studies CPT® 76801/CPT® 76802, CPT® 76805/CPT® 76810 or CPT® 76811/CPT® 76812 or with CPT® 76816 or BPP (CPT® 76818 and CPT® 76819).
- Though fetal anatomy survey (CPT® 76805/CPT® 76811) can be performed as early as 14 weeks gestation, per ACOG, in the absence of other specific indications, it is optimally performed at 18 to 22 weeks of gestation.

References (OB-18)

v1.0.2024

1. ACOG Practice Bulletin No.142: Cerclage for the Management of Cervical Insufficiency. *Obstetrics & Gynecology*. 2014;123(2, PART 1):372-379.Reaffirmed 2020. doi:10.1097/01.aog.0000443276.68274.cc
2. ACOG Practice Bulletin No. 234: Prediction and Prevention of Spontaneous Preterm Birth. *Obstetrics & Gynecology*. 2021;138:e65-90
3. ACOG. Practice Bulletin No. 171: Management of Preterm Labor. *Obstetrics & Gynecology*. 2016;128(4).Reaffirmed 2022. doi:10.1097/aog.0000000000001711
4. Practice Bulletin No. 175: Ultrasound in Pregnancy. *Obstetrics & Gynecology*. 2016;128(6):e241-e256. Reaffirmed 2022. doi:10.1097/AOG.0000000000001815
5. Society for Maternal-Fetal Medicine. Progesterone and preterm birth prevention: translating clinical trials data into clinical practice. *American Journal of Obstetrics and Gynecology*. 2012;206(5):376-386. doi:10.1016/j.ajog.2012.03.010
6. Esplin MS, Elovitz MA, Iams JD, et al. Predictive Accuracy of Serial Transvaginal Cervical Lengths and Quantitative Vaginal Fetal Fibronectin Levels for Spontaneous Preterm Birth Among Nulliparous Women. *JAMA*. 2017;317(10):1047. doi:10.1001/jama.2017.1373
7. Mcintosh J, Feltovich H, Berghella V, Manuck T. The role of routine cervical length screening in selected high- and low-risk women for preterm birth prevention. Society for Maternal-Fetal Medicine (SMFM) Consult Series #40. *American Journal of Obstetrics and Gynecology*. 2016;215(3). doi:10.1016/j.ajog.2016.04.027
8. Meis PJ, Klebanoff M, Thom E, Dombrowski MP, et.al.; National Institute of Child Health and Human Development Maternal-Fetal Medicine Units Network. Prevention of recurrent preterm delivery by 17 alpha-hydroxyprogesterone caproate. *N Engl J Med*. 2003 Jun 12;348(24):2379-85. doi: 10.1056/NEJMoa035140
9. Blackwell SC, Gyamfi-Bannerman C, Biggio JR Jr, et al. 17-OHPC to Prevent Recurrent Preterm Birth in Singleton Gestations (PROLONG Study): A Multicenter, International, Randomized Double-Blind Trial. *Am J Perinatol*. 2020;37(2):127–136. doi:10.1055/s-0039-3400227
10. EPPPIC Group. Evaluating Progestogens for Preventing Preterm birth International Collaborative (EPPPIC): meta-analysis of individual participant data from randomised controlled trials. *Lancet*. 2021 Mar 27;397(10280):1183-1194
11. SMFM, 2021. SMFM Statement: Response to EPPPIC and considerations of the use of progestogens for the prevention of preterm birth
12. Society for Maternal-Fetal Medicine (SMFM). Electronic address: pubs@smfm.org; SMFM Publications Committee. Society for Maternal-Fetal Medicine Statement: Response to the Food and Drug Administration's withdrawal of 17-alpha hydroxyprogesterone caproate. *Am J Obstet Gynecol*. 2023 Jul;229(1):B2-B6. doi: 10.1016/j.ajog.2023.04.012

No Fetal Heart Tones/Decreased Fetal Movement (OB-19)

No Fetal Heart Tones (OB-19.1)

OB.FT.0019.1.A

v1.0.2024

- Prior to considering ultrasound, fetal heart tones (FHT) should be assessed with a hand-held doppler device.

First Trimester

- If ≥ 12 weeks gestation and unable to obtain FHT using a hand-held doppler, **or**
- If < 12 weeks gestation, in the setting of absent fetal heart tones, only if accompanied by other maternal signs or symptoms (such as cramping, vaginal bleeding, etc.) **or**
- If < 12 weeks and FHT had previously been heard using a fetal hand-held doppler, but now are unable to be heard by this method, regardless of symptoms
- Report **one** of the following:
 - Complete first trimester anatomy ultrasound CPT[®] 76801 (plus CPT[®] 76802 for each additional fetus) and/or CPT[®] 76817 if a complete ultrasound has not yet been performed; **or**
 - CPT[®] 76815 and/or CPT[®] 76817

Second and Third Trimester

Report **one** of the following:

- CPT[®] 76815 for limited ultrasound **or**
- CPT[®] 76805 (plus CPT[®] 76810 for each additional fetus) if ≥ 14 weeks, when complete fetal anatomic scan CPT[®] 76805 has not yet been performed **or**
- CPT[®] 76816 if ≥ 14 weeks and an anatomy ultrasound (CPT[®] 76801 or CPT[®] 76805/CPT[®] 76811) was performed previously

Decreased Fetal Movement (OB-19.2)

OB.FT.0019.2.A

v1.0.2024

- One of the following can be performed at the time of the complaint of decreased fetal movement:
 - Limited ultrasound or modified BPP (CPT® 76815) or
 - If ≥ 26 weeks BPP (CPT® 76818 or CPT® 76819) or a modified BPP (CPT® 76815) can be performed. See **Biophysical Profile (BPP) (OB-28.8)**
 - CPT® 76816 for delivery planning, e.g. if BPP/Modified BPP is abnormal.
 - Subsequent/repeat ultrasound is not usually necessary unless there are new indications or if BPP is abnormal.

Background and Supporting Information

- CPT® 76815 should never be reported with complete studies CPT® 76801/CPT® 76802, CPT® 76805/CPT® 76810 or CPT® 76811/CPT® 76812 or with CPT® 76816 or BPP (CPT® 76818 and CPT® 76819).

References (OB-19)

v1.0.2024

1. ACOG Practice Bulletin No. 229: Antepartum Fetal Surveillance. *Obstetrics & Gynecology*. 2021;137(6):e177-e197. doi:10.1097/aog.0000000000004407
2. ACOG Committee Opinion No. 828. Indications for outpatient antenatal fetal surveillance. *Obstetrics & Gynecology*. 2021;137:e177–e197. doi:10.1097/aog.0000000000004407
3. Practice Bulletin No. 175: Ultrasound in Pregnancy. *Obstetrics & Gynecology* 2016;128(6):e241-e256. Reaffirmed 2022. doi:10.1097/AOG.0000000000001815

Fetal Growth Problems (FGR and Macrosomia) (OB-20)

Fetal Growth Restriction Current Pregnancy (OB-20.1)

OB.FG.0020.1.A

v1.0.2024

- The ACOG definition of Fetal Growth Restriction (FGR): Estimated or actual weight of the fetus $\leq 10^{\text{th}}$ percentile for gestational age, and/or Abdominal Circumference $\leq 10^{\text{th}}$ percentile.

For Suspected FGR:

- If there is a $\geq 3\text{cm}$ difference in fundal height measurement and gestational age, **or**
- FGR is suspected based on reduced fetal growth velocity, defined as a fall in the EFW or AC of 50% or more (e.g. from 70% to 20% ect.).¹²
- Report **one** of the following:
 - CPT[®] 76805/CPT[®] 76811 if otherwise indicated (plus CPT[®] 76810/CPT[®] 76812 for each additional fetus) if anatomy ultrasound has not yet been performed **or**
 - CPT[®] 76816 if anatomy ultrasound (CPT[®] 76805/CPT[®] 76811) previously performed
- For clinical situations that have a higher probability of FGR such as maternal hypertension, maternal diabetes, previous stillbirth, etc. See **High Risk Pregnancy (OB-9)**, or the specific guidelines for these clinical entities for guidance regarding follow-up ultrasounds to assess fetal growth

For Known FGR:

- Detailed Fetal Anatomic Scan (CPT[®] 76811) at diagnosis if not already performed
- Starting at diagnosis, if ≥ 16 weeks gestation, follow up ultrasound (CPT[®] 76816) can be performed every 2 to 4 weeks if complete anatomy ultrasound previously performed
- Starting at 22 weeks, a modified BPP (CPT[®] 76815) can be performed once or twice weekly, **or**
- Starting at 26 weeks, BPP (CPT[®] 76818 or CPT[®] 76819) **or** a modified BPP (CPT[®] 76815) can be performed once or twice weekly, **and**
- Starting at 22 weeks Umbilical artery (UA) Doppler (CPT[®] 76820) can be performed weekly.
- If FGR is diagnosed in the current ultrasound, BPP (CPT[®] 76818 or CPT[®] 76819) can be performed if ≥ 26 weeks, and/or UA Doppler (CPT[®] 76820) if ≥ 22 weeks.

For Known FGR:

- If Severe FGR (EFW \leq 3%, AC \leq 3%), **OR** Abnormal UA Doppler studies (defined as a PI, RI, or S/D ratio greater than the 95th percentile for gestational age **OR** absent or reversed end-diastolic velocity (AEDV or REDV), **OR** confirmed oligohydramnios:
 - BPP (CPT[®] 76818 or CPT[®] 76819 or CPT[®] 76815) and/or umbilical artery (UA) Doppler (CPT[®] 76820) can be performed twice weekly.⁵
- Per SMFM guidelines: Ductus venosus, middle cerebral artery, or uterine artery Doppler use for routine clinical management of early- or late-onset FGR is not recommended

Background and Supporting Information

- An abnormal umbilical artery Doppler is defined as a PI, RI, or S/D ratio greater than the 95th percentile for gestational age or an absent or reversed end-diastolic velocity (AEDV or REDV). Those with REDV are usually hospitalized for closer surveillance and delivery planning.
- Fetuses with early onset FGR are at significant risk for Intrauterine Fetal Demise (IUFD) and the rate of fetal growth prior to 23 weeks and Umbilical Artery (UA) Doppler findings may aid in counseling patients in this peri-viability period (Termination of Pregnancy (TOP) versus attempt at prolonging pregnancy till viability).
- In circumstances where CPT[®] 76811 cannot be performed See **Ultrasound Code Selection (OB-1.3)**
- Typically all components of the BPP (CPT[®] 76818 and CPT[®] 76819), such as breathing, are not present until \geq 26 weeks gestation. However, a modified BPP (CPT[®] 76815) can be utilized sooner in certain high risk cases but should not be done prior to 22 weeks.
- CPT[®] 76815 should never be reported with complete studies CPT[®] 76801/CPT[®] 76802, CPT[®] 76805/CPT[®] 76810 or CPT[®] 76811/CPT[®] 76812 or with CPT[®] 76816 or BPP (CPT[®] 76818 and CPT[®] 76819).
- Though fetal anatomy survey (CPT[®] 76805/CPT[®] 76811) can be performed as early as 14 weeks gestation, per ACOG, in the absence of other specific indications, it is optimally performed at 18 to 22 weeks of gestation.

Macrosomia – Large for Dates Current Pregnancy (OB-20.2)

OB.FG.0020.2.A

v1.0.2024

- The ACOG definition of macrosomia: Estimated fetal weight of greater than 4000 grams (DM) or 4500 grams (non-DM); $\geq 90^{\text{th}}$ percentile for gestational age.
- For history of a macrosomia See **Prior Pregnancy with Macrosomia (OB-9.4.1)**

For Suspected Macrosomia

- At ≥ 22 weeks gestation, if there is a ≥ 3 week difference in fundal height and gestational age, or if the estimated fetal weight is $\geq 90^{\text{th}}$ percentile for gestational age¹¹, report **one** of the following:
 - CPT® 76805 [plus CPT® 76810 for each additional fetus] if a complete fetal anatomic scan has not yet been performed **or**
 - CPT® 76816 if a complete ultrasound was done previously
- See **Unequal Fundal Size and Dates (OB-27.1)**

For Known Macrosomia $\geq 90^{\text{th}}$ percentile

Report:

- CPT® 76816 at ≥ 35 weeks for delivery planning (if more than 2 weeks since last growth).¹¹
- In a low risk pregnancy, ultrasound is generally not indicated to estimate fetal weight before 30 weeks gestation. As such, repeat imaging is generally not necessary unless needed to plan for delivery or if there are other high risk indications.
- Additional imaging recommendations are usually guided by the cause of the fetal macrosomia (obesity, DM, etc.) See appropriate guideline for indication
- Per SMFM guidelines: Ductus venosus, middle cerebral artery, or uterine artery Doppler use for routine clinical management of early- or late-onset FGR is not recommended

References (OB-20)

v1.0.2024

1. ACOG Practice Bulletin No. 227: Fetal Growth Restriction. *Obstetrics & Gynecology*. 2021;137(2):e16-e28 doi: 10.1097/AOG.0000000000004251
2. Martins JG, Biggio, JR, Abuhamad, A. Society for Maternal-Fetal Medicine (SMFM) Consult Series #52: Diagnosis and Management of Fetal Growth Restriction. 2020 doi:10.1016/j.ajog.2015.01.059
3. ACOG Practice Bulletin No. 230: Obesity in Pregnancy, *Obstetrics & Gynecology*. 2021;137(6):e128-e144. doi:10.1097/aog.0000000000004395
4. ACOG Practice Bulletin No. 229: Antepartum Fetal Surveillance. *Obstetrics & Gynecology*. 2021;137(6):e177-e197. doi:10.1097/aog.0000000000004407
5. ACOG Committee Opinion No. 828. Indications for outpatient antenatal fetal surveillance. American College of Obstetricians and Gynecologists. *Obstetrics & Gynecology*. 2021;137(6):e177-e197. doi:10.1097/aog.0000000000004407
6. American Institute of Ultrasound in Medicine. AIUM practice guideline for the performance of detailed second-and-third-trimester diagnostic obstetric ultrasound examinations. *Journal of Ultrasound Medicine*. 2019; 38:3093-3100
7. ACOG Practice Bulletin No. 175: Ultrasound in Pregnancy. *Obstetrics & Gynecology*. 2016;128(6):e241-e256. Reaffirmed 2022. doi:10.1097/AOG.0000000000001815
8. Berkley E, Chauhan SP, Abuhamad A. Doppler assessment of the fetus with intrauterine growth restriction. *American Journal of Obstetrics and Gynecology*. 2012; 206(4):300-308. doi:10.1016/j.ajog.2012.01.022
9. Obstetric Care consensus No. 6: Periviable Birth. American College of Obstetricians and Gynecologists; Society for Maternal-Fetal Medicine. *Obstetrics & Gynecology*. 2017;130(4):e187-e199. Reaffirmed 2019. doi:10.1097/aog.0000000000002352
10. ACOG Practice Bulletin No. 216: Fetal Macrosomia. *Obstetrics & Gynecology*. 2020; 135(1):246-248. Reaffirmed 2023. doi:10.1097/aog.0000000000003607
11. Frick AP, Syngelaki A, Zheng M, Poon LC, Nicolaides KH. Prediction of large-for-gestational-age neonates: screening by maternal factors and biomarkers in the three trimesters of pregnancy. *Ultrasound Obstet Gynecol*. 2016 Mar;47(3):332-9. doi: 10.1002/uog.15780
12. ISUOG Practice Guidelines: diagnosis and management of small-for-gestational-age fetus and fetal growth restriction. *Ultrasound Obstet Gynecol* 2020; 56: 298–312

Placental and Cord Abnormalities (OB-21)

Single Umbilical Artery (Two Vessel Cord) (OB-21.1)

OB.UA.0021.1.A
v1.0.2024

If a single umbilical artery is found on initial imaging:	
<ul style="list-style-type: none"> Detailed anatomic ultrasound at ≥ 16 weeks <ul style="list-style-type: none"> Though fetal anatomy survey (CPT[®] 76805/CPT[®] 76811) can be performed as early as 14 weeks gestation, per ACOG, in the absence of other specific indications, it is optimally performed at 18 to 22 weeks of gestation. 	CPT [®] 76811
<ul style="list-style-type: none"> Fetal echocardiogram (if ≥ 16 weeks) 	CPT [®] 76825 and/or CPT [®] 76827 and/or CPT [®] 93325
<ul style="list-style-type: none"> Follow-up ultrasound to evaluate fetal growth at ≥ 28 weeks and then every 3 to 6 weeks if more than one clinical high-risk factors are documented 	CPT [®] 76816
<ul style="list-style-type: none"> Weekly BPP or modified BPP starting at 36 weeks 	CPT [®] 76818 or CPT [®] 76819 (BPP) or modified BPP CPT [®] 76815

Background and Supporting Information

- In circumstances where the individual is deemed to have an increased risk for a fetal abnormality and does not have access to a provider who can perform a fetal anatomic ultrasound examination (CPT[®] 76811) due to geographic or other constraints, a standard (after first trimester) fetal anatomic ultrasound examination (CPT[®] 76805) can be authorized instead.
- CPT[®] 76811 and CPT[®] 76812 should only be used once per pregnancy unless the mother changes to a new medical caregiver at a new office and there is a new medical indication and/or change in condition.

Persistent Right Umbilical Vein (PRUV) (OB-21.2)

OB.UA.0021.2.A
v1.0.2024

PRUV – is a variant of the usual intra-abdominal umbilical venous connection. It may be associated with other fetal defects.

If a PRUV is found on initial imaging:	
<ul style="list-style-type: none"> Detailed anatomic ultrasound at ≥ 16 weeks <ul style="list-style-type: none"> Though fetal anatomy survey (CPT[®] 76805/CPT[®] 76811) can be performed as early as 14 weeks gestation, per ACOG, in the absence of other specific indications, it is optimally performed at 18 to 22 weeks of gestation. 	CPT [®] 76811
<ul style="list-style-type: none"> Fetal echocardiogram (if ≥ 16 weeks) 	CPT [®] 76825 and/or CPT [®] 76827 and/or CPT [®] 93325
<ul style="list-style-type: none"> Follow-up ultrasound to evaluate fetal growth at ≥ 22 weeks and then every 3 to 6 weeks if more than one clinical high-risk factors are documented 	CPT [®] 76816
<ul style="list-style-type: none"> Weekly BPP or modified BPP starting at 32 weeks 	CPT [®] 76818 or CPT [®] 76819 (BPP) or modified BPP CPT [®] 76815

Placental/Cord Abnormalities (OB-21.3)

OB.UA.0021.3.A
v1.0.2024

Placental/Cord Abnormalities (OB-21.3.1)

Circumvallate Placenta

Placental hemangioma

Succenturiate placenta or accessory lobe

Hypo/Hyper-coiled Umbilical Cord

Marginal Cord Insertion

Umbilical cord cyst

Velamentous Cord Insertion

- Fetal anatomic scan can be performed after 16 weeks (CPT® 76805/CPT® 76811) with or without CPT® 93976 (limited duplex scan of arterial and venous)
 - Though fetal anatomy survey (CPT® 76805/CPT® 76811) can be performed as early as 14 weeks gestation, per ACOG, in the absence of other specific indications, it is optimally performed at 18 to 22 weeks of gestation.
- Ultrasound CPT® 76817 can be performed to evaluate the placenta and/or cord in relation to the cervix
- Ultrasound (CPT® 76816) with or without CPT® 93976 (limited duplex scan) every 3-6 weeks starting at 28 weeks until delivery
- Weekly BPP or modified BPP (CPT® 76818/CPT® 76819 or CPT® 76815) starting at 32 weeks

Background and Supporting Information

- **Hypo/Hyper-coiled umbilical cord** - Several studies have reported an increased frequency of adverse pregnancy outcome, including congenital anomalies, growth restriction, fetal heart rate abnormalities, preterm birth, and intrauterine death in pregnancies with both hypocoiled and hypercoiled umbilical cord.

Other Placental/Cord Abnormalities (OB-21.3.2)

Amniotic Sheet/ Amniotic Band (Uterine Synechiae)

- Fetal anatomic scan can be performed after 16 weeks (CPT® 76805)
 - Though fetal anatomy survey (CPT® 76805/CPT® 76811) can be performed as early as 14 weeks gestation, per ACOG, in the absence of other specific indications, it is optimally performed at 18 to 22 weeks of gestation.

- One follow-up Ultrasound (CPT® 76816) can be performed in the 3rd trimester to ensure that the band is not restricting fetal growth or movement.
- **Amniotic Band Syndrome** is a completely different entity, associated with an increased risk of fetal anomalies and poor outcome. If Amniotic band syndrome is suspected or diagnosed, image as in **High Risk Pregnancy (OB-9)**.

Chorioangioma

Umbilical cord varix

- Detailed fetal anatomic scan can be performed after 16 weeks (CPT® 76811) with or without CPT® 93976 (limited duplex scan).
 - Though fetal anatomy survey (CPT® 76805/CPT® 76811) can be performed as early as 14 weeks gestation, per ACOG, in the absence of other specific indications, it is optimally performed at 18 to 22 weeks of gestation.
- Ultrasound (CPT® 76816) with or without CPT® 93976 (limited duplex scan) every 3-6 weeks starting at the time of diagnosis until delivery
- Weekly BPP (CPT® 76818 or CPT® 76819) or a modified BPP (CPT® 76815) starting at 32 weeks
- Both chorioangioma and UVV can be associated with fetal anemia and/or low output heart failure. As such, MCA Dopplers (CPT® 76821) may be indicated on a case-by-case basis, e.g. If turbulence develops within the UVV
- If suspected or known hydrops, Fetal ECHO (CPT® 76825, CPT® 76827, CPT® 93325) may be indicated. See **Fetal Echocardiography - Indications for Fetal Conditions (OB-12.2)**. If fetal hydrops develops then image as per **Alloimmunization/Rh Isoimmunization (OB-16.1)**

Background and Supporting Information

- Amniotic Bands visualized on ultrasound are often due to uterine synechiae (intrauterine adhesions), residual gestation sac of a demised twin, fibrin strands s/p bleeding, chorioamniotic separation or may be noted with a circumvallate placenta. In general, they are benign entities and are not associated with adverse pregnancy outcome.
- In circumstances where the individual is deemed to have an increased risk for a fetal abnormality and does not have access to a provider who can perform the more desirable fetal and maternal ultrasound with detailed fetal anatomic examination (CPT® 76811) due to geographic or other constraints, a standard (after first trimester) fetal and maternal ultrasound (CPT® 76805) can be authorized instead.
- CPT® 76811 and CPT® 76812 should only be used once per pregnancy unless the mother changes to a new medical caregiver at a new office and there is a new medical indication and/or change in condition

Subchorionic Hematoma/Hemorrhage (Placental Hematoma) (OB-21.4)

OB.UA.0021.4.A

v1.0.2024

Subchorionic Hematoma/Hemorrhage (Placental Hematoma)

- Ultrasound can be performed for follow-up of a known subchorionic hematoma or placental hematoma
 - CPT® 76815 and/or CPT® 76817 if the last ultrasound was performed ≥ 7 days ago or
 - CPT® 76816 and/or CPT® 76817 if a complete ultrasound scan was performed ≥ 2 weeks ago
- Imaging can be repeated earlier than seven days if there are new or worsening symptoms such as an increasing amount of vaginal bleeding or increasing cramping or pain.
- No further imaging is needed if the follow-up ultrasound shows that the hemorrhage has resolved.
- If pregnancy is in second or third trimester follow **Suspected Abruption Placentae (OB-21.5)**

Suspected Abruption Placentae (OB-21.5)

OB.UA.0021.5.A

v1.0.2024

Suspected Abruption Placentae

Second and Third Trimesters

- For **suspected** abruption placentae:
 - CPT® 76805 [plus CPT® 76810 for each additional fetus] or CPT® 76811 if confirmed,¹⁶ and/or CPT® 76817 if a complete fetal anatomic scan has not yet been performed during this pregnancy, with or without CPT® 93976 (limited duplex scan)
 - CPT® 76815 for limited ultrasound and/or CPT® 76817, or
 - CPT® 76816 if anatomy ultrasound was done previously, and/or CPT® 76817
 - Vaginal bleeding with +KB (Kleihauer-Betke) – feto-maternal hemorrhage – at risk for fetal anemia and hydrops CPT® 76821 can be performed.
- Ultrasound is appropriate to follow-up a **known** abruption:
 - CPT® 76815 or CPT® 76816 if a complete ultrasound was done previously and/or CPT® 76817.
 - The number and frequency of follow-up ultrasounds will depend on the degree of abruption and the presence or absence of ongoing signs and symptoms.

Previa (Placenta Previa and Vasa Previa) (OB-21.6)

OB.UA.0021.6.A
v1.0.2024

Placenta Previa (OB-21.6.1)

Placenta Previa

Second and Third Trimesters

- For **suspected** placenta previa (placental edge covers the internal cervical os) one of the following ultrasound can be performed:
 - CPT® 76805 [plus CPT® 76810 for each additional fetus] and/or CPT® 76817 if a complete fetal anatomic scan has not yet been performed during this pregnancy with or without CPT® 93976 (limited duplex scan) **or**
 - CPT® 76815 for limited ultrasound and/or CPT® 76817 with or without CPT® 93976 (limited duplex scan) **or**
 - CPT® 76816 if a complete ultrasound was done previously **and/or** CPT® 76817 for a transvaginal ultrasound with or without CPT® 93976 (limited duplex scan)
- For **known** placenta previa (placental edge covers the internal cervical os) or low lying placenta (placental edge <2 cm from internal os):
 - One routine follow-up ultrasound can be performed in the 3rd trimester (CPT® 76815 or CPT® 76816 and/or CPT® 76817)
 - If placenta previa or low lying placenta is still present, one follow-up ultrasound (CPT® 76815 or CPT® 76816 and/or CPT® 76817) can be performed in 3-4 weeks
 - If persistent placenta previa (placental edge covers the internal cervical os), BPP (CPT® 76818/CPT® 76819 or modified BPP (CPT® 76815) weekly, starting at 32 weeks
 - Follow-up ultrasound can be performed at any time if bleeding occurs BPP (CPT® 76818 **or** CPT® 76819) **or** CPT® 76815 **or** CPT® 76816 if a complete ultrasound was done previously **and/or** CPT® 76817)

Background and Supporting Information

- For pregnancies beyond 16 weeks, if the placental edge is ≥ 2 cm away from the internal os, the placental location should be reported as normal.
- If the placental edge is <2 cm from the internal os but not covering the internal os, it should be labeled as low lying.
- If the placental edge covers the internal cervical os, the placenta should be labeled as a placenta previa.
- "There is no evidence to guide the optimal time of subsequent imaging in pregnancies thought to have placenta previa. In stable patients it is reasonable to

perform a follow-up ultrasonogram at approximately 32 weeks of gestation and an additional study at 36 weeks of gestation (if the previa persists) to determine the optimal route and timing of delivery. There is no clear benefit from more frequent ultrasonograms (eg, every 4 weeks) in stable cases."¹⁷

Vasa Previa (OB-21.6.2)

- Vasa previa occurs when fetal blood vessels that are unprotected by the umbilical cord or placenta run through the amniotic membranes and cross over the internal cervical os.

If a Vasa Previa is found on initial imaging:	
Detailed anatomic ultrasound at ≥16 weeks <ul style="list-style-type: none"> • Though fetal anatomy survey (CPT® 76805/CPT® 76811) can be performed as early as 14 weeks gestation, per ACOG, in the absence of other specific indications, it is optimally performed at 18 to 22 weeks of gestation. 	CPT® 76811 and/or ¹⁹ CPT® 76817
Follow-up growth ultrasound every 2 to 4 weeks starting at ≥22 weeks	CPT® 76816 and/or ¹⁹ CPT® 76817
Once vasa previa is confirmed cervical length screening every 2 to 4 weeks starting at 28 weeks	CPT® 76817 and CPT® 76816 or CPT® 76815
BPP or modified BPP weekly starting at 32 weeks (can be performed earlier and/or more frequently if worsening fetal condition suspected)	CPT® 76818 or CPT® 76819 (BPP) or CPT® 76815

Placenta Accreta Spectrum (PAS): Accreta, Increta, Percreta (OB-21.7)

OB.UA.0021.7.A

v1.0.2024

- PAS includes placenta accreta, placenta increta or placenta percreta.

Suspected PAS (OB-21.7.1)

- For **suspected** PAS:
 - CPT® 76811 or CPT® 76805 and/or CPT® 76817 if a complete fetal anatomic scan has not yet been performed. Can be performed with or without CPT® 93976 (limited duplex scan) **or**
 - CPT® 76816 (if a complete ultrasound was done previously) or CPT® 76815 and/or CPT® 76817 with or without CPT® 93976 (limited duplex scan)
 - MRI Pelvis without contrast (CPT® 72195) if inconclusive or equivocal ultrasound

Known PAS (OB-21.7.2)

- For **known** PAS:
 - Follow up growth ultrasounds can be performed every 2 to 4 weeks (CPT® 76816 if a complete ultrasound was done previously and/or CPT® 76817)
 - BPP (CPT® 76818 or CPT® 76819) or a modified BPP (CPT® 76815) weekly, starting at 32 weeks or sooner if indicated (other high-risk concerns)
 - Follow-up ultrasound can be performed at any time if bleeding occurs (CPT® 76815 and/or CPT® 76817)
 - MRI Pelvis without contrast (CPT® 72195) if the ultrasound is indeterminate or advanced imaging is needed for surgical planning. MRI Pelvis without contrast (CPT® 72195) is the appropriate code if only placenta or maternal pelvis is imaged without fetal imaging
 - The uterus, tubes and ovaries arise out of the pelvis and are considered pelvic organs. If the uterus rises out of the pelvic cavity, the imaging field can be determined on scout films. Imaging of the abdomen is not supported for problems suspected to arise from the pelvis.
 - The scout images (CT) and localizer images (MRI) are used to define the imaging field that is relevant to anatomical structures of clinical interest. The imaging field is defined by this clinical question, not by the imaging procedure code. The imaging code indicates the general anatomical region but does not define the specific imaging protocol or sequences.

Background and Supporting Information

- ACOG recommendations for imaging during pregnancy and lactation:

- Ultrasonography and magnetic resonance imaging (MRI) are not associated with risk and are the imaging techniques of choice for the pregnant patient, but they should be used prudently and only when use is expected to answer a relevant clinical question or otherwise provide medical benefit to the patient.
- The use of gadolinium contrast with MRI should be limited; it should be used as a contrast agent in a pregnant female only if it significantly improves diagnostic performance and is expected to improve fetal or maternal outcome.

References (OB-21)

v1.0.2024

1. ACOG Committee Opinion No. 723. Guidelines for Diagnostic Imaging During Pregnancy and Lactation *Obstetrics & Gynecology*. 2017 Oct;130(4):933-934. Reaffirmed 2021 doi: 10.1097/AOG.0000000000002350
2. AIUM Practice Parameter for the Performance of Limited Obstetric Ultrasound Examinations by Advanced Clinical Providers. *Journal of Ultrasound in Medicine*. 2018;37(7):1587-1596. doi:10.1002/jum.14677
3. Prabhu, M, Kuller, JA, Biggio, JR. Society for Maternal-Fetal Medicine Consult Series #57: Evaluation and management of isolated soft ultrasound markers for aneuploidy in the second trimester. October 2021
4. Lide B, Lindsley W, Foster MJ, Hale R, Haeri S. Intrahepatic Persistent Right Umbilical Vein and Associated Outcomes. *Journal of Ultrasound in Medicine*. 2016;35(1):1-5. doi:10.7863/ultra.15.01008
5. Zangen R, Boldes R, Yaffe H, Schwed P, Weiner Z. Umbilical cord cysts in the second and third trimesters: significance and prenatal approach. *Ultrasound in Obstetrics and Gynecology*. 2010;36(3):296-301. doi:10.1002/uog.7576
6. Predanic M, Perni SC, Chasen ST, et al. Ultrasound evaluation of abnormal umbilical cord coiling in second trimester of gestation in association with adverse pregnancy outcome. *American Journal of Obstetrics and Gynecology*. 2005 Aug;193(2):387-94. doi:10.1016/j.ajog.2004.12.092
7. Laat MWMD, Franx A, Bots ML, Visser GHA, Nikkels PGJ. Umbilical Coiling Index in Normal and Complicated Pregnancies. *Obstetrics & Gynecology*. 2006;107(5):1049-1055. doi:10.1097/01.aog.0000209197.84185.15
8. Mckinney J, Rac MW, Gandhi M. Society for Maternal-Fetal Medicine (SMFM) Fetal Anomalies Consult Series #2: December 2019. <https://doi.org/10.1016/j.ajog.2019.09>
9. Jensen KK, Oh KY, Kennedy AM, Sohaey R. Intrauterine Linear Echogenicities in the Gravid Uterus: What Radiologists Should Know. *Radiographics*. 2018 Mar-Apr;38(2):642-657. doi: 10.1148/rg.2018170062
10. Siström CL, Ferguson JE. Abnormal membranes in obstetrical ultrasound: incidence and significance of amniotic sheets and circumvallate placenta. *Ultrasound in Obstetrics and Gynecology*. 1993 Jul 1;3(4):249-55. doi: 10.1046/j.1469-0705.1993.03040249.x
11. Weissmann-Brenner A, Simchen MJ, Moran O, Kassif E, Achiron R, Zalel Y. Isolated fetal umbilical vein varix-prenatal sonographic diagnosis and suggested management. *Prenatal Diagnosis*. 2009;29(3):229-233. doi:10.1002/pd.2219
12. Zalel Y, Lehavi O, Heifetz S, et al. Varix of the fetal intra-abdominal umbilical vein: prenatal sonographic diagnosis and suggested in utero management. *Ultrasound in Obstetrics and Gynecology*. 2000;16(5):476-478. doi:10.1046/j.1469-0705.2000.00283.x
13. Lee SW, Kim MY, Kim JE, Chung JH, Lee HJ, Yoon JY. Clinical characteristics and outcomes of antenatal fetal intra-abdominal umbilical vein varix detection. *Obstetrics & Gynecology Science*. 2014;57(3):181. doi:10.5468/ogs.2014.57.3.181
14. ACOG Committee Opinion No. 831 Summary: Medically Indicated Late-Preterm and Early-Term Deliveries. *Obstetrics & Gynecology*. 2021;138:e35-39
15. Tuuli MG, Norman SM, Odibo AO, Macones GA, Cahill AG. Perinatal Outcomes in Women With Subchorionic Hematoma. *Obstetrics & Gynecology*. 2011;117(5):1205-1212. doi:10.1097/aog.0b013e31821568de
16. Gyamfi-Bannerman C. Society for Maternal-Fetal Medicine (SMFM) Consult Series #44: Management of bleeding in the late preterm period. *American Journal of Obstetrics and Gynecology*. 2018;218(1). doi:10.1016/j.ajog.2017.10.019
17. Heller HT, Mullen KM, Gordon RW, Reiss RE, Benson CB. Outcomes of pregnancies with a low-lying placenta diagnosed on second-trimester sonography. *Journal of Ultrasound in Medicine*. 2014 Apr;33(4):691-6. doi: 10.7863/ultra.33.4.691
18. Silver RM. Abnormal Placentation Placenta Previa, Vasa Previa, and Placenta Accreta. *Obstetrics & Gynecology*. 2015;126(3):654-668. doi:10.1097/aog.0000000000001005
19. Sinkey RG, Odibo AO, Dashe JS. Society for Maternal-Fetal Medicine (SMFM) #37: Diagnosis and management of vasa previa. *American Journal of Obstetrics and Gynecology*. 2015;213(5):615-619. doi:10.1016/j.ajog.2015.08.031
20. Cahill AG, Beigi R, Heine P, Silver RM, Wax JR. Placenta Accreta Spectrum. *Obstetric Care Consensus No. 7. Obstetrics & Gynecology*. 2018;132(6):e259-e275. doi:10.1097/aog.0000000000002983
21. Kilcoyne A, Shenoy-Bhangle AS, Roberts DJ, Sisodia RC, Gervais DA, Lee SI. MRI of Placenta Accreta, Placenta Increta, and Placenta Percreta: Pearls and Pitfalls. *American Journal of Roentgenology*. 2017;208(1):214-221. doi:10.2214/ajr.16.16281
22. SMFM Coding Committee White Paper: Coding for Placenta Accreta Spectrum

23. Cali G, Giambanco L, Puccio G, Forlani F. Morbidly adherent placenta: evaluation of ultrasound diagnostic criteria and differentiation of placenta accreta from percreta. *Ultrasound in Obstetrics & Gynecology*. 2013;41(4):406-412. doi:10.1002/uog.12385
24. Jauniaux E, Collins S, Burton GJ. Placenta accreta spectrum: pathophysiology and evidence-based anatomy for prenatal ultrasound imaging. *American Journal of Obstetrics and Gynecology*. 2018;218(1):75-87. doi:10.1016/j.ajog.2017.05.067
25. Mari G, Norton ME, Stone J, et al. Society for Maternal-Fetal Medicine (SMFM) Clinical Guideline #8: The fetus at risk for anemia—diagnosis and management. *American Journal of Obstetrics and Gynecology*. 2015;212(6):697-710. doi:10.1016/j.ajog.2015.01.059
26. Shainker SA, Coleman B, Timor-Tritsch IE, Bhide A, Bromley B, Cahill AG, Gandhi M, Hecht JL, Johnson KM, Levine D, Mastrobattista J, Philips J, Platt LD, Shamshirsaz AA, Shipp TD, Silver RM, Simpson LL, Copel JA, Abuhamad A; Society for Maternal-Fetal Medicine. Electronic address: pubs@smfm.org. Special Report of the Society for Maternal-Fetal Medicine Placenta Accreta Spectrum Ultrasound Marker Task Force: Consensus on definition of markers and approach to the ultrasound examination in pregnancies at risk for placenta accreta spectrum. *American Journal of Obstetrics and Gynecology*. 2021 Jan;224(1):B2-B14. doi: 10.1016/j.ajog.2020.09.001

Late-term/Post-term Pregnancy (OB-22)

Late-term/Post-term Pregnancy (OB-22.1)

OB.LT.0022.1.A

v1.0.2024

- Ultrasound is supported at ≥ 41 weeks gestation
 - CPT[®] 76816 (if ≥ 2 weeks since last follow up ultrasound).
 - Twice weekly BPP (CPT[®] 76818 or CPT[®] 76819) or modified BPP CPT[®] 76815

Background and Supporting Information

- In late-term/post-term pregnancies, uterine artery Doppler velocimetry (CPT[®] 93976) has not been found to be useful. Per SMFM - uterine artery Doppler has limited diagnostic accuracy and clinical utility in predicting FGR, SGA birth, and perinatal mortality.

References (OB-22)

v1.0.2024

1. Practice Bulletin No. 146: Management of Late-Term and Postterm Pregnancies. *Obstetrics & Gynecology*. 2014;124(2, PART 1):390-396. Reaffirmed 2020. doi:10.1097/01.AOG.0000452744.06088.48
2. Martins JG, Biggio JR, Abuhamad A. Society for Maternal-Fetal Medicine (SMFM) Consult Series #52: Diagnosis and Management of Fetal Growth Restriction. *American Journal of Obstetrics and Gynecology*. 2020. doi:10.1016/j.ajog.2020.05.010
3. ACOG Committee Opinion No. 828. Indications for outpatient antenatal fetal surveillance. American College of Obstetricians and Gynecologists. *Obstetrics & Gynecology*. 2021;137(6):e177-e197. doi:10.1097/aog.0000000000004407

Preterm/Prelabor Rupture of Membranes (OB-23)

Current Preterm/Prelabor Rupture of Membranes (PPROM) (OB-23.1)

OB.RM.0023.1.A

v1.0.2024

- If suspected preterm/prelabor rupture of membranes (<37 weeks) perform:
 - One time CPT® 76815 for quick look for AFI check, **OR**
 - If confirmed oligohydramnios or PPRM CPT® 76816 or CPT® 76811 if detailed anatomy scan not previously performed¹ for delivery planning
 - This will likely result in a hospital admission for evaluation and monitoring until delivery. Only in rare cases is outpatient monitoring performed.
- See **Amniotic Fluid Abnormalities (OB-17.1)**

Current Prelabor Rupture of Membranes (PROM) (OB-23.2)

OB.RM.0023.2.A

v1.0.2024

- If ≥ 37 weeks and PROM is suspected
 - One time CPT® 76815 for quick look for AFI check, **OR**
 - CPT® 76816 (If confirmed oligohydramnios or PROM), for delivery planning
 - This will likely result in a hospital admission for delivery

Background and Supporting Information

- CPT® 76815 should never be reported with complete studies CPT® 76801/CPT® 76802, CPT® 76805/CPT® 76810 or CPT® 76811/CPT® 76812 or with CPT® 76816 or BPP (CPT® 76818 and CPT® 76819).

References (OB-23)

v1.0.2024

1. ACOG Practice Bulletin No. 234: Prediction and Prevention of Spontaneous Preterm Birth. *Obstetrics & Gynecology*. 2021;138(2):e65-e90. doi:10.1097/aog.0000000000004479
2. ACOG Practice Bulletin No. 171: Management of Preterm Labor. *Obstetrics & Gynecology*. 2016;128(4):e155-e164. Reaffirmed 2022. doi:10.1097/AOG.000000000000171
3. ACOG Practice Bulletin No. 217: Prelabor Rupture of Membranes. *Obstetrics & Gynecology*. March 2020;135:e80–e97. Reaffirmed 2022. doi: 10.1097/AOG.0000000000003701
4. ACOG Committee Opinion No. 831. Medically Indicated Late-Preterm and Early-Term Deliveries. *Obstetrics & Gynecology*. 2021;138(1):e35-e39. doi:10.1097/aog.0000000000004447

Previous C-section or History of Uterine Scar (OB-24)

Previous C-section or History of Uterine Scar (OB-24.1)

OB.CS.0024.1.A

v1.0.2024

Previous Cesarean section and/or uterine scar

- Report one of the following:
 - Complete first trimester ultrasound CPT® 76801 [plus CPT® 76802 for each additional fetus] if <14 weeks and a complete ultrasound has not yet been performed, and/or CPT® 76817 for a transvaginal ultrasound
 - CPT® 76801 is preferred for dating, but if this is unable to be completed then CPT® 76815 and/or CPT® 76817 for a transvaginal ultrasound is indicated
- For a normal/low risk pregnancy report a fetal anatomy ultrasound CPT® 76805 if ≥16 weeks. If pregnancy is high risk report a detailed fetal anatomy ultrasound CPT® 76811 if ≥16 weeks – See **High Risk Pregnancy (OB-9)**
- Growth scan (CPT® 76816) in the early third trimester (between 28-32 weeks) **and**
- CPT® 76816 once in the late third trimester for delivery planning (36-38 weeks)
- Transvaginal ultrasound, CPT® 76817 if poor visualization of the lower uterine segment or if uterine wall thinning (dehiscence) is suspected.
- If a cesarean scar pregnancy⁵ is suspected, can perform:
 - CPT® 76817 with or without CPT® 93976 (limited duplex scan) and/or
 - CPT® 76376 or CPT® 76377
 - MRI Pelvis without contrast (CPT® 72195) if inconclusive or equivocal ultrasound
- See **3D and 4D Rendering (OB 28.12)** and **Suspected PAS (OB-21.7.1)**

Background and Supporting Information

- Cesarean scar pregnancy (CSP) is a complication in which an early pregnancy implants in the fibrous tissue of a prior uterine scar. Because of the fibrous nature of scar tissue, a CSP is at risk for dehiscence, placenta accreta and hemorrhage. Females who consider pregnancy after a CSP are at significant risk of recurrence.
- A combination of transvaginal and transabdominal, combined with color Doppler ultrasound imaging are recommended for diagnosis.
- CPT® 76815 should never be reported with complete studies CPT® 76801/CPT® 76802, CPT® 76805/CPT® 76810 or CPT® 76811/CPT® 76812 or with CPT® 76816 or BPP (CPT® 76818 and CPT® 76819).
- Though fetal anatomy survey (CPT® 76805/CPT® 76811) can be performed as early as 14 weeks gestation, per ACOG, in the absence of other specific indications, it is optimally performed at 18 to 22 weeks of gestation.

References (OB-24)

v1.0.2024

1. Gyamfi-Bannerman C, Gilbert S, Landon MB, et al. Risk of Uterine Rupture and Placenta Accreta With Prior Uterine Surgery Outside of the Lower Segment. *Obstetrics & Gynecology*. 2012;120(6):1332-1337. doi:10.1097/aog.0b013e318273695b
2. ACOG Practice Bulletin No. 205: Vaginal Birth After Cesarean Delivery. *Obstetrics & Gynecology*. 2019;133(2):110-127. doi:10.1097/aog.0000000000003078
3. Hamar BD, Levine D, Katz NL, Lim K-H. Expectant Management of Uterine Dehiscence in the Second Trimester of Pregnancy. *Obstetrics & Gynecology*. 2003;102(Supplement):1139-1142. doi:10.1097/00006250-200311001-00006
4. Oyelese Y, Tchabo J-G, Chapin B, Nair A, Hanson P, McLaren R. Conservative Management of Uterine Rupture Diagnosed Prenatally on the Basis of Sonography. *Journal of Ultrasound in Medicine*. 2003;22(9):977-980. doi:10.7863/jum.2003.22.9.977
5. Miller R, Timor-Tritsch IE, Gyamfi-Bannerman C. Society for Maternal-Fetal Medicine (SMFM) Consult Series #49: Cesarean scar pregnancy. *American Journal of Obstetrics and Gynecology*. 2020;222(5):B2-B14. doi:10.1016/j.ajog.2020.01.030
6. Ramanathan S, Raghu V, Ladumor SB, Nagadi AN, Palaniappan Y, Dogra V, Schieda N. Magnetic resonance imaging of common, uncommon, and rare implantation sites in ectopic pregnancy. *Abdom Radiol (NY)*. 2018 Dec;43(12):3425-3435. doi: 10.1007/s00261-018-1604-2
7. Dibble EH, Lourenco AP. Imaging Unusual Pregnancy Implantations: Rare Ectopic Pregnancies and More. *AJR Am J Roentgenol*. 2016 Dec;207(6):1380-1392. doi: 10.2214/AJR.15.15290

Termination of Pregnancy – Imaging (OB-25)

Imaging for Planned Pregnancy Termination (OB-25.1)

OB.PT.0025.1.A

v1.0.2024

- State and Federal legislation supersede these guidelines, see individual state regulations. For states in which pregnancy termination is supported by law, imaging as follows:
- For a planned pregnancy termination, ultrasound can be performed to determine intrauterine pregnancy and gestational age.
 - Complete first trimester anatomy ultrasound CPT® 76801 if <14 weeks and/or CPT® 76817, or
 - CPT® 76815 and/or CPT® 76817, or
 - If ≥14 weeks, CPT® 76805 (or CPT® 76811 if otherwise indicated, e.g. termination planned for chromosomal or structural fetal anomaly) can be performed (there may be State mandated imaging prior to termination).
- Routine follow-up is not usually necessary after uncomplicated medical abortion.
- For suspected medical abortion complication See **Spontaneous Abortion/Threatened/Missed Abortion (OB 5.4)**

Background and Supporting Information

- In general, most ultrasounds are indicated for planned pregnancy termination regardless of clinical information provided. Imaging may be indicated to confirm EGA, placenta location, and/or fetal anomalies.
- Though routine follow-up is not usually necessary after uncomplicated medical abortion, if otherwise medically indicated or preferred by the patient, follow-up ultrasound assessment after a medically induced termination can be considered
- CPT® 76815 should never be reported with complete studies CPT® 76801/CPT® 76802, CPT® 76805/CPT® 76810 or CPT® 76811/CPT® 76812 or with CPT® 76816 or BPP (CPT® 76818 and CPT® 76819).
- Though fetal anatomy survey (CPT® 76805/CPT® 76811) can be performed as early as 14 weeks gestation, per ACOG, in the absence of other specific indications, it is optimally performed at 18 to 22 weeks of gestation

References (OB-25)

v1.0.2024

1. ACOG Practice Bulletin No.225. Medication abortion up to 70 days of gestation. *Obstetrics & Gynecology*. 2020;136:e31-47. Reaffirmed 2023.
2. ACOG Practice Bulletin No. 135. Second-trimester abortion. *Obstetrics & Gynecology*. 2013;121(6):1394-1406. Reaffirmed 2021. Reaffirmed 2023. doi:10.1097/01.aog.0000431056.79334.cc

Trauma (OB-26)

Trauma – Imaging (OB-26.1)

OB.TR.0026.1.A

v1.0.2024

Prior to 13 weeks:

- Blunt trauma in the first trimester (prior to 13 weeks) generally does not cause pregnancy loss with the exception of profound hypotension:
 - No imaging is indicated unless there is cramping and/or bleeding.

Between 13-20 weeks gestation:

- CPT® 76815 and/or CPT® 76817 can be performed, **or**
- Complete first trimester anatomy ultrasound CPT® 76801 and/or CPT® 76817 if complete ultrasound has not yet been performed, and is <14 weeks **or**
- CPT® 76805 (plus CPT® 76810 for each additional fetus) (or CPT® 76811/CPT® 76812 if otherwise indicated) if ≥14 weeks, when complete fetal anatomic scan has not yet been performed

After 20 weeks:

- CPT® 76805 (or CPT® 76811 plus CPT® 76812 for each additional fetus if otherwise indicated) when a fetal anatomic scan has not yet been performed, or
- CPT® 76815 and/or CPT® 76817 or
- CPT® 76816
- Additionally, starting at 26 weeks, BPP (CPT® 76818 or CPT® 76819) or modified BPP (CPT® 76815) can be considered
- CPT® 76821 if vaginal bleeding with +KB (Kleihauer-Betke) (if fetomaternal hemorrhage - at risk for fetal anemia and hydrops)
- Other advanced imaging may be indicated. See **Blunt Abdominal Trauma (AB-10.1)**

Background and Supporting Information

- Typically all components of the BPP (CPT® 76818 and CPT® 76819), such as breathing, are not present until ≥26 weeks gestation. However, a modified BPP (CPT® 76815) can be utilized sooner in certain high risk cases but should not be done prior to 22 weeks.
- CPT® 76815 should never be reported with complete studies CPT® 76801/CPT® 76802, CPT® 76805/CPT® 76810 or CPT® 76811/CPT® 76812 or with CPT® 76816 or BPP (CPT® 76818 and CPT® 76819).
- Though fetal anatomy survey (CPT® 76805/CPT® 76811) can be performed as early as 14 weeks gestation, per ACOG, in the absence of other specific indications, it is optimally performed at 18 to 22 weeks of gestation.
- ACOG recommendations for imaging during pregnancy and lactation:

- Ultrasonography and magnetic resonance imaging (MRI) are not associated with risk and are the imaging techniques of choice for the pregnant patient, but they should be used prudently and only when use is expected to answer a relevant clinical question or otherwise provide medical benefit to the patient.
- With few exceptions, radiation exposure through radiography (Xrays), computed tomography (CT) scan, or nuclear medicine imaging techniques is at a dose much lower than the exposure associated with fetal harm. If these techniques are necessary in addition to ultrasound or MRI or are more readily available for the diagnosis in question, they should not be withheld from a pregnant patient.
- The use of gadolinium contrast with MRI should be limited; it should be used as a contrast agent in a pregnant female only if it significantly improves diagnostic performance and is expected to improve fetal or maternal outcome.
- With regards to iodinated IV contrast media, “it is generally recommended that contrast only be used if absolutely required to obtain additional diagnostic information that will affect the care of the fetus or woman during pregnancy”.

References (OB-26)

v1.0.2024

1. Jain V, Chari R, Maslovitz S, Farine D; Maternal Fetal Medicine Committee, Bujold E, Gagnon R, Basso M, Bos H, Brown R, Cooper S, Gouin K, McLeod NL, Menticoglou S, Mundle W, Pylypjuk C, Roggensack A, Sanderson F. Guidelines for the Management of a Pregnant Trauma Patient. *Journal of Obstetrics and Gynecology Can.* 2015 Jun;37(6):553-74. English, French. doi: 10.1016/s1701-2163(15)30232-2
2. Greco PS, Day LJ, Pearlman MD. Guidance for Evaluation and Management of Blunt Abdominal Trauma in Pregnancy. *Obstetrics & Gynecology.* 2019 Dec;134(6):1343-1357. doi: 10.1097/AOG.0000000000003585
3. Mari G, Norton ME, Stone J, et al. Society for Maternal-Fetal Medicine (SMFM) Clinical Guideline #8: The fetus at risk for anemia—diagnosis and management. *American Journal of Obstetrics and Gynecology.* 2015;212(6):697-710. doi:10.1016/j.ajog.2015.01
4. ACOG Practice Bulletin No. 211: Critical Care in Pregnancy. *Obstetrics & Gynecology.* 2019 May;133(5):e303-e319. Reaffirmed 2021. doi: 10.1097/AOG.0000000000003241

Unequal Fundal Size and Dates (OB-27)

Unequal Fundal Size and Dates (OB-27.1)

OB.US.0027.1.A

v1.0.2024

Unequal fundal size is defined as ≥ 3 cm difference between fundal height measurement and gestational age (weeks), at ≥ 22 weeks gestation

- One ultrasound can be performed (CPT® 76805) if complete fetal anatomic scan is planned and has not been performed **or**
- CPT® 76816 if complete anatomy scan or detailed anatomy ultrasound (CPT® 76805/CPT® 76811) has been done previously
- Where fundus cannot be adequately palpated such as in obesity, leiomyomas, multiple gestations, See appropriate chapter

Background and Supporting Information

- CPT® 76815 should never be reported with complete studies CPT® 76801/CPT® 76802, CPT® 76805/CPT® 76810 or CPT® 76811/CPT® 76812 or with CPT® 76816 or BPP (CPT® 76818 and CPT® 76819).
- Though fetal anatomy survey (CPT® 76805/CPT® 76811) can be performed as early as 14 weeks gestation, per ACOG, in the absence of other specific indications, it is optimally performed at 18 to 22 weeks of gestation

References (OB-27)

v1.0.2024

1. Pay A, Frøen J, Staff A, Jacobsson B, Gjessing H. Prediction of small-for-gestational-age status by symphysis-fundus height: a registry-based population cohort study. *BJOG: An International Journal of Obstetrics & Gynaecology*. 2016;123(7):1167-1173. doi:10.1111/1471-0528.13727
2. Pay ASD, Wiik J, Backe B, Jacobsson B, Strandell A, Klovning A. Symphysis-fundus height measurement to predict small-for-gestational-age status at birth: a systematic review. *BMC Pregnancy and Childbirth*. 2015;15(1). doi:10.1186/s12884-015-0461-z
3. ACOG Practice Bulletin No. 227: Fetal Growth Restriction. *Obstetrics & Gynecology*. 2021;137(2):e16-e28 doi: 10.1097/AOG.0000000000004251
4. ACOG Practice Bulletin No. 216: Macrosomia. *Obstetrics & Gynecology*. 2020;135(1):246-248. Reaffirmed 2023. doi:10.1097/aog.0000000000003607

Procedure Coding Basics for Established Pregnancy (OB-28)

Procedure Coding Basics for Established Pregnancy General Considerations (OB-28.1)

OB.PC.0028.1.A

v1.0.2024

- All obstetric ultrasound studies require permanently recorded images which may be stored on film or in a Picture Archiving and Communication System (PACS). Obstetric ultrasound services may not be billed without image recording.
- Ultrasound procedure codes include the preparation of a required final written report which should be included in the patient's medical record.
 - Each procedure code has specific required elements which are described in this section.
 - The report should document the results of the evaluation of each element or the reason any element is non-visualized.
 - Documentation of less than the required elements requires the billing of the "limited" code for that anatomic region.
 - Only one (1) limited exam should be billed per encounter.
- The use of a hand-held or any Doppler device that does not create a hard-copy output is considered part of the physical examination and is not separately billable.

Required Elements for Complete First Trimester Ultrasound (OB-28.2)

OB.PC.0028.2.A

v1.0.2024

CPT® Code Guidance

- Complete First Trimester Ultrasound [CPT® 76801 and CPT® 76802 (for each additional fetus)] can be performed up to and including 13 6/7 weeks gestation and is defined in CPT® as including the following elements:
 - Number and size of gestational sacs and fetuses
 - Survey of visible fetal anatomic structures and placental evaluation when possible
 - Qualitative assessment of amniotic fluid volume/gestational sac shape
 - Examination of maternal uterus and adnexa
- Complete First Trimester Ultrasound (CPT® 76801 and CPT® 76802) should only be reported once per pregnancy/per practice/facility unless the mother changes to a new medical caregiver at a new practice/facility and there is a new medical indication for ultrasound.

Required Elements for Second or Third Trimester Fetal Anatomic Evaluation Ultrasound (OB-28.3)

OB.PC.0028.3.A

v1.0.2024

CPT® Code Guidance

- A complete second or third trimester fetal anatomic evaluation ultrasound (CPT® 76805 and CPT® 76810 for each additional fetus) is defined in CPT® as including the following elements:
 - **Head, face, and neck:** Lateral cerebral ventricles; Choroid plexus; Midline falx; Cavum septum pellucidum; Cerebellum; Cistern magna; Upper lip: A measurement of the nuchal fold may be helpful during a specific age interval to assess the risk of aneuploidy
 - **Chest/Heart:** Four-chamber view; Left and Right ventricular outflow tracts
 - **Abdomen:** Stomach (presence, size, and situs); Kidneys; Urinary bladder; Umbilical cord insertion site into the fetal abdomen and number of vessels
 - **Spine:** Cervical, thoracic, lumbar, and sacral spine
 - **Extremities:** Legs and arms
 - **Genitalia:** (In multiple gestations and when medically indicated)
 - **Placenta:** Location; Relationship to internal os; Appearance; Placental cord insertion (when possible) and overall standard evaluation
 - Fetal number and Presentation
 - Qualitative or semi-qualitative estimate of amniotic fluid
 - **Maternal anatomy:** Cervix (transvaginal if cervical length is ≤ 3.6 cm on transabdominal ultrasound), Uterus, and Adnexa See **Cervical Length Screening (OB-7.3)**
 - **Fetal Biometry:** Biparietal diameter, Head circumference, Femur length, Abdominal circumference, and Fetal weight estimate.
- CPT® 76805 and CPT® 76810 **should only be used once per pregnancy per practice/facility** unless the mother changes to a new medical caregiver at a new practice/facility and there is a new medical indication for ultrasound.
- Though fetal anatomy survey (CPT® 76805/CPT® 76811) can be performed as early as 14 weeks gestation, per ACOG, in the absence of other specific indications, it is optimally performed at 18 to 22 weeks of gestation. This timing allows for a survey of fetal anatomy and an accurate estimation of gestational age
- Follow-up studies to CPT® 76805/CPT® 76810 should be coded as CPT® 76815 or CPT® 76816.

Required Elements for a Detailed Fetal Anatomic Evaluation Ultrasound (OB-28.4)

OB.PC.0028.4.A

v1.0.2024

CPT® Code Guidance

- Detailed fetal anatomy scan (CPT® 76811 and CPT® 76812 for each additional fetus) is generally performed by those with special skills to perform this study, such as Maternal Fetal Medicine specialists (Perinatologists), or Radiologists **with advanced training in fetal imaging**.
- CPT® 76811 and CPT® 76812 are defined in CPT® as including all of the requirements listed for CPT® 76805 and CPT® 76810. In addition, the report must document detailed anatomic evaluation of the following elements:
 - **Head, face, and neck:** 3rd and 4th ventricles; Lateral ventricles; Cerebellar lobes, vermis, and cisterna magna; Corpus callosum; Integrity and shape of cranial vault; Brain parenchyma; Neck; Profile; Coronal face (nose/lips/lenses); Palate, maxilla, mandible, and tongue; Ear position and size; Orbits
 - **Chest/Heart:** Aortic arch; Superior and inferior vena cava; 3-vessel view; 3-vessel and trachea view; Lungs; Integrity of diaphragm; Ribs
 - **Abdomen:** Small and large bowel; Adrenal glands; Gallbladder; Liver; Renal arteries; Spleen; Integrity of abdominal wall
 - **Spine:** Integrity of spine and overlying soft tissue; Shape and curvature
 - **Extremities:** Number: architecture and position; Hands; Feet; Digits: number and position
 - **Genitalia:** Gender
 - **Placenta:** Masses; Placental cord insertion; Accessory/succenturiate lobe with location of connecting vascular supply to primary placenta
 - **Biometry:** Cerebellum; Inner and outer orbital diameters; Nuchal thickness (16 to 20 wk); Nasal bone measurement (15 to 22 wk); Humerus; Ulna/radius; Tibia/fibula
 - **Maternal Anatomy:** Cervix (transvaginal if cervical length is ≤ 3.6 cm on transabdominal ultrasound); Uterus; Adnexa See **Cervical Length Screening (OB-7.3)**

CPT® Code Guidance

- CPT® 76811 and CPT® 76812 **should only be used once per pregnancy per practice/ facility** unless the mother changes to a new medical caregiver at a new facility and there is a new medical indication for ultrasound.
- Though fetal anatomy survey (CPT® 76805/CPT® 76811) can be performed as early as 14 weeks gestation, per ACOG, in the absence of other specific indications, it is optimally performed at 18 to 22 weeks of gestation. This timing allows for a survey of fetal anatomy and an accurate estimation of gestational age
- Follow-up studies to CPT® 76811/CPT® 76812 should be coded as CPT® 76815 or CPT® 76816.
- In circumstances where the individual is deemed to have an increased risk for a fetal abnormality and does not have access to a provider who can perform a fetal anatomic ultrasound examination (CPT® 76811) due to geographic or other constraints, a standard (after first trimester) fetal anatomic ultrasound examination (CPT® 76805) can be authorized instead.

Fetal Nuchal Translucency (OB-28.5)

OB.PC.0028.5.A

v1.0.2024

CPT® Code Guidance

- CPT® 76813 and CPT® 76814 (for each additional fetus) describe ultrasound measurement of the clear (translucent) space at the back of the fetal neck.
 - The first trimester screening can be performed if CRL measures 44-83 mm (typically between 10 4/7 and 14 weeks' gestation).
 - Abnormal Fetal Nuchal Translucency scan (NT \geq 3 mm or above the 95th percentile for the CRL) suggests an increased risk for aneuploidy, or may be a marker for cardiac defects, abdominal wall defects, diaphragmatic hernia, and genetic syndromes in euploid fetuses during current pregnancy.
 - The sonographer performing the study and/or the physician interpreting the study must be credentialed by the Maternal Fetal Medicine Foundation or Nuchal Translucency Quality Review Program (NTQR)
-
- The use of ultrasound codes (CPT® 76801/CPT® 76802) should be indication driven and should not be routinely done whenever an ultrasound for nuchal translucency (CPT® 76813/CPT® 76814) is requested. In cases where there is either a maternal and/or fetal indication, then the CPT® 76801 code can be billed along with the nuchal translucency screening (CPT® 76813/CPT® 76814).
 - Fetal Nuchal Translucency (CPT® 76813 and CPT® 76814) should only be reported once per pregnancy

Background and Supporting Information

- The first trimester screening is typically done between 11 and 13 6/7 weeks but can be performed if the crown rump length (CRL) measures between 44-83 mm (typically at gestational age range 10 4/7 to 14 weeks)
- **Required elements of the CPT® 76813 ultrasound code include:**
 - Fetal crown-rump measurement
 - Observation of fetal cardiac activity
 - Observation of the embryo at high magnification until the embryonic neck is in a neutral position and spontaneous embryonic movement allows for differentiation between the outer edge of the nuchal skin and the amnion
 - Measurement of the largest distance between the inner borders of the fetal nuchal translucency

Limited and Follow-up Studies (OB-28.6)

OB.PC.0028.6.A

v1.0.2024

CPT® Code Guidance

- **CPT® 76815** describes a **limited** or “quick look” study used when medically indicated to report one or more of the elements listed in the code definition, i.e. “fetal heartbeat”, placental location, for viability/dating (when indicated), or fluid check (re: modified BPP which is NST with CPT® 76815)
 - Reported only once, regardless of the number of fetuses, and only once per date of service
 - CPT® 76815 should never be reported with complete studies CPT® 76801/CPT® 76802, CPT® 76805/CPT® 76810 or CPT® 76811/CPT® 76812 or with CPT® 76816 or BPP (CPT® 76818 and CPT® 76819).
- **CPT® 76816** describes a **follow-up** ultrasound (eg, re-evaluation of fetal size by measuring standard growth parameters and amniotic fluid volume, re-evaluation of organ system(s) suspected or confirmed to be abnormal on a previous scan), trans-abdominal approach, per fetus.
 - The use of this CPT code is reserved for subsequent follow up ultrasound only; i.e. complete ultrasound (CPT® 76801, or CPT® 76805/CPT® 76811) must have been performed previously.
 - Components include: Focused assessment of fetal biometry, amniotic fluid volume and/or a detailed re-examination of a specific organ or system known or suspected to be abnormal on prior ultrasound.
 - CPT® 76816 should be reported once per fetus evaluated in follow-up.
 - CPT® 76816 should never be reported with complete studies (CPT® 76801, CPT® 76802, CPT® 76805/CPT® 76810, or CPT® 76811/CPT® 76810) or with a limited study (CPT® 76815).
 - CPT® 76816 should not be performed prior to a CPT® 76801 and/or an anatomy scan CPT® 76805 (normal pregnancy) or Detailed anatomy scan CPT® 76811 (high risk pregnancy), and is typically not performed before 14 weeks gestation.

Obstetric Transvaginal Ultrasound (OB-28.7)

OB.PC.0028.7.A

v1.0.2024

CPT® Code Guidance

- **CPT® 76817** is used to report an obstetrical transvaginal ultrasound for cervical length assessment (when indicated), or in certain circumstances with poor visualization by transabdominal US assessment.
- **CPT® 76817** is reported only once regardless of the number of fetuses.

Biophysical Profile (BPP) (OB-28.8)

OB.PC.0028.8.A

v1.0.2024

CPT® Code Guidance

- CPT® 76818 includes non-stress testing. Supported ≥26 weeks.
- CPT® 76819 does not include the non-stress testing portion. Supported ≥26 weeks
- CPT® 76815 is a modified BPP – includes NST and AFI. Supported ≥22 weeks
- BPPs performed on more than one fetus, should be reported separately.
- Modified BPP (CPT® 76815) should be reported only once, regardless of the number of fetuses, and only once per date of service.
- Modified BPP (CPT® 76815) should never be reported with complete studies, CPT® 76805/CPT® 76810 or CPT® 76811/CPT® 76812 or with CPT® 76816 or BPP (CPT® 76818 and CPT® 76819).

Background and Supporting Information

- The BPP is designed to predict the presence or absence of fetal asphyxia and, ultimately the risk of fetal death. A BPP is scored out of 10 with each parameter given a score of 0 or 2. A score ≥8 is considered normal. The following parameters are evaluated:
 - Fetal breathing movements
 - Gross fetal body movements
 - Fetal tone
 - Amniotic fluid volume, at least one vertical pocket 2 x 2 cm
 - Reactive FHR (non-stress testing portion)
- CPT® 76815 is used to assess the AFI portion of a modified BPP (NST + AFI)
- Typically all components of the BPP (CPT® 76818 and CPT® 76819), such as breathing, are not present until ≥26 weeks gestation. However, a modified BPP (CPT® 76815) can be utilized sooner in certain high risk cases but should not be done prior to 22.
- If BPP ≤6, repeat BPP in ≤24 hours

Fetal Doppler (OB-28.9)

OB.PC.0028.9.A

v1.0.2024

CPT® Code Guidance

- CPT® 76820 describes Doppler velocimetry of the umbilical artery (UA Doppler)
 - Utilized for known FGR; See **Fetal Growth Restriction Current Pregnancy (OB-20.1)** and known oligohydramnios See **Amniotic Fluid Abnormalities (OB-17.1)**, and is typically performed ≥ 22 weeks gestation.
 - Can be performed with known twin to twin transfusion or known discordant twins (See **Multiple Gestations (OB-11)**)
 - Its use to predict preeclampsia, and stillbirth is considered investigational.
- CPT® 76821 describes Doppler velocimetry of the middle cerebral artery (MCA Doppler).
 - Performed to evaluate a fetus at risk for anemia due to Rhesus isoimmunization/alloimmunization (as a substitute for amniocentesis), Twin anemia polycythemia sequence and non-immune hydrops caused by parvovirus B19 infection or any other known acquired or congenital cause of fetal anemia. See **Alloimmunization/Rh Isoimmunization (OB-16.1)**, **Other Causes of Fetal Anemia (OB-16.5)**, and **Multiple Gestations (OB-11)**
 - MCA Doppler (CPT® 76821) assessment can be performed if the fetus is at high risk for fetal anemia due to other pregnancy complications, e.g. chorioangioma, umbilical vein varix, or finding of sustained fetal tachyarrhythmia or bradyarrhythmia or a known congenital heart defect with suspected heart failure in the fetus - See **Indications for Fetal Conditions (OB-12.2)**, **Alloimmunization/Rh Isoimmunization (OB-16.1)**, and **Placental and Cord Abnormalities (OB-21)**
 - SMFM suggest that ductus venosus, middle cerebral artery, or uterine artery Doppler use for routine clinical management of early- or late-onset FGR *is not recommended*

Duplex Scan (OB-28.10)

OB.PC.0028.10.A

v1.0.2024

- A Duplex scan describes an ultrasonic scanning procedure for characterizing the pattern and direction of blood flow in arteries and veins. It produces real-time images integrating a B-mode two dimensional vascular structure, Doppler spectral analysis, and color flow Doppler imaging.
- **CPT® 93976** describes a limited duplex scan and is used during pregnancy to report uterine artery Doppler studies (done to report fetal umbilical-placental flow evaluation, accreta or other placental or cord abnormalities).
 - **CPT® 93975** describes a complete duplex scan. This code is **NOT** used in obstetrical imaging.
- The minimal use of color Doppler alone, when performed for anatomical structure identification, during a standard ultrasound procedure, is not separately reimbursable.
- SMFM state that uterine artery Doppler has limited diagnostic accuracy and clinical utility in predicting FGR, SGA birth, and perinatal mortality. As such, its use for screening in high risk groups is not recommended

Fetal Echocardiography (OB-28.11)

OB.PC.0028.11.A

v1.0.2024

CPT® Code Guidance

- CPT® 76825 describes a complete fetal echocardiography.
- CPT® 76827 describes a complete Doppler echocardiography, fetal, pulsed wave and/or continuous wave with spectral display
 - It is usually billed along with CPT® 76825
- CPT® 76826 describes a follow-up or repeat fetal echocardiogram
 - It should never be billed with CPT® 76825 or more than once per fetus on any date of service
- CPT® 76828 is a follow-up or repeat Doppler fetal echocardiogram
- Procedure code (CPT® 76827 or CPT® 76828) includes the evaluation of veins, arteries, and valves, and covers Doppler evaluation of the ductus venosus, ductus arteriosus, and PR Interval measurement as well as other vessels. Guidelines do not support the additional billing of CPT® 76820 and/or CPT® 76821.
- It is inappropriate to report codes CPT® 76825 – CPT® 76828 for the routine monitoring of fetal heart tones using a hand-held or any Doppler device that does not create a hard-copy output. Such fetal heart tone monitoring is considered part of the physical examination and is not separately billable.
- CPT® 93325 is used to report color mapping in conjunction with fetal echocardiography procedures CPT® 76825 – CPT® 76828.
 - The use of color Doppler (CPT® 93325) alone, when performed for anatomical structure identification, during a standard ultrasound procedure, is not separately reimbursable.

3D and 4D Rendering (OB-28.12)

OB.PC.0028.12.A

v1.0.2024

- There is currently insufficient data to generate appropriateness criteria for the use of 3D and 4D rendering in conjunction with Obstetrical ultrasound imaging.
 - Per ACOG, despite the technical advantages of 3-dimensional ultrasonography, proof of a clinical advantage of 3-dimensional ultrasonography in prenatal diagnosis, in general, is still lacking.
- However, 3D-4D (CPT® 76376 or CPT® 76377) rendering can be considered in certain situations of abnormal pregnancy implantation like suspected C-section scar pregnancies or suspected cornual (interstitial) ectopic pregnancy, or to locate an IUD. See **Locate an Intrauterine Device (IUD) (OB-3.1)**, **Previous C-section or History of Uterine Scar (OB 24.1)**, **Ectopic Pregnancy (OB 5.3)**, and **Uterine Anomalies (PV-14.1)** in the Pelvis Imaging Guidelines
- 3D-4D (CPT® 76376 or CPT® 76377) rendering can be used for surgical planning with diagnosis of complex CHD in the fetus or for surgical planning of other complex fetal malformations.¹⁶

Required Elements for a Detailed First Trimester Fetal Anatomic Evaluation Ultrasound (OB-28.13)

OB.PC.0028.13.A

v1.0.2024

CPT® Code Guidance

- Detailed first trimester fetal anatomy scan, CPT® 76801 **plus** CPT® 76813 (and CPT® 76802 **plus** CPT® 76814 for each additional fetus) can be performed between 12 weeks 0 days and 13 weeks 6 days when indicated (See **Detailed First Trimester Fetal Anatomic Scan (OB-9.12)** for indications).

A Detailed first trimester fetal anatomy scan must document detailed anatomic evaluation of the following elements:

- General:** Cardiac activity; Number of fetuses and gestational sacs
- Head, face, and neck:** Cranial bones (calvarium); falx cerebri; choroid plexus; transthalamic flax cerebri; Thalami; Posterior fossa; brain stem; 4th ventricles; cisterns magna; Corpus callosum; nasal bone; profile; maxilla; mandible; evaluation for cystic hygroma, dilated jugular; lymphatic sacs; nuchal translucency evaluation
- Chest/Heart:** Cardiac position and axis; 4-chamber view; 3- vessel and trachea view; Lungs; Integrity of diaphragm; Ribs
- Abdomen:** Stomach; Liver; Cord insertion into abdominal wall; Bladder; Umbilical arteries; Integrity of abdominal wall
- Spine:** Integrity of spine and overlying soft tissue; Shape and curvature
- Extremities:** Number: architecture and position; Hands; Feet: number and position
- Placenta:** Position; Umbilical cord insertion; Echo texture
- Biometry:** Crown-rump length
- Maternal Anatomy:** Myometrial masses; Mullein duct anomalies; Uterus; Ovaries; Adnexa and cul-de-sac

- A Detailed first trimester fetal anatomy scan, CPT® 76811 (and CPT® 76812 for each additional fetus) should only be reported once per pregnancy/per practice/facility unless the mother changes to a new medical caregiver at a new practice/facility and there is a new medical indication for ultrasound.
- It is generally performed by those with special skills to perform this study, such as Maternal Fetal Medicine specialists (Perinatologists), or Radiologists **with advanced training in fetal imaging**.

References (OB-28)

v1.0.2024

1. AIUM-ACR-ACOG-SMFM-SRU Practice Parameter for the Performance of Standard Diagnostic Obstetric Ultrasound Examinations. *Journal of Ultrasound in Medicine*. 2018;37(11). doi:10.1002/jum.14831
2. AIUM Practice Parameter for the Performance of Detailed Second- and Third-Trimester Diagnostic Obstetric Ultrasound Examinations. *Journal of Ultrasound in Medicine*. 2019;38(12):3093-3100. doi:10.1002/jum.15163
3. Reddy UM, Abuhamad AZ, Levine D, Saade GR. Fetal Imaging: Executive Summary of a Joint Eunice Kennedy Shriver National Institute of Child Health and Human Development, Society for Maternal-Fetal Medicine, American Institute of Ultrasound in Medicine, American College of Obstetricians and Gynecologists, American College of Radiology, Society for Pediatric Radiology, and Society of Radiologists in Ultrasound Fetal Imaging Workshop. *Obstetrics & Gynecology*. 2014;123(5):1070-1082. doi:10.1097/aog.0000000000000245
4. Practice Bulletin No. 175: Ultrasound in Pregnancy. *Obstetrics & Gynecology*. 2016;128(6):e241-e256. Reaffirmed 2020. Reaffirmed 2022. doi:10.1097/AOG.0000000000001815
5. ACOG Practice Bulletin No. 226: Screening for Fetal Chromosomal Abnormalities. *Obstetrics & Gynecology*. 2020;136(4):e48-e69. doi:10.1097/aog.0000000000004084
6. Society for Maternal and Fetal Medicine (SMFM), coding committee. SMFM Coding Committee White Paper: Billing of 76801 and/or 76813 with cfDNA. October 2017
7. AIUM Practice Parameter for the Performance of Limited Obstetric Ultrasound Examinations by Advanced Clinical Providers. *Journal of Ultrasound in Medicine*. 2018;37(7):1587-1596. doi:10.1002/jum.14677
8. ACOG Practice Bulletin No. 229: Indications for Outpatient Antenatal Fetal Surveillance. *Obstetrics & Gynecology*. 2021;137(6):e177-e197. doi:10.1097/aog.0000000000004407
9. ACOG Committee Opinion No. 828. Indications for outpatient antenatal fetal surveillance. American College of Obstetricians and Gynecologists. *Obstetrics & Gynecology*. 2021;137:e177-97. doi:10.1097/aog.0000000000004407
10. ACOG Practice Bulletin No. 227: Fetal Growth Restriction. *Obstet Gynecol*. 2021;137(2):e16-e28 doi: 10.1097/AOG.0000000000004251 Galan HL. Timing Delivery of the Growth-Restricted Fetus. *Seminars in Perinatology*. 2011;35(5):262-269. doi:10.1053/j.semperi.2011.05.009
11. Martins JG, Biggio JR, Abuhamad A. Society for Maternal-Fetal Medicine (SMFM) Consult Series #52: Diagnosis and Management of Fetal Growth Restriction. *American Journal of Obstetrics and Gynecology*. 2020. doi:10.1016/j.ajog.2020.05.010
12. AIUM Practice Parameter for the Performance of Fetal Echocardiography. *Journal of Ultrasound in Medicine*. 2019;39(1). doi:10.1002/jum.15188
13. Miller R, Timor-Tritsch IE, Gyamfi-Bannerman C. Society for Maternal-Fetal Medicine (SMFM) Consult Series #49: Cesarean scar pregnancy. *American Journal of Obstetrics and Gynecology*. 2020;222(5):B2-B14. doi:10.1016/j.ajog.2020.01.030
14. Dibble EH, Lourenco AP. Imaging Unusual Pregnancy Implantations: Rare Ectopic Pregnancies and More. *AJR Am J Roentgenol*. 2016 Dec;207(6):1380-1392. doi: 10.2214/AJR.15.15290
15. Ramanathan S, Raghu V, Ladumor SB, Nagadi AN, Palaniappan Y, Dogra V, Schieda N. Magnetic resonance imaging of common, uncommon, and rare implantation sites in ectopic pregnancy. *Abdom Radiol (NY)*. 2018 Dec;43(12):3425-3435. doi: 10.1007/s00261-018-1604-2
16. Lloyd DFA, Pushparajah K, Simpson JM, et al. Three-dimensional visualisation of the fetal heart using prenatal MRI with motion-corrected slice-volume registration: a prospective, single-centre cohort study. *The Lancet*. 2019;393(10181):1619-1627. doi:10.1016/s0140-6736(18)32490-5

Table of Contents

Guideline

- General Guidelines (ONC-1)
- Primary Central Nervous System Tumors (ONC-2)
- Squamous Cell Carcinomas of the Head and Neck (ONC-3)
- Salivary Gland Cancers (ONC-4)
- Melanomas and Other Skin Cancers (ONC-5)
- Thyroid Cancer (ONC-6)
- Small Cell Lung Cancer (ONC-7)
- Non-Small Cell Lung Cancer (ONC-8)
- Esophageal and GE Junction Cancer (ONC-9)
- Other Thoracic Tumors (ONC-10)
- Breast Cancer (ONC-11)
- Sarcomas – Bone, Soft Tissue, and GIST (ONC-12)
- Pancreatic Cancer (ONC-13)
- Upper GI Cancers (ONC-14)
- Neuroendocrine Cancers and Adrenal Tumors (ONC-15)
- Colorectal and Small Bowel Cancer (ONC-16)
- Renal Cell Cancer (RCC) (ONC-17)
- Transitional Cell Cancer (ONC-18)
- Prostate Cancer (ONC-19)
- Testicular, Ovarian and Extragenital Germ Cell Tumors (ONC-20)
- Ovarian Cancer (ONC-21)
- Uterine Cancer (ONC-22)
- Cervical Cancer (ONC-23)
- Anal Cancer & Cancers of the External Genitalia (ONC-24)
- Multiple Myeloma and Plasmacytomas (ONC-25)
- Leukemias, Myelodysplasia and Myeloproliferative Neoplasms (ONC-26)
- Non-Hodgkin Lymphomas (ONC-27)
- Hodgkin Lymphoma (ONC-28)
- Hematopoietic Stem Cell Transplantation (ONC-29)
- Medical Conditions with Cancer in the Differential Diagnosis (ONC-30)
- Metastatic Cancer, Carcinoma of Unknown Primary Site, and Other Types of Cancer (ONC-31)

General Guidelines (ONC-1)

Guideline

Abbreviations for Oncology Imaging Guidelines

General Guidelines (ONC-1.0)

Key Principles (ONC-1.1)

Phases of Oncology Imaging and General Phase-Related Considerations (ONC-1.2)

Nuclear Medicine (NM) Imaging in Oncology (ONC-1.3)

PET Imaging in Oncology (ONC-1.4)

Unlisted Procedure Codes in Oncology (ONC-1.5)

Predisposition Syndromes (ONC-1.6)

References (ONC-1)

Abbreviations for Oncology Imaging Guidelines

ON.GG.Abbreviations.A

v2.0.2024

Abbreviations for Oncology Imaging Guidelines	
ACTH	adrenocorticotrophic hormone
AFP	alpha-fetoprotein
ALKP	alkaline phosphatase
AP	anteroposterior
betaHCG	beta human chorionic gonadotropin
CA 125	cancer antigen 125 test
CA 19-9	cancer antigen 19-9
CA 15-3	cancer antigen 15-3
CA 27-29	cancer antigen 27-29
CBC	complete blood count
CEA	carcinoembryonic antigen
CNS	central nervous system
CR	complete response
CTA	computed tomography angiography
DCIS	ductal carcinoma in situ
DLBCL	diffuse large B cell lymphomas
DRE	digital rectal exam
EGD	esophagogastroduodenoscopy
ENT	ear, nose, throat
EOT	end of therapy
ERCP	endoscopic retrograde cholangiopancreatography
ESR	erythrocyte sedimentation rate
EUA	exam under anesthesia
EUS	endoscopic ultrasound
FDG	fluorodeoxyglucose
FNA	fine needle aspiration

Abbreviations for Oncology Imaging Guidelines	
FUO	fever of unknown origin
GE	gastroesophageal
GI	gastrointestinal
GU	genitourinary
GTR	gross total resection
HG	high-grade
HIV	human immunodeficiency disease
HRPC	hormone refractory prostate cancer
hypermet	hypermetabolic
IFRT	involved field radiation therapy
inv	invasive
LAR	low anterior resection
LCIS	lobular carcinoma in situ
LDH	lactate dehydrogenase
LFT	liver function tests
LND	lymph node dissection
MALT	mucosa associated lymphoid tissue
maint	maintenance
MEN	multiple endocrine neoplasia
MG	myasthenia gravis
MGUS	monoclonal gammopathy of unknown significance
MIBG	I-123 metaiodobenzylguanidine scintigraphy
MRA	magnetic resonance angiography
MRI	magnetic resonance imaging
MUGA	'multiple gated acquisition' cardiac nuclear scan
MWA	microwave ablation
NaF	sodium fluoride
NET	neuroendocrine tumor
NCCN®	National Comprehensive Cancer Network

Abbreviations for Oncology Imaging Guidelines	
NHL	non-Hodgkin's lymphoma
NPC	nasopharyngeal carcinoma
NSABP	National Surgical Adjuvant Breast and Bowel Project
NSAIDS	nonsteroidal anti-inflammatory drugs
NSCLC	non-small cell lung cancer
NSGCT	non-seminomatous germ cell tumor
PA	posteroanterior
PCI	prophylactic cranial irradiation
PET	positron emission tomography
COG	Children's Oncology Group
PSA	prostate specific antigen
RFA	radiofrequency ablation
RPLND	retroperitoneal lymph node dissection
SqCCa	squamous cell carcinoma
SCLC	small cell lung cancer
SIADH	syndrome of inappropriate secretion of antidiuretic hormone
TCC	transitional cell carcinoma
TLH	total laparoscopic hysterectomy
TNM	tumor node metastasis staging system
TSH	thyroid-stimulating hormone
TURBT	trans-urethral resection of bladder tumor
VIPoma	vasoactive intestinal polypeptide
WLE	wide local incision
WB-MRI	whole body MRI
WM	Waldenstrom's macroglobulinemia
WBXRT	whole brain radiation therapy

General Guidelines (ONC-1.0)

ON.GG.0001.0.A

v2.0.2024

- A recent clinical evaluation (within 60 days) or meaningful contact (telephone call, electronic mail or messaging) should be performed prior to considering advanced imaging, unless the individual is undergoing guideline-supported scheduled off therapy surveillance evaluation or cancer screening. The clinical evaluation may include a relevant history and physical examination, including biopsy, appropriate laboratory studies, and results of non-advanced or advanced imaging modalities.
- Unless otherwise stated in the disease-specific guideline, a histological confirmation of malignancy (or recurrence) and the stage of disease is required to perform a medical necessity review of the requested imaging.
- Generally, the studies listed in the disease-specific sections reflect the studies supported by current literature and research for that condition. If a study is not listed, then it is not supported.
- Routine imaging of brain, spine, neck, chest, abdomen, pelvis, bones, or other body areas is not indicated except where explicitly stated in a diagnosis-specific guideline section, or if one of the following applies:
 - Known prior disease involving the requested body area
 - New or worsening symptoms or physical exam findings involving the requested body area (including non-specific findings such as ascites or pleural effusion)
 - New finding on basic imaging study such as plain x-ray or ultrasound
 - New finding on adjacent body area CT/MRI study (i.e., pleural effusion observed on CT abdomen)
- Unless otherwise stated in the disease-specific guideline, advanced imaging of asymptomatic individuals is not routinely supported without signs or symptoms of systemic involvement of cancer.
- Repeat imaging studies are not generally necessary unless there is evidence of disease progression, recurrence of disease, and/or the repeat imaging will affect an individual's clinical management.
- Conventional imaging performed prior to diagnosis should not be repeated unless there is a delay of at least 6 weeks since previous imaging and treatment initiation or there are new or significantly worsening clinical signs or symptoms

Phase	Imaging Timeframe
After definitive local therapy of primary tumor (surgery or radiation therapy)	• Follow surveillance guidelines
During adjuvant chemotherapy	• Follow surveillance guidelines
After ablative therapy	• See disease-specific guidelines
During chemotherapy or immunotherapy for measurable disease	• Every 2 cycles (generally every 6 to 8 weeks)

Phase	Imaging Timeframe
During endocrine/hormonal therapy for measurable disease	<ul style="list-style-type: none"> • Every 3 months (12 weeks)
Measurable metastatic disease being monitored off therapy	<ul style="list-style-type: none"> • Every 3 months (12 weeks)
Minimal metastatic disease on maintenance therapy	<ul style="list-style-type: none"> • Every 3 months (12 weeks)
Surveillance for history of metastatic disease with complete response and being observed off-therapy	<ul style="list-style-type: none"> • Imaging typically not indicated beyond 5 years from completion of treatment for metastatic disease

- Advanced imaging is not indicated for evaluation of in situ or non-invasive cancers or cancer surveillance after complete surgical removal of primary disease unless otherwise stated in the cancer-specific guidelines.
- Advanced imaging is not indicated for monitoring disease in individuals who choose to not receive standard oncologic therapy, but may be receiving alternative therapies or palliative care and/or hospice. All advanced imaging indicated for initial staging of the specific cancer type can be approved once when the individual is considering initiation of a standard therapeutic approach (surgery, chemotherapy, or radiation therapy).
- Brain imaging is performed for signs or symptoms of brain disease
 - MRI Brain without and with contrast (CPT® 70553) is the recommended study for evaluation of suspected or known brain metastases. If a non-contrast CT head shows suspicious lesion, MRI brain may be obtained to further characterize the lesion
 - CT without and with contrast (CPT® 70470) can be approved when MRI is contraindicated or not available, or if there is skull bone involvement
 - Certain malignancies including, but not limited to melanoma and lung cancer have indications for brain imaging for asymptomatic individuals
 - If stage IV disease is demonstrated elsewhere or if systemic disease progression is noted, refer to disease specific guidelines
 - Initiation of angiogenesis therapy is not an indication for advanced imaging of the brain in asymptomatic individuals (Avastin/Bevacizumab; < 3% risk of bleeding and < 1% risk of serious bleeding)
- Bone Scan:
 - Primarily used for evaluation of bone metastases in individuals with solid malignancies.
 - Indications for bone scan in individuals with history of malignancy include – bone pain, rising tumor markers, elevated alkaline phosphatase or in individuals with primary bone tumor.
 - For evaluation of suspected or known bony metastases, CPT® 78306 (Nuclear bone scan whole body), may be approved.

- Radiopharmaceutical Localization scan SPECT (CPT® 78803 or CPT® 78831) or SPECT/CT (CPT® 78830 or CPT® 78832) may be approved as an add-on test for further evaluation of a specific area of interest.
- CPT® codes 78300 (Nuclear bone scan limited), 78305 (Nuclear bone scan multiple areas) or 78315 do not have any indications in oncology nuclear medicine imaging.
- Bone scan supplemented by plain x-rays are the initial imaging modalities for suspected malignant bone pain. For specific imaging indications, see also:
 - **Nuclear Medicine (NM) Imaging in Oncology (ONC-1.3)**
 - **Bone (Non-Vertebral) Metastases (ONC-31.5)**
 - **Spinal/Vertebral Metastases (ONC-31.6)**
 - **Carcinoma of Unknown Primary Site (ONC-31.7)**
- Advanced imaging used for radiation therapy treatment planning should not be authorized using any of the diagnostic imaging codes for CT, MRI, or PET.
 - In the absence of written payor guidelines, advanced imaging performed in support of radiation therapy treatment planning should be reported with CPT® 76498 for Unlisted MRI or CPT® 76497 for Unlisted CT scan
- Delay PET/CT for at least 12 weeks after completion of radiation treatment, unless required sooner for imminent surgical resection.
- PET/CT may be considered prior to biopsy in order to determine a more favorable site for biopsy when a prior biopsy was nondiagnostic or a relatively inaccessible site is contemplated which would require invasive surgical intervention for biopsy attempt.
- PET/CT may be indicated if:
 - Conventional imaging (CT, MRI or bone scan) reveals findings that are inconclusive or negative, with continued suspicion for recurrence
- Unless specified in diagnosis-specific guideline section PET/CT Imaging is NOT indicated for:
 - Infection, inflammation, trauma, post-operative healing, granulomatous disease, rheumatological conditions
 - Concomitantly with separate diagnostic CT studies
 - Conclusive evidence of distant or diffuse metastatic disease on recent conventional imaging studies
 - Metastatic disease in the central nervous system (CNS)
 - Lesions less than 8 mm in size
 - Follow up after localized therapy (i.e. radiofrequency ablation, embolization, stereotactic radiation, etc.)
 - Rare malignancies, due to lack of available evidence regarding the diagnostic accuracy of PET in rare cancers
 - Surveillance

- Serial monitoring of individuals who are not currently receiving anti-tumor treatment or are receiving maintenance treatment
- Serial monitoring of FDG avidity until resolution.
- PET/CT avidity in a residual mass at the end of planned therapy is not an indication for PET/CT imaging during surveillance.
- Residual mass that has not changed in size since the last conventional imaging does not justify PET imaging
- Unless otherwise specified for a specific cancer type, once PET has been documented to be negative for a given individual's cancer or all PET-avid disease has been surgically resected, PET should not be used for continued disease monitoring or surveillance.
- PET/MRI is generally not supported by eviCore for imaging adults with a vast majority of oncologic conditions due to lack of standardization in imaging technique and interpretation.
 - However, it may be indicated in certain pediatric oncologic conditions. See: **PET Imaging in Pediatric Oncology (PEDONC-1.4)** for indications.
- The specific radiotracer planned to be used with PET/CT imaging is required to perform a medical necessity review. Indications for PET/CT imaging using non-FDG radiotracers are listed in diagnosis-specific guidelines.
 - Supported radiotracers:
 - ¹⁸F-FDG
 - ⁶⁸Gallium DOTATATE (NETSPOT[®]) for low-grade neuroendocrine tumors and medullary thyroid cancer
 - ⁶⁴Cu-DOTATATE (DETECTNET[®]) for low-grade neuroendocrine tumors
 - ⁶⁸Ga-DOTA-TOC for low-grade neuroendocrine tumors
 - ¹¹C Choline for prostate cancer
 - ¹⁸F-Fluciclovine (AXUMIN[®]) for prostate cancer
 - ⁶⁸Ga PSMA-11 for prostate cancer
 - ¹⁸F Piflufolastat (Pylarify[®]) for prostate cancer
 - ⁶⁸Ga Gozetotide (Illuccix[®] and Locametz[®]) for prostate cancer
 - ¹⁸F Flotufolastat (Posluma[®]) for prostate cancer
 - ¹⁸F Fluoroestradiol (Cerianna[®]) for breast cancer
 - Unsupported radiotracers:
 - ¹⁸F-Na Fluoride PET bone scan
 - PET/CT imaging using isotopes other than those specified above
- Octreotide scan:
 - Specific for low and intermediate grade neuroendocrine tumors which express specific cell surface somatostatin receptors. See cancer specific guidelines for recommended use.
 - One of the following codes may be approved when Octreotide scan is requested:

- CPT® 78802 (Radiopharmaceutical localization of tumor whole-body single day study)
- CPT® 78804 (Radiopharmaceutical localization of tumor whole-body two or more days)
- In addition to one of the above CPT codes, CPT® 78803 (Radiopharmaceutical localization of tumor SPECT), SPECT CPT® 78831, or hybrid SPECT/CT (CPT® 78830 or 78832) may be approved as an add-on test for further evaluation of a specific area of interest.

Clinical Trials

- Similar to investigational and experimental studies, clinical trial imaging requests will be considered to determine whether they meet Health Plan coverage and eviCore's evidence-based guidelines.
- Imaging studies which are inconsistent with established clinical standards, or are requested for data collection and not used in direct clinical management are not supported.

Key Principles (ONC-1.1)

ON.GG.0001.1.A

v2.0.2024

AGE APPROPRIATE GUIDELINES	
Age of Individual	Appropriate Imaging Guidelines
≥18 years old at initial diagnosis	<ul style="list-style-type: none"> General Oncology Imaging Guidelines, except where directed otherwise by a specific guideline section
<18 years old at initial diagnosis	<ul style="list-style-type: none"> Pediatric and Special Populations Oncology Imaging Guidelines, except where directed otherwise by a specific guideline section
15 to 39 years old at initial diagnosis (defined as Adolescent and Young Adult (AYA) oncology individuals)	<ul style="list-style-type: none"> When unique guidelines for a specific cancer type exist only in either General Oncology or Pediatric and Special Populations Oncology, AYA individuals should be imaged according to the guideline section for their specific cancer type, regardless of the individual's age When unique guidelines for a specific cancer type exist in both General Oncology and Pediatric and Special Populations Oncology, AYA individuals should be imaged according to the age rule in the previous bullet

- Conventional Imaging (mostly CT, sometimes MRI or bone scan) of the affected area(s) drives much of initial and re-staging and surveillance. PET is not indicated for surveillance imaging unless specifically stated in the diagnosis-specific guideline sections
- Brain imaging is performed for signs or symptoms of brain disease
 - MRI Brain without and with contrast (CPT® 70553) is the recommended study for evaluation of suspected or known brain metastases.
 - MRI Brain without and with contrast (CPT® 70553) may be obtained if a non-contrast CT Head shows suspicious lesion.
 - CT Head without and with contrast (CPT® 70470) can be approved when MRI is contraindicated or not available, or if there is skull bone involvement.
 - Initiation of angiogenesis therapy is not an indication for advanced imaging of the brain in asymptomatic individuals (Avastin/Bevacizumab; <3% risk of bleeding and <1% risk of serious bleeding)

- Individuals receiving cardiotoxic chemotherapy (such as doxorubicin, trastuzumab, pertuzumab, mitoxantrone, etc.) may undergo cardiac evaluation – at baseline and for monitoring while on active therapy.
 - Echocardiography (CPT® 93306, CPT® 93307, or CPT® 93308) rather than MUGA scan for determination of LVEF and/or wall motion.
 - MUGA Scan may be performed instead of ECHO in individuals who have a low LV ejection fraction of <50% on a prior ECHO or MUGA, pre-existing left ventricular wall motion abnormalities from ischemic or non-ischemic cardiomyopathies, congestive heart failure or when ECHO is technically limited and prevents accurate assessment of LV function.
 - A prior MUGA is not a reason to approve another MUGA (it is not necessary to compare LVEF by the same modality)
 - The timeframe for monitoring the ejection fraction should be determined by the provider, but no more often than baseline and at every 6 weeks.
 - May repeat every 4 weeks if cardiotoxic chemotherapeutic drug is withheld for significant left ventricular cardiac dysfunction.
 - See: **Oncologic Indications for Cancer Therapeutics-Related Cardiac Dysfunction (CTRCD) (CD-12.1)** in the Cardiology Imaging Guidelines
- CTA or MRA of a specific anatomic region is indicated when requested for surgical planning when there is suspected vascular proximity to proposed resection margin.
- Adults (≥18 years) with a diagnosis of Li-Fraumeni Syndrome (LFS) may be screened for malignancy with a Whole-Body MRI (CPT® 76498) on an annual basis. Annual Brain MRI (CPT® 70553) may be performed as part of Whole-Body MRI or as a separate exam. Due to lack of standardization of technique, interpretation, and availability of Whole-Body MRI, individuals with LFS are encouraged to participate in clinical trials.

Use of Contrast

- CT imaging should be performed with contrast for known or suspected body regions, unless contraindicated.
 - Shellfish allergy is not a contraindication to contrast. Individuals with known shellfish allergy do not have contrast reaction any more often than other atopic individuals or individuals with other food allergies.
 - For iodinated contrast dye allergy, either CT scans without contrast or MRI scans without and with contrast are indicated.
 - If CT scanning is considered strongly indicated in an individual with known contrast allergy, CT with contrast may be considered to be safely performed following prednisone premedication over a 24-hour period prior to the study.
- For individuals with renal insufficiency which precludes contrast use, CT without contrast appropriate disease-specific areas should be offered. Further imaging (such as MRI) may be indicated if noncontrast CT results are inconclusive.
- Severe renal insufficiency, i.e. an eGFR less than 30, is a contraindication for an MRI using a gadolinium-based contrast agent (GBCA) as well. In individuals with eGFR greater than 40, GBCA administration can be safely performed. GBCA

administered to individuals with acute kidney injury or severe chronic kidney disease can result in a syndrome of nephrogenic systemic fibrosis (NSF), but GBCAs are not considered nephrotoxic at dosages approved for MRI.

- Gadolinium deposition has been found in individuals with normal renal function following the use of gadolinium based contrast agents (GBCAs).
 - The U.S. Food and Drug Administration (FDA) is investigating the risk of brain deposits following repeated use of GBCAs.
 - The FDA has noted that, “It is unknown whether these gadolinium deposits are harmful or can lead to adverse health effects.” and have recommended:
 - To reduce the potential for gadolinium accumulation, health care professionals should consider limiting GBCA use to clinical circumstances in which the additional information provided by the contrast is necessary.
 - Health care professionals are also urged to reassess the necessity of repetitive GBCA MRIs in established treatment protocols.

Radiation Exposure

- The use of MRI in place of CT scans to reduce risk of secondary malignancy from radiation exposure during CT is not supported by the peer-reviewed literature. Unless otherwise specified in the Guidelines, MRI in place of CT scans for this purpose alone is not indicated. In some instances (i.e., testicular cancer surveillance), MRI may be considered inferior to CT scans.

Phases of Oncology Imaging and General Phase-Related Considerations (ONC-1.2)

ON.GG.0001.2.A
v2.0.2024

Phases of Oncology Imaging	Definition
Screening	Imaging requested for individuals at increased risk for a particular cancer in the absence of known clinical signs or symptoms
Suspected Diagnosis	Imaging requested to evaluate a suspicion of cancer, prior to histological confirmation
Initial work-up and Staging	Imaging requested after biopsy confirmation and prior to starting specific treatment
Treatment response or Interim Restaging	Imaging performed during active treatment with chemotherapy, targeted therapy, immunotherapy, or endocrine therapy
Restaging of locally treated lesions	Imaging performed to evaluate primary or metastatic lesions with ablation using cryoablation, radiofrequency, radioactive isotope, microwave or chemotherapy
Restaging / Suspected Recurrence	Imaging requested when there is suspicion for progression or recurrence of known cancer based on clinical signs/symptoms, laboratory tests or basic imaging studies
Surveillance	Imaging performed in individuals who: <ul style="list-style-type: none"> • Are asymptomatic or have chronic stable symptoms, and • Have no clinical suspicion of change in disease status, and • Are not receiving active anti-tumor treatment or are receiving maintenance treatment

General phase-related considerations

- Conventional imaging performed prior to diagnosis should not be repeated unless there is a delay of at least 6 weeks since previous imaging and treatment initiation or there are new or significantly worsening clinical signs or symptoms

Phase	Imaging Timeframe
After definitive local therapy of primary tumor (surgery or radiation therapy)	<ul style="list-style-type: none"> • Follow surveillance guidelines

Phase	Imaging Timeframe
During adjuvant chemotherapy or endocrine therapy	<ul style="list-style-type: none">Follow surveillance guidelines
After ablative therapy	<ul style="list-style-type: none">See disease-specific guidelines
During chemotherapy or immunotherapy for measurable disease	<ul style="list-style-type: none">Every 2 cycles (generally every 6 to 8 weeks)
During endocrine/hormonal therapy for measurable disease	<ul style="list-style-type: none">Every 3 months (12 weeks)
Metastatic disease on maintenance therapy	<ul style="list-style-type: none">Every 3 months (12 weeks)
Measurable metastatic disease being monitored off therapy	<ul style="list-style-type: none">Every 3 months (12 weeks) for up to 5 years after completion of treatment for metastatic disease

Nuclear Medicine (NM) Imaging in Oncology (ONC-1.3)

ON.GG.0001.3.A

v2.0.2024

- This section does not apply to PET imaging. PET imaging considerations can be found in [PET Imaging in Oncology \(ONC-1.4\)](#)
- Bone Scan:
 - Primarily used for evaluation of bone metastases in individuals with solid malignancies.
 - Indications for bone scan in individuals with history of malignancy include – bone pain, rising tumor markers, elevated alkaline phosphatase or in individuals with primary bone tumor.
 - For evaluation of suspected or known bony metastases, CPT® 78306 (Nuclear bone scan whole-body), may be approved.
 - Radiopharmaceutical Localization scan SPECT (CPT® 78803 or CPT® 78831) or SPECT/CT (CPT® 78830 or CPT® 78832) may be approved as an add-on test for further evaluation of a specific area of interest with prior positive whole-body scan or documented bone metastasis.
 - CPT® codes 78300 (Nuclear bone scan limited), 78305 (Nuclear bone scan multiple areas) or 78315 do not have any indications in oncology nuclear medicine imaging.
- Octreotide scan:
 - Specific for low and intermediate grade neuroendocrine tumors which express specific cell surface somatostatin receptors. See cancer specific guidelines for recommended use.
 - One of the following codes may be approved when Octreotide scan is requested:
 - CPT® 78802 (Radiopharmaceutical localization of tumor whole-body single day study)
 - CPT® 78804 (Radiopharmaceutical localization of tumor whole-body two or more days)
 - In addition to one of the above CPT codes, CPT® 78803 (Radiopharmaceutical localization of tumor SPECT), SPECT CPT® 78831, or hybrid SPECT/CT (CPT® 78830 or 78832) may be approved as an add-on test for further evaluation of a specific area of interest.
- Bone marrow imaging:
 - This study is rarely performed for evaluation of the entire bone marrow in conditions like myeloproliferative disorders, sickle cell bone infarct or ischemia, avascular necrosis or myeloma

- The correct CPT code for this study is CPT® 78104 (Diagnostic Nuclear Medicine Procedures on the Hematopoietic, Reticuloendothelial and Lymphatic System)
- Brain imaging SPECT with Technetium-99m or thallium-201 (CPT® 78803):
 - Immunocompromised individuals with mass lesion detected on CT or MRI for differentiation between lymphoma and infection
 - In distinguishing recurrent brain tumor from radiation necrosis
- Radiopharmaceutical localization of tumor or distribution of radiopharmaceutical agent(s):
 - CPT® 78800, CPT® 78801, CPT® 78802, CPT® 78804, CPT® 78803, CPT® 78831 (SPECT), or CPT® 78830 or CPT® 78832 (SPECT/CT)
 - For evaluation of fever of unknown origin and osteomyelitis
 - For suspected infections such as infected central lines, grafts or shunts
- Gallium Isotope Scan:
 - Radiopharmaceutical Localization of tumor (CPT® 78800, CPT® 78801, CPT® 78802, CPT® 78803, or CPT® 78804), SPECT CPT® 78831, or hybrid SPECT/CT CPT® 78830 or 78832
 - This may be rarely used in place of PET/CT scan when PET/CT scan not available and PET/CT is indicated by guidelines for lymphoma, sarcoma, melanoma or myeloma

PET Imaging in Oncology (ONC-1.4)

ON.GG.0001.4.U

v2.0.2024

- CPT codes:
 - PET imaging in oncology should use PET/CT fusion (CPT® 78815 or CPT® 78816) Unbundling PET/CT imaging into separate PET and diagnostic CT codes is otherwise not supported.
 - The decision whether to use skull base to mid-femur (“eyes to thighs”) procedure code for PET (CPT® 78812 or CPT® 78815) or whole-body PET (CPT® 78813 or CPT® 78816) is addressed in the diagnosis-specific guideline sections.
 - ”Limited area” protocol is done infrequently, but may be considered, and is reported with PET (CPT® 78811) or for PET/CT (CPT® 78814).
- Radiotracers:
 - Unless specified otherwise, the term “PET” refers to ¹⁸F-FDG-PET and PET/CT fusion studies
 - Indications for PET/CT imaging using non-FDG radiotracers are listed in diagnosis-specific guidelines. The indications may be as follows:
- Supported radiotracers:
 - ¹⁸F-FDG
 - ⁶⁸Gallium DOTATATE (NETSPOT®) for low-grade neuroendocrine tumors and medullary thyroid cancer
 - ⁶⁴Cu-DOTATATE (DETECTNET®) for low-grade neuroendocrine tumors
 - ⁶⁸Ga-DOTA-TOC for low-grade neuroendocrine tumors
 - ¹¹C Choline for prostate cancer
 - ¹⁸F-Fluciclovine (AXUMIN®) for prostate cancer
 - ⁶⁸Ga PSMA-11 for prostate cancer
 - ¹⁸F Piflufolastat (Pylarify®) for prostate cancer
 - ⁶⁸Ga Gozetotide (Illuccix® and Locametz®) for prostate cancer
 - ¹⁸F Flotufolastat (Posluma®) for prostate cancer
 - ¹⁸F Fluoroestradiol (Cerianna®) for breast cancer
- Unsupported radiotracers:
 - ¹⁸F-Na Fluoride PET bone scan
 - PET/CT imaging using isotopes other than those specified above

CPT/ HCPCS Code	Code Description	Brand or common name	Guideline Section and Cancer Type
A9552	¹⁸ F Fluoro deoxyglucose	FDG	Various guideline sections where PET is indicated
A9580	¹⁸ F Sodium fluoride	N/A	ONC-1

CPT/ HCPCS Code	Code Description	Brand or common name	Guideline Section and Cancer Type
A9587	⁶⁸ Ga-68 Dotatate	NETSPOT [®]	ONC-15: Low-grade neuroendocrine tumors, ONC-6: Medullary thyroid cancer
A9515	¹¹ C Choline	N/A	ONC-19, Prostate Cancer
A9588	¹⁸ F-Fluciclovine	AXUMIN [®]	ONC-19, Prostate Cancer
A9593 A9594	⁶⁸ Ga PSMA-11	N/A	ONC-19, Prostate Cancer
A9595	¹⁸ F Piflufolastat	Pylarify [®]	ONC-19, Prostate Cancer
A9596	⁶⁸ Ga Gozetotide	Illuccix [®]	ONC-19, Prostate Cancer
A9800	⁶⁸ Ga Gozetotide	Locametz [®]	ONC-19, Prostate Cancer
A9608	¹⁸ F Flotufolastat	Posluma [®]	ONC-19, Prostate Cancer
A9591	¹⁸ F Fluoroestradiol	Cerianna [®]	ONC-11, Breast Cancer
A9592	⁶⁴ Cu Copper dotatate	Detectnet [®]	ONC-15, Low-grade neuroendocrine tumors
C9067	⁶⁸ Ga Gallium-DOTA-TOC	N/A	ONC-15, Low-grade neuroendocrine tumors

- Unless specified in diagnosis-specific guideline section PET/CT Imaging is NOT indicated for:
 - Infection, inflammation, trauma, post-operative healing, granulomatous disease, rheumatological conditions
 - Concomitantly with separate diagnostic CT studies
 - Conclusive evidence of distant or diffuse metastatic disease on recent conventional imaging studies
 - Metastatic disease in the central nervous system (CNS)
 - Lesions less than 8 mm in size
 - Follow up after localized therapy (i.e. radiofrequency ablation, embolization, stereotactic radiation, etc.)
 - Rare malignancies, due to lack of available evidence regarding the diagnostic accuracy of PET in rare cancers
 - Surveillance
 - Serial monitoring of individuals who are not currently receiving anti-tumor treatment or are receiving maintenance treatment
 - Serial monitoring of FDG avidity until resolution.

- PET/CT avidity in a residual mass at the end of planned therapy is not an indication for PET/CT imaging during surveillance.
- Residual mass that has not changed in size since the last conventional imaging does not justify PET imaging
- Unless otherwise specified for a specific cancer type, once PET has been documented to be negative for a given individual's cancer or all PET-avid disease has been surgically resected, PET should not be used for continued disease monitoring or surveillance.

PET/CT may be indicated if:

- Conventional imaging (CT, MRI or bone scan) reveals findings that are inconclusive or negative, with continued suspicion for recurrence
- The individual is undergoing salvage treatment for a recurrent solid tumor with residual measurable disease on conventional imaging and confirmed repeat negative PET imaging will allow the individual to transition from active treatment to surveillance.
- PET/CT may be considered prior to biopsy in order to determine a more favorable site for biopsy when a prior biopsy was nondiagnostic or a relatively inaccessible site is contemplated which would require invasive surgical intervention for biopsy attempt.

PET/CT for rare malignancies is not covered by eviCore guidelines due to lack of available evidence regarding diagnostic accuracy of PET/CT in the majority of rare cancers. Conventional imaging studies should be used for initial staging and treatment response for these diagnoses. PET/CT can be approved if all of the following apply:

- Conventional imaging (CT, MRI or bone scan) reveals equivocal or suspicious findings
- No other specific metabolic imaging (MIBG, octreotide, technetium, etc.) is appropriate for the disease type
- The submitted clinical information describes a specific decision regarding the individual's care that will be made based on the PET/CT results
- Delay PET/CT for at least 12 weeks after completion of radiation treatment, unless required sooner for imminent surgical resection.
- PET mammography (PEM, generally reported with CPT® 78811) is considered experimental and investigational at this time.

Unlisted Procedure Codes in Oncology (ONC-1.5)

ON.GG.0001.5.U

v2.0.2024

- eviCore does not routinely authorize requests for PET associated with image-directed biopsy or radiation therapy treatment planning.
- There is often no unique procedure code for a service performed solely for treatment planning purposes. AMA instructions in the CPT state that if no specific code exists for a particular service, the service is reported with an unlisted code.
- Advanced imaging being used for radiation therapy treatment planning should not be authorized using any of the diagnostic imaging codes for CT, MRI or PET. In the absence of written payor guidelines, advanced imaging performed in support of radiation therapy treatment planning should be reported with:
 - **CPT® 76498 for Unlisted MRI** – when MRI will be used for treatment planning of radiation therapy to be delivered ONLY to the brain, prostate and cervix. The use of this code for radiation treatment planning of any other cancers/body parts not listed above may be reviewed on a case-by-case basis.
 - **CPT® 76497 for Unlisted CT** – may NOT be used for radiation treatment planning. CT imaging performed in support of radiation therapy treatment planning is bundled in with the concurrent radiation treatment authorization codes and a separate authorization for treatment planning is not required.
 - **CPT® 78999 for Unlisted procedure, nuclear medicine (PET)** – eviCore does not perform prior authorization for this CPT code for any payor. This code may not be reviewed or offered as an alternative recommendation to the provider.
 - Imaging associated with image-directed biopsy should be reported with the corresponding interventional codes. See also: **CT-, MR-, or Ultrasound-Guided Procedures (Preface-4.2)** in the Preface Imaging Guidelines.
 - For advanced imaging used solely for the purpose of Surgical planning, see: **Unlisted Procedures/Therapy treatment planning (Preface-4.3)** in the Preface Imaging Guidelines

Predisposition Syndromes (ONC-1.6)

ON.GG.0001.6.A

v2.0.2024

- For predisposition syndrome screening in adult individuals, see: **Screening Imaging in Cancer Predisposition Syndromes (PEDONC-2)** in the Pediatric Oncology Imaging Guidelines

References (ONC-1)

v2.0.2024

1. ACR Committee on Drugs and Contrast Media. *ACR Manual on Contrast Media, version 10.3*. Reston, VA: American College of Radiology; 2018.
2. The American College of Radiology. *Practice parameter for the performance of skeletal scintigraphy (bone scan)*. Rev. 2017.
3. The American College of Radiology. *Practice parameter for performing FDG-PET/CT in oncology*. Rev. 2016.
4. The American College of Radiology. *Practice parameter for the performance of tumor scintigraphy with gamma cameras*. Rev. 2015.
5. Erdi YE. Limits of tumor detectability in nuclear medicine and PET. *Mol Imaging Radionucl Ther*. 2012;21(1):23-28. doi:10.4274/Mirt.128.
6. Hapani S, Sher A, Chu D, Wu S. Increased risk of serious hemorrhage with bevacizumab in cancer patients: a meta-analysis. *Oncology*. 2010;79(1):27-38. doi:10.1159/000314980.
7. ACR Appropriateness Criteria. *Pretreatment planning of Invasive cancer of Cervix*. Rev. 2015.
8. ACR Appropriateness Criteria. *External Beam Radiation therapy treatment planning for clinically localized prostate cancer*. Rev. 2016.
9. Metcalfe P, Liney GP, Holloway L, et al. The potential for an enhanced role for MRI in radiation-therapy treatment planning. *Technol Cancer Res Treat*. 2013;12(5):429-46. doi:10.7785/tcrt.2012.500342.
10. Daly MB, Pal T, AIHilli Z, et. al. National Comprehensive Cancer Network (NCCN) Guidelines Version 3.2023 – February 13, 2023, Genetic/Familial High Risk Assessment: Breast and Ovarian, available at: http://www.nccn.org/professionals/physician_gls/pdf/genetics_bop.pdf Referenced with permission from the NCCN Clinical Practice Guidelines in Oncology (NCCN Guidelines™) for Genetic/Familial High Risk Assessment: Breast and Ovarian V3.2023 – February 13, 2023 ©2023 National Comprehensive Cancer Network, Inc. All rights reserved. The NCCN Guidelines™ and illustrations herein may not be reproduced in any form for any purpose without the express written permission of the NCCN. To view the most recent and complete version of the NCCN Guidelines™, go online to NCCN.org.
11. Coverage of Clinical Trials under the Patient Protection and Affordable Care Act; 42 U.S.C.A. § 300gg-8.
12. Shah MH, Goldner WS, Benson III AB, et al. National Comprehensive Cancer Network (NCCN) Guidelines Version 2.2022 – December 21, 2022. Neuroendocrine tumors, available at: https://www.nccn.org/professionals/physician_gls/pdf/neuroendocrine.pdf. Referenced with permission from the NCCN Clinical Practice Guidelines in Oncology (NCCN Guidelines™) for Neuroendocrine tumors V2.2022 – December 21, 2022. ©2022 National Comprehensive Cancer Network, Inc. All rights reserved. The NCCN Guidelines™ and illustrations herein may not be reproduced in any form for any purpose without the express written permission of the NCCN. To view the most recent and complete version of the NCCN Guidelines™, go online to NCCN.org.

Primary Central Nervous System Tumors (ONC-2)

Guideline

Primary Central Nervous System Tumors – General Considerations (ONC-2.1)

Low Grade Gliomas (ONC-2.2)

High Grade Gliomas (ONC-2.3)

Medulloblastoma and Supratentorial Primitive Neuroectodermal Tumors (sPNET) (ONC-2.4)

Ependymoma (ONC-2.5)

Central Nervous System Germ Cell Tumors (ONC-2.6)

CNS Lymphoma (also known as Microglioma) (ONC-2.7)

Meningiomas (Intracranial and Intraspinal) (ONC-2.8)

Spinal Cord Tumors (Benign and Malignant) (ONC-2.9)

Choroid Plexus Tumors (ONC-2.10)

References (ONC-2)

Primary Central Nervous System Tumors – General Considerations (ONC-2.1)

ON.CN.0002.1.U

v2.0.2024

- This guideline section applies to primary CNS tumors only. For imaging guidelines in metastatic brain cancer, see the appropriate diagnosis-specific section or **Brain Metastases (ONC-31.3)** for imaging guidelines.
- Primary brain tumors presenting only with uncomplicated headache are very uncommon. Most primary brain tumors present with specific CNS symptoms.
- Histologic confirmation is critical. Therapeutic decisions should not be made on radiographic findings alone, except for ANY of the following:
 - Medically fragile individuals for whom attempted biopsy carries excess medical risk, as stated in writing by both the attending physician and surgeon.
 - Brain stem tumors or other sites where the imaging findings are pathognomonic and the risk of permanent neurological damage is excessive with even a limited biopsy attempt.
- For evaluation of known or suspected spinal cord compromise, see: **Spinal/Vertebral Metastases (ONC-31.6)**
- For suspected brain tumors in neurofibromatosis, see: **Screening Imaging in Cancer Predisposition Syndromes (PEDONC-2)** in the Pediatric Oncology Imaging Guidelines
- Rare tumors occurring more commonly in the pediatric population should be imaged according to the imaging guidelines in: **Pediatric Central Nervous System Tumors (PEDONC-4)** in the Pediatric Oncology Imaging Guidelines

Indication	Imaging Study
Characterization and follow up of all brain tumors	<ul style="list-style-type: none"> • MRI Brain without and with contrast (CPT® 70553) • CT Head without and with contrast (CPT® 70470) can be approved when MRI is contraindicated or not available, or there is skull bone involvement • CT Head (contrast as requested) can be approved for preoperative planning when requested by the operating surgeon
Preoperative planning or to clarify inconclusive findings on MRI or CT	<ul style="list-style-type: none"> • MRA Head (CPT® 70544) or CTA Head (CPT® 70496)

Indication	Imaging Study
Within 24 to 72 hours following brain tumor surgery	<ul style="list-style-type: none"> • MRI Brain without and with contrast (CPT® 70553)
Clinical deterioration or development of new neurological features	<ul style="list-style-type: none"> • MRI Brain without and with contrast (CPT® 70553) • MRI Spine without and with contrast (Cervical-CPT® 72156, Thoracic-CPT® 72157, Lumbar-CPT® 72158) for signs/symptoms of spinal involvement or if spinal involvement is suspected

MR Spectroscopy in Brain Tumors (MRS, CPT® 76390)

- MRS is only supported for use in brain tumors of specified histologies where diagnostic accuracy has been established in peer-reviewed literature
 - See diagnosis-specific guidelines for MRS indications
- MRS is considered investigational/experimental for all other histologies and indications not listed in a diagnosis-specific guideline section.

PET Brain Imaging (CPT® 78608 and CPT® 78609)

- PET Brain Metabolic Imaging (CPT® 78608) is only supported for use in brain tumors of specified histologies where diagnostic accuracy has been established in peer-reviewed literature
 - According to Medicare NCD 220.6.17, FDG-PET may be approved once for initial treatment strategy and three times for subsequent treatment strategy for brain tumors.
- PET Brain metabolic imaging (CPT® 78608) is considered investigational/experimental for all other histologies and indications not listed in a diagnosis-specific guideline section.
- PET Brain perfusion imaging (CPT® 78609) is not indicated in the evaluation or management of primary CNS tumors, and is nationally non-covered by Medicare per NCD 220.6.17.
- Body PET studies (CPT® 78811, CPT® 78812, and CPT® 78813) and fusion PET/CT studies (CPT® 78814, CPT® 78815, or CPT® 78816) are not indicated in the evaluation or management of primary CNS tumors
- See: **Other Imaging Studies (HD-24)** in the Head Imaging Guidelines for details on other advanced neuro-imaging studies

Low Grade Gliomas (ONC-2.2)

ON.CN.0002.2.A
v2.0.2024

- These tumors are defined as having a WHO histologic grade of I or II (out of IV), can occur anywhere in the CNS, and includes the following tumors:
 - Pilocytic Astrocytoma
 - Fibrillary (or Diffuse) Astrocytoma
 - Optic Pathway Gliomas
 - Pilomyxoid Astrocytoma
 - Oligodendroglioma
 - Oligoastrocytoma
 - Oligodendrocytoma
 - Subependymal Giant Cell Astrocytoma (SEGA)
 - Ganglioglioma
 - Gangliocytoma
 - Dysembryoplastic infantile astrocytoma (DIA)
 - Dysembryoplastic infantile ganglioglioma (DIG)
 - Dysembryoplastic neuroepithelial tumor (DNT)
 - Tectal plate gliomas
 - Cervicomedullary gliomas
 - Pleomorphic xanthoastrocytoma (PXA)
 - Any other glial tumor with a WHO grade of I or II

Indication	Imaging Study
Initial Staging	<ul style="list-style-type: none"> • MRI Brain without and with contrast (CPT® 70553) if not already done • MRI Spine without and with contrast (Cervical-CPT® 72156, Thoracic-CPT® 72157, Lumbar-CPT® 72158) <ul style="list-style-type: none"> • MRI Spine with contrast only (Cervical-CPT® 72142, Thoracic-CPT® 72147, Lumbar-CPT® 72149) can be approved if being performed immediately following a contrast-enhanced MRI Brain
After initial resection or other treatment (radiation therapy, etc.)	<ul style="list-style-type: none"> • MRI Brain without and with contrast (CPT® 70553)

Indication	Imaging Study
<p>For individuals undergoing chemotherapy treatment</p>	<ul style="list-style-type: none"> • MRI Brain without and with contrast (CPT® 70553) every 2 cycles • Individuals with spinal cord involvement at diagnosis can have MRI without and with contrast of the involved spinal region on the same schedule as MRI brain
<p><u>ONE of the following:</u></p> <ul style="list-style-type: none"> • Determine need for biopsy when transformation to high-grade glioma is suspected based on clinical symptoms or recent MRI findings • Evaluate a brain lesion of indeterminate nature when the study will be used to determine whether biopsy/resection can be safely postponed 	<p><u>ANY of the following:</u></p> <ul style="list-style-type: none"> • PET Brain Metabolic Imaging (CPT® 78608) • MRI Perfusion imaging (CPT® 70553)
<p><u>ONE of the following:</u></p> <ul style="list-style-type: none"> • Distinguish low-grade from high-grade gliomas • Evaluate a brain lesion of indeterminate nature when the study will be used to determine whether biopsy/resection can be safely postponed • Distinguish radiation-induced tumor necrosis from progressive disease within 18 months of completing radiotherapy 	<p><u>ANY of the following:</u></p> <ul style="list-style-type: none"> • MR Spectroscopy (CPT® 76390) • MRI Perfusion imaging (CPT® 70553)
<p>Suspected intracranial or intraspinal recurrence</p>	<ul style="list-style-type: none"> • All imaging supported for initial staging may be repeated
<p>Surveillance</p>	<ul style="list-style-type: none"> • MRI Brain without and with contrast (CPT® 70553) every 3 months for 2 years, then every 6 months thereafter • Individuals with spinal cord involvement at diagnosis can have MRI Spine without and with contrast (Cervical-CPT® 72156, Thoracic-CPT® 72157, Lumbar-CPT® 72158) on the same schedule as MRI Brain

High Grade Gliomas (ONC-2.3)

ON.CN.0002.3.A
v2.0.2024

- These tumors are defined as having a WHO histologic grade of III or IV (out of IV can occur anywhere in the CNS (though the majority occur in the brain), and include the following tumors:
 - Anaplastic astrocytoma
 - Glioblastoma multiforme
 - Diffuse intrinsic pontine glioma (DIPG, or “brainstem glioma”)
 - Gliomatosis cerebri
 - Gliosarcoma
 - Anaplastic oligodendroglioma
 - Anaplastic ganglioglioma
 - Anaplastic mixed glioma
 - Anaplastic mixed ganglioneuronal tumors
 - Any other glial tumor with a WHO grade of III or IV

Indication	Imaging Study
Initial Staging	<ul style="list-style-type: none"> • MRI Brain without and with contrast (CPT® 70553) if not already done • MRI Spine without and with contrast (Cervical-CPT® 72156, Thoracic-CPT® 72157, Lumbar-CPT® 72158) <ul style="list-style-type: none"> • MRI Spine with contrast only (Cervical-CPT® 72142, Thoracic-CPT® 72147, Lumbar-CPT® 72149) can be approved if being performed immediately following a contrast-enhanced MRI Brain
Immediately following partial or complete resection	<ul style="list-style-type: none"> • MRI Brain without and with contrast (CPT® 70553)
Immediately following radiation therapy (XRT)	<ul style="list-style-type: none"> • MRI Brain without and with contrast (CPT® 70553) once within 2 to 6 weeks following completion of treatment, and then go to surveillance imaging

Indication	Imaging Study
<p>For individuals undergoing chemotherapy treatment</p>	<ul style="list-style-type: none"> • MRI Brain without and with contrast (CPT® 70553) every 2 cycles • Individuals with spinal cord involvement at diagnosis can have MRI without and with contrast of the involved spinal region on the same schedule as MRI Brain
<p><u>ONE of the following:</u></p> <ul style="list-style-type: none"> • Distinguish low-grade from high-grade gliomas • Evaluate a brain lesion of indeterminate nature when the study will be used to determine whether biopsy/resection can be safely postponed • Distinguish radiation-induced tumor necrosis from progressive disease within 18 months of completing radiotherapy 	<p><u>ANY of the following:</u></p> <ul style="list-style-type: none"> • MR Spectroscopy (CPT® 76390) • MRI Perfusion imaging (CPT® 70553)
<p><u>ONE of the following:</u></p> <ul style="list-style-type: none"> • Distinguish radiation-induced tumor necrosis from progressive disease • Evaluate inconclusive MRI findings when the study will be used to determine need for biopsy or change in therapy, including a change from active therapy to surveillance • Evaluate a brain lesion of indeterminate nature when the study will be used to determine whether biopsy/resection can be safely postponed 	<p><u>ANY of the following:</u></p> <ul style="list-style-type: none"> • MRI Perfusion imaging (CPT® 70553) • PET Brain metabolic imaging (CPT® 78608) <ul style="list-style-type: none"> • PET Brain is not indicated in gliomas occurring in the brain stem due to poor uptake and lack of impact on individual outcomes
<p>Suspected intracranial or intraspinal recurrence</p>	<ul style="list-style-type: none"> • All imaging supported for initial staging may be repeated

Indication	Imaging Study
Surveillance	<ul style="list-style-type: none">• MRI Brain without and with contrast (CPT[®] 70553) every 3 months for 3 years and every 6 months thereafter• Individuals with spinal cord involvement at diagnosis can have MRI Spine without and with contrast (Cervical-CPT[®] 72156, Thoracic-CPT[®] 72157, Lumbar-CPT[®] 72158) on the same schedule as MRI Brain

Medulloblastoma and Supratentorial Primitive Neuroectodermal Tumors (sPNET) (ONC-2.4)

ON.CN.0002.4.A

v2.0.2024

- Medulloblastoma and sPNET imaging indications in adult individuals are identical to those for pediatric individuals. See: **Medulloblastoma (MDB), Supratentorial Primitive Neuroectodermal Tumors (sPNET), and Pineoblastoma (PEDONC-4.4)** in the Pediatric Oncology Imaging Guidelines.

Ependymoma (ONC-2.5)

ON.CN.0002.5.A

v2.0.2024

- Ependymoma imaging indications in adult individuals are identical to those for pediatric individuals. See: **Ependymoma (PEDONC-4.8)** in the Pediatric Oncology Imaging Guidelines.

Central Nervous System Germ Cell Tumors (ONC-2.6)

ON.CN.0002.6.A

v2.0.2024

- Central nervous system germ cell tumor imaging indications in adult individuals are identical to those for pediatric individuals. See: **CNS Germinomas and Non-Germinomatous Germ Cell Tumors (NGGCT) (PEDONC-4.7)** in the Pediatric Oncology Imaging Guidelines.

CNS Lymphoma (also known as Microglioma) (ONC-2.7)

ON.CN.0002.7.A

v2.0.2024

Indication	Imaging Study
Initial Staging	<p><u>ALL of the following are indicated:</u></p> <ul style="list-style-type: none"> • MRI Brain without and with contrast (CPT® 70553) • MRI Cervical Spine without and with contrast (CPT® 72156) • MRI Thoracic Spine without and with contrast (CPT® 72157) • MRI Lumbar Spine without and with contrast (CPT® 72158)
<p>Extra-neural evaluation to confirm CNS primary</p> <p>*Individuals with CNS Lymphoma that is metastatic should be imaged according to:</p> <ul style="list-style-type: none"> • <u>Non-Hodgkin Lymphomas (ONC-27)</u> for individuals age ≥18 years • <u>Pediatric Aggressive Mature B-Cell Non-Hodgkin Lymphomas (NHL) (PEDONC-5.3)</u> in the Pediatric Oncology Imaging Guidelines for individuals age ≤17 years 	<p><u>ANY or ALL of the following are indicated:</u></p> <ul style="list-style-type: none"> • CT Chest with contrast (CPT® 71260) • CT Abdomen and Pelvis with contrast (CPT® 74177) • PET/CT (CPT® 78815) can be approved for evaluation of inconclusive findings on CT imaging
Treatment Response	<ul style="list-style-type: none"> • MRI without and with contrast of all positive disease sites every 2 cycles
Suspected intracranial or intraspinal recurrence	<ul style="list-style-type: none"> • All imaging supported for initial staging may be repeated
Surveillance	<ul style="list-style-type: none"> • MRI without and with contrast of all positive disease sites every 3 months for 2 years, then every 6 months for 3 years, then annually thereafter

Meningiomas (Intracranial and Intraspinal) (ONC-2.8)

ON.CN.0002.8.A

v2.0.2024

Indication	Imaging Study
Initial Staging of Intracranial Meningioma	<p><u>ANY</u> or <u>ALL</u> of the following are indicated:</p> <ul style="list-style-type: none"> • MRI Brain without and with contrast (CPT® 70553) • CT Head (contrast as requested)
Initial staging of Intraspinal Meningioma	<p><u>ONE</u> of the following:</p> <ul style="list-style-type: none"> • MRI without and with contrast of appropriate spinal region (Cervical CPT® 72156, Thoracic CPT® 72157, and Lumbar CPT® 72158) <p>OR</p> <ul style="list-style-type: none"> • CT without and with contrast of the appropriate spinal region (Cervical CPT® 72127, Thoracic CPT® 72130, and Lumbar CPT® 72133)
Treatment Response	<ul style="list-style-type: none"> • MRI without and with contrast of all positive disease sites every 2 cycles
Suspected recurrence of intracranial or intraspinal recurrence	<ul style="list-style-type: none"> • All imaging supported for initial staging may be repeated
Suspected recurrence with inconclusive findings on MRI	<p>Any <u>ONE</u> of the following studies:</p> <ul style="list-style-type: none"> • Octreotide SPECT Brain (CPT® 78803) • Octreotide SPECT/CT Brain (CPT® 78830) • Dotatate PET/CT Brain (CPT® 78814)
<p>Surveillance for Grade I (low-grade) and Grade II (atypical) intracranial meningioma</p> <p>(completely resected, partially resected, and unresected)</p>	<ul style="list-style-type: none"> • MRI Brain without and with contrast (CPT® 70553) at 3, 6, and 12 months, then annually for 5 years • Imaging beyond 5 years is only indicated for evaluation of new signs or symptoms

Indication	Imaging Study
<p>Surveillance for Grade I (low-grade) and Grade II (atypical) intraspinal meningioma (completely resected, partially resected, and unresected)</p>	<p><u>ONE of the following at 3, 6, and 12 months, and then annually for 5 years:</u></p> <ul style="list-style-type: none"> • MRI without and with contrast (CPT® 72156 [Cervical spine], CPT® 72157 [Thoracic spine], CPT® 72158 [Lumbar spine]) of the involved spinal level <p>OR</p> <ul style="list-style-type: none"> • CT without and with contrast (CPT® 72127 [Cervical spine], CPT® 72130 [Thoracic spine], CPT® 72133 [Lumbar spine]) of the involved spinal level • Imaging beyond 5 years is only indicated for evaluation of new signs or symptoms
<p>Surveillance for Grade III (malignant or anaplastic) Meningioma</p>	<ul style="list-style-type: none"> • <u>Intracranial Meningioma:</u> MRI Brain without and with contrast (CPT® 70553) every 3 months for 3 years, and then every 6 months thereafter • <u>Intraspinal Meningioma:</u> MRI or CT without and with contrast of the involved spinal region every 3 months for 3 years and then every 6 months thereafter

Spinal Cord Tumors (Benign and Malignant) (ONC-2.9)

ON.CN.0002.9.A

v2.0.2024

- See: **Low Grade Gliomas (ONC-2.2)** and **High Grade Gliomas (ONC-2.3)** for imaging guidelines of low-grade and high-grade gliomas of the spinal cord
- See: **Malignant Tumors of the Spinal Cord (PEDONC-4.9)** in the Pediatric Oncology Imaging Guidelines for other malignant spinal cord tumors
- See: **Neurofibromatosis 1 and 2 (NF1 and NF2) (PEDONC-2.3)** in the Pediatric Oncology Imaging Guidelines for spinal tumors in individuals with Neurofibromatosis 1 or 2
- See: **Spinal/Vertebral Metastases (ONC-31.6)** for known secondary malignancy involving the spine/spinal canal/spinal cord

Choroid Plexus Tumors (ONC-2.10)

ON.CN.0002.10.A

v2.0.2024

- Choroid Plexus Tumor imaging indications in adult individuals are identical to those for pediatric individuals. See: **Choroid Plexus Tumors (PEDONC-4.13)** in the Pediatric Oncology Imaging Guidelines.

References (ONC-2)

v2.0.2024

1. Nabors LB, Portnow J, Baehring J, et al. National Comprehensive Cancer Network (NCCN) Guidelines Version 1.2023 – March 24, 2023 Central Nervous System Cancers, available at: https://www.nccn.org/professionals/physician_gls/pdf/cns.pdf. Referenced with permission from the NCCN Clinical Practice Guidelines in Oncology (NCCN Guidelines™) for Central Nervous System Tumors Cancer V1.2023. – March 24, 2023 ©2023 National Comprehensive Cancer Network, Inc. All rights reserved. The NCCN Guidelines™ and illustrations herein may not be reproduced in any form for any purpose without the express written permission of the NCCN. To view the most recent and complete version of the NCCN Guidelines™, go online to NCCN.org.
2. Brandão LA, Castillo M. Adult brain tumors: clinical applications of magnetic resonance spectroscopy. *Magn Reson Imaging Clin N Am*. 2016;24(4):781-809. doi:10.1016/j.mric.2016.07.005.
3. Pasquier D, Bijmolt S, Veninga T, et al. Atypical and malignant meningioma: outcome and prognostic factors in 119 irradiated patients. A multicenter, retrospective study of the Rare Cancer Network. *Int J Radiat Oncol Biol Phys*. 2008;71(5):1388. doi:10.1016/j.ijrobp.2007.12.020.
4. Modha A, Gutin PH. Diagnosis and treatment of atypical and anaplastic meningiomas: a review. *Neurosurgery*. 2005;57(3):538-550.
5. Horská A, Barker PB. Imaging of brain tumors: MR spectroscopy and metabolic imaging. *Neuroimaging Clin N Am*. 2010;20(3):293-310. doi:10.1016/j.nic.2010.04.003.
6. Sundgren PC. MR Spectroscopy in radiation Injury. *Am J Neuroradiol*. 2009;30(8):1469-1476. doi:10.3174/ajnr.A1580.
7. American College of Radiology. ACR–ASNR–SPR practice parameter for the performance of intracranial magnetic resonance perfusion imaging. 2017; Available at: <https://www.acr.org/-/media/ACR/Files/Practice-Parameters/MR-Perfusion.pdf?la=en>.

Squamous Cell Carcinomas of the Head and Neck (ONC-3)

Guideline

Squamous Cell Carcinomas of the Head and Neck – General Considerations (ONC-3.0)

Squamous Cell Carcinomas of the Head and Neck – Suspected/Diagnosis (ONC-3.1)

Squamous Cell Carcinomas of the Head and Neck – Initial Work-up/Staging (ONC-3.2)

Squamous Cell Carcinomas of the Head and Neck – Restaging/Recurrence (ONC-3.3)

Squamous Cell Carcinomas of the Head and Neck – Surveillance/Follow-up (ONC-3.4)

References (ONC-3)

Squamous Cell Carcinomas of the Head and Neck – General Considerations (ONC-3.0)

ON.HN.0003.0.A
v2.0.2024

- Individuals with esthesioneuroblastoma should be imaged according to this guideline section
- Stage III/IV disease encompasses any primary tumor larger than 4 cm or documented lymph node positive disease

Squamous Cell Carcinomas of the Head and Neck – Suspected/Diagnosis (ONC-3.1)

ON.HN.0003.1.A
v2.0.2024

- See: **Neck Masses - Imaging (NECK-5.1)** in the Neck Imaging Guidelines for evaluation of suspected malignancy in the neck
- PET may be considered prior to biopsy in order to determine a more favorable site for biopsy when:
 - A prior biopsy was nondiagnostic or
 - A relatively inaccessible site is contemplated which would require invasive surgical intervention for biopsy attempt

Squamous Cell Carcinomas of the Head and Neck – Initial Work-up/Staging (ONC-3.2)

ON.HN.0003.2.A
v2.0.2024

Indication	Imaging Study
All Stages of Disease	<ul style="list-style-type: none"> • CT Neck with contrast (CPT® 70491) or MRI Orbits/Face/Neck (OFN) without and with contrast (CPT® 70543) • CT Chest with contrast (CPT® 71260)
For sentinel lymph node evaluation when nodes are not clinically positive	<ul style="list-style-type: none"> • Lymph system imaging (lymphoscintigraphy, CPT® 78195) <ul style="list-style-type: none"> • SPECT/CT (CPT® 78830) is indicated as an add on code if requested
Nasal cavity and paranasal sinuses (bony erosion or skull base and intracranial involvement)	<p><u>ONE of the following studies is indicated:</u></p> <ul style="list-style-type: none"> • CT Maxillofacial with contrast (CPT® 70487) • CT Neck with contrast (CPT® 70491) • MRI Orbits/Face/Neck without and with contrast (CPT® 70543)
Nasopharyngeal (NPC) Cancer	<ul style="list-style-type: none"> • PET/CT (CPT® 78815) • MRI Orbits/Face/Neck without and with contrast (CPT® 70543) is the preferred study <ul style="list-style-type: none"> • CT Neck (CPT® 70491) and/or CT Maxillofacial (CPT® 70487) with contrast can be approved if contraindication to MRI • CT Chest with contrast (CPT® 71260)

Indication	Imaging Study
<p><u>For ANY of the following:</u></p> <ul style="list-style-type: none">• Known stage III or IV disease• Prior to start of primary chemoradiotherapy and have not undergone definitive surgical resection• Inconclusive findings on conventional imaging (CT, MRI)• In order to direct laryngoscopy/exam under anesthesia for biopsy• Pulmonary nodule(s) ≥8 mm in size• Cervical lymph node biopsy positive for squamous cell carcinoma and no primary site identified on CT or MRI Neck and Chest• Inconclusive findings suggestive of disease outside the head and neck area	<ul style="list-style-type: none">• PET/CT (CPT® 78815)
<p>Signs or symptoms of abdominal metastatic disease, including elevated liver function tests</p>	<ul style="list-style-type: none">• CT Abdomen with contrast (CPT® 74160)
<p>Any head and neck cancer with neurological findings or suspicion of skull base invasion</p>	<ul style="list-style-type: none">• MRI Brain without and with contrast (CPT® 70553)

Squamous Cell Carcinomas of the Head and Neck – Restaging/Recurrence (ONC-3.3)

ON.HN.0003.3.A
v2.0.2024

Indication	Imaging Study
Following complete resection and/or radical neck dissection	See: Surveillance/Follow-up (ONC-3.4)
Following primary chemoradiotherapy or radiation therapy in individuals who have not undergone surgical resection of primary tumor or neck dissection	<p><u>ONE of the following:</u></p> <ul style="list-style-type: none"> • CT Neck with contrast (CPT® 70491); or • MRI Orbits/Face/Neck without and with contrast (CPT® 70543); or • PET/CT (CPT® 78815) no sooner than 12 weeks (3 months) post completion of radiation therapy <ul style="list-style-type: none"> • If post-treatment PET/CT scan is negative, further surveillance imaging is not routinely indicated.
Induction chemotherapy response	<ul style="list-style-type: none"> • CT Neck with contrast (CPT® 70491) or MRI Orbits/Face/Neck without and with contrast (CPT® 70543) • PET not indicated to assess response to induction chemotherapy
Measurable or metastatic disease undergoing active treatment	<p><u>Every 2 cycles (6-8 weeks):</u></p> <ul style="list-style-type: none"> • CT Neck with contrast (CPT® 70491) <p>OR</p> <ul style="list-style-type: none"> • MRI Orbits/ Face/Neck without and with contrast (CPT® 70543) <p>AND</p> <ul style="list-style-type: none"> • CT with contrast of involved body sites
Suspected local recurrence	<ul style="list-style-type: none"> • CT Neck with contrast (CPT® 70491) or MRI Orbits/Face/Neck without and with contrast (CPT® 70543) • CT Chest with contrast (CPT® 71260)

Indication	Imaging Study
Biopsy proven local recurrence	<u>ONE of the following:</u> <ul style="list-style-type: none"><li data-bbox="651 310 1008 342">• PET/CT (CPT® 78815) or <ul style="list-style-type: none"><li data-bbox="651 394 1409 499">• CT Neck with contrast (CPT® 70491) or MRI Orbits/Face/Neck without and with contrast (CPT® 70543) and CT Chest with contrast (CPT® 71260)
Inconclusive conventional imaging (CT or MRI)	<ul style="list-style-type: none"><li data-bbox="651 527 1008 558">• PET/CT (CPT® 78815)
If new pulmonary symptoms or chest previously involved	<ul style="list-style-type: none"><li data-bbox="651 617 1219 648">• CT Chest with contrast (CPT® 71260)

Squamous Cell Carcinomas of the Head and Neck – Surveillance/Follow-up (ONC-3.4)

ON.HN.0003.4.A
v2.0.2024

Indications	Imaging Study
Individuals treated with surgical resection of primary site and/or neck dissection (with or without postoperative radiation therapy)	<p><u>Once within 6 months of completing all treatment:</u></p> <ul style="list-style-type: none"> • CT Neck with contrast (CPT® 70491) or MRI Orbits/Face/Neck without and with contrast (CPT® 70543) • CT with contrast of any other involved body area
Individuals treated with definitive radiation therapy or combined chemoradiation, and post-treatment imaging is negative	Further surveillance imaging is not routinely indicated
If post-treatment imaging shows residual abnormalities	<p><u>ONE of the following, once within 6 months of prior imaging:</u></p> <ul style="list-style-type: none"> • CT Neck with contrast (CPT® 70491) OR • MRI Orbits/Face/Neck without and with contrast (CPT® 70543)
<p><u>After initial post-treatment study, for ANY of the following:</u></p> <ul style="list-style-type: none"> • Nasopharyngeal primary site • Physical exam unable to visualize deep-seated primary site 	<p><u>Annually for 3 years:</u></p> <ul style="list-style-type: none"> • CT Neck with contrast (CPT® 70491) or MRI Orbits/Face/Neck without and with contrast (CPT® 70543)
<ul style="list-style-type: none"> • CT Chest is not indicated for surveillance. Individuals with smoking history may undergo annual low dose CT cancer screening if criteria are met (See: Lung Cancer Screening (CH-33) in the Chest Imaging Guidelines) 	

References (ONC-3)

v2.0.2024

1. Pfister DG, Spencer S, Adkins D, et al. National Comprehensive Cancer Network (NCCN) Guidelines Version 3.2024 – February 29, 2024 Head and Neck Cancers, available at: https://www.nccn.org/professionals/physician_gls/pdf/head-and-neck.pdf. Referenced with permission from the NCCN Clinical Practice Guidelines in Oncology (NCCN Guidelines™) for Head and Neck Cancer V3.2024 – February 29, 2024 ©2024 National Comprehensive Cancer Network, Inc. All rights reserved. The NCCN Guidelines™ and illustrations herein may not be reproduced in any form for any purpose without the express written permission of the NCCN. To view the most recent and complete version of the NCCN Guidelines™, go online to NCCN.org.
2. Goel R, Moore W, Sumer B, Khan S, Sher D, Subramaniam RM. Clinical practice in PET/CT for the management of head and neck squamous cell cancer. *AJR Am J Roentgenol.* 2017;209(2):289-303. doi:10.2214/AJR.17.18301.
3. Moncrieff M, Pywell S, Snelling A, et. al. Effectiveness of SPECT/CT imaging for sentinel node biopsy staging of primary cutaneous melanoma and patient outcomes. *Ann Surg Oncol.* 2022;29(2):767-775. doi:10.1245/s10434-021-10911-4.
4. Quartuccio N, Garau LM, Arnone A, et. al. Comparison of 99mTc-labeled colloid SPECT/CT and planar lymphoscintigraphy in sentinel lymph node detection in patients with melanoma: a meta-analysis. *J Clin Med.* 2020;9(6):1680. doi:10.3390/jcm9061680.
5. Bennie G, Vorster M, Buscombe J, Sathekge M. The added value of a single-photon emission computed tomography-computed in sentinel lymph node mapping in patients with breast cancer and malignant melanoma. *World J Nucl Med.* 2015;14(01):41-46. doi:10.4103/1450-1147.150543.

Salivary Gland Cancers (ONC-4)

Guideline

Salivary Gland Cancers – General Considerations (ONC-4.0)

Salivary Gland Cancers – Suspected/Diagnosis (ONC-4.1)

Salivary Gland Cancers – Initial Work-up/Staging (ONC-4.2)

Salivary Gland Cancers – Restaging/Recurrence (ONC-4.3)

Salivary Gland Cancers – Surveillance/Follow-up (ONC-4.4)

References (ONC-4)

Salivary Gland Cancers – General Considerations (ONC-4.0)

ON.SG.0004.0.A

v2.0.2024

- Salivary gland tumors may originate within the parotid, submandibular, sublingual or minor salivary glands in the mouth.
- Histological subtypes include:
 - Mucoepidermoid
 - Acinic
 - Adenocarcinoma
 - Adenoid cystic carcinoma
 - Malignant myoepithelial tumors
 - Squamous cell carcinoma
 - Lymphoma and metastatic squamous carcinoma can occur in the parotid gland
- Over 80% of parotid gland tumors are benign. A bilateral parotid tumor is most likely Warthin's tumor.
- The role of PET in salivary gland tumors is considered experimental, investigational, or unproven.

Salivary Gland Cancers – Suspected/Diagnosis (ONC-4.1)

ON.SG.0004.1.A

v2.0.2024

- See: **Salivary Gland Disorders (NECK-11)** and **Neck Masses – Imaging (NECK-5.1)** in the Neck Imaging Guidelines for evaluation of salivary gland masses, salivary gland stones and neck masses.

Salivary Gland Cancers – Initial Work-up/Staging (ONC-4.2)

ON.SG.0004.2.A
v2.0.2024

Indication	Imaging Study
Biopsy-proven malignancy	<u>ONE of the following can be approved:</u> <ul style="list-style-type: none">• MRI Orbits/Face/Neck without and with contrast (CPT® 70543)• CT Neck with contrast (CPT® 70491)• CT Neck without contrast (CPT® 70490)
Skull base invasion	<ul style="list-style-type: none">• MRI Brain without and with contrast (CPT® 70553)
<ul style="list-style-type: none">• Adenoid cystic carcinoma• Lymphadenopathy in the neck• Pulmonary signs or symptoms• Abnormal chest x-ray	<ul style="list-style-type: none">• CT Chest with contrast (CPT® 71260)

Salivary Gland Cancers – Restaging/Recurrence (ONC-4.3)

ON.SG.0004.3.A

v2.0.2024

Indication	Imaging Study
After complete surgical resection	See: Salivary Gland Cancers - Surveillance (ONC-4.4)
Individuals with unresected disease receiving systemic therapy (chemotherapy)	<p><u>ONE of the following may be approved every 2 cycles:</u></p> <ul style="list-style-type: none"> • CT Neck with contrast (CPT® 70491) and any other sites of disease • MRI Orbits/Face/Neck without and with contrast (CPT® 70543) and any other sites of disease
Recurrence or progression suspected based on new or worsening signs or symptoms	<p><u>ONE of the following may be approved:</u></p> <ul style="list-style-type: none"> • CT Neck with contrast (CPT® 70491) • MRI Orbits/Face/Neck without and with contrast (CPT® 70543) <p><u>In addition, for all individuals:</u></p> <ul style="list-style-type: none"> • CT Chest with contrast (CPT® 71260)
All other individuals	<ul style="list-style-type: none"> • No routine advanced imaging indicated

Salivary Gland Cancers – Surveillance/ Follow-up (ONC-4.4)

ON.SG.0004.4.A

v2.0.2024

Indication	Imaging Study
Total surgical resection	<ul style="list-style-type: none">No routine advanced imaging indicated
Unresectable or partially resected disease, including those treated with radiation therapy	<ul style="list-style-type: none">Either CT Neck with contrast (CPT® 70491) or MRI Orbits/Face/Neck without and with contrast (CPT® 70543) once within 6 months of completion of treatment
Adenoid cystic carcinoma	<p><u>ANY of the following, annually for up to 10 years:</u></p> <ul style="list-style-type: none">CT Neck with contrast (CPT® 70491) or MRI Orbits/Face/Neck without and with contrast (CPT® 70543)CT Chest with contrast (CPT® 71260) or CT Chest without contrast (CPT® 71250)

References (ONC-4)

v2.0.2024

1. Pfister DG, Spencer S, Adkins D et al. National Comprehensive Cancer Network (NCCN) Guidelines Version 2.2023 – May 15, 2023 Head and Neck Cancers, available at: https://www.nccn.org/professionals/physician_gls/pdf/head-and-neck.pdf. Referenced with permission from the NCCN Clinical Practice Guidelines in Oncology (NCCN Guidelines™) for Head and Neck Cancer V2.2023 – May 15, 2023. ©2023 National Comprehensive Cancer Network, Inc. All rights reserved. The NCCN Guidelines™ and illustrations herein may not be reproduced in any form for any purpose without the express written permission of the NCCN. To view the most recent and complete version of the NCCN Guidelines™, go online to NCCN.org.
2. Palacios E, Ellis M, Lam EC, Neitzschman H, Haile M. Pitfalls in imaging the submandibular glands with PET/CT. *Ear Nose Throat J.* 2015;94(10-11):E37-E39.
3. Seo YL, Yoon DY, Baek S, et al. Incidental focal FDG uptake in the parotid glands on PET/CT in patients with head and neck malignancy. *Eur Radiol.* 2015;25(1):171-177. doi:10.1007/s00330-0140339701.
4. Park HL, Yoo le R, Lee N, et al. The value of F-18 FDG PET for planning treatment and detecting recurrence in malignant salivary gland tumors: comparison with conventional imaging studies. *Nucl Med Mol Imaging.* 2013;47(4):242-248. doi:10.1007/s13139-013-0222-8.
5. Bertagna F, Nicolai P, Maroldi R. Diagnostic role of 18F-FDG-PET or PET/CT in salivary gland tumors: a systematic review. *Rev Esp Med Nucl Imagen Mol.* 2015;34(5):295-302.
6. Garg M, Tudor-Green B, Bisase B. Current thinking in the management of adenoid cystic carcinoma of the head and neck. *British Journal of Oral and Maxillofacial Surgery.* 2019;57(8):716-721. doi:10.1016/j.bjoms.2019.07.021.
7. Geiger JL, Ismaila N, Beadle B, et al. Management of salivary gland malignancy: ASCO guideline. *Journal of Clinical Oncology.* 2021;39(17):1909-1941. doi:10.1200/JCO.21.00449.

Melanomas and Other Skin Cancers (ONC-5)

Guideline

- Melanoma – General Considerations (ONC-5.0)
- Melanoma – Suspected/Diagnosis (ONC-5.1)
- Melanoma – Initial Work-up/Staging (ONC-5.2)
- Melanoma – Restaging/Recurrence (ONC-5.3)
- Melanoma – Surveillance/Follow-up (ONC-5.4)
- Non-Melanoma Skin Cancers – General Considerations (ONC-5.5)
- Non-Melanoma Skin Cancers – Initial Work-up/Staging (ONC-5.6)
- Non-Melanoma Skin Cancers – Restaging/Recurrence (ONC-5.7)
- Non-Melanoma Skin Cancers – Surveillance/Follow-up (ONC-5.8)
- Ocular Melanoma (ONC-5.9)
- References (ONC-5)

Melanoma – General Considerations (ONC-5.0)

ON.SC.0005.0.A

v2.0.2024

- Melanomas can metastasize in an unpredictable fashion.

Melanoma – Suspected/Diagnosis (ONC-5.1)

ON.SC.0005.1.A

v2.0.2024

Indication	Imaging Study
All	<ul style="list-style-type: none">Imaging is not indicated until histologic diagnosis is confirmed

Melanoma – Initial Work-up/Staging (ONC-5.2)

ON.SC.0005.2.A

v2.0.2024

Indication	Imaging Study
Stage 0 or IA (in situ or disease <1 mm)	<ul style="list-style-type: none"> Routine advanced imaging is not indicated
<ul style="list-style-type: none"> Stage IB (<0.8 mm with ulceration or 0.8-1 mm without or with ulceration) Stage II (lesions >1 mm thick, but node negative) 	<ul style="list-style-type: none"> CT with contrast or MRI without and with contrast of specific areas, only if signs or symptoms indicate need for further evaluation
For sentinel lymph node evaluation in stages IB and II	<ul style="list-style-type: none"> Lymph system imaging (lymphoscintigraphy, CPT® 78195) <ul style="list-style-type: none"> SPECT/CT (CPT® 78830) is indicated as an add on code if requested
<p><u>Any of the following:</u></p> <ul style="list-style-type: none"> Stage III (sentinel node positive, palpable regional nodes) Stage IV (metastatic) 	<ul style="list-style-type: none"> PET/CT (CPT® 78815 or CPT® 78816) <p>OR</p> <ul style="list-style-type: none"> CT Chest with contrast (CPT® 71260) and CT Abdomen and Pelvis with contrast (CPT® 74177) MRI Brain without and with contrast (CPT® 70553)
<ul style="list-style-type: none"> Head or neck primary site Palpable lymphadenopathy in the neck Mucosal melanoma of the head or neck region 	<p>In addition to above initial staging imaging, if PET/CT not performed:</p> <ul style="list-style-type: none"> CT Neck with contrast (CPT® 70491)
<ul style="list-style-type: none"> Primary site of melanoma is unknown and CT Chest, Abdomen, and Pelvis are negative 	<ul style="list-style-type: none"> PET/CT (CPT® 78815 or CPT® 78816)

Melanoma – Restaging/Recurrence (ONC-5.3)

ON.SC.0005.3.A

v2.0.2024

- All recurrences should be confirmed histologically, except when excessive morbidity from a biopsy may occur, such as a biopsy requiring craniotomy.

Indication	Imaging Study
Individuals receiving chemotherapy, with measurable disease, every 2 cycles (commonly every 6 to 8 weeks)	<ul style="list-style-type: none"> • CT Chest with contrast (CPT® 71260); and CT Abdomen and Pelvis with contrast (CPT® 74177)
All in situ recurrences	<ul style="list-style-type: none"> • Restaging imaging is not needed after adequate aggressive local therapy (See Surveillance below)
<u>Documented or clinically suspected (See top of page regarding biopsy morbidity) recurrence at:</u> <ul style="list-style-type: none"> • Primary site • In-transit disease • Regional lymph nodes • Metastatic site 	<ul style="list-style-type: none"> • CT Chest with contrast (CPT® 71260); and CT Abdomen and Pelvis with contrast (CPT® 74177) <p><u>In addition, for all individuals:</u></p> <ul style="list-style-type: none"> • MRI Brain without and with contrast (CPT® 70553)
<u>ANY of the following:</u> <ul style="list-style-type: none"> • Inconclusive findings on conventional imaging • Isolated metastatic site found on conventional imaging 	<ul style="list-style-type: none"> • PET/CT (CPT® 78815 or CPT® 78816)
<u>Brain imaging is indicated for:</u> <ul style="list-style-type: none"> • New discovery of metastatic disease or progression of metastatic disease • Signs or symptoms of CNS disease • If considering Interleukin (IL-2) therapy 	<ul style="list-style-type: none"> • MRI Brain without and with contrast (CPT® 70553)

Melanoma – Surveillance/Follow-up (ONC-5.4)

ON.SC.0005.4.A

v2.0.2024

Indication	Imaging Study
Stage 0, IA, IB and IIA Melanomas	<ul style="list-style-type: none"> No routine advanced imaging indicated
Stage IIB, IIC, IIIA and IIIB Melanomas	<ul style="list-style-type: none"> CT Chest (CPT® 71260) and CT Abdomen and Pelvis (CPT® 74177) with contrast every 6 months for 2 years, then annually for 3 years For melanoma arising from extremities, advanced imaging of the primary site is not routinely indicated for surveillance in asymptomatic individuals.
Stage IIIC and IV Melanomas	<ul style="list-style-type: none"> CT Chest (CPT® 71260) and CT Abdomen and Pelvis (CPT® 74177) with contrast every 3 months for 2 years, then every 6 months for 3 years MRI Brain without and with contrast (CPT® 70553) annually for 3 years For melanoma arising from extremities, advanced imaging of the primary site is not routinely indicated for surveillance in asymptomatic individuals.
Mucosal Melanoma of the head or neck region	<p>In addition to above stage-based surveillance imaging, the following may be obtained ONCE within 6 months of completing all treatment:</p> <ul style="list-style-type: none"> CT Neck with contrast (CPT® 70491) or MRI Orbits/Face/Neck without and with contrast (CPT® 70543) CT with contrast of any other involved body area
Liver metastases treated with focal therapy	<ul style="list-style-type: none"> See: <u>Liver Metastases (ONC-31.2)</u>

Non-Melanoma Skin Cancers – General Considerations (ONC-5.5)

ON.SC.0005.5.A

v2.0.2024

- Advanced imaging is generally not indicated for basal cell and squamous cell skin cancers
- PET/CT scan is not indicated for evaluation of non-melanoma skin cancers unless specified within the guidelines below (e.g. Merkel cell carcinoma)
- Merkel cell carcinoma is an unusual skin cancer with neuroendocrine-like histologic features, which has a high propensity (25% to 33%) for regional lymph node spread and occasionally, metastatic spread to lungs.
- Merkel cell carcinoma may present as a primary cancer or as a skin metastasis from a non-cutaneous primary neuroendocrine carcinoma (i.e., small cell lung cancer), therefore conventional imaging is indicated initially to confirm the absence of metastasis prior to considering PET scan.

Non-Melanoma Skin Cancers – Initial Work-up/Staging (ONC-5.6)

ON.SC.0005.6.A

v2.0.2024

Indication	Imaging Study
Body area with unexplained signs or symptoms	<ul style="list-style-type: none"> CT with contrast of that body area
Perineural invasion or local regional extension (i.e. bone; deep soft tissue) involvement	<p><u>ONE of the following may be approved of the primary site:</u></p> <ul style="list-style-type: none"> MRI without contrast or without and with contrast CT (contrast as requested)
Skin lesion may be a dermal metastasis from distant primary	<ul style="list-style-type: none"> CT Chest (CPT® 71260) and CT Abdomen and Pelvis (CPT® 74177) with contrast PET/CT (CPT® 78815 or CPT® 78816) is indicated if conventional imaging (CT or MRI) is unable to identify a primary site
Squamous cell carcinoma head or neck skin with regional lymphadenopathy	<ul style="list-style-type: none"> CT Neck (CPT® 70491) and CT Chest (CPT® 71260) with contrast
Merkel Cell carcinoma	<ul style="list-style-type: none"> CT Chest with contrast (CPT® 71260) and CT Abdomen and Pelvis with contrast (CPT® 74177) CT with contrast of other involved body area(s) PET/CT (CPT® 78815 or CPT® 78816) if inconclusive conventional imaging Lymph system imaging (lymphoscintigraphy, CPT® 78195) for sentinel lymph node evaluation <ul style="list-style-type: none"> SPECT/CT (CPT® 78830) is indicated as an add on code if requested
Signs or symptoms of CNS involvement	<ul style="list-style-type: none"> MRI Brain with and without contrast (CPT® 70553)

Non-Melanoma Skin Cancers – Restaging/Recurrence (ONC-5.7)

ON.SC.0005.7.A

v2.0.2024

- All recurrences should be confirmed histologically, except when excessive morbidity from a biopsy may occur, such as a biopsy requiring craniotomy.

Indication	Imaging Study
Recurrence where planned therapy is more extensive than simple wide local excision	<ul style="list-style-type: none">• CT with contrast of the primary and recurrent site(s)
Suspected or biopsy-proven recurrence of Merkel cell carcinoma	<ul style="list-style-type: none">• CT Chest (CPT® 71260) and CT Abdomen and Pelvis (CPT® 74177) with contrast• CT with contrast of other symptomatic body area(s)
Inconclusive findings on conventional imaging	<ul style="list-style-type: none">• PET/CT (CPT® 78815 or 78816)
Signs or symptoms of CNS involvement	<ul style="list-style-type: none">• MRI Brain without and with contrast (CPT® 70553)

Non-Melanoma Skin Cancers – Surveillance/Follow-up (ONC-5.8)

ON.SC.0005.8.A

v2.0.2024

Indication	Imaging Study
Merkel cell cancer – only if node positive	<ul style="list-style-type: none">• CT Chest (CPT® 71260) and CT Abdomen and Pelvis (CPT® 74177) with contrast every 6 months for 5 years• Add CT Neck with contrast (CPT® 70491) if known prior neck disease or scalp/facial/neck disease
All others	<ul style="list-style-type: none">• Routine advanced imaging for surveillance is not indicated• Imaging indicated only for signs and symptoms of recurrent disease

Ocular Melanoma (ONC-5.9)

ON.SC.0005.9.A
v2.0.2024

General Considerations

- Approximately 95% of ocular melanomas arise from the uvea (iris, ciliary body and choroid) and 5% arise from the conjunctiva or orbit.
- Biopsy is usually not necessary for initial diagnosis of uveal melanoma but may be useful in cases when diagnosis is uncertain (e.g. amelanotic tumors, retinal detachment) or for prognostic analysis and risk stratification.
- Treatment is directed to the affected eye with systemic therapy reserved only for known metastatic disease.
- The most common site of metastatic disease is the liver.
- Surveillance of the affected eye is with clinical examination only; advanced imaging is supported for surveillance of systemic metastatic disease based on individual risk factors. See risk categories below for surveillance recommendations.

Ocular Melanoma Risk Categories

Low Risk	Medium Risk	High-Risk
T1	T2 and T3	T4
Class IA	Class IB	Class 2
Spindle cell histology	Mixed Spindle and Epitheloid cells	Epitheloid cell histology
No extraocular extension	No extraocular extension	Extraocular extension present
No ciliary body involvement	No ciliary body involvement	Ciliary body involvement present
Chromosome mutations: <ul style="list-style-type: none"> • Disomy 3 • EIF1AX mutation • Gain of chromosome 6p 	Chromosome mutations: <ul style="list-style-type: none"> • SF3B1 mutation 	Chromosome mutations: <ul style="list-style-type: none"> • BAP1 mutation • PRAME mutation • Monosomy 3 • Gain of chromosome 8q

Indication	Imaging Study
Initial staging of suspected or biopsy-proven uveal melanoma	<p><u>ANY or ALL of the following:</u></p> <ul style="list-style-type: none"> • CT Chest with contrast (CPT® 71260) • CT Abdomen and Pelvis with contrast (CPT® 74177) • MRI Orbits/Face/Neck without and with contrast (CPT® 70543)
Neurological signs/symptoms	<ul style="list-style-type: none"> • MRI Brain without and with contrast (CPT® 70553)
Restaging/Suspected Recurrence	<p><u>ANY or ALL of the following:</u></p> <ul style="list-style-type: none"> • CT Chest with contrast (CPT® 71260) • CT Abdomen and Pelvis with contrast (CPT® 74177) • MRI Orbits/Face/Neck without and with contrast (CPT® 70543) • MRI Brain without and with contrast (CPT® 70553)
Surveillance for Low Risk disease	<p><u>Annually for 10 years:</u></p> <ul style="list-style-type: none"> • CT Chest with contrast (CPT® 71260) • CT Abdomen with contrast (CPT® 74160) or MRI Abdomen without and with contrast (CPT® 74183)
Surveillance for Medium Risk disease	<p><u>Every 6 months for 2 years and then annually up to year 10:</u></p> <ul style="list-style-type: none"> • CT Chest with contrast (CPT® 71260) • CT Abdomen with contrast (CPT® 74160) or MRI Abdomen without and with contrast (CPT® 74183)
Surveillance for High Risk disease	<p><u>Every 3 months for 2 years, every 6 months for 3 years, then annually up to year 10:</u></p> <ul style="list-style-type: none"> • CT Chest with contrast (CPT® 71260) • CT Abdomen with contrast (CPT® 74160) or MRI Abdomen without and with contrast (CPT® 74183)

References (ONC-5)

v2.0.2024

1. Swetter SM, Johnson D, Thompson JA, et al. National Comprehensive Cancer Network (NCCN) Guidelines Version 2.2023 – March 10, 2023 Cutaneous Melanoma, available at: https://www.nccn.org/professionals/physician_gls/pdf/cutaneous_melanoma.pdf Referenced with permission from the NCCN Clinical Practice Guidelines in Oncology (NCCN Guidelines™) for Cutaneous Melanoma V2.2023 – March 10, 2023 ©2023 National Comprehensive Cancer Network, Inc. All rights reserved. The NCCN Guidelines™ and illustrations herein may not be reproduced in any form for any purpose without the express written permission of the NCCN. To view the most recent and complete version of the NCCN Guidelines™, go online to NCCN.org.
2. Swetter S, Johnson D, Thompson JA, et al. National Comprehensive Cancer Network (NCCN) Guidelines Version 1.2023 – May 4, 2023 Melanoma: Uveal, available at: https://www.nccn.org/professionals/physician_gls/pdf/uveal.pdf Referenced with permission from the NCCN Clinical Practice Guidelines in Oncology (NCCN Guidelines™) for Melanoma: Uveal V1.2023 – May 4, 2023 ©2023 National Comprehensive Cancer Network, Inc. All rights reserved. The NCCN Guidelines™ and illustrations herein may not be reproduced in any form for any purpose without the express written permission of the NCCN. To view the most recent and complete version of the NCCN Guidelines™, go online to NCCN.org.
3. Schmults CD, Blitzblau R, Aasi SZ, et al. National Comprehensive Cancer Network (NCCN) Guidelines Version 1.2023 – April 10, 2023 Merkel Cell Carcinoma, available at: https://www.nccn.org/professionals/physician_gls/pdf/mcc.pdf Referenced with permission from the NCCN Clinical Practice Guidelines in Oncology (NCCN Guidelines™) for Merkel Cell Carcinoma V1.2023 – April 10, 2023 ©2023 National Comprehensive Cancer Network, Inc. All rights reserved. The NCCN Guidelines™ and illustrations herein may not be reproduced in any form for any purpose without the express written permission of the NCCN. To view the most recent and complete version of the NCCN Guidelines™, go online to NCCN.org .
4. Schmults CD, Blitzblau R, Aasi SZ, et al. National Comprehensive Cancer Network (NCCN) Guidelines Version 1.2023 – March 10, 2023 Basal Cell Skin Cancer, available at: https://www.nccn.org/professionals/physician_gls/pdf/nmsc.pdf Referenced with permission from the NCCN Clinical Practice Guidelines in Oncology (NCCN Guidelines™) for Basal Cell Skin Cancer 1.2023 – March 10, 2023 ©2023 National Comprehensive Cancer Network, Inc. All rights reserved. The NCCN Guidelines™ and illustrations herein may not be reproduced in any form for any purpose without the express written permission of the NCCN. To view the most recent and complete version of the NCCN Guidelines™, go online to NCCN.org .
5. Schmults CD, Blitzblau R, Aasi SZ, et al. National Comprehensive Cancer Network (NCCN) Guidelines Version 1.2023 – May 10, 2023 Squamous Cell Skin Cancer, available at: https://www.nccn.org/professionals/physician_gls/pdf/squamous.pdf Referenced with permission from the NCCN Clinical Practice Guidelines in Oncology (NCCN Guidelines™) for Squamous Cell Skin Cancer V1.2023 – May 10, 2023 ©2023 National Comprehensive Cancer Network, Inc. All rights reserved. The NCCN Guidelines™ and illustrations herein may not be reproduced in any form for any purpose without the express written permission of the NCCN. To view the most recent and complete version of the NCCN Guidelines™, go online to NCCN.org .
6. Schröder-Günther MA, Wolff RF, Westwood ME, et al. F-18-fluoro-2-deoxyglucose positron emission tomography (PET) and PET/computed tomography imaging in primary staging of patients with malignant melanoma: a systematic review. *Syst Rev.* 2012;1:62. doi:10.1186/2046-4053-1-62.
7. Xing Y, Bronstein Y, Ross MI, et al. Contemporary diagnostic imaging modalities for the staging and surveillance of melanoma patients: a meta-analysis. *J Natl Cancer Inst.* 2011;103(2):129-142. doi:10.1093/jnci/djq455.
8. Rodriguez Rivera AM, Alabbas H, Ramjuan A, Meguerditchian AN. Value of positron emission tomography scan in stage III cutaneous melanoma: a systematic review and meta-analysis. *Surg Oncol.* 2014;23(1):11-16. doi: 10.1016/j.suronc.2014.01.002.
9. Nathan P, Cohen V, Coupland S, et al. Uveal melanoma UK national guidelines. *European Journal of Cancer.* 2015;51(16):2404-2412. doi:10.1016/j.ejca/2015.07.013.
10. Moncrieff M, Pywell S, Snelling A, et al. Effectiveness of SPECT/CT imaging for sentinel node biopsy staging of primary cutaneous melanoma and patient outcomes. *Ann Surg Oncol.* 2022;29(2):767-775. doi:10.1245/s10434-021-10911-4.
11. Bennie G, Vorster M, Buscombe J, Sathekge M. The added value of a single-photon emission computed tomography-computed in sentinel lymph node mapping in patients with breast cancer and malignant melanoma. *World J Nucl Med.* 2015;14(01):41-46. doi:10.4103/1450-1147.150543

12. Quartuccio N, Garau LM, Arnone A, et. al. Comparison of ^{99m}Tc-labeled colloid SPECT/CT and planar lymphoscintigraphy in sentinel lymph node detection in patients with melanoma: a meta-analysis. *J Clin Med.* 2020;9(6):1680. doi:10.3390/jcm9061680.

Thyroid Cancer (ONC-6)

Guideline

Thyroid Cancer – General Considerations (ONC-6.0)

Thyroid Cancer – Suspected/Diagnosis (ONC-6.1)

Thyroid Cancer – Initial Work-up/Staging (ONC-6.2)

Thyroid Cancer – Restaging/Recurrence (ONC-6.3)

Thyroid Cancer – Surveillance/Follow-up (ONC-6.4)

References (ONC-6)

Thyroid Cancer – General Considerations (ONC-6.0)

ON.TC.0006.0.A

v2.0.2024

- Individuals of all ages with thyroid cancer are imaged according to this guideline.
- Whole-Body Thyroid Nuclear scan (also known as whole-body radioiodine scan) is coded with CPT® 78018. If CPT® 78018 is obtained and found to be positive, CPT® 78020 may be approved as an add-on test to evaluate the degree of iodine uptake.
- Single photon emission computed tomography (SPECT) imaging – Radiopharmaceutical Localization of Tumor SPECT (CPT® 78803 or CPT® 78831) or SPECT/CT Hybrid study (CPT® 78830 or CPT® 78832) may complement planar and pinhole imaging and can be approved as an add-on wherever radioiodine (RAI) scans are indicated.
- Whole-Body Thyroid Nuclear scan (also known as whole-body RAI scan) is the imaging modality of choice for differentiated thyroid cancers, as these are usually not well visualized on FDG-PET/CT scans. Individuals who have RAI-diagnostic scan negative and PET-positive disease will generally not respond to RAI treatment, whereas individuals who have PET-negative and RAI-diagnostic scan negative disease may still be candidates for empiric RAI treatment.
- Radioiodine (RAI) refractory disease is defined as: (i) the malignant/metastatic tissue does not ever concentrate RAI (no uptake outside the thyroid bed at the first therapeutic WBS), (ii) the tumor tissue loses the ability to concentrate RAI after previous evidence of RAI-avid disease (in the absence of stable iodine contamination), (iii) RAI is concentrated in some lesions but not in others, and (iv) metastatic disease progresses despite significant concentration of RAI⁶.

Thyroid Cancer – Suspected/Diagnosis (ONC-6.1)

ON.TC.0006.1.A

v2.0.2024

- See: **Thyroid Nodule (NECK-8.1)** in the Neck Imaging Guidelines for suspected thyroid malignancies

Thyroid Cancer – Initial Work-up/Staging (ONC-6.2)

ON.TC.0006.2.A

v2.0.2024

Follicular, Papillary and Hürthle Cell Carcinomas	Imaging Study
<p><u>ONE of the following:</u></p> <ul style="list-style-type: none"> Locally advanced disease or fixation suggested by clinical exam and/or ultrasound Substernal or bulky disease Disease precluding full ultrasound examination Vocal cord paresis 	<p><u>ONE of the following:</u></p> <ul style="list-style-type: none"> MRI Neck without contrast (CPT® 70540) MRI Neck without and with contrast (CPT® 70543) CT Neck without contrast (CPT® 70490) CT Neck with contrast (CPT® 70491) can be approved if contrast study is necessary for complete pre-operative assessment and use of IV contrast will not delay post-operative use of RAI therapy.
<p><u>Post-thyroidectomy to assess thyroid remnant and to look for iodine-avid metastases for ONE of the following:</u></p> <ul style="list-style-type: none"> Extent of thyroid remnant cannot be accurately ascertained from the surgical report or neck ultrasound When the results may alter the decision to treat Prior to administration of RAI therapy 	<ul style="list-style-type: none"> Whole-Body Thyroid Nuclear scan (CPT® 78018) The following may be approved as an add-on test: <ul style="list-style-type: none"> CPT® 78020 to evaluate the degree of iodine uptake AND/OR SPECT (CPT® 78803, or CPT® 78831), OR SPECT/CT Hybrid study (CPT® 78830, or CPT® 78832)
<p>Skeletal pain</p>	<ul style="list-style-type: none"> Bone scan <p>See also: <u>Nuclear Medicine (NM) Imaging (ONC-1.3)</u> in Oncology</p> <ul style="list-style-type: none"> Whole-Body Thyroid Nuclear scan (CPT® 78018) The following may be approved as an add-on test: <ul style="list-style-type: none"> CPT® 78020 to evaluate the degree of iodine uptake AND/OR SPECT (CPT® 78803 or CPT® 78831), OR SPECT/CT Hybrid study (CPT® 78830, or CPT® 78832)

Follicular, Papillary and Hürthle Cell Carcinomas	Imaging Study
Suspicious findings on Chest X-ray, US, or substernal extension of mass	<ul style="list-style-type: none"> CT Chest without contrast (CPT® 71250)
All other individuals	<ul style="list-style-type: none"> Routine preoperative advanced imaging is not indicated

Medullary Thyroid Carcinomas	Imaging Study
<u>ANY of the following:</u> <ul style="list-style-type: none"> Elevated CEA levels Calcitonin level >400pg/mL Positive lymph nodes 	<u>ANY or ALL of the following:</u> <ul style="list-style-type: none"> CT Neck with contrast (CPT® 70491) CT Chest with contrast (CPT® 71260) CT Abdomen with contrast (CPT® 74160) or CT Abdomen without and with contrast (CPT® 74170) Bone scan see also: <u>Nuclear Medicine (NM) Imaging (ONC-1.3)</u> in Oncology
Skeletal pain	<ul style="list-style-type: none"> Bone scan see also: <u>Nuclear Medicine (NM) Imaging (ONC-1.3)</u> in Oncology
Inconclusive findings on conventional imaging	<ul style="list-style-type: none"> ⁶⁸Gallium-labeled PET/CT (CPT® 78815)

Anaplastic Thyroid Carcinomas	Imaging Study
All	<u>ONE of the following combinations, not both:</u> <ul style="list-style-type: none"> CT Neck with contrast (CPT® 70491), CT Chest with contrast (CPT® 71260), CT Abdomen and Pelvis with contrast (CPT® 74177) <p>OR</p> <ul style="list-style-type: none"> FDG PET/CT (CPT® 78815) <p><u>In addition to one of the above studies:</u></p> <ul style="list-style-type: none"> MRI Brain without and with contrast (CPT® 70553)
Skeletal pain	<ul style="list-style-type: none"> Bone scan see also: <u>Nuclear Medicine (NM) Imaging (ONC-1.3)</u> in Oncology

Thyroid Cancer – Restaging/Recurrence (ONC-6.3)

ON.TC.0006.3.A

v2.0.2024

Follicular, Papillary and Hürthle Cell Carcinomas	Imaging Study
Gross residual disease found in the neck post-thyroidectomy	<p><u>ANY one of the following:</u></p> <ul style="list-style-type: none"> • CT Neck with contrast (CPT® 70491) • MRI Neck without and with contrast (CPT® 70543)
Within 2 weeks (ideally 7 to 10 days) following the administration of Radioactive Iodine therapy	<ul style="list-style-type: none"> • Whole-body thyroid nuclear scan (CPT® 78018) • The following may be approved as an add-on test: <ul style="list-style-type: none"> • CPT® 78020 to evaluate the degree of iodine uptake • SPECT (CPT® 78803, or CPT® 78831), or SPECT/CT Hybrid study (CPT® 78830, or CPT® 78832)
<p><u>ANY of the following:</u></p> <ul style="list-style-type: none"> • Recurrence documented by biopsy • Increasing thyroglobulin level without Thyrogen® stimulation • Thyroglobulin level >2 ng/mL or higher than previous after Thyrogen® stimulation • Anti-thyroglobulin antibody present • Evidence of residual thyroid tissue on ultrasound or physical exam after thyroidectomy or ablation 	<p><u>ALL of the following:</u></p> <ul style="list-style-type: none"> • CT Neck with contrast (CPT® 70491) or MRI Neck without and with contrast (CPT® 70543) • CT Chest with contrast (CPT® 71260) • CT with contrast of any symptomatic body area • Whole-body Thyroid Nuclear Scan (CPT® 78018) • The following may be approved as an add-on test: <ul style="list-style-type: none"> • CPT® 78020 to evaluate the degree of iodine uptake • SPECT (CPT® 78803 or CPT® 78831), or SPECT/CT Hybrid study (CPT® 78830, or CPT® 78832)

Follicular, Papillary and Hürthle Cell Carcinomas	Imaging Study
<p><u>ANY of the following:</u></p> <ul style="list-style-type: none"> • Rising thyroglobulin level with negative CT scans AND radioiodine scan • Inconclusive findings on conventional imaging (CT scans and radioiodine scan) • Known radioiodine-refractory disease and CT scans are negative or inconclusive 	<ul style="list-style-type: none"> • FDG PET/CT (CPT® 78815)
<p>Measurable metastatic disease on systemic therapy (no more often than every 2 cycles)</p>	<ul style="list-style-type: none"> • CT Chest with contrast (CPT® 71260) • CT with contrast of affected or symptomatic body area

Medullary Thyroid Carcinoma	Imaging Study
<p><u>ANY of the following:</u></p> <ul style="list-style-type: none"> • Elevated CEA levels • Calcitonin level ≥150 pg/mL • Signs or symptoms of recurrence 	<p><u>ANY or ALL of the following:</u></p> <ul style="list-style-type: none"> • CT Neck with contrast (CPT® 70491) • CT Chest with contrast (CPT® 71260) • CT Abdomen either with (CPT® 74160) or without and with contrast (CPT® 74170) • Bone scan <p>See also: <u>Nuclear Medicine (NM) Imaging (ONC-1.3)</u> in Oncology</p>
<p>Inconclusive conventional imaging with calcitonin ≥150 pg per mL</p>	<ul style="list-style-type: none"> • ⁶⁸Gallium-labeled DOTATATE PET/CT (CPT® 78815)

Anaplastic Thyroid Carcinoma	Imaging Study
<p>Measurable metastatic disease on systemic treatment</p>	<p><u>Any of the following every 2 cycles (usually every 6-8 weeks):</u></p> <ul style="list-style-type: none"> • CT Neck with contrast (CPT® 70491) • CT Chest with contrast (CPT® 71260) • CT Abdomen and Pelvis with contrast (CPT® 74177) • CT of any other involved/symptomatic sites

Anaplastic Thyroid Carcinoma	Imaging Study
Signs or symptoms of recurrence	<p><u>ONE of the following combinations, not both:</u></p> <ul style="list-style-type: none">• CT Neck with contrast (CPT® 70491), CT Chest with contrast (CPT® 71260), CT Abdomen and Pelvis with contrast (CPT® 74177) OR• FDG PET/CT (CPT® 78815) <p><u>In addition to one of the above studies:</u></p> <ul style="list-style-type: none">• MRI Brain without and with contrast (CPT® 70553)

Thyroid Cancer – Surveillance/Follow-up (ONC-6.4)

ON.TC.0006.4.A

v2.0.2024

Follicular, Papillary and Hürthle Cell Carcinomas	Imaging Study
Individuals being monitored on active surveillance	<ul style="list-style-type: none"> • Neck ultrasound (CPT® 76536) every 6 months for 2 years, and then annually thereafter
All other individuals post-treatment	<ul style="list-style-type: none"> • Neck ultrasound (CPT® 76536) once at 6-12 months post-treatment, and then annually thereafter
<p><u>For individuals with ANY of the following:</u></p> <ul style="list-style-type: none"> • Node positive disease • RAI-avid metastases 	<ul style="list-style-type: none"> • Whole-body Thyroid Nuclear Scan annually (CPT® 78018) <ul style="list-style-type: none"> • The following may be approved as an add-on test: <ul style="list-style-type: none"> • CPT® 78020 to evaluate the degree of iodine uptake • SPECT (CPT® 78803, or CPT® 78831), OR SPECT/CT Hybrid study (CPT® 78830, or CPT® 78832)

Medullary Carcinomas	Imaging Study
All individuals	<ul style="list-style-type: none"> • CEA and calcitonin are required for monitoring medullary carcinomas • Routine surveillance imaging is not indicated

Anaplastic Thyroid Carcinomas	Imaging Study
All individuals	<p><u>Every 3 months for 2 years:</u></p> <ul style="list-style-type: none"> • CT Neck with contrast (CPT® 70491) • CT Chest with contrast (CPT® 71260) • CT Abdomen and Pelvis with contrast (CPT® 74177) • MRI Brain without and with contrast (CPT® 70553)

References (ONC-6)

v2.0.2024

1. Haddad RH, Bischoff L, Ball D, et al. National Comprehensive Cancer Network (NCCN) Guidelines Version 3.2023 – July 27, 2023 Thyroid carcinoma, available at: https://www.nccn.org/professionals/physician_gls/pdf/thyroid.pdf Referenced with permission from the NCCN Clinical Practice Guidelines in Oncology (NCCN Guidelines™) for Thyroid carcinoma V3.2023 – July 27, 2023 ©2023 National Comprehensive Cancer Network, Inc. All rights reserved. The NCCN Guidelines™ and illustrations herein may not be reproduced in any form for any purpose without the express written permission of the NCCN. To view the most recent and complete version of the NCCN Guidelines™, go online to NCCN.org.
2. Slough CM, Randolph GW. Workup of well-differentiated thyroid carcinoma. *Cancer Control*. 2006;13(2):99-105. doi:10.1177/107327480601300203.
3. Smallridge RC, Ain KB, Asa SL, et al. American Thyroid Association guidelines for management of patients with anaplastic thyroid cancer. *Thyroid*. 2012;22(11):1104-1139. doi:10.1089/thy.2012.0302.
4. Wells SA Jr, Asa SL, Dralle H, et al. American Thyroid Association guidelines for the management of medullary thyroid carcinoma. *Thyroid*. 2015;25(6):567-610. doi:10.1089/thy.2014.0335.
5. Yeh MW, Bauer AJ, Bernet VA, et al. American Thyroid Association statement on preoperative imaging for thyroid cancer surgery. *Thyroid*. 2015;25:3-14. doi:10.1089/thy.2014.0096.
6. Haugen BR, Alexander EK, Bible KB, et al. 2015 American Thyroid Association management guidelines for adult patients with thyroid nodules and differentiated thyroid cancer: the American Thyroid Association guidelines task force on thyroid nodules and differentiated thyroid cancer. *Thyroid*. 2016;26(1):1-133. doi:10.1089/thy.2015.0020.
7. Silberstein EB, Alavi A, Balon HR, et al. The SNMMI Practice Guideline for therapy of thyroid disease with ¹³¹I. *J Nucl Med*. 2012;53(10):1633-1651. doi:10.2967/jnumed.112.105148.
8. Avram AM, Fig LM, Frey KA, Gross MD, Wong KK. Preablation ¹³¹I scans with SPECT/CT in postoperative thyroid cancer patients: what is the impact on staging? *J Clin Endocrinol Metab*. February 21, 2013 [Epub ahead of print].

Small Cell Lung Cancer (ONC-7)

Guideline

Small Cell Lung Cancer – General Considerations (ONC-7.0)

Small Cell Lung Cancer – Suspected/Diagnosis (ONC-7.1)

Small Cell Lung Cancer – Initial Work-up/Staging (ONC-7.2)

Small Cell Lung Cancer – Restaging/Recurrence (ONC-7.3)

Small Cell Lung Cancer – Surveillance/Follow-up ONC-7.4

References (ONC-7)

Small Cell Lung Cancer – General Considerations (ONC-7.0)

ON.SL.0007.0.A

v2.0.2024

- Combined histologies of Small and Non-Small cell are considered Small cell lung cancer. Use this guideline for imaging recommendations for small and large cell high-grade (poorly differentiated) neuroendocrine tumors of the lung.
- Imaging is presently guided by traditional staging of limited or extensive disease.
 - Extensive stage is either metastatic disease or an extent which cannot be encompassed by a single radiotherapy portal.
 - Limited staging is confined to one side of the chest.
- Individuals treated curatively for SCLC are at increased risk for developing a second lung cancer. If new lung nodule is seen on imaging without any evidence of other systemic disease, follow **Lung Metastases (ONC-31.1)** for work-up of nodule.
- For carcinoid (low-grade neuroendocrine tumors) of the lung, see: **Neuroendocrine Cancers and Adrenal Tumors (ONC-15)**

Small Cell Lung Cancer – Suspected/Diagnosis (ONC-7.1)

ON.SL.0007.1.A

v2.0.2024

Indication	Imaging Study
<ul style="list-style-type: none"> Abnormal chest x-ray or clinical suspicion remains high despite a normal chest x-ray in symptomatic individual 	<ul style="list-style-type: none"> CT Chest without contrast (CPT® 71250) or CT Chest with contrast (CPT® 71260)
<ul style="list-style-type: none"> Pulmonary nodule <8 mm in size noted on CT Chest 	<ul style="list-style-type: none"> See: <u>Incidental Pulmonary Nodules Detected on CT Images (CH-16.2)</u> in the Chest Imaging Guidelines
<ul style="list-style-type: none"> Pulmonary nodule 8 mm (0.8 cm) to 30 mm (3 cm) seen on CT Chest or MRI Chest 	<ul style="list-style-type: none"> See: <u>PET (CH-16.4)</u> in the Chest Imaging Guidelines If PET is Positive: Qualifies as initial staging PET/CT Biopsy is indicated prior to PET imaging for pulmonary masses ≥31 mm (3.1 cm) in size
<ul style="list-style-type: none"> Mediastinal/Hilar Mass 	<ul style="list-style-type: none"> See: <u>Lymphadenopathy (CH-2)</u> in the Chest Imaging Guidelines
<ul style="list-style-type: none"> Paraneoplastic syndrome suspected 	<ul style="list-style-type: none"> See: <u>Paraneoplastic Syndromes (ONC-30.3)</u>

Small Cell Lung Cancer – Initial Work-up/Staging (ONC-7.2)

ON.SL.0007.2.A

v2.0.2024

Indication	Imaging Study
Initial staging	<p><u>ANY or ALL</u> of the following:</p> <ul style="list-style-type: none">• CT Chest with contrast (CPT® 71260)• CT Abdomen and Pelvis with contrast (CPT® 74177)• MRI Brain without and with contrast (CPT® 70553)• Bone scan, if PET/CT not being done (See also: <u>Nuclear Medicine (NM) Imaging (ONC-1.3)</u> in Oncology)
To confirm the extent of disease when initial CT and MRI indicate limited stage disease (confined to one side of the chest)	<ul style="list-style-type: none">• PET/CT (CPT® 78815)

Small Cell Lung Cancer – Restaging/Recurrence (ONC-7.3)

ON.SL.0007.3.A

v2.0.2024

Indication	Imaging study
<p><u>Treatment Response:</u></p> <ul style="list-style-type: none"> • After every 2 cycles of chemotherapy • Following completion of chemoradiation 	<p><u>ANY or ALL of the following:</u></p> <ul style="list-style-type: none"> • CT Chest with contrast (CPT® 71260) • CT Abdomen and Pelvis with contrast (CPT® 74177) • MRI Brain without and with contrast (CPT® 70553) for measurable brain metastases being treated with systemic therapy • Bone scan (See also: <u>Nuclear Medicine (NM) Imaging in Oncology (ONC-1.3)</u>) • PET is not indicated for evaluation of treatment response in SCLC, but can be considered on a case-by-case basis.
<p>Restaging (suspected recurrence)</p>	<p><u>ANY or ALL of the following:</u></p> <ul style="list-style-type: none"> • CT Chest with contrast (CPT® 71260) • CT Abdomen and Pelvis with contrast (CPT® 74177) • MRI Brain without and with contrast (CPT® 70553) • Bone scan (See: <u>Nuclear Medicine (NM) Imaging in Oncology (ONC-1.3)</u>) • PET is not indicated for evaluation of recurrent SCLC but can be considered on a case-by-case basis.
<p>Complete or partial response to initial treatment, if prophylactic cranial irradiation (PCI) is planned</p>	<ul style="list-style-type: none"> • MRI Brain without and with contrast (CPT® 70553)

Small Cell Lung Cancer – Surveillance/ Follow-up ONC-7.4

ON.PC.0007.4.A

v2.0.2024

Indication	Imaging Study
Limited stage SCLC	<p><u>Every 3 months for one year, every 6 months for two years, and then annually:</u></p> <ul style="list-style-type: none"> • CT Chest without (CPT® 71250) or CT Chest with (CPT® 71260) contrast • CT Abdomen and Pelvis with contrast (CPT® 74177) • For new nodules, see: <u>Lung Metastases (ONC-31.1)</u>
Extensive stage SCLC	<p><u>Every 2 months for one year, every 4 months for two years, every 6 months for two years, and then annually:</u></p> <ul style="list-style-type: none"> • CT Chest without (CPT® 71250) or CT Chest with (CPT® 71260) contrast • CT Abdomen and Pelvis with contrast (CPT® 74177) • For new nodules, see: <u>Lung Metastases (ONC-31.1)</u>
Screening for brain metastases, regardless of PCI status	<ul style="list-style-type: none"> • MRI Brain without and with contrast (CPT® 70553) every 4 months for 1 year and then every 6 months thereafter

References (ONC-7)

v2.0.2024

1. Ganti AKP, Loo Jr. BW, Bassetti M, et al. National Comprehensive Cancer Network (NCCN) Guidelines Version 2.2024 – November 21, 2023 Small Cell Lung Cancer, available at: https://www.nccn.org/professionals/physician_gls/pdf/sclc.pdf Referenced with permission from the NCCN Clinical Practice Guidelines in Oncology (NCCN Guidelines™) for Small Cell Lung Cancer V2.2024 – November 21, 2023 ©2023 National Comprehensive Cancer Network, Inc. All rights reserved. The NCCN Guidelines™ and illustrations herein may not be reproduced in any form for any purpose without the express written permission of the NCCN. To view the most recent and complete version of the NCCN Guidelines™, go online to NCCN.org.
2. Lu YY, Chen JH, Liang JA, Chu S, Lin WY, Kao CH. 18F-FDG PET or PET/CT for detecting extensive disease in small-cell lung cancer: a systematic review and meta-analysis. *Nucl Med Commun.* 2014;35(7):697-703. doi:10.1097/MNM.000000000000122.
3. Carter BW, Glisson BS, Truong MT, Erasmus JJ. Small cell lung carcinoma: staging, imaging, and treatment considerations. *Radiographics.* 2014;34(6):1707-1721. doi:10.1148/rg.346140178.
4. Kalemkerian G. Staging and imaging of small cell lung cancer. *Cancer Imag.* 2011;11(1):253-258. doi:10.1102/1470-7330.2011.0036.

Non-Small Cell Lung Cancer (ONC-8)

Guideline

- Non-Small Cell Lung Cancer – General Considerations (ONC-8.0)
- Non-Small Cell Lung Cancer – Asymptomatic Screening (ONC-8.1)
- Non-Small Cell Lung Cancer – Suspected/Diagnosis (ONC-8.2)
- Non-Small Cell Lung Cancer – Initial Work-up/Staging (ONC-8.3)
- Non-Small Cell Lung Cancer – Restaging/Recurrence (ONC-8.4)
- Non-Small Cell Lung Cancer – Surveillance/Follow-up (ONC-8.5)
- References (ONC-8)

Non-Small Cell Lung Cancer – General Considerations (ONC-8.0)

ON.NL.0008.0.A

v2.0.2024

- Non-small cell lung cancer includes adenocarcinoma, squamous cell carcinoma, adenosquamous and large cell tumors.
- See: **Bronchopulmonary or Thymic Carcinoid – Initial Staging (ONC-15.6)** for evaluation of low-grade neuroendocrine tumors (carcinoid) of the lung.
- See: **Small Cell Lung Cancer (ONC-7)** for evaluation of high-grade small cell and large cell neuroendocrine tumors of the lung.
- PET/CT scan is generally not indicated for initial staging or restaging of NSCLC when multiple sites of extra-pulmonary metastases are found on conventional imaging (i.e., liver, bone and adrenal metastases, etc.).
- PET/CT may be considered to confirm solitary focus of extra-pulmonary metastatic disease (i.e., brain or adrenal) if the individual is being considered for an aggressive treatment for oligometastatic disease.

Non-Small Cell Lung Cancer – Asymptomatic Screening (ONC-8.1)

ON.NL.0008.1.A

v2.0.2024

- See: **Lung Cancer Screening (CH-33)** in the Chest Imaging Guidelines for criteria for Low-dose CT Chest for lung cancer screening.

Non-Small Cell Lung Cancer – Suspected/Diagnosis (ONC-8.2)

ON.NL.0008.2.A

v2.0.2024

Indication	Imaging Study
Abnormal Chest X-ray or clinical suspicion remains high despite a normal Chest X-ray in symptomatic individual	<ul style="list-style-type: none"> • CT Chest without contrast (CPT® 71250) or • CT Chest with contrast (CPT® 71260)
Pulmonary nodule <8 mm in size noted on CT Chest	<ul style="list-style-type: none"> • See: <u>Incidental Pulmonary Nodules Detected on CT Images (CH-16.2)</u> in the Chest Imaging Guidelines
Pulmonary nodule 8 mm (0.8 cm) to 30 mm (3 cm) seen on CT Chest or MRI Chest	<ul style="list-style-type: none"> • PET/CT (CPT® 78815) • See: <u>PET (CH-16.4)</u> in the Chest Imaging Guidelines • If PET is Positive: Qualifies as initial staging PET/CT
Pulmonary mass 31 mm (3.1 cm) or greater seen on CT or MRI	<ul style="list-style-type: none"> • PET/CT (CPT® 78815) can be approved prior to biopsy if ONE or MORE of the following applies: <ul style="list-style-type: none"> • Definitive treatment with resection or radiation will be utilized instead of biopsy if PET confirms limited disease • Multiple possible biopsy options are present within the chest and PET findings will be used to determine the most favorable biopsy site • Biopsy is indicated prior to PET imaging for all other indications in pulmonary masses ≥31 mm (3.1 cm) in size
Mediastinal/Hilar Lymphadenopathy	See: <u>Mediastinal Lymphadenopathy (CH-2.3)</u> in the Chest Imaging Guidelines
Mediastinal/Hilar Mass	See: <u>Mediastinal Mass (CH-20)</u> in the Chest Imaging Guidelines
Paraneoplastic syndrome suspected	See: <u>Paraneoplastic Syndromes (ONC-30.3)</u>

Non-Small Cell Lung Cancer – Initial Work-up/Staging (ONC-8.3)

ON.NL.0008.3.A

v2.0.2024

Indication	Imaging Study
All individuals	<p><u>ANY or ALL</u> of the following:</p> <ul style="list-style-type: none"> • CT Chest with contrast (CPT® 71260) • CT Abdomen with contrast (CPT® 74160) <ul style="list-style-type: none"> • CT Abdomen may be omitted if CT Chest report clearly documents upper abdomen through level of adrenals • Bone scan, if PET/CT not being done <p>See also: Nuclear Medicine (NM) Imaging in Oncology (ONC-1.3)</p>
<p><u>ANY</u> of the following:</p> <ul style="list-style-type: none"> • Stage I-III B • Stage IV confined to the chest region (including pleural/pericardial effusion) • Stage IV with oligometastatic disease on conventional imaging and individual is a candidate for aggressive surgical resection or other localized treatment of metastases with a curative intent • Conventional imaging is inconclusive 	<ul style="list-style-type: none"> • PET/CT (CPT® 78815) (if not already completed prior to histological diagnosis)
<p><u>ANY</u> of the following:</p> <ul style="list-style-type: none"> • All Stage II-IV disease • Stage I disease and considering surgical resection as primary therapy 	<ul style="list-style-type: none"> • MRI Brain without and with contrast (CPT® 70553)
Superior sulcus (Pancoast) tumor suspected	<p><u>ANY or ALL</u> of the following:</p> <ul style="list-style-type: none"> • MRI Chest without and with contrast (CPT® 71552) • MRI Cervical Spine without and with contrast (CPT® 72156) • MRI Thoracic Spine without and with contrast (CPT® 72157)

Non-Small Cell Lung Cancer – Restaging/Recurrence (ONC-8.4)

ON.NL.0008.4.A

v2.0.2024

Indication	Imaging Study
Stage I or II individuals who undergo definitive local treatment with surgery, radiation, or radiosurgery	<ul style="list-style-type: none"> Restaging imaging is not indicated. See: Surveillance/Follow-up (ONC-8.5)
Measurable disease, undergoing active treatment	<p><u>ANY or ALL of the following every 2 cycles:</u></p> <ul style="list-style-type: none"> CT Chest with (CPT® 71260) or CT Chest without contrast (CPT® 71250) CT Abdomen with contrast (CPT® 74160) <ul style="list-style-type: none"> CT Abdomen and Pelvis with contrast (CPT® 74177) may be substituted for known pelvic disease or pelvic symptoms MRI Brain without and with contrast (CPT® 70553) for measurable brain metastases being treated with systemic therapy
<p><u>ANY of the following:</u></p> <ul style="list-style-type: none"> After neoadjuvant treatment for evaluation of surgical resectability Prior to starting adjuvant therapy Inadequately resected disease 	<ul style="list-style-type: none"> CT Chest with (CPT® 71260) or CT Chest without contrast (CPT® 71250)
Suspected recurrence	<p><u>ANY or ALL of the following:</u></p> <ul style="list-style-type: none"> CT Chest with (CPT® 71260) or CT Chest without contrast (CPT® 71250) CT Abdomen with contrast (CPT® 74160) CT Abdomen and Pelvis with contrast (CPT® 74177) may be substituted for known pelvic disease or pelvic symptoms
Newly identified lung nodule(s)	<ul style="list-style-type: none"> See: Lung Metastases (ONC-31.1) for new nodule evaluation

Indication	Imaging Study
<p><u>ANY of the following:</u></p> <ul style="list-style-type: none">• Suspected/biopsy proven recurrence localized to the chest cavity• Inconclusive findings conventional imaging• To differentiate tumor from radiation scar/fibrosis• Stage IV with oligometastatic disease on conventional imaging and individual is a candidate for aggressive surgical resection or other localized treatment of metastases with a curative intent	<ul style="list-style-type: none">• PET/CT (CPT® 78815)
<p><u>ANY of the following:</u></p> <ul style="list-style-type: none">• Following a demonstrated adequate response to neoadjuvant therapy if intracranial disease will preclude surgery• Documented recurrence/progression• New or worsening neurological signs or symptoms	<ul style="list-style-type: none">• MRI Brain without and with contrast (CPT® 70553)

Non-Small Cell Lung Cancer – Surveillance/Follow-up (ONC-8.5)

ON.NL.0008.5.A

v2.0.2024

Indication	Study
Stage I-II	<ul style="list-style-type: none">CT Chest with contrast (CPT® 71260) or CT Chest without contrast (CPT® 71250) every 6 months for 3 years and then annually <p>***Individuals treated with radiation therapy and residual abnormality on imaging may undergo CT Chest every 3 months for the first year after therapy, every 6 months for 2 years, and then annually thereafter</p>
Stage III-IV (metastatic sites treated with definitive intent)	<ul style="list-style-type: none">CT Chest with contrast (CPT® 71260) or CT Chest without contrast (CPT® 71250) every 3 months for 2 years, every 6 months for 3 years and then annually
New lung nodule	<ul style="list-style-type: none">See: Lung Metastases (ONC-31.1)

References (ONC-8)

v2.0.2024

1. Ettinger DS, Wood DE, Aisner DL, et al, National Comprehensive Cancer Network (NCCN) Guidelines Version 3.2023 – April 13, 2023. Non small cell lung cancer, available at: https://www.nccn.org/professionals/physician_gls/pdf/nscl.pdf Referenced with permission from the NCCN Clinical Practice Guidelines in Oncology (NCCN Guidelines™) for Non-small cell lung cancer V3.2023 – April 13, 2023. ©2023 National Comprehensive Cancer Network, Inc. All rights reserved. The NCCN Guidelines™ and illustrations herein may not be reproduced in any form for any purpose without the express written permission of the NCCN. To view the most recent and complete version of the NCCN Guidelines™, go online to NCCN.org.
2. Scheider BJ, Ismaila N, Aerts J, et al. Lung cancer surveillance after definitive curative-intent therapy: ASCO guideline. *J Clin Oncol*. 2020;38(7):753-766. doi:10.1200/JCO.19.02748.
3. MacMahon H, Naidich DP, Goo JM, et al. Guidelines for management of incidental pulmonary nodules detected on CT images: from the Fleischner Society 2017. *Radiology*. 2017;284(1):228-243. doi:10.1148/radiol.2017161659.
4. Calman L, Beaver K, Hind D, Lorigan P, Roberts C, Lloyd-Jones M. Survival benefits from follow-up of patients with lung cancer: a systematic review and meta-analysis. *J Thorac Oncol*. 2011;6(12):1993-2004. doi:10.1097/JTO.0b013e31822b01a1.
5. Lou F, Huang J, Sima CS et al. Patterns of recurrence and second primary lung cancer in early-stage lung cancer survivors followed with routine computed tomography surveillance. *J Thorac Cardiovasc Surg*. 2013;145:75-81. <https://www.ncbi.nlm.nih.gov/pubmed/23127371>.
6. Colt HG, Murgu SD, Korst RJ, et al. Follow-up and surveillance of the patient with lung cancer after curative-intent therapy: diagnosis and management of lung cancer, 3rd ed: American College of Chest Physicians evidence-based clinical practice guidelines. *Chest*. 2013;143:e437S-454S. <https://www.ncbi.nlm.nih.gov/pubmed/23649451>.
7. Dane B, Grechushkin V, Plank A, et al. PET/CT vs. non-contrast CT alone for surveillance 1-year post lobectomy for stage I non-small cell lung cancer. *Am J Nucl Med Mol Imaging*. 2013; 3:408-416. <https://www.ncbi.nlm.nih.gov/pmc/articles/PMC3784804/>.
8. Zhao L, He ZY, Zhong XN, et al. (18)FDG-PET/CT for detection of mediastinal nodal metastasis in non-small cell lung cancer: a meta-analysis. *Surg Oncol*. 2012;21(3):230-236. <https://www.ncbi.nlm.nih.gov/pubmedhealth/PMH0049561/>.
9. Li J, Xu W, Kong F, et al. Meta-analysis: accuracy of 18FDG PET-CT for distant metastasis in lung cancer patients. *Surg Oncol*. 2013;22(3):151-155. <https://www.ncbi.nlm.nih.gov/pubmed/23664848>.
10. Ravenel JG. Evidence-based imaging in lung cancer: a systematic review. *J Thorac Imaging*. 2012; 27(5):315-324. http://journals.lww.com/thoracicimaging/Abstract/2012/09000/Evidence_based_Imaging_in_Lung_Cancer__A.8.aspx.
11. Bille A, Pelosi E, Skanjeti A, et al. Preoperative intrathoracic lymph node staging in patients with non-small-cell lung cancer: accuracy of integrated positron emission tomography and computed tomography. *Eur J Cardiothorac Surg*. 2009;36(3):440-445. <https://academic.oup.com/ejcts/article-lookup/doi/10.1016/j.ejcts.2009.04.003>.

Esophageal and GE Junction Cancer (ONC-9)

Guideline

Esophageal and GE Junction Cancer – General Considerations
(ONC-9.0)

Esophageal and GE Junction Cancer – Suspected/Diagnosis
(ONC-9.1)

Esophageal and GE Junction Cancer – Initial Work-up/Staging
(ONC-9.2)

Esophageal and GE Junction Cancer – Restaging/Recurrence
(ONC-9.3)

Esophageal and GE Junction Cancer – Surveillance/Follow-up
(ONC-9.4)

References (ONC-9)

Esophageal and GE Junction Cancer – General Considerations (ONC-9.0)

ON.EJ.0009.0.A

v2.0.2024

- Imaging for esophageal cancer is determined by cell type and in which third of the esophagus it occurs.
- Cancers of the upper and middle third are usually squamous cell and are highly associated with tobacco and alcohol abuse.
- Cancers of the gastroesophageal (GE) junction are treated as lower third cancers. Lower third cancers are usually adenocarcinomas; 62% of these arise in the setting of Barrett's esophagus, a condition associated with high body mass index (BMI).

Esophageal and GE Junction Cancer – Suspected/Diagnosis (ONC-9.1)

ON.EJ.0009.1.A

v2.0.2024

- See: **Dysphagia and Esophageal Disorders (NECK-3.1)** in the Neck Imaging Guidelines for evaluation of suspected esophageal malignancy.

Esophageal and GE Junction Cancer – Initial Work-up/Staging (ONC-9.2)

ON.EJ.0009.2.A

v2.0.2024

Indication	Imaging Study
Biopsy proven	<ul style="list-style-type: none">CT Chest (CPT® 71260) and CT Abdomen (CPT® 74160) with contrastCT Abdomen and Pelvis with contrast (CPT® 74177) may be approved instead of CT Abdomen if there are pelvic signs or symptoms
Upper 1/3 or neck mass	<ul style="list-style-type: none">CT Neck with contrast (CPT® 70491)
If no evidence of metastatic disease on conventional imaging	<ul style="list-style-type: none">PET/CT (CPT® 78815)

Esophageal and GE Junction Cancer – Restaging/Recurrence (ONC-9.3)

ON.EJ.0009.3.A

v2.0.2024

Indication	Imaging Study
After primary chemoradiation therapy prior to surgery	<p><u>Any ONE of the following, not both:</u></p> <ul style="list-style-type: none"> • CT Chest (CPT® 71260) and CT Abdomen (CPT® 74160) with contrast OR • PET/CT (CPT® 78815) no sooner than 8 weeks post completion of radiation therapy
Post-surgical resection	<ul style="list-style-type: none"> • See: <u>Surveillance/Follow-up (ONC-9.4)</u>
Monitoring response to chemotherapy for stage IV/metastatic disease	<p><u>Every 2 cycles of treatment (~every 6-8 weeks):</u></p> <ul style="list-style-type: none"> • CT Abdomen with contrast (CPT® 74160) • CT Chest with contrast (CPT® 71260)
<ul style="list-style-type: none"> • If conventional imaging is inconclusive or • Salvage surgical candidate with recurrence and no metastatic disease documented by conventional imaging 	<ul style="list-style-type: none"> • PET/CT (CPT® 78815)
<p><u>For ANY of the following:</u></p> <ul style="list-style-type: none"> • Signs or symptoms of recurrence • Biopsy proven on follow-up endoscopy • Recurrence suggested by other imaging (i.e. Chest x-ray or barium swallow) 	<ul style="list-style-type: none"> • CT Chest (CPT® 71260) and CT Abdomen (CPT® 74160) with contrast
If previously involved or new signs or symptoms	<ul style="list-style-type: none"> • CT Pelvis with contrast (CPT® 72193) and/or CT Neck with contrast (CPT® 70491)

Esophageal and GE Junction Cancer – Surveillance/Follow-up (ONC-9.4)

ON.EJ.0009.4.A

v2.0.2024

Indication	Imaging Study
Stage 0-IA (Tis, T1a) disease	<ul style="list-style-type: none">No routine advanced imaging indicated
Stage IB (T1b)-III disease	<ul style="list-style-type: none">CT Chest (CPT® 71260) and CT Abdomen (CPT® 74160) with contrast every 6 months for 2 years and then annually for 3 more years
Stage IV disease	<ul style="list-style-type: none">See: <u>Phases of Oncology Imaging and General Phase-Related Considerations (ONC-1.2)</u>

References (ONC-9)

v2.0.2024

1. Ajani JA, D'Amico TA, Barzi A, et al. National Comprehensive Cancer Network (NCCN) Guidelines Version 1.2024 – March 7, 2024. Esophageal and esophagogastric junction cancers, available at: https://www.nccn.org/professionals/physician_gls/pdf/esophageal.pdf Referenced with permission from the NCCN Clinical Practice Guidelines in Oncology (NCCN Guidelines™) for Esophageal and esophagogastric junction cancers V1.2024 – March 7, 2024. ©2024 National Comprehensive Cancer Network, Inc. All rights reserved. The NCCN Guidelines™ and illustrations herein may not be reproduced in any form for any purpose without the express written permission of the NCCN. To view the most recent and complete version of the NCCN Guidelines™, go online to [NCCN.org](https://www.nccn.org).
2. Klaeser B, Nitzsche E, Schuller JC, et al. Limited predictive value of FDG-PET for response assessment in the preoperative treatment of esophageal cancer: results of a prospective multi-center trial (SAKK 75/02). *Onkologie*. 2009;32(12):724-730. doi:10.1159/000251842.
3. Malik V, Lucey JA, Duffy GJ, et al. Early repeated 18F-FDG PET scans during neoadjuvant chemoradiation fail to predict histopathologic response or survival benefit in adenocarcinoma of the esophagus. *J Nucl Med*. 2010;51(12):1863-1869. doi:10.2967/jnumed.110.079566.
4. Stiekema J, Vermeulen D, Vegt E, et al. Detecting interval metastases and response assessment using 18F-FDG PET/CT after neoadjuvant chemoradiotherapy for esophageal cancer. *Clin Nucl Med*. 2014;39(10):862-867. doi:10.1097/RLU.0000000000000517.
5. Sudo K, Xiao L, Wadhwa R, et al. Importance of surveillance and success of salvage strategies after definitive chemoradiation in patients with esophageal cancer. *J Clin Oncol*. 2014;32(30):3400-3405. doi:10.1200/JCO.2014.56.7156.
6. Lou F, Sima CS, Adusumilli PS, et al. Esophageal cancer recurrence patterns and implications for surveillance. *J Thorac Oncol*. 2013;8(12):1558–1562. doi:10.1097/01.JTO.0000437420.38972.fb.
7. Goense L, van Rossum PS, Reitsma JB, et al. Diagnostic performance of 18F-FDG PET and PET/CT for the detection of recurrent esophageal cancer after treatment with curative intent: a systematic review and meta-analysis. *J Nucl Med*. 2015;56(7):995-1002. doi:10.2967/jnumed.115.155580.

Other Thoracic Tumors (ONC-10)

Guideline

- Malignant Pleural Mesothelioma – Suspected/Diagnosis (ONC-10.1)
- Malignant Pleural Mesothelioma – Initial Work-up/Staging (ONC-10.2)
- Malignant Pleural Mesothelioma – Restaging (ONC-10.3)
- Malignant Pleural Mesothelioma – Surveillance (ONC-10.4)
- Thymoma and Thymic Carcinoma – Suspected/Diagnosis (ONC-10.5)
- Thymoma and Thymic Carcinoma – Initial Work-up/Staging (ONC-10.6)
- Thymoma and Thymic Carcinoma – Restaging (ONC-10.7)
- Thymoma and Thymic Carcinoma – Surveillance (ONC-10.8)
- References (ONC-10)

Malignant Pleural Mesothelioma – Suspected/Diagnosis (ONC-10.1)

ON.OT.0010.1.A

v2.0.2024

- See: **Asbestos Exposure (CH-9.1)** in the Chest Imaging Guidelines for evaluation of suspected mesothelioma.

Malignant Pleural Mesothelioma – Initial Work-up/Staging (ONC-10.2)

ON.OT.0010.2.A

v2.0.2024

Indication	Imaging Study
Cytologically or pathologically proven	<ul style="list-style-type: none">• CT Chest (CPT® 71260) and CT Abdomen (CPT® 74160) with contrast• CT Abdomen and Pelvis with contrast (CPT® 74177) may be approved instead of CT Abdomen if there are pelvic signs or symptoms• PET/CT (CPT® 78815) if no evidence of metastatic disease or inconclusive conventional imaging
Preoperative planning	<ul style="list-style-type: none">• MRI Chest without and with contrast (CPT® 71552)

Malignant Pleural Mesothelioma – Restaging (ONC-10.3)

ON.OT.0010.3.A

v2.0.2024

Indication	Imaging Study
Signs or symptoms of recurrence	<ul style="list-style-type: none"> • CT Chest (CPT® 71260) and CT Abdomen (CPT® 74160) with contrast • CT Abdomen and Pelvis with contrast (CPT® 74177) may be approved instead of CT Abdomen if there are pelvic signs or symptoms
Treatment with chemotherapy	<p><u>Every 2 cycles:</u></p> <ul style="list-style-type: none"> • CT Chest (CPT® 71260) and CT Abdomen (CPT® 74160) with contrast • CT Abdomen and Pelvis with contrast (CPT® 74177) may be approved instead of CT Abdomen if there are pelvic signs or symptoms
Following induction chemotherapy prior to surgical resection	<ul style="list-style-type: none"> • CT Chest (CPT® 71260) and CT Abdomen (CPT® 74160) with contrast • CT Abdomen and Pelvis with contrast (CPT® 74177) may be approved instead of CT Abdomen if there are pelvic signs or symptoms • PET/CT (CPT® 78815) if no evidence of metastatic disease
Inconclusive CT Chest	<ul style="list-style-type: none"> • MRI Chest without and with contrast (CPT® 71552)

Malignant Pleural Mesothelioma – Surveillance (ONC-10.4)

ON.OT.0010.4.A

v2.0.2024

Indication	Imaging Study
All	<ul style="list-style-type: none">CT Chest with contrast (CPT® 71260) and previously involved regions every 3 months for 2 years, then annually thereafter

Thymoma and Thymic Carcinoma – Suspected/Diagnosis (ONC-10.5)

ON.OT.0010.5.A

v2.0.2024

- See: **Mediastinal Mass (CH-20.1)** in the Chest Imaging Guidelines for evaluation of suspected thymic malignancies.
- See: **Bronchopulmonary or Thymic Carcinoid – Initial Staging (ONC-15.6)** for imaging guidelines for thymic carcinoid.

Thymoma and Thymic Carcinoma – Initial Work-up/Staging (ONC-10.6)

ON.OT.0010.6.A

v2.0.2024

Indication	Imaging Study
Encapsulated or invasive limited disease	<ul style="list-style-type: none">CT Chest with contrast (CPT® 71260)
Extensive mediastinal involvement on CT Chest	<ul style="list-style-type: none">CT Abdomen with contrast (CPT® 74160)CT Neck with contrast (CPT® 70491)
Inconclusive finding on CT	<p><u>ONE of the following:</u></p> <ul style="list-style-type: none">PET/CT (CPT® 78815)MRI Chest without and with contrast (CPT® 71552)
Preoperative planning	<ul style="list-style-type: none">MRI Chest without and with contrast (CPT® 71552)
Thymic Carcinomas	<ul style="list-style-type: none">Image according to <u>Non-Small Cell Lung Cancer - Initial Work-up/Staging (ONC-8.3)</u>

Thymoma and Thymic Carcinoma – Restaging (ONC-10.7)

ON.OT.0010.7.A

v2.0.2024

Indication	Study
Adjuvant therapy following surgical resection	<ul style="list-style-type: none"> Follow surveillance imaging
Following induction chemotherapy prior to surgical resection, if no evidence of metastatic disease	<ul style="list-style-type: none"> PET/CT (CPT® 78815)
For suspected recurrence	<ul style="list-style-type: none"> CT Chest with contrast (CPT® 71260)
Recurrence with extensive mediastinal involvement on CT Chest	<ul style="list-style-type: none"> CT Abdomen with contrast (CPT® 74160) CT Neck with contrast (CPT® 70491)
Inconclusive finding on CT	<p><u>ONE of the following:</u></p> <ul style="list-style-type: none"> PET/CT (CPT® 78815) MRI Chest without and with contrast (CPT® 71552)
Metastatic disease on chemotherapy	<ul style="list-style-type: none"> CT Neck (CPT® 70491), CT Chest (CPT® 71260), and CT Abdomen (CPT® 74160) with contrast, every 2 cycles of therapy
Thymic carcinomas	<ul style="list-style-type: none"> See: <u>Non-Small Cell Lung Cancer Restaging/Recurrence (ONC-8.4)</u>

Thymoma and Thymic Carcinoma – Surveillance (ONC-10.8)

ON.OT.0010.8.A

v2.0.2024

Indication	Study
Thymoma	<ul style="list-style-type: none">CT Chest with contrast (CPT® 71260) and previously involved regions every 6 months for 2 years, then annually for next 10 years
Thymic carcinomas	<ul style="list-style-type: none">CT Chest with contrast (CPT® 71260) every 6 months for 2 years and then annually for next 5 years

References (ONC-10)

v2.0.2024

1. Ettinger DS, Wood DE, Stevenson J, et al. National Comprehensive Cancer Network (NCCN) Guidelines Version 1.2023 – December 15, 2022. Mesothelioma: Pleural, available at: https://www.nccn.org/professionals/physician_gls/pdf/meso_pleural.pdf. Referenced with permission from the NCCN Clinical Practice Guidelines in Oncology (NCCN Guidelines™) for Mesothelioma: Pleural V1.2023 – December 15, 2022. ©2022 National Comprehensive Cancer Network, Inc. All rights reserved. The NCCN Guidelines™ and illustrations herein may not be reproduced in any form for any purpose without the express written permission of the NCCN. To view the most recent and complete version of the NCCN Guidelines™, go online to NCCN.org.
2. Ettinger DS, Wood DE, Stevenson J, et al. National Comprehensive Cancer Network (NCCN) Guidelines Version 2.2023 – July 20, 2023. Mesothelioma: Peritoneal, available at: https://www.nccn.org/professionals/physician_gls/pdf/meso_peritoneal.pdf. Referenced with permission from the NCCN Clinical Practice Guidelines in Oncology (NCCN Guidelines™) for Mesothelioma: Peritoneal V2.2023 – July 20, 2023. ©2023 National Comprehensive Cancer Network, Inc. All rights reserved. The NCCN Guidelines™ and illustrations herein may not be reproduced in any form for any purpose without the express written permission of the NCCN. To view the most recent and complete version of the NCCN Guidelines™, go online to NCCN.org.
3. Ettinger DS, Wood DE, Riely GJ, et al. National Comprehensive Cancer Network (NCCN) Guidelines Version 1.2023 – December 15, 2022. Thymoma and Thymic carcinoma, available at: https://www.nccn.org/professionals/physician_gls/pdf/thymic.pdf. Referenced with permission from the NCCN Clinical Practice Guidelines in Oncology (NCCN Guidelines™) for Thymoma and Thymic carcinoma, V1.2023 – December 15, 2022. ©2022 National Comprehensive Cancer Network, Inc. All rights reserved. The NCCN Guidelines™ and illustrations herein may not be reproduced in any form for any purpose without the express written permission of the NCCN. To view the most recent and complete version of the NCCN Guidelines™, go online to NCCN.org.
4. Sørensen JB, Ravn J, Loft A, Brenøe J, Berthelsen AK, Nordic Mesothelioma Group. Preoperative staging of mesothelioma by 18F-fluoro-2-deoxy-D-glucose positron emission tomography/computer tomography fused imaging and mediastinoscopy compared to pathological findings after extrapleural pneumonectomy. *Eur J Cardiothorac Surg*. 2008;34:1090-1096. doi:10.1016/j.ejcts.2008.07.050.
5. Wilcox BE, Subramaniam RM, Peller PJ, et al. Utility of computed tomography-positron emission tomography for selection of operable malignant pleural mesothelioma. *Clin lung cancer*. 2009;10:244-248. doi: 10.3816/CLC.2009.n.033.
6. Marom EM. Imaging thymoma. *J Thorac Oncol*. 2010;5(10 Suppl 4):S296-S303. doi:10.1097/JTO.0b013e3181f209ca.
7. Marom EM. Advances in thymoma imaging. *J Thorac Imaging*. 2013;28(2):69-80. doi:10.1097/RTI.0b013e31828609a0.
8. Hayes SA, Huang J, Plodkowski AJ, et al. Preoperative computed tomography findings predict surgical resectability of thymoma. *J Thorac Oncol*. 2014;9(7):1023-1030. doi:10.1097/JTO.000000000000204.
9. Mineo TC, Ambrogi V. Malignant pleural mesothelioma: factors influencing the prognosis. *Oncology*. 2012;26(12):1164-75.

Breast Cancer (ONC-11)

Guideline

Breast Cancer – General Considerations (ONC-11.0)

Breast Cancer – Suspected/Diagnosis (ONC-11.1)

Breast Cancer – Initial Work-up/Staging (ONC-11.2)

Breast Cancer – Restaging/Recurrence (ONC-11.3)

Breast Cancer – Surveillance/Follow-up (ONC-11.4)

References (ONC-11)

Breast Cancer – General Considerations (ONC-11.0)

ON.BC.0011.0.A

v2.0.2024

- This guideline applies to invasive and pre-invasive (lobular and ductal carcinoma in-situ) histologies of breast cancer.
- MRI Breast is not routinely indicated for all individuals with newly diagnosed breast cancer or carcinoma in situ. The use of MRI has not shown to increase the likelihood of negative surgical margins, decrease the rate of mastectomy, reduce local recurrence rates or improve long-term survival.
- Advanced imaging to evaluate for distant metastases is not indicated for asymptomatic individuals with invasive or pre-invasive or in-situ breast cancer (histologies such as DCIS and LCIS).
- Bone scan has a high concordance rate with PET for detecting bone metastases.
- Scintimammography and Breast Specific Gamma Imaging (BSGI) are considered experimental, investigational, or unproven.

Breast Cancer – Suspected/Diagnosis (ONC-11.1)

ON.BC.0011.1.A

v2.0.2024

- See: **Breast MRI Indications (BR-5)** in the Breast Imaging Guidelines for evaluation of suspected breast cancer.

Breast Cancer – Initial Work-up/Staging (ONC-11.2)

ON.BC.0011.2.A

v2.0.2024

Indication	Imaging Study
<p>Newly diagnosed breast cancer or carcinoma in situ</p>	<ul style="list-style-type: none"> Diagnostic bilateral mammogram and/or Ultrasound Breast (CPT® 76641 or CPT® 76642) are imaging modalities of choice MRI Breast is not routinely indicated for all individuals with newly diagnosed breast cancer or carcinoma in situ^{1, 11, 12, 13, 14}
<p><u>ANY of the following:</u></p> <ul style="list-style-type: none"> Multifocal or multicentric breast cancer Before neoadjuvant systemic therapy High risk histologies: atypical ductal hyperplasia (ADH), atypical lobular hyperplasia (ALH), lobular carcinoma in situ (LCIS), or invasive lobular carcinoma (ILC) Paget's disease of the breast Inconclusive findings on both mammogram and ultrasound Extremely dense breast tissue (breast density category D) on mammography Adenocarcinoma in axillary lymph node without a breast primary site identified on mammogram/ultrasound 	<ul style="list-style-type: none"> MRI Breast Bilateral without and with contrast (CPT® 77049)
<p><u>ANY of the following:</u></p> <ul style="list-style-type: none"> Ductal carcinoma in situ Stage I-III 	<ul style="list-style-type: none"> For planned sentinel lymph node (SLN) biopsy: Lymph system imaging (lymphoscintigraphy, CPT® 78195) <ul style="list-style-type: none"> SPECT/CT (CPT® 78830) is indicated as an add on code if requested

Indication	Imaging Study
Stages I, II, and III	<ul style="list-style-type: none"> Routine systemic imaging is not indicated for initial staging of non-metastatic breast cancer in the absence of signs or symptoms
<p><u>ANY of the following:</u></p> <ul style="list-style-type: none"> Clinically suspected or biopsy proven metastatic/Stage IV disease Signs or symptoms of systemic disease Elevated liver function tests or tumor markers Inflammatory breast cancer (stage T4d) 4 or more axillary lymph nodes positive for cancer involvement 	<p><u>ANY or ALL of the following:</u></p> <ul style="list-style-type: none"> CT Chest (CPT® 71260) and CT Abdomen and Pelvis (CPT® 74177) with contrast Bone scan <p>See: <u>Nuclear Medicine (NM) Imaging in Oncology (ONC-1.3)</u></p>
Inconclusive CT and/or bone scan	<ul style="list-style-type: none"> PET/CT (CPT® 78815)
Bone pain	<ul style="list-style-type: none"> Bone scan (see: <u>Nuclear Medicine (NM) Imaging in Oncology (ONC-1.3)</u>) See: <u>Bone (Non-Vertebral) Metastases (ONC-31.5)</u> See: <u>Spinal/Vertebral Metastases (ONC-31.6)</u>

Breast Cancer – Restaging/Recurrence (ONC-11.3)

ON.BC.0011.3.A

v2.0.2024

Indication	Imaging Study
<p><u>ANY of the following:</u></p> <ul style="list-style-type: none"> • End of planned neoadjuvant chemotherapy to determine resectability • Biopsy proven local recurrence • Suspicion of recurrence with inconclusive mammogram and/or ultrasound (BIRADS 0) • Mammogram and ultrasound conflicts with physical exam 	<ul style="list-style-type: none"> • MRI Breast Bilateral without and with contrast (CPT® 77049)
<p>After neoadjuvant chemotherapy, if sentinel node evaluation is planned</p>	<ul style="list-style-type: none"> • Lymph system imaging (lymphoscintigraphy, CPT® 78195) <ul style="list-style-type: none"> • SPECT/CT (CPT® 78830) is indicated as an add on code if requested
<p><u>ANY of the following:</u></p> <ul style="list-style-type: none"> • Assessing for residual disease after surgery • Assessing response to neoadjuvant chemotherapy • After lumpectomy or mastectomy, prior to adjuvant therapy 	<ul style="list-style-type: none"> • Neither PET nor CT are indicated for systemic restaging after neoadjuvant chemotherapy or after surgery
<ul style="list-style-type: none"> • Treatment response in individuals with metastatic disease and measurable disease on imaging <ul style="list-style-type: none"> • For individuals receiving chemotherapy, imaging is indicated after every 2 cycles • For individuals receiving hormonal or endocrine therapy, imaging is indicated every 3 months 	<ul style="list-style-type: none"> • CT Chest with contrast (CPT® 71260); and CT Abdomen and Pelvis with contrast (CPT® 74177) • Bone scan (see also: <u>Nuclear Medicine (NM) Imaging in Oncology (ONC-1.3)</u>) <p>In addition to the above options, for individuals receiving systemic treatment for brain metastases:</p> <ul style="list-style-type: none"> • MRI Brain without and with contrast (CPT® 70553)

Indication	Imaging Study
<p><u>ANY of the following:</u></p> <ul style="list-style-type: none"> Elevated LFTs Elevated tumor markers Signs or symptoms of recurrence Biopsy proven recurrence 	<p><u>Any or all of the following:</u></p> <ul style="list-style-type: none"> CT Chest (CPT® 71260) and CT Abdomen and Pelvis (CPT® 74177) with contrast Bone scan (See also: <u>Nuclear Medicine (NM) Imaging in Oncology (ONC-1.3)</u>)
<ul style="list-style-type: none"> Inconclusive CT, MRI, and/or bone scan for suspected recurrence, and further characterization is needed to make treatment decisions Bone metastasis as the only site of stage IV disease (excluding brain metastases) and a prior bone scan has not been performed for serial comparison 	<ul style="list-style-type: none"> ¹⁸F-FDG PET/CT (CPT® 78815)
<p><u>To determine the ER-status of suspected/known metastatic recurrence noted on CT/bone scan and any one of the following:</u></p> <ul style="list-style-type: none"> Biopsy of metastatic site is non-diagnostic/inconclusive Biopsy of metastatic site is risky & cannot be performed (metastatic sites in the brain, spine or near vascular structures) 	<ul style="list-style-type: none"> ¹⁸F-FES (fluoroestradiol) PET/CT scan (CPT® 78815 or CPT® 78816)

Breast Cancer – Surveillance/Follow-up (ONC-11.4)

ON.BC.0011.4.U

v2.0.2024

Indication	Imaging Study
Measurable metastatic disease on maintenance therapy or being monitored off therapy	<u>ANY or ALL of the following, every 3 months for up to 5 years after completion of active treatment:</u> <ul style="list-style-type: none">• CT Chest (CPT® 71260) and CT Abdomen and Pelvis (CPT® 74177) with contrast• Bone scan (see also: Nuclear Medicine (NM) Imaging in Oncology (ONC-1.3))
<ul style="list-style-type: none">• Asymptomatic non-metastatic disease• Individuals receiving post-operative adjuvant therapy	<ul style="list-style-type: none">• No advanced imaging indicated
Individuals with a personal history of breast cancer (not treated with bilateral mastectomy)	<ul style="list-style-type: none">• Annual MRI Breast Bilateral without and with contrast (CPT® 77049)

References (ONC-11)

v2.0.2024

1. Gradishar WJ, Moran MS, Abraham J, et al. National Comprehensive Cancer Network (NCCN) Guidelines Version 2.2024 – March 11, 2024. Breast cancer, available at: https://www.nccn.org/professionals/physician_gls/pdf/breast.pdf Referenced with permission from the NCCN Clinical Practice Guidelines in Oncology (NCCN Guidelines™) for Breast Cancer V2.2024 – March 11, 2024. ©2024 National Comprehensive Cancer Network, Inc. All rights reserved. The NCCN Guidelines™ and illustrations herein may not be reproduced in any form for any purpose without the express written permission of the NCCN. To view the most recent and complete version of the NCCN Guidelines™, go online to NCCN.org.
2. Cardoso F, Costa A, Norton L, et al. ESO-ESMO 2nd international consensus guidelines for advanced breast cancer (ABC2). *Ann Oncol*. 2014;25(10):1871-1888. doi:10.1093/annonc/mdl385.
3. Khatcheressian JL, Hurley P, Bantug E, et al. Breast cancer follow-up and management after primary treatment: American Society of Clinical Oncology clinical practice guideline update. *J Clin Oncol*. 2013;31:961-965. doi:10.1200/JCO.2012.45.9859.
4. Puglisi F, Follador A, Minisini AM, et al. Baseline staging tests after a new diagnosis of breast cancer: further evidence of their limited indications. *Ann Oncol*. 2005;16(2):263-266. doi:10.1093/annonc/mdi063.
5. Rong J, Wang S, Ding Q, Yun M, Zheng Z, Ye S. Comparison of 18 FDG PET-CT and bone scintigraphy for detection of bone metastases in breast cancer patients. A meta-analysis. *Surg Oncol*. 2013;22(2):86-91. doi:10.1016/j.suronc.2013.01.002.
6. Hong S, Li J, Wang S. 18FDG PET-CT for diagnosis of distant metastases in breast cancer patients. A meta-analysis. *Surg Oncol*. 2013;22(2):139-143. doi:10.1016/j.suronc.2013.03.001.
7. Cheng X, Li Y, Liu B, Xu Z, Bao L, Wang J. 18F-FDG PET/CT and PET for evaluation of pathological response to neoadjuvant chemotherapy in breast cancer: a meta-analysis. *Acta Radiol*. 2012;53(6):615-627. doi:10.1258/ar.2012.110603.
8. Simos D, Catley C, van Walraven C, et al. Imaging for distant metastases in women with early-stage breast cancer: a population-based cohort study. *CMAJ*. 2015;187(12):E387-E397. doi:10.1503/cmaj.150003.
9. Crivello ML, Ruth K, Sigurdson ER, et al. Advanced imaging modalities in early stage breast cancer: preoperative use in the United States Medicare population. *Ann Surg Oncol*. 2013;20(1):102-110. doi:10.1245/s10434-012-2571-4.
10. Heller SL, Lourenco AP, Niell BL, et al. ACR Appropriateness Criteria® - Imaging after Mastectomy and Breast Reconstruction. Available at <https://acsearch.acr.org/docs/3155410/Narrative/>. American College of Radiology.
11. Landercasper J, Bailey L, Berry TS, et al. Don't routinely order breast MRI in new breast cancer patients. American Society of Breast Surgeons. <https://www.choosingwisely.org/clinician-lists/breast-surgeons-mri-in-new-breast-cancer-patients/>
12. Chagpar AB, Howard-McNatt M, Chiba A, et al. Factors affecting time to surgery in breast cancer patients. *Am Surg*. 2022;88(4):648-652. doi:10.1177/00031348211054714.
13. Peters NHGM, van Esser S, van den Bosch MAAJ, et al. Preoperative MRI and surgical management in patients with nonpalpable breast cancer: the MONET – randomized controlled trial. *Eur J Cancer*. 2011;47(6):879-886. doi:10.1016/j.ejca.2010.11.035
14. Turnbull L, Brown S, Harvey I, et al. Comparative effectiveness of MRI in breast cancer (COMICE) trial: a randomized controlled trial. *Lancet*. 2010;375(9714):563-571. doi:10.1016/S0140-6736(09)62070-5.
15. Daly MB, Pal T, AIHilli Z, et al. National Comprehensive Cancer Network (NCCN) Guidelines Version 3.2024 – February 12, 2024. Genetic/Familial High-Risk Assessment: Breast, Ovarian, and Pancreatic, available at: https://www.nccn.org/professionals/physician_gls/pdf/genetics_bop.pdf Referenced with permission from the NCCN Clinical Practice Guidelines in Oncology (NCCN Guidelines™) for Genetic/Familial High-Risk Assessment: Breast, Ovarian, and Pancreatic V3.2023 – February 12, 2024. ©2024 National Comprehensive Cancer Network, Inc. All rights reserved. The NCCN Guidelines™ and illustrations herein may not be reproduced in any form for any purpose without the express written permission of the NCCN. To view the most recent and complete version of the NCCN Guidelines™, go online to NCCN.org.
16. Moncrieff M, Pywell S, Snelling A, et al. Effectiveness of SPECT/CT imaging for sentinel node biopsy staging of primary cutaneous melanoma and patient outcomes. *Ann Surg Oncol*. 2022;29(2):767-775. doi:10.1245/s10434-021-10911-4.
17. Quartuccio N, Garau LM, Arnone A, et al. Comparison of 99mTc-labeled colloid SPECT/CT and planar lymphoscintigraphy in sentinel lymph node detection in patients with melanoma: a meta-analysis. *J Clin Med*. 2020;9(6):1680. doi:10.3390/jcm9061680.

18. Bennie G, Vorster M, Buscombe J, Sathekge M. The added value of a single-photon emission computed tomography-computed in sentinel lymph node mapping in patients with breast cancer and malignant melanoma. *World J Nucl Med.* 2015;14(01):41-46. doi:10.4103/1450-1147.150543
19. Ulaner GA, Mankoff DA, Clark AS, et al. Appropriate use criteria for estrogen receptor-targeted pet imaging with 16 α -18f-fluoro-17 β -fluoroestradiol. *J Nucl Med.* 2023;64(3):351-354. doi:10.2967/jnumed.123.265420.

Sarcomas – Bone, Soft Tissue, and GIST (ONC-12)

Guideline

- Bone and Soft Tissue Sarcomas – General Considerations (ONC-12.1)
- Soft Tissue Sarcomas – Initial Work-up/Staging (ONC-12.2)
- Soft Tissue Sarcomas – Restaging/Recurrence (ONC-12.3)
- Soft Tissue Sarcomas Surveillance/Follow-up (ONC-12.4)
- Gastrointestinal Stromal Tumor (GIST) (ONC-12.5)
- Bone Sarcomas – Initial Work-up/Staging (ONC-12.6)
- Bone Sarcomas – Restaging/Recurrence (ONC-12.7)
- Bone Sarcomas – Surveillance/Follow-up (ONC-12.8)
- Benign Bone Tumors – General Considerations (ONC-12.9)
- Benign Bone Tumors – Initial Work-up/Staging (ONC-12.10)
- Benign Bone Tumors – Restaging/Recurrence (ONC-12.11)
- Benign Bone Tumors – Surveillance/Follow-up (ONC-12.12)
- References (ONC-12)

Bone and Soft Tissue Sarcomas – General Considerations (ONC-12.1)

ON.SS.0012.1.A

v2.0.2024

- Sarcomas are tumors of mesenchymal origin, classified as high-, intermediate-, and low-grade (G) tumors (sometimes described as “spindle cell” cancers). They can arise in any bony, cartilaginous, smooth muscle, skeletal muscle, or cardiac muscle tissue.
- Malignant nerve sheath tumor cell types should be imaged as high-grade sarcoma.
- Sarcomas occur in both adult and pediatric individuals, but some are more common in one age group than the other. Unless specified below, individuals age ≥ 18 years old should be imaged according to this guideline section.
- Exceptions include:
 - Rhabdomyosarcoma in individuals of all ages should be imaged according to guidelines in **Rhabdomyosarcoma (RMS) (PEDONC-8.2)** in the Pediatric Oncology Imaging Guidelines
 - Osteogenic sarcoma (Osteosarcoma) in individuals of all ages should be imaged according to guidelines in **Osteogenic Sarcoma (OS) (PEDONC-9.3)** in the Pediatric Oncology Imaging Guidelines
 - Ewing sarcoma and Primitive Neuroectodermal Tumor in individuals of all ages should be imaged according to guidelines in **Ewing Sarcoma and Primitive Neuroectodermal Tumors (ESFT) (PEDONC-9.4)** in the Pediatric Oncology Imaging Guidelines
 - Kaposi’s sarcoma in individuals of all ages should be imaged according to guidelines in **Kaposi’s Sarcoma (ONC-31.10)**
 - See: **Uterine Cancer (ONC-22)** for imaging recommendations for uterine sarcoma
 - Desmoplastic small round cell tumor in individuals of all ages should be imaged according to guidelines in **Non-Rhabdomyosarcoma Soft Tissue Sarcomas (NRSTS) (PEDONC-8.3)**

Soft Tissue Sarcomas – Initial Work-up/Staging (ONC-12.2)

ON.SS.0012.2.A

v2.0.2024

Indication	Imaging Study
Retroperitoneal or intra-abdominal primary site	<u>ANY or ALL of the following:</u> <ul style="list-style-type: none"> • CT Chest with (CPT® 71260) or without (CPT® 71250) contrast • Either CT Abdomen and Pelvis with contrast (CPT® 74177) or MRI Abdomen (CPT® 74183) and MRI Pelvis (CPT® 72197) without and with contrast
<u>ANY of the following:</u> <ul style="list-style-type: none"> • Extremity or trunk primary site • Head or neck primary site 	<u>ANY or ALL of the following:</u> <ul style="list-style-type: none"> • MRI without and with contrast of involved area • CT Chest with (CPT® 71260) or without (CPT® 71250) contrast
<u>ANY of the following:</u> <ul style="list-style-type: none"> • Angiosarcoma • Alveolar soft part sarcoma • Clear cell sarcoma • Epithelioid sarcoma • Hemangiopericytoma • Leiomyosarcoma • Other histologies documented to have propensity for lymphatic spread and deep-seated tumors 	<u>ANY or ALL of the following:</u> <ul style="list-style-type: none"> • MRI without and with contrast of involved area • CT Chest with (CPT® 71260) or without (CPT® 71250) contrast • Either CT Abdomen and Pelvis with contrast (CPT® 74177) or MRI Abdomen (CPT® 74183) and MRI Pelvis (CPT® 72197) without and with contrast
Myxoid round cell liposarcoma	<u>ANY or ALL of the following:</u> <ul style="list-style-type: none"> • MRI without and with contrast of involved area • CT Chest with (CPT® 71260) or without contrast (CPT® 71250) • Either CT Abdomen and Pelvis with contrast (CPT® 74177) or MRI Abdomen (CPT® 74183) and Pelvis (CPT® 72197) without and with contrast • MRI Cervical/Thoracic/Lumbar Spine without and with contrast (CPT® 72156, CPT® 72157, and CPT® 72158)

Indication	Imaging Study
<p><u>ANY of the following:</u></p> <ul style="list-style-type: none"> • Angiosarcoma • Alveolar soft part sarcoma • All individuals with signs/symptoms of brain metastases 	<ul style="list-style-type: none"> • MRI Brain without and with contrast (CPT® 70553)
<p><u>ANY of the following:</u></p> <ul style="list-style-type: none"> • Grade of tumor in doubt following biopsy • Conventional imaging suggests solitary metastasis amenable to surgical resection 	<ul style="list-style-type: none"> • PET/CT (CPT® 78815 or CPT® 78816)
<p>Desmoid Tumors</p>	<p><u>ONE of the following:</u></p> <ul style="list-style-type: none"> • CT without contrast or with contrast of the affected body part • MRI without contrast or without and with contrast of the affected body part • Imaging of lung, lymph node, and metastatic site for these tumors is not indicated
<p>Dermatofibrosarcoma Protuberans (DFSP)</p>	<p><u>ONE of the following:</u></p> <ul style="list-style-type: none"> • CT without contrast or with contrast of the affected body part • MRI without contrast or without and with contrast of the affected body part • CT Chest with (CPT® 71260) or without (CPT® 71250) contrast for: <ul style="list-style-type: none"> • Pulmonary symptoms • Abnormal Chest X-ray • Sarcomatous differentiation

Soft Tissue Sarcomas – Restaging/Recurrence (ONC-12.3)

ON.SS.0012.3.A

v2.0.2024

Indication	Imaging Study
<p><u>ANY of the following:</u></p> <ul style="list-style-type: none"> • After preoperative radiotherapy • After surgical resection • After adjuvant radiotherapy 	<ul style="list-style-type: none"> • MRI without and with contrast or CT with contrast of affected body area • Chest or lymph node imaging is not indicated if no abnormality on previous imaging
<p><u>ANY of the following:</u></p> <ul style="list-style-type: none"> • Differentiate tumor from radiation or surgical fibrosis • Determine response to neoadjuvant therapy • Confirm oligometastatic disease prior to curative intent surgical resection 	<ul style="list-style-type: none"> • PET/CT (CPT® 78815 or CPT® 78816)
<p>Chemotherapy response for individuals with measurable disease</p>	<ul style="list-style-type: none"> • CT with contrast or MRI without and with contrast of affected body area every 2 cycles
<p>Local recurrence suspected</p>	<ul style="list-style-type: none"> • Repeat all imaging for initial workup of specific histology and/or primary site
<p>Preoperative planning prior to resection</p>	<p><u>ANY or ALL of the following:</u></p> <ul style="list-style-type: none"> • MRI without contrast or without and with contrast of involved area • CT (contrast as requested) of involved area
<p>Dermatofibrosarcoma Protuberans (DFSP)</p>	<ul style="list-style-type: none"> • CT without contrast or with contrast of the affected body part or MRI without contrast or without and with contrast of the affected body part • CT Chest with (CPT® 71260) or without (CPT® 71250) contrast for: <ul style="list-style-type: none"> • Pulmonary symptoms • Abnormal Chest X-ray • Sarcomatous differentiation

Soft Tissue Sarcomas Surveillance/Follow-up (ONC-12.4)

ON.SS.0012.4.A

v2.0.2024

Indication	Imaging Study
<p><u>For any of the following:</u></p> <ul style="list-style-type: none"> • Retroperitoneal/intra-abdominal primary site • Angiosarcoma • Epithelioid sarcoma 	<p><u>ANY or ALL of the following every 3 months for 2 years, then every 6 months for 2 more years, then annually:</u></p> <ul style="list-style-type: none"> • CT Chest with (CPT® 71260) or without (CPT® 71250) contrast • CT Abdomen and Pelvis with contrast (CPT® 74177) • CT with contrast or MRI without and with contrast of any other involved body areas
<p>Myxoid/round cell liposarcoma</p>	<p><u>ANY or ALL of the following every 3 months for 2 years, then every 6 months for 2 more years, then annually:</u></p> <ul style="list-style-type: none"> • CT Chest with (CPT® 71260) or without (CPT® 71250) contrast • CT Abdomen and Pelvis with contrast (CPT® 74177) • CT with contrast or MRI without and with contrast of any other involved body areas • MRI Cervical/Thoracic/Lumbar Spine without and with contrast (CPT® 72156, CPT® 72157, and CPT® 72158)
<p>Low-grade/stage I extremity or trunk, primary site</p>	<p><u>ANY or ALL of the following every 6 months for 5 years, then annually thereafter:</u></p> <ul style="list-style-type: none"> • Chest x-ray <ul style="list-style-type: none"> • CT Chest with (CPT® 71260) or without (CPT® 71250) contrast is indicated for new findings on Chest X-ray or new/worsening pulmonary signs/symptoms • CT with contrast, MRI without contrast, or MRI without and with contrast of primary site if primary site not easily evaluated by physical exam
<p>ANY of the following:</p> <ul style="list-style-type: none"> • Extremity/trunk primary site - grade II/stage II or higher • Head/neck primary site 	<p><u>ANY or ALL of the following every 3 months for 2 years, then every 6 months for 2 more years, then annually:</u></p> <ul style="list-style-type: none"> • CT with contrast, MRI without contrast, or MRI without and with contrast of primary site • CT Chest with (CPT® 71260) or without (CPT® 71250) contrast • CT with contrast or MRI without and with contrast of any other involved body areas

Indication	Imaging Study
ANY of the following: <ul style="list-style-type: none">• Angiosarcoma• Alveolar soft part sarcoma• Cardiac sarcoma	In addition to the above studies: <ul style="list-style-type: none">• MRI Brain without and with contrast (CPT® 70553) annually For surveillance of individuals with known brain metastases, see: Brain Metastases (ONC-31.3)
Desmoid tumors	<u>ONE of the following every 6 months for 3 years, then annually:</u> <ul style="list-style-type: none">• CT without contrast or with contrast of the affected body part• MRI without contrast or without and with contrast of the affected body part
Dermatofibrosarcoma Protuberans	<ul style="list-style-type: none">• No routine imaging unless clinical signs/symptoms of recurrence

Gastrointestinal Stromal Tumor (GIST) (ONC-12.5)

ON.SS.0012.5.A

v2.0.2024

General Considerations

- GISTs are mesenchymal neoplasms of the gastrointestinal (GI) tract, mostly found in the stomach and upper small bowel, commonly metastasizing to the liver and abdominal cavity and primarily treated with surgery.
- Recurrence risk of GIST is estimated by prognostic model based on location, size of primary tumor, and mitotic rate per high power field (HPF). High-risk category includes any tumor >5 cm with >5 mitoses/50 HPF and any tumors >10 cm in size regardless of mitotic rate.

Indication	Imaging Study
Suspected/Diagnosis	<ul style="list-style-type: none"> • CT Abdomen and Pelvis with contrast (CPT® 74177)
Initial Work-up/Staging	<ul style="list-style-type: none"> • CT Chest (CPT® 71260) and CT Abdomen and Pelvis (CPT® 74177) with contrast • MRI Abdomen without and with contrast (CPT® 74183) is indicated for evaluation of liver lesions that are equivocal on CT imaging or for preoperative assessment of liver • PET (CPT® 78815) is indicated for evaluation of inconclusive findings on conventional imaging
<u>Monitoring response to treatment (every 8 to 12 weeks) in either of the following:</u> <ul style="list-style-type: none"> • Unresectable primary disease • Metastatic disease 	<u>EITHER</u> of the following: <ul style="list-style-type: none"> • CT Abdomen and Pelvis with contrast (CPT® 74177) • MRI Abdomen without and with contrast (CPT® 74183) and MRI Pelvis without and with contrast (CPT® 72197)
Known or suspected recurrence	<ul style="list-style-type: none"> • <u>CT Abdomen and Pelvis with contrast (CPT® 74177)</u>
<u>Any of the following:</u> <ul style="list-style-type: none"> • Prior evidence of chest disease • Signs or symptoms of chest disease 	<ul style="list-style-type: none"> • CT Chest with contrast (CPT® 71260)
Evaluation of inconclusive findings on conventional imaging	<ul style="list-style-type: none"> • PET/CT (CPT® 78815)

Indication	Imaging Study
<u>Surveillance for any of the following:</u> <ul style="list-style-type: none">Incompletely resectedMetastatic diseaseHigh-risk disease	<ul style="list-style-type: none">CT Abdomen and Pelvis with contrast (CPT® 74177) every 3 months for 3 years, then every 6 months for 2 years, and then annually
Surveillance for all others	<ul style="list-style-type: none">CT Abdomen and Pelvis with contrast (CPT® 74177) every 6 months for 5 years, then annually

Bone Sarcomas – Initial Work-up/Staging (ONC-12.6)

ON.SS.0012.6.A

v2.0.2024

Indication	Imaging Study
<p>Chondrosarcoma</p> <ul style="list-style-type: none"> • Low-grade intra-compartmental • High-grade (grade II or grade III) • Clear cell • Extra-compartmental 	<p><u>ANY or ALL of the following:</u></p> <ul style="list-style-type: none"> • MRI without contrast or without and with contrast of involved area • CT (contrast as requested) of involved area • CT Chest with (CPT® 71260) or without (CPT® 71250) contrast
<p>Dedifferentiated chondrosarcoma</p>	<p>See: Osteogenic Sarcoma (OS) (PEDONC-9.3) for imaging recommendations</p>
<p>Mesenchymal chondrosarcoma</p>	<p>See: Ewing’s Sarcoma Family of Tumors (PEDONC-9.4) for imaging recommendations</p>
<p>Chordoma</p>	<p><u>ANY or ALL of the following:</u></p> <ul style="list-style-type: none"> • MRI without contrast or without and with contrast of involved area • CT (contrast as requested) of involved area • CT Chest with (CPT® 71260) or without (CPT® 71250) contrast • CT Abdomen and Pelvis with contrast (CPT® 74177) • MRI Cervical (CPT® 72156), Thoracic (CPT® 72157), and Lumbar (CPT® 72158) Spine without and with contrast • Bone scan (see also: Nuclear Medicine (NM) Imaging in Oncology (ONC-1.3)) • PET may be approved for inconclusive conventional imaging

Bone Sarcomas – Restaging/Recurrence (ONC-12.7)

ON.SS.0012.7.A

v2.0.2024

Indication	Imaging Study
<p>Chondrosarcoma</p> <ul style="list-style-type: none"> • Low-grade intra-compartmental • High-grade (grade II or grade III) • Clear cell Extra-compartmental 	<p><u>ANY or ALL of the following, after completion of radiotherapy or every 2 cycles of chemotherapy:</u></p> <ul style="list-style-type: none"> • MRI without contrast or without and with contrast of involved area • CT (contrast as requested) of involved area • CT Chest with (CPT® 71260) or without (CPT® 71250) contrast
<p>Dedifferentiated chondrosarcoma</p>	<p>See: Osteogenic Sarcoma (OS) (PEDONC-9.3) for imaging recommendations</p>
<p>Mesenchymal chondrosarcoma</p>	<p>See: Ewing’s Sarcoma Family of Tumors (PEDONC-9.4) for imaging recommendations</p>
<p>Chordoma</p>	<p><u>ANY or ALL of the following, after completion of radiotherapy or every 2 cycles of chemotherapy:</u></p> <ul style="list-style-type: none"> • MRI without contrast or without and with contrast of involved area • CT (contrast as requested) of involved area • Bone scan (see also: Nuclear Medicine (NM) Imaging in Oncology [ONC-1.3]) • PET may be approved for inconclusive conventional imaging

Bone Sarcomas – Surveillance/Follow-up (ONC-12.8)

ON.SS.0012.8.A

v2.0.2024

Indication	Imaging Study
<ul style="list-style-type: none"> Grade I Chondrosarcoma Intra-compartmental Chondrosarcoma 	<p><u>ANY or ALL of the following every 6 months for 2 years, then annually for 10 years:</u></p> <ul style="list-style-type: none"> Plain x-ray of primary site <ul style="list-style-type: none"> MRI without and with contrast is indicated for new findings on plain x-ray or new/worsening clinical symptoms. Chest x-ray <ul style="list-style-type: none"> CT Chest with (CPT® 71260) or without (CPT® 71250) contrast for new findings on chest x-ray, or new/worsening signs/symptoms
<ul style="list-style-type: none"> Grade II or III Chondrosarcoma Clear Cell Chondrosarcoma Extra-compartmental Chondrosarcoma 	<p><u>ANY or ALL of the following every 6 months for 5 years, then annually for 10 years:</u></p> <ul style="list-style-type: none"> Plain x-ray of primary site <ul style="list-style-type: none"> MRI without and with contrast is indicated for new findings on plain x-ray or new/worsening clinical symptoms. Chest x-ray or CT Chest with (CPT® 71260) or CT Chest without (CPT® 71250) contrast
Dedifferentiated chondrosarcoma	See: Osteogenic Sarcoma (OS) (PEDONC-9.3) for imaging recommendations
Mesenchymal chondrosarcoma	See: Ewing’s Sarcoma Family of Tumors (PEDONC-9.4) for imaging recommendations
Chordoma	<ul style="list-style-type: none"> Plain x-ray of primary site every 6 months for 5 years and then annually until year 10 <ul style="list-style-type: none"> MRI without and with contrast is indicated for new findings on plain x-ray or new/worsening clinical symptoms. Chest x-ray every 6 months for 5 years and then annually until year 10 <ul style="list-style-type: none"> CT Chest with (CPT® 71260) or without (CPT® 71250) contrast may be obtained annually or for evaluation of any new findings on chest x-ray or new/worsening signs/symptoms

Benign Bone Tumors – General Considerations (ONC-12.9)

ON.SS.0012.9.A

v2.0.2024

- Variety of diagnoses, including osteoid osteochondroma, chondroblastoma, desmoplastic fibroma, Paget's disease, osteoid osteoma and others.
- Plain x-ray appearance is diagnostic for many benign bone tumors and advanced imaging is generally unnecessary except for preoperative planning.
- MRI without and with contrast is the primary modality for advanced imaging of bone tumors, and can be approved to help narrow differential diagnoses and determine whether biopsy is indicated.
- Some benign bone tumor types carry a risk of malignant degeneration over time, but routine advanced imaging surveillance has not been shown to improve outcomes for these individuals.
- MRI without and with contrast can be approved to evaluate new findings on Plain x-ray new/worsening clinical symptoms not explained by a recent Plain x-ray.
- There are no data to support the use of PET/CT in the evaluation of benign bone tumors, and PET requests should not be approved without biopsy confirmation of a malignancy.
- Other benign bone tumors should be imaged according to guidelines in **Lesion of Bone (MS-10.1)** in the General Musculoskeletal Imaging Guidelines or **Mass Involving Bone (including Lytic and Blastic Metastatic Disease) (PEDMS-3.4)** in the Pediatric Musculoskeletal Imaging Guidelines.

Benign Bone Tumors – Initial Work-up/ Staging (ONC-12.10)

ON.SS.0012.10.A
v2.0.2024

Indication	Imaging Study
Giant Cell Tumor of Bone (GCTB)	<u>ANY or ALL</u> of the following: <ul style="list-style-type: none">• MRI without contrast or without and with contrast of involved area• CT (contrast as requested) of involved area• CT Chest with (CPT® 71260) or without (CPT® 71250) contrast• Bone scan (see also: Nuclear Medicine (NM) in Oncology [ONC-1.3])
Enchondroma	<ul style="list-style-type: none">• MRI without contrast or without and with contrast of primary site

Benign Bone Tumors – Restaging/Recurrence (ONC-12.11)

ON.ss.0012.11.A

v2.0.2024

Indication	Imaging Study
Giant Cell Tumor of Bone (GCTB)	<u>ANY or ALL of the following, after completion of radiotherapy or every 2 cycles of chemotherapy:</u> <ul style="list-style-type: none">• MRI without contrast or without and with contrast of involved area• CT (contrast as requested) of involved area• Bone scan (see also: Nuclear Medicine (NM) Imaging in Oncology [ONC-1.3])
Enchondroma	Plain films of primary site

Benign Bone Tumors – Surveillance/Follow-up (ONC-12.12)

ON.SS.0012.12.A

v2.0.2024

Indication	Imaging Study
Giant Cell Tumor of Bone (GCTB)	<u>ANY or ALL of the following every 6 months for 4 years, then annually thereafter:</u> <ul style="list-style-type: none">• Plain x-ray of primary site<ul style="list-style-type: none">• MRI without and with contrast is indicated for new findings on plain x-ray or new/worsening clinical symptoms.• Chest x-ray<ul style="list-style-type: none">• CT Chest with (CPT® 71260) or without (CPT® 71250) contrast for new findings on chest x-ray, or new/worsening signs/symptoms.
Enchondroma	Plain films of primary site

References (ONC-12)

v2.0.2024

1. Mehren MV, Kane III JM, Armstrong SA, et al. National Comprehensive Cancer Network (NCCN) Guidelines Version 3.2023 – December 12, 2023. Soft Tissue Sarcoma, available at: https://www.nccn.org/professionals/physician_gls/pdf/sarcoma.pdf. Referenced with permission from the NCCN Clinical Practice Guidelines in Oncology (NCCN Guidelines™) for Soft Tissue Sarcoma V3.2023 – December 12, 2023. ©2023 National Comprehensive Cancer Network, Inc. All rights reserved. The NCCN Guidelines™ and illustrations herein may not be reproduced in any form for any purpose without the express written permission of the NCCN. To view the most recent and complete version of the NCCN Guidelines™, go online to NCCN.org.
2. Biermann JS, Hirbe A, Agulnik M, et al. National Comprehensive Cancer Network (NCCN) Guidelines Version 2.2024 – March 12, 2024. Bone cancer, available at: https://www.nccn.org/professionals/physician_gls/pdf/bone.pdf. Referenced with permission from the NCCN Clinical Practice Guidelines in Oncology (NCCN Guidelines™) for Bone cancer V2.2024– March 12, 2024. ©2024 National Comprehensive Cancer Network, Inc. All rights reserved. The NCCN Guidelines™ and illustrations herein may not be reproduced in any form for any purpose without the express written permission of the NCCN. To view the most recent and complete version of the NCCN Guidelines™, go online to NCCN.org.
3. Von Mehren M, Kane III JM, Armstrong SA, et al. National Comprehensive Cancer Network (NCCN) Guidelines Version 1.2023 – March 13, 2023. Gastrointestinal Stromal Tumors (GISTs), available at: https://www.nccn.org/professionals/physician_gls/pdf/gist.pdf. Referenced with permission from the NCCN Clinical Practice Guidelines in Oncology (NCCN Guidelines™) for Gastrointestinal Stromal Tumors (GISTs) V1.2023 – March 13, 2023. ©2023 National Comprehensive Cancer Network, Inc. All rights reserved. The NCCN Guidelines™ and illustrations herein may not be reproduced in any form for any purpose without the express written permission of the NCCN. To view the most recent and complete version of the NCCN™ Guidelines, go online to NCCN.org
4. Nishiguchi T, Mochizuki K, Ohsawa M, et al. Differentiating benign notochordal cell tumors from chordomas: radiographic features on MRI, CT, and tomography. *Am Jour Roentgenol*. 2011;196(3):644-650. doi:10.2214/AJR.10.4460.
5. Van den Abbeele AD. The lessons of GIST-PET and PET/CT: a new paradigm for imaging. *Oncologist*. 2008;13:8-13. doi:10.1634/theoncologist.13-S2-8.
6. Demetri GD, von Mehren M, Antonescu CR, et al. NCCN Task Force report: update on the management of patients with gastrointestinal stromal tumors. *J Natl Compr Canc Netw*. 2010;8(Suppl 2):S42-44.
7. Peng PD, Hyder O, Mavros MN, et al. Management and recurrence patterns of desmoids tumors: a multi-institutional analysis of 211 patients. *Ann Surg Oncol*. 2012;19(13):4036-4042. doi:10.1245/s10434-012-2634-6.
8. Tseng WW, Amini B, Madewell JE. Follow-up of the soft tissue sarcoma patient. *J Surg Oncol*. 2015;111(5):641-645. doi:10.1002/jso.23814.
9. Grotz TE, Donohue JH. Surveillance strategies for gastrointestinal stromal tumors. *J Surg Oncol*. 2011;104(8):921-927. doi:10.1002/jso.21862.
10. Akram J, Wooler G, Lock-Andersen J. Dermatofibrosarcoma protuberans: clinical series, national Danish incidence data and suggested guidelines. *J Plast Surg Hand Surg*. 2014;48(1):67-73. doi:10.3109/2000656X.2013.812969.
11. Puri A, Gulia A, Hawaldar R, Ranganathan P, Badwe RA. Does intensity of surveillance affect survival after surgery for sarcomas? Results of a randomized noninferiority trial. *Clin Orthop Relat Res*. 2014;472(5):1568-1575. doi:10.1007/s11999-013-3385-9.
12. Biermann JS, Adkins DR, Agulnik M, et al. Bone cancer. *J Natl Compr Canc Netw*. 2013;11(6):688-723.

Pancreatic Cancer (ONC-13)

Guideline

Pancreatic Cancer – General Considerations (ONC-13.0)

Pancreatic Cancer – Screening Studies for Pancreatic Cancer (ONC-13.1)

Pancreatic Cancer – Suspected/Diagnosis (ONC-13.2)

Pancreatic Cancer – Initial Work-up/Staging (ONC-13.3)

Pancreatic Cancer – Restaging/Recurrence (ONC-13.4)

Pancreatic Cancer – Surveillance/Follow-up (ONC-13.5)

References (ONC-13)

Pancreatic Cancer – General Considerations (ONC-13.0)

ON.PC.0013.0.A

v2.0.2024

- This guideline refers only to adenocarcinoma of the exocrine pancreas, which accounts for over 90% of pancreatic malignancies. This guideline may also be used for cancer of the Ampulla of Vater.
- Neuroendocrine and carcinoid tumors of the pancreas are not included in this guideline, see: **Neuroendocrine Cancers and Adrenal Tumors (ONC-15)**.

Pancreatic Cancer – Screening Studies for Pancreatic Cancer (ONC-13.1)

ON.PC.0013.1.A

v2.0.2024

- Detailed history of any known inherited syndrome in the individual and detailed family history in first- and second-degree relatives, including the age and lineage, is essential to guide screening recommendations. See table below for age- and risk-specific screening recommendations
- New onset of diabetes in individuals older than 50 has been recognized as a potential indicator of the development of pancreatic cancer. Approximately 1% of individuals in this category are diagnosed with cancer within 3 years. A prediction model has been established which identifies those individuals at greatest risk for pancreatic malignancy. The scoring system, known as ENDPAC (Enriching New-Onset Diabetes for Pancreatic Cancer) is based on 3 discriminatory factors, including change in blood glucose, change in weight, and age of onset at the time of the new diagnosis of diabetes. A score of >3 imparts an elevated risk of pancreatic cancer (3.6%), and these individuals should be screened. Screening is not indicated at this time for scores of 0-2.

Indications	Imaging Study
<p>Individuals who meet BOTH of the following criteria:</p> <ul style="list-style-type: none"> • One or more first- or second-degree relative affected with pancreatic cancer AND • Known mutation carrier of ONE of the following genes: <ul style="list-style-type: none"> • Lynch Syndrome (MLH1, MSH2, or MSH6 gene mutations) • BRCA1, BRCA2 (Familial Breast and Ovarian syndrome) • PALB2 mutation • ATM (Ataxia-Telangiectasia) 	<ul style="list-style-type: none"> • MRI Abdomen without and with contrast (CPT® 74183) starting at age 50 or 10 years earlier than the youngest affected family member, repeat annually
<p>Individuals with family history of pancreatic cancer but no known genetic mutation:</p> <ul style="list-style-type: none"> • Individuals with 2 relatives with pancreatic cancer where one is a first-degree relative • Individuals with 3 or more relatives with pancreatic cancer 	<ul style="list-style-type: none"> • MRI Abdomen without and with contrast (CPT® 74183) starting at age 45 or 10 years earlier than the youngest affected family member, repeat annually

Indications	Imaging Study
Pancreatic Cancer Kindred (individuals who have at least one first-degree relative with pancreatic cancer who in turn also has a first-degree relative with pancreatic cancer) and NO known genetic germline mutations	<ul style="list-style-type: none"> MRI Abdomen without and with contrast (CPT® 74183) starting at age 50 or 10 years earlier than the youngest affected family member, repeat annually
Hereditary Pancreatitis (PRSS1, CPA1, and CTRC gene mutations)	<ul style="list-style-type: none"> MRI Abdomen without and with contrast (CPT® 74183) beginning at age 40 or 20 years after the first pancreatitis attack, repeat annually.
Peutz-Jeghers Syndrome (LKB1/STK11 gene mutation)	<ul style="list-style-type: none"> MRI Abdomen without and with contrast (CPT® 74183) starting at age 30, repeat annually
CDKN2A mutation (also known as p16, p16INK4a, and MTS1, FAMM-Familial Atypical Multiple Melanoma and Mole Syndrome)	<ul style="list-style-type: none"> MRI Abdomen without and with contrast or MRCP (CPT® 74183) beginning at age 40, repeat annually.
Screening MRI reveals cystic lesion of the pancreas	<ul style="list-style-type: none"> Repeat MRI Abdomen without and with contrast (CPT® 74183) in 6 months
Screening MRI reveals indeterminate solid lesion	<ul style="list-style-type: none"> CT Abdomen with contrast – pancreatic protocol (CPT® 74160) May repeat MRI Abdomen without and with contrast (CPT® 74183) in 3 months after the CT scan
Screening MRI reveals pancreatic stricture and/or dilation ≥ 6 mm without a mass	<ul style="list-style-type: none"> CT Abdomen with contrast – pancreatic protocol (CPT® 74160) May repeat MRI Abdomen without and with contrast (CPT® 74183) in 3 months after the CT scan
New onset diabetes in adults with ENDPAC score of ≥ 3	<ul style="list-style-type: none"> CT Abdomen without and with contrast (CPT® 74170) or MRI Abdomen without and with contrast (CPT® 74183) at baseline; if negative, can be repeated once after 6 months

Pancreatic Cancer – Suspected/Diagnosis (ONC-13.2)

ON.PC.0013.2.A

v2.0.2024

Indication	Imaging Study
For any suspected symptoms only (e.g. epigastric pain, weight loss, pain radiating to back, etc.)	<ul style="list-style-type: none"> • Ultrasound (CPT® 76700 or CPT® 76705) • Also see: <u>Epigastric Pain and Dyspepsia (AB-2.5)</u>
Symptoms suspicious for pancreatic cancer AND any one of the following: <ul style="list-style-type: none"> • Abnormal labs (e.g. elevated CA 19-9, ALKP, bilirubin, or GGTP) • Abnormal physical exam findings (e.g. abdominal mass) • Abnormal or non-diagnostic ultrasound/ERCP 	<u>Any ONE of the following:</u> <ul style="list-style-type: none"> • CT Pancreatic Protocol (CT Abdomen with contrast with dual phase imaging, CPT® 74160) • MRI Abdomen without and with contrast (CPT® 74183)
Preoperative studies for potentially resectable tumors without confirmed histologic diagnosis	<ul style="list-style-type: none"> • See: <u>Pancreatic Cancer – Initial Work-up/Staging (ONC-13.3)</u>

Pancreatic Cancer – Initial Work-up/Staging (ONC-13.3)

ON.PC.0013.3.A

v2.0.2024

Indication	Imaging Study
All individuals	<ul style="list-style-type: none">• CT Chest with contrast (CPT® 71260)• CT Abdomen and Pelvis with (CPT® 74177) or CT Abdomen and Pelvis without and with contrast (CPT® 74178)• EUS
For any of the following: <ul style="list-style-type: none">• Preoperative planning• CT insufficient to determine resectability• Evaluation of indeterminate liver lesions	<ul style="list-style-type: none">• MRI Abdomen without and with contrast (CPT® 74183)
No evidence of metastatic disease on CT or MRI AND any of the following high-risk features: <ul style="list-style-type: none">• Borderline resectable disease• Markedly elevated CA 19-9• Large primary tumor(s)• Enlarged regional lymph nodes	<ul style="list-style-type: none">• PET/CT (CPT® 78815)

Pancreatic Cancer – Restaging/Recurrence (ONC-13.4)

ON.PC.0013.4.A

v2.0.2024

Indication	Imaging Study
For ANY of the following: <ul style="list-style-type: none"> • After neoadjuvant chemoradiation • Post-operative baseline • Suspected recurrence 	<ul style="list-style-type: none"> • CT Chest with contrast (CPT® 71260) • CT Abdomen and Pelvis with (CPT® 74177) or CT Abdomen and Pelvis without and with contrast (CPT® 74178) • CT with contrast of other involved or symptomatic areas
Unresectable disease or metastatic disease on chemotherapy	<u>Every 2 cycles of treatment (commonly every 6 to 8 weeks):</u> <ul style="list-style-type: none"> • CT Chest with contrast (CPT® 71260) • CT Abdomen and Pelvis with (CPT® 74177) or CT Abdomen and Pelvis without and with contrast (CPT® 74178) • CT with contrast of other involved or symptomatic areas
Unexplained elevated liver enzymes or inconclusive recent CT abnormality	<ul style="list-style-type: none"> • MRI Abdomen without and with contrast (CPT® 74183)
If complete surgical resection was initial therapy	<ul style="list-style-type: none"> • See: <u>Pancreatic Cancer – Surveillance/Follow-up for surveillance imaging (ONC-13.5)</u>

Pancreatic Cancer – Surveillance/Follow-up (ONC-13.5)

ON.PC.0013.5.A
v2.0.2024

Indication	Imaging Study
All individuals	<p><u>Every 3 months for 2 years, then annually:</u></p> <ul style="list-style-type: none">• CT Chest with contrast (CPT® 71260) <p><u>And ANY ONE of the following:</u></p> <ul style="list-style-type: none">• CT Abdomen and Pelvis with contrast (CPT® 74177)• MRI Abdomen without and with contrast (CPT® 74183) and MRI Pelvis without and with contrast (CPT® 72197)
Measurable metastatic disease on maintenance therapy or being monitored off therapy	<p><u>Every 3 months for up to 5 years after completion of definitive treatment:</u></p> <ul style="list-style-type: none">• CT Chest with contrast (CPT® 71260)• CT Abdomen and Pelvis with contrast (CPT® 74177)

References (ONC-13)

v2.0.2024

1. Tempero MA, Malafa MP, Benson III AB, et al. National Comprehensive Cancer Network (NCCN) Guidelines Version 1.2024 – December 13, 2023. Pancreatic Adenocarcinoma, available at: https://www.nccn.org/professionals/physician_gls/pdf/pancreatic.pdf Referenced with permission from the NCCN Clinical Practice Guidelines in Oncology (NCCN Guidelines™) for Pancreatic Adenocarcinoma V1.2024 – December 13, 2023. ©2023 National Comprehensive Cancer Network, Inc. All rights reserved. The NCCN Guidelines™ and illustrations herein may not be reproduced in any form for any purpose without the express written permission of the NCCN. To view the most recent and complete version of the NCCN Guidelines™, go online to NCCN.org.
2. Syngal S, Brand RE, Church JM, et al. ACG clinical guideline: genetic testing and management of hereditary gastrointestinal cancer syndromes. *Am. J. Gastroenterol.* 2015;110(2):223-262. doi:10.1038/ajg.2014.435.
3. Canto MI, Harinck F, Hruban RH, et al. International Cancer of the Pancreas Screening (CAPS) consortium summit on the management of patients with increased risk for familial pancreatic cancer. *Gut.* 2013;62(3):339-347. doi:10.1136/gutjnl-2012-303108.
4. U.S. Preventive Services Task Force. *Screening for pancreatic cancer: recommendation statement.* Rockville, Maryland: Agency for Healthcare Research and Quality (AHRQ); 2004.
5. Heinrich S, Goerres GW, Schafer M, et al. Positron emission tomography/computed tomography influences on the management of resectable pancreatic cancer and its cost-effectiveness. *Ann Surg.* 2005;242(2):235-243.
6. Gemmel C, Eickhoff A, Helmstädter L, Riemann JF. Pancreatic cancer screening: state of the art. *Expert Rev Gastroenterol Hepatol.* 2009;3(1):89-96. doi:10.1586/17474124.3.1.89.
7. Al-Hawary MM, Francis IR, Chari ST, et al. Pancreatic ductal adenocarcinoma radiology reporting template: consensus statement of the Society of Abdominal Radiology and the American Pancreatic Association. *Gastroenterology.* 2014;146(1):291-304. doi:10.1053/j.gastro.2013.11.004.
8. Tersmette AC, Petersen GM, Offerhaus GJ. Increased risk of incident pancreatic cancer among first-degree relatives of patients with familial pancreatic cancer. *Clin Cancer Res.* 2001;7(3):738-44.
9. Tzeng CW, Abbott DE, Cantor SB et al. Frequency and intensity of postoperative surveillance after curative treatment of pancreatic cancer: a cost-effectiveness analysis. *Ann Surg Oncol.* 2013;20(7):2197-2203. doi:10.1245/s10434-013-2889-6.
10. Furman MJ, Lambert LA, Sullivan ME, Whalen GF. Rational follow-up after curative cancer resection. *Journal of Clinical Oncology.* 2013;31(9):1130-1133. doi:10.1200/JCO.2012.46.4438.
11. Tzeng C, Fleming J, Lee J, et al. Yield of clinical and radiographic surveillance in patients with resected pancreatic adenocarcinoma following multimodal therapy. *HPB.* 2012;14(6):365-372. doi:10.1111/j.1477-2574.2012.00445.x.
12. Sharma, A, Kandlakunta H, Nagpal SJS, et.al. Model to determine risk of pancreatic cancer in patients with new-onset diabetes. *Gastroenterology.* 2018;155(3):730-739.
13. Goggins M, Overbeek KA, Brand R, et. al. Management of patients with increased risk for familial pancreatic cancer: updated recommendations from the International Cancer of the Pancreas Screening Consortium. *Gut.* 2020;69(1):7-17. doi:10.1136/gutjnl-2019-319352.

Upper GI Cancers (ONC-14)

Guideline

Hepatocellular Carcinoma (HCC) – General Considerations
(ONC-14.1)

Hepatocellular Carcinoma (HCC) – Suspected/Diagnosis (ONC-14.2)

Hepatocellular Carcinoma (HCC) – Initial Work-up/Staging (ONC-14.3)

Hepatocellular Carcinoma (HCC) – Restaging/Recurrence (ONC-14.4)

Hepatocellular Carcinoma (HCC) – Surveillance/Follow-up (ONC-14.5)

Gallbladder and Biliary Tumors – Initial Work-up/Staging (ONC-14.6)

Gallbladder and Biliary Tumors – Restaging/Recurrence (ONC-14.7)

Gallbladder and Biliary Tumors – Surveillance/Follow-up (ONC-14.8)

Gastric Cancer – Initial Work-up/Staging (ONC-14.9)

Gastric Cancer – Restaging/Recurrence (ONC-14.10)

Gastric Cancer – Surveillance/Follow-up (ONC-14.11)

References (ONC-14)

Hepatocellular Carcinoma (HCC) – General Considerations (ONC-14.1)

ON.GI.0014.1.A

v2.0.2024

- A biopsy is not always required for the diagnosis of Hepatocellular carcinoma (HCC). A dedicated triple-phase CT or MRI may be obtained. MRI with contrast is the test of choice for the evaluation of liver masses. It offers soft tissue contrast resolution superior to CT as well as the possibility of using two different contrast agents, one of which is more blood flow based and the other which also is blood flow based and demonstrates hepatobiliary function (Eovist). Classical imaging findings include:
 - Arterial phase hyperenhancement
 - Venous phase washout appearance
 - Capsule appearance
 - Threshold growth
- For individuals who are high-risk for developing HCC (cirrhosis, chronic Hepatitis B or current or prior HCC), if the liver lesion is >1 cm with 2 classic enhancements on triple-phase CT or MRI, the diagnosis is confirmatory and biopsy is not needed.
- For lesions less than 1 cm or with less than 2 classical enhancements or for any liver lesions in individuals who are not high-risk, a biopsy is needed for histological confirmation. PET/CT scan is considered experimental, investigational, or unproven for the diagnosis or staging of HCC

Hepatocellular Carcinoma (HCC) – Suspected/Diagnosis (ONC-14.2)

ON.GI.0014.2.A

v2.0.2024

- See: **Chronic Liver Disease, Cirrhosis and Screening for HCC (AB-26.1)** in the Abdomen Imaging Guidelines
- See: **Liver Lesion Characterization (AB-29.1)** in the Abdomen Imaging Guidelines

Hepatocellular Carcinoma (HCC) – Initial Work-up/Staging (ONC-14.3)

ON.GI.0014.3.A

v2.0.2024

Indication	Imaging Study
All individuals	<ul style="list-style-type: none">• CT Chest with contrast (CPT® 71260) or CT Chest without contrast (CPT® 71250) <p><u>And ONE of the following:</u></p> <ul style="list-style-type: none">• CT Abdomen with contrast (CPT® 74160)• CT Abdomen without and with contrast (CPT® 74170)• CT Abdomen and Pelvis with contrast (CPT® 74177) or without and with contrast (CPT® 74178)• MRI Abdomen (CPT® 74183) and MRI Pelvis (CPT® 72197) without and with contrast

Hepatocellular Carcinoma (HCC) – Restaging/Recurrence (ONC-14.4)

ON.GI.0014.4.A

v2.0.2024

Indication	Imaging Study
<p><u>ONE of the following:</u></p> <ul style="list-style-type: none"> • After initial therapy • For suspected recurrence or new liver lesions • Individuals receiving systemic therapy (every 2 cycles) 	<ul style="list-style-type: none"> • CT Chest with contrast (CPT® 71260) or CT Chest without contrast (CPT® 71250) <p><u>ONE of the following:</u></p> <ul style="list-style-type: none"> • CT Abdomen with contrast (CPT® 74160) • CT Abdomen without and with contrast (CPT® 74170) • CT Abdomen and Pelvis with contrast (CPT® 74177) or CT Abdomen and Pelvis without and with contrast (CPT® 74178) • MRI Abdomen (CPT® 74183) and MRI Pelvis (CPT® 72197) without and with contrast
<p>Hepatocellular Carcinoma treated with embolization</p>	<ul style="list-style-type: none"> • CTA Abdomen (CPT® 74175) can be approved immediately prior to embolization <p><u>ONE of the following, immediately prior to and 1 month post-ablation:</u></p> <ul style="list-style-type: none"> • MRI Abdomen without and with contrast (CPT® 74183) • CT Abdomen without and with contrast (CPT® 74170) <p>See: Liver Metastases (ONC-31.2) for imaging studies indicated prior to and post-embolization</p>
<p>Hepatocellular Carcinoma awaiting liver transplant</p>	<ul style="list-style-type: none"> • See: Liver Transplant, Pre-Transplant (AB-42.1) in the Abdomen Imaging Guidelines

Hepatocellular Carcinoma (HCC) – Surveillance/Follow-up (ONC-14.5)

ON.GI.0014.5.A

v2.0.2024

Indication	Imaging Study
<p><u>Hepatocellular Carcinoma:</u></p> <ul style="list-style-type: none"> • Treated with surgical resection • Treated with embolization • Being monitored off therapy 	<p><u>Every 3 months for 2 years, then every 6 months until year 5:</u></p> <ul style="list-style-type: none"> • CT Chest with contrast (CPT® 71260) or CT Chest without contrast (CPT® 71250) <p><u>And ONE of the following:</u></p> <ul style="list-style-type: none"> • CT Abdomen with contrast (CPT® 74160) • CT Abdomen without and with contrast (CPT® 74170) • CT Abdomen and Pelvis with contrast (CPT® 74177) or without and with contrast (CPT® 74178) • MRI Abdomen (CPT® 74183) and Pelvis (CPT® 72197) without and with contrast
<p>Hepatocellular Carcinoma treated with liver transplant</p>	<ul style="list-style-type: none"> • See: <u>Liver Transplant, Post-transplant Imaging (AB-42.3)</u> in the Abdomen Imaging Guidelines

Gallbladder and Biliary Tumors – Initial Work-up/Staging (ONC-14.6)

ON.GI.0014.6.A
v2.0.2024

Indication	Imaging Study
All individuals	<ul style="list-style-type: none">CT Chest with contrast (CPT® 71260) or CT Chest without contrast (CPT® 71250) <p>And ONE of the following:</p> <ul style="list-style-type: none">CT Abdomen with contrast (CPT® 74160)CT Abdomen without and with contrast (CPT® 74170)CT Abdomen and Pelvis with contrast (CPT® 74177)MRI Abdomen (CPT® 74183) and MRI Pelvis (CPT® 72197) without and with contrast
Inconclusive findings on conventional imaging	<ul style="list-style-type: none">PET/CT (CPT® 78815)

Gallbladder and Biliary Tumors – Restaging/Recurrence (ONC-14.7)

ON.GI.0014.7.A

v2.0.2024

Indication	Imaging Study
<p><u>ANY of the following:</u></p> <ul style="list-style-type: none">• After initial therapy• For suspected recurrence or new liver lesions• Individuals receiving systemic chemotherapy (every 2 cycles)	<ul style="list-style-type: none">• CT Chest with contrast (CPT® 71260) or CT Chest without contrast (CPT® 71250) <p><u>And ONE of the following:</u></p> <ul style="list-style-type: none">• CT Abdomen with contrast (CPT® 74160)• CT Abdomen and Pelvis with contrast (CPT® 74177)• MRI Abdomen (CPT® 74183) and MRI Pelvis (CPT® 72197) without and with contrast
<p>Inconclusive findings on conventional imaging</p>	<ul style="list-style-type: none">• PET/CT (CPT® 78815)

Gallbladder and Biliary Tumors – Surveillance/Follow-up (ONC-14.8)

ON.GI.0014.8.A

v2.0.2024

Indication	Imaging Study
All individuals	<u>Every 6 months for 2 years, and then annually up to year 5:</u> <ul style="list-style-type: none">• CT Chest with contrast (CPT® 71260) or CT Chest without contrast (CPT® 71250) <u>And ONE of the following:</u> <ul style="list-style-type: none">• CT Abdomen with contrast (CPT® 74160)• CT Abdomen without and with contrast (CPT® 74170)• CT Abdomen and Pelvis with contrast (CPT® 74177)• MRI Abdomen (CPT® 74183) and MRI Pelvis (CPT® 72197) without and with contrast
Biliary carcinoma treated with liver transplant	See: <u>Liver Transplant, Post-transplant Imaging (AB-42.3)</u> in the Abdomen Imaging Guidelines

Gastric Cancer – Initial Work-up/Staging (ONC-14.9)

ON.GI.0014.9.A
v2.0.2024

Indication	Imaging Study
All individuals	<ul style="list-style-type: none">CT Chest with contrast (CPT® 71260)CT Abdomen and Pelvis with contrast (CPT® 74177)
Gastric cancer ≥T2 or higher with no metastatic disease by conventional imaging	<ul style="list-style-type: none">PET/CT (CPT® 78815)

Gastric Cancer – Restaging/Recurrence (ONC-14.10)

ON.GI.0014.10.A

v2.0.2024

Indication	Imaging Study
<ul style="list-style-type: none">• After initial therapy for presumed surgically resectable disease• Post curative chemoradiation being treated without surgery• For suspected recurrence	<ul style="list-style-type: none">• CT Chest with contrast (CPT® 71260) and CT Abdomen and Pelvis with contrast (CPT® 74177)
Monitoring response to chemotherapy (every 2 cycles, ~every 6-8 weeks) for: <ul style="list-style-type: none">• Unresected primary disease• Metastatic disease	<ul style="list-style-type: none">• CT Abdomen and Pelvis with contrast (CPT® 74177)• CT Chest with contrast (CPT® 71260) for:<ul style="list-style-type: none">• New/worsening pulmonary symptoms• Abnormal chest x-ray findings• Known prior pulmonary involvement
New liver lesion(s) and primary site controlled	<ul style="list-style-type: none">• CT Abdomen without and with contrast (CPT® 74170) or MRI Abdomen without and with contrast (CPT® 74183)
Inconclusive findings on conventional imaging	<ul style="list-style-type: none">• PET/CT (CPT® 78815)

Gastric Cancer – Surveillance/Follow-up (ONC-14.11)

ON.GI.0014.11.A

v2.0.2024

Indication	Imaging Study
Stage I (treated with resection alone)	<ul style="list-style-type: none">No routine imaging unless clinical signs/symptoms of recurrence
<u>ANY of the following:</u> <ul style="list-style-type: none">Stage I treated with systemic therapyStages II-IIIStage IV - Metastatic disease (post definitive treatment of all measurable disease or being observed off therapy)	Every 6 months for 2 years, and then annually for 3 more years: <ul style="list-style-type: none">CT Chest with contrast (CPT® 71260) and CT Abdomen and Pelvis with contrast (CPT® 74177)
Measurable metastatic disease on maintenance therapy or being monitored off therapy	Every 3 months for up to 5 years after completion of active treatment: <ul style="list-style-type: none">CT Chest with contrast (CPT® 71260)CT Abdomen and Pelvis with contrast (CPT® 74177)

References (ONC-14)

v2.0.2024

1. Ajani JA, D'Amico TA, Bentrem DJ et al. National Comprehensive Cancer Network (NCCN) Guidelines Version 1.2023 – March 10, 2023. Gastric cancer, available at: https://www.nccn.org/professionals/physician_gls/pdf/gastric.pdf Referenced with permission from the NCCN Clinical Practice Guidelines in Oncology (NCCN Guidelines™) for Gastric cancer V1.2023 – March 10, 2023. ©2023 National Comprehensive Cancer Network, Inc. All rights reserved. The NCCN Guidelines™ and illustrations herein may not be reproduced in any form for any purpose without the express written permission of the NCCN. To view the most recent and complete version of the NCCN Guidelines™, go online to NCCN.org.
2. Benson AB, D'Angelica MI, Abrams T, et al. National Comprehensive Cancer Network (NCCN) Guidelines Version 1.2023—March 10, 2023, Hepatocellular Carcinoma, available at: https://www.nccn.org/professionals/physician_gls/pdf/hcc.pdf, Referenced with permission from the NCCN Clinical Practice Guidelines in Oncology (NCCN Guidelines™) for Hepatocellular Carcinoma V1.2023 3/10/2023. ©2023 National Comprehensive Cancer Network, Inc. All rights reserved. The NCCN Guidelines™ and illustrations herein may not be reproduced in any form for any purpose without the express written permission of the NCCN. To view the most recent and complete version of the NCCN Guidelines™, go online to NCCN.org.
3. Benson AB, D'Angelica MI, Abrams T, et al. National Comprehensive Cancer Network (NCCN) Guidelines Version 2.2023—May 10, 2023, Biliary Tract Cancers, available at: https://www.nccn.org/professionals/physician_gls/pdf/btc.pdf, Referenced with permission from the NCCN Clinical Practice Guidelines in Oncology (NCCN Guidelines™) for Biliary Tract Cancers V2.2023 5/10/2023. ©2023 National Comprehensive Cancer Network, Inc. All rights reserved. The NCCN Guidelines™ and illustrations herein may not be reproduced in any form for any purpose without the express written permission of the NCCN. To view the most recent and complete version of the NCCN Guidelines™, go online to NCCN.org.
4. Vallböhmer D, Hölscher AH, Schnieder PM, et al. [18F]-fluorodeoxyglucose-positron emission tomography for the assessment of histopathologic response and prognosis after completion of neoadjuvant chemotherapy in gastric cancer. *J Surg Oncol*. 2010;102(2):135-140. doi:10.1002/jso.21592.
5. Zou H, Zhao Y. 18FDG PET-CT for detecting gastric cancer recurrence after surgical resection: a meta-analysis. *Surg Oncol*. 2013;22(3):162-166. doi:10.1016/j.suronc.2013.05.001.
6. Bridgewater J, Galle PR, Khan SA, et al. Guidelines for the diagnosis and management of intrahepatic cholangiocarcinoma. *J Hepatol*. 2014;60(6):1268-1289. doi:10.1016/j.jhep.2014.01.021.
7. Khan SA, Davidson BR, Goldin RD, et al. Guidelines for the diagnosis and treatment of cholangiocarcinoma: an update. *Gut*. 2012;61(12):1657-1669. doi:10.1136/gutjnl-2011-301748.
8. Benson AB 3rd, D'Angelica MI, Abrams TA, et al. Hepatobiliary cancers, version 2.2014. *J Natl Compr Canc Netw*. 2014;12(8):1152-1182.

Neuroendocrine Cancers and Adrenal Tumors (ONC-15)

Guideline

- General Considerations (ONC-15.1)
- Gastrointestinal/Pancreatic Neuroendocrine Cancers – Suspected/Diagnosis (ONC-15.2)
- Gastrointestinal/Pancreatic Neuroendocrine Cancers – Initial Work-up/Staging (ONC-15.3)
- Gastrointestinal/Pancreatic Neuroendocrine Cancers – Restaging/Recurrence (ONC-15.4)
- Gastrointestinal/Pancreatic Neuroendocrine Cancers – Surveillance (ONC-15.5)
- Bronchopulmonary or Thymic Carcinoid – Initial Staging (ONC-15.6)
- Bronchopulmonary or Thymic Carcinoid – Restaging/Recurrence (ONC-15.7)
- Bronchopulmonary or Thymic Carcinoid – Surveillance (ONC-15.8)
- Adrenal Tumors – Suspected/Diagnosis (ONC-15.9)
- Adrenal Tumors – Initial Work-up/Staging (ONC-15.10)
- Adrenal Tumors – Restaging/Recurrence (ONC-15.11)
- Adrenal Tumors – Surveillance (ONC-15.12)
- Adrenocortical Carcinoma (ONC-15.13)
- References (ONC-15)

General Considerations (ONC-15.1)

ON.NA.0015.1.A

v2.0.2024

This guideline includes low-grade or well-differentiated carcinoid and endocrine tumors of the lung, thymus, pancreas, gastrointestinal tract or unknown primary site; including insulinoma, glucagonoma, VIPoma, gastrinoma, somatostatinoma and others as well as catecholamine-secreting tumors of the adrenal gland such as pheochromocytoma, paraganglioma, adrenocortical carcinoma, and others.

- For poorly-differentiated or high-grade small cell or large cell neuroendocrine tumors arising outside the lung or from an unknown primary site, see: **Extrathoracic Small Cell and Large Cell Neuroendocrine Tumors (ONC-31.8)**.
- For poorly-differentiated or high grade neuroendocrine tumors of the lung, see: **Small Cell Lung Cancer (ONC-7)**.
- Neuroblastoma, ganglioneuroblastoma, and ganglioneuroma occurring in adults should be imaged according to **Neuroblastoma (PEDONC-6)** in the Pediatric Oncology Imaging Guidelines.
- Many are associated with Multiple Endocrine Neoplasia (MEN) familial syndromes. – See: **Multiple Endocrine Neoplasias (MEN) (PEDONC-2.8)** in the Pediatric Oncology Imaging Guidelines for screening recommendations.
- Somatostatin receptor (SSR) based imaging is more sensitive and specific for evaluation of well-differentiated neuroendocrine tumors and may be performed using ^{111}In DTPA Octreotide scintigraphy or PET/CT scan with SSR radiotracers (such as ^{68}Ga -DOTATATE, ^{68}Ga -DOTATOC, or ^{64}Cu -DOTATATE). This study is not part of evaluation of poorly-differentiated or high-grade neuroendocrine tumors, which are imaged according to: **Extrathoracic Small Cell and Large Cell Neuroendocrine Tumors (ONC-31.8)**.

Gastrointestinal/Pancreatic Neuroendocrine Cancers – Suspected/ Diagnosis (ONC-15.2)

ON.NA.0015.2.A
v2.0.2024

Indication	Imaging Study
<ul style="list-style-type: none"> • Systemic symptoms strongly suggestive of functioning neuroendocrine tumor • Suspicious findings on other imaging studies • Unexplained elevation in ANY of the following: <ul style="list-style-type: none"> • Chromogranin A • 5HIAA • Insulin • VIP • Glucagon • Gastrin • Substance P • Serotonin • Somatostatin 	<p><u>ANY of the following:</u></p> <ul style="list-style-type: none"> • CT Abdomen and Pelvis with contrast (CPT® 74177) or without and with contrast (CPT® 74178) OR MRI Abdomen (CPT® 74183) and MRI Pelvis (CPT® 72197) without and with contrast • CT Chest with contrast (CPT® 71260) or CT Chest without contrast (CPT® 71250) • CT with contrast or MRI without and with contrast of any other symptomatic body areas
<ul style="list-style-type: none"> • Continued suspicion with negative/inconclusive CT or MRI 	<p><u>ONE of the following:</u></p> <ul style="list-style-type: none"> • Octreotide scan <ul style="list-style-type: none"> • Any one of the following planar imaging codes - CPT® 78801, 78802, or 78804 AND • Any one of the follow SPECT/SPECT-CT codes - CPT® 78803, 78830, 78831, 78832 • PET/CT scan (CPT® 78815) with any ONE of the following SSR radiotracers: <ul style="list-style-type: none"> • ⁶⁸Ga-DOTATATE • ⁶⁸Ga-DOTATOC • ⁶⁴Cu-DOTATATE

Gastrointestinal/Pancreatic Neuroendocrine Cancers – Initial Work-up/Staging (ONC-15.3)

ON.NA.0015.3.A
v2.0.2024

Indication	Imaging Study
GI or pancreatic neuroendocrine (carcinoid) tumors	<p><u>If not already done:</u></p> <ul style="list-style-type: none"> CT Abdomen and Pelvis with contrast (CPT® 74177) or without and with contrast (CPT® 74178) OR MRI Abdomen (CPT® 74183) and Pelvis (CPT® 72197) without and with contrast is indicated CT Chest with contrast (CPT® 71260) or CT Chest without contrast (CPT® 71250)
Inconclusive CT or MRI scans	<p><u>ONE of the following:</u></p> <ul style="list-style-type: none"> Octreotide scan (ANY ONE of the following): <ul style="list-style-type: none"> Any one of the following planar imaging codes - CPT® 78801, 78802, or 78804 AND Any one of the following SPECT/SPECT-CT codes - CPT® 78803, 78830, 78831, 78832 PET/CT scan (CPT® 78815) with any ONE of the following SSR radiotracers: <ul style="list-style-type: none"> ⁶⁸Ga-DOTATATE ⁶⁸Ga-DOTATOC ⁶⁴Cu-DOTATATE
<p><u>ANY of the following:</u></p> <ul style="list-style-type: none"> Markers fail to normalize after complete resection AND CT/MRI and somatostatin-receptor based study are negative Biopsy-proven neuroendocrine tumor of unknown primary site AND CT/MRI and somatostatin-receptor based study are negative 	<ul style="list-style-type: none"> FDG-PET/CT scan (CPT® 78815)

Gastrointestinal/Pancreatic Neuroendocrine Cancers – Restaging/ Recurrence (ONC-15.4)

ON.NA.0015.4.A
v2.0.2024

Indication	Imaging Study
All after surgical resection	<ul style="list-style-type: none"> See: <u>Gastrointestinal/Pancreatic Neuroendocrine Cancers – Surveillance (ONC-15.5)</u>
Unresectable/metastatic disease on treatment with somatostatin analogues	<ul style="list-style-type: none"> CT of involved body area no more frequently than every 3 months
Unresectable/metastatic disease on treatment with chemotherapy	<ul style="list-style-type: none"> CT of involved body area every 2 cycles (6 to 8 weeks)
Progression of symptoms or elevation of tumor markers	<ul style="list-style-type: none"> CT Chest without contrast (CPT® 71250) or CT Chest with contrast (CPT® 71260) <p><u>And ONE of the following:</u></p> <ul style="list-style-type: none"> CT Abdomen and Pelvis with contrast (CPT® 74177) CT Abdomen and Pelvis without and with contrast (CPT® 74178) MRI Abdomen (CPT® 74183) and MRI Pelvis (CPT® 72197) without and with contrast
Continued suspicion for recurrence with negative or inconclusive CT or MRI	<p><u>ONE of the following:</u></p> <ul style="list-style-type: none"> Octreotide scan: <ul style="list-style-type: none"> Any one of the following planar imaging codes - CPT® 78801, 78802, or 78804 AND Any one of the following SPECT/SPECT-CT codes - CPT® 78803, 78830, 78831, 78832 PET/CT scan (CPT® 78815) with any ONE of the following SSR radiotracers: <ul style="list-style-type: none"> ⁶⁸Ga-DOTATATE ⁶⁸Ga-DOTATOC ⁶⁴Cu-DOTATATE

Indication	Imaging Study
To assess candidacy for peptide receptor radionuclide therapy (PRRT) with Lutetium ¹⁷⁷ Lu-dotatate	<ul style="list-style-type: none">• PET/CT scan (CPT[®] 78815) with any ONE of the following SSR radiotracers:<ul style="list-style-type: none">• ⁶⁸Ga-DOTATATE• ⁶⁸Ga-DOTATOC• ⁶⁴Cu-DOTATATE

Gastrointestinal/Pancreatic Neuroendocrine Cancers – Surveillance (ONC-15.5)

ON.NA.0015.5.A
v2.0.2024

Indication	Imaging Study
<p><u>ANY of the following:</u></p> <ul style="list-style-type: none"> Appendix carcinoid ≤ 2 cm, completely resected Rectal carcinoid < 1 cm, completely resected Gastric carcinoid treated with complete endoscopic resection 	<ul style="list-style-type: none"> Advanced imaging is not routinely indicated for surveillance
Rectal carcinoid 1-2 cm, completely resected	<ul style="list-style-type: none"> MRI Pelvis without and with contrast (CPT® 72197) at 6 and 12 months post resection. If clear, no further surveillance imaging indicated
All other GI neuroendocrine tumors (stomach, large and small intestine)	<ul style="list-style-type: none"> CT Abdomen and Pelvis with contrast (CPT® 74177) once at 3 to 12 months postoperatively and annually for 3 years and then every 2 years up to year 10
Unresected GI neuroendocrine tumors being monitored with observation alone	<ul style="list-style-type: none"> CT Abdomen with contrast (CPT® 74160) once at 3 to 12 months from initial diagnosis then annually up to year 10
Pancreatic neuroendocrine tumors	<ul style="list-style-type: none"> CT Abdomen with contrast (CPT® 74160) once at 3 to 12 months postoperatively then annually up to year 10
Unresected pancreatic neuroendocrine tumors being monitored with observation alone	<ul style="list-style-type: none"> CT Abdomen with contrast (CPT® 74160) once at 3 to 12 months from initial diagnosis then annually up to year 10
Measurable metastatic disease on maintenance treatment or off therapy	<ul style="list-style-type: none"> CT of involved body area no more frequently than every 3 months

Bronchopulmonary or Thymic Carcinoid – Initial Staging (ONC-15.6)

ON.NA.0015.6.A

v2.0.2024

Indication	Imaging Study
Initial diagnosis	<p><u>If not already done:</u></p> <ul style="list-style-type: none"> • CT Chest with contrast (CPT® 71260) • CT Abdomen with contrast (CPT® 74160) or without and with contrast (CPT® 74170) <ul style="list-style-type: none"> • If CT inconclusive, MRI Abdomen (CPT® 74183) without and with contrast is indicated
Inconclusive CT or MRI scans	<p><u>ONE of the following:</u></p> <ul style="list-style-type: none"> • Octreotide scan (ANY ONE of the following): <ul style="list-style-type: none"> • Any one of the following planar imaging codes - CPT® 78801, 78802, or 78804 AND • Any one of the following SPECT/SPECT-CT codes - CPT® 78803, 78830, 78831, 78832 • PET/CT scan (CPT® 78815) with any ONE of the following SSR radiotracers: <ul style="list-style-type: none"> • ⁶⁸Ga-DOTATATE • ⁶⁸Ga-DOTATOC • ⁶⁴Cu-DOTATATE
<p><u>ANY of the following:</u></p> <ul style="list-style-type: none"> • Markers fail to normalize after complete resection AND CT/MRI and somatostatin-receptor based study are negative • Biopsy-proven neuroendocrine tumor of unknown primary site AND CT/MRI and somatostatin-receptor based study are negative 	<ul style="list-style-type: none"> • FDG-PET/CT scan (CPT® 78815)

Bronchopulmonary or Thymic Carcinoid – Restaging/Recurrence (ONC-15.7)

ON.NA.0015.7.A
v2.0.2024

Indication	Imaging Study
All after surgical resection	<ul style="list-style-type: none"> See: <u>Bronchopulmonary or Thymic Carcinoid - Surveillance (ONC-15.8)</u>
Unresectable/metastatic disease on treatment with somatostatin analogues	<ul style="list-style-type: none"> CT of involved body area no more frequently than every 3 months
Unresectable/metastatic disease on treatment with chemotherapy	<ul style="list-style-type: none"> CT of involved body area every 2 cycles (6 to 8 weeks)
Progression of symptoms or elevation of tumor markers	<ul style="list-style-type: none"> CT Chest without (CPT® 71250) or CT Chest with contrast (CPT® 71260) <u>And ONE of the following:</u> CT Abdomen and Pelvis with contrast (CPT® 74177) CT Abdomen and Pelvis without and with contrast (CPT® 74178) MRI Abdomen (CPT® 74183) and Pelvis (CPT® 72197) without and with contrast
Continued suspicion for recurrence with negative or inconclusive CT or MRI	<p><u>ONE of the following:</u></p> <ul style="list-style-type: none"> Octreotide scan <ul style="list-style-type: none"> Any one of the following planar imaging codes - CPT® 78801, 78802, or 78804 AND Any one of the following SPECT/SPECT-CT codes - CPT® 78803, 78830, 78831, 78832 PET/CT scan (CPT® 78815) with any ONE of the following SSR radiotracers: <ul style="list-style-type: none"> ⁶⁸Ga-DOTATATE ⁶⁸Ga-DOTATOC ⁶⁴Cu-DOTATATE

Bronchopulmonary or Thymic Carcinoid – Surveillance (ONC-15.8)

ON.NA.0015.8.A

v2.0.2024

Indication	Imaging Study
Carcinoid tumors of lung or thymus	<ul style="list-style-type: none">CT Chest with contrast (CPT® 71260) or CT Chest without contrast (CPT® 71250) once at 3 to 12 months post resection and then annually for 3 years and then every 2 years up to year 10
Unresected primary tumors being monitored with observation alone	<ul style="list-style-type: none">CT Chest with contrast (CPT® 71260) or CT Chest without contrast (CPT® 71250) once at 3 to 12 months from initial diagnosis then annually for 3 years and then every 2 years up to year 10
Measurable metastatic disease on maintenance treatment or off therapy	<ul style="list-style-type: none">CT of involved body area no more frequently than every 3 months

Adrenal Tumors – Suspected/Diagnosis (ONC-15.9)

ON.NA.0015.9.A

v2.0.2024

- See: **Adrenal Cortical Lesions (AB-16.1)** in the Abdomen Imaging Guidelines for evaluation of indeterminate adrenal masses.
- Adrenal tumors that involve the adrenal medulla or neural crest tissue outside the adrenal gland include pheochromocytoma, paraganglioma, and paraganglioneuroma
 - These tumors are imaged according to sections **ONC-15.10 through ONC-15.12**
 - Malignant adrenal tumors that involve the adrenal cortex are addressed in **Adrenocortical Carcinoma (ONC-15.13)**
- Adrenocortical carcinoma is imaged according to **Adrenocortical Carcinoma (ONC-15.13)**
- If concern for genetic predisposition syndrome such as MEN, neurofibromatosis, or Von Hippel-Lindau disease, see screening recommendations in **Screening Imaging and Cancer Predisposition Syndromes (PEDONC-2)** in the Pediatric Oncology Imaging Guidelines.

Adrenal Tumors – Initial Work-up/Staging (ONC-15.10)

ON.NA.0015.10.A

v2.0.2024

Indication	Imaging Study
<p><u>For ANY of the following:</u></p> <ul style="list-style-type: none"> • Pheochromocytoma • Paraganglioma • Paraganglioneuroma 	<p><u>If not already done:</u></p> <ul style="list-style-type: none"> • CT Chest without (CPT® 71250) or CT Chest with contrast (CPT® 71260) <p><u>And ONE of the following (if not already done):</u></p> <ul style="list-style-type: none"> • CT Abdomen and Pelvis with contrast (CPT® 74177) • CT Abdomen and Pelvis without and with contrast (CPT® 74178) • MRI Abdomen (CPT® 74183) and MRI Pelvis (CPT® 72197) without and with contrast • CT with contrast or MRI without and with contrast of any other symptomatic body areas
<p>Continued suspicion with negative/inconclusive CT or MRI</p>	<p><u>ONE of the following:</u></p> <ul style="list-style-type: none"> • Octreotide or MIBG scan: <ul style="list-style-type: none"> • Any one of the following planar imaging codes - CPT® 78801, 78802, 78804 AND • Any one of the following SPECT/SPECT-CT codes - CPT® 78803, 78830, 78831, 78832 • PET/CT scan (CPT® 78815) with any ONE of the following SSR radiotracers: <ul style="list-style-type: none"> • ⁶⁸Ga-DOTATATE • ⁶⁸Ga-DOTATOC • ⁶⁴Cu-DOTATATE
<p>All above studies done and negative/inconclusive</p>	<ul style="list-style-type: none"> • FDG-PET/CT scan (CPT® 78815)

Adrenal Tumors – Restaging/Recurrence (ONC-15.11)

ON.NA.0015.11.A

v2.0.2024

Indication	Imaging Study
If surgery is primary therapy	<ul style="list-style-type: none"> CT Abdomen with contrast (CPT® 74160) one time within first year post resection then go to surveillance recommendations
Recurrence, progression of symptoms, or elevation of tumor markers	<ul style="list-style-type: none"> CT Chest without contrast (CPT® 71250) or CT Chest with contrast (CPT® 71260) CT with contrast of involved areas <p><u>And ONE of the following:</u></p> <ul style="list-style-type: none"> CT Abdomen and Pelvis with contrast (CPT® 74177) CT Abdomen and Pelvis without and with contrast (CPT® 74178) MRI Abdomen (CPT® 74183) and MRI Pelvis (CPT® 72197) without and with contrast
Continued suspicion for recurrence with negative or inconclusive CT or MRI	<p><u>ONE of the following:</u></p> <ul style="list-style-type: none"> Octreotide scan (ANY ONE of the following): <ul style="list-style-type: none"> Any one of the following planar imaging codes - CPT® 78801, 78802, or 78804 AND Any one of the following SPECT/SPECT-CT codes - CPT® 78803, 78830, 78831, 78832 PET/CT scan (CPT® 78815) with any ONE of the following SSR radiotracers: <ul style="list-style-type: none"> ⁶⁸Ga-DOTATATE ⁶⁸Ga-DOTATOC ⁶⁴Cu-DOTATATE
All above studies done and negative/ inconclusive	<ul style="list-style-type: none"> FDG-PET/CT scan (CPT® 78815)

Adrenal Tumors – Surveillance (ONC-15.12)

ON.NA.0015.12.A

v2.0.2024

Indication	Imaging Study
All individuals	Once within 3-12 months post resection and then annually for 10 years: <ul style="list-style-type: none">• CT Chest with contrast (CPT® 71260) or without contrast (CPT® 71250)• CT Abdomen and Pelvis with contrast (CPT® 74177) or MRI Abdomen and Pelvis without and with contrast (CPT® 74183 and 72197)• CT with contrast of other involved body areas
Measurable metastatic disease being observed off therapy or on maintenance treatment	<ul style="list-style-type: none">• CT of involved body area no more frequently than every 3 months for up to 5 years after completion of definitive therapy and annually thereafter

Adrenocortical Carcinoma (ONC-15.13)

ON.NA.0015.13.A

v2.0.2024

Indication	Imaging Study
Initial Staging	<ul style="list-style-type: none"> CT Chest without (CPT® 71250) or CT Chest with contrast (CPT® 71260) <p><u>And ONE of the following (if not already done):</u></p> <ul style="list-style-type: none"> CT Abdomen and Pelvis with contrast (CPT® 74177) CT Abdomen and Pelvis without and with contrast (CPT® 74178) MRI Abdomen (CPT® 74183) and MRI Pelvis (CPT® 72197) without and with contrast
Suspected recurrence	<ul style="list-style-type: none"> CT Chest without (CPT® 71250) or CT Chest with contrast (CPT® 71260) <p><u>And ONE of the following:</u></p> <ul style="list-style-type: none"> CT Abdomen and Pelvis with contrast (CPT® 74177) CT Abdomen and Pelvis without and with contrast (CPT® 74178) MRI Abdomen (CPT® 74183) and MRI Pelvis (CPT® 72197) without and with contrast
<ul style="list-style-type: none"> Solitary adrenal mass >4 cm on conventional imaging and plans for aggressive surgical resection Inconclusive findings on conventional imaging 	<ul style="list-style-type: none"> FDG PET/CT scan (CPT® 78815)
Surveillance after complete response to definitive treatment	<p><u>Annually for 5 years:</u></p> <ul style="list-style-type: none"> CT Chest with contrast (CPT® 71260), CT Abdomen with contrast (CPT® 74160), and CT of other involved body areas with contrast
Measurable metastatic disease on maintenance therapy or being monitored off therapy	<p><u>Every 3 months for up to 5 years after completion of definitive therapy:</u></p> <ul style="list-style-type: none"> CT Chest with contrast (CPT® 71260), CT Abdomen and Pelvis with contrast (CPT® 74177), and CT with contrast of other involved body areas

References (ONC-15)

v2.0.2024

1. Bergsland E, Goldner WS, Benson III AB, et al. National Comprehensive Cancer Network (NCCN) Guidelines Version 1.2023 – August 2, 2023. Neuroendocrine and Adrenal tumors, available at: https://www.nccn.org/professionals/physician_gls/pdf/neuroendocrine.pdf Referenced with permission from the NCCN Clinical Practice Guidelines in Oncology (NCCN Guidelines™) for Neuroendocrine and Adrenal tumors V1.2023 – August 2, 2023. ©2023 National Comprehensive Cancer Network, Inc. All rights reserved. The NCCN Guidelines™ and illustrations herein may not be reproduced in any form for any purpose without the express written permission of the NCCN. To view the most recent and complete version of the NCCN Guidelines™, go online to NCCN.org.
2. Qadan M, Ma Y, Visser BC, et al. Reassessment of the current American Joint Committee on Cancer staging system for pancreatic neuroendocrine tumors. *J Am Coll Surg*. 2014;218(2):188-195. doi:10.1016/j.jamcollsurg.2013.11.001.
3. Lenders JWM, Duh Q-Y, Eisenhofer G, et al. Pheochromocytoma and paraganglioma: an Endocrine Society clinical practice guideline. *J Clin Endocrinol Metab*. 2014;99(6):1915-1942. doi:10.1210/jc.2014-1498.
4. Ruys AT, Bennink RJ, van Westreenen HL, et al. FDG-positron emission tomography/computed tomography and standardized uptake value in the primary diagnosis and staging of hilar cholangiocarcinoma. *HPB (Oxford)*. 2011;13(4):256-262. doi:10.1111/j.1477-2574.2010.00280.x.
5. Ter-Minassian M, Chan JA, Hooshmand SM, et al. Clinical presentation, recurrence, and survival in patients with neuroendocrine tumors: results from a prospective institutional database. *Endocr Relat Can*. 2013;20(2):187-196. doi:10.1530/ERC-12-0340.
6. Murray SE, Lloyd RV, Sippel RS, Chen H, Oltmann SC. Postoperative surveillance of small appendiceal carcinoid tumors. *Am J Surg*. 2014;207(3):342-345. doi:10.1016/j.amjsurg.2013.08.038.
7. Thakker RV, Newey PJ, Walls GV, et al. Clinical practice guidelines for multiple endocrine neoplasia type 1 (MEN1). *J Clin Endocrinol Metab*. 2012;97(9):2990-3011. doi:10.1210/jc.2012-1230.
8. Singh S, Moody L, Chan DL, et al. Follow-up recommendations for completely resected gastroenteropancreatic neuroendocrine tumors. *JAMA Oncol*. 2018;4(11):1597-1604. doi:10.1001/jamaoncol.2018.2428.

Colorectal and Small Bowel Cancer (ONC-16)

Guideline

- Colorectal Cancer – General Considerations (ONC-16.0)
- Colorectal Cancer – Suspected/Diagnosis (ONC-16.1)
- Colorectal Cancer – Initial Work-up/Staging (ONC-16.2)
- Colorectal Cancer – Restaging/Recurrence (ONC-16.3)
- Colorectal Cancer – Surveillance/Follow-up (ONC-16.4)
- Small Bowel Cancer – Initial Work-up/Staging (ONC-16.5)
- Small Bowel Cancer – Restaging/Recurrence (ONC-16.6)
- Small Bowel Cancer – Surveillance/Follow-up (ONC-16.7)
- References (ONC-16)

Colorectal Cancer – General Considerations (ONC-16.0)

ON.CC.0016.0.A

v2.0.2024

- Neuroendocrine tumors of the bowel are covered in: **Neuroendocrine Cancers and Adrenal Tumors. (ONC-15)**
- Appendiceal adenocarcinoma (including pseudomyxoma peritonei) follows imaging guidelines for colorectal cancer.
- For squamous cell carcinoma of the rectum, see: **Anal Carcinoma (ONC-24)**

Colorectal Cancer – Suspected/Diagnosis (ONC-16.1)

ON.CC.0016.1.A

v2.0.2024

- See: **GI Bleeding (AB-22)** or **CT Colonography (CTC) (AB-25.1)** in the Abdomen Imaging Guidelines for evaluation of suspected colorectal malignancies.
- See: **Abnormal Findings on Endoscopy/Colonoscopy (AB-13.3)** in the Abdomen Imaging Guidelines for evaluation of abnormal findings on endoscopy/colonoscopy.
- If findings on colonoscopy are suspicious for colon cancer, see: **Colorectal Cancer – Initial Work-up/Staging (ONC-16.2)**

Colorectal Cancer – Initial Work-up/Staging (ONC-16.2)

ON.CC.0016.2.A

v2.0.2024

Indication	Imaging Study
Carcinoma within a polyp that is completely removed	<ul style="list-style-type: none"> No advanced imaging needed
<ul style="list-style-type: none"> Biopsy proven invasive adenocarcinoma Colonoscopy findings suspicious for colon cancer 	<ul style="list-style-type: none"> CT Chest with contrast (CPT® 71260) and CT Abdomen and Pelvis with contrast (CPT® 74177)
<ul style="list-style-type: none"> Further evaluation of an inconclusive liver lesion seen on CT Potentially resectable liver metastases 	<ul style="list-style-type: none"> MRI Abdomen without and with contrast (CPT® 74183)
Rectal adenocarcinoma	<ul style="list-style-type: none"> MRI Pelvis without and with contrast (CPT® 72197) or MRI Pelvis without contrast (CPT® 72195) (can be obtained in addition to CT scans for initial staging)
Rectal adenocarcinoma with ANY one of the following: <ul style="list-style-type: none"> Rectal MRI is contraindicated Rectal MRI is inconclusive Superficial lesions 	<ul style="list-style-type: none"> Endorectal ultrasound (CPT® 76872)
ONE of the following: <ul style="list-style-type: none"> Isolated metastatic lesion(s) on other imaging and individual is a candidate for aggressive surgical resection or other localized treatment to metastasis for curative intent Inconclusive conventional imaging 	<ul style="list-style-type: none"> PET/CT (CPT® 78815)

Colorectal Cancer – Restaging/Recurrence (ONC-16.3)

ON.CC.0016.3.A

v2.0.2024

Indication	Imaging Study
<ul style="list-style-type: none"> Complete resection Individuals receiving post-operative adjuvant chemotherapy 	<ul style="list-style-type: none"> See: Surveillance/Follow-up (ONC-16.4)
<p>Recurrence suspected</p>	<ul style="list-style-type: none"> CT Chest with contrast (CPT® 71260) and CT Abdomen and Pelvis (CPT® 74177) with contrast
<p>After completion of planned neoadjuvant therapy</p>	<p><u>Prior to surgical resection in individuals with non-metastatic rectal cancer:</u></p> <ul style="list-style-type: none"> CT Chest with contrast (CPT® 71260) and <p><u>Any ONE of the following:</u></p> <ul style="list-style-type: none"> CT Abdomen and Pelvis with contrast (CPT® 74177) CT Abdomen with contrast (CPT® 74160) and MRI Pelvis without and with contrast (CPT® 72197)
<p>Unresected primary disease or metastatic disease on chemotherapy</p>	<p><u>Every 2 cycles of chemotherapy treatment and at the completion of chemoradiotherapy:</u></p> <ul style="list-style-type: none"> CT Chest with contrast (CPT® 71260) CT Abdomen and Pelvis with contrast (CPT® 74177) CT with contrast of other involved or symptomatic areas
<ul style="list-style-type: none"> Further evaluation of an inconclusive liver lesion seen on CT Potentially resectable liver metastases 	<ul style="list-style-type: none"> MRI Abdomen without and with contrast (CPT® 74183)

Indication	Imaging Study
<p><u>ONE of the following:</u></p> <ul style="list-style-type: none">• Postoperative elevated or rising CEA or LFTs with negative recent conventional imaging• Isolated metastatic lesion(s) on other imaging and individual is a candidate for aggressive surgical resection or other localized treatment to metastasis for curative intent• Differentiate local tumor recurrence from postoperative and/or post-radiation scarring	<ul style="list-style-type: none">• PET/CT (CPT® 78815)
<p>New or worsening pelvic pain and recent CT imaging negative or inconclusive</p>	<ul style="list-style-type: none">• MRI Pelvis without and with contrast (CPT® 72197)

Colorectal Cancer – Surveillance/Follow-up (ONC-16.4)

ON.CC.0016.4.A

v2.0.2024

Indication	Imaging/Lab Study
<u>Colon and rectal adenocarcinoma:</u> <ul style="list-style-type: none"> • Stage I 	<ul style="list-style-type: none"> • No routine advanced imaging indicated
<u>Colon and rectal adenocarcinoma:</u> <ul style="list-style-type: none"> • Stage II-III 	<ul style="list-style-type: none"> • CT Chest with contrast (CPT® 71260) and CT Abdomen and Pelvis with contrast (CPT® 74177) after completion of surgery and then annually for 5 years
<u>Colon and rectal adenocarcinoma:</u> <ul style="list-style-type: none"> • Stage IV or distant metastatic disease (post definitive treatment of all measurable disease or being observed off therapy) 	<ul style="list-style-type: none"> • CT Chest with contrast (CPT® 71260) and CT Abdomen and Pelvis with contrast (CPT® 74177) every 6 months for 2 years and then annually for 3 years
Measurable metastatic disease on maintenance therapy	<u>Every 3 months for up to 5 years after completion of active treatment:</u> <ul style="list-style-type: none"> • CT Chest with contrast (CPT® 71260) • CT Abdomen and Pelvis with contrast (CPT® 74177)
Rectal cancer treated with transanal excision alone	<u>Any one of the following every 6 months for 5 years:</u> <ul style="list-style-type: none"> • Endorectal ultrasound (CPT® 76872) • MRI Pelvis without and with contrast (CPT® 72197)
Stage II-III rectal cancer treated with chemoradiation alone (no surgical treatment)	<u>In addition to the above stage-specific surveillance:</u> <ul style="list-style-type: none"> • MRI Pelvis (CPT® 72197) without and with contrast every 6 months for 3 years

Indication	Imaging/Lab Study
Pseudomyxoma peritonei	<p><u>ONE of each of the following, every 3 months for first year, then every 6 months for 4 more years:</u></p> <ul style="list-style-type: none">• CT Chest with (CPT® 71260) or CT Chest without contrast (CPT® 71250)• CT Abdomen and Pelvis with contrast (CPT® 74177) or MRI Abdomen (CPT® 74183) and MRI Pelvis (CPT® 72197) without and with contrast

Small Bowel Cancer – Initial Work-up/Staging (ONC-16.5)

ON.CC.0016.5.A
v2.0.2024

This section provides imaging guidelines for small bowel adenocarcinoma arising from the duodenum, jejunum, and ileum.

Indication	Imaging/Lab Study
Carcinoma within a polyp that is completely removed	<ul style="list-style-type: none">No advanced imaging needed
Invasive adenocarcinoma	<ul style="list-style-type: none">CT Chest with contrast (CPT® 71260) and CT Abdomen and Pelvis (CPT® 74177) with contrastMRI Abdomen without and with contrast (CPT® 74183) and MRI Pelvis without and with contrast (CPT® 72197) if CT is inconclusive or cannot be performed

Small Bowel Cancer – Restaging/Recurrence (ONC-16.6)

ON.CC.0016.6.A

v2.0.2024

Indication	Imaging Study
Complete resection	<ul style="list-style-type: none"> See Surveillance below
Recurrence suspected	<ul style="list-style-type: none"> CT Chest (CPT® 71260) and CT Abdomen and Pelvis (CPT® 74177) with contrast
Unresected primary disease or metastatic disease on chemotherapy	<p><u>Every 2 cycles of chemotherapy:</u></p> <ul style="list-style-type: none"> CT Chest with contrast (CPT® 71260) CT Abdomen and Pelvis with contrast (CPT® 74177)
Further evaluation of an inconclusive liver lesion seen on CT	<ul style="list-style-type: none"> MRI Abdomen without and with contrast (CPT® 74183)
<p><u>ONE of the following:</u></p> <ul style="list-style-type: none"> Postoperative elevated or rising CEA or LFTs with negative recent conventional imaging Isolated metastatic lesion(s) on other imaging and individual is a candidate for aggressive surgical resection or other localized treatment to metastasis for curative intent 	<ul style="list-style-type: none"> PET/CT (CPT® 78815)

Small Bowel Cancer – Surveillance/Follow-up (ONC-16.7)

ON.CC.0016.7.A

v2.0.2024

Indication	Imaging/Lab Study
Stage I-III	<ul style="list-style-type: none">CT Chest (CPT® 71260) and CT Abdomen and Pelvis (CPT® 74177) with contrast after completion of surgery, and then annually for 5 years
Stage IV - Metastatic disease (post definitive treatment of all measurable disease, or being observed off therapy)	<ul style="list-style-type: none">CT Chest with contrast (CPT® 71260) and CT Abdomen and Pelvis (CPT® 74177) with contrast every 6 months for 2 years and then annually for 3 years
Measurable metastatic disease on maintenance therapy	<p><u>Every 3 months for up to 5 years after completion of active treatment:</u></p> <ul style="list-style-type: none">CT Chest with contrast (CPT® 71260)CT Abdomen and Pelvis with contrast (CPT® 74177)

References (ONC-16)

v2.0.2024

1. Benson III AB, Venook AP, Adam M, et al. National Comprehensive Cancer Network (NCCN) Guidelines Version 1.2024 – January 29, 2024. Colon cancer, available at: https://www.nccn.org/professionals/physician_gls/pdf/colon.pdf. Referenced with permission from the NCCN Clinical Practice Guidelines in Oncology (NCCN Guidelines™) for Colon cancer V1.2024 – January 29, 2024. ©2024 National Comprehensive Cancer Network, Inc. All rights reserved. The NCCN Guidelines™ and illustrations herein may not be reproduced in any form for any purpose without the express written permission of the NCCN. To view the most recent and complete version of the NCCN Guidelines™, go online to NCCN.org.
2. Benson III AB, Venook AP, Adam M, et al. National Comprehensive Cancer Network (NCCN) Guidelines Version 1.2024 – January 29, 2024. Rectal cancer, available at: https://www.nccn.org/professionals/physician_gls/pdf/rectal.pdf. Referenced with permission from the NCCN Clinical Practice Guidelines in Oncology (NCCN Guidelines™) for Rectal cancer V1.2024 – January 29, 2024. ©2024 National Comprehensive Cancer Network, Inc. All rights reserved. The NCCN Guidelines™ and illustrations herein may not be reproduced in any form for any purpose without the express written permission of the NCCN. To view the most recent and complete version of the NCCN Guidelines™, go online to NCCN.org.
3. Benson AB, Venook AP, Pedersen K, et al. National Comprehensive Cancer Network (NCCN) Guidelines Version 2.2024 – February 27, 2024. Small Bowel Adenocarcinoma, available at: https://www.nccn.org/professionals/physician_gls/pdf/small_bowel.pdf. Referenced with permission from the NCCN Clinical Practice Guidelines in Oncology (NCCN Guidelines™) for Small Bowel Adenocarcinoma V1.2024 – February 27, 2024. ©2024 National Comprehensive Cancer Network, Inc. All rights reserved. The NCCN Guidelines™ and illustrations herein may not be reproduced in any form for any purpose without the express written permission of the NCCN. To view the most recent and complete version of the NCCN Guidelines™, go online to NCCN.org.
4. ACR Appropriateness Criteria. Pretreatment Staging of Colorectal Cancer. Rev. 2011.
5. Bailey CE, Hu C-Y, You YN et al. Variation in positron emission tomography use after colon cancer resection. *J Oncol Pract*. 2015;11(3):e363-e372. doi:10.1200/JOP.2014.001933.
6. Lu YY, Chen JH, Ding HJ, Chien CR, Lin WY, Kao CH. A systematic review and meta-analysis of pretherapeutic lymph node staging of colorectal cancer by 18F-FDG PET or PET/CT. *Nucl Med commun*. 2012;33(11):1127-1133. doi:10.1097/MNM0b013e328357b2d9.
7. Moulton CA, Gu CS, Law CH, et al. Effect of PET before liver resection on surgical management for colorectal adenocarcinoma metastases: a randomized clinical trial. *JAMA*. 2014;311(18):1863-1869. doi:10.1001/jama.2014.3740.
8. Steele SR, Chang GJ, Hendren S, et al. Practice guideline for the surveillance of patients after curative treatment of colon and rectal cancer. *Dis Colon Rectum*. 2015;58(8):713-725. doi:10.1097/DCR.0000000000000410.
9. van de Velde CJ, Boelens PG, Borrás JM, et al. EURECCA colorectal: multidisciplinary management: European consensus conference colon & rectum. *Eur J Cancer*. 2014;50(1):e1-e34. doi:10.1016/j.ejca.2013.06.048.
10. Akce M, El-Rayes BF. Nonsurgical management of rectal cancer. *Journal of Oncology Practice*. 2019;15(3):123-131. doi:10.1200/JOP.18.00769.

Renal Cell Cancer (RCC) (ONC-17)

Guideline

Renal Cell Cancer (RCC) – General Considerations (ONC-17.0)

Renal Cell Cancer (RCC) – Suspected/Diagnosis (ONC-17.1)

Renal Cell Cancer (RCC) – Initial Work-up/Staging (ONC-17.2)

Renal Cell Cancer (RCC) – Restaging/Recurrence (ONC-17.3)

Renal Cell Cancer (RCC) – Surveillance (ONC-17.4)

References (ONC-17)

Renal Cell Cancer (RCC) – General Considerations (ONC-17.0)

ON.RC.0017.0.A

v2.0.2024

- PET considered experimental, investigational, or unproven for initial diagnosis, staging or restaging of renal cell cancer.
- A minority of adult individuals with renal cell cancer (RCC) will have translocations in TFE3 or TFEB, which have a different natural history than “adult type” RCC. Individuals of any age with TFE3 or TFEB translocated RCC should be imaged according to guidelines in **Pediatric Renal Cell Carcinoma (RCC) (PEDONC-7.4)** in the Pediatric Oncology Imaging Guidelines.
- Individuals of any age with Wilms tumor should be imaged according to guidelines in section **Unilateral Wilms Tumor (UWT) (PEDONC-7.2)** or **Bilateral Wilms Tumor (BWT) (PEDONC-7.3)** in the Pediatric Oncology Imaging Guidelines.
- Oncocytoma in individuals of all ages should be imaged according to these guidelines.

Renal Cell Cancer (RCC) – Suspected/ Diagnosis (ONC-17.1)

ON.RC.0017.1.A

v2.0.2024

Indication	Imaging Study
<ul style="list-style-type: none">• Solitary renal mass suspicious for renal cell cancer	<ul style="list-style-type: none">• See: Indeterminate Renal Lesion (AB-35.1) in the Abdomen Imaging Guidelines for evaluation of suspected renal malignancies• Chest x-ray or CT Chest with contrast with (CPT® 71260) or without contrast (CPT® 71250)

Renal Cell Cancer (RCC) – Initial Work-up/Staging (ONC-17.2)

ON.RC.0017.2.A

v2.0.2024

Indication	Imaging study
All individuals	<p><u>If not done previously:</u></p> <ul style="list-style-type: none"> • CT Chest with (CPT® 71260) or without (CPT® 71250) contrast • CT Abdomen and Pelvis, contrast as requested
<p><u>ANY of the following:</u></p> <ul style="list-style-type: none"> • Extension of tumor into the vena cava by other imaging • Inconclusive findings on CT 	<ul style="list-style-type: none"> • MRI Abdomen without and with contrast (CPT® 74183)
Bone pain	<ul style="list-style-type: none"> • Bone scan (See: <u>Nuclear Medicine (NM) Imaging in Oncology (ONC-1.3)</u>)
<p><u>EITHER of the following:</u></p> <ul style="list-style-type: none"> • Signs/symptoms suspicious for brain metastases • Newly diagnosed stage IV/metastatic RCC 	<ul style="list-style-type: none"> • MRI Brain without and with contrast (CPT® 70553)

Renal Cell Cancer (RCC) – Restaging/Recurrence (ONC-17.3)

ON.RC.0017.3.A

v2.0.2024

Indication	Imaging Study
Unresectable disease or metastatic disease on systemic therapy	<u>Every 2 cycles of treatment (commonly every 6 to 8 weeks):</u> <ul style="list-style-type: none">• CT Chest with contrast (CPT® 71260)• CT Abdomen and Pelvis with contrast (CPT® 74177)• CT with contrast of other involved or symptomatic areas
Recurrence suspected	<ul style="list-style-type: none">• CT Chest with contrast (CPT® 71260)• CT Abdomen and Pelvis with contrast (CPT® 74177)
<u>EITHER of the following:</u> <ul style="list-style-type: none">• Biopsy-proven recurrent/metastatic disease• Signs or symptoms concerning for brain metastases	<ul style="list-style-type: none">• MRI Brain without and with contrast (CPT® 70553)

Renal Cell Cancer (RCC) – Surveillance (ONC-17.4)

ON.RC.0017.4.A

v2.0.2024

Indication	Imaging Study
RCC on active surveillance of renal mass <1 cm	<p><u>ONE of the following, once within 6 months of surveillance initiation and annually thereafter:</u></p> <ul style="list-style-type: none"> • CT Abdomen without and with contrast (CPT® 74170) • MRI Abdomen without and with contrast (CPT® 74183) • See: Indeterminate Renal Lesion (AB-35.1) in the Abdomen Imaging Guidelines • Chest x-ray (in addition to abdominal imaging) <ul style="list-style-type: none"> • CT Chest with contrast (CPT® 71260) or without contrast (CPT® 71250) may be obtained for one of the following: <ul style="list-style-type: none"> • New chest x-ray abnormalities • Pulmonary signs/symptoms
RCC on active surveillance of renal mass ≥1 cm	<p><u>One of the following, every 3 months for year 1, every 6 months for years 2 and 3 and annually thereafter:</u></p> <ul style="list-style-type: none"> • CT Abdomen without and with contrast (CPT® 74170) • MRI Abdomen without and with contrast (CPT® 74183) • Chest x-ray (in addition to abdominal imaging) <ul style="list-style-type: none"> • CT Chest with contrast (CPT® 71260) or without contrast (CPT® 71250) may be obtained for one of the following: <ul style="list-style-type: none"> • New chest x-ray abnormalities • Pulmonary signs/symptoms
Follow up after post-ablation therapy of RCC	<p><u>EITHER of the following, at 1 to 3 months, 6 months, and 12 months post-ablation and then annually thereafter:</u></p> <ul style="list-style-type: none"> • CT Abdomen without and with contrast (CPT® 74170) or • MRI Abdomen without and with contrast (CPT® 74183) <p>AND</p> <p>Annually for 5 years:</p> <ul style="list-style-type: none"> • Chest x-ray or CT Chest with contrast (CPT® 71260) or without contrast (CPT® 71250)

Indication	Imaging Study
<p>Stage I RCC, after partial or radical nephrectomy</p>	<p><u>ONE of each of the following, 3 to 12 months post-resection:</u></p> <ul style="list-style-type: none"> • CT Chest with (CPT® 71260) or CT Chest without contrast (CPT® 71250) • CT Abdomen with (CPT® 74160) or CT Abdomen without contrast (CPT® 74150) or MRI Abdomen without and with contrast (CPT® 74183) <p><u>Annually for 5 years:</u></p> <ul style="list-style-type: none"> • Chest x-ray or CT Chest with (CPT® 71260) or without (CPT® 71250) contrast • Abdominal imaging with any ONE of the following: <ul style="list-style-type: none"> • CT Abdomen with (CPT® 74160) or without (CPT® 74150) contrast • MRI Abdomen without and with contrast (CPT® 74183)
<p>Stage II RCC, post-nephrectomy</p>	<p><u>ONE of each of the following, 3 to 6 months post-resection:</u></p> <ul style="list-style-type: none"> • CT Chest with (CPT® 71260) or without (CPT® 71250) contrast • CT Abdomen with (CPT® 74160) or without (CPT® 74150) contrast or MRI Abdomen without and with contrast (CPT® 74183) <p><u>ONE of each of the following, every 6 months for 2 years, then annually until year 5:</u></p> <ul style="list-style-type: none"> • Chest x-ray or CT Chest with (CPT® 71260) or without (CPT® 71250) contrast • Abdominal imaging with any ONE of the following: <ul style="list-style-type: none"> • CT Abdomen with (CPT® 74160) or without (CPT® 74150) contrast • MRI Abdomen without and with contrast (CPT® 74183)
<p>Stage III RCC, post-nephrectomy</p>	<p><u>ONE of each of the following, 3 to 6 months post-resection:</u></p> <ul style="list-style-type: none"> • CT Chest with (CPT® 71260) or without (CPT® 71250) contrast • CT Abdomen with (CPT® 74160) or without (CPT® 74150) contrast or MRI Abdomen without and with contrast (CPT® 74183) <p><u>ONE of each of the following, every 3 months for 3 years, then annually to year 5:</u></p> <ul style="list-style-type: none"> • CT Chest with (CPT® 71260) or without (CPT® 71250) contrast • CT Abdomen with (CPT® 74160) or without (CPT® 74150) contrast or MRI Abdomen without and with contrast (CPT® 74183)

Indication	Imaging Study
Stage IV/metastatic disease on maintenance therapy or being observed off therapy	<p><u>Every 3 months for up to 5 years after completion of active treatment:</u></p> <ul style="list-style-type: none">• CT Chest (CPT® 71260) and CT Abdomen and Pelvis (CPT® 74177) with contrast

References (ONC-17)

v2.0.2024

1. Motzer RJ, Jonasch E, Agarwal N, et al. National Comprehensive Cancer Network (NCCN) Guidelines Version 1.2024 – June 21, 2023. Kidney cancer, available at: https://www.nccn.org/professionals/physician_gls/pdf/kidney.pdf Referenced with permission from the NCCN Clinical Practice Guidelines in Oncology (NCCN Guidelines™) for Kidney cancer V1.2024 – June 21, 2023. ©2023 National Comprehensive Cancer Network, Inc. All rights reserved. The NCCN Guidelines™ and illustrations herein may not be reproduced in any form for any purpose without the express written permission of the NCCN. To view the most recent and complete version of the NCCN Guidelines™, go online to NCCN.org.
2. ACR Appropriateness Criteria. *Post-treatment follow up of renal cell carcinoma*. Rev. 2013.
3. Herts BR, Silverman SG, Hindman NM, et al. *Management of the incidental renal mass on CT: a white paper of the ACR incidental findings committee*. *J Am Coll Radiol*. 2018;15(2):264-273. doi:10.1016/j.jacr.2017.04.028.
4. Finelli A, Ismaila N, Bro B, et al. Management of small renal masses. American Society of Clinical Oncology clinical practice guideline. *Journal of Clinical Oncology*. 2017;35(6):668-680. doi:10.1200/JCO.2016.69.9645.
5. Davenport MS, Caoili EM, Cohan RH, et al. MRI and CT characteristics of successfully ablated renal masses: imaging surveillance after radiofrequency ablation. *AJR Am J Roentgenol*. 2009;192:1571-1578. doi:10.2214/AJR.08.1303.
6. Clark TW, Millward SF, Gervais DA, et al. Reporting standards for percutaneous thermal ablation of renal cell carcinoma. *J Vasc Interv Radiol*. 2009;20(7 Suppl):S409-S416. doi:10.1016/j.jvir.2009.04.013.
7. Rais-Bahrami S, Guzzo TJ, Jarrett TW, Kavoussi LR, Allaf ME. Incidentally discovered renal masses: oncological and perioperative outcomes in patients with delayed surgical intervention. *BJU Int*. 2009;103(10):1355-1358. doi:10.1111/j.1464-410X.2008.08242.x.
8. Wang HY, Ding HJ, Chen JH, Chao CH, Lu YY, Lin WY, Kao CH. Meta-analysis of the diagnostic performance of [18F]FDG-PET and PET/CT in renal cell carcinoma. *Cancer Imaging*. 2012 October;12:464-474. doi:10.1102/1470-7330.2012.0042.
9. Kim EH, Strobe SA. Postoperative surveillance imaging for patients undergoing nephrectomy for renal cell carcinoma. *Urol Oncol*. 2015;33(12):499-502. doi:10.1016/j.urolonc.2015.08.008.
10. Sankineni S, Brown A, Cieciera M, Choyke PL, Turkbey B. Imaging of renal cell carcinoma. *Urol Oncol*. 2016;34(3):147-155. doi:10.1016/j.urolonc.2015.05.020.
11. ACR Appropriateness Criteria. *Renal cell carcinoma staging*. Rev. 2015.
12. Campbell S, Uzzo R, Allaf M, et al. Renal mass and localized renal cancer: AUA guideline. *J Urol*. 2017;198(3):520-529. doi:10.1016/j.juro.2017.04.100.

Transitional Cell Cancer (ONC-18)

Guideline

Transitional Cell Cancer – General Considerations (ONC-18.0)

Transitional Cell Cancer – Suspected/Diagnosis (ONC-18.1)

Transitional Cell Cancer – Initial Work-up/Staging (ONC-18.2)

Transitional Cell Cancer – Restaging/Recurrence (ONC-18.3)

Transitional Cell Cancer – Surveillance/Follow-up (ONC-18.4)

References (ONC-18)

Transitional Cell Cancer – General Considerations (ONC-18.0)

ON.TS.0018.0.A

v2.0.2024

- Transitional cell cancers can include: tumors of the bladder, ureters, prostate, urethra, or renal pelvis. For primary cancer of the kidney, see: **Renal Cell Cancer (RCC) (ONC-17)**.
- Most common histology of bladder cancer is transitional cell (TCC) or urothelial carcinoma (UCC). Rare histologies include adenocarcinoma, squamous cell (imaged according to **Transitional Cell Cancer (ONC-18)**), or small cell (imaged according to **Extrathoracic Small Cell and Large Cell Neuroendocrine Tumors (ONC-31.8)**).
- Urachal cancer is rare type of bladder cancer; the most common histology is adenocarcinoma. These are imaged according to muscle invasive bladder cancer.
- PET not routinely indicated in transitional cell cancer with exception noted below in **Transitional Cell Cancer – Initial Work-up/Staging (ONC-18.2)**

Transitional Cell Cancer – Suspected/Diagnosis (ONC-18.1)

ON.TS.0018.1.A

v2.0.2024

- See: **Hematuria and Hydronephrosis (AB-39)** in the Abdomen Imaging Guidelines for evaluation of suspected transitional cell malignancies.

Transitional Cell Cancer – Initial Work-up/Staging (ONC-18.2)

ON.TS.0018.2.A

v2.0.2024

Indication	Imaging Study
All individuals	<p><u>ONE of the following:</u></p> <ul style="list-style-type: none"> • CT Abdomen and Pelvis without and with contrast (CPT® 74178) • MRI Abdomen (CPT® 74183) and MRI Pelvis (CPT® 72197) without and with contrast if contraindication to CT contrast • CT Abdomen and Pelvis without contrast (CPT® 74176) with retrograde pyelogram or renal ultrasound (CPT® 76770 or CPT® 76775) in individuals who cannot receive either CT or MRI contrast
<p><u>ANY of the following:</u></p> <ul style="list-style-type: none"> • Muscle invasive bladder carcinoma • Urethral carcinoma • Urothelial carcinoma of the prostate 	<ul style="list-style-type: none"> • CT Chest without (CPT® 71250) or with (CPT® 71260) contrast
Individuals without metastatic disease, when requested by operating surgeon for operative planning	<ul style="list-style-type: none"> • CT with contrast or MRI without and with contrast of all operative sites
To evaluate inconclusive findings on conventional imaging	<ul style="list-style-type: none"> • PET/CT (CPT® 78815)

Transitional Cell Cancer – Restaging/Recurrence (ONC-18.3)

ON.TS.0018.3.A

v2.0.2024

Indication	Imaging Study
After definitive surgery	<ul style="list-style-type: none"> • CT Abdomen and Pelvis with contrast (CPT® 74177) or CT Abdomen and Pelvis without and with contrast (CPT® 74178) for post-operative baseline
Recurrence suspicion	<ul style="list-style-type: none"> • CT Abdomen and Pelvis with contrast (CPT® 74177) or with and without contrast (CPT® 74178) • CT Chest with contrast (CPT® 71260) for ANY of the following: <ul style="list-style-type: none"> • Signs/symptoms of pulmonary disease • Abnormal chest x-ray • Prior involvement of the chest
After neoadjuvant therapy and before resection	<ul style="list-style-type: none"> • CT Chest with contrast (CPT® 71260) and CT Urogram (CPT® 74178)
Monitoring therapy for metastatic disease	<p><u>Every 2 cycles of therapy:</u></p> <ul style="list-style-type: none"> • CT Abdomen and Pelvis with contrast (CPT® 74177) • CT Chest with contrast (CPT® 71260) for ANY of the following: <ul style="list-style-type: none"> • Signs/symptoms of pulmonary disease • Prior involvement of the chest • Abnormal chest x-ray
To evaluate inconclusive findings on conventional imaging	<ul style="list-style-type: none"> • PET/CT (CPT® 78815)

Transitional Cell Cancer – Surveillance/Follow-up (ONC-18.4)

ON.TS.0018.4.A

v2.0.2024

Indication	Imaging Study
<p><u>ANY of the following:</u></p> <ul style="list-style-type: none"> • Papillary urothelial neoplasm of low malignant potential • Low risk lesions <ul style="list-style-type: none"> • Solitary Ta lesions ≤3cm • Intermediate risk lesions <ul style="list-style-type: none"> • Low-grade >3 cm • Low-grade multifocal • T1 lesions • High-grade solitary Ta ≤3cm 	<ul style="list-style-type: none"> • Advanced imaging is not routinely indicated for surveillance
<p><u>ANY of the following high-risk non-muscle invasive transitional cell carcinoma of the bladder or upper tracts:</u></p> <ul style="list-style-type: none"> • Multifocal high-grade lesions • High-grade lesions >3 cm • Superficial and minimally invasive (Tis and T1) • BCG unresponsive • Lymphovascular invasion • Prostatic urethral invasion 	<ul style="list-style-type: none"> • CT Urogram (CPT® 74178) every 2 years for 10 years • MR Urogram (CPT® 74183 and CPT® 72197) may be obtained for renal insufficiency or CT dye allergy
<p>Non-muscle-invasive transitional carcinoma of the bladder treated with cystectomy</p>	<ul style="list-style-type: none"> • CT Urogram (CPT® 74178) at 3 and 12 months post-cystectomy, and then annually for years 2-5 • MR Urogram (CPT® 74183 and CPT® 72197) may be obtained for renal insufficiency or CT dye allergy

Indication	Imaging Study
Muscle invasive lower and upper genitourinary tumors treated with cystectomy, nephrectomy, or chemoradiation	<p><u>Every 6 months for 2 years, then annually for 3 more years:</u></p> <ul style="list-style-type: none"> CT Chest with contrast (CPT® 71260) or CT Chest without contrast (CPT® 71250), and CT Abdomen and Pelvis with contrast (CPT® 74177) or without and with contrast (CPT® 74178) <p>OR</p> <ul style="list-style-type: none"> CT Chest with contrast (CPT® 71260) or CT Chest without contrast (CPT® 71250), and MR Urogram (CPT® 74183 and CPT® 72197)
Measurable metastatic disease on maintenance therapy or being monitored off therapy	<p><u>Every 3 months for up to 5 years after completion of active treatment:</u></p> <ul style="list-style-type: none"> CT Chest with contrast (CPT® 71260) CT Abdomen and Pelvis with contrast (CPT® 74177) or CT Urogram (CPT® 74178)
Urethral cancers (high-risk T1 or greater) and urothelial carcinoma of the prostate	<p><u>Every 6 months for 2 years, then annually:</u></p> <ul style="list-style-type: none"> CT Abdomen and Pelvis with contrast (CPT® 74177) or without and with contrast (CPT® 74178) <p>OR</p> <ul style="list-style-type: none"> MR Urogram (CPT® 74183 and CPT® 72197) <p>AND</p> <ul style="list-style-type: none"> Chest x-ray <ul style="list-style-type: none"> CT Chest with contrast (CPT® 71260) or CT Chest without contrast (CPT® 71250) if abnormal signs/symptoms of pulmonary disease or abnormal chest x-ray

References (ONC-18)

v2.0.2024

1. Flaig TW, Spiess PE, Abern M, et al. National Comprehensive Cancer Network (NCCN) Guidelines Version 1.2024 – January 30, 2024. Bladder cancer, available at: https://www.nccn.org/professionals/physician_gls/pdf/bladder.pdf Referenced with permission from the NCCN Clinical Practice Guidelines in Oncology (NCCN Guidelines™) for Bladder cancer V1.2024, January 30, 2024. ©2024 National Comprehensive Cancer Network, Inc. All rights reserved. The NCCN Guidelines™ and illustrations herein may not be reproduced in any form for any purpose without the express written permission of the NCCN. To view the most recent and complete version of the NCCN Guidelines™, go online to NCCN.org.
2. Verma S, Rajesh A, Prasad SR et al, Urinary bladder cancer: role of MR imaging. *Radiographics*. 2012;32(2):371-387. doi:10.1148/rg.322115125.
3. Lu YY, Chen JH, Liang JA. Clinical value of FDG PET or PET/CT in urinary bladder cancer: a systematic review and meta-analysis. *Eur J Radiol*. 2012;81(9):2411-2416. doi:10.1016/j.ejrad.2011.07.018.
4. Witjes JA, Comperat E, Cowan NC, et al. EAU guidelines on muscle-invasive and metastatic bladder cancer: summary of the 2013 guidelines. *Eur Urol*. 2014;65(4):778-792. doi:10.1016/j.eururo.2013.11.046.
5. Gakis G, Witjes JA, Comperat E, et al. EAU guidelines on primary urethral carcinoma. *Eur Urol*. 2013;64(5):823-830. doi:10.1016/j.eururo.2013.03.044.
6. Rouprêt M, Babjuk M, Compérat E, et al. European guidelines on upper tract urothelial carcinomas: 2013 update. *Eur Urol*. 2013;63(6):1059-1071. doi:10.1016/j.eururo.2013.03.032.

Prostate Cancer (ONC-19)

Guideline

Prostate Cancer – General Considerations (ONC-19.0)

Suspected Prostate Cancer (ONC-19.1)

Prostate Cancer – Initial Work-up/Staging (ONC-19.2)

Prostate Cancer – Restaging/Recurrence (ONC-19.3)

Prostate Cancer – Follow-up On Active Surveillance (ONC-19.4)

Surveillance/Follow-up For Treated Prostate Cancer (ONC-19.5)

References (ONC-19)

Prostate Cancer – General Considerations (ONC-19.0)

ON.PR.0019.0.A

v2.0.2024

- Prostate cancer screening begins at age 45 for individuals at average risk of prostate cancer. However, individuals at high-risk may begin screening at age 40. High-risk features include:
 - African ancestry
 - Germline mutations (BRCA1 or 2, HOXB13, ATM, CHEK2, or mismatch repair genes - MLH1, MSH2, MSH6, PMS2) that increase the risk of prostate cancer
 - Family history of first or second-degree relative with prostate, male breast, colorectal, pancreatic, endometrial or female breast cancer at age <45 years.
- Treatment of benign prostatic hyperplasia with 5- α reductase inhibitors (such as finasteride and dutasteride) can falsely reduce the measured PSA levels by 50%. Thus, the reported PSA level should be doubled when prostate cancer is suspected in individuals on these medications.
- Individuals with high-risk adverse clinical and pathological factors may benefit from a more aggressive diagnostic and therapeutic approach at the time of relapse after initial treatment. These factors include pre-treatment Gleason score of ≥ 8 , pre-treatment clinical stage of cT3b or higher, positive surgical margins, post-treatment PSA doubling time of <3 months, and an interval to biochemical failure of <3 years after initial treatment.
- PET/CT scan using ^{18}F -FDG radiotracer are considered investigational and experimental for evaluation of prostate cancer.
- ^{11}C Choline, ^{18}F -Fluciclovine (AXUMIN[®]), and PSMA-specific radiopharmaceuticals have recently gained FDA approval for evaluation of prostate cancer. Optimal detection rates for these radiotracers vary greatly with PSA levels. False positive rate is high and histological confirmation of positive sites is recommended. Coverage may vary with individual health care plan.
- PSMA-specific PET radiopharmaceuticals that are currently FDA-approved and indicated in prostate cancer are: ^{68}Ga PSMA-11 (UCSF & UCLA), ^{18}F Piflufolostat (Pylarify[®]), ^{18}F Flotufolostat (Posluma[®]), and ^{68}Ga Gozetotide (Illuccix[®] and Locametz[®]).
- While early detection of low-volume recurrence after treatment of prostate cancer using PET/CT scans may influence therapeutic decisions, there is lack of evidence that this approach has any meaningful impact on overall survival.
- As high intensity focused ultrasound prostate ablation is considered investigational and experimental at this time, and advanced imaging for treatment planning and/or surveillance of high intensity focused ultrasound prostate ablation is not indicated.
- MR Spectroscopy (CPT[®] 76390) is considered investigational and experimental in the evaluation of prostate cancer at this time.

- As laser prostate ablation is considered investigational and experimental at this time, advanced imaging for treatment planning and/or surveillance of laser prostate ablation is not indicated.
- Monitoring an elevated prostate-specific antigen level (PSA) with serial MRI is not indicated for suspected prostate cancer.
- Requests for imaging based on PSA must provide a recent (within the last 60 days) PSA.

ISUP Prostate Cancer Grade Groups³⁰

Grade Group	Gleason Score	Gleason Pattern
1	≤6	≤3+3
2	7	3+4
3	7	4+3
4	8	4+4, 3+5, 5+3
5	9 or 10	4+5, 5+4, or 5+5

NCCN Initial Risk Stratification

- Very Low Risk
 - ALL of the following features are present:
 - Tumor not clinically palpable, but present on one or both lobes on biopsy (cT1a, cT1b, or cT1c)
 - PSA (ng/mL) <10
 - Gleason Grade Group = 1
 - <3 prostate biopsy cores positive, ≤50% cancer in each core
 - PSA Density <0.15 ng/mL/g
- Low Risk
 - ALL of the following features are present but does not qualify for very low risk:
 - Clinical T Stage = cT1-cT2a (palpable tumor limited to ≤1/2 of one side)
 - PSA (ng/mL) <10
 - Gleason Grade Group = 1
- Favorable Intermediate Risk
 - ALL of the following features are present:
 - Gleason Grade Group = 1 or 2
 - <50% biopsy cores positive (e.g., <6 of 12 cores)
 - And only ONE of the following features is present:
 - Clinical T Stage = cT2b (tumor involves more than half of one lobe, but not both lobes) and cT2c (tumor involves both lobes)
 - PSA (ng/mL) = 10-20

- Unfavorable Intermediate Risk
 - Any one of the following are present:
 - Gleason grade group = 3
 - ≥50% biopsy cores positive (e.g., ≥6 of 12 cores)
 - Presence of at least two of the following three features:
 - PSA (ng/mL) = 10-20
 - Gleason Grade Group = 2 or 3
 - Clinical T Stage = cT2b (tumor involves more than half of one lobe, but not both lobes) and cT2c (tumor involves both lobes)
- High-Risk
 - Only ONE of the following high-risk features is present:
 - Clinical T Stage = cT3a (unilateral or bilateral extra-prostatic extension that is not fixed and does not invade the seminal vesicles)
 - PSA (ng/mL) >20
 - Gleason Grade Group = 4 or 5
- Very High-Risk
 - At least ONE of the following features is present:
 - Clinical T stage = cT3b-cT4 (extension into the seminal vesicles or invasion into adjacent structures)
 - Primary Gleason Pattern = 5
 - Gleason Grade Group = 4 or 5 in >4 cores
 - Presence of 2 or 3 high-risk features (noted above)

3D Rendering of MRI for MRI / Ultrasound Fusion Biopsy:

- When specific target lesion(s) is (are) detected on mpMRI (multi-parametric MRI) prostate and classified as PIRADS 4 or 5, 3D Rendering (CPT® 76377) to generate prostate segmentation data image set for target identification on MRI/Transrectal ultrasound (TRUS) fusion biopsy is approvable as:
 - Subsequent separate standalone request; or
 - As retrospective request for medical necessity.
- For MRI/TRUS fusion biopsy of a PIRADS 1-3 lesion, approval of 3D rendering at independent workstation (CPT® 76376 or CPT® 76377) can be considered on a case-by-case basis.
- If there is no target lesion identified on MRI then 3D rendering and MRI/TRUS fusion biopsy is generally not indicated.
- The 3D rendering for the TRUS component of the fusion is a part of the UroNav Fusion Equipment Software and an additional 3D code CPT® 76376 or CPT® 76377 should not be approved.

Suspected Prostate Cancer (ONC-19.1)

ON.PR.0019.1.A

v2.0.2024

Indication	Imaging Study
<p>ANY of the following:</p> <ul style="list-style-type: none"> • Age 40-75 years with PSA >3 ng/ml or very suspicious DRE and ONE of the following high-risk features: <ul style="list-style-type: none"> • African ancestry • Germline mutations that increase the risk of prostate cancer • Family history of first or second-degree relative with prostate, male breast, colorectal, pancreatic, endometrial or female breast cancer at age <45 years • Age 45-75 years and ONE of the following: <ul style="list-style-type: none"> • PSA >3 ng/ml • Very suspicious DRE • Age >75 years and ONE of the following: <ul style="list-style-type: none"> • PSA ≥4 ng/ml • Very suspicious DRE • At least one negative/non-diagnostic TRUS biopsy and ANY of the following: <ul style="list-style-type: none"> • Rising PSA • Abnormal DRE • Need for confirmatory MR/US fusion biopsy 	<p>ANY of the following:</p> <ul style="list-style-type: none"> • Transrectal ultrasound (CPT® 76872) • TRUS-guided biopsy (CPT® 76942) • MRI Pelvis without and with contrast (CPT® 72197) or MRI Pelvis without contrast (CPT® 72195) if an MR/US guided fusion biopsy is planned • MRI/US fusion biopsy (CPT® 76942)
<ul style="list-style-type: none"> • PIRADS 4 or 5 lesion identified on recent diagnostic MRI Pelvis (CPT® 72195 or CPT® 72197) and planning for biopsy to be done by MRI/TRUS fusion technique 	<ul style="list-style-type: none"> • 3D Rendering (CPT® 76376 or CPT® 76377)

Indication	Imaging Study
<p><u>ANY of the following:</u></p> <ul style="list-style-type: none">• Multifocal (3 or more lesions) high-grade prostatic intraepithelial neoplasia (PIN)• Atypia on biopsy	<ul style="list-style-type: none">• Extended pattern rebiopsy within 6 months by TRUS-guided biopsy (CPT® 76942)
<ul style="list-style-type: none">• Focal PIN (1-2 lesions)	<p><u>ONE of the following:</u></p> <ul style="list-style-type: none">• MRI Pelvis without contrast (CPT® 72195)• MRI Pelvis without and with contrast (CPT® 72197)• MRI/US fusion biopsy (CPT® 76942)• MRI guided biopsy (CPT® 77021)

Prostate Cancer – Initial Work-up/Staging (ONC-19.2)

ON.PR.0019.2.A

v2.0.2024

Indication	Imaging Study
<p><u>Localized prostate cancer with any of the following risk groups (see: ONC-19.0 for definition of risk groups):</u></p> <ul style="list-style-type: none"> • Very low risk • Low risk • Favorable intermediate risk 	<p>Advanced imaging is not routinely indicated for initial staging</p> <p>If not already performed prior to biopsy, MRI Pelvis without and with contrast (CPT[®] 72197) is appropriate for any of the following:</p> <ul style="list-style-type: none"> • Prior to planned treatment (surgery and/or radiation therapy) • To establish candidacy for active surveillance
<p><u>Localized prostate cancer with any of the following risk groups (see: ONC-19.0 for definition of risk groups):</u></p> <ul style="list-style-type: none"> • Unfavorable intermediate risk • High-risk • Very high-risk 	<p><u>Any ONE of the following combinations, not all (may be obtained in addition to mpMRI prostate):</u></p> <ul style="list-style-type: none"> • CT Chest with contrast (CPT[®] 71260), CT Abdomen and Pelvis with contrast (CPT[®] 74177), and Bone scan • CT Chest with contrast (CPT[®] 71260), CT Abdomen with contrast (CPT[®] 74160), MRI Pelvis without and with contrast (CPT[®] 72197) if not previously performed, and Bone scan • PSMA PET/CT scan (CPT[®] 78815 or CPT[®] 78816) using any one of the following radiotracers: <ul style="list-style-type: none"> • ⁶⁸Ga-PSMA-11 • ¹⁸F Piflufolastat (Pylarify[®]) • ⁶⁸Ga Gozetotide (Illuccix[®] and Locametz[®]) • ¹⁸F Flotufolastat (Posluma[®])
<p>Known or clinically suspected metastatic prostate cancer (including prior to prostate biopsy)</p>	<p>CT Chest with contrast (CPT[®] 71260), CT Abdomen and Pelvis with contrast (CPT[®] 74177), and Bone scan</p>
<p>Inconclusive bone scan</p>	<p>CT with contrast or MRI without and with contrast of involved body site</p>

Indication	Imaging Study
<p><u>For ANY of the following:</u></p> <ul style="list-style-type: none">• Inconclusive bone findings on both CT/MRI and bone scan• Conventional imaging studies (CT and bone scan) suggests oligo- or low volume metastatic disease that need further confirmation	<ul style="list-style-type: none">• <u>PET/CT scan (CPT[®] 78815 or CPT[®]78816) using any one of the following radiotracers:</u><ul style="list-style-type: none">• ¹⁸F Fluciclovine• ¹¹C Choline• ⁶⁸Ga-PSMA-11• ¹⁸F Piflufolastat (Pylarify[®])• ⁶⁸Ga Gozetotide (Illuccix[®] and Locametz[®])• ¹⁸F Flotufolastat (Posluma[®])

Prostate Cancer – Restaging/Recurrence (ONC-19.3)

ON.PR.0019.3.A

v2.0.2024

Indication	Imaging Study
<p><u>For ANY of the following:</u></p> <ul style="list-style-type: none"> • Obvious progression by DRE with plans for prostatectomy or radiation therapy • Repeat TRUS biopsy for rising PSA shows progression to a higher Gleason’s score with plans for prostatectomy or radiation therapy • Inconclusive findings on CT scan 	<ul style="list-style-type: none"> • MRI Pelvis without and with contrast (CPT® 72197)
<p><u>Non-metastatic prostate cancer previously treated with prostatectomy, radiation therapy, ablation, hormonal therapy or chemotherapy and any one of the following:</u></p> <ul style="list-style-type: none"> • Clinical suspicion of relapse/recurrence • PSA fails to become undetectable post prostatectomy • Palpable anastomotic recurrence • PSA rises above post-treatment baseline to >0.2 ng/mL but <0.5 ng/mL on two consecutive measurements 	<p>Any ONE of the following combinations:</p> <ul style="list-style-type: none"> • CT Chest with contrast (CPT® 71260), CT Abdomen and Pelvis with contrast (CPT® 74177), and Bone scan (see: <u>Nuclear Medicine (NM) Imaging in Oncology (ONC-1.3)</u> for bone scan coding) • CT Chest with contrast (CPT® 71260), CT Abdomen with contrast (CPT® 74160), MRI Pelvis without and with contrast (CPT® 72197), and Bone scan (see: <u>Nuclear Medicine (NM) Imaging in Oncology (ONC-1.3)</u> for bone scan coding)

Indication	Imaging Study
<p><u>Non-metastatic prostate cancer previously treated with prostatectomy or radiation therapy, and all of the following are met:</u></p> <ul style="list-style-type: none"> • PSA rises on two consecutive measurements above post-treatment baseline and • PSA ≥ 0.5 ng/mL and • Individual is a candidate for salvage local therapy 	<p>Any ONE of the following:</p> <ul style="list-style-type: none"> • PSMA PET/CT scan (CPT[®] 78815 or CPT[®] 78816) with any of the following radiotracers: <ul style="list-style-type: none"> • ⁶⁸Ga-PSMA-11 • ¹⁸F Piflufolastat (Pylarify[®]) • ¹⁸F Flotufolastat (Posluma[®]) • ⁶⁸Ga Gozetotide (Illuccix[®] and Locamet[®]) • CT Chest with contrast (CPT[®] 71260), CT Abdomen and Pelvis with contrast (CPT[®] 74177), and Bone scan • CT Chest with contrast (CPT[®] 71260), CT Abdomen with contrast (CPT[®] 74160), MRI Pelvis without and with contrast (CPT[®] 72197), and Bone scan (see: Nuclear Medicine (NM) Imaging in Oncology (ONC-1.3) for bone scan coding)
<p><u>Non-metastatic prostate cancer previously treated with prostatectomy or radiation therapy, and all of the following are met:</u></p> <ul style="list-style-type: none"> • PSA rises on two consecutive measurements above post-treatment baseline and • PSA ≥ 1 ng/mL and • Recent CT scan and bone scan are negative for metastatic disease and • Individual is a candidate for salvage local therapy 	<ul style="list-style-type: none"> • PET/CT scan (CPT[®] 78815 or CPT[®] 78816) using any ONE of the following radiotracers: <ul style="list-style-type: none"> • ¹⁸F-Fluciclovine • ¹¹C Choline
<p><u>Suspected progression of known metastatic disease based on:</u></p> <ul style="list-style-type: none"> • New or worsening signs/symptoms • Rising PSA levels 	<ul style="list-style-type: none"> • CT Chest with contrast (CPT[®] 71260), CT Abdomen and Pelvis with contrast (CPT[®] 74177), and Bone scan (see: Nuclear Medicine (NM) Imaging in Oncology (ONC-1.3) for bone scan coding) • CT with contrast of any involved or symptomatic body part

Indication	Imaging Study
Metastatic prostate cancer receiving treatment with chemotherapy	<ul style="list-style-type: none"> CT Abdomen and Pelvis with contrast (CPT® 74177) and CT scan with contrast of any involved body part every 2 cycles (6 to 8 weeks) while on chemotherapy Bone scan may be obtained every 3-6 months (see: <u>Nuclear Medicine (NM) Imaging in Oncology (ONC-1.3)</u> for bone scan coding)
Metastatic prostate cancer receiving anti-androgen therapy	<ul style="list-style-type: none"> CT Abdomen and Pelvis with contrast (CPT® 74177) and CT scan of any involved body part every 3 months while on anti-androgen therapy Bone scan may be obtained every 3-6 months (see: <u>Nuclear Medicine (NM) Imaging in Oncology (ONC-1.3)</u> for bone scan coding)
Previously treated metastatic prostate cancer progressed on conventional imaging and being considered for ¹⁷⁷ Lu-PSMA-617 (Pluvicto®) treatment ^{31, 32}	<ul style="list-style-type: none"> PSMA PET/CT scan (CPT® 78815 or CPT® 78816) with one of the following agents: <ul style="list-style-type: none"> ⁶⁸Ga PSMA-11 ¹⁸F Piflufolastat (Pylarify®) ⁶⁸Ga Gozetotide (Illuccix® and Locametz®) ¹⁸F Flotufolastat (Posluma®)
Prior to start of Xofigo (Radium-223) therapy	<ul style="list-style-type: none"> ONE time CT Chest, Abdomen, and Pelvis with contrast (CPT® 71260 and CPT® 74177)
Inconclusive bone scan	<ul style="list-style-type: none"> CT with contrast or MRI without and with contrast of involved body site

Indication	Imaging Study
<p><u>For ANY of the following:</u></p> <ul style="list-style-type: none">• Inconclusive bone findings on both CT/MRI and bone scan• Conventional imaging studies (CT and bone scan) suggests oligo- or low volume metastatic disease that needs further confirmation	<ul style="list-style-type: none">• <u>PET/CT scan (CPT® 78815 or CPT® 78816) using any one of the following radiotracers:</u><ul style="list-style-type: none">• ¹⁸F Fluciclovine• ¹¹C Choline• ⁶⁸Ga-PSMA-11• ¹⁸F Piflufolastat (Pylarify®)• ⁶⁸Ga Gozetotide (Illuccix® and Locametz®)• ¹⁸F Flotufolastat (Posluma®)

Prostate Cancer – Follow-up On Active Surveillance (ONC-19.4)

ON.PR.0019.4.A

v2.0.2024

Active surveillance is being increasingly utilized in prostate cancer, and this therapeutic option involves regimented monitoring of an individual with known diagnosis of low risk prostate cancer for disease progression, without specific anticancer treatment. While being treated with active surveillance, an individual is generally considered a potential candidate for curative intent treatment approaches in the event that disease progression occurs.

It is important to distinguish active surveillance from watchful waiting (or observation), which is generally employed in individuals with limited life expectancy. Watchful waiting involves cessation of routine monitoring and treatment is initiated only if symptoms develop.

Current active surveillance guidelines suggest the following protocol:

- PSA every 6 months
- Digital Rectal Exam (DRE) every 12 months
- Repeat prostate biopsy every 12 months
- Repeat mpMRI (CPT® 72195 or CPT® 72197) no more often than every 12 months

Indication	Imaging Study
Routine monitoring on active surveillance protocol	<ul style="list-style-type: none"> • MRI Pelvis without (CPT® 72195) or without and with contrast (CPT® 72197) at initiation of active surveillance, and every 12 months thereafter
<p><u>For ANY of the following:</u></p> <ul style="list-style-type: none"> • Progression is suspected based on DRE changes or rising PSA and a recent TRUS biopsy was negative • Repeat TRUS biopsy shows progression to a higher Gleason score 	<ul style="list-style-type: none"> • MRI Pelvis without (CPT® 72195) or MRI Pelvis without and with contrast (CPT® 72197)
Individuals on active surveillance who are noted to have progression and have plans to initiate treatment	<ul style="list-style-type: none"> • Imaging studies for initial staging as per <u>ONC-19.2</u>

Surveillance/Follow-up For Treated Prostate Cancer (ONC-19.5)

ON.PR.0019.5.A

v2.0.2024

Indication	Imaging Study
<p><u>ANY of the following:</u></p> <ul style="list-style-type: none">Asymptomatic or stable chronic symptomsStable DRE findingsStable PSA levels	<ul style="list-style-type: none">Advanced imaging is not routinely indicated for surveillance

References (ONC-19)

v2.0.2024

1. Schaeffer E, Srinivas S, Adra N, et al. National Comprehensive Cancer Network (NCCN) Guidelines Version 3.2024 – March 8, 2024. Prostate cancer, available at: https://www.nccn.org/professionals/physician_gls/pdf/prostate.pdf. Referenced with permission from the NCCN Clinical Practice Guidelines in Oncology (NCCN Guidelines™) for Prostate cancer V3.2024 – March 8, 2024. ©2024 National Comprehensive Cancer Network, Inc. All rights reserved. The NCCN Guidelines™ and illustrations herein may not be reproduced in any form for any purpose without the express written permission of the NCCN. To view the most recent and complete version of the NCCN Guidelines™, go online to NCCN.org.
2. Moses KA, Sprenkle PC, Bahler C, et al. National Comprehensive Cancer Network (NCCN) Guidelines V2.2024 – March 6, 2024. Prostate Cancer Early Detection available at: https://www.nccn.org/professionals/physician_gls/pdf/prostate_detection.pdf. Referenced with permission from the NCCN Clinical Practice Guidelines in Oncology (NCCN Guidelines™) for Prostate Cancer Early Detection V2.2024 – March 6, 2024 ©2024 National Comprehensive Cancer Network, Inc. All rights reserved. The NCCN Guidelines™ and illustrations herein may not be reproduced in any form for any purpose without the express written permission of the NCCN. To view the most recent and complete version of the NCCN Guidelines™, go online to NCCN.org.
3. Jadvar H, Calais J, Fanti S, et al. Appropriate use criteria for prostate-specific membrane antigen PET imaging, Society for Nuclear Medicine and Molecular Imaging. <https://www.snmmi.org/ClinicalPractice/content.aspx?ItemNumber=38657>.
4. Hofman MS, Lawrentschuk N, Francis RJ, et al. Prostate-specific membrane antigen PET-CT in patients with high-risk prostate cancer before curative-intent surgery or radiotherapy (proPSMA): a prospective, randomised, multicentre study. *Lancet*. 2020;395(10231):1208-1216. doi:10.1016/S0140-6736(20)30314-7.
5. Pienta KJ, Gorin MA, Rowe SP, et al. A phase 2/3 prospective multicenter study of the diagnostic accuracy of prostate specific membrane antigen PET/CT with ¹⁸F-DCFPyL in prostate cancer patients (OSPNEY). *J Urol*. 2021;206(1):52-61. doi:10.1097/JU.0000000000001698.
6. Artibani W, Porcaro AB, De Marco V, et al. Management of biochemical recurrence after primary curative treatment for prostate cancer: A review. *Urol Int*. 2018;100:251–262. doi:10.1159/000481438.
7. Zumsteg ZS, Spratt DE, Romesser PB, et al. The natural history and predictors of outcome following biochemical relapse in the dose escalation era for prostate cancer patients undergoing definitive external beam radiotherapy. *Eur Urol*. 2015;67(6):1009-1016. doi:10.1016/j.eururo.2014.09.028.
8. Trabulsi EJ, Rumble RB, Jadvar H, et al. Optimum imaging strategies for advanced prostate cancer: ASCO guideline. *J Clin Oncol*. 2020 Jan 15. doi:10.1200/JCO.19.02757 (Epub ahead of print).
9. Andriole G, Siegel B, LOCATE Study Group. PD60-12 Sites of prostate cancer recurrence delineated with ¹⁸F-Fluciclovod positron emission tomography in patients with negative or equivocal conventional imaging. *Journal of Urology*. 2019;201(4):e1100-e1101. doi:10.1097/01.JU.0000557289.21741.20.
10. ACR Appropriateness Criteria. Prostate cancer – pretreatment detection, surveillance, and staging. Rev. 2016.
11. Schoots IG, Nieboer D, Giganti F, Moore CM, Bangma CH, Roobol MJ. Is magnetic resonance imaging-targeted biopsy a useful addition to systematic confirmatory biopsy in men on active surveillance for low risk prostate cancer? A systematic review and meta-analysis. *BJU Int*. 2018;122(6):946-958. doi:10.1111/bju.14358.
12. Mullins J, Bodenkamp D, Landis P, et al. Multiparametric magnetic resonance imaging findings in men with low-risk prostate cancer followed by active surveillance. *BJU Int*. 2013;111(7):1037-1045. doi:10.1111/j.1464-410X.2012.11641.x.
13. Sanda MG, Chen RC, Crispino T, et al. *AUA/ASTRO/SUO guidelines for clinically localized prostate cancer*. Linthicum, MD: American Urological Association; 2017.
14. Lu-Yao GL, Albertsen PC, Moore DF, et al. Outcomes of localized prostate cancer following conservative management. *JAMA*. 2009;302(11):1202-1209. doi:10.1001/jama.2009.1348.
15. Chen RC, Rumble RB, Loblaw DA, et al. Active surveillance for the management of localized prostate cancer (Cancer Care Ontario guideline): American Society of Clinical Oncology clinical practice guideline endorsement. *J Clin Oncol*. 2016;34(18):2182-2190. doi:10.1200/JCO.2015.65.7759.
16. Liu D, Lehmann HP, Frick KD, Carter HB. Active surveillance versus surgery for low risk prostate cancer: a clinical decision analysis. *J Urol*. 2012;187(4):1241-1246. doi:10.1016/j.juro.2011.12.015.
17. Klotz L, Zhang L, Lam A, Nam R, Mamedov A, Loblaw A. Clinical results of long-term follow-up of a large, active surveillance cohort with localized prostate cancer. *J Clin Oncol*. 2010;28(1):126-131. doi:10.1200/JCO.2009.24.2180.

18. Blomqvist L, Carlsson S, Gjertsson P, et al. Limited evidence for the use of imaging to detect prostate cancer: a systematic review. *Eur J Radiol.* 2014;83(9):1601–1606. doi:10.1016/j.ejrad.2014.06.028.
19. Schoots IG, Petrides N, Giganti F, et al. Magnetic resonance imaging in active surveillance of prostate cancer: a systematic review. *Eur Urol.* 2015;67(4):627-636. doi:10.1016/j.eururo.2014.10.050.
20. Quentin M, Blondin D, Arsov C, et al. Prospective evaluation of magnetic resonance imaging guided in-bore prostate biopsy versus systematic transrectal ultrasound guided prostate biopsy in biopsy naïve men with elevated prostate specific antigen. *J Urol.* 2014;192(5):1374-1379. doi:10.1016/j.juro.2014.05.090.
21. Klotz L, Vesprini D, Sethukavalan P, et al. Long-term follow-up of a large active surveillance cohort of patients with prostate cancer. *J Clin Oncol.* 2015;33(3):272-277. doi:10.1200/JCO.2014.55.1192.
22. Cooperberg MR. Long-term active surveillance for prostate cancer: answers and questions. *J Clin Oncol.* 2015;33(3):238-240. doi:10.1200/JCO.2014.59.2329.
23. Risko R, Merdan S, Womble PR, et al. Clinical predictors and recommendations for staging CT scan among men with prostate cancer. *Urology.* 2014;84(6):1329-1334. doi:10.1016/j.urology.2014.07.051.
24. Heck MM, Souvatzoglou M, Retz M, et al. Prospective comparison of computed tomography, diffusion-weighted magnetic resonance imaging and [11C]choline positron emission tomography/computed tomography for preoperative lymph node staging in prostate cancer patients. *Eur J Nucl Med Mol Imaging.* 2014;41(4):694-701. doi:10.1007/s00259-013-2634-1.
25. Armstrong JM, Martin CR, Dechet C, et al. ¹⁸F-fluciclovine PET CT detection of biochemical recurrent prostate cancer at specific PSA thresholds after definitive treatment. *J Urol Onc.* 2020;38(7):636.e1-636.e6. doi:10.1016/j.urolonc.2020.03.021.
26. Baruch B, Lovrec P, Solanki A, et al. Fluorine 18 labeled fluciclovine PET/CT in clinical practice: factors affecting the rate of detection of recurrent prostate cancer. *AJR.* 2019;213(4):851-858. doi:10.2214/AJ.19.21153.
27. Marcus C, Butler P, Bagrodia A, et al. Fluorine-18-labeled fluciclovine PET/CT in primary and biochemical recurrent prostate cancer management. *AJR.* 2020;1-10. doi:10.2214/AJR.19.22404.
28. Trabulsi EJ, Rumble BR, Jadvar H, et al. Optimum imaging strategies for advanced prostate cancer: ASCO guideline. *J Clin Oncol.* 2020;38:1963-1996. doi:10.1200/JCO.19.02757.
29. Lowrance WT, Breau RH, Chou R, et al. Advanced Prostate Cancer: AUA/ASTRO/SUO Guideline PART I. *J Urol.* 2021;205:14.
30. Epstein JI, Egevad L, Amin MB, Delahunt B, Srigley JR, Humphrey PA. The 2014 International Society of Urological Pathology (ISUP) consensus conference on gleason grading of prostatic carcinoma: definition of grading patterns and proposal for a new grading system. *Am J Surg Pathol.* 2016;40(2):244-52. doi:10.1097/PAS.0000000000000530.
31. FDA Oncology Center of Excellence. FDA approves Pluvicto for metastatic castration-resistant prostate cancer. 2022. <https://www.fda.gov/drugs/resources-information-approved-drugs/fda-approves-pluvicto-metastatic-castration-resistant-prostate-cancer>.
32. Sartor O, de Bono J, Chi KN, et al. Lutetium-177-PSMA-617 for metastatic castration-resistant prostate cancer. *N Engl J Med.* 2021;385:1091-1103. doi:10.1056/NEJMoa2107322.

Testicular, Ovarian and Extragonadal Germ Cell Tumors (ONC-20)

Guideline

Testicular, Ovarian and Extragonadal Germ Cell Tumors – General Considerations (ONC-20.0)

Testicular, Ovarian and Extragonadal Germ Cell Tumors – Initial Work-Up/Staging (ONC-20.1)

Testicular, Ovarian and Extragonadal Germ Cell Tumors – Restaging/Recurrence (ONC-20.2)

Testicular, Ovarian and Extragonadal Germ Cell Tumors – Surveillance (ONC-20.3)

References (ONC-20)

Testicular, Ovarian and Extragenital Germ Cell Tumors – General Considerations (ONC-20.0)

ON.TO.0020.0.A
v2.0.2024

- This section applies to primary germ cell tumors occurring outside the central nervous system if individual's age >15 years at the time of initial diagnosis. Individuals age ≤15 years at diagnosis should be imaged according to pediatric guidelines in: **Pediatric Germ Cell Tumors (PEDONC-10)** in the Pediatric Oncology Imaging Guidelines.
- These guidelines are for germ cell tumors of the testicle, ovary and extragenital sites as well as malignant sex cord stromal tumors (granulosa cell and Sertoli-Leydig cell tumors).
- Requests for imaging must state the histologic type of the cancer being evaluated.
- Classified as pure seminomas (dysgerminomas, 40%) or Non-seminomatous germ cell tumors (NSGCT, 60%):
 - Pure seminomas are defined as pure seminoma histology with a normal serum concentration of alpha fetoprotein (AFP). Seminomas with elevated AFP are by definition Mixed.
 - Required for TNM staging are the tumor marker levels indicated by "S" (TNMS)
 - Mixed tumors are treated as NSGCTs, as they tend to be more aggressive.
 - The NSGCT histologies include:
 - Yolk-Sac tumors
 - Immature (malignant) teratomas
 - Choriocarcinomas (<1%)
 - Embryonal cell carcinomas (15% to 20%)
 - Endodermal Sinus Tumors (ovarian)
 - Combinations of all of the above (Mixed)
- MRI in place of CT scans to reduce risk of secondary malignancy is not supported by the peer-reviewed literature. CT scans are indicated for surveillance and are the preferred modality of imaging to assess for recurrence.
- PET/CT Scan is considered experimental, investigational, or unproven for evaluation of non-seminomatous germ cell tumors
- Active surveillance in testicular cancer refers to treatment with surgery (orchiectomy) alone without any additional post-operative treatment such as chemotherapy or radiotherapy

Testicular, Ovarian and Extragonadal Germ Cell Tumors – Initial Work-Up/Staging (ONC-20.1)

ON.TO.0020.1.A
v2.0.2024

Indication	Imaging Study
Orchiectomy/oophorectomy is both diagnostic and therapeutic	<u>All individuals, following orchiectomy or oophorectomy:</u> <ul style="list-style-type: none">• CT Abdomen and Pelvis with contrast (CPT® 74177)
<u>For ANY of the following:</u> <ul style="list-style-type: none">• Non-seminoma histology• Ovarian germ cell tumor• Abdominal lymphadenopathy noted on CT scan• Abnormal Chest X-ray or signs/symptoms suggestive of chest involvement	<ul style="list-style-type: none">• CT Chest with contrast (CPT® 71260)
Extragonadal Germ Cell Tumor	<ul style="list-style-type: none">• CT Chest with contrast (CPT® 71260) and CT Abdomen and Pelvis with contrast (CPT® 74177)

Testicular, Ovarian and Extragonadal Germ Cell Tumors – Restaging/Recurrence (ONC-20.2)

ON.TO.0020.2.A
v2.0.2024

Indication	Imaging Study
Treatment response for stage II-IV individuals with measurable disease on CT	<ul style="list-style-type: none"> CT with contrast of previously involved body areas every 2 cycles
Seminoma with residual mass >3 cm after completion of chemotherapy	<ul style="list-style-type: none"> PET/CT (CPT® 78815)
End of therapy evaluation for NSGCT post chemotherapy or post retroperitoneal lymph node dissection (RPLND)	<ul style="list-style-type: none"> CT Abdomen and Pelvis with contrast (CPT® 74177)
Recurrence suspected, including increased tumor markers	<ul style="list-style-type: none"> CT Chest (CPT® 71260) and CT Abdomen and Pelvis (CPT® 74177) with contrast Ultrasound (CPT® 76856 or CPT® 76857) of the remaining gonad if applicable
Unexplained pulmonary symptoms despite a negative chest x-ray, or new findings on chest x-ray	<ul style="list-style-type: none"> CT Chest with contrast (CPT® 71260)
All others	<ul style="list-style-type: none"> See: Surveillance (ONC-20.3)

Testicular, Ovarian and Extragonadal Germ Cell Tumors – Surveillance (ONC-20.3)

ON.TO.0020.3.A
v2.0.2024

Indication	Imaging Study
Stage I Seminoma treated with orchiectomy alone (no radiotherapy or chemotherapy, also called active surveillance)	<ul style="list-style-type: none"> CT Abdomen and Pelvis with contrast (CPT® 74177) or CT Abdomen with contrast (CPT® 74160) once at 4-6 months and 12 months post-orchiectomy, then every 6 months for years 2 and 3, and then annually until year 5
Stage I Seminoma treated with radiotherapy and/or chemotherapy	<ul style="list-style-type: none"> CT Abdomen and Pelvis with contrast (CPT® 74177) or CT Abdomen with contrast (CPT® 74160) annually for 3 years
Stage IIA and non-bulky Stage IIB Seminomas treated with radiotherapy or chemotherapy	<ul style="list-style-type: none"> CT Abdomen and Pelvis with contrast (CPT® 74177) or CT Abdomen with contrast (CPT® 74160) once at 3 months then once at 9-12 months after completion of therapy, then annually for 2 additional years
Bulky Stage IIB, IIC, and III Seminomas treated with chemotherapy	<p><u>For individuals with ≤3 cm residual mass:</u></p> <ul style="list-style-type: none"> CT Abdomen and Pelvis with contrast (CPT® 74177) or CT Abdomen with contrast (CPT® 74160) every 4 months for 1 year, every 6 months for 1 year and then annually for 2 additional years <p><u>For individuals with >3 cm residual mass and negative PET scan:</u></p> <ul style="list-style-type: none"> CT Abdomen and Pelvis with contrast (CPT® 74177) or CT Abdomen with contrast (CPT® 74160) at 6 and 12 months after completion of therapy, then annually until year 5 <p><u>For individuals with thoracic disease:</u></p> <ul style="list-style-type: none"> CT Chest with contrast (CPT® 71260) every 2 months for 1 year, then every 3 months for 1 year, then annually until year 5 after completion of therapy

Indication	Imaging Study
Stage IA Non-Seminomatous germ cell tumors treated with orchiectomy alone (without risk factors)	<ul style="list-style-type: none"> CT Abdomen and Pelvis with contrast (CPT[®] 74177) or CT Abdomen with contrast (CPT[®] 74160) every 6 months for 2 years and then annually for 1 additional year
Stage IB Non-Seminomatous germ cell tumors treated with orchiectomy alone (with risk factors – lymphovascular invasion or invasion into spermatic cord/scrotum)	<ul style="list-style-type: none"> CT Abdomen and Pelvis with contrast (CPT[®] 74177) or CT Abdomen with contrast (CPT[®] 74160) every 4 months for 1 year, then every 6 months for 2 years, then annually until year 4
Stage IA/IB Non-Seminomatous germ cell tumors treated with chemotherapy and/or primary RPLND	<ul style="list-style-type: none"> CT Abdomen and Pelvis with contrast (CPT[®] 74177) or CT Abdomen with contrast (CPT[®] 74160) annually for 2 years
Stage II-III Non-Seminomatous germ cell tumors with complete response to chemotherapy +/- post-chemotherapy RPLND	<ul style="list-style-type: none"> CT Abdomen and Pelvis with contrast (CPT[®] 74177) or CT Abdomen with contrast (CPT[®] 74160) once at 6, 12, 24 and 36 months after completion of therapy <p><u>For individuals with thoracic disease:</u></p> <ul style="list-style-type: none"> CT Chest with contrast (CPT[®] 71260) every 6 months for 2 years, then annually until year 4 after completion of therapy
Stage IIA or IIB Non-Seminomatous germ cell tumors treated with post-primary RPLND <u>and</u> adjuvant chemotherapy	<ul style="list-style-type: none"> CT Abdomen and Pelvis with contrast (CPT[®] 74177) or CT Abdomen with contrast (CPT[®] 74160) once at 4 months after completion of RPLND
Stage IIA or IIB Non-Seminomatous germ cell tumors treated with post-primary RPLND <u>without</u> adjuvant chemotherapy	<ul style="list-style-type: none"> CT Abdomen and Pelvis with contrast (CPT[®] 74177) or CT Abdomen with contrast (CPT[®] 74160) once at 3 to 4 months after completion of therapy and repeat annually for 1 additional year
All stages of ovarian dysgerminoma germ cell tumors	<ul style="list-style-type: none"> CT Abdomen and Pelvis with contrast (CPT[®] 74177) every 4 months for 1 year, every 6 months for 1 year and then annually for 3 years after completion of therapy

Indication	Imaging Study
<u>All ovarian non-dysgerminoma germ cell tumors</u> <ul style="list-style-type: none">Embryonal tumorEndodermal sinus tumorImmature teratomaNon-gestational choriocarcinoma	<ul style="list-style-type: none">CT Abdomen and Pelvis with contrast (CPT[®] 74177) every 4 months for 1 year, every 6 months for 1 year and then annually for 3 years after completion of therapyCT Chest with contrast (CPT[®] 71260) every 4 months for 1 year and every 6 months for 1 year after completion of therapy
<ul style="list-style-type: none">Sex cord stromal tumors (male and female)Mature teratoma	<ul style="list-style-type: none">No routine advanced imaging indicated unless elevated tumor markers or clinical signs/symptoms of recurrence
Extragenital germ cell tumors	<ul style="list-style-type: none">CT of the involved region every 3 months for one year and every 6 months for one year.

References (ONC-20)

v2.0.2024

1. Gilligan T, Lin DW, Aggarwal R, et al. National Comprehensive Cancer Network (NCCN) Guidelines Version 1.2023 – January 26, 2023. Testicular cancer, available at: https://www.nccn.org/professionals/physician_gls/pdf/testicular.pdf Referenced with permission from the NCCN Clinical Practice Guidelines in Oncology (NCCN Guidelines™) for Testicular cancer V1.2023 – January 26, 2023. ©2023 National Comprehensive Cancer Network, Inc. All rights reserved. The NCCN Guidelines™ and illustrations herein may not be reproduced in any form for any purpose without the express written permission of the NCCN. To view the most recent and complete version of the NCCN Guidelines™, go online to NCCN.org.
2. Armstrong DK, Alvarez RD, Backes FJ, et al. National Comprehensive Cancer Network (NCCN) Guidelines Version 1.2024 – January 17, 2024. Ovarian cancer, including fallopian tube cancer and primary peritoneal cancer, available at: https://www.nccn.org/professionals/physician_gls/pdf/ovarian.pdf Referenced with permission from the NCCN Clinical Practice Guidelines in Oncology (NCCN Guidelines™) for Ovarian cancer V1.2024 – January 17, 2024. ©2024 National Comprehensive Cancer Network, Inc. All rights reserved. The NCCN Guidelines™ and illustrations herein may not be reproduced in any form for any purpose without the express written permission of the NCCN. To view the most recent and complete version of the NCCN Guidelines™, go online to NCCN.org.
3. Salani R, Backes FJ, Fung MF, et al. Post treatment surveillance and diagnosis of recurrence in women with gynecologic malignancies: Society of Gynecologic Oncologists recommendations. *Am J Obstet Gynecol.* 2011;204(6):466-478. doi:10.1016/j.ajog.2011.03.008.
4. Gershenson DM. Management of ovarian germ cell tumors. *J Clin Oncol.* 2007;25(20):2938-2943. doi:10.1200/JCO.2007.10.8738.
5. Colombo N, Parma G, Zanagnolo V, Insinga A. Management of ovarian stromal cell tumors. *J Clin Oncol.* 2007;25(20):2944-2951. doi:10.1200/JCO.2007.11.1005.
6. Cadron I, Leunen K, Van Gorp T, Amant F, Neven P, Vergote I. Management of Borderline Ovarian Neoplasms. *J Clin Oncol.* 2007;25(20):2928-2937. doi:10.1200/JCO/2007.10.8076.
7. del Carmen MG, Birrer M, Schorge JO. Carcinosarcoma of the ovary: a review of the literature. *Gynecol Oncol.* 2012;125(1):271-277. Doi:10.1016/j.ygyno.2011.12.418.
8. Kollmannsberger C, Tandstad T, Bedard PL, et al. Patterns of relapse in patients with clinical stage I testicular cancer managed with active surveillance. *J Clin Oncol.* 2015;33(1):51-57. doi:10.1200/JCO.2014.56.2116.
9. Oechsle K, Hartmann M, Brenner W, et al. [18F]Fluorodeoxyglucose positron emission tomography in nonseminomatous germ cell tumors after chemotherapy: the German multicenter positron emission tomography study group. *J Clin Oncol.* 2008;26(36):5930-5935. doi:10.1200/JCO.2008.17.1157.
10. Daugard G, Gundgaard MG, Mortensen MS, et al. Surveillance for stage I non seminoma testicular cancer: outcomes and long term follow-up in a population based cohort. *J. Clin Oncol.* 2014;32(34):3817-3823. doi:10.1200/JCO.2013.53.5831.
11. Zuniga A, Kakiashvili D, Jewett MA. Surveillance in stage I nonseminomatous germ cell tumours of the testis. *BJU Int.* 2009;104:1351-1356. doi:10.1111/j.1464-410X.2009.08858.x.

Ovarian Cancer (ONC-21)

Guideline

Ovarian Cancer – General Considerations (ONC-21.0)

Screening for Ovarian Cancer (ONC-21.1)

Ovarian Cancer – Suspected/Diagnosis (ONC-21.2)

Ovarian Cancer – Initial Work-Up/Staging (ONC-21.3)

Ovarian Cancer – Restaging/Recurrence (ONC-21.4)

Ovarian Cancer – Surveillance (ONC-21.5)

References (ONC-21)

Ovarian Cancer – General Considerations (ONC-21.0)

ON.OC.0021.0.A

v2.0.2024

- Ovarian cancers include: epithelial ovarian cancers, ovarian cancers of low malignant potential and mixed Müllerian tumors, primary peritoneal and fallopian tube cancers.
 - There are five main types of epithelial ovarian cancers:
 - High-grade serous carcinoma (HGSC) (70%)
 - Endometrioid carcinoma (EC) (10%)
 - Clear cell carcinoma (CCC) (10%)
 - Mucinous carcinoma (MC) (3%)
 - Low-grade serous carcinoma (LGSC) (<5%)
- Borderline tumors (formerly referred to as tumors of low malignant potential) usually have some feature of carcinoma when they recur.
- Fallopian tube and primary peritoneal are usually serous carcinoma.
- Germ cell tumors and sex cord stromal tumors (granulosa cell tumors), are imaged according to **Testicular, Ovarian and Extragonadal Germ Cell Cancer (ONC-20)**.

Screening for Ovarian Cancer (ONC-21.1)

ON.OC.0021.1.A
v2.0.2024

Indication	Imaging/Lab Study
<p><u>High-Risk Factors:</u></p> <ul style="list-style-type: none">• Family history of BRCA 1 or BRCA 2 mutations• Family history of ovarian cancer• Hereditary ovarian cancer syndrome that includes ovarian, breast, and/or endometrial and gastrointestinal cancers [Lynch II syndrome] in multiple members of two to four generations• Low parity• Decreased fertility• Delayed childbearing	<ul style="list-style-type: none">• Ovarian cancer screening is considered experimental & investigational and is not recommended.• Genetic counseling is recommended for women with an increased-risk family history (USPSTF, 2015)
<p>Known BRCA-1 or BRCA-2 mutation</p>	<ul style="list-style-type: none">• Transvaginal ultrasound (CPT® 76830), combined with CA-125 for ovarian cancer screening may be considered annually starting at age 30, until risk-reducing salpingo-oophorectomy is performed

Ovarian Cancer – Suspected/Diagnosis (ONC-21.2)

ON.OC.0021.2.A

v2.0.2024

- See: **Complex Adnexal Masses (PV-5.3)** for imaging guidelines for evaluation of suspected ovarian malignancies
- Staging of ovarian cancer is primarily surgical and routine imaging is not indicated pre-operatively, unless it is obtained to evaluate specific signs/symptoms.
- To differentiate the origin of pelvic masses that are not clearly of ovarian origin, see: **Suspected Adnexal Mass (PV-5.1)**

Indication	Imaging/Lab Study
<ul style="list-style-type: none"> • Pelvic symptoms (pelvic pain, abdominal bloating) • Palpable pelvic mass 	<ul style="list-style-type: none"> • Transvaginal (TV) ultrasound imaging (CPT® 76830) and/or Pelvic ultrasound (CPT® 76856 or CPT® 76857)
<p>Ultrasound shows a complex and/or solid adnexal mass</p>	<ul style="list-style-type: none"> • See: Complex Adnexal Masses (PV-5.3)
<p>Ultrasound shows complex and/or solid adnexal mass suspicious for ovarian malignancy AND any of the following signs/symptoms concerning for metastatic disease:</p> <ul style="list-style-type: none"> • Ascites • Abdominal symptoms (distension, tenderness) • Elevated CA-125 • Elevated LFTs • Obstructive uropathy** 	<ul style="list-style-type: none"> • CT Abdomen and Pelvis with contrast (CPT® 74177) • **CT Abdomen and Pelvis without and with contrast (CT Urogram – CPT® 74178) may be approved only for symptoms of obstructive uropathy

Ovarian Cancer – Initial Work-Up/Staging (ONC-21.3)

ON.OC.0021.3.A

v2.0.2024

Indication	Imaging Study
Clinical stage II disease or higher	<ul style="list-style-type: none">• CT Abdomen and Pelvis with contrast (CPT® 74177)• CT Chest with contrast (CPT® 71260) for:<ul style="list-style-type: none">• Abnormal signs/symptoms of pulmonary disease• Abnormal chest x-ray
<p><u>ANY of the following:</u></p> <ul style="list-style-type: none">• Primary peritoneal disease with biopsy-proven malignancy consistent with ovarian carcinoma• Elevated tumor markers with negative or inconclusive CT imaging	<ul style="list-style-type: none">• PET/CT (CPT® 78815)

Ovarian Cancer – Restaging/Recurrence (ONC-21.4)

ON.OC.0021.4.A

v2.0.2024

Indication	Imaging Study
Completely resected or definitively treated with chemotherapy and normal(ized) tumor markers	<ul style="list-style-type: none"> No advanced imaging needed
<u>ANY of the following:</u> <ul style="list-style-type: none"> Unresected disease Unknown preoperative markers Difficult or abnormal examination Elevated LFTs Elevated tumor markers (CA-125, inhibin) Signs or symptoms of recurrence 	<ul style="list-style-type: none"> CT Abdomen and Pelvis with contrast (CPT® 74177) CT Chest with contrast (CPT® 71260) for ANY of the following: <ul style="list-style-type: none"> Known prior thoracic disease New or worsening pulmonary symptoms New or worsening chest x-ray findings Rising tumor markers (CA-125, inhibin)
Monitoring response to treatment (every 2 cycles, or ~every 6 to 8 weeks)	<ul style="list-style-type: none"> CT Abdomen and Pelvis with contrast (CPT® 74177) CT Chest with contrast (CPT® 71260) for ANY of the following: <ul style="list-style-type: none"> Known prior thoracic disease New or worsening pulmonary symptoms New or worsening chest x-ray findings
<ul style="list-style-type: none"> CT negative or inconclusive and CA-125 continues to rise or elevated LFTs Conventional imaging failed to demonstrate tumor or if persistent radiographic mass with rising tumor markers 	<ul style="list-style-type: none"> PET/CT (CPT® 78815)

Ovarian Cancer – Surveillance (ONC-21.5)

ON.OC.0021.5.A
v2.0.2024

Indication	Imaging Study
Stages I-III	<ul style="list-style-type: none">Advanced imaging is not routinely indicated for surveillance
Measurable metastatic disease on maintenance therapy or being monitored off therapy	<p><u>Every 3 months for up to 5 years after completion of active treatment:</u></p> <ul style="list-style-type: none">CT Abdomen and Pelvis with contrast (CPT[®] 74177)CT with contrast of previously involved body areas

References (ONC-21)

v2.0.2024

1. Armstrong DK, Alvarex RD, Backes FJ, et al. National Comprehensive Cancer Network (NCCN) Guidelines Version 2.2023 – June 2, 2023. Ovarian Cancer Including Fallopian Tube Cancer and Primary Peritoneal Cancer available at: https://www.nccn.org/professionals/physician_gls/pdf/ovarian.pdf Referenced with permission from the NCCN Clinical Practice Guidelines in Oncology (NCCN Guidelines™) for Ovarian Cancer Including Fallopian Tube Cancer and Primary Peritoneal Cancer V2.2023 – June 2, 2023. ©2023 National Comprehensive Cancer Network, Inc. All rights reserved. The NCCN Guidelines™ and illustrations herein may not be reproduced in any form for any purpose without the express written permission of the NCCN. To view the most recent and complete version of the NCCN Guidelines™, go online to NCCN.org.
2. Daly MB, Pal T, AlHilli Z, et al. National Comprehensive Cancer Network (NCCN) Guidelines Version V3.2023 – February 13, 2023. Genetic/Familial High-Risk Assessment: Breast, Ovarian, and Pancreatic available at: https://www.nccn.org/professionals/physician_gls/pdf/genetics_bop.pdf Referenced with permission from the NCCN Clinical Practice Guidelines in Oncology (NCCN Guidelines™) for Ovarian cancer V3.2023 – February 13, 2023. ©2023 National Comprehensive Cancer Network, Inc. All rights reserved. The NCCN Guidelines™ and illustrations herein may not be reproduced in any form for any purpose without the express written permission of the NCCN. To view the most recent and complete version of the NCCN Guidelines™, go online to NCCN.org.
3. Moyer VA, U.S. Preventive Services Task Force. Screening for ovarian cancer: U.S. Preventive Services Task Force reaffirmation recommendation statement. *Ann Intern Med.* 2012;157(12):900-904. doi:10.7326/0003-4819-157-11-201212040-00539.
4. Cadron I, Leunen K, Van Gorp T, Amant F, Neven P, Vergote I. Management of borderline ovarian neoplasms. *J Clin Oncol.* 2007;25(20):2928-2937. doi:10.1200/JCO.2007.10.8076.
5. ACR Appropriateness Criteria. *Ovarian cancer screening.* Rev. 2017.
6. Rosenthal AN, Fraser LSM, Phipott S. Evidence of stage shift in women diagnosed with ovarian cancer during phase II of the United Kingdom familial ovarian cancer screening study. *J Clin Oncol.* 2017;35(13):13:1411-1420. doi:10.1200/JCO.2016.69.9330.
7. Shinagare AB, O'Neill AC, Cheng S, et al. Advanced high-grade serous ovarian cancer: frequency and timing of thoracic metastases and the implications for chest imaging follow-up. *Radiology.* 2015;277(3):733-740. doi:10.1148/radiol.2015142467.
8. Musto A, Grassetto G, Marzola MC, et al. Management of epithelial ovarian cancer from diagnosis to restaging: an overview of the role of imaging techniques with particular regard to the contribution of 18F-FDG PET/CT. *Nucl Med Commun.* 2014;35(6):588-597. doi:10.1097/MNM.000000000000091.
9. Fischerova D, Burgetova A. Imaging techniques for the evaluation of ovarian cancer. *Best Pract Res Clin Obstet Gynaecol.* 2014;28(5):697-720. doi:10.1016/j.bpobgyn.2014.04.006.

Uterine Cancer (ONC-22)

Guideline

- Uterine Cancer – General Considerations (ONC-22.0)
- Uterine Cancer – Suspected/Diagnosis (ONC-22.1)
- Uterine Cancer – Initial Work-Up/Staging (ONC-22.2)
- Uterine Cancer – Restaging/Recurrence (ONC-22.3)
- Uterine Cancer – Surveillance (ONC-22.4)
- Gestational Trophoblastic Neoplasia (GTN) (ONC-22.5)
- References (ONC-22)

Uterine Cancer – General Considerations (ONC-22.0)

ON.UC.0022.0.A

v2.0.2024

- Gestational trophoblastic neoplasia (GTN) – see: **Molar Pregnancy and Gestational Trophoblastic Neoplasia (GTN) (PV-16.1)** in the Pelvic Imaging Guidelines.
- Most common cell type is adenocarcinoma. Uterine sarcomas are also imaged according to this guideline.
- Staging of uterine cancer is primarily surgical. Advanced imaging is not routinely indicated pre-operatively for laparoscopic/minimally invasive surgery unless initial staging criteria are met. Pelvic and para-aortic lymphadenectomy can still be performed.

Uterine Cancer – Suspected/Diagnosis (ONC-22.1)

ON.UC.0022.1.A

v2.0.2024

- See: **Abnormal Uterine Bleeding (PV-2.1)** in the Pelvic Imaging Guidelines for evaluation of suspected uterine malignancies.

Uterine Cancer – Initial Work-Up/Staging (ONC-22.2)

ON.UC.0022.2.A

v2.0.2024

Indication	Imaging Study
<p><u>ANY of the following:</u></p> <ul style="list-style-type: none"> • Extruterine disease suspected • To assess local extent of tumor prior to fertility-sparing surgery for well-differentiated Stage IA (grade 1) uterine cancer • Poor surgical candidate (due to medical comorbidities) considering medical therapy 	<ul style="list-style-type: none"> • MRI Pelvis without and with contrast (CPT® 72197) • Transvaginal ultrasound (CPT® 76830) if MRI is contraindicated • Chest x-ray <ul style="list-style-type: none"> • CT Chest with contrast (CPT® 71260) if chest x-ray is abnormal
<p><u>ANY of the following:</u></p> <ul style="list-style-type: none"> • Abdominal symptoms or abnormal examination findings • Elevated LFTs • Other imaging studies suggest liver involvement 	<p><u>ONE of the following:</u></p> <ul style="list-style-type: none"> • CT Abdomen and Pelvis with contrast (CPT® 74177) • CT Abdomen with contrast (CPT® 74160)
<p><u>ANY of the following high-risk histologies:</u></p> <ul style="list-style-type: none"> • Papillary serous • Clear cell • High-grade/poorly differentiated endometrioid carcinoma • Uterine sarcomas: <ul style="list-style-type: none"> • Carcinosarcoma • Soft tissue sarcoma of the uterus • Leiomyosarcoma • Rhabdomyosarcoma • Undifferentiated sarcoma • Endometrial stromal sarcoma 	<ul style="list-style-type: none"> • CT Chest (CPT® 71260) and CT Abdomen and Pelvis (CPT® 74177) with contrast

Indication	Imaging Study
<p><u>Tumors detected incidentally or incompletely staged surgically and ANY of the following high-risk features:</u></p> <ul style="list-style-type: none">• Myoinvasion >50%• Cervical stromal involvement• Lymphovascular invasion• Tumor >2 cm	<ul style="list-style-type: none">• CT Chest (CPT® 71260) and CT Abdomen and Pelvis (CPT® 74177) with contrast
<p>Inconclusive findings on conventional imaging</p>	<ul style="list-style-type: none">• PET/CT scan (CPT® 78815)

Uterine Cancer – Restaging/Recurrence (ONC-22.3)

ON.UC.0022.3.A

v2.0.2024

Indication	Imaging Study
<ul style="list-style-type: none"> • Unresected disease • Medically inoperable disease • Incomplete surgical staging • Difficult or abnormal examination • Elevated LFTs or rising tumor markers • Signs or symptoms of recurrence 	<ul style="list-style-type: none"> • CT Chest (CPT® 71260) and • CT Abdomen and Pelvis with contrast (CPT® 74177)
<p><u>Monitoring response to chemotherapy (every 2 cycles, ~every 6-8 weeks) for:</u></p> <ul style="list-style-type: none"> • Unresected primary disease • Metastatic disease 	<ul style="list-style-type: none"> • CT Abdomen and Pelvis with contrast (CPT® 74177) • CT Chest with contrast (CPT® 71260) for: <ul style="list-style-type: none"> • New/worsening pulmonary symptoms • Abnormal chest x-ray findings • Known prior pulmonary involvement
<p><u>Any of the following:</u></p> <ul style="list-style-type: none"> • After fertility sparing treatment • Inconclusive CT scan findings 	<ul style="list-style-type: none"> • MRI Pelvis without and with contrast (CPT® 72197)
<ul style="list-style-type: none"> • Inconclusive findings on conventional imaging 	<ul style="list-style-type: none"> • PET/CT (CPT® 78815)

Uterine Cancer – Surveillance (ONC-22.4)

ON.UC.0022.4.A

v2.0.2024

Indication	Imaging Study
Stage I-III of uterine carcinoma	Advanced imaging is not routinely indicated for surveillance
Measurable metastatic disease on maintenance therapy or being monitored off therapy	<p><u>Every 3 months for up to 5 years after completion of definitive treatment:</u></p> <ul style="list-style-type: none"> • CT Abdomen and Pelvis with contrast (CPT® 74177) • CT with contrast of previously involved body areas
<p><u>All stages of uterine sarcoma:</u></p> <ul style="list-style-type: none"> • Soft tissue sarcoma of the uterus • Leiomyosarcoma • Adenosarcoma • Carcinosarcoma • Rhabdomyosarcoma • Undifferentiated sarcoma • Endometrial stromal sarcoma 	CT Chest (CPT® 71260) and CT Abdomen and Pelvis with contrast (CPT® 74177) every 3 months for 2 years, every 6 months for 3 years, and then every 1-2 years until year 10

Gestational Trophoblastic Neoplasia (GTN) (ONC-22.5)

ON.UC.0022.5.A

v2.0.2024

- The most common form of gestational trophoblastic disease (GTD) is hydatidiform mole (HM), a benign form, also known as molar pregnancy.
 - See: **Molar Pregnancy and GTN (PV-16.1)**
- Gestational trophoblastic neoplastic disorders including a malignant form of GTD, and can present as invasive mole, choriocarcinoma, placental site trophoblastic tumor (PSTT), or epithelioid trophoblastic tumor (ETT). GTN cells are malignant and can metastasize to other organs such as lungs, brain, bone and vagina. These tumors have a high likelihood of cure and treatment with methotrexate usually allows for fertility preservation.
- Surveillance is generally with serial monitoring of HCG levels, and advanced imaging is reserved for high-risk histologies where HCG levels may not be a reliable marker.

Indication	Imaging Study
Initial staging	<ul style="list-style-type: none"> • CT Chest with contrast (CPT® 71260) • CT Abdomen and Pelvis with contrast (CPT® 74177)
<u>EITHER of the following:</u> <ul style="list-style-type: none"> • Pulmonary metastases noted on CT scan • Signs/symptoms of CNS involvement 	<ul style="list-style-type: none"> • MRI Brain without and with contrast (CPT® 70553)
<u>EITHER of the following:</u> <ul style="list-style-type: none"> • Monitoring response to systemic therapy (every 2 cycles, i.e., 6-8 weeks) • Suspected progression 	<ul style="list-style-type: none"> • CT Chest with contrast (CPT® 71260) • CT Abdomen and Pelvis with contrast (CPT® 74177)
<u>Surveillance for any of the following high risk histologies:</u> <ul style="list-style-type: none"> • Placental site trophoblastic tumor (PSTT) • Epithelioid trophoblastic tumor (ETT) 	<u>Annually for 2 years:</u> <ul style="list-style-type: none"> • CT Chest with contrast (CPT® 71260) • CT Abdomen and Pelvis with contrast (CPT® 74177)

References (ONC-22)

v2.0.2024

1. Abu-Rustum NR, Yashar CM, Arend R, et al. National Comprehensive Cancer Network (NCCN) Guidelines Version 2.2023 – April 28, 2023. Uterine Neoplasms, available at: https://www.nccn.org/professionals/physician_gls/pdf/uterine.pdf Referenced with permission from the NCCN Clinical Practice Guidelines in Oncology (NCCN Guidelines™) for Uterine Neoplasms 2.2023 – April 28, 2023. ©2023 National Comprehensive Cancer Network, Inc. All rights reserved. The NCCN Guidelines™ and illustrations herein may not be reproduced in any form for any purpose without the express written permission of the NCCN. To view the most recent and complete version of the NCCN Guidelines™, go online to NCCN.org.
2. Fader AN, Boruta D, Olawaiye AB, Gehrig PA. Updates on uterine papillary serous carcinoma. *Expert Rev Obstet Gynecol.* 2009;4(6):647-657. doi:10.1586/eog.09.49.
3. Boruta DM 2nd, Gehrig PA, Fader AN, Olawaiye AB. Management of women with uterine papillary serous cancer: A Society of Gynecologic Oncology (SGO) review. *Gynecol Oncol.* 2009;115(1):142-153. doi:10.1016/j.ygyno.2009.06.011.
4. Olawaiye AB, Boruta DM 2nd. Management of women with clear cell endometrial cancer: a Society of Gynecologic Oncology (SGO) review. *Gynecol Oncol.* 2009;113(2):277-283. doi:10.1016/j.ygyno.2009.02.003.
5. Salani R, Backes FJ, Fung MF et al. Post treatment surveillance and diagnosis of recurrence in women with gynecologic malignancies: Society of Gynecologic Oncologists recommendations. *Am J Obstet Gynecol.* 2011;204(6):466-478. doi:10.1016/j.ajog.2011.03.008.
6. Reinhold C, Ueno Y, Akin EA, et. al. ACR Appropriateness Criteria® - Evaluation and follow-up of endometrial cancer. Available at <https://acsearch.acr.org/docs/69459/Narrative/>. American College of Radiology. Accessed 7/29/2020.
7. Abu-Rustum NR, Yashar CM, Bradley, K, et al. National Comprehensive Cancer Network (NCCN) Guidelines Version 2.2021 – March 31, 2021. Gestational Trophoblastic Neoplasia, available at: https://www.nccn.org/professionals/physician_gls/pdf/cns.pdf. Referenced with permission from the NCCN Clinical Practice Guidelines in Oncology (NCCN Guidelines™ for Gestational Trophoblastic Neoplasia, March 31, 2021 National Comprehensive Cancer Network, Inc. All rights reserved. The NCCN Guidelines™ and illustrations herein may not be reproduced in any form for any purpose without the express written permission of the NCCN. To view the most recent and complete version of the NCCN Guidelines™, go online to NCCN.org.

Cervical Cancer (ONC-23)

Guideline

Cervical Cancer – General Considerations (ONC-23.0)

Cervical Cancer – Suspected/Diagnosis (ONC-23.1)

Cervical Cancer – Initial Work-Up/Staging (ONC-23.2)

Cervical Cancer – Restaging/Recurrence (ONC-23.3)

Cervical Cancer – Surveillance (ONC-23.4)

References (ONC-23)

Cervical Cancer – General Considerations (ONC-23.0)

ON.CV.0023.0.A

v2.0.2024

- Primary histology for cervical cancer is squamous cell. Other, less common histologies are adenosquamous and adenocarcinoma. If biopsy is consistent with one of these less common histologies, it is necessary to clarify that tumor is not of primary uterine origin.
- If the primary histology is uterine in origin, follow imaging recommendations for uterine cancer, see: **Uterine Cancer (ONC-22)**.

Cervical Cancer – Suspected/Diagnosis (ONC-23.1)

ON.CV.0023.1.A

v2.0.2024

Indication	Imaging Study
All	<ul style="list-style-type: none">• Biopsy should be performed prior to imaging

Cervical Cancer – Initial Work-Up/Staging (ONC-23.2)

ON.CV.0023.2.A

v2.0.2024

Indication	Imaging Study
Stage IB1 or higher stages	<p><u>ANY of the following combinations, not both:</u></p> <ul style="list-style-type: none"> • PET/CT (CPT® 78815) <p>or</p> <ul style="list-style-type: none"> • CT Chest with contrast (CPT® 71260) and CT Abdomen and Pelvis with contrast (CPT® 74177)
Any size cervical cancer incidentally found in a hysterectomy specimen	<ul style="list-style-type: none"> • CT Chest with contrast (CPT® 71260) • CT Abdomen and Pelvis with contrast (CPT® 74177)
<p><u>ANY of the following:</u></p> <ul style="list-style-type: none"> • To assess local extent of disease • To assess residual pelvic disease post-operatively • Inconclusive CT findings 	<ul style="list-style-type: none"> • MRI Pelvis without and with contrast (CPT® 72197)
Inconclusive findings on conventional imaging	<ul style="list-style-type: none"> • PET/CT (CPT® 78815)

Cervical Cancer – Restaging/Recurrence (ONC-23.3)

ON.CV.0023.3.A

v2.0.2024

Indication	Imaging Study
Stage I treated with definitive surgery	<ul style="list-style-type: none"> See: Cervical Cancer – Surveillance (ONC-23.4)
Stage I-III treated with primary radiation therapy ± chemotherapy (no surgery)	<p><u>ANY of the following, not both:</u></p> <ul style="list-style-type: none"> PET/CT (CPT® 78815) at least 12 weeks after completion of treatment <p>OR</p> <ul style="list-style-type: none"> CT Chest (CPT® 71260) and CT Abdomen and Pelvis (CPT® 74177) with contrast
<ul style="list-style-type: none"> After completion of primary non-surgical treatment (radiation therapy +/- chemotherapy) Inconclusive findings on CT scan 	MRI Pelvis without and with contrast (CPT® 72197)
Unresectable disease or metastatic disease on systemic treatment	<p><u>Every 2 cycles of treatment (commonly every 6 to 8 weeks):</u></p> <ul style="list-style-type: none"> CT Chest with contrast (CPT® 71260) CT Abdomen and Pelvis with contrast (CPT® 74177) CT with contrast of other involved or symptomatic areas
Suspected or biopsy proven recurrence	<p><u>ANY of the following, not both:</u></p> <ul style="list-style-type: none"> PET/CT (CPT® 78815) <p>OR</p> <ul style="list-style-type: none"> CT Chest (CPT® 71260) and CT Abdomen and Pelvis with contrast (CPT® 74177)

Cervical Cancer – Surveillance (ONC-23.4)

ON.CV.0023.4.A
v2.0.2024

Indication	Imaging Study
Stage I disease treated with fertility sparing approach	<ul style="list-style-type: none">MRI Pelvis without and with contrast (CPT® 72197) at 6 months after surgery and then annually for 2 years
All individuals	<ul style="list-style-type: none">No routine advanced imaging needed in asymptomatic individuals.

References (ONC-23)

v2.0.2024

1. Abu-Rustum NR, Yashar CM, Arend R, et al. National Comprehensive Cancer Network (NCCN) Guidelines Version 2.2024 – February 23, 2024. Cervical Cancer, available at: https://www.nccn.org/professionals/physician_gls/pdf/cervical.pdf. Referenced with permission from the NCCN Clinical Practice Guidelines in Oncology (NCCN Guidelines™) for Cervical Cancer V2.2024 – February 23, 2024. ©2024 National Comprehensive Cancer Network, Inc. All rights reserved. The NCCN Guidelines™ and illustrations herein may not be reproduced in any form for any purpose without the express written permission of the NCCN. To view the most recent and complete version of the NCCN Guidelines™, go online to NCCN.org.
2. Salani R, Backes FJ, Fung MF et al. Post treatment surveillance and diagnosis of recurrence in women with gynecologic malignancies: Society of Gynecologic Oncologists recommendations. *Am J Obstet Gynecol.* 2011;204(6):466-478. doi:10.1016/j.ajog.2011.03.008.
3. Zanagnolo V, Ming L, Gadducci A, et al. Surveillance procedures for patients with cervical carcinoma: a review of the literature. *Int J Gynecol Cancer.* 2009;19(3):194-201. doi:10.1111/IGC.0b013e3181a130f3.
4. Elit L, Fyles AW, Devries MC, et al. Follow-up for women after treatment for cervical cancer: A systematic review. *Gynecol Oncol.* 2009;114(3):528-535. doi:10.1016/j.ygyno.2009.06.001.
5. Schwarz JK, Siegel BA, Dehdashti F, Grigsby PW. Association of posttherapy positron emission tomography with tumor response and survival in cervical carcinoma. *JAMA.* 2007;298(19):2289-2295. doi:10.1001/jama.298.19.2289.
6. Meads C, Davenport C, Malysiak S, et al. Evaluating PET-CT in the detection and management of recurrent cervical cancer: systematic reviews of diagnostic accuracy and subjective elicitation. *BJOG.* 2014;121(4):398-407. doi:10.1111/1471-0528.12488.
7. Chu Y, Zheng A, Wang F, et al. Diagnostic value of 18F-FDG-PET or PET-CT in recurrent cervical cancer: a systematic review and meta-analysis. *Nucl Med Commun.* 2014; 35(2):144-150. doi:10.1097/MNM.000000000000026.

Anal Cancer & Cancers of the External Genitalia (ONC-24)

Guideline

Anal Carcinoma – General Considerations (ONC-24.0)

Anal Carcinoma – Suspected/Diagnosis (ONC-24.1)

Anal Carcinoma – Initial Work-up/Staging (ONC-24.2)

Anal Carcinoma – Restaging/Recurrence (ONC-24.3)

Anal Carcinoma – Surveillance (ONC-24.4)

Cancers of External Genitalia – General Considerations (ONC-24.5)

Cancers of External Genitalia – Initial Work-Up/Staging (ONC-24.6)

Cancers of External Genitalia – Restaging/Recurrence (ONC-24.7)

Cancers of External Genitalia – Surveillance (ONC-24.8)

References (ONC-24)

Anal Carcinoma – General Considerations (ONC-24.0)

ON.AN.0024.0.A

v2.0.2024

- Most are squamous cell carcinomas, although some transitional and cloacogenic carcinomas are seen.
- Adenocarcinoma of the anal canal is managed as rectal cancer according to **Colorectal and Small Bowel Cancer (ONC-16)**
- Squamous cell carcinoma of the perianal region (up to 5 cm radius from the anal verge) are imaged according to anal carcinoma guidelines.
- Bowen’s disease and Paget’s disease of the perianal and perigenital skin are considered non-invasive/in-situ conditions and do not routinely require advanced imaging. See: **Non-Melanoma Skin Cancers – Initial Work-up/Staging (ONC-5.6)**

Anal Carcinoma – Suspected/Diagnosis (ONC-24.1)

ON.AN.0024.1.A

v2.0.2024

Indication	Imaging Study
All	<ul style="list-style-type: none">Advanced imaging prior to biopsy is not needed

Anal Carcinoma – Initial Work-up/Staging (ONC-24.2)

ON.AN.0024.2.A

v2.0.2024

Indication	Imaging Study
All individuals	<ul style="list-style-type: none">CT Chest with contrast (CPT® 71260) and <p><u>Any ONE of the following:</u></p> <ul style="list-style-type: none">CT Abdomen and Pelvis with contrast (CPT® 74177)CT Abdomen with contrast (CPT® 74160) and MRI Pelvis without and with contrast (CPT® 72197)
<ul style="list-style-type: none">Stage II-III Squamous Cell Carcinoma of the Anal Canal and no evidence of metastatic disease by conventional imagingInconclusive findings on conventional imaging	<ul style="list-style-type: none">PET/CT (CPT® 78815)

Anal Carcinoma – Restaging/Recurrence (ONC-24.3)

ON.AN.0024.3.A

v2.0.2024

Indication	Imaging Study
Stage I treated with complete surgical resection	<ul style="list-style-type: none"> See: <u>Anal Carcinoma – Surveillance (ONC-24.4)</u> for surveillance guidelines
Stages I, II and III – post chemoradiation evaluation	<p><u>Any ONE</u> of the following:</p> <ul style="list-style-type: none"> CT Abdomen and Pelvis with contrast (CPT® 74177) MRI Abdomen (CPT® 74183) and MRI Pelvis (CPT® 72197) without and with contrast
Metastatic (stage IV) disease	<ul style="list-style-type: none"> CT Abdomen and Pelvis with contrast (CPT® 74177) every 2 cycles (generally 6 to 8 weeks) on treatment CT Chest with contrast (CPT® 71260) if Chest X-ray is abnormal or if symptoms of chest involvement
<ul style="list-style-type: none"> Difficult or abnormal examination Elevated LFTs Signs or symptoms of recurrence Biopsy proven recurrence 	<ul style="list-style-type: none"> CT Chest (CPT® 71260) with contrast and <u>Any ONE</u> of the following: CT Abdomen and Pelvis with contrast (CPT® 74177) MRI Abdomen (CPT® 74183) and MRI Pelvis (CPT® 72197) without and with contrast
Inconclusive findings on conventional imaging	<ul style="list-style-type: none"> PET/CT (CPT® 78815)

Anal Carcinoma – Surveillance (ONC-24.4)

ON.AN.0024.4.A

v2.0.2024

Indication	Imaging Study
Stage I	<ul style="list-style-type: none"> Advanced imaging is not routinely indicated for surveillance
<ul style="list-style-type: none"> Stage II Stage III Local recurrence treated definitively 	<ul style="list-style-type: none"> CT Chest (CPT® 71260) with contrast or CT Chest without contrast (CPT® 71250) annually for 3 years And ANY one of the following annually for three years: <ul style="list-style-type: none"> CT Abdomen and Pelvis with contrast (CPT® 74177) MRI Abdomen without and with contrast (CPT® 74183) and MRI Pelvis without and with contrast (CPT® 72197)
Stage IV – measurable metastatic disease on maintenance treatment or being observed off treatment	<p><u>Every 3 months for up to 5 years after completion of all treatment:</u></p> <ul style="list-style-type: none"> CT Chest (CPT® 71260) with contrast CT Abdomen and Pelvis with contrast (CPT® 74177)

Cancers of External Genitalia – General Considerations (ONC-24.5)

ON.AN.0024.5.A

v2.0.2024

- These imaging guidelines are applicable for squamous cell carcinomas arising from the vulva, vagina, penis, urethra, and scrotum

Cancers of External Genitalia – Initial Work-Up/Staging (ONC-24.6)

ON.AN.0024.6.A

v2.0.2024

Indication	Imaging Study
Clinical node negative vulvar cancer with ANY of the following: <ul style="list-style-type: none"> • Lesion >2 cm • Any size with stromal invasion >1 mm 	<ul style="list-style-type: none"> • For planned sentinel lymph node (SLN) biopsy: Lymph system imaging (lymphoscintigraphy, CPT® 78195) • SPECT/CT (CPT® 78830) is indicated as an add on code if requested
For stage II or higher	<u>ONE of the following:</u> <ul style="list-style-type: none"> • CT Abdomen and Pelvis with contrast (CPT® 74177) OR • CT Abdomen with contrast (CPT® 74160) and MRI Pelvis without and with contrast (CPT® 72197) • CT Chest with contrast (CPT® 71260) is indicated only for: <ul style="list-style-type: none"> • Signs/symptoms suggestive of chest involvement • Abnormal findings on chest x-ray
Inconclusive findings on conventional imaging	<ul style="list-style-type: none"> • PET/CT (CPT® 78815)

Cancers of External Genitalia – Restaging/Recurrence (ONC-24.7)

ON.AN.0024.7.A

v2.0.2024

Indication	Imaging Study
<ul style="list-style-type: none">• Difficult or abnormal examination• Elevated LFTs• Signs or symptoms of recurrence• Biopsy proven recurrence	<ul style="list-style-type: none">• CT Chest with contrast (CPT® 71260) <u>And ANY one of the following:</u>• CT Abdomen and Pelvis with contrast (CPT® 74177)• MRI Abdomen (CPT® 74183) and MRI Pelvis (CPT® 72197) without and with contrast
Individuals receiving systemic treatment	<ul style="list-style-type: none">• CT Abdomen and Pelvis with contrast (CPT® 74177) every 2 cycles (generally 6 to 8 weeks) during treatment and at the end of planned chemotherapy treatment• CT Chest with contrast (CPT® 71260) if chest x-ray is abnormal or if symptoms of chest involvement
Inconclusive findings on conventional imaging	<ul style="list-style-type: none">• PET/CT (CPT® 78815)

Cancers of External Genitalia – Surveillance (ONC-24.8)

ON.AN.0024.8.A

v2.0.2024

Indication	Imaging Study
<ul style="list-style-type: none">All stages of vulvar and vaginal cancers	<ul style="list-style-type: none">Routine advanced imaging is not indicated for asymptomatic surveillance
<ul style="list-style-type: none">Penile Cancer: stage I- IIIA	<ul style="list-style-type: none">Routine advanced imaging is not indicated for asymptomatic surveillance
<ul style="list-style-type: none">Penile cancer: stages IIIB and higher	<ul style="list-style-type: none">CT Abdomen and Pelvis with contrast (CPT® 74177) every 3 months for year 1, and then every 6 months for year 2, then no further routine advanced imaging indicated

References (ONC-24)

v2.0.2024

1. Benson III AB, Venook AP, Al-Hawary MM, et al. National Comprehensive Cancer Network (NCCN) Guidelines Version 2.2023 – April 28, 2023. Anal Carcinoma, available at: https://www.nccn.org/professionals/physician_gls/pdf/anal.pdf. Referenced with permission from the NCCN Clinical Practice Guidelines in Oncology (NCCN Guidelines™) for anal carcinoma V2.2023– April 28, 2023. ©2023 National Comprehensive Cancer Network, Inc. All rights reserved. The NCCN Guidelines™ and illustrations herein may not be reproduced in any form for any purpose without the express written permission of the NCCN. To view the most recent and complete version of the NCCN Guidelines™, go online to NCCN.org.
2. Flaig TW, Spiess PE, Agarwal N. National Comprehensive Cancer Network (NCCN) Guidelines Version 1.2023 – December 1, 2022. Penile Cancer, available at: https://www.nccn.org/professionals/physician_gls/pdf/penile.pdf. Referenced with permission from the NCCN Clinical Practice Guidelines in Oncology (NCCN Guidelines™) for Penile Cancer V1.2023 – December 1, 2022. ©2022 National Comprehensive Cancer Network, Inc. All rights reserved. The NCCN Guidelines™ and illustrations herein may not be reproduced in any form for any purpose without the express written permission of the NCCN. To view the most recent and complete version of the NCCN Guidelines™, go online to NCCN.org.
3. Abu-Rustum NR, Yashar CM, Arend R. et al. National Comprehensive Cancer Network (NCCN) Guidelines Version 1.2023 – December 22, 2022. Vulvar Cancer (Squamous Cell Carcinoma), available at: https://www.nccn.org/professionals/physician_gls/pdf/vulvar.pdf. Referenced with permission from the NCCN Clinical Practice Guidelines in Oncology (NCCN Guidelines™) for Vulvar Cancer (Squamous Cell Carcinoma) V1.2023 – December 22, 2022. ©2022 National Comprehensive Cancer Network, Inc. All rights reserved. The NCCN Guidelines™ and illustrations herein may not be reproduced in any form for any purpose without the express written permission of the NCCN. To view the most recent and complete version of the NCCN Guidelines™, go online to NCCN.org.
4. Bhuvana NJ, Glynne-Jones R, Sonoda L, Wong WL, Harrison MK. To PET or not to PET? That is the question. Staging in anal cancer. *Ann Oncol.* 2012;23(8):2078-2082. doi:10.1093/annonc/mdr599.
5. Mistrangelo M, Pelosi E, Bellò M, et al. Role of positron emission tomography-computed tomography in the management of anal cancer. *Int J Radiat Oncol Biol Phys.* 2012;84(1):66-72. doi:10.1016/j.ijrobp.2011.10.048.
6. Jones M, Hruby G, Solomon M, Rutherford N, Martin J. The role of FDG-PET in the initial staging and response assessment of anal cancer: a systematic review and meta-analysis. *Ann Surg Oncol.* 2015;22(11):3574-3581. doi:10.1245/s10434-015-4391-9.
7. Moncrieff M, Pywell S, Snelling A, et. al. Effectiveness of SPECT/CT imaging for sentinel node biopsy staging of primary cutaneous melanoma and patient outcomes. *Ann Surg Oncol.* 2022;29(2):767-775. doi:10.1245/s10434-021-10911-4.
8. Quartuccio N, Garau LM, Arnone A, et. al. Comparison of 99mTc-labeled colloid SPECT/CT and planar lymphoscintigraphy in sentinel lymph node detection in patients with melanoma: a meta-analysis. *J Clin Med.* 2020;9(6):1680. doi:10.3390/jcm9061680.
9. Bennie G, Vorster M, Buscombe J, Sathekge M. The added value of a single-photon emission computed tomography-computed in sentinel lymph node mapping in patients with breast cancer and malignant melanoma. *World J Nucl Med.* 2015;14(01):41-46. doi:10.4103/1450-1147.150543

Multiple Myeloma and Plasmacytomas (ONC-25)

Guideline

Multiple Myeloma and Plasmacytomas – General Considerations
(ONC-25.0)

Multiple Myeloma and Plasmacytomas – Suspected/Diagnosis
(ONC-25.1)

Multiple Myeloma and Plasmacytomas – Initial Work-Up/Staging
(ONC-25.2)

Multiple Myeloma and Plasmacytomas – Restaging/Recurrence
(ONC-25.3)

Multiple Myeloma and Plasmacytomas – Surveillance (ONC-25.4)

References (ONC-25)

Multiple Myeloma and Plasmacytomas – General Considerations (ONC-25.0)

ON.MM.0025.0.A

v2.0.2024

- Multiple myeloma (MM) is a neoplastic disorder characterized by the proliferation of a single clone of plasma cells derived from B cells which grows in the bone marrow and adjacent bone, producing skeletal destruction.
- Multiple myeloma group of disorders can be classified as below, which influence imaging modality of choice.

Condition	Monoclonal protein	Bone marrow plasma cells	CRAB criteria**
Solitary Plasmacytoma (biopsy proven tumor containing plasma cells)	<3 gm/dL	Absent	Absent
Monoclonal Gammopathy of Unknown Significance (MGUS)	<3 gm/dL	<10%	Absent
Smoldering Myeloma (SMM) (stage I MM or asymptomatic MM)	≥3 gm/dL	10% - 60%	Absent
Multiple Myeloma (MM)	≥3 gm/dL	≥10%	Present

**CRAB criteria = hypercalcemia, renal insufficiency, anemia, lytic bony lesions

- Diagnosis and monitoring of response to therapy is primarily with laboratory studies that include urine and serum monoclonal protein levels, serum free light chain levels, LDH and beta-2 microglobulin. Routine advanced imaging to monitor response to treatment is not indicated.
- Rarely, (<5%), an individual may have Nonsecretory Myeloma, which does not produce measurable M-protein. These individuals require imaging as primary method to monitor disease.
- Other conditions that may present with Monoclonal Gammopathy include:
 - **POEMS syndrome:** Polyneuropathy, Organomegaly, Endocrinopathy, Monoclonal protein and Skin Changes – may also have sclerotic bone lesions and Castleman’s disease. See: **Multiple Myeloma and Plasmacytomas – Initial Work-up/Staging (ONC-25.2)** for imaging recommendations.
 - **Waldenström’s Macroglobulinemia:** IgM monoclonal protein along with bone marrow infiltration of small lymphocytes. See: **Waldenström Macroglobulinemia or Lymphoplasmacytic Lymphoma (ONC-27.10)** for imaging recommendations.
 - **Systemic Light chain Amyloidosis:** light chain monoclonal protein in serum or urine with clonal plasma cells in bone marrow, systemic involvement of the kidneys, liver, heart, gastrointestinal tract or peripheral nerves due to amyloid

deposition. See: **Multiple Myeloma and Plasmacytomas – Initial Work-up/Staging (ONC-25.2)** and **Cardiac Amyloidosis (CD-3.8)** for imaging recommendations for systemic light chain amyloidosis.

Multiple Myeloma and Plasmacytomas –Suspected/Diagnosis (ONC-25.1)

ON.MM.0025.1.A

v2.0.2024

Indication	Imaging Study
All	<ul style="list-style-type: none"><li data-bbox="586 499 919 527">• X-ray skeletal series

Multiple Myeloma and Plasmacytomas – Initial Work-Up/Staging (ONC-25.2)

ON.MM.0025.2.A

v2.0.2024

Indication	Imaging Study
<p><u>ANY of the following:</u></p> <ul style="list-style-type: none"> Abnormal skeletal survey Abnormal myeloma labs Signs/symptoms of multiple myeloma 	<ul style="list-style-type: none"> Whole-body low-dose skeletal CT (CPT® 76497)
<p><u>ANY of the following:</u></p> <ul style="list-style-type: none"> If skeletal CT is negative, inconclusive, or not feasible Suspected solitary bone/osseous plasmacytoma 	<p><u>ONE of the following:</u></p> <ul style="list-style-type: none"> MRI Bone Marrow Blood Supply (CPT® 77084) MRI Cervical (CPT® 72141), Thoracic (CPT® 72146), Lumbar spine (CPT® 72148), and Pelvis (CPT® 72195) without contrast MRI Cervical (CPT® 72156), Thoracic (CPT® 72157), Lumbar spine (CPT® 72158), and Pelvis (CPT® 72197) without and with contrast CT contrast as requested of a specific area to determine radiotherapy or surgical candidacy, or for suspected extra-osseous plasmacytoma
<p><u>ANY of the following (after above tests completed):</u></p> <ul style="list-style-type: none"> Determine if plasmacytoma is truly solitary Suspected extra-osseous plasmacytomas Suspected progression of MGUS or SMM to a more malignant form and CT/MRI imaging are negative Whole-body skeletal CT and MRI Bone Marrow are negative, inconclusive, or not feasible 	<ul style="list-style-type: none"> PET/CT (CPT® 78815 or CPT® 78816)
<p><u>ANY of the following:</u></p> <ul style="list-style-type: none"> Systemic light chain amyloidosis POEMS syndrome 	<ul style="list-style-type: none"> CT Chest with contrast (CPT® 71260) and CT Abdomen and Pelvis with contrast (CPT® 74177)

Multiple Myeloma and Plasmacytomas – Restaging/Recurrence (ONC-25.3)

ON.MM.0025.3.A

v2.0.2024

Indication	Imaging Study
Extra-osseous plasmacytoma response to initial therapy	<p><u>ONE of the following:</u></p> <ul style="list-style-type: none"> • CT of any previously involved area, contrast as requested • MRI of any previously involved area, contrast as requested
Known spine involvement with new neurological signs/symptoms or worsening pain	<ul style="list-style-type: none"> • MRI Cervical (CPT® 72156), Thoracic (CPT® 72157), Lumbar spine (CPT® 72158) without and with contrast
<p><u>Treatment response assessment</u></p> <ul style="list-style-type: none"> • After completion of primary therapy • Non-secretory multiple myeloma • To determine therapy response with inconclusive labs 	<p><u>ONE of the following:</u></p> <ul style="list-style-type: none"> • Whole-body low-dose skeletal CT scan (CPT® 76497) • MRI Bone Marrow Blood Supply (CPT® 77084) • MRI Cervical (CPT® 72141), Thoracic (CPT® 72146), Lumbar spine (CPT® 72148), and Pelvis (CPT® 72195) without contrast • MRI Cervical (CPT® 72156), Thoracic (CPT® 72157), Lumbar spine (CPT® 72158), and Pelvis (CPT® 72197) without and with contrast • MRI without contrast, or MRI without and with contrast for any previously involved bony area or symptomatic area
CAR-T cell therapy	<p><u>Once before treatment and once 30-60 days after completion of treatment:</u></p> <ul style="list-style-type: none"> • PET/CT (CPT® 78815 or CPT® 78816)

Indication	Imaging Study
<p><u>ANY of the following:</u></p> <ul style="list-style-type: none"> • Suspected relapse/recurrence • Suspected progression of MGUS or SMM to a more malignant form 	<p><u>ONE of the following:</u></p> <ul style="list-style-type: none"> • Whole-body low-dose skeletal CT (CPT® 76497) • MRI Bone Marrow Blood Supply (CPT® 77084) • MRI Cervical (CPT® 72141), Thoracic (CPT® 72146), Lumbar spine (CPT® 72148), and Pelvis (CPT® 72195) without contrast • MRI Cervical (CPT® 72156), Thoracic (CPT® 72157), Lumbar spine (CPT® 72158), and Pelvis (CPT® 72197) without and with contrast • MRI without contrast, or MRI without and with contrast for any previously involved bony area or symptomatic area
<p><u>ANY of the following:</u></p> <ul style="list-style-type: none"> • Negative PET will allow change in management from active treatment to maintenance or surveillance. • Inconclusive findings on conventional imaging 	<ul style="list-style-type: none"> • PET/CT (CPT® 78815 or CPT® 78816)
<p>Stem cell transplant recipients</p>	<p><u>ONE of the following, once before transplant and once within 30-100 days after transplant:</u></p> <ul style="list-style-type: none"> • Whole-body low-dose skeletal CT scan (CPT® 76497) • MRI Bone Marrow Blood Supply (CPT® 77084) • MRI Cervical (CPT® 72141), Thoracic (CPT® 72146), Lumbar spine (CPT® 72148), and Pelvis (CPT® 72195) without contrast • MRI Cervical (CPT® 72156), Thoracic (CPT® 72157), Lumbar spine (CPT® 72158), and Pelvis (CPT® 72197) without and with contrast

Multiple Myeloma and Plasmacytomas – Surveillance (ONC-25.4)

ON.MM.0025.4.A

v2.0.2024

Indication	Study
<ul style="list-style-type: none">• Plasmacytomas• Smoldering myeloma• Multiple myeloma	<p><u>ANY ONE</u> of the following annually for 5 years:</p> <ul style="list-style-type: none">• Whole-body low-dose skeletal CT (CPT® 76497)• MRI Bone Marrow Blood Supply (CPT® 77084)

References (ONC-25)

v2.0.2024

1. Kumar SK, Callander NS, Adekola K, et al. National Comprehensive Cancer Network (NCCN) Guidelines Version 3.2023 – December 8, 2022. Myeloma, available at: https://www.nccn.org/professionals/physician_gls/pdf/myeloma.pdf Referenced with permission from the NCCN Clinical Practice Guidelines in Oncology (NCCN Guidelines™) for Myeloma V3.2023 – December 8, 2022. ©2022 National Comprehensive Cancer Network, Inc. All rights reserved. The NCCN Guidelines™ and illustrations herein may not be reproduced in any form for any purpose without the express written permission of the NCCN. To view the most recent and complete version of the NCCN Guidelines™, go online to NCCN.org.
2. Hillengass J, Usmani S, Rajkumar SV, Durie BGM, Mateos M, Lonial S. International myeloma working group consensus recommendations on imaging in monoclonal plasma cell disorders. *The Lancet*. 2019;20(6):PE302-E312. doi:10.1016/S1470-2045(19)30309-2.
3. Kyle RA, Remstein ED, Therneau TM, et al. Clinical course and prognosis of smoldering (asymptomatic) multiple myeloma. *N Engl J Med*. 2007;356:2582-2590. doi:10.1056/NEJMoa070389.
4. Dimopoulos M, Terpos E, Comenzo RL, et al. International myeloma working group consensus statement and guidelines regarding the current role of imaging techniques in the diagnosis and monitoring of multiple myeloma. *Leukemia*. 2009;23(9):1545-1556. doi:10.1038/leu.2009.89.
5. ACR Committee on Drugs and Contrast Media. ACR Manual on Contrast Media, version 10.3. Reston, VA: American College of Radiology; 2018.
6. Mulligan ME, Badros AZ. PET/CR and MR imaging in myeloma. *Skeletal Radiol*. 2007;36(1):5-16. doi:10.1007/s00256-006-0184-3.
7. Dimopoulos MA, Hillengrass J, Usmani S, et al. Role of magnetic resonance imaging in the management of patients with multiple myeloma: a consensus statement. *J Clin Oncol*. 2015;33(6):657-664. doi:10.1200/JCO.2014.57.9961.
8. Dimopoulos M, Terpos E, Comenzo RL, et al. International myeloma working group consensus statement and guidelines regarding the current role of imaging techniques in the diagnosis and monitoring of multiple myeloma. *Leukemia*. 2009;23(9):1545-1556. doi:10.1038.leu.2008.89.
9. Dammacco F, Rubini G, Ferrari C, Vacca A, Racanelli V. 18F-FDG PET/CT: a review of diagnostic and prognostic features in multiple myeloma and related disorders. *Clin Exp Med*. 2015;15(1):1-18. doi:10.1007/s10238-014-0308-3.
10. Ferraro R, Agarwal A, Martin-Macintosh EL, Peller PJ, Subramaniam RM. MR imaging and PET/CT in diagnosis and management of multiple myeloma. *Radiographics*. 2015;35(2):438-454. doi:10.1148/rg.352140112.
11. Rajkumar SV, Kumar S. Multiple myeloma: diagnosis and treatment. *Mayo Clin Proc*. 2016;91(1):101-119. doi:10.1016/j.mayocp.2015.11.007.
12. Westerland O, Amlani A, Kelly-Morland C, et al. Comparison of the diagnostic performance and impact on management of 18F-FDG PET/CT and whole-body MRI in multiple myeloma. *Eur J Nucl ed Mol Imaging*. 2021. doi:10.1007/s00259-020-05182-2

Leukemias, Myelodysplasia and Myeloproliferative Neoplasms (ONC-26)

Guideline

Leukemias, Myelodysplasia and Myeloproliferative Neoplasms – General Considerations (ONC-26.1)

Acute Leukemias (ONC-26.2)

Chronic Myeloid Leukemias, Myelodysplastic Syndrome and Myeloproliferative Disorders (ONC-26.3)

Chronic Lymphocytic Leukemia (CLL)/Small Lymphocytic Lymphoma (SLL) (ONC-26.4)

References (ONC-26)

Leukemias, Myelodysplasia and Myeloproliferative Neoplasms – General Considerations (ONC-26.1)

ON.LM.0026.1.A

v2.0.2024

- PET imaging is considered investigational, experimental, or unproven for all indications in acute lymphoblastic leukemia, acute myeloid leukemia, and chronic myeloid leukemia.
- Routine advanced imaging is not indicated for the evaluation and management of Hairy cell leukemia in the absence of specific localizing clinical symptoms.

Acute Leukemias (ONC-26.2)

ON.LM.0026.2.A

v2.0.2024

- Imaging indications for acute lymphoblastic leukemia in adult individuals are identical to those for pediatric individuals. See: **Acute Lymphoblastic Leukemia (ALL) (PEDONC-3.2)** in the Pediatric Oncology Imaging Guidelines.
- Imaging indications for acute myeloid leukemia in adult individuals are identical to those for pediatric individuals. See: **Acute Myeloid Leukemia (AML) (PEDONC-3.3)** in the Pediatric Oncology Imaging Guidelines.

Chronic Myeloid Leukemias, Myelodysplastic Syndrome and Myeloproliferative Disorders (ONC- 26.3)

ON.LM.0026.3.A
v2.0.2024

- Routine advanced imaging is not indicated in the evaluation and management of chronic myeloid leukemias, myelodysplastic syndromes or myeloproliferative disorders in the absence of specific localizing clinical symptoms or clearance for hematopoietic stem cell transplantation.
- See: **Hematopoietic Stem Cell Transplantation (ONC-29)** for imaging guidelines related to transplant.
- For work-up of elevated blood counts, see: **Paraneoplastic Syndromes – General Considerations (ONC-30.3)**.

Chronic Lymphocytic Leukemia (CLL)/ Small Lymphocytic Lymphoma (SLL) (ONC-26.4)

ON.LM.0026.4.A
v2.0.2024

- PET imaging is not indicated in the evaluation of CLL/SLL with the exception of suspected Richter’s transformation (See Suspected transformation, below).
- CLL/SLL is monitored with serial laboratory studies. Routine advanced imaging is not indicated for monitoring treatment response or surveillance, except when initial studies reveal bulky disease involvement.
- Bulky disease is defined as lymph node mass >10 cm or spleen >6 cm below costal margin

Indication	Imaging Study
Initial Staging/Diagnosis	<ul style="list-style-type: none"> • Advanced imaging is not routinely indicated for initial evaluation of asymptomatic individuals
<p><u>For ANY of the following:</u></p> <ul style="list-style-type: none"> • Bulky lymph node mass (>10 cm) • Splenomegaly >6 cm below costal margin • Presence of B symptoms • Progressive anemia and thrombocytopenia • Prior to planned systemic therapy 	<p><u>ANY or ALL of the following may be approved:</u></p> <ul style="list-style-type: none"> • CT Chest with contrast (CPT® 71260) • CT Abdomen and Pelvis with contrast (CPT® 74177)
Treatment Response	<ul style="list-style-type: none"> • For individuals with bulky nodal disease at diagnosis, CT with contrast of previously involved area(s) every 2 cycles of therapy • Routine imaging is not indicated for individuals without bulky nodal disease at diagnosis
End of Therapy Evaluation	<ul style="list-style-type: none"> • For individuals with bulky nodal disease at diagnosis, CT with contrast of previously involved area(s)
Suspected Progression	<p><u>ANY or ALL of the following may be approved:</u></p> <ul style="list-style-type: none"> • CT Chest with contrast (CPT® 71260) • CT Abdomen and Pelvis with contrast (CPT® 74177) • CT with contrast of previously involved area(s)

Indication	Imaging Study
<p><u>Suspected transformation (Richter's) from a low-grade lymphoma to a more aggressive type based on one or more of the following:</u></p> <ul style="list-style-type: none">• New B symptoms• Rapidly growing lymph nodes• Extranodal disease develops• Significant recent rise in LDH above normal range	<ul style="list-style-type: none">• PET/CT (CPT® 78815 or CPT® 78816)
<p>Surveillance</p>	<p><u>For individuals with bulky nodal disease at diagnosis, every 6 months for two years, then annually:</u></p> <ul style="list-style-type: none">• CT Chest with contrast (CPT® 71260)• CT Abdomen and Pelvis with contrast (CPT® 74177)• CT with contrast of previously involved area(s) <p>Routine imaging is not indicated for individuals without bulky nodal disease at diagnosis</p>

References (ONC-26)

v2.0.2024

1. Wierda WG, Brown J, Abramson JS, et al. National Comprehensive Cancer Network (NCCN) Guidelines Version 3.2023 – June 12, 2023. Chronic Lymphocytic Leukemia/Small Lymphocytic Lymphoma, available at: https://www.nccn.org/professionals/physician_gls/pdf/cll.pdf Referenced with permission from the NCCN Clinical Practice Guidelines in Oncology (NCCN Guidelines™) for Chronic Lymphocytic Leukemia/Small Lymphocytic Lymphoma V3.2023 – June 12, 2023. ©2023 National Comprehensive Cancer Network, Inc. All rights reserved. The NCCN Guidelines™ and illustrations herein may not be reproduced in any form for any purpose without the express written permission of the NCCN. To view the most recent and complete version of the NCCN Guidelines™, go online to NCCN.org.
2. Conte MJ, Bowen DA, Wiseman GA, et al. Use of positron emission tomography-computed tomography in the management of patients with chronic lymphocytic leukemia/small lymphocytic lymphoma. *Leuk Lymphoma*. 2014;55(9):2079-2084. doi:10.3109/10428194.2013.869801.
3. Mauro FR, Chauvie S, Paoloni F, et al. Diagnostic and prognostic role of PET/CT in patients with chronic lymphocytic leukemia and progressive disease. *Leukemia*. 2015;29(6):1360-1365. doi:10.1038/leu.2015.21.
4. Nabhan C, Rosen ST. Chronic lymphocytic leukemia: a clinical review. *JAMA*. 2014;312(21):2265-2276. doi:10.1001/jama.2014.14553.
5. Patnaik MM, Tefferi A. Chronic myelomonocytic leukemia: focus on clinical practice. *Mayo Clin Proc*. 2016;91(2):259-272. doi:10.1016/j.mayocp.2015.11.011.
6. American Society of Hematology. Choosing Wisely: Don't perform baseline or routine surveillance computed tomography (CT) scans in patients with asymptomatic, early-stage chronic lymphocytic leukemia (CLL). 2014. <https://www.choosingwisely.org/clinician-lists/american-society-hematology-baseline-or-routine-surveillance-ct-scans-for-asymptomatic-early-stage-chronic-lymphocytic-leukemia/>.

Non-Hodgkin Lymphomas (ONC-27)

Guideline

- Non-Hodgkin Lymphomas – General Considerations (ONC-27.1)
- Diffuse Large B Cell Lymphoma (DLBCL) (ONC-27.2)
- Follicular Lymphoma (ONC-27.3)
- Marginal Zone Lymphomas (ONC-27.4)
- Mantle Cell Lymphoma (ONC-27.5)
- Burkitt's Lymphomas (ONC-27.6)
- Lymphoblastic Lymphomas (ONC-27.7)
- T Cell Lymphomas (ONC-27.8)
- Post-Transplant Lymphoproliferative Disorders (ONC-27.9)
- Waldenström Macroglobulinemia or Lymphoplasmacytic Lymphoma (ONC-27.10)
- References (ONC-27)

Non-Hodgkin Lymphomas – General Considerations (ONC-27.1)

ON.NH.0027.1.A

v2.0.2024

- Lymphoma is often suspected when individuals have any of the following:
 - Bulky lymphadenopathy (lymph node mass >10 cm in size), hepatomegaly or splenomegaly
 - The presence of systemic symptoms (fever, drenching night sweats or unintended weight loss of >10%, called “B symptoms”)
- Individuals with AIDS-related lymphoma should be imaged according to the primary lymphoma histology
- See: **Castleman’s Disease (unicentric and multicentric) (ONC-31.11)** for guidelines covering Castleman’s disease.
- See: **Chronic Lymphocytic Leukemia (CLL)/Small Lymphocytic Lymphoma (SLL) (ONC-26.4)** for guidelines covering Chronic Lymphocytic Leukemia (CLL)/Small Lymphocytic Lymphoma (SLL).

Indication	Imaging Study
<p><u>Biopsy proven lymphoma or suspected lymphoma with one of the following:</u></p> <ul style="list-style-type: none"> • Bulky lymphadenopathy (LN mass >10 cm) • Hepatomegaly • Splenomegaly • B symptom: Unexplained fever, drenching night sweats, unintended weight loss >10% total body weight 	<ul style="list-style-type: none"> • CT Chest (CPT® 71260) and CT Abdomen and Pelvis (CPT® 74177) with contrast • MRI without and with contrast for individuals who cannot tolerate CT contrast due to allergy or impaired renal function
Signs or symptoms of disease involving the neck	<ul style="list-style-type: none"> • CT Neck with contrast (CPT® 70491)
Signs or symptoms suggesting CNS involvement with lymphoma.	<ul style="list-style-type: none"> • MRI Brain without and with contrast (CPT® 70553) • See: CNS Lymphoma (also known as Microglioma) (ONC-2.7)
Known or suspected bone involvement with lymphoma	<ul style="list-style-type: none"> • MRI without and with contrast of symptomatic or previously involved bony areas • Bone scan is inferior to MRI for evaluation of known or suspected bone involvement with lymphoma

Indication	Imaging Study
Determine a more favorable site for biopsy when a relatively inaccessible site is contemplated	<ul style="list-style-type: none">• PET/CT (CPT® 78815 or CPT® 78816)• PET/CT is not indicated for all other indications prior to histological confirmation of lymphoma
CAR-T cell therapy	<p><u>Once before treatment and once 30-60 days after completion of treatment:</u></p> <ul style="list-style-type: none">• PET/CT (CPT® 78815 and CPT® 78816)

Diffuse Large B Cell Lymphoma (DLBCL) (ONC-27.2)

ON.TO.0027.2.A

v2.0.2024

- Grey zone lymphomas, primary mediastinal B cell lymphomas, Grade 3 (high) follicular lymphoma, double-hit or triple-hit lymphomas, and primary cutaneous diffuse large B cell lymphoma should also be imaged according to these guidelines.

Indication	Imaging Study
Initial Staging/Diagnosis	<p><u>ONE of the following may be approved:</u></p> <ul style="list-style-type: none"> • PET/CT (CPT® 78815 or CPT® 78816) <p>OR</p> <ul style="list-style-type: none"> • CT Chest with contrast (CPT® 71260) and CT Abdomen and Pelvis with contrast (CPT® 74177)
Treatment response for all stages	<p><u>ANY one of the following may be approved, not both:</u></p> <ul style="list-style-type: none"> • CT with contrast of previously involved area(s) may be approved every 2 cycles (6-8 weeks) of therapy <p>Or</p> <ul style="list-style-type: none"> • PET/CT (CPT® 78815 or CPT® 78816) after 3-4 cycles of chemotherapy
End of Chemotherapy and/or Radiation Therapy Evaluation	<p><u>ANY or ALL of the following may be approved:</u></p> <ul style="list-style-type: none"> • PET/CT (CPT® 78815 or CPT® 78816) may be approved at the end of chemotherapy and again at the end of radiation • CT with contrast of previously involved area(s)
Suspected Recurrence	<p><u>ANY or ALL of the following may be approved:</u></p> <ul style="list-style-type: none"> • CT Chest with contrast (CPT® 71260) • CT Abdomen and Pelvis with contrast (CPT® 74177) • CT with contrast of previously involved area(s) • PET/CT can be considered in rare circumstances (e.g. bone involvement).
Biopsy-proven recurrence	<ul style="list-style-type: none"> • PET/CT (CPT® 78815 or CPT® 78816)
CAR-T cell therapy	<p><u>Once before treatment and once 30-60 days after completion of treatment:</u></p> <ul style="list-style-type: none"> • PET/CT (CPT® 78815 or CPT® 78816)

Indication	Imaging Study
<p><u>Surveillance for ANY of the following:</u></p> <ul style="list-style-type: none">• All stages of DLBCL• Relapsed lymphoma• Primary mediastinal large B cell lymphoma• Primary cutaneous diffuse large B cell lymphoma	<ul style="list-style-type: none">• <u>Every 6 months for 2 years after completion of treatment:</u><ul style="list-style-type: none">• CT Chest with contrast (CPT® 71260)• CT Abdomen and Pelvis with contrast (CPT® 74177)• CT with contrast of previously involved area(s)

Follicular Lymphoma (ONC-27.3)

ON.NH.0027.3.A
v2.0.2024

- This section applies to follicular lymphomas with WHO grade of 1 (low) or 2 (intermediate) and primary cutaneous follicle center lymphoma. Grade 3 (high) follicular lymphomas should be imaged according to guidelines found in: **Diffuse Large B Cell Lymphoma (DLBCL) (ONC-27.2)**.

Indication	Imaging Study
Initial Staging/Diagnosis	<p><u>ANY or ALL of the following may be approved:</u></p> <ul style="list-style-type: none"> CT Chest with contrast (CPT® 71260) CT Abdomen and Pelvis with contrast (CPT® 74177)
<p><u>For ANY of the following:</u></p> <ul style="list-style-type: none"> If radiation therapy is being considered for stage I or II disease If systemic therapy is planned Pediatric-type follicular lymphoma in adults 	<ul style="list-style-type: none"> PET/CT (CPT® 78815 or CPT® 78816)
Treatment Response	<ul style="list-style-type: none"> CT with contrast of previously involved area(s) every 2 cycles of therapy
End of Therapy Evaluation	<p><u>ONE of the following may be approved:</u></p> <ul style="list-style-type: none"> PET/CT (CPT® 78815 or CPT® 78816) <p>OR</p> <ul style="list-style-type: none"> CT Chest with contrast (CPT® 71260) and CT Abdomen and Pelvis with contrast (CPT® 74177) CT with contrast of previously involved area(s)
Suspected Recurrence	<p><u>ANY or ALL of the following may be approved:</u></p> <ul style="list-style-type: none"> CT Chest with contrast (CPT® 71260) CT Abdomen and Pelvis with contrast (CPT® 74177) CT with contrast of previously involved area(s)

Indication	Imaging Study
<p><u>Suspected transformation (Richter's) from a low grade lymphoma to a more aggressive type based on one or more of the following:</u></p> <ul style="list-style-type: none"> • New B symptoms • Rapidly growing lymph nodes • Extranodal disease develops • Significant recent rise in LDH above normal range 	<ul style="list-style-type: none"> • PET/CT (CPT® 78815 or CPT® 78816)
<p><u>Surveillance for ANY of the following:</u></p> <ul style="list-style-type: none"> • After completion of active treatment • On maintenance treatment • Observation without any treatment 	<p><u>For all stages, every 6 months for two years, then annually:</u></p> <ul style="list-style-type: none"> • CT Chest with contrast (CPT® 71260) • CT Abdomen and Pelvis with contrast (CPT® 74177) • CT with contrast of previously involved area(s)
<p>Surveillance of pediatric-type follicular lymphoma in adults</p>	<p>Advanced imaging is not indicated routinely after complete response</p>

Marginal Zone Lymphomas (ONC-27.4)

ON.NH.0027.4.A
v2.0.2024

- MALT lymphomas in any location and primary cutaneous marginal zone lymphoma should also be imaged according to these guidelines
- Splenic Marginal Zone Lymphoma is diagnosed with splenomegaly, peripheral blood flow cytometry and bone marrow biopsy. Splenectomy is diagnostic and therapeutic. PET scan is not routinely indicated prior to splenectomy.

Indication	Imaging Study
Initial Staging/Diagnosis	<p><u>ANY or ALL of the following may be approved:</u></p> <ul style="list-style-type: none"> • CT Chest with contrast (CPT® 71260) • CT Abdomen and Pelvis with contrast (CPT® 74177)
<p><u>EITHER of the following:</u></p> <ul style="list-style-type: none"> • If radiation therapy is being considered for stage I or II disease • If systemic therapy is planned 	<ul style="list-style-type: none"> • PET/CT (CPT® 78815 or CPT® 78816)
Treatment Response	<ul style="list-style-type: none"> • CT with contrast of previously involved area(s) every 2 cycles of therapy
End of Therapy Evaluation	<p><u>ONE of the following may be approved:</u></p> <ul style="list-style-type: none"> • CT with contrast of previously involved area(s) • PET/CT (CPT® 78815 or CPT® 78816)
Suspected Recurrence	<p><u>ANY or ALL of the following may be approved:</u></p> <ul style="list-style-type: none"> • CT Chest with contrast (CPT® 71260) • CT Abdomen and Pelvis with contrast (CPT® 74177) • CT with contrast of previously involved area(s) • PET/CT can be considered in rare circumstances (e.g. bone involvement).

Indication	Imaging Study
<p><u>Surveillance of all stages of nodal marginal zone lymphoma for any of the following:</u></p> <ul style="list-style-type: none">• After completion of active treatment• On maintenance treatment• Observation without any treatment	<p><u>Every 6 months for two years, then annually:</u></p> <ul style="list-style-type: none">• CT Chest with contrast (CPT® 71260)• CT Abdomen and Pelvis with contrast (CPT® 74177)• CT with contrast of previously involved area(s)
<p>Surveillance of all stages of extranodal marginal zone lymphoma</p>	<p>Advanced imaging is not routinely indicated for surveillance of asymptomatic individuals</p>

Mantle Cell Lymphoma (ONC-27.5)

ON.NH.0027.5.A
v2.0.2024

Indication	Imaging Study
Initial Staging/Diagnosis	<p><u>ONE of the following may be approved:</u></p> <ul style="list-style-type: none"> CT Chest with contrast (CPT® 71260) and CT Abdomen and Pelvis with contrast (CPT® 74177) <p>OR</p> <ul style="list-style-type: none"> PET/CT (CPT® 78815 or CPT® 78816)
Treatment Response	<ul style="list-style-type: none"> CT with contrast of previously involved area(s) every 2 cycles of therapy PET/CT is not indicated for monitoring treatment response but can be considered in rare circumstances when CT did not show disease (e.g. bone).
End of Therapy Evaluation	<p><u>ONE of the following may be approved:</u></p> <ul style="list-style-type: none"> CT with contrast of previously involved area(s) PET/CT (CPT® 78815 or CPT® 78816)
Suspected Recurrence	<p><u>ANY or ALL of the following may be approved:</u></p> <ul style="list-style-type: none"> CT Chest with contrast (CPT® 71260) CT Abdomen and Pelvis with contrast (CPT® 74177) CT with contrast of previously involved area(s) PET/CT can be considered in rare circumstances (e.g. bone involvement).
Surveillance for all stages	<p><u>Every 6 months for 2 years, and then annually:</u></p> <ul style="list-style-type: none"> CT Chest with contrast (CPT® 71260) CT Abdomen and Pelvis with contrast (CPT® 74177) CT with contrast of previously involved area(s)

Burkitt's Lymphomas (ONC-27.6)

ON.NH.0027.6.A
v2.0.2024

Indication	Imaging Study
Initial Staging/Diagnosis	<p><u>ANY or ALL of the following may be approved:</u></p> <ul style="list-style-type: none"> • PET/CT (CPT® 78815 or CPT® 78816) • CT Chest with contrast (CPT® 71260) • CT Abdomen and Pelvis with contrast (CPT® 74177)
Treatment Response	<ul style="list-style-type: none"> • CT with contrast of previously involved area(s) every 2 cycles of therapy • PET/CT is not indicated for monitoring treatment response but can be considered in rare circumstances when CT did not show disease (e.g. bone).
End of Therapy Evaluation	<p><u>ANY or ALL of the following may be approved:</u></p> <ul style="list-style-type: none"> • PET/CT (CPT® 78815 or CPT® 78816) may be approved at the end of chemotherapy and again at the end of radiation • CT with contrast of previously involved area(s)
Suspected Recurrence	<p><u>ANY or ALL of the following may be approved:</u></p> <ul style="list-style-type: none"> • CT Chest with contrast (CPT® 71260) • CT Abdomen and Pelvis with contrast (CPT® 74177) • CT with contrast of previously involved area(s) • PET/CT can be considered in rare circumstances (e.g. bone involvement).
Surveillance	<p><u>Every 6 months for 2 years after completion of treatment:</u></p> <ul style="list-style-type: none"> • CT Chest with contrast (CPT® 71260) • CT Abdomen and Pelvis with contrast (CPT® 74177)

Lymphoblastic Lymphomas (ONC-27.7)

ON.NH.0027.7.A

v2.0.2024

- Individuals with lymphoblastic lymphoma (even those with bulky nodal disease) are treated using the leukemia treatment plan appropriate to the cell type (B or T cell). Imaging indications in adult individuals are identical to those for pediatric individuals. See: **Acute Lymphoblastic Leukemia (ALL) (PEDONC-3.2)** in the Pediatric Oncology Imaging Guidelines.

T Cell Lymphomas (ONC-27.8)

ON.NH.0027.8.A
v2.0.2024

- Includes Peripheral T-Cell Lymphomas, Mycosis Fungoides/Sézary Syndrome, Anaplastic Large Cell Lymphoma (ALCL) including breast implant-associated ALCL, Angioimmunoblastic lymphoma, and Primary Cutaneous CD30+T Cell Lymphoproliferative Disorders

Indication	Imaging Study
Initial Staging/Diagnosis	<p><u>ANY or ALL of the following may be approved:</u></p> <ul style="list-style-type: none"> PET/CT (CPT® 78815 or CPT® 78816) CT Chest with contrast (CPT® 71260) CT Abdomen and Pelvis with contrast (CPT® 74177)
Breast implant-associated ALCL	<p>In addition to the above initial staging studies:</p> <ul style="list-style-type: none"> Ultrasound Breast (CPT® 76641 or CPT® 76642) <ul style="list-style-type: none"> MRI Breast (CPT® 77049) may be indicated for evaluation of inconclusive ultrasound findings
Treatment Response	<p><u>Any ONE of the following may be approved after 3-4 cycles:</u></p> <ul style="list-style-type: none"> PET/CT (CPT® 78815 or 78816) <p>or</p> <ul style="list-style-type: none"> CT Chest with contrast (CPT® 71260), and CT Abdomen and Pelvis with contrast (CPT® 74177) and CT with contrast of previously involved area(s)
End of Therapy Evaluation	<p><u>Any ONE of the following may be approved at the end of chemotherapy and again at the end of radiation therapy:</u></p> <ul style="list-style-type: none"> PET/CT (CPT® 78815 or CPT® 78816) <p>or</p> <ul style="list-style-type: none"> CT Chest with contrast (CPT® 71260), and CT Abdomen and Pelvis with contrast (CPT® 74177), and CT with contrast of previously involved area(s)
Suspected Recurrence	<p><u>ANY or ALL of the following may be approved:</u></p> <ul style="list-style-type: none"> CT Chest with contrast (CPT® 71260) CT Abdomen and Pelvis with contrast (CPT® 74177) CT with contrast of previously involved area(s) PET/CT can be considered in rare circumstances (e.g., bone involvement).

Indication	Imaging Study
Surveillance, all stages	<u>Every 6 months for 2 years, then annually for 5 years:</u> <ul style="list-style-type: none">• CT Chest with contrast (CPT® 71260), CT Abdomen and Pelvis with contrast (CPT® 74177), and CT of previously involved areas

Post-Transplant Lymphoproliferative Disorders (ONC-27.9)

ON.NH.0027.9.A

v2.0.2024

- Post-transplant lymphoproliferative disorder (PTLD) or viral-associated lymphoproliferative disorder can rarely occur following solid organ or hematopoietic stem cell transplantation, or in primary immunodeficiency. When reduction of immunosuppression is unsuccessful, these are often treated with chemoimmunotherapy similar to high-grade NHL.
- This section applies to Monomorphic (B-cell type) PTLD and Polymorphic PTLD.
- For Hodgkin-lymphoma subtype of PTLD, see: **Hodgkin Lymphomas (ONC-28)** for imaging recommendations.

Indication	Imaging Study
Initial Staging/Diagnosis	<p><u>ANY or ALL of the following may be approved:</u></p> <ul style="list-style-type: none"> • PET/CT (CPT® 78815 or CPT® 78816) • CT Chest with contrast (CPT® 71260) • CT Abdomen and Pelvis with contrast (CPT® 74177)
Treatment Response	<p><u>ANY or ALL of the following may be approved after 4 weeks of reducing immunosuppression or every 2 cycles (6-8 weeks) of chemo/immunotherapy:</u></p> <ul style="list-style-type: none"> • CT Chest with contrast (CPT® 71260), and • CT Abdomen and Pelvis with contrast (CPT® 74177), and • CT with contrast of previously involved area(s)
End of Therapy Evaluation	<p><u>ANY one of the following may be approved at the end of treatment:</u></p> <ul style="list-style-type: none"> • PET/CT (CPT® 78815 or CPT® 78816) <p>or</p> <ul style="list-style-type: none"> • CT Chest with contrast (CPT® 71260), and • CT Abdomen and Pelvis with contrast (CPT® 74177), and • CT with contrast of previously involved area(s)
Suspected recurrence	<ul style="list-style-type: none"> • CT Chest with contrast (CPT® 71260) • CT Abdomen and Pelvis with contrast (CPT® 74177)
Surveillance	Advanced imaging is not routinely indicated for surveillance

Waldenström Macroglobulinemia or Lymphoplasmacytic Lymphoma (ONC-27.10)

ON.NH.0027.10.A
v2.0.2024

Indication	Imaging Study
Initial Staging/Diagnosis	<u>ANY or ALL of the following may be approved:</u> <ul style="list-style-type: none">• CT Chest with contrast (CPT® 71260)• CT Abdomen and Pelvis with contrast (CPT® 74177)
Treatment Response	<ul style="list-style-type: none">• CT with contrast of previously involved area(s) every 2 cycles of therapy
End of Therapy Evaluation	<ul style="list-style-type: none">• CT with contrast of previously involved area(s)
Suspected Recurrence	<u>ANY or ALL of the following may be approved:</u> <ul style="list-style-type: none">• CT Chest with contrast (CPT® 71260)• CT Abdomen and Pelvis with contrast (CPT® 74177)• CT with contrast of previously involved area(s)
Surveillance	Advanced imaging is not routinely indicated for surveillance

References (ONC-27)

v2.0.2024

1. Zelenetz AD, Gordon LI, Abramson JS, et al. National Comprehensive Cancer Network (NCCN) Guidelines Version 1.2024 – January 18, 2024. B-cell lymphomas, available at: https://www.nccn.org/professionals/physician_gls/pdf/B-CELL.pdf Referenced with permission from the NCCN Clinical Practice Guidelines in Oncology (NCCN Guidelines™) for B-cell lymphomas V1.2024 – January 18, 2024. ©2024 National Comprehensive Cancer Network, Inc. All rights reserved. The NCCN Guidelines™ and illustrations herein may not be reproduced in any form for any purpose without the express written permission of the NCCN. To view the most recent and complete version of the NCCN Guidelines™, go online to NCCN.org.
2. Horwitz SM, Ansell S, Ai WZ, et al. National Comprehensive Cancer Network (NCCN) Guidelines Version 1.2024 – December 21, 2023. T-cell lymphomas, available at: https://www.nccn.org/professionals/physician_gls/pdf/T-CELL.pdf Referenced with permission from the NCCN Clinical Practice Guidelines in Oncology (NCCN Guidelines™) for T-cell lymphomas V1.2024 – December 21, 2023. ©2023 National Comprehensive Cancer Network, Inc. All rights reserved. The NCCN Guidelines™ and illustrations herein may not be reproduced in any form for any purpose without the express written permission of the NCCN. To view the most recent and complete version of the NCCN Guidelines™, go online to NCCN.org.
3. Cheson BD, Fisher RI, Barrington SF, et al. Recommendations for initial evaluation, staging, and response assessment for Hodgkin and Non-Hodgkin lymphoma: the Lugano classification. *J Clin Oncol*. 2014;32(27):3059-3067. doi:10.1200/JCO.2013.54.8800.
4. Barrington SF, Mikhaeel NG, Kostakoglu L, et al. Role of imaging in the staging and response assessment of lymphoma: consensus of the International Conference on Malignant Lymphomas Imaging Working Group. *J Clin Oncol*. 2014;32(27):3048-3058. doi:10.1200/JCO.2013.53.5229.
5. Thompson CA, Ghesquieres H, Maurer MJ, et al. Utility of routine post-therapy surveillance imaging in diffuse Large B-Cell Lymphoma. *J Clin Oncol*. 2014;32(31):3506-3512. doi:10.1200/JCO.2014.55.7561.
6. El-Galaly TC, Jakobsen LH, Hutchings M, et al. Routine imaging for diffuse Large B-Cell Lymphoma in first complete remission does not improve post-treatment survival: a Danish-Swedish population-based study. *J Clin Oncol*. 2015;33(34):3993-3998. doi:10.1200/JCO.2015.62.0229.
7. Huntington SF, Svoboda J, Doshi JA. Cost-effectiveness analysis of routine surveillance imaging of patients with diffuse Large B-Cell Lymphoma in first remission. *J Clin Oncol*. 2015;33(13):1467-1474. doi:10.1200/JCO.2014.58.5729.
8. Mamot C, Klingbiel D, Hitz F, et al. Final results of a prospective evaluation of the predictive value of interim positron emission tomography in patients with diffuse large B-cell lymphoma treated with R-CHOP-14 (SAKK 38/07). *J Clin Oncol*. 2015;33(23):2523-2529. doi:10.1200/JCO.2014.58.9846.
9. Mylam KJ, Nielsen AL, Pedersen LM, Hutchings M. Fluorine-18-fluorodeoxyglucose positron emission tomography in diffuse large B-cell lymphoma. *PET Clin*. 2014;9(4):443-455. doi:10.1016/j.cpet.2014.06.001.
10. Avivi I, Zilberlicht A, Dann EJ, et al. Strikingly high false positivity of surveillance FDG-PET/CT scanning among patients with diffuse large cell lymphoma in the rituximab era. *Am J Hematol*. 2013;88(5):400-405. doi:10.1002/ajh.23423.
11. Ulrich Dührsen, Stefan Müller, Bernd Hertenstein, et al. Positron emission tomography-guided therapy of aggressive non-Hodgkin lymphomas (PETAL): a multicenter, randomized phase III trial. *J Clin Oncol*. 2018;36(20):2024-2034. doi:10.1200/JCO.2017.76.8093.

Hodgkin Lymphoma (ONC-28)

Guideline

Hodgkin Lymphoma – General Considerations (ONC-28.1)

Classical Hodgkin Lymphoma (ONC-28.2)

Nodular Lymphocyte – Predominant Hodgkin Lymphoma (ONC-28.3)

References (ONC-28)

Hodgkin Lymphoma – General Considerations (ONC-28.1)

ON.HL.0028.1.A

v2.0.2024

- Lymphoma is often suspected when individuals have any of the following:
 - Bulky lymphadenopathy (lymph node mass >10 cm in size), hepatomegaly or splenomegaly
 - The presence of systemic symptoms (fever, drenching night sweats or unintended weight loss of >10%, called “B symptoms”)
- Individuals with AIDS-related lymphoma should be imaged according to the primary lymphoma histology
- The **Deauville Criteria** are internationally accepted criteria, which utilize a five-point scoring system for the FDG avidity of a Hodgkin's lymphoma or Non-Hodgkin's lymphoma tumor mass as seen on FDG PET.
 - Score 1: No uptake above the background
 - Score 2: Uptake ≤mediastinum
 - Score 3: Uptake >mediastinum but ≤liver
 - Score 4: Uptake moderately increased compared to the liver at any site
 - Score 5: Uptake markedly increased compared to the liver at any site
 - Score X: New areas of uptake unlikely to be related to lymphoma

Indication	Imaging Study
<p><u>Biopsy proven lymphoma or suspected lymphoma with one of the following:</u></p> <ul style="list-style-type: none"> • Bulky lymphadenopathy (LN mass >10 cm) • Hepatomegaly • Splenomegaly • B symptom: Unexplained fever, drenching night sweats, unintended weight loss >10% total body weight 	<ul style="list-style-type: none"> • CT Chest (CPT® 71260) and CT Abdomen and Pelvis (CPT® 74177) with contrast • MRI without and with contrast for individuals who cannot tolerate CT contrast due to allergy or impaired renal function
<p>Signs or symptoms of disease involving the neck</p>	<ul style="list-style-type: none"> • CT Neck with contrast (CPT® 70491)
<p>Signs or symptoms suggesting CNS involvement with lymphoma</p>	<ul style="list-style-type: none"> • MRI Brain without and with contrast (CPT® 70553) • See: <u>CNS Lymphoma (also known as Microglioma) (ONC-2.7)</u>

Indication	Imaging Study
Known or suspected bone involvement with lymphoma	<ul style="list-style-type: none">• MRI without and with contrast of symptomatic or previously involved bony areas• Bone scan is inferior to MRI for evaluation of known or suspected bone involvement with lymphoma
Determine a more favorable site for biopsy when a relatively inaccessible site is contemplated	<ul style="list-style-type: none">• PET/CT (CPT® 78815 or CPT® 78816)• PET/CT is medically unnecessary for all other indications prior to histological confirmation of lymphoma
CAR-T cell therapy	<p><u>Once before treatment and once 30-60 days after completion of treatment:</u></p> <ul style="list-style-type: none">• PET/CT (CPT® 78815 or CPT® 78816)

Classical Hodgkin Lymphoma (ONC-28.2)

ON.HL.0028.2.A

v2.0.2024

- This section applies to nodular sclerosis, mixed cellularity, lymphocyte-depleted and lymphocyte-rich subtypes of Hodgkin lymphoma.

Indication	Imaging Study
Initial Staging/Diagnosis	<p><u>ANY or ALL of the following may be approved:</u></p> <ul style="list-style-type: none"> • PET/CT (CPT® 78815 or CPT® 78816) • CT Neck with contrast (CPT® 70491) • CT Chest with contrast (CPT® 71260) • CT Abdomen and Pelvis with contrast (CPT® 74177)
Treatment Response	<ul style="list-style-type: none"> • PET/CT (CPT® 78815 or CPT® 78816) as frequently as every 2 cycles
End of Chemotherapy and/or Radiation Therapy Evaluation	<ul style="list-style-type: none"> • PET/CT (CPT® 78815 or CPT® 78816) may be approved at the end of chemotherapy and again at the end of radiation (at least 12 weeks after completion of radiation therapy)
Suspected Recurrence	<p><u>ANY or ALL of the following may be approved:</u></p> <ul style="list-style-type: none"> • CT Neck with contrast (CPT® 70491) • CT Chest with contrast (CPT® 71260) • CT Abdomen and Pelvis with contrast (CPT® 74177) • CT with contrast of previously involved area(s)
Biopsy proven recurrence	<ul style="list-style-type: none"> • PET/CT (CPT® 78815 or CPT® 78816)
Surveillance	<p><u>ANY or ALL of the following may be approved every 6 months for 2 years after completion of therapy:</u></p> <ul style="list-style-type: none"> • CT Neck with contrast (CPT® 70491) • CT Chest with contrast (CPT® 71260) • CT Abdomen and Pelvis with contrast (CPT® 74177) • CT with contrast of previously involved area(s) <p><u>In addition to the above studies:</u></p> <ul style="list-style-type: none"> • A single follow-up PET/CT may be approved at three months if end of therapy PET/CT shows Deauville 4 or 5 FDG avidity

Nodular Lymphocyte – Predominant Hodgkin Lymphoma (ONC-28.3)

ON.HL.0028.3.A

v2.0.2024

Indication	Imaging Study
Initial Staging/Diagnosis	<p><u>ANY or ALL of the following may be approved:</u></p> <ul style="list-style-type: none"> • PET/CT (CPT® 78815 or CPT® 78816) • CT Neck with contrast (CPT® 70491) • CT Chest with contrast (CPT® 71260) • CT Abdomen and Pelvis with contrast (CPT® 74177)
Treatment Response	<ul style="list-style-type: none"> • CT with contrast of previously involved areas as frequently as every 2 cycles
End of Chemotherapy and/or Radiation Therapy Evaluation	<ul style="list-style-type: none"> • PET/CT (CPT® 78815 or CPT® 78816) may be approved at the end of chemotherapy and again at the end of radiation (at least 12 weeks after completion of radiation therapy)
Suspected Recurrence	<p><u>ANY or ALL of the following may be approved:</u></p> <ul style="list-style-type: none"> • CT Neck with contrast (CPT® 70491) • CT Chest with contrast (CPT® 71260) • CT Abdomen and Pelvis with contrast (CPT® 74177) • CT with contrast of previously involved area(s)
Biopsy proven recurrence	<ul style="list-style-type: none"> • PET/CT (CPT® 78815 or CPT® 78816)
<p><u>Suspected transformation (Richter's) from a low-grade lymphoma to a more aggressive type based on one or more of the following:</u></p> <ul style="list-style-type: none"> • New B symptoms • Rapidly growing lymph nodes • Extranodal disease develops • Significant recent rise in LDH above normal range 	<ul style="list-style-type: none"> • PET/CT (CPT® 78815 or CPT® 78816)

Indication	Imaging Study
Surveillance	<p><u>ANY or ALL of the following may be approved every 6 months for 2 years after completion of therapy:</u></p> <ul style="list-style-type: none">• CT Neck with contrast (CPT® 70491)• CT Chest with contrast (CPT® 71260)• CT Abdomen and Pelvis with contrast (CPT® 74177)• CT with contrast of previously involved area(s) <p><u>In addition to the above studies:</u></p> <ul style="list-style-type: none">• A single follow-up PET/CT may be approved at three months if end of therapy PET/CT shows Deauville 4 or 5 FDG avidity

References (ONC-28)

v2.0.2024

1. Hoppe RT, Advani RH, Ambinder RF, et al. National Comprehensive Cancer Network (NCCN) Guidelines Version 2.2023 – November 8, 2022. Hodgkin lymphoma, available at: https://www.nccn.org/professionals/physician_gls/pdf/hodgkins.pdf Referenced with permission from the NCCN Clinical Practice Guidelines in Oncology (NCCN Guidelines™) for Hodgkins Lymphoma V2.2023 – November 8, 2022. ©2022 National Comprehensive Cancer Network, Inc. All rights reserved. The NCCN Guidelines™ and illustrations herein may not be reproduced in any form for any purpose without the express written permission of the NCCN. To view the most recent and complete version of the NCCN Guidelines™, go online to NCCN.org.
2. Cheson BD, Fisher RI, Barrington SF, et al. Recommendations for initial evaluation, staging, and response assessment for Hodgkin and Non-Hodgkin lymphoma: the Lugano classification. *J Clin Oncol.* 2014;32(27):3059-3067. doi:10.1200/JCO.2013.54.8800.
3. Barrington SF, Mikhaeel NG, Kostakoglu L, et al. Role of imaging in the staging and response assessment of lymphoma: consensus of the International Conference on Malignant Lymphomas Imaging Working Group. *J Clin Oncol.* 2014;32(27):3048-3058. doi:10.1200/JCO.2013.53.5229.
4. Pingali SR, Jewell SW, Havlat L, et al. Limited utility of routine surveillance imaging for classical Hodgkin lymphoma patients in first complete remission. *Cancer.* 2014;120:2122-2129.
5. Ha CS, Hodgson DC, Advani R, et al. Follow-up of Hodgkin lymphoma. *ACR Appropriateness Criteria®* 2014;1-16.
6. Picardi M, Pugliese N, Cirillo, M et al. Advanced-stage Hodgkin lymphoma: US/Chest radiography for detection of relapse in patients in first complete remission—a randomized trial of routine surveillance imaging procedures. *Radiology.* 2014;272:262-274.
7. Gallamini A, and Kostakoglu L. Interim FDG-PET in Hodgkin lymphoma: a compass of a safe navigation in clinical trials? *Blood.* 2012;120(25):4913-4920.
8. Biggi A, Gallamini A, Chauvie S, et al. International validation study for interim PET in ABVD-treated, advanced-stage Hodgkin lymphoma: interpretation criteria and concordance rate among reviewers. *J Nucl Med.* 2013; 54(5):683-690.
9. Gallamini A, Barrington SF, Biggi, et al. The predictive role of interim positron emission tomography for Hodgkin lymphoma treatment outcome is confirmed using the interpretation criteria of the Deauville five-point scale. *Haematologica.* 2014; 99(6):1107-1113.
10. El-Galaly TC, Mylam KJ, Brown P, et al. Positron emission tomography/computed tomography surveillance in patients with Hodgkin lymphoma in first remission has a low positive predictive value and high costs. *Haematologica.* 2012;97(6):931-936.

Hematopoietic Stem Cell Transplantation (ONC-29)

Guideline

General Considerations for Stem Cell Transplant (ONC-29.1)

Reference (ONC-29)

General Considerations for Stem Cell Transplant (ONC-29.1)

ON.HT.0029.1.A

v2.0.2024

Transplant types:

Allogeneic (“allo”): The donor and recipient are different people, and there are multiple types depending on the source of the stem cells and degree of match between donor and recipient. This is most commonly used in diseases originating in the hematopoietic system, such as leukemias and lymphomas, and bone marrow failure syndromes or metabolic disorders. Common types are:

- Matched sibling donor (MSD or MRD): Donor and recipient are full siblings and HLA-matched
- Matched unrelated donor (MUD): Donor and recipient are HLA matched but not related to each other
- Cord blood: Donor stem cells come from frozen umbilical cord blood not related to the recipient, sometimes from multiple different donors at once
- Haploidentical transplant (haplo): Donor is a half-HLA match to the recipient, usually a parent

Autologous (“auto”): The donor and recipient are the same person. The process involves delivery of high dose chemotherapy that is ablative to the bone marrow, followed by an infusion of one’s own harvested stem cells.

Allogeneic HSCT results in a much greater degree of immunosuppression than autologous HSCT because of the need to allow the new immune system to chimerize with the recipient’s body. Immune reconstitution commonly takes more than a year for individuals who receive allogeneic HSCT, and individuals remain at high- risk for invasive infections until that has occurred.

Pre-Transplant Imaging in HSCT:

- Pre-transplant imaging in HSCT generally takes place within 30 days prior to transplant and involves a reassessment of the individual’s disease status as well as infectious disease clearance.

Indication	Imaging
Immediate pre-transplant period	<ul style="list-style-type: none"> • Chest x-ray • CT Chest with contrast (CPT® 71260) or CT Chest without contrast (CPT® 71250) for new findings on chest x-ray, or new/worsening signs/symptoms • CT Sinus (CPT® 70486) for any clinical signs or symptoms

Indication	Imaging
Assess cardiac function	<ul style="list-style-type: none"> Echocardiogram (CPT® 93306, CPT® 93307 or CPT® 93308) MUGA scan (CPT® 78472) may be indicated in specific circumstances, see: <u>Oncologic Indications for Cancer Therapeutics-Related Cardiac Dysfunction (CTRCD) (CD-12.1)</u> in the Cardiac Imaging Guidelines
Assess pulmonary function	<ul style="list-style-type: none"> Pulmonary function tests
Assess primary disease status	<ul style="list-style-type: none"> See disease-specific guidelines for end of therapy response assessment

Post-Transplant Imaging in HSCT:

- There are many common complications from HSCT, including infection, acute and chronic graft versus host disease (GVHD), hepatic sinusoidal obstruction syndrome, restrictive lung disease, among others.
- Disease response generally takes place at ~Day +30 (autos and some allos) or ~Day +100 (allos) post-transplant.

Indication	Imaging
Assess known or suspected HSCT complications	<ul style="list-style-type: none"> Site-specific imaging should generally be approved
Suspected hepatic GVHD (elevated liver enzymes)	<ul style="list-style-type: none"> Abdominal US (CPT® 76700 or CPT® 76705)
Suspected Bronchiolitis Obliterans Syndrome (BOS)	<ul style="list-style-type: none"> CT Chest without contrast (CPT® 71250)
Assess primary disease status post-transplant	<ul style="list-style-type: none"> See disease-specific guidelines for end of therapy evaluation and surveillance
Individuals receiving tandem auto transplants (2-4 autos back-to-back, spaced 6 to 8 weeks apart)	<ul style="list-style-type: none"> Guideline recommended imaging can be repeated after each transplant

Reference (ONC-29)

v2.0.2024

1. Loren AW, Mielcarek M, Bolaños-Meade J, et. al. National Comprehensive Cancer Network (NCCN) Guidelines Version 1.2023 – March 31, 2023. Hematopoietic Cell Transplantation, available at: https://www.nccn.org/professionals/physician_gls/pdf/hct.pdf. Referenced with permission from the NCCN Clinical Practice Guidelines in Oncology (NCCN Guidelines®) for Hematopoietic Cell Transplantation V1.2023 – March 31, 2023. ©2023 National Comprehensive Cancer Network, Inc. All rights reserved. The NCCN Guidelines® and illustrations herein may not be reproduced in any form for any purpose without the express written permission of the NCCN. To view the most recent and complete version of the NCCN Guidelines®, go online to NCCN.org.

Medical Conditions with Cancer in the Differential Diagnosis (ONC-30)

Guideline

Fever of Unknown Origin (FUO) (ONC-30.1)

Unexplained Weight Loss (ONC-30.2)

Paraneoplastic Syndromes (ONC-30.3)

References (ONC-30)

Fever of Unknown Origin (FUO) (ONC-30.1)

ON.MC.0030.1.A

v2.0.2024

- FUO is defined as a persistent fever $\geq 101^{\circ}\text{F}$ and ≥ 3 weeks with unidentified cause.
- While fever is a classic “B” symptom of advanced lymphoma, a cancer-related fever presenting in isolation without any other signs or symptoms of neoplastic disease is rare.

Indication	Imaging Study
If physical examination, Chest X-ray, and laboratory studies are non-diagnostic	<ul style="list-style-type: none"> • Echocardiogram (CPT[®] 93306) • Abdominal ultrasound (CPT[®] 76700) • MRI Brain without and with contrast (CPT[®] 70553)
Above studies (including PE/ENT exam, pelvic exam, and DRE with laboratory studies) have failed to demonstrate site of infection	<ul style="list-style-type: none"> • CT Chest (CPT[®] 71260) and CT Abdomen and Pelvis (CPT[®] 74177) with contrast • Radiopharmaceutical localization of tumor or distribution of radiopharmaceutical agent(s): CPT[®] 78800, CPT[®] 78801, or CPT[®] 78802, CPT[®] 78804, CPT[®] 78803 or CPT[®] 78831 (SPECT), or CPT[®] 78830, or CPT[®] 78832 (SPECT/CT)
“B” symptoms	<ul style="list-style-type: none"> • See: <u>Non-Hodgkin Lymphomas (ONC-27)</u>
Any CNS sign/symptom accompanied by fever	<ul style="list-style-type: none"> • MRI Brain without and with contrast (CPT[®] 70553)
All individuals	<ul style="list-style-type: none"> • PET is not indicated in the work-up of individuals with FUO

Unexplained Weight Loss (ONC-30.2)

ON.MC.0030.2.A
v2.0.2024

- Unintentional weight loss is defined as loss of ≥ 10 lbs. or $\geq 5\%$ of body weight over 6 months or less, without an identifiable reason.
- Initial workup for all individuals may include appropriate detailed history, physical exam, baseline laboratory studies (e.g., CBC, CMP, HgbA1c, ESR/CRP, infectious workup, stool hemoccult, endocrine evaluation to rule out thyroid, pituitary, or gonadal dysfunction, etc.), chest x-ray, age-appropriate cancer screening, and neurological evaluation to rule out depression/dementia.
- Additional workup is directed to evaluate specific signs, symptoms, red flags, or abnormalities detected on initial workup. See condition-specific imaging guidelines for additional details.
- PET is not appropriate in the work-up of individuals with unexplained weight loss.

Indication	Imaging Study
CNS symptoms or abnormal pituitary hormones	<ul style="list-style-type: none"> • MRI Brain or Sella Turcica without and with contrast (CPT[®] 70553)
Abnormal thyroid function	<ul style="list-style-type: none"> • Thyroid ultrasound (CPT[®] 76536)
Abnormal liver function	<ul style="list-style-type: none"> • Abdominal ultrasound (CPT[®] 76700)
Abnormal kidney function	<ul style="list-style-type: none"> • Ultrasound kidney and bladder (CPT[®] 76770 or CPT[®] 76775)
Suspected cardiac dysfunction	<ul style="list-style-type: none"> • Echocardiogram (CPT[®] 93306)
Non-smokers	<ul style="list-style-type: none"> • Chest x-ray <ul style="list-style-type: none"> • CT Chest with contrast (CPT[®] 71260) to evaluate abnormalities on chest x-ray
Current or former smokers	<ul style="list-style-type: none"> • CT Chest with contrast (CPT[®] 71260)
Dysphagia or early satiety	<ul style="list-style-type: none"> • See: <u>Dysphagia and Esophageal Disorders (NECK-3)</u>
GI bleeding	<ul style="list-style-type: none"> • See: <u>GI Bleeding (AB-22)</u>
Abdominal pain without red flag signs	See: <u>Abdominal Pain (AB-2)</u>

Indication	Imaging Study
<p><u>Suspected pancreatic cancer in individuals aged ≥60 years with weight loss and at least one of the following</u> ¹³:</p> <ul style="list-style-type: none"> • Diarrhea • Back pain • Abdominal pain • Nausea/vomiting • Constipation • New onset diabetes • Abnormal labs (CA 19-9, LFTs) • Non-diagnostic or negative abdominal ultrasound 	<p><u>Any ONE of the following may be obtained:</u></p> <ul style="list-style-type: none"> • CT Abdomen with contrast (CPT® 74160) • CT Abdomen and Pelvis with contrast (CPT® 74177) • MRI Abdomen without and with contrast (CPT® 74183) <p>See also: <u>Epigastric Pain and Dyspepsia (AB-2.5)</u></p>
<p>If all of the above do not identify cause of weight loss</p>	<p><u>Any of the following, if not previously performed:</u></p> <ul style="list-style-type: none"> • CT Chest (CPT® 71260) • CT Abdomen and Pelvis (CPT® 74177) with contrast

Paraneoplastic Syndromes (ONC-30.3)

ON.MC.0030.3.A

v2.0.2024

- Paraneoplastic syndromes are metabolic and neuromuscular disturbances. These syndromes are not directly related to a tumor or to metastatic disease. There may be a lead time between initial finding of a possible paraneoplastic syndrome and appearance of the cancer with imaging. Limited studies suggest annual imaging for 2 years after diagnosis of possible paraneoplastic syndrome may detect cancer, however benefit after 2 years is not well documented.
- The following are the most common symptoms of paraneoplastic syndromes known to arise from various malignancies:
 - Hypertrophic Pulmonary Osteoarthropathy: Often presents as a constellation of rheumatoid-like polyarthritis, periostitis of long bones, and clubbing of fingers and toes
 - Amyloidosis
 - Hypercalcemia
 - Hypophosphatemia
 - Cushing's Syndrome
 - Somatostatinoma syndrome (vomiting, abdominal pain, diarrhea, cholelithiasis)
 - Syndrome of inappropriate antidiuretic hormone secretion (SIADH)
 - Polymyositis/dermatomyositis
 - Opsoclonus
 - Paraneoplastic sensory neuropathy
 - Subacute cerebellar degeneration
 - Eaton-Lambert syndrome (a myasthenia-like syndrome)
 - Second event of unprovoked thrombosis
 - Disseminated Intravascular Coagulation
 - Migratory thrombophlebitis
 - Polycythemia
 - Chronic leukocytosis and/or thrombocytosis
 - Elevated tumor markers
 - Cryptogenic stroke (see also: **HD-21.3**)
- See: **Muscle Disorders (PN-6)** in the Peripheral Nerve Disorders Imaging Guidelines.
- See: **Multiple Myeloma and Plasmacytomas (ONC-25)** for evaluation of possible multiple myeloma.

Indication	Imaging Study
Initial evaluation	<ul style="list-style-type: none"> CT Chest (CPT® 71260) and CT Abdomen and Pelvis (CPT® 74177) with contrast
<p><u>ANY of the following:</u></p> <ul style="list-style-type: none"> Abnormality on conventional imaging difficult to biopsy Inconclusive conventional imaging Documented paraneoplastic antibody and conventional imaging fails to demonstrate primary site 	<ul style="list-style-type: none"> PET/CT (CPT® 78815 or CPT® 78816)
Subsequent evaluation for known paraneoplastic syndrome	<ul style="list-style-type: none"> CT Chest (CPT® 71260) and CT Abdomen and Pelvis (CPT® 74177) with contrast may be repeated every 6 months for 2 years after initial imaging for Lambert-Eaton Myasthenia syndrome CT Chest (CPT® 71260) and CT Abdomen and Pelvis (CPT® 74177) with contrast may be repeated every 6 months for 4 years for all other paraneoplastic syndromes
Systemic mastocytosis	<p><u>ANY ONE of the following:</u></p> <ul style="list-style-type: none"> CT Abdomen and Pelvis (CPT® 74177) with contrast MRI Abdomen (CPT® 74183) and MRI Pelvis (CPT® 72197) without and with contrast is indicated PET/CT scan is not indicated for evaluation of mastocytosis
First episode of unprovoked DVT/VTE	<ul style="list-style-type: none"> Imaging to evaluate for malignancy is not indicated
Second unprovoked DVT/PE	<ul style="list-style-type: none"> Imaging may be considered in the setting of a negative work-up for inherited thrombophilia and antiphospholipid syndrome
<p>Thyroid US is recommended for elevated CEA, and upper/lower endoscopy is recommended for elevated CEA or CA 19-9.</p>	

References (ONC-30)

v2.0.2024

1. Carrier M, Lazo-Langner A, Shivakumar S, et al. Screening for occult cancer in unprovoked venous thromboembolism. *N Engl J Med*. 2015 June;373:697-704. doi:10.1056/NEJMoa1506623.
2. Sioka C, Fotopoulos A, Kyritsis AP. Paraneoplastic neurological syndromes and the role of PET imaging. *Oncology*. 2010;78(2):150–156. doi:10.1159/000312657.
3. Schramm N, Rominger A, Schmidt C, et al. Detection of underlying malignancy in patients with paraneoplastic neurological syndromes: comparison of 18F-FDG PET/CT and contrast-enhanced CT. *Eur J Nucl Med Mol Imaging*. 2013;40(7):1014-1024. doi:10.1007/s00259-013-2372-4.
4. Qiu L, Chen Y. The role of 18F-FDG PET or PET/CT in the detection of fever of unknown origin. *Eur J Radiol*. 2012;81(11):3524-3529. doi:10.1016/j.ejrad.2012.05.025.
5. Pelosof LC, Gerber DE. Paraneoplastic syndromes: an approach to diagnosis and treatment. *Mayo Clin Proc*. 2010;85(9):838-854. doi:10.4065/mcp.2010.0099.
6. Wong CJ. Involuntary weight loss. *Med Clin North Am*. 2014;98(3):625-43. doi:10.1016/j.mcna.2014.01.012.
7. Titulaer MJ, Soffieti R, Dalmau J, et al. Screening of tumours in paraneoplastic syndromes: report of an EFNS task force. *Eur J Neurol*. 2011;18(1):19–e3. doi:10.1111/j.1468-1331.2010.03220.x.
8. Lancaster E. Paraneoplastic disorders. *Continuum (Minneapolis)*. 2017;23(6, Neuro-oncology):1653-1679. doi:10.1212/CON.0000000000000542.
9. Gerds AT, Gotlib J, Ali H, et al. National Comprehensive Cancer Network (NCCN) Guidelines Version 1.2022 – April 14, 2022. Systemic Mastocytosis, available at: https://www.nccn.org/professionals/physician_gls/pdf/mastocytosis.pdf. Referenced with permission from the NCCN Clinical Practice Guidelines in Oncology (NCCN Guidelines™) for Systemic Mastocytosis V1.2022 – April 14, 2022. ©2022 National Comprehensive Cancer Network, Inc. All rights reserved. The NCCN Guidelines™ and illustrations herein may not be reproduced in any form for any purpose without the express written permission of the NCCN. To view the most recent and complete version of the NCCN Guidelines™, go online to NCCN.org.
10. Saver JL. Cryptogenic stroke. *N Engl J Med*. 2016;374:2065-2074. doi:10.1056/NEJMcp1503946.
11. Schwarzbach CJ, Schaefer A, Ebert A, et al. Stroke and cancer: the importance of cancer-associated hypercoagulation as a possible stroke etiology. *Stroke*. 2012;43(11):3029-3034. doi:10.1161/STROKEAHA.112.658625.
12. Kamel H, Merkler AE, Iadecola C, Gupta A, Navi B. Tailoring the approach to embolic stroke of undetermined source: a review. *JAMA Neurol*. 2019;76(7):855-861. doi:10.1001/jamaneurol.2019.0591.
13. National Institute for Health and Care Excellence (NICE). Upper gastrointestinal tract cancers. In: Suspected cancer: recognition and referral. 2015. <https://www.nice.org.uk/guidance/ng12/chapter/Recommendations-organised-by-site-of-cancer#upper-gastrointestinal-tract-cancers>

Metastatic Cancer, Carcinoma of Unknown Primary Site, and Other Types of Cancer (ONC-31)

Guideline

General Guidelines (ONC-31.0)

Lung Metastases (ONC-31.1)

Liver Metastases (ONC-31.2)

Brain Metastases (ONC-31.3)

Adrenal Gland Metastases (ONC-31.4)

Bone (Non-Vertebral) Metastases (ONC-31.5)

Spinal/Vertebral Metastases (ONC-31.6)

Carcinoma of Unknown Primary Site (ONC-31.7)

Extrathoracic Small Cell and Large Cell Neuroendocrine Tumors
(ONC-31.8)

Primary Peritoneal Mesothelioma (ONC-31.9)

Kaposi's Sarcoma (ONC-31.10)

Castleman's Disease (Unicentric and Multicentric) (ONC-31.11)

References (ONC-31)

General Guidelines (ONC-31.0)

ON.UP.0031.0.A

v2.0.2024

- Guideline sections **Lung Metastases (ONC-31.1)** through Bone (Non-Vertebral) Metastases (ONC-31.5) should only be used for individuals with metastatic cancer in the following circumstances:
 - The primary diagnosis section does not address a particular metastatic site that is addressed in these sections
 - The cancer type is rare and does not have its own diagnosis-specific imaging guidelines

Lung Metastases (ONC-31.1)

ON.UP.0031.1.A
v2.0.2024

Indication	Imaging Study
New or worsening signs or symptoms suggestive of metastatic lung involvement or new or worsening chest x-ray abnormality	<ul style="list-style-type: none"> CT Chest with contrast (CPT® 71260) CT Chest without contrast (CPT® 71250) can be approved if there is a contraindication to CT contrast or only parenchymal lesions are being evaluated
Chest wall or brachial plexus involvement	<ul style="list-style-type: none"> MRI Chest without and with contrast (CPT® 71552)
<p><u>ONE of the following and no diagnosis-specific guideline regarding PET imaging:</u></p> <ul style="list-style-type: none"> Lung nodule(s) ≥8 mm Confirm solitary metastasis amenable to resection on conventional imaging 	<ul style="list-style-type: none"> PET/CT (CPT® 78815) When primary cancer known, PET request should be reviewed by primary cancer guideline
Previous or current malignancy and pulmonary nodule(s) that would reasonably metastasize to the lungs	<ul style="list-style-type: none"> CT Chest with contrast (CPT® 71260) at 3, 6, 12, and 24 months from the first study

Liver Metastases (ONC-31.2)

ON.UP.0031.2.A
v2.0.2024

- Ablation of liver metastases or primary HCC may be performed utilizing chemical, chemotherapeutic, radiofrequency, or radioactive isotope. Regardless of the modality of ablation, PET is not indicated for assessing response to this mode of therapy.

Indication	Imaging Study
New or worsening signs or symptoms suggestive of metastatic liver involvement or new elevation in LFTs	<ul style="list-style-type: none"> • CT Abdomen with (CPT® 74160) or without and with (CPT® 74170) contrast
<p><u>ANY of the following:</u></p> <ul style="list-style-type: none"> • Considering limited resection • Inconclusive CT findings 	<ul style="list-style-type: none"> • MRI Abdomen without and with contrast (CPT® 74183)
<p><u>ONE of the following and no diagnosis-specific guideline regarding PET imaging:</u></p> <ul style="list-style-type: none"> • Confirm solitary metastasis amenable to resection on conventional imaging • LFT's and/or tumor markers continue to rise and CT and MRI are negative 	<ul style="list-style-type: none"> • PET/CT (CPT® 78815) <ul style="list-style-type: none"> • When primary cancer known, PET request should be reviewed by primary cancer guideline
Monitoring of liver metastases that have been surgically resected	<ul style="list-style-type: none"> • Review according to primary cancer guideline
Evaluation of hepatic artery chemotherapy infusion or TACE (transarterial chemoembolization)	<p><u>ONE of the following studies, if not previously done:</u></p> <ul style="list-style-type: none"> • CT Abdomen without and with contrast (CPT® 74170) • MRI Abdomen without and with contrast (CPT® 74183)

Indication	Imaging Study
<p>Evaluation for hepatic artery radioembolization with Y-90 radioactive spheres (TheraSphere or SIR Spheres) for liver metastases or primary liver tumors</p>	<p><u>To assess hepatic vascular anatomy before the procedure, any ONE of the following:</u></p> <ul style="list-style-type: none"> • 3D Rendering (CPT® 76377) if conventional hepatic angiogram is being performed • CTA Abdomen (CPT® 74175) <p><u>ONE of the following studies may be approved PRE-treatment based upon provider preference:</u></p> <ul style="list-style-type: none"> • Liver Imaging Planar (CPT® 78201) • Radiopharmaceutical Localization Limited Area (CPT® 78800 or CPT® 78801) • SPECT or SPECT/CT (CPT® 78803, 78831, 78830, or 78832) <p><u>ONE of the following studies may be approved POST-treatment based upon provider preference:</u></p> <ul style="list-style-type: none"> • Liver Planar Imaging (CPT® 78201) • Radiopharmaceutical Localization Limited Area (CPT® 78800 or CPT® 78801) • SPECT or SPECT/CT (CPT® 78803, 78831, 78830, or 78832) <p>Please note: liver-lung shunt calculation is included in the pre-treatment Liver Scan and does not require additional Lung Perfusion Scan</p>
<p>Monitoring of ablated liver metastases or primary tumors</p>	<p><u>ONE of the following, immediately prior to ablation, 1 month post-ablation, then every 3 months for 2 years, and then every 6 months until year 5:</u></p> <ul style="list-style-type: none"> • CT Abdomen without and with contrast (CPT® 74170) • MRI Abdomen without and with contrast (CPT® 74183)

Brain Metastases (ONC-31.3)

ON.UP.0031.3.A
v2.0.2024

Indication	Imaging Study
Individual with cancer and signs or symptoms of CNS disease or known brain metastasis with new signs or symptoms.	<ul style="list-style-type: none"> MRI Brain without and with contrast (CPT® 70553)
To determine candidacy for SRS, and a diagnostic thin-slice MRI Brain has not been performed in the preceding 30 days	<ul style="list-style-type: none"> MRI Brain without and with contrast (CPT® 70553)
Stereotactic radiosurgery planning	<ul style="list-style-type: none"> Unlisted MRI for treatment planning purposes (CPT® 76498)
Monitoring of brain metastases treated with surgery or radiation therapy	<p><u>Post-treatment, then every 3 months for 1 year and every 6 months thereafter:</u></p> <ul style="list-style-type: none"> MRI Brain without and with contrast (CPT® 70553) <p>***Individuals treated with stereotactic radiosurgery alone may have MRI Brain without and with contrast (CPT® 70553) immediately after stereotactic radiosurgery, then every 2 months for the first year, and then every 6 months thereafter</p>
Brain metastases treated with radiation therapy, with recent MRI Brain indeterminate in distinguishing radiation necrosis vs. tumor progression	<ul style="list-style-type: none"> MRI Perfusion imaging (CPT® 70553)
Brain metastases treated with radiation therapy, with recent MRI Brain and MR Perfusion studies both unable to distinguish radiation necrosis vs. tumor progression	<ul style="list-style-type: none"> PET Metabolic Brain (CPT® 78608)

Indication	Imaging Study
<p><u>Any of the following:</u></p> <ul style="list-style-type: none">• Solitary brain metastasis suspected in individual with prior diagnosis of cancer and no diagnosis-specific guideline regarding PET imaging• Brain metastases and no known primary tumor	<ul style="list-style-type: none">• CT Chest (CPT® 71260) and CT Abdomen and Pelvis (CPT® 74177) with contrast• Mammography for female individuals• PET/CT (CPT® 78815 or CPT® 78816) is indicated for ANY of the following:<ul style="list-style-type: none">• Inconclusive conventional imaging• Confirm either stable systemic disease or absence of other metastatic disease• When primary cancer known, PET request should be reviewed by primary cancer guideline
Primary brain tumors	See: <u>Primary Central Nervous System Tumors (ONC-2)</u>
MR Spectroscopy (CPT® 76390) is considered investigational and experimental for evaluation of metastatic brain cancer	

Adrenal Gland Metastases (ONC-31.4)

ON.UP.0031.4.A
v2.0.2024

Indication	Imaging Study
Differentiate benign adrenal adenoma from metastatic disease	<ul style="list-style-type: none"> See: Adrenal Cortical Lesions (AB-16.1) in the Abdomen Imaging Guidelines
<u>Known cancer and no known systemic metastases:</u> <ul style="list-style-type: none"> New adrenal mass Enlarging adrenal mass Inconclusive findings on recent CT 	<u>If not done previously, ANY of the following may be obtained:</u> <ul style="list-style-type: none"> CT Abdomen without contrast (CPT® 74150) CT Abdomen without and with contrast (CPT® 74170, adrenal protocol) MRI Abdomen without contrast (CPT® 74181) MRI Abdomen without and with contrast (CPT® 74183) CT-directed needle biopsy (CPT® 77012)
<u>One of the following and no diagnosis-specific guideline regarding PET imaging:</u> <ul style="list-style-type: none"> Biopsy is not feasible or is non-diagnostic Isolated metastasis on conventional imaging and individual is a candidate for aggressive surgical management 	<ul style="list-style-type: none"> PET/CT (CPT® 78815) <p>When primary cancer known, PET request should be reviewed by primary cancer guideline</p>
Known extra-adrenal malignancy and undiagnosed adrenal mass being monitored off treatment	See: Phases of Oncology Imaging and General Phase-Related Considerations (ONC-1.2)

Bone (Non-Vertebral) Metastases (ONC-31.5)

ON.UP.0031.5.A

v2.0.2024

Indication	Imaging Study
<p><u>ANY of the following in an individual with a current or prior malignancy:</u></p> <ul style="list-style-type: none"> Bone pain Rising tumor markers Elevated alkaline phosphatase 	<ul style="list-style-type: none"> Bone scan supplemented by plain x-rays is the initial diagnostic imaging study of choice (see: <u>Nuclear Medicine (NM) Imaging in Oncology [ONC-1.3]</u>)
<p><u>ANY of the following:</u></p> <ul style="list-style-type: none"> Bone scan is not feasible or readily available Bone scan is equivocal or indeterminate Continued suspicion despite negative/inconclusive bone scan or other imaging modalities Soft tissue component suspected on other imaging modalities Differentiate neoplastic disease from Paget's disease of the bone 	<p><u>ANY one of the following:</u></p> <ul style="list-style-type: none"> MRI without and with contrast of the involved body site CT without or with contrast of the involved body site
<p>Bone metastases suspected and both bone scan and either CT or MRI are inconclusive</p>	<ul style="list-style-type: none"> ¹⁸F-FDG-PET/CT (CPT® 78815 or CPT® 78816)
<p>Suspected metastatic bone disease and negative work-up for myeloma</p>	<ul style="list-style-type: none"> CT Chest (CPT® 71260) and CT Abdomen and Pelvis (CPT® 74177) with contrast
<p>No prior cancer history with suspected pathologic fracture on plain x-ray</p>	<ul style="list-style-type: none"> See: <u>Carcinoma of Unknown Primary Site (ONC-31.7)</u>

Spinal/Vertebral Metastases (ONC-31.6)

ON.UP.0031.6.A

v2.0.2024

- Individuals with stage IV cancer with new onset back pain can forgo a bone scan (and plain films) in lieu of an MRI with and without contrast of the spine.

Indication	Imaging Study
<p><u>Known cancer history and spinal cord compression suspected based on signs/symptoms of neurological compromise, including, but not limited to:</u></p> <ul style="list-style-type: none"> Unexpected, sudden loss of bowel or bladder control Sudden loss of ability to ambulate Complete loss of pinprick sensation corresponding to a specific vertebral level Loss of pain at a site that had previously been refractory to pain management 	<ul style="list-style-type: none"> MRI Cervical (CPT® 72156), MRI Thoracic (CPT® 72157), and MRI Lumbar Spine (CPT® 72158) without and with contrast OR without contrast CT Cervical (CPT® 72126), CT Thoracic (CPT® 72129), and CT Lumbar (CPT® 72132) Spine if MRI is contraindicated
<p><u>Individual with a known history of cancer and ANY of the following:</u></p> <ul style="list-style-type: none"> Metastatic or stage IV cancer with new or worsening back pain Back pain and suspicion of spinal malignancy based on any one of the following: <ul style="list-style-type: none"> Night pain Age >70 years Uncontrolled or unintentional weight loss Pain unrelieved by change in position Severe and worsening spinal pain despite a reasonable (generally after 1 week) trial of provider-directed treatment with re-evaluation 	<p><u>ONE of the following:</u></p> <ul style="list-style-type: none"> MRI of the relevant spinal level without contrast MRI of the relevant spinal level without and with contrast CT of the relevant spinal level without contrast CT Myelogram of the relevant spinal level

Indication	Imaging Study
Monitoring untreated vertebral metastases	<p><u>One of the following, every 3 months for 1 year:</u></p> <ul style="list-style-type: none">• MRI without and with contrast of the involved spinal level• CT without or with contrast of the involved spinal level <p>**Imaging beyond 1 year is based on any new clinical signs/symptoms</p>
Monitoring metastases within the spine treated with surgery and/or radiation therapy	<p><u>One of the following, once within 3 months post-treatment, and then every 3 months for 1 year:</u></p> <ul style="list-style-type: none">• MRI without and with contrast of the involved spinal level• CT without or with contrast of the involved spinal level <p>**Imaging beyond 1 year is based on any new clinical signs/symptoms</p>

Indication	Imaging Study
Leptomeningeal involvement with cancer	<p><u>Suspected:</u></p> <ul style="list-style-type: none">• MRI Brain without and with contrast (CPT® 70553) and MRI Cervical (CPT® 72156), Thoracic (CPT® 72157), and Lumbar spine (CPT® 72158) without and with contrast• CT Cervical (CPT® 72127), Thoracic (CPT® 72130), and Lumbar Spine (CPT® 72133) without and with contrast can be approved if MRI is contraindicated or not readily available <p><u>On active treatment:</u></p> <ul style="list-style-type: none">• MRI Brain without and with contrast (CPT® 70553) and MRI Cervical (CPT® 72156), Thoracic (CPT® 72157), and Lumbar spine (CPT® 72158) without and with contrast every 2 cycles• CT with or without contrast of the involved spinal level if MRI is contraindicated <p><u>Once treatment completed:</u></p> <ul style="list-style-type: none">• Routine advanced imaging not indicated for surveillance in asymptomatic individuals

Carcinoma of Unknown Primary Site (ONC-31.7)

ON.UP.0031.7.A

v2.0.2024

General Considerations

- Defined as carcinoma found in a lymph node or in an organ known not to be the primary for that cell type (e.g., adenocarcinoma arising in the brain or in a neck lymph node).
- This guideline also applies to a pathologic fracture that is clearly due to metastatic neoplastic disease in an individual without a previous cancer history.
- Detailed history and physical examination including pelvic and rectal exams and laboratory tests to be performed before advanced imaging.
- Individuals presenting with a thoracic squamous cell carcinoma described as metastatic appearing on chest imaging, or in lymph nodes above the clavicle, should undergo a detailed head and neck examination by a clinician skilled in laryngeal and pharyngeal examinations, especially in smokers.
- Individuals with suspected unknown primary based on only suspicious lytic bone lesions should be considered for serum protein electrophoresis (SPEP); urine protein electrophoresis (UPEP) and serum free light chains prior to consideration of extensive imaging.

Indication	Imaging Study
Carcinoma found in a lymph node or in an organ known not to be primary	<ul style="list-style-type: none"> • CT Chest (CPT® 71260) and CT Abdomen and Pelvis with contrast (CPT® 74177) • CT Neck with contrast (CPT® 70491) if cervical or supraclavicular involvement • CT with contrast or MRI without and with contrast of any other symptomatic site • For female individuals: <ul style="list-style-type: none"> • Diagnostic (not screening) mammogram and full pelvic exam • MRI Breasts Bilateral (CPT® 77049) if pathology consistent with breast primary and mammogram is inconclusive
Sebaceous carcinoma of the skin (can be associated with underlying primary malignancy)	<ul style="list-style-type: none"> • CT Chest (CPT® 71260) and CT Abdomen and Pelvis with contrast (CPT® 74177) • CT Neck with contrast (CPT® 70491) if cervical or supraclavicular involvement • CT with contrast or MRI without and with contrast of any other symptomatic site

Indication	Imaging Study
Axillary adenocarcinoma	<ul style="list-style-type: none"> • Diagnostic (not screening) mammogram and full pelvic exam • MRI Breasts Bilateral (CPT® 77049) if pathology consistent with breast primary and mammogram is inconclusive • If the above are non-diagnostic for primary site: <ul style="list-style-type: none"> • CT Neck (CPT® 70491), CT Chest (CPT® 71260), and CT Abdomen (CPT® 74160) with contrast • CT with contrast or MRI without and with contrast of any other symptomatic site
Carcinoma found within a bone lesion	<ul style="list-style-type: none"> • CT Chest (CPT® 71260) and CT Abdomen and Pelvis with contrast (CPT® 74177) • Bone Scan (see: ONC-1.3) • CT with contrast or MRI without and with contrast of any symptomatic site
<p><u>ANY of the following:</u></p> <ul style="list-style-type: none"> • Above studies have failed to demonstrate site of primary • CT scans reveal isolated metastatic disease for which definitive curative therapy is planned 	<ul style="list-style-type: none"> • PET/CT (CPT® 78815 or CPT® 78816)
Post-treatment surveillance	<ul style="list-style-type: none"> • Advanced imaging is not indicated for routine surveillance of asymptomatic individuals after treatment completion

Extrathoracic Small Cell and Large Cell Neuroendocrine Tumors (ONC-31.8)

ON.UP.0031.8.A
v2.0.2024

All poorly-differentiated or high-grade, small cell and large cell neuroendocrine tumors arising outside the lungs or of unknown primary origin are imaged according to these guidelines.

Indication	Imaging Study
Initial staging	<ul style="list-style-type: none"> CT Chest (CPT® 71260) and CT Abdomen and Pelvis (CPT® 74177) with contrast
Inconclusive findings on conventional imaging studies	<ul style="list-style-type: none"> PET/CT (CPT® 78815)
<p><u>ANY of the following:</u></p> <ul style="list-style-type: none"> Poorly differentiated neuroendocrine cancers of the head or neck Signs or symptoms of CNS involvement 	<ul style="list-style-type: none"> MRI Brain without and with contrast (CPT® 70553)
Restaging during treatment	<ul style="list-style-type: none"> CT Chest (CPT® 71260) and CT Abdomen and Pelvis (CPT® 74177) and any known sites of disease with contrast every 2 cycles
Suspected Recurrence	<p><u>ANY or ALL of the following are indicated:</u></p> <ul style="list-style-type: none"> CT Chest (CPT® 71260) and CT Abdomen and Pelvis (CPT® 74177) with contrast MRI Brain without and with contrast (CPT® 70553) Bone scan (See: Nuclear Medicine (NM) Imaging in Oncology (ONC-1.3)) PET imaging is generally not indicated but can be considered for rare circumstances.
Surveillance	<ul style="list-style-type: none"> CT Chest (CPT® 71260) and CT Abdomen and Pelvis (CPT® 74177) with contrast every 3 months for 1 year, then every 6 months for 4 additional years and then annually

Primary Peritoneal Mesothelioma (ONC-31.9)

ON.UP.0031.9.A

v2.0.2024

Indication	Imaging Study
Initial staging	<ul style="list-style-type: none">CT Chest (CPT® 71260) and CT Abdomen and Pelvis (CPT® 74177) with contrastPET/CT (CPT® 78815) if there is no evidence of metastatic disease or conventional imaging is inconclusive
Recurrence/ Restaging	<ul style="list-style-type: none">If there is known prior disease, CT Chest (CPT® 71260) and CT Abdomen and Pelvis (CPT® 74177) with contrastPET for inconclusive finding on conventional imaging
Surveillance	<ul style="list-style-type: none">CT Abdomen and Pelvis with contrast (CPT® 74177) every 3 months for 2 years, then every year of life

Kaposi's Sarcoma (ONC-31.10)

ON.UP.0031.10.A

v2.0.2024

Indication	Imaging Study
Kaposi's Sarcoma	<ul style="list-style-type: none">Advanced imaging is not generally indicated since disease is generally localized to skin.CT Chest (CPT® 71260) and CT Abdomen and Pelvis (CPT® 74177) with contrast can be approved at initial diagnosis. If initial scans are negative then future imaging would be based on signs or symptoms.

Castleman’s Disease (Unicentric and Multicentric) (ONC-31.11)

ON.UP.0031.11.A

v2.0.2024

Indication	Imaging Study
Initial staging	<ul style="list-style-type: none"> • Either CT Chest (CPT® 71260) and CT Abdomen and Pelvis (CPT® 74177) with contrast or PET/CT (CPT® 78815) • CT Neck with contrast (CPT® 70491) if cervical or supraclavicular involvement • If CT scans were utilized initially and suggested unicentric disease, and surgical resection is being considered, PET/CT (CPT® 78815) can be approved to confirm unicentric disease • If unicentric disease is surgically removed, proceed to Surveillance section
<u>Restaging:</u> <ul style="list-style-type: none"> • Multicentric disease or surgically unresected unicentric disease on chemotherapy 	<u>ONE of the following every 2 cycles:</u> <ul style="list-style-type: none"> • CT Chest (CPT® 71260) and CT Abdomen and Pelvis (CPT® 74177) with contrast • PET/CT (CPT® 78815)
<u>ANY of the following:</u> <ul style="list-style-type: none"> • Suspected recurrence • Recurrent B symptoms • Rising LDH/IL-6/VEGF levels 	<u>ONE of the following:</u> <ul style="list-style-type: none"> • CT Chest (CPT® 71260) and CT Abdomen and Pelvis (CPT® 74177) with contrast • PET/CT (CPT® 78815)
Surveillance	<ul style="list-style-type: none"> • CT with contrast of involved areas no more than every 6 months up to 5 years

References (ONC-31)

v2.0.2024

1. Ettinger DS, Stevenson MM, Ahn D, et al. National Comprehensive Cancer Network (NCCN) Guidelines Version 3.2023 – December 21, 2022. Occult primary, available at: https://www.nccn.org/professionals/physician_gls/pdf/occult.pdf Referenced with permission from the NCCN Clinical Practice Guidelines in Oncology (NCCN Guidelines™) for Occult Primary V3.2023 – December 21, 2022 ©2022 National Comprehensive Cancer Network, Inc. All rights reserved. The NCCN Guidelines™ and illustrations herein may not be reproduced in any form for any purpose without the express written permission of the NCCN. To view the most recent and complete version of the NCCN Guidelines™, go online to NCCN.org.
2. Nabors BL, Portnow J, Baehring J, et al. National Comprehensive Cancer Network (NCCN) Guidelines Version 1.2023 – March 24, 2023. Central Nervous System Cancers, available at: https://www.nccn.org/professionals/physician_gls/pdf/cns.pdf Referenced with permission from the NCCN Clinical Practice Guidelines in Oncology (NCCN Guidelines™) for CNS Cancer V1.2023 – March 24, 2023. ©2023 National Comprehensive Cancer Network, Inc. All rights reserved. The NCCN Guidelines™ and illustrations herein may not be reproduced in any form for any purpose without the express written permission of the NCCN. To view the most recent and complete version of the NCCN Guidelines™, go online to NCCN.org.
3. Zelenetz AD, Gordon LI, Abramson JS, et al. National Comprehensive Cancer Network (NCCN) Guidelines Version 5.2023 – July 7, 2023. B-cell lymphomas, available at: https://www.nccn.org/professionals/physician_gls/pdf/B-CELL.pdf Referenced with permission from the NCCN Clinical Practice Guidelines in Oncology (NCCN Guidelines™) for B-cell lymphomas V5.2023 – July 7, 2023. ©2023 National Comprehensive Cancer Network, Inc. All rights reserved. The NCCN Guidelines™ and illustrations herein may not be reproduced in any form for any purpose without the express written permission of the NCCN. To view the most recent and complete version of the NCCN Guidelines™, go online to NCCN.org.
4. Mayo-Smith WM, Song JH, Boland GL, et al. Management of incidental adrenal masses: a white paper of the ACR Incidental Findings Committee. *J Am Coll Radiol.* 2017;14(8):1038-1044. doi:10.1016/j.jacr.2017.05.001.
5. ACR Appropriateness Criteria®. *Incidentally discovered adrenal mass.* Rev. 2012.
6. Braat AJ, Smits ML, Braat MN, et al. 90Y hepatic radioembolization: an update on current practice and recent developments. *J Nucl Med.* 2015;56(7):1079–1087. doi:10.2967/jnumed.115.157446.
7. Pawaskar AS, Basu S. Role of 2-fluoro-2-deoxyglucose PET/computed tomography in carcinoma of unknown primary. *PET Clin.* 2015;10(3):297-310. doi:10.1016/j.cpet.2015.03.004.
8. Avram AM. Radioiodine scintigraphy with SPECT/CT: an important diagnostic tool for thyroid cancer staging and risk stratification. *J Nucl Med.* 2012;53(5): 754-764. doi:10.2967/jnumed.111.104133.
9. Mayo-Smith WW, Song JH, Boland GL, et al. Management of incidental adrenal masses: a white paper of the ACR Incidental Findings Committee. *J Am Coll Radiol.* 2017;14(8):1038-1044. doi:10.1016/j.jacr.2017.05.001.
10. Vaidya A, Hamrahian A, Bancos I, Fleseriu M, Ghayee HK. The evaluation of incidentally discovered adrenal masses. *Endocrine Practice.* 2019;25(2);178-192. doi: 10.4158/DSCR-2018-0565.
11. Bergsland E, Goldner WS, Benson III AB, et al. National Comprehensive Cancer Network (NCCN) Guidelines Version 1.2023 – August 2, 2023. Neuroendocrine and Adrenal Tumors, available at: https://www.nccn.org/professionals/physician_gls/pdf/neuroendocrine.pdf Referenced with permission from the NCCN Clinical Practice Guidelines in Oncology (NCCN Guidelines™) for Neuroendocrine and Adrenal Tumors V1.2023 – August 2, 2023. ©2023 National Comprehensive Cancer Network, Inc. All rights reserved. The NCCN Guidelines™ and illustrations herein may not be reproduced in any form for any purpose without the express written permission of the NCCN. To view the most recent and complete version of the NCCN Guidelines™, go online to NCCN.org.
12. Furuse M, Nonoguchi N, Yamada K, et al. Radiological diagnosis of brain radiation necrosis after cranial irradiation for brain tumor: a systematic review. *Radiat Oncol.* 2019;14(28). doi:10.1186/s13014-019-1228-x.
13. American College of Radiology. ACR practice parameter for the performance of stereotactic radiosurgery. 2016; <https://www.acr.org/-/media/ACR/Files/Practice-Parameters/stereobrain.pdf>
14. Soffietti R, Abacioglu U, Baumert B, et al. Diagnosis and treatment of brain metastases from solid tumors: guidelines from the European Association of Neuro-Oncology (EANO). *Neuro-Oncology.* 2017;19(2):162-174. doi:10.1093/neuonc/now241.
15. Mehrabian H, Detsky J, Soliman H, Sahgal A, Stanisiz GJ. Advanced magnetic resonance imaging techniques in management of brain metastases. *Front Oncol.* 2019;9(440). doi:10.3389/fonc.2019.00440.

16. Murthy R, Nunez R, Szklaruk J, et. al. Yttrium-90 microsphere therapy for hepatic malignancy: devices, indications, technical considerations and potential complications. *RadioGraphics*. 2005;25:S41–S55. doi:10.1148/rg.25si055515.
17. Lencioni R, Petruzzi P, Crocetti L. Chemoembolization of hepatocellular carcinoma. *Semin Intervent Radiol*. 2013;30(1):3-11. doi:10.1055/s-0033-1333648.

Table of Contents

Guideline

- General Guidelines (PV-1)
- Abnormal Uterine Bleeding (PV-2)
- Amenorrhea (PV-3)
- Adenomyosis (PV-4)
- Adnexal Mass/Ovarian Cysts (PV-5)
- Endometriosis (PV-6)
- Pelvic Inflammatory Disease (PID) (PV-7)
- Polycystic Ovary Syndrome (PV-8)
- Initial Infertility Evaluation, Female (PV-9)
- Intrauterine Device (IUD) and Tubal Occlusion (PV-10)
- Pelvic Pain/Dyspareunia, Female (PV-11)
- Leiomyoma/Uterine Fibroids (PV-12)
- Periurethral Cysts, Urethral Diverticula, and Vaginal Masses (PV-13)
- Congenital (Mullerian) Uterine and Vaginal Anomalies (PV-14)
- Fetal MRI and Other Pregnancy Imaging (PV-15)
- Molar Pregnancy and Gestational Trophoblastic Neoplasia (GTN) (PV-16)
- Impotence/Erectile Dysfunction (PV-17)
- Penis–Soft Tissue Mass (PV-18)
- Male Pelvic Disorders (PV-19)
- Scrotal Pathology (PV-20)
- Fistulae, Abscess, and Pilonidal Cyst (PV-21)
- Urinary Incontinence/Pelvic Prolapse/Fecal Incontinence (PV-22)
- Patent Urachus (PV-23)
- Bladder Mass (PV-24)
- Ureteral and/or Bladder Trauma or Injury (PV-25)
- Gender Affirmation Surgery; Pelvic (PV-26)

General Guidelines (PV-1)

Guideline

Abbreviations for Pelvis Imaging Guidelines

General Guidelines (PV-1.0)

General Guidelines – Overview (PV-1.1)

References (PV-1)

Abbreviations for Pelvis Imaging Guidelines

PV.GG.Abbreviations.A

v2.0.2024

Abbreviations for Pelvis Imaging Guidelines	
CA-125	cancer antigen 125 test
CT	computed tomography
FSH	follicle-stimulating hormone
GTN	gestational trophoblastic neoplasia
HCG	human chorionic gonadotropin
IC/BPS	interstitial cystitis/bladder pain syndrome
IUD	intrauterine device
KUB	kidneys, ureters, bladder (frontal supine abdomen radiograph)
LH	luteinizing hormone
MRA	magnetic resonance angiography
MRI	magnetic resonance imaging
MSv	millisievert
PA	posteroanterior projection
PID	pelvic inflammatory disease
TA	transabdominal
TSH	thyroid-stimulating hormone
TV	transvaginal
UCPPS	Urologic Chronic Pelvic Pain Syndrome
WBC	white blood cell count

General Guidelines (PV-1.0)

PV.GG.0001.0.U

v2.0.2024

- A current clinical evaluation since the onset or change in symptoms is required before advanced imaging can be considered. The clinical evaluation should include a relevant history and physical examination including a pelvic and/or urological exam, appropriate laboratory studies, and non-advanced imaging modalities such as plain x-ray or Pelvic ultrasound (CPT® 76856 or CPT® 76857) and/or Transvaginal ultrasound (CPT® 76830) and/or Transperineal ultrasound (CPT® 76872).
 - Other meaningful contact (telehealth visit, telephone call, electronic mail or messaging) since the onset or change in symptoms for follow up visit by an established individual can substitute for a face-to-face clinical evaluation.
- The use of gynecology CPT codes for pregnant females is not supported. Therefore, transvaginal ultrasound (CPT® 76830) and pelvic ultrasound (CPT® 76856 or CPT® 76857) are not supported for those with a positive pregnancy test or known pregnancy. If a pregnancy test is positive, then obstetrical CPT codes are indicated.
- The uterus, tubes and ovaries arise out of the pelvis and are considered pelvic organs. If the uterus rises out of the pelvic cavity, the imaging field can be determined on scout films. Imaging of the abdomen is not routinely supported for problems suspected to arise from the pelvis unless specifically described in other areas of the guidelines.
- The scout images (CT) and localizer images (MRI) are used to define the imaging field that is relevant to anatomical structures of clinical interest. The imaging field is defined by this clinical question, not by the imaging procedure code. The imaging code indicates the general anatomical region but does not define the specific imaging protocol or sequences.
- MRI (MRI Pelvis without contrast CPT® 72195 for Defecography) is considered investigational/experimental by UHC.

General Guidelines – Overview (PV-1.1)

PV.GG.0001.1.A

v2.0.2024

- When indicated, pregnant females should be evaluated with ultrasound or MRI without contrast to avoid radiation exposure. In carefully selected clinical circumstances, evaluation with CT may be considered with careful attention to technique and radiation protection as deemed clinically appropriate.

Ultrasound

- Transvaginal ultrasound is the recommended modality for imaging; no alternative modality has demonstrated sufficient superiority to justify routine use, and Transvaginal (TV) ultrasound (CPT® 76830) is the optimal study to evaluate adult female pelvic pathology.
- Pelvic ultrasound (complete CPT® 76856, or limited CPT® 76857) is supported if it is a complementary study to the TV ultrasound. It may substitute for TV in pediatric individuals or non-sexually active females.
- Transperineal ultrasound (CPT® 76872) is supported for cases of suspected urethral abnormalities, urinary incontinence, pelvic prolapse, or vaginal cysts.
- CPT® 76942 is used to report ultrasound imaging guidance for needle placement during biopsy, aspiration, and other percutaneous procedures.

Soft Tissue Ultrasound

- Pelvic wall, buttocks, and penis - CPT® 76857

Scrotal Ultrasound

- See
 - [Impotence/Erectile Dysfunction \(PV-17.1\)](#)
 - [Penis-Soft Tissue Mass \(PV-18.1\)](#)
- Ultrasound scrotum and contents - CPT® 76870

3D Rendering with Ultrasound

- 3D Rendering (CPT® 76376 or CPT® 76377)
 - CPT® 76377 (3D rendering requiring image post-processing on an independent work station) or CPT® 76376 (3D rendering not requiring image post-processing on an independent workstation) can be considered in the following clinical scenarios:
 - Uterine intra-cavitary lesion when initial ultrasound is equivocal (See [Abnormal Uterine Bleeding \(AUB\) \(PV-2.1\)](#) and [Leiomyoma/Uterine Fibroids \(PV-12.1\)](#))

- Hydrosalpinges or peritoneal cysts when initial ultrasound is equivocal (See **Complex Adnexal Masses (PV-5.3)**)
 - Lost IUD (inability to feel or see IUD string) with initial ultrasound (See **Intrauterine Device (PV-10.1)**)
 - Uterine anomaly is suspected on ultrasound (See **Uterine Anomalies (PV-14.1)**)
 - Infertility if ultrasound is indeterminate or there is clinical suspicion for intracavitary lesion (such as polyp or fibroid), hydrosalpinx, uterine synechia, adenomyosis or uterine anomalies (See **Initial Infertility Evaluation, Female (PV-9.1)**)
- There is currently insufficient data to generate appropriateness criteria for the use of 3D and 4D rendering in conjunction with Obstetrical ultrasound imaging. Per ACOG, proof of a clinical advantage of 3-dimensional ultrasonography in prenatal diagnosis, in general, is still lacking.
 - However, 3D-4D (CPT® 76376 or CPT® 76377) rendering can be considered in certain situations of abnormal pregnancy implantation like suspected C-section scar pregnancies or suspected cornual (interstitial) ectopic pregnancy, or to locate an IUD.
 - 3D-4D (CPT® 76376 or CPT® 76377) rendering can be used for surgical planning with diagnosis of complex CHD in the fetus or for surgical planning of other complex fetal malformations.

Other Ultrasound

- CPT® 93975 Duplex scan (complete) of arterial inflow and venous outflow of abdominal, pelvic, scrotal contents and/or retroperitoneal organs; complete study.
- CPT® 93976 Duplex scan (limited) of arterial inflow and venous outflow of abdominal, pelvic, scrotal contents and/or retroperitoneal organs; limited study.
- CPT® 93975 and CPT® 93976 should not be reported together during the same session.

CT

- CT is not generally warranted for evaluating pelvic anatomy because it is limited due to soft tissue contrast resolution.

MRI

- Can be used as a more targeted study or for individuals allergic to iodinated contrast.
 - MRI Pelvis without contrast (CPT® 72195)
 - MRI Pelvis without and with contrast (CPT® 72197)
 - MRI Pelvis with contrast only (CPT® 72196) is rarely performed

References (PV-1)

v2.0.2024

1. Practice Bulletin No. 174. The Evaluation and Management of Adnexal Masses. *Obstetrics & Gynecology*. 2016 Reaffirmed 2021;128(5):1193-1195. doi:10.1097/aog.0000000000001763
2. Lakshmy S, Rose N, Ramachandran M. Role of three dimensional ultrasound in uterine anomalies - 3D assessment of cervix in septate uteri. *International Journal of Reproduction, Contraception, Obstetrics and Gynecology*. 2016;3563-3567. doi:10.18203/2320-1770.ijrcog20163445
3. Benacerraf BR, Abuhamad AZ, Bromley B, et al. Consider ultrasound first for imaging the female pelvis. *American Journal of Obstetrics and Gynecology*. 2015;212(4):450-455. doi:10.1016/j.ajog.2015.02.015
4. Turkgeldi E, Urman B, Ata B. Role of Three-Dimensional Ultrasound in Gynecology. *Journal of Obstetrics and Gynaecology of India*. 2014;65(3):146-154. doi:10.1007/s13224-014-0635-z
5. Graupera B, Pascual MA, Hereter L, et al. Accuracy of three-dimensional ultrasound compared with magnetic resonance imaging in diagnosis of Müllerian duct anomalies using ESHRE-ESGE consensus on the classification of congenital anomalies of the female genital tract. *Ultrasound in Obstetrics & Gynecology*. 2015;46(5):616-622. doi:10.1002/uog.14825
6. Sakhel K, Benson CB, Platt LD, Goldstein SR, Benacerraf BR. Begin with the basics: role of 3-dimensional sonography as a first-line imaging technique in the cost-effective evaluation of gynecologic pelvic disease. *Journal of Ultrasound in Medicine*. 2013;32(3):381-388. doi:10.7863/jum.2013.32.3.381
7. AIUM Practice Parameter for the Performance of an Ultrasound Examination of the Female Pelvis *J Ultrasound Med* 2020; 9999:1-7
8. Seidel, H. M. (2011). *Mosby's guide to physical examination*. St. Louis, Mo: Mosby/Elsevier
9. Practice Bulletin No. 175: Ultrasound in Pregnancy, *Obstetrics & Gynecology*: December 2016 - Volume 128 - Issue 6 - p e241-e25 Reaffirmed 2022
10. Lloyd DFA, Pushparajah K, Simpson JM, et al. Three-dimensional visualisation of the fetal heart using prenatal MRI with motion-corrected slice-volume registration: a prospective, single-centre cohort study. *Lancet*. 2019;393(10181):1619-1627. doi:10.1016/s0140-6736(18)32490-5.

Abnormal Uterine Bleeding (PV-2)

Guideline

Abnormal Uterine Bleeding (AUB) (PV-2.1)
Retained Products of Conception (PV-2.2)
References (PV-2)

Abnormal Uterine Bleeding (AUB) (PV-2.1)

PV.UB.0002.1.A

v2.0.2024

- Pregnancy test should be done initially if premenopausal
- If pregnancy test is negative or post menopausal initial evaluation includes ANY or ALL of the following:
 - Pelvic ultrasound (CPT® 76856 or CPT® 76857) and/or Transvaginal ultrasound (CPT® 76830), D&C and/or endometrial biopsy
- Advanced imaging is not indicated for endometrial intraepithelial neoplasia.
- If biopsy confirms a malignancy, then see the appropriate oncology guideline.
- If ultrasound is equivocal for intracavitary lesion
 - Duplex (Doppler) scan (CPT® 93975 complete; CPT® 93976 limited) as an add-on to TV ultrasound (CPT® 76830).
 - 3-D Rendering (CPT® 76377 or CPT® 76376) as an add-on.
- If ultrasound is equivocal for an intracavitary lesion, saline infusion sonohysterography (CPT® 76831) may be indicated.
- CT is not generally warranted for evaluating AUB since uterine anatomy is limited due to soft tissue contrast resolution.
 - An abnormal endometrium found incidentally on CT should be referred for TV ultrasound for further evaluation.
- MRI is not indicated for evaluation of abnormal uterine bleeding, please see specific Pelvis Imaging sections for MRI indications for ultrasound findings such as adnexal mass or uterine fibroids. See **Adnexal Mass/Ovarian Cysts (PV-5)** and **Leiomyomata (PV-12.1)**.

Retained Products of Conception (PV-2.2)

PV.UB.0002.2.A

v2.0.2024

- For abnormal uterine bleeding and/or pelvic pain with concern for retained products of conception (RPOC):
 - Pelvic ultrasound (CPT® 76856 or CPT® 76857) and/or Transvaginal ultrasound (CPT® 76830) is supported one time, repeat US is indicated for continued symptoms
 - Color Doppler ultrasonography (CPT® 93975 or CPT® 93976) may be added to ultrasound to aid in diagnosis of RPOC
 - CT Pelvis with and without contrast (CPT® 72194) OR MRI Pelvis with and without contrast (CPT® 72197) is supported if US with Color Doppler is equivocal AND further imaging is needed for surgical planning

References (PV-2)

v2.0.2024

1. Committee Opinion No. 631. Endometrial Intraepithelial Neoplasia. *Obstetrics & Gynecology*. 2015;125(5):1272-1278. doi:10.1097/01.aog.0000465189.50026.20 (May 2015, Reaffirmed 2020.)
2. Trimble C, Method M, et al. Management of Endometrial Precancers. *Obstetrics & Gynecology* 2012;120(5): 1160-1175. doi: 10.1097/AOG.0b013e31826bb121
3. Practice Bulletin No. 128. Diagnosis of Abnormal Uterine Bleeding in Reproductive-Aged Women. *Obstetrics & Gynecology*. 2012;120(1):197-206; reaffirmed 2021. doi:10.1097/aog.0b013e318262e320
4. Sakhel K, Benson CB, Platt LD, Goldstein SR, Benacerraf BR. Begin With the Basics. *Journal of Ultrasound in Medicine*. 2013;32(3):381-388. doi:10.7863/jum.2013.32.3.381
5. Benacerraf BR, Abuhamad AZ, Bromley B, et al. Consider ultrasound first for imaging the female pelvis. *American Journal of Obstetrics and Gynecology*. 2015;212(4):450-455. doi:10.1016/j.ajog.2015.02.015
6. Practice Bulletin No. 136. Management of Abnormal Uterine Bleeding Associated With Ovulatory Dysfunction. *Obstetrics & Gynecology*. 2013; Reaffirmed 2022. 122(1):176-185. doi:10.1097/01.aog.0000431815.52679.bb
7. Bocca SM, Oehninger S, Stadtmauer L, et al. A Study of the Cost, Accuracy, and Benefits of 3-Dimensional Sonography Compared With Hysterosalpingography in Women With Uterine Abnormalities. *Journal of Ultrasound in Medicine*. 2012;31(1):81-85. doi:10.7863/jum.2012.31.1.81
8. Maheux-Lacroix S, Li F, Laberge PY, Abbott J. Imaging for Polyps and Leiomyomas in Women With Abnormal Uterine Bleeding. *Obstetrics & Gynecology*. 2016;128(6):1425-1436. doi:10.1097/aog.0000000000001776
9. Cil AP, Tulunay G, Kose MF, Haberal A. Power Doppler properties of endometrial polyps and submucosal fibroids: a preliminary observational study in women with known intracavitary lesions. *Ultrasound in Obstetrics and Gynecology*. 2010;35(2):233-237. doi:10.1002/uog.7470
10. Bezircioglu I, Baloglu A, Cetinkaya B, Yigit S, Oziz E. The diagnostic value of the Doppler ultrasonography in distinguishing the endometrial malignancies in women with postmenopausal bleeding. *Archives of Gynecology and Obstetrics*. 2011;285(5):1369-1374. doi:10.1007/s00404-011-2159-4
11. Gupta A, Desai A, Bhatt S. Imaging of the Endometrium: Physiologic Changes and Diseases: *Women's Imaging. Radiographics*. 2017;37(7):2206-2207. doi:10.1148/rg.2017170008
12. Postpartum hemorrhage. Practice Bulletin No. 183. *Obstetrics & Gynecology*. 2017; Reaffirmed 2021; 130(4):e168-e186. doi:10.1097/aog.0000000000002351
13. Kamaya A, Krishnarao PM, Nayak N, Jeffrey RB, Maturen KE. Clinical and imaging predictors of management in retained products of conception. *Abdom Radiol (NY)*. 2016 Dec;41(12):2429-2434. doi: 10.1007/s00261-016-0954-x
14. The role of transvaginal ultrasonography in evaluating the endometrium of women with postmenopausal bleeding. ACOG Committee Opinion No. 734. *Obstetrics & Gynecology*. 2018; Reaffirmed 2023; 131(5):e124-e129. doi:10.1097/aog.0000000000002631
15. Sellmyer MA, Desser TS, Maturen KE, Jeffrey RB, Kamaya A. Physiologic, Histologic, and Imaging Features of Retained Products of Conception. *RadioGraphics*. 2013;33(3):781-796. doi:10.1148/rg.333125177
16. Committee Opinion No. 557. American College of Obstetricians and Gynecologists. *Obstet Gynecol* 2013; 121:891-6. Reaffirmed 2020

Amenorrhea (PV-3)

Guideline

Secondary Amenorrhea (PV-3.1)

Primary Amenorrhea (PV-3.2)

References (PV-3)

Secondary Amenorrhea (PV-3.1)

PV.AM.0003.1.A
v2.0.2024

- Pregnancy test should be done initially
- If a pregnancy test is positive:
 - Refer to the member's individual coverage policy regarding obstetrical imaging indications and appropriate obstetrical imaging procedural codes. Billing of gynecology codes during pregnancy is not supported.
- If a pregnancy test is negative, further evaluation includes any of the following:
 - FSH, TSH, estradiol, and/or prolactin levels are indicated depending on clinical suspicion.
 - Serum free and total testosterone and/or DHEAS levels are indicated if there is evidence of hyperandrogenism
 - Pelvic ultrasound (CPT® 76856 or CPT® 76857) and/or TV ultrasound (CPT® 76830) for suspected uterine or ovarian pathology
- The results of test(s) above determine the next steps, which include:
 - For suspected adrenal tumor, See **Adrenal Cortical Lesions (AB-16)** in the Abdomen Imaging Guidelines.
 - For suspected pituitary tumor, See **Pituitary (HD-19)** in the Head Imaging Guidelines
 - For suspected Asherman's Syndrome:
 - Hysterosalpingogram (CPT® 74740), sonohysterosalpingography (CPT® 76831), and/or hysteroscopy if ultrasound is indeterminate for Asherman's syndrome.
 - MRI Pelvis without contrast (CPT® 72195) or without and with contrast (CPT® 72197) if hysterosalpingogram (CPT® 74740), sonohysterosalpingography (CPT® 76831), or hysteroscopy is indeterminate for Asherman's Syndrome.

Background and Supporting Information

- Asherman's syndrome: an acquired condition which refers to having scar tissue in the uterus

Primary Amenorrhea (PV-3.2)

PV.AM.0003.2.A

v2.0.2024

- Prior to imaging a history, physical examination and Tanner stage should be evaluated.
- Initial evaluation may include pelvic ultrasound (CPT® 76856 or CPT® 76857) and/or TV ultrasound (CPT® 76830) if ANY of the following:
 - Normal pubertal development and negative pregnancy test
 - Pelvic exam is indeterminate or unable to be performed
 - Delayed puberty with follicle-stimulating hormone (FSH) or luteinizing hormone (LH) that is elevated for the individual's age and Tanner stage
- If ultrasound defines a uterine or vaginal anomaly see **Uterine Anomalies (PV-14.1)**
- For suspected pituitary tumor, See **Pituitary (HD-19)** in the Head Imaging Guidelines

Background and Supporting Information

- Evaluation of an individual without a uterus (determined by imaging or examination) may include karyotype and/or testosterone levels.
- TV ultrasound (CPT® 76830) is appropriate in pediatric individuals who are sexually active or use a tampon and consent to the study.

References (PV-3)

v2.0.2024

1. Hoffman BL, Schorge JO, Schaffer JI, et al. Chapter 17. Amenorrhea. In: Hoffman BL, Schorge JO, Schaffer JI, et al, eds. *Williams Gynecology*. 4th ed. New York: McGraw-Hill; 2020
2. Klein DA, Paradise SL, Reeder R. Amenorrhea: an approach to diagnosis and management. *American Family Physician*. 2019 Jul 1;100(1):39-48
3. Committee Opinion No. 605. Primary Ovarian Insufficiency in Adolescents and Young Women. *Obstetrics & Gynecology*. 2014;124(1):193-197. doi:10.1097/01.aog.0000451757.51964.98. (July 2014, Reaffirmed 2020)
4. Polycystic ovary syndrome. ACOG Practice Bulletin No. 194. American College of Obstetricians and Gynecologists. *Obstetrics and Gynecology*. 2018. Reaffirmed 2022. 131:e157-71. doi:10.1097/aog.0000000000002656
5. Committee Opinion 779. Management of Acute Obstructive Uterovaginal Anomalies. *Obstetrics & Gynecology*. 2019;133(6). doi:10.1097/aog.0000000000003281. Reaffirmed 2021
6. Committee on Adolescent Health Care. ACOG Committee Opinion No. 728: Müllerian Agenesis: Diagnosis, Management, And Treatment. *Obstetrics and Gynecology*. 2018;131(1):e35-e42. doi:10.1097/AOG.0000000000002458. Reaffirmed 2020

Adenomyosis (PV-4)

Guideline

Adenomyosis (PV-4.1)

References (PV-4)

Adenomyosis (PV-4.1)

PV.AD.0004.1.A

v2.0.2024

- TV ultrasound (CPT® 76830) and/or Pelvic ultrasound (CPT® 76856 or CPT® 76857) is the diagnostic procedure of choice for the initial evaluation of suspected adenomyosis. Duplex Doppler (CPT® 93975 or CPT® 93976) can be added if requested.
- MRI Pelvis without contrast (CPT® 72195) or MRI Pelvis without and with contrast (CPT® 72197) is considered a second-line imaging option after transvaginal ultrasound if:
 - Diagnosis is inconclusive for adenomyosis and the individual has failed a 3-month trial of medical treatment and further delineation would affect management
 - MRI needed to guide the treatment of adenomyosis in an individual with an enlarged uterus, and coexisting leiomyoma/fibroid following indeterminate ultrasound

Background and Supporting Information

Adenomyosis is when endometrial tissue, which normally lines the uterus, moves into the outer muscular walls of the uterus. Adenomyosis is a histologic diagnosis and is suspected by history and physical examination. Ultrasound findings of adenomyosis include heterogeneous myometrium, myometrial cysts, asymmetric myometrial thickness, and subendometrial echogenic linear striations.

References (PV-4)

v2.0.2024

1. Practice Bulletin No. 128. Diagnosis of Abnormal Uterine Bleeding in Reproductive-Aged Women. *Obstet Gynecol*. 2012 Jul;120(1):197-206. doi:10.1097/aog.0b013e318262e320. (July 2012, Reaffirmed 2021)
2. Bazot M, Daraï E. Role of transvaginal sonography and magnetic resonance imaging in the diagnosis of uterine adenomyosis. *Fertility and Sterility*. 2018;109(3):389-397. doi:10.1016/j.fertnstert.2018.01.024
3. Chronic pelvic pain. ACOG Practice Bulletin No. 218. American College of Obstetricians and Gynecologists. *Obstet Gynecol* 2020; Reaffirmed 2023; 135:e98–109. doi:10.1097/aog.0000000000003716
4. Vannuccini S, Luisi S. et al. Role of Medical Therapy in the management of Uterine Adenomyosis. *Fertility and Sterility*. 2018;109(3):398-405.
5. Dessouky R, Gamil SA, Nada MG, Mousa R, Libda Y. Management of Uterine Adenomyosis: current trends and uterine artery embolization as a potential alternative to hysterectomy. *Insights Imaging*. 2019;10(1):48. Published 2019 Apr 27. doi:10.1186/s13244-019-0732-8
6. Vannuccini S, Petraglia F. Recent advances in understanding and managing adenomyosis. *F1000Res*. 2019;8: F1000 Faculty Rev-283. Published 2019 Mar 13. doi:10.12688/f1000research.17242.
7. Diagnosis and treatment of adenomyosis (Ebernella). Shirin Dason, Crystal Chan and Mara Sobel CMAJ February 16, 2021 193 (7) E242; doi: <https://doi.org/10.1503/cmaj.201607>
8. Chapron C, Vannuccini S, Santulli P, et al. Diagnosing adenomyosis: an integrated clinical and imaging approach. *Human Reproduction Update*. 2020;26(3):392-411. doi:10.1093/humupd/dmz049

Adnexal Mass/Ovarian Cysts (PV-5)

Guideline

Suspected Adnexal Mass – Initial Evaluation (PV-5.1)

Simple Cysts (PV-5.2)

Complex Adnexal Masses (PV-5.3)

Screening for Ovarian Cancer/Suspected Ovary Cancer (PV-5.4)

References (PV-5)

Suspected Adnexal Mass – Initial Evaluation (PV-5.1)

PV.MC.0005.1.A

v2.0.2024

- A potential mass is found on exam and/or found incidentally on other imaging
- Transvaginal (TV) ultrasound imaging (CPT® 76830) is the initial study of choice.
 - Pelvic ultrasound (CPT® 76856 or CPT® 76857) can be performed if requested as a complimentary study to the TV ultrasound.
 - Once confirmed, Color Doppler ultrasonography (CPT® 93975 or CPT® 93976) may be useful to evaluate the vascular characteristics of adnexal masses.
- MRI Pelvis without contrast (CPT® 72195), OR without and with contrast (CPT® 72197; CPT® 72195 if pregnant) if ultrasound does not identify the origin of the pelvic mass (adnexal, uterine, or other in etiology).
 - If the mass is unrelated to female pelvic anatomy, see **Abdominal Mass (AB-13)** in the Abdomen Imaging Guidelines.
 - The uterus, tubes, and ovaries arise out of the pelvis and are considered pelvic organs. If the uterus rises out of the pelvic cavity, the imaging field can be determined on scout films. Imaging of the abdomen is not supported for problems suspected to arise from the pelvis.

Background and Supporting Information

- Consultation with or referral to a gynecologic oncologist is recommended for females with an adnexal mass who meet one or more of the following criteria:⁷
 - Postmenopausal with elevated CA-125 level, ultrasound findings suggestive of malignancy, ascites, a nodular or fixed pelvic mass, or evidence of abdominal or distant metastasis.⁷
 - Premenopausal with very elevated CA-125 level, ultrasound findings suggestive of malignancy, ascites, a nodular or fixed pelvic mass, or evidence of abdominal or distant metastasis.⁷
 - Premenopausal or postmenopausal with an elevated score on a formal risk assessment test such as the multivariate index assay, risk of malignancy index, or the Risk of Ovarian Malignancy Algorithm or one of the ultrasound-based scoring systems from the International Ovarian Tumor Analysis group.⁷
- Simple and Complex Adnexal Cysts
 - Simple cysts are smooth walled and clear without debris.
 - Complex cysts can have solid areas or excrescences, and/or debris in them, greater than 3mm irregular septations, mural nodules with Doppler-detected blood flow, and/or free abdominal/pelvic fluid.
- Suspected Adnexal Mass – Tumor Markers

- The adnexa include the ovaries, Fallopian tubes, and ligaments that hold the uterus in place.
- CA-125 is a tumor marker that is useful for the evaluation of adnexal mass:
 - Elevation occurs with both malignant (epithelial cancer) and benign entities (leiomyoma, endometriosis, PID, inflammatory disease such as lupus, and inflammatory bowel disease).
 - Increase in the markers over time occurs with malignancy only
 - Consider tumor markers in individuals with an abnormal ultrasound that is not a simple cyst
- Other markers include Beta hCG, LDH, and AFP (germ cell tumors) and Inhibin A and B (granulosa cell tumor).

Simple Cysts (PV-5.2)

PV.MC.0005.2.A

v2.0.2024

- Simple cysts are smooth, thin walled, anechoic and clear without debris. Simple cysts up to 10 cm in diameter as measured by ultrasound are almost universally benign.
 - Repeat TV ultrasound (CPT® 76830) and/or Pelvic ultrasound (CPT® 76857 or CPT® 76856)
 - Follow up according to the below schedule if ≤10 cm
 - Routine use of 3D rendering (CPT® 76376/CPT® 76377) for evaluation of simple ovarian cysts is not supported.

Simple Cyst Follow-Up

Size	Pre-Menopausal	Post-Menopausal
≤3 cm	<ul style="list-style-type: none"> • None 	<ul style="list-style-type: none"> • None
>3 cm to 5 cm	<ul style="list-style-type: none"> • None 	<ul style="list-style-type: none"> • Follow-up in 12 months with TV ultrasound (CPT® 76830) and/or Pelvic ultrasound (CPT® 76857 or CPT® 76856) <ul style="list-style-type: none"> • If smaller (≥10-15% decrease) no further surveillance. • If stable follow-up TV ultrasound (CPT® 76830) and/or Pelvic ultrasound (CPT® 76857 or CPT® 76856) at 24 months from initial exam • If enlarging (≥10%-15% increase) follow-up TV ultrasound (CPT® 76830) and/or Pelvic ultrasound (CPT® 76857 or CPT® 76856) at 12 and 24 months from initial exam • If there is a change in morphology on follow imaging see Complex Adnexal Masses (PV 5.3)

Size	Pre-Menopausal	Post-Menopausal
>5 cm to ≤10 cm	<ul style="list-style-type: none">Follow up in 8-12 weeks (proliferative phase if possible) TV ultrasound (CPT® 76830) and/or Pelvic ultrasound (CPT® 76857 or CPT® 76856); further follow-up intervals may be adjusted on basis of degree of cyst change	<ul style="list-style-type: none">Follow-up in 3-6 months with TV ultrasound (CPT® 76830) and/or Pelvic ultrasound (CPT® 76857 or CPT® 76856); further follow-up intervals may be adjusted on basis of degree of cyst change.Subsequent follow up with TV ultrasound (CPT® 76830) and/or Pelvic ultrasound (CPT® 76857 or CPT® 76856), annually and if stable for 2 years or decreasing in size, no further imaging follow-up is needed.

Size	Pre-Menopausal	Post-Menopausal
>10 cm	<ul style="list-style-type: none"> • If not excised consider US follow up within 6 months. TV Ultrasound (CPT® 76830) and/or Pelvic ultrasound (CPT® 76857 or CPT® 76856) • If stable follow up Ultrasound can be done at 12 and 24 months from initial exam • If solid component, MRI Pelvis without and with contrast (CPT® 72197) may be approved • If ultrasound equivocal for Simple cyst, MRI Pelvis without and with contrast (CPT® 72197) • If follow up ultrasound imaging shows changing morphology and/or a vascular component then consider MRI Pelvis without and with contrast (CPT® 72197) 	<ul style="list-style-type: none"> • If not excised consider US follow up within 6 months. TV ultrasound (CPT® 76830) and/or Pelvic ultrasound (CPT® 76857 or CPT® 76856) • If stable follow up Ultrasound can be done at 12 and 24 months from initial exam • If solid component, MRI Pelvis without and with contrast (CPT® 72197) may be approved • If ultrasound equivocal for Simple cyst, MRI Pelvis without and with contrast (CPT® 72197) • If follow up ultrasound imaging shows changing morphology and/or a vascular component then consider MRI Pelvis without and with contrast (CPT® 72197)

Complex Adnexal Masses (PV-5.3)

PV.MC.0005.3.A

v2.0.2024

- Ultrasound imaging should provide characteristics of the cyst/mass prior to consideration of advanced imaging.
- Complex cysts found on ultrasound have characteristics that include: solid areas or excrescences, and/or debris, may have greater than 3mm irregular septations, and/or mural nodules with Doppler-detected blood flow, and/or free abdominal/pelvic fluid. Complex cysts have an O-RADS™ score of 2 or higher.
- Routine use of 3D rendering (CPT® 76376/CPT® 76377) for evaluation of complex ovarian cysts is not supported unless otherwise mentioned in the table below.

Follow up Complex Adnexal Masses

Condition	Pre-Menopausal	Post-Menopausal
Typical hemorrhagic cyst < 10 cm (O-RADS™ 2)	<ul style="list-style-type: none"> • If initial ultrasound imaging confirms hemorrhagic cyst ≤5 cm no further imaging is necessary • If initial ultrasound imaging confirms hemorrhagic cyst >5 cm but <10 cm, follow up with Pelvic ultrasound (CPT® 76856 or CPT® 76857) and/or TV ultrasound (CPT® 76830) in 8-12 weeks is indicated. Duplex (Doppler) scan (CPT® 93975 complete; CPT® 93976 limited) may be approved as an add-on to TV ultrasound (CPT® 76830). <ul style="list-style-type: none"> • If follow-up imaging confirms a hemorrhagic cyst that has not completely resolved or has enlarged, an MRI Pelvis without and with contrast (CPT® 72197) can be considered. • If stable follow up TV ultrasound (CPT® 76830) and/or Pelvic ultrasound (CPT® 76857 or CPT® 76856) can be done at 24 months from initial exam 	<ul style="list-style-type: none"> • Early postmenopausal (<5 years) either: <ul style="list-style-type: none"> • follow-up TV ultrasound (CPT® 76830) and/or Pelvic ultrasound (CPT® 76857 or CPT® 76856) in 2-3 months OR • MRI Pelvis without and with contrast (CPT® 72197) • Late postmenopausal (≥ 5 years) hemorrhagic cyst should not occur <ul style="list-style-type: none"> • MRI Pelvis without and with contrast (CPT® 72197)

Condition	Pre-Menopausal	Post-Menopausal
<p>Hemorrhagic cyst $\geq 10\text{cm}$ (O-RADS™ 3)</p>	<ul style="list-style-type: none"> • If initial ultrasound imaging confirms a Typical Hemorrhagic cyst $\geq 10\text{cm}$ <ul style="list-style-type: none"> • If not excised consider TV ultrasound (CPT® 76830) and/or Pelvic ultrasound (CPT® 76857 or CPT® 76856) follow up within 6 months • If stable, follow up Ultrasound can be done at 12 and 24 months from initial exam • If solid component, MRI Pelvis without and with contrast (CPT® 72197) may be approved • If ultrasound equivocal for Hemorrhagic cyst, MRI Pelvis without and with contrast (CPT® 72197) • If follow up ultrasound imaging shows changing morphology and/or a vascular component then consider MRI Pelvis without and with contrast (CPT® 72197) 	<ul style="list-style-type: none"> • MRI Pelvis without and with contrast (CPT® 72197) can be considered
<p>Typical Endometriomas $< 10\text{cm}$ (O-RADS™ 2)</p>	<ul style="list-style-type: none"> • If initial imaging confirms a Typical Endometrioma, follow-up Pelvic ultrasound (CPT® 76856 or CPT® 76857) and/or TV ultrasound (CPT® 76830); duplex (Doppler) scan (CPT® 93975 complete; CPT® 93976 limited) may be approved as an add-on to TV ultrasound (CPT® 76830) <ul style="list-style-type: none"> • If $< 10\text{cm}$ and not surgically excised follow-up TV ultrasound (CPT® 76830) and/or Pelvic ultrasound (CPT® 76857 or CPT® 76856) in 12 months • If stable follow up Ultrasound can be done at 24 months from initial exam • If ultrasound equivocal for Endometriomas, MRI Pelvis without and with contrast (CPT® 72197) • If follow up ultrasound imaging shows changing morphology and/or a vascular component then consider MRI Pelvis without and with contrast (CPT® 72197) 	<ul style="list-style-type: none"> • If initial ultrasound imaging confirms a typical endometrioma $< 10\text{cm}$ then either: <ul style="list-style-type: none"> • Follow-up TV ultrasound (CPT® 76830) and/or Pelvic ultrasound (CPT® 76857 or CPT® 76856) in 2-3 months OR • MRI Pelvis without and with contrast (CPT® 72197)

Condition	Pre-Menopausal	Post-Menopausal
Typical Endometriomas $\geq 10\text{cm}$ (O-RADS™ 3)	<ul style="list-style-type: none">• If initial ultrasound imaging confirms a Typical Endometrioma $\geq 10\text{cm}$<ul style="list-style-type: none">• If not excised consider TV ultrasound (CPT® 76830) and/or Pelvic ultrasound (CPT® 76857 or CPT® 76856) follow up within 6 months• If stable follow up Ultrasound can be done at 12 and 24 months from initial exam• If solid component, MRI Pelvis without and with contrast (CPT® 72197) may be approved• If ultrasound equivocal for Endometrioma, MRI Pelvis without and with contrast (CPT® 72197)• If follow up ultrasound imaging shows changing morphology and/or a vascular component then consider MRI Pelvis without and with contrast (CPT® 72197)	<ul style="list-style-type: none">• MRI Pelvis without and with contrast (CPT® 72197)

Condition	Pre-Menopausal	Post-Menopausal
Typical Dermoid < 10cm (O-RADS™ 2)	<ul style="list-style-type: none"> • If initial features are only suggestive for or if assessment is uncertain follow up Pelvic ultrasound (CPT® 76856 or CPT® 76857) and/or TV ultrasound (CPT® 76830) within 3 months is appropriate • If initial ultrasound imaging confirms a Dermoid, follow-up Pelvic ultrasound (CPT® 76856 or CPT® 76857); and/or TV ultrasound (CPT® 76830); duplex (Doppler) scan (CPT® 93975 complete; CPT® 93976 limited) may be approved as an add-on to TV ultrasound (CPT® 76830). <ul style="list-style-type: none"> • If ≤3 cm, may consider follow-up TV ultrasound (CPT® 76830) and/or Pelvic ultrasound (CPT® 76857 or CPT® 76856) in 12 months <ul style="list-style-type: none"> • If stable follow up Ultrasound can be done at 24 months from initial exam • If >3cm but <10cm, follow-up Ultrasound in 12 months if not surgically excised • If stable follow up Ultrasound can be done at 24 months from initial exam • If ultrasound equivocal for Dermoid, MRI Pelvis without and with contrast (CPT® 72197) • If follow up ultrasound imaging shows changing morphology and/or a vascular component then consider MRI Pelvis without and with contrast (CPT® 72197) 	<ul style="list-style-type: none"> • Same as Pre-Menopausal

Condition	Pre-Menopausal	Post-Menopausal
Typical Dermoid ≥ 10cm (O-RADS™ 3)	<ul style="list-style-type: none"> • If initial ultrasound imaging confirms a Typical Dermoid ≥10cm <ul style="list-style-type: none"> • If not excised consider TV ultrasound (CPT® 76830) and/or Pelvic ultrasound (CPT® 76857 or CPT® 76856) follow up within 6 months • If stable follow up Ultrasound can be done at 12 and 24 months from initial exam • If solid component, MRI Pelvis without and with contrast (CPT® 72197) may be approved • If ultrasound equivocal for Dermoid, MRI Pelvis without and with contrast (CPT® 72197) • If follow up ultrasound imaging shows changing morphology and/or a vascular component then consider MRI Pelvis without and with contrast (CPT® 72197) 	<ul style="list-style-type: none"> • Same as Pre-Menopausal
Typical benign extraovarian lesions Hydrosalpinges (Hydrosalpinx) or Peritoneal cysts (ORADS™ 2)	<ul style="list-style-type: none"> • If initial imaging confirms hydrosalpinx or peritoneal cysts, follow up imaging is not indicated 	<ul style="list-style-type: none"> • If initial imaging confirms hydrosalpinx or peritoneal cysts, follow up imaging is not indicated

Complex and/or solid adnexal mass incompletely evaluated by ultrasound

- Generally a repeat ultrasound is recommended (see table above for appropriate time intervals): TV ultrasound (CPT® 76830) and/or Pelvic ultrasound (CPT® 76857 or CPT® 76856)
- MRI Pelvis without and with contrast (CPT® 72197, CPT® 72195 if pregnant) one time:
 - To follow masses when they cannot be optimally visualized by ultrasound (e.g. suboptimal sonography due to large mass or obese individual)
 - Unexplained change of appearance during ultrasound follow-up
 - Other Individual-driven indications (e.g. the application of established risk prediction models (e.g., family history of ovarian cancer), correlation with abnormal serum biomarkers, and/or pelvic symptoms)
 - Differentiate the origin of pelvic masses that are not clearly of ovarian origin

- O-RADS™ score of 3 with a solid component
- O-RADS™ score of 4 or 5
- Concern for metastatic ovarian malignancy, see **Ovarian Cancer (ONC-21)** in the Oncology Imaging Guidelines

Background and Supporting Information

O-RADS™ Classification

O-RADS	
O-RADS™ 0	Incomplete Evaluation
O-RADS™ 1	Normal Ovary <ul style="list-style-type: none"> No ovarian lesion Physiologic cyst: follicle ≤3cm or corpus luteum typically ≤3cm
O-RADS™ 2	Almost Certainly Benign <ul style="list-style-type: none"> Simple cyst less than 10 cm Bilocular, smooth cyst Unilocular, smooth, non-simple cysts (internal echos and/or incomplete septations) Typical benign ovarian lesions <10cm (hemorrhagic cyst, dermoid cyst, endometrioma) Typical benign extraovarian lesions (paraovarian cyst, peritoneal inclusion cysts, hydrosalpinx)
O-RADS™ 3	Low Risk <ul style="list-style-type: none"> Typical benign ovarian lesions ≥10cm Uni- or bilocular cyst, smooth, ≥10cm Unilocular cyst, irregular, any size Multilocular cyst, smooth, <10cm, Color Score (CS) <4 Solid lesion, ± shadowing, smooth, any size, CS =1 Solid lesion, shadowing, smooth, any size, CS 2-3

O-RADS	
ORADS™ 4	<p>Intermediate Risk</p> <ul style="list-style-type: none"> • Bilocular cysts without solid component(s), Irregular, any size, any color score • Multilocular cysts without solid component(s) <ul style="list-style-type: none"> • Smooth, 10 cm, CS <4 • Smooth, any size, CS 4 • Irregular, any size, any CS • Unilocular cyst with solid component(s) <ul style="list-style-type: none"> • <4 papillary projections or any solid component(s) not considered a papillary projection, any size • Bi- or multilocular cyst with solid component(s), any size, CS 1-2 • Solid lesion, non-shadowing, smooth, any size, CS 2-3
ORADS™ 5	<p>High Risk</p> <ul style="list-style-type: none"> • Unilocular cyst, ≥4 papillary projections, any size, and CS • Bi- or multilocular cyst with solid component(s), any size, CS 3-4 • Solid lesion, ± shadowing, smooth, any size, CS 4 • Solid lesion, irregular, any size, any CS • Ascites and/or peritoneal nodules

Pre-Menopausal – see table above

- For females of reproductive age (Pre-Menopausal), evaluation may include a pregnancy test (a quantitative hCG may be necessary if an ectopic pregnancy is suspected), CBC, serial hematocrit measurements, and appropriate cultures.
- Symptomatic individuals often require immediate interventions (antibiotics, surgery, and/or expectant management).
- Ultrasound characteristics usually suggest the diagnosis (ectopic pregnancy, functional cysts, tubo-ovarian abscess (See **Pelvic Inflammatory Disease (PV-7.1)**), hydrosalpinx, dermoid, endometrioma, hemorrhagic cyst and pedunculated fibroids (See **Leiomyomata/Uterine Fibroids (PV-12.1)**) and direct the treatment.

- An ovarian mass suspicious for metastatic disease (e.g. from breast, uterine, colorectal or gastric cancer) should be evaluated based on the appropriate Oncology Imaging Guidelines.

Post-Menopausal – see table above

- For post-menopausal females, most pelvic complex cysts or solid masses should be evaluated for surgical intervention and have tumor markers (i.e. CA-125) measured.
- Some females for whom the usual management of a pelvic mass would include surgery may be at increased risk for perioperative morbidity and mortality. In such cases, repeat imaging may be a safer alternative than immediate surgery, although the frequency of follow-up imaging has not been determined.
- An ovarian mass suspicious for metastatic disease (e.g. from breast, uterine, colorectal or gastric cancer) should be evaluated based on the appropriate Oncology Imaging Guidelines.

Screening for Ovarian Cancer/Suspected Ovary Cancer (PV- 5.4)

PV.MC.0005.4.A
v2.0.2024

- See **Ovarian Cancer (ONC-21)** in the Oncology Imaging Guidelines

References (PV-5)

v2.0.2024

1. Sakhel K, Benson CB, Platt LD, Goldstein SR, Benacerraf BR. Begin With the Basics. *Journal of Ultrasound in Medicine*. 2013;32(3):381-388. doi:10.7863/jum.2013.32.3.381
2. Benacerraf BR, Abuhamad AZ, Bromley B, et al. Consider ultrasound first for imaging the female pelvis. *American Journal of Obstetrics and Gynecology*. 2015;212(4):450-455. doi:10.1016/j.ajog.2015.02.015
3. Practice Bulletin No. 174 Evaluation and Management of Adnexal masses. *Obstetrics & Gynecology*. 2016; Reaffirmed 2021.128(5):1193-1195. doi:10.1097/aog.0000000000001763
4. Alcázar JL, Guerriero S, Laparte C, Ajossa S, Jurado M. Contribution of power Doppler blood flow mapping to gray-scale ultrasound for predicting malignancy of adnexal masses in symptomatic and asymptomatic women. *European Journal of Obstetrics & Gynecology and Reproductive Biology*. 2011;155(1):99-105. doi:10.1016/j.ejogrb.2010.11.010
5. Guerriero S, Alcazar JL, Ajossa S, et al. Transvaginal Color Doppler Imaging in the Detection of Ovarian Cancer in a Large Study Population. *International Journal of Gynecological Cancer*. 2010;20(5):781-786. doi:10.1111/igc.0b013e3181de9481
6. Andreotti RF, Timmerman D, Benacerraf BR, et al. Ovarian-Adnexal Reporting Lexicon for Ultrasound: A White Paper of the ACR Ovarian-Adnexal Reporting and Data System Committee. *Journal of the American College of Radiology*. 2018;15(10):1415-1429. doi:10.1016/j.jacr.2018.07.004
7. Andreotti RF, Timmerman D, Strachowski LM, et al. O-RADS US Risk Stratification and Management System: A Consensus Guideline from the ACR Ovarian-Adnexal Reporting and Data System Committee. *Radiology*. 2020;294(1):168-185. doi:10.1148/radiol.2019191150
8. Levine D, Patel MD, Suh-Burgmann EJ, et al. Simple Adnexal Cysts: SRU Consensus Conference Update on Follow-up and Reporting. *Radiology*. 2019;293(2):359-371. doi:10.1148/radiol.2019191354
9. Atri M, Alabousi A, Reinhold C, et al. ACR Appropriateness Criteria® Clinically Suspected Adnexal Mass, No Acute Symptoms. *Journal of the American College of Radiology*. 2019;16(5). doi:10.1016/j.jacr.2019.02.011
10. Wu M-H, Cheng Y-C, Chang C-H, Ko H-C, Chang F-M. Three-dimensional Ultrasound in Evaluation of the Ovary. *Journal of Medical Ultrasound*. 2012;20(3):136-141. doi:10.1016/j.jmu.2012.07.001
11. Sladkevicius P, Jokubkiene L, Timmerman D, et al. Vessel morphology depicted by three-dimensional power Doppler ultrasound as second-stage test in adnexal tumors that are difficult to classify: prospective diagnostic accuracy study. *Ultrasound in Obstetrics & Gynecology*. 2021;57(2):324-334. doi:10.1002/uog.22191
12. Dirrichs T, Bauerschlag D, Maass N, Kuhl CK, Schrading S. Impact of multiparametric MRI (mMRI) on the therapeutic management of adnexal masses detected with transvaginal ultrasound (TVUS): an interdisciplinary management approach. *Acad Radiol*. 2022;29(2):183-97. doi:10.1016/j.acra.2020.11.016
13. American College of Radiology Committee on O-RADS™ (Ovarian and Adnexal). O-RADS MRI Risk Score Governing Concepts. Available at: <https://www.acr.org/-/media/ACR/Files/RADS/O-RADS/O-RADS-MR-Risk-Stratification-System-Table-Updated-May-2023.pdf>. Accessed on June 01, 2023.

Endometriosis (PV-6)

Guideline

Endometriosis (PV-6.1)

References (PV-6)

Endometriosis (PV-6.1)

PV.EM.0006.1.A

v2.0.2024

- TV ultrasound (CPT® 76830) and/or Pelvic ultrasound (CPT® 76856 or CPT® 76857) is the first line diagnostic exam for suspected endometriosis.
- MRI Pelvis without contrast (CPT® 72195) or without and with contrast (CPT® 72197):
 - Prior to planned surgery for suspected deep pelvic endometriosis such as rectovaginal endometriosis, deeply infiltrative bladder endometriosis, and cul-de-sac obliteration.
 - To characterize complex adnexal masses as endometrioma if ultrasound equivocal See **Complex Adnexal Masses (PV-5.3)**
 - If known or suspected thoracic endometriosis, see **Pneumothorax/Hemothorax (CH-19.1)** in the Chest Imaging Guidelines.

References (PV-6)

v2.0.2024

1. Practice Bulletin No. 114: Management of Endometriosis. *Obstetrics & Gynecology*. 2010;116(1):223-236. doi:10.1097/aog.0b013e3181e8b073. (July 2010. Reaffirmed 2022)
2. Hudelist G, English J, Thomas AE, Tinelli A, Singer CF, Keckstein J. Diagnostic accuracy of transvaginal ultrasound for non-invasive diagnosis of bowel endometriosis: systematic review and meta-analysis. *Ultrasound in Obstetrics & Gynecology*. 2011;37(3):257-263. doi:10.1002/uog.8858
3. Macario S, Chassang M, Novellas S, et al. The Value of Pelvic MRI in the Diagnosis of Posterior Cul-De-Sac Obliteration in Cases of Deep Pelvic Endometriosis. *American Journal of Roentgenology*. 2012;199(6):1410-1415. doi:10.2214/ajr.11.7898
4. ACOG Committee Opinion No. 760 Summary: Dysmenorrhea and Endometriosis in the Adolescent. *Obstetrics & Gynecology*. 2018;132(6):1517-1518. doi:10.1097/aog.0000000000002981. Reaffirmed 2021
5. Guerriero S, Saba L, Pascual MA, et al. Transvaginal ultrasound vs magnetic resonance imaging for diagnosing deep infiltrating endometriosis: systematic review and meta-analysis. *Ultrasound in Obstetrics & Gynecology*. 2018;51(5):586-595. doi:10.1002/uog.18961
6. Chronic pelvic pain. ACOG Practice Bulletin No. 218. American College of Obstetricians and Gynecologists. *Obstet Gynecol* 2020; Reaffirmed 2023;135:e98–109
7. Goncalves MO, Siufi Neto J, Andres MP, Siufi D, de Mattos LA, Abrao MS. Systematic evaluation of endometriosis by transvaginal ultrasound can accurately replace diagnostic laparoscopy, mainly for deep and ovarian endometriosis. *Human Reproduction*. 2021;36(6):1492-1500. doi:10.1093/humrep/deab085
8. Nisenblat V, Bossuyt PMM, Farquhar C, Johnson N, Hull ML. Imaging modalities for the non-invasive diagnosis of endometriosis. *The Cochrane Database of Systematic Reviews*. 2016;2:CD009591. doi:10.1002/14651858.CD009591.pub2
9. Siegelman ES, Oliver ER. MR Imaging of Endometriosis: Ten Imaging Pearls. *RadioGraphics*. 2012;32(6):1675-1691. doi:10.1148/rg.326125518

Pelvic Inflammatory Disease (PID) (PV-7)

Guideline

Pelvic Inflammatory Disease (PV-7.1)

References (PV-7)

Pelvic Inflammatory Disease (PV-7.1)

PV.PI.0007.1.A

v2.0.2024

- Clinical examination alone is usually sufficient for confirming the diagnosis of pelvic inflammatory disease. See **Pelvic Pain/Dyspareunia, Female (PV-11.1)** if other causes of pelvic pain are suspected.
- Pelvic ultrasound (CPT® 76856 or CPT® 76857) and/or TV ultrasound (CPT® 76830) is the initial study for imaging of suspected pelvic inflammatory disease (PID) if diagnosis is uncertain following bimanual pelvic examination and laboratory testing (such as WBC, CRP and ESR, Microscopy of the vaginal secretions, and testing for Neisseria gonorrhoeae and Chlamydia trachomatis) OR for suspected Tubo-Ovarian Abscess (TOA). Color Doppler ultrasonography (CPT® 93975 or CPT® 93976) may be added.
- CT Pelvis with contrast (CPT® 72193) or MRI Pelvis with and without contrast (CPT® 72197):
 - If diagnosis is uncertain following examination, laboratory testing and ultrasound
 - Ultrasound shows extensive abscess formation and further imaging is needed for treatment planning
 - Suspected TOA with inconclusive ultrasound
- If suspected abdominal abscess see **Abdominal Sepsis (Suspected Abdominal Abscess) (AB-3.1)** in the Abdomen Imaging Guidelines.

Background and Supporting Information

PID may be clinically suspected based on findings of abdominal and/or pelvic pain, cervical or vaginal mucopurulent discharge, dyspareunia, inter-menstrual and/or post coital bleeding, fever, low back pain, nausea/vomiting, urinary frequency, cervical motion tenderness, uterine and/or adnexal tenderness on exam.

Laboratory findings may include elevated erythrocyte sedimentation rate, elevated C-reactive protein, lab documentation of cervical infection with N. gonorrhoeae or C. trachomatis, WBC on saline microscopy of vaginal fluid, and/or endometrial biopsy with endometritis.

References (PV-7)

v2.0.2024

1. Liu B, Donovan B, Hocking JS, Knox J, Silver B, Guy R. Improving Adherence to Guidelines for the Diagnosis and Management of Pelvic Inflammatory Disease: A Systematic Review. *Infectious Diseases in Obstetrics and Gynecology*. 2012;2012:1-6. doi:10.1155/2012/325108
2. Jaiyeoba O, Soper DE. A Practical Approach to the Diagnosis of Pelvic Inflammatory Disease. *Infectious Diseases in Obstetrics and Gynecology*. 2011;2011:1-6. doi:10.1155/2011/753037
3. Workowski KA. Centers for Disease Control and Prevention Sexually Transmitted Diseases Treatment Guidelines. *Clinical Infectious Diseases*. 2015;61(suppl 8). doi:10.1093/cid/civ771
4. Practice Bulletin No. 174. Evaluation and Management of Adnexal Masses. American College of Obstetricians and Gynecologists. *Obstet Gynecol* 2016; Reaffirmed 2021.128:e210–26. doi:10.1097/aog.0000000000001768.
5. Prevention of Infection After Gynecologic Procedures. *Obstetrics & Gynecology*. 2018;131(6):1177-1179. doi:10.1097/aog.0000000000002672
6. Revzin MV, Mathur M, Dave HB, Macer ML, Spektor M. Pelvic Inflammatory Disease: Multimodality Imaging Approach with Clinical-Pathologic Correlation. *RadioGraphics*. 2016;36(5):1579-1596. doi:10.1148/rg.2016150202
7. ACR Appropriateness Criteria® Acute Pelvic Pain in the Reproductive Age Group, *Ultrasound Quarterly*: June 2016 - Volume 32 - Issue 2 - p 108-115 doi: 10.1097/RUQ.0000000000000200
8. Maturen KE, Akin EA, Dassel M, et al. ACR Appropriateness Criteria® Postmenopausal Subacute or Chronic Pelvic Pain. *Journal of the American College of Radiology*. 2018;15(11):S365-S372. doi:10.1016/j.jacr.2018.09.023
9. Henrichsen TL, Maturen KE, Robbins JB, et al. ACR Appropriateness Criteria® Postmenopausal Acute Pelvic Pain. *Journal of the American College of Radiology*. 2021;18(5):S119-S125. doi:10.1016/j.jacr.2021.02.003
10. Polena V, Huchon C, Varas Ramos C, Rouzier R, Dumont A, Fauconnier A. Non-invasive tools for the diagnosis of potentially life-threatening gynaecological emergencies: a systematic review. *PLoS One*. 2015;10(2):e0114189. doi: 10.1371/journal.pone.0114189.

Polycystic Ovary Syndrome (PV-8)

Guideline

Polycystic Ovary Syndrome (PCOS) (PV-8.1)
References (PV-8)

Polycystic Ovary Syndrome (PCOS) (PV-8.1)

PV.PC.0008.1.A

v2.0.2024

- Pelvic ultrasound (CPT® 76856 or CPT® 76857) and/or TV ultrasound (CPT® 76830) is indicated when history, exam, and/or laboratory findings are suspicious for PCOS.
- Laboratory testing to be done prior to advanced imaging: Virilizing hormone levels (Testosterone and DHEAS). Disorders that mimic the clinical features of Polycystic ovary syndrome (PCOS) should be excluded by measuring: TSH, Prolactin, and 17-OHP (hydroxyprogesterone) levels. Others to consider based on the clinical presentation: Cortisol levels, ACTH, dexamethasone suppression testing, IGF-1, FSH, LH, estradiol.
- If elevated serum levels of androgens are found and an adrenal etiology is suspected - see **Adrenal Cortical Lesions (AB-16.1)** in the Abdomen Imaging Guidelines.

Background and Supporting Information

- Polycystic ovary syndrome is the most common hormonal disorder among females of reproductive age, and is one of the leading causes of infertility.
- Diagnostic criteria of polycystic ovary syndrome (Two of the following three criteria are required):
 - Oligo/anovulation
 - Hyperandrogenism
 - Clinical (hirsutism or less commonly male pattern alopecia) or
 - Biochemical (raised FAI (free androgen index) or free testosterone)
 - Polycystic ovaries on ultrasound
 - Defined as an ovary containing 12 or more follicles (or 25 or more follicles using new ultrasound technology) measuring 2 to 9 mm in diameter or an ovary that has a volume of greater than 10 mL on ultrasonography. A single ovary meeting either or both of these definitions is sufficient for diagnosis of polycystic ovaries.
- Clinical Features of PCOS
 - Hirsutism and male pattern balding consistent with hyperandrogenism
 - Irregular or absent menstrual cycles
 - Subfertility or infertility
 - Psychological symptoms – anxiety, depression, psychosexual dysfunction, eating disorders
 - Metabolic features – obesity, dyslipidaemia, diabetes

References (PV-8)

v2.0.2024

1. ACOG Practice Bulletin 194. Polycystic Ovary Syndrome. *Obstetrics and Gynecology*. 2018 Reaffirmed 2020. 131(6):e157-e171. doi: 10.1097/AOG.0000000000002656
2. Dumesic DA, Oberfield SE, Stener-Victorin E, Marshall JC, Laven JS, Legro RS. Scientific Statement on the Diagnostic Criteria, Epidemiology, Pathophysiology, and Molecular Genetics of Polycystic Ovary Syndrome. *Endocrine Reviews*. 2015;36(5):487-525. doi:10.1210/er.2015-1018
3. Teede HJ, Misso ML, Costello MF, et al. Erratum. Recommendations from the international evidence-based guideline for the assessment and management of polycystic ovary syndrome. *Human Reproduction*. 2018;34(2):388-388. doi:10.1093/humrep/dey363
4. Martin KA, Anderson RR, Chang RJ, et al. Evaluation and Treatment of Hirsutism in Premenopausal Women: An Endocrine Society*Clinical Practice Guideline. *The Journal of Clinical Endocrinology & Metabolism*. 2018;103(4):1233-1257. doi:10.1210/jc.2018-00241
5. Mayo-Smith WW, Song JH, Boland GL, et al. Management of Incidental Adrenal Masses: A White Paper of the ACR Incidental Findings Committee. *Journal of the American College of Radiology*. 2017;14(8):1038-1044. doi:10.1016/j.jacr.2017.05.001.
6. Rotterdam ESHRE/ASRM-Sponsored PCOS Consensus Workshop Group. Revised 2003 consensus on diagnostic criteria and long-term health risks related to polycystic ovary syndrome. *Fertil Steril*. 2004;81(1):19–25.
7. Obesity in adolescents. Committee Opinion No. 714. *Obstetrics & Gynecology*. 2017. Reaffirmed 2021;130(3):e127-e140. doi:10.1097/aog.0000000000002297

Initial Infertility Evaluation, Female (PV-9)

Guideline

Initial Infertility Evaluation, Female (PV-9.1)

References (PV-9)

Initial Infertility Evaluation, Female (PV-9.1)

PV.IE.0009.1.U

v2.0.2024

This guideline is not intended for fertility treatment follow-up and management. See individual fertility coverage policy for imaging during active fertility treatment.

- A one time Pelvic ultrasound (CPT® 76856 or CPT® 76857) and/or TV ultrasound (CPT® 76830) for initial infertility workup.¹
 - Repeat ultrasounds or serial ultrasounds are not indicated for initial infertility workup
- To evaluate for tubal patency:
 - Hysterosalpingography (HSG) (CPT® 74740) **or** Sonohysterosalpingography (CPT® 76831)
- If ultrasound is indeterminate or there is clinical suspicion for intra-cavitary lesion (such as polyp or fibroid), hydrosalpinx, uterine synechia, adenomyosis or uterine anomalies:
 - 3D US imaging (add-on CPT® 76376 or CPT® 76377)
 - US Color Doppler (CPT® 93975 or CPT® 93976)

References (PV-9)

v2.0.2024

1. Vickramarajah S, Stewart V, Ree KV, Hemingway AP, Crofton ME, Bharwani N. Subfertility: What the Radiologist Needs to Know. *RadioGraphics*. 2017;37(5):1587-1602. doi:10.1148/rg.2017170053
2. AIUM Practice Parameter for Ultrasonography in Reproductive Medicine. 2017 American Institute of Ultrasound in Medicine
3. B Benacerraf, T Shipp, B Bromley. Which Patients Benefit from a 3D Reconstructed Coronal View of the Uterus Added to Standard Routine 2D Pelvic Sonography? *AJR*: 190, March 2008
4. Pleş L, Alexandrescu C, Ionescu CA, Arvătescu CA, Vladareanu S, Moga MA. Three-dimensional scan of the uterine cavity of infertile women before assisted reproductive technology use. *Medicine (Baltimore)*. 2018;97(41):e12764. doi:10.1097/MD.00000000000012764
5. Groszmann YS, Benacerraf BR. Complete evaluation of anatomy and morphology of the infertile patient in a single visit; the modern infertility pelvic ultrasound examination. *Fertility and sterility*. 2016 Jun 1;105(6):1381-93
6. Practice Committee of the American Society for Reproductive Medicine. Diagnostic evaluation of the infertile female: a committee opinion. *Fertility and Sterility*. 2015;103(6):e44-e50. doi:10.1016/j.fertnstert.2015.03.019.
7. Cil AP, Tulunay G, Kose MF, Haberal A. Power Doppler properties of endometrial polyps and submucosal fibroids: a preliminary observational study in women with known intracavitary lesions. *Ultrasound in Obstetrics and Gynecology*. 2010;35(2):233-237. doi:10.1002/uog.7470
8. Infertility workup for the women's health specialist. ACOG Committee Opinion No. 781. American College of Obstetricians and Gynecologists. *Obstetrics & Gynecol*. 2019;133(6):e377-e384. Reaffirmed 2023

Intrauterine Device (IUD) and Tubal Occlusion (PV-10)

Guideline

Intrauterine Device (PV-10.1)

Hysteroscopically Placed Tubal Occlusion Device (PV-10.2)

References (PV-10)

Intrauterine Device (PV-10.1)

PV.ID.0010.1.A

v2.0.2024

- Imaging to evaluate position prior to, immediately after and, for example, 6 weeks after IUD insertion is not indicated
- Pelvic ultrasound (CPT® 76856 or CPT® 76857) and/or TV ultrasound (CPT® 76830) if:
 - Abnormal pelvic exam prior to IUD insertion, such as pelvic mass, irregularly shaped uterus, or enlarged uterus
 - Suspected IUD complication:
 - Abnormal IUD position
 - Uterine perforation
 - Severe pain
 - Excessive bleeding
 - Suspected infection
- “Lost” IUD inability to palpate IUD string on pelvic exam, and/or see IUD on speculum exam:
 - Desires continuation of IUD for contraception,
 - unable to visualize with cytobrush sweep of the cervix:
 - TV ultrasound (CPT® 76830) with or without 3-D Rendering (CPT® 76377 or CPT® 76376)
 - If TV ultrasound is negative or non-diagnostic, Pelvic ultrasound (CPT® 76856 or CPT® 76857):
 - If Pelvic ultrasound is negative or non-diagnostic, plain x-ray should be performed if pregnancy test is negative.
 - CT Pelvis without contrast (CPT® 72192) or CT Abdomen and Pelvis without contrast (CPT® 74176) or MRI Pelvis without contrast (CPT® 72195) when both ultrasound and plain x-ray are negative or non-diagnostic.
 - Desires removal of IUD
 - If unable to palpate, see, or retrieve IUD string on pelvic exam and/or speculum exam
 - If failed attempt to retrieve IUD with instrumentation of external cervical os
 - TV ultrasound (CPT® 76830); 3-D Rendering (CPT® 76377 or CPT® 76376) may be an add-on
 - If Pelvic ultrasound is negative or non-diagnostic, plain x-ray should be performed if pregnancy test is negative
 - CT Pelvis without contrast (CPT® 72192) or CT Abdomen and Pelvis without contrast (CPT® 74176) or MRI Pelvis without contrast (CPT®

72195) when both ultrasound and plain x-ray are equivocal or non-diagnostic

- If pregnancy test is positive:
 - The use of gynecology CPT codes for pregnant females is not supported. Therefore, transvaginal ultrasound (CPT® 76830) and pelvic ultrasound (CPT® 76856 or CPT® 76857) are not supported for those with a positive pregnancy test or known pregnancy. If a pregnancy test is positive, then obstetrical CPT codes are indicated (General Guidelines (PV-1.0))

Hysteroscopically Placed Tubal Occlusion Device (PV-10.2)

PV.ID.0010.2.A

v2.0.2024

- TV ultrasound (CPT® 76830) and/or Pelvic ultrasound (CPT® 76856 or CPT® 76857) if:
 - Suspected complication of hysteroscopically placed tubal occlusion device:
 - Abnormal tubal occlusion device position
 - Uterine perforation
 - Severe pain
 - Excessive bleeding

Background and Supporting Information

- As of 2019, neither the Essure nor the Adiana tubal occlusion device is in production

References (PV-10)

v2.0.2024

1. Boortz HE, Margolis DJA, Ragavendra N, Patel MK, Kadell BM. Migration of Intrauterine Devices: Radiologic Findings and Implications for Patient Care. *RadioGraphics*. 2012;32(2):335-352. doi:10.1148/rg.322115068
2. Prabhakaran S, Chuang A. In-office retrieval of intrauterine contraceptive devices with missing strings. *Contraception*. 2011;83(2):102-106. doi:10.1016/j.contraception.2010.07.004
3. Sakhel K, Benson CB, Platt LD, Goldstein SR, Benacerraf BR. Begin With the Basics. *Journal of Ultrasound in Medicine*. 2013;32(3):381-388. doi:10.7863/jum.2013.32.3.381
4. Benacerraf BR, Abuhamad AZ, Bromley B, et al. Consider ultrasound first for imaging the female pelvis. *American Journal of Obstetrics and Gynecology*. 2015;212(4):450-455. doi:10.1016/j.ajog.2015.02.015
5. Practice Bulletin No. 186: Long-Acting Reversible Contraception: Implants and Intrauterine Devices. *Obstet Gynecol*. 2017 Nov 2017 130(5):251-269. Reaffirmed 2021. doi: 10.1097/AOG.0000000000002394.
6. Nowitzki KM, Hoimes ML, Chen B, Zheng LZ, Kim YH. Ultrasonography of intrauterine devices. *Ultrasonography*. 2015;34(3):183-194. doi:10.14366/usg.15010
7. Guelfguat M, Gruenberg TR, Dipocce J, Hochsztein JG. Imaging of Mechanical Tubal Occlusion Devices and Potential Complications. *RadioGraphics*. 2012;32(6):1659-1673. doi:10.1148/rg.326125501
8. Simpson W, Beitia L. Multimodality imaging of the Essure tubal occlusion device. *Clinical Radiology*. 2012;67(12). doi:10.1016/j.crad.2012.08.013
9. Wong L, White N, Ramkrishna J, Júnior EA, Meagher S, Costa FDS. Three-dimensional imaging of the uterus: The value of the coronal plane. *World Journal of Radiology*. 2015;7(12):484. doi:10.4329/wjr.v7.i12.484
10. Rowlands S, Oloto E, Horwell DH. Intrauterine devices and risk of uterine perforation: current perspectives. *Open Access J Contracept*. 2016;7:19–32. Published 2016 Mar 16. doi:10.2147/OAJC.S85546

Pelvic Pain/Dyspareunia, Female (PV-11)

Guideline

Pelvic Pain/Dyspareunia, Female (PV-11.1)

References (PV-11)

Pelvic Pain/Dyspareunia, Female (PV-11.1)

PV.PD.0011.1.U

v2.0.2024

- Often, the history, physical examination, and laboratory data can guide subsequent workup in individuals presenting with pelvic pain. When possible, use the more specific guideline, depending on clinical presentation and the differential diagnosis. (i.e.-endometriosis **Endometriosis (PV-6.1)**, adnexal mass **Adnexal Mass/Ovarian Cysts (PV-5)**, etc.).
- If there is clinical concern that a non gynecological condition is the cause of pelvic pain, such as a vascular, urological or gastrointestinal etiology, see the applicable guideline section(s).
- Premenopausal pelvic pain - Pregnancy test should be done prior to imaging.
 - If pregnancy test is positive, see the applicable obstetrical imaging policy.
- If pregnancy test is negative or postmenopausal:
 - Ultrasound – transvaginal (CPT® 76830) and/or pelvic (CPT® 76856 or CPT® 76857)
 - Duplex Doppler (CPT® 93975 or CPT® 93976) can be added if there is an ovarian mass and/or suspicion of ovarian torsion on the initial ultrasound.
 - Duplex Doppler (CPT® 93975 or CPT® 93976) for chronic pelvic pain (pelvic pain for 6 months or greater)
- Further imaging as per appropriate section of guidelines (i.e.-ovarian mass/torsion **Adnexal Mass/Ovarian Cysts (PV-5)**, PID **Pelvic Inflammatory Disease (PV-7.1)**, etc.)
- If initial ultrasound is normal, further evaluation depending on the clinical suspicion may include urological work-up, gastroenterology work-up, laparoscopic evaluation(s)
- If the initial ultrasound is equivocal for unexplained chronic pelvic pain (pelvic pain for 6 months or greater) and/or above evaluations are non-diagnostic:
 - CT Pelvis with contrast (CPT® 72193) OR
 - MRI Pelvis without contrast or with and without contrast (CPT® 72195 or CPT® 72197)
- Pelvic Pain/Hip Pain - Rule Out Piriformis Syndrome
 - See **Focal Neuropathy (PN-2.1)** in the Peripheral Nerve Disorders Imaging Guidelines
 - See **Hip(MS-24)** in the Musculoskeletal Imaging Guidelines
- Work-up of interstitial cystitis/bladder pain syndrome (IC/BPS) may include history, physical exam, laboratory exam (urinalysis and urine culture), cystoscopy, and measurement of post void residual urine by bladder catheterization.

- Pelvic ultrasound (CPT® 76856 or CPT® 76857) and/or TV ultrasound (CPT® 76830).
 - CT Pelvis with contrast (CPT® 72193) if ultrasound is equivocal for complicated interstitial cystitis/bladder pain syndrome (when ordered by specialist or any provider in consultation with a specialist).
- Proctalgia Syndromes
 - Prior to advanced imaging, the evaluation of rectal/perineal pain should include:
 - Digital rectal examination (assess for mass, fissures, hemorrhoids, etc.)
 - Pelvic examination in females to exclude PID
 - Recent flexible sigmoidoscopy or colonoscopy subsequent to the start of reported symptoms to exclude inflammatory conditions or malignancy.
 - Endoanal ultrasound (CPT® 76872), MRI Pelvis with and without contrast (CPT® 72197), or CT Pelvis with contrast (CPT® 72193) are appropriate after the above studies have been performed or if laboratory or clinical information suggest infection, abscess, or inflammation
 - MRI (MRI Pelvis without contrast CPT® 72195) for Defecography is considered investigational/experimental by UHC.

Background and Supporting Information

- Interstitial Cystitis/Bladder Pain Syndrome (IC/BPS) has an unpleasant sensation (pain, pressure, discomfort), perceived to be related to the urinary bladder. It is associated with lower urinary tract symptoms of more than six weeks duration, in the absence of infection or other identifiable causes.
- Proctalgia syndromes are characterized by recurrent episodes of rectal/perineal pain, and may be due to sustained contractions of the pelvic floor musculature.

References (PV-11)

v2.0.2024

1. Hanno PM, Erickson D, Moldwin R, Faraday MM. Diagnosis and Treatment of Interstitial Cystitis/Bladder Pain Syndrome: AUA Guideline Amendment. *Journal of Urology*. 2015;193(5):1545-1553. doi:10.1016/j.juro.2015.01.086
2. Hanno PM, Burks DA, Clemens JQ, et al. AUA Guideline for the Diagnosis and Treatment of Interstitial Cystitis/Bladder Pain Syndrome. *Journal of Urology*. 2011;185(6):2162-2170. doi:10.1016/j.juro.2011.03.064
3. Steege JF, Siedhoff MT. Chronic Pelvic Pain. *Obstetrics & Gynecology*. 2014;124(3):616-629. doi:10.1097/aog.0000000000000417
4. Wald A, Bharucha AE, Cosman BC, Whitehead WE. ACG Clinical Guideline: Management of Benign Anorectal Disorders. *The American Journal of Gastroenterology*. 2014;109(8):1141-1157. doi:10.1038/ajg.2014.190
5. Practice Bulletin No. 114: Management of Endometriosis. *Obstetrics & Gynecology*. July 2010;116(1):223-236. Reaffirmed 2020. doi:10.1097/aog.0b013e3181e8b073
6. Practice Bulletin No. 213: Female Sexual Dysfunction. *Obstetrics & Gynecology*. 2019 July; Reaffirmed 2022; (134):1-18.
7. Practice Bulletin No. 218. Chronic pelvic pain. *Obstetrics & Gynecology*. 2020; Reaffirmed 2023;135(3). doi:10.1097/aog.00000000000003716
8. Kraemer S, Watson V, Peters KM. The Evaluation and Management of Interstitial Cystitis/Bladder Pain Syndrome. *EMJ Urol* 2019;7(1):75-82
9. Maturen KE, Akin EA, Dassel M, et al. ACR Appropriateness Criteria® Postmenopausal Subacute or Chronic Pelvic Pain. *Journal of the American College of Radiology*. 2018;15(11):S365-S372. doi:10.1016/j.jacr.2018.09.023
10. Henrichsen TL, Maturen KE, Robbins JB, et al. ACR Appropriateness Criteria® Postmenopausal Acute Pelvic Pain. *Journal of the American College of Radiology*. 2021;18(5):S119-S125. doi:10.1016/j.jacr.2021.02.003.
11. ACR Appropriateness Criteria® Acute Pelvic Pain in the Reproductive Age Group. *Ultrasound Quarterly*. 2016 - Volume 32 - Issue 2 - p 108-115 doi: 10.1097/RUQ.0000000000000200

Leiomyoma/Uterine Fibroids (PV-12)

Guideline

Leiomyoma/Uterine Fibroids (PV-12.1)

References (PV-12)

Leiomyoma/Uterine Fibroids (PV-12.1)

PV.UF.0012.1.A

v2.0.2024

Leiomyomata are also known as “fibroids.”

The uterus, tubes and ovaries arise out of the pelvis and are considered pelvic organs. If the uterus rises out of the pelvic cavity, the imaging field can be determined on scout films. Imaging of the abdomen is not supported for problems suspected to arise from the pelvis.

- Pelvic ultrasound (CPT® 76856 or CPT® 76857) and/or TV ultrasound (CPT® 76830) for any of the following:
 - Suspected leiomyoma with symptoms of pelvic pain, suspected ureteral obstruction secondary to inability to void urine, pelvic pressure and/or abnormal uterine bleeding and/or an enlarged uterus found on physical exam with a negative pregnancy test (if pre-menopausal).
 - Pre-operative prior to myomectomy
 - Recurrent symptoms such as abnormal bleeding, pain, or pelvic pressure
 - 3-D Rendering (CPT® 76377 or CPT® 76376) and/or Duplex (Doppler) scan (CPT® 93975 complete; CPT® 93976 limited) if ultrasound is equivocal and intracavitary lesion is suspected, or for surgical planning for myomectomy
 - There is no current evidence to support 3-D Rendering (CPT® 76377 or CPT® 76376) for planning for uterine artery embolization.
- MRI Pelvis and/or Abdomen to determine surgical approach for hysterectomy is not supported.
- MRI Pelvis without and with contrast (CPT® 72197), or without contrast (CPT® 72195) in the evaluation of leiomyomas for the following:
 - Guide the treatment of leiomyoma/fibroid in an enlarged uterus with multiple leiomyoma/fibroid following indeterminate ultrasound when myomectomy is planned.
 - Equivocal sonohysterography or panoramic hysteroscopy with suspected submucous leiomyoma and imaging is needed to plan for myomectomy
 - Leiomyoma necrosis is suspected
 - Guide the treatment of leiomyoma/fibroid in an enlarged uterus with multiple leiomyoma/fibroid following indeterminate ultrasound when Radiofrequency Ablation of Leiomyomas is planned
 - Uterine artery embolization is being considered
 - If MRI is equivocal, MRA Pelvis (CPT® 72198) or CTA Pelvis (CPT® 72191) if requested by or in consultation with the interventional radiologist planning the uterine artery embolization
 - There is no evidence to support interval MRI after embolization unless persistent or recurrent symptoms
- If malignancy is suspected, See **Oncology Imaging Guidelines** .

- MRI Pelvis with and without (CPT® 72197) may be considered for suspected leiomyosarcoma if one or more of the following ultrasound features AND symptoms are present;
 - Ultrasound features suggestive of leiomyosarcoma are:
 - Large sized (greater than 8 cm)
 - Irregular borders
 - Areas of cystic change or necrosis
 - Increase in central and peripheral vascularity
 - Rapid change in size
 - Symptoms suggestive of leiomyosarcoma would include postmenopausal woman with an new or rapidly enlarging myometrial mass or rapid growth of a uterine mass in a premenopausal patient (increase of 6 weeks gestation size within 1 year)
- CT is generally not warranted for evaluating pelvic anatomy because it is limited due to soft tissue contrast resolution

References (PV-12)

v2.0.2024

1. Sakhel K, Benson CB, Platt LD, Goldstein SR, Benacerraf BR. Begin With the Basics. *Journal of Ultrasound in Medicine*. 2013;32(3):381-388. doi:10.7863/jum.2013.32.3.381
2. Benacerraf BR, Abuhamad AZ, Bromley B, et al. Consider ultrasound first for imaging the female pelvis. *American Journal of Obstetrics and Gynecology*. 2015;212(4):450-455. doi:10.1016/j.ajog.2015.02.015
3. Turkgeldi E, Urman B, Ata B. Role of Three-Dimensional Ultrasound in Gynecology. *Journal of Obstetrics and Gynaecology of India*. 2014;65(3):146-154. doi:10.1007/s13224-014-0635-z
4. Deshmukh SP, Gonsalves CF, Guglielmo FF, Mitchell DG. Role of MR Imaging of Uterine Leiomyomas before and after Embolization. *RadioGraphics*. 2012;32(6). doi:10.1148/rg.326125517
5. Silberzweig JE, Powell DK, Matsumoto AH, Spies JB. Management of Uterine Fibroids: A Focus on Uterine-sparing Interventional Techniques. *Radiology*. 2016;280(3):675-692. doi:10.1148/radiol.2016141693
6. Matteson KA, Butts SF. Choosing the Route of Hysterectomy for Benign Disease. *Obstetrics and Gynecology*. 2017 Jun 1;129(6):1149-50 (Reaffirmed 2019)
7. Practice Bulletin No. 228. Management of Symptomatic Uterine Leiomyomas. *Obstetrics & Gynecology*. 2021;137(6):e100-e115. doi:10.1097/aog.0000000000004401
8. Hindman N, Kang S, Fournier L, Lakhman Y, Nougaret S, Reinhold C, Sadowski E, Huang JQ, Ascher S. MRI Evaluation of Uterine Masses for Risk of Leiomyosarcoma: A Consensus Statement. *Radiology*. 2023 Feb;306(2):e211658. doi: 10.1148/radiol.211658.
9. Stewart KA, Greenberg JA, Kho KA, Cohen Rassier SL. Radiofrequency Ablation of Leiomyomas. *Obstet Gynecol*. 2023 Apr 13. doi: 10.1097/AOG.0000000000005196.

Periurethral Cysts, Urethral Diverticula, and Vaginal Masses (PV-13)

Guideline

Periurethral cysts, Skene duct cyst and Gartner's duct cyst (PV-13.1)
Urethral Diverticula (PV-13.2)
Vaginal Masses (PV-13.3)
References (PV-13)

Periurethral cysts, Skene duct cyst and Gartner's duct cyst (PV-13.1)

PV.UD.0013.1.A

v2.0.2024

- Initial evaluation includes any of the following:
 - Pelvic ultrasound (CPT® 76856 or CPT® 76857) and/or Transvaginal ultrasound (CPT® 76830) and/or Transperineal ultrasound (CPT® 76872)
 - MRI Pelvis without and with contrast (CPT® 72197) for surgical planning when ultrasound equivocal

Urethral Diverticula (PV-13.2)

PV.UD.0013.2.A

v2.0.2024

- Initial evaluation may include Pelvic ultrasound (CPT® 76856 or CPT® 76857) and/or Transvaginal ultrasound (CPT® 76830) and/or Transperineal ultrasound (CPT® 76872)
- Urethrography, or CT Urethrography (CT Pelvis without and with contrast CPT® 72194 or CT Pelvis with contrast CPT® 72193) to evaluate any urethral abnormalities
- MRI Pelvis without and with contrast (CPT® 72197) for surgical planning

Vaginal Masses (PV-13.3)

PV.UD.0013.3.A

v2.0.2024

- Initial evaluation includes Pelvic ultrasound (CPT® 76856 or CPT® 76857) and/or Transvaginal ultrasound (CPT® 76830) and/or Transperineal ultrasound (CPT® 76872)
- MRI Pelvis without and with contrast (CPT® 72197) for surgical planning

Background and Supporting Information

Symptomatic infection of congenital periurethral glands can result in urethral diverticula. Symptoms include pain, urinary urgency, frequency of urination, recurrent urinary tract infection, dribbling after urination, or incontinence.

References (PV-13)

v2.0.2024

1. Lazarus E, Allen BC, Blaufox MD, et al. ACR Appropriateness Criteria® Recurrent Lower Urinary Tract Infection in Women. Last review date: 2014. <https://acsearch.acr.org/docs/69491/Narrative/>
2. Crescenze IM, Goldman HB. Female Urethral Diverticulum: Current Diagnosis and Management. *Current Urology Reports*. 2015;16(10). doi:10.1007/s11934-015-0540-8
3. El-Nashar SA, Singh R, Bacon MM, et al. Female Urethral Diverticulum. *Female Pelvic Medicine & Reconstructive Surgery*. 2016;22(6):447-452. doi:10.1097/spv.0000000000000312
4. Greiman AK, Rolef J, Rovner ES. Urethral diverticulum: A systematic review. *Arab Journal of Urology*. 2019;17(1):49-57. doi:10.1080/2090598x.2019.1589748
5. Desmarais CM. Skene's Gland Abscess. *Journal of Diagnostic Medical Sonography*. 2015;31(6):390-393. doi:10.1177/8756479315599545
6. Yang et al. Ultrasonographic Imaging Features of Female Urethral and Peri-urethral Masses. *Ultrasound in Medicine and Biology*. 2020;46 (8):1896-1907
7. Okeahialam NA, Taitongchai A, Sultan AH, Thakar R. Transperineal and endovaginal ultrasound for evaluating suburethral masses: comparison with magnetic resonance imaging. *Ultrasound in Obstetrics & Gynecology*. 2021;57(6):999-1005. doi:10.1002/uog.23123
8. Vaidya RV, Olson K, Wolter C, Khan A. Characterization of Urethral Diverticula in Women. *Female Pelvic Med Reconstr Surg*. 2022 Jan 1;28(1):54-56. doi: 10.1097/SPV.0000000000001060.
9. Pirpiris A, Chan G, Chaulk RC, Tran H, Liu M. An update on urethral diverticula: Results from a large case series. *Can Urol Assoc J*. 2022 Aug;16(8):E443-E447. doi: 10.5489/cuaj.7650.
10. Hamed ST, Mansour SM. Surface transperineal ultrasound and vaginal abnormalities: applications and strengths. *Br J Radiol*. 2017 Dec;90(1080):20170326. doi: 10.1259/bjr.20170326.
11. Zulfiqar M, Shetty A, Yano M, McGettigan M, Itani M, Naeem M, Ratts VS, Siegel CL. Imaging of the Vagina: Spectrum of Disease with Emphasis on MRI Appearance. *Radiographics*. 2021 Sep-Oct;41(5):1549-1568. doi: 10.1148/rg.2021210018. Epub 2021 Jul 23.

Congenital (Mullerian) Uterine and Vaginal Anomalies (PV-14)

Guideline

Uterine Anomalies (PV-14.1)

Vaginal Anomalies (PV-14.2)

References (PV-14)

Uterine Anomalies (PV-14.1)

PV.UA.0014.1.A

v2.0.2024

- Pelvic ultrasound (CPT® 76856 or CPT® 76857) and/or TV ultrasound (CPT® 76830) indicated for initial evaluation. 3-D Rendering (CPT® 76377 or CPT® 76376) may be an add-on if uterine anomaly is suspected on ultrasound.
- If ultrasound is indeterminate:
 - Sonohysterosalpingography (CPT® 76831)
- Retroperitoneal ultrasound (CPT® 76770 or CPT® 76775) is indicated to evaluate for possible coexisting renal anomalies.
 - MRI Abdomen without contrast or without and with contrast (CPT® 74181 or CPT® 74183) or CT urography (CT Abdomen and Pelvis without and with contrast CPT® 74178) for indeterminate renal anomaly⁸ on ultrasound.
- An arcuate uterus is considered a normal variant. Therefore, advanced imaging of a known arcuate uterus is not supported.
- MRI Pelvis without and with contrast (CPT® 72197):
 - Ultrasound is indeterminate for a complex uterine anomaly, or
 - Requested for surgical planning of previously diagnosed uterine anomaly

Vaginal Anomalies (PV-14.2)

PV.UA.0014.2.A

v2.0.2024

- Pelvic ultrasound (CPT® 76856 or CPT® 76857) and/or TV ultrasound (CPT® 76830) and/or Transperineal ultrasound (CPT® 76872) and/or Translabial ultrasound (CPT® 76857) are indicated for initial evaluation. 3-D Rendering (CPT® 76377 or CPT® 76376) may be an add-on if vaginal anomaly is suspected on ultrasound.
- MRI Pelvis without and with contrast (CPT® 72197):
 - Ultrasound is indeterminate for a complex vaginal anomaly, or
 - Requested for surgical planning of previously diagnosed vaginal anomaly

Background and Supporting Information

- Mullerian anomalies are complex structural anomalies deriving from errors in the embryonic development of the mullerian duct. These may include uterine remnant or agenesis, cervical agenesis, unicornate uterus, bicornuate uterus, uterine didelphys, septate uterus, vaginal septum and/or other complex anomalies.

References (PV-14)

v2.0.2024

1. Benacerraf BR, Abuhamad AZ, Bromley B, et al. Consider ultrasound first for imaging the female pelvis. *American Journal of Obstetrics and Gynecology*. 2015;212(4):450-455. doi:10.1016/j.ajog.2015.02.015
2. Graupera B, Pascual MA, Hereter L, et al. Accuracy of three-dimensional ultrasound compared with magnetic resonance imaging in diagnosis of Müllerian duct anomalies using ESHRE-ESGE consensus on the classification of congenital anomalies of the female genital tract. *Ultrasound in Obstetrics & Gynecology*. 2015;46(5):616-622. doi:10.1002/uog.14825
3. ACR–SAR–SPR Practice Parameter for the Performance of Magnetic Resonance Imaging of the Soft Tissue Components of the Pelvis. Resolution 4. Revised 2015. <https://www.acr.org/-/media/ACR/Files/Practice-Parameters/mr-softtissue-pel.pdf?la=en>
4. Committee Opinion No. 779 Management of Acute Obstructive Uterovaginal Anomalies. *Obstetrics & Gynecology*. 2019; Reaffirmed 2021;133(6). doi:10.1097/aog.0000000000003281
5. Committee Opinion No. 728 Mullerian Agenesis: Diagnosis, Management and Treatment. *Obstetrics & Gynecology*. 2018;131(1). Reaffirmed 2020. doi:10.1097/aog.0000000000002458
6. Uterine septum: a guideline Practice Committee of the American Society for Reproductive Medicine. *Fertility and Sterility*. 2016;106(3):530-540. doi:10.1016/j.fertnstert.2016.05.014
7. Ramanathan, Subramaniyan et al. "Multi-modality imaging review of congenital abnormalities of kidney and upper urinary tract." *World journal of radiology* vol. 8,2 (2016): 132-41. doi:10.4329/wjr.v8.i2.132
8. Houat AP, Guimarães CTS, Takahashi MS, et al. Congenital Anomalies of the Upper Urinary Tract: A Comprehensive Review. *RadioGraphics*. 2021;41(2):462-486. doi:10.1148/rg.2021200078
9. Pfeifer SM, Attaran M, Goldstein J, et. al. ASRM müllerian anomalies classification 2021. *Fertil Steril*. 2021;116(5):1238-1252. doi:10.1016/j.fertnstert.2021.09.025.

Fetal MRI and Other Pregnancy Imaging (PV-15)

Guideline

Fetal MRI (PV-15.1)

Placenta Accreta/Placenta Accreta Spectrum/Placenta Percreta (PV-15.2)

C-section or Cornual (interstitial) Ectopic Pregnancy (PV-15.3)

Pelvimetry (PV-15.4)

References (PV-15)

Fetal MRI (PV-15.1)

PV.MR.0015.1.A

v2.0.2024

CPT® Code Guidance

- Fetal MRI (CPT® 74712) [plus CPT® 74713 for each additional fetus]
- Do not report CPT® 74712 and CPT® 74713 in conjunction with CPT® 72195, CPT® 72196, CPT® 72197
- If only placenta or maternal pelvis is imaged without fetal imaging, use MRI Pelvis (CPT® 72195)

Indications for Fetal MRI

- Fetal MRI (CPT® 74712) [plus CPT® 74713 for each additional fetus] optimally performed after 18 to 22 weeks gestation, for assessment of known or suspected fetal abnormalities for counseling, surgical, or delivery planning.
 - There are cases when surgical planning may necessitate imaging earlier than 18 weeks. For those cases where surgery is to be performed prior to 18 weeks and they otherwise meet indications for imaging per this criteria, Fetal MRI may be approved.
- 3D-4D (CPT® 76376 or CPT® 76377) rendering can be added for surgical planning with diagnosis of complex CHD in the fetus or for surgical planning of other complex fetal malformations
- Repeat fetal MRI (CPT® 74712) [plus CPT® 74713 for each additional fetus] later in pregnancy for:
 - Delivery or perinatal surgical planning
- Fetal MRI indications include but may not be limited to the following:
 - Brain
 - Congenital anomalies
 - Ventriculomegaly
 - Agenesis of the corpus callosum
 - Abnormalities of the cavum septum pellucidum
 - Holoprosencephaly
 - Posterior fossa anomalies
 - Malformations of cerebral cortical development
 - Microcephaly
 - Solid or cystic masses
 - Cephalocele
 - Screening fetuses with a family risk for brain anomalies
 - Tuberous sclerosis

- Corpus callosal dysgenesis
- Malformations of cerebral cortical development
- Vascular abnormalities
 - Vascular malformations
 - Hydranencephaly
 - Intra-uterine cerebrovascular accident (CVA)
- Spine
 - Congenital anomalies
 - Neural tube defects
 - Sacrococcygeal teratomas
 - Caudal regression/sacral agenesis
 - Syringomyelia
 - Vertebral anomalies
- Skull, face, and neck
 - Masses of the face and neck
 - Vascular or lymphatic malformations
 - Hemangiomas
 - Goiter
 - Teratomas
 - Facial clefts
 - Airway obstruction
 - Conditions that may impact parental counseling, prenatal management, delivery planning, and postnatal therapy
- Thorax
 - Masses
 - Congenital pulmonary airway malformations (congenital cystic adenomatoid malformation; sequestration, and congenital lobar emphysema);
 - Congenital diaphragmatic hernia
 - Effusion
 - Mediastinal masses
 - Assessment for esophageal atresia
 - Volumetric assessment of lung
 - Cases at risk for pulmonary hypoplasia secondary to oligohydramnios, chest mass, or skeletal dysplasias
- Abdomen, retroperitoneal and pelvis
 - Bowel anomalies such as anorectal malformations, or complex bowel obstructions such as with megacystis microcolon hypoperistalsis syndrome
 - Abdominal wall defect
 - Mass

- Abdominal–pelvic cyst
- Tumors (e.g. hemangiomas, neuroblastomas, sacrococcygeal teratomas, and suprarenal or renal masses)
 - Complex genitourinary anomalies (e.g. cloaca, prune belly syndrome)
- Congenital Heart Disease (CHD)
- Skeletal dysplasia
- Multiple malformations
- Complications of monochorionic twins/TTTS (e.g. Laser treatment of twins, demise of one twin, conjoined twins)
- Any suspected fetal anomaly associated with severe oligohydramnios or anhydramnios.

Placenta Accreta/Placenta Accreta Spectrum/Placenta Percreta (PV-15.2)

PV.MR.0015.2.A

v2.0.2024

- Obstetrical Ultrasound is the initial imaging modality, Color Doppler CPT® 93975 Duplex scan (complete) or CPT® 93976 Duplex scan (limited) may be added to evaluate vascularity for suspected or confirmed placenta accreta spectrum
- MRI Pelvis without contrast (CPT® 72195) if the ultrasound is indeterminate or advanced imaging is needed for surgical planning.
- MRI Pelvis without contrast (CPT® 72195) is the appropriate code if only placenta or maternal pelvis is imaged without fetal imaging
 - Abdominal imaging is not indicated to evaluate a pelvic organ such as uterus, tubes or ovaries.

C-section or Cornual (interstitial) Ectopic Pregnancy (PV-15.3)

PV.MR.0015.3.A

v2.0.2024

- If a cornual (interstitial) ectopic or C-section scar ectopic pregnancy is suspected on ultrasound:^{9,10}
 - 3D rendering (CPT[®] 76376 or CPT[®] 76377), and/or Color Doppler (CPT[®] 93976) can be performed with ultrasound
 - MRI Pelvis without contrast (CPT[®] 72195) if ultrasound is inconclusive.

Pelvimetry (PV-15.4)

PV.MR.0015.4.A

v2.0.2024

- Pelvimetry (CT or MRI Pelvimetry) lacks sufficient evidence to be clinically useful. Current recommendations are that further randomized control studies be performed before it is adapted into routine clinical practice.^{11,12}

References (PV-15)

v2.0.2024

1. Saleem SN. Fetal MRI: An approach to practice: A review. *Journal of Advanced Research*. 2014;5(5):507-523. doi:10.1016/j.jare.2013.06.001
2. American College of Radiology (ACR), Society for Pediatric Radiology (SPR). ACR-SPR practice guideline for the safe and optimal performance of fetal magnetic resonance imaging (MRI). American College of Radiology (ACR). Revised 2015 (Resolution 11) <https://www.acr.org/-/media/ACR/Files/Practice-Parameters/MR-Fetal.pdf>
3. Kilcoyne A, Shenoy-Bhangle AS, Roberts DJ, Sisodia RC, Gervais DA, Lee SI. MRI of Placenta Accreta, Placenta Increta, and Placenta Percreta: Pearls and Pitfalls. *American Journal of Roentgenology*. 2017;208(1):214-221. doi:10.2214/ajr.16.16281
4. Reddy UM, Abuhamad AZ, Levine D, Saade GR. Fetal Imaging: Executive Summary of a Joint Eunice Kennedy Shriver National Institute of Child Health and Human Development, Society for Maternal-Fetal Medicine, American Institute of Ultrasound in Medicine, American College of Obstetricians and Gynecologists, American College of Radiology, Society for Pediatric Radiology, and Society of Radiologists in Ultrasound Fetal Imaging Workshop. *Obstetrics & Gynecology*. 2014;123(5):1070-1082. doi:10.1097/aog.0000000000000245
5. Cahill AG, Beigi R, Heine RP, Silver RM, Wax JR. Placenta Accreta Spectrum. *American Journal of Obstetrics and Gynecology*. 2018;219(6). doi:10.1016/j.ajog.2018.09.042
6. Prayer D, Malinger G, Brugger PC, et al. ISUOG Practice Guidelines: performance of fetal magnetic resonance imaging. *Ultrasound in Obstetrics & Gynecology*. 2017;49(5):671-680. doi:10.1002/uog.17412
7. Shainker SA, Coleman B, Timor IE, Bhide A, Bromley B, Cahill AG, Gandhi M, Hecht JL, Johnson KM, Levine D, Mastrobattista J. Special Report of the Society for Maternal-Fetal Medicine Placenta Accreta Spectrum Ultrasound Marker Task Force: Consensus on definition of markers and approach to the ultrasound examination in pregnancies at risk for placenta accreta spectrum. *American Journal of Obstetrics and Gynecology*. 2021 Jan;224(1):B2-14
8. American College of Obstetricians and Gynecologists Committee Opinion No. 723. Guidelines for diagnostic imaging during pregnancy and lactation. *Obstetrics & Gynecology*. 2017; Reaffirmed 2021;130(4). doi:10.1097/aog.0000000000002355
9. Ramanathan S, Raghu V, Ladumor SB, Nagadi AN, Palaniappan Y, Dogra V, Schieda N. Magnetic resonance imaging of common, uncommon, and rare implantation sites in ectopic pregnancy. *Abdom Radiol (NY)*. 2018 Dec;43(12):3425-3435. doi: 10.1007/s00261-018-1604-2
10. Dibble EH, Lourenco AP. Imaging Unusual Pregnancy Implantations: Rare Ectopic Pregnancies and More. *AJR Am J Roentgenol*. 2016 Dec;207(6):1380-1392. doi: 10.2214/AJR.15.15290
11. Pattinson RC, Cuthbert A, Vannevel V. Pelvimetry for fetal cephalic presentations at or near term for deciding on mode of delivery. *Cochrane Database of Systematic Reviews*. Published online March 30, 2017. doi:10.1002/14651858.cd000161.pub2
12. Salk I, Cetin A, Salk S, Cetin M. Pelvimetry by Three-Dimensional Computed Tomography in Non-Pregnant Multiparous Women Who Delivered Vaginally. *Polish Journal of Radiology*. 2016;81:219-227. doi:10.12659/pjr.896380
13. Lloyd DFA, Pushparajah K, et. al. Three-dimensional visualisation of the fetal heart using prenatal MRI with motion-corrected slice-volume registration: a prospective, single-centre cohort study. *Lancet*. 2019 Apr 20;393(10181):1619-1627. doi: 10.1016/S0140-6736(18)32490-5

Molar Pregnancy and Gestational Trophoblastic Neoplasia (GTN) (PV-16)

Guideline

Molar Pregnancy and GTN (PV-16.1)
References (PV-16)

Molar Pregnancy and GTN (PV-16.1)

PV.MP.0016.1.A

v2.0.2024

- Molar pregnancy – once diagnosed on an Obstetrical Ultrasound treatment is usually evacuation. Individuals should undergo chest x-ray pre- and post-evacuation.
 - If chest x-ray is positive for metastases, management as per GTN guidelines, see **Gestational Trophoblastic Neoplasia (GTN)/Choriocarcinoma (ONC-22.5)** in the Oncology Imaging Guidelines.
- Serum hCG levels are obtained every 1-2 weeks after treatment of molar pregnancy until they normalize
- Individuals with a molar pregnancy and rising or plateauing hCG levels post evacuation and/or Gestational trophoblastic neoplasia please see **Gestational Trophoblastic Neoplasia (GTN)/Choriocarcinoma (ONC-22.5)** in the Oncology Imaging Guidelines.

References (PV-16)

v2.0.2024

1. Soper JT. Gestational Trophoblastic Disease. *Obstetrics & Gynecology*. 2021;137(2):355-370. doi:10.1097/aog.0000000000004240
2. Abu-Rustum NR, Yashar CM, Arend R, et al. National Comprehensive Cancer Network (NCCN) Guidelines Version 1.2023 – December 20, 2022. Gestational Trophoblastic Neoplasia, Gestational Trophoblastic Neoplasia, available at: https://www.nccn.org/professionals/physician_gls/pdf/gtn.pdf. Referenced with permission from the NCCN Clinical Practice Guidelines in Oncology (NCCN Guidelines™ for Gestational Trophoblastic Neoplasia, V1.2023 -12/20/2022. ©2022 National Comprehensive Cancer Network, Inc. All rights reserved. The NCCN Guidelines™ and illustrations herein may not be reproduced in any form for any purpose without the express written permission of the NCCN. To view the most recent and complete version of the NCCN Guidelines™, go online to NCCN.org.
3. Horowitz NS, Eskander RN, Adelman MR, Burke W. Epidemiology, diagnosis, and treatment of gestational trophoblastic disease: A Society of Gynecologic Oncology evidenced-based review and recommendation. *Gynecol Oncol*. 2021;163(3):605-613. doi:10.1016/j.ygyno.2021.10.003.

Impotence/Erectile Dysfunction (PV-17)

Guideline

Impotence/Erectile Dysfunction (PV-17.1)
References (PV-17)

Impotence/Erectile Dysfunction (PV-17.1)

PV.ED.0017.1.A

v2.0.2024

- Imaging depends on the suspected disease:
 - Penile Doppler ultrasound (CPT® 93980) if erectile dysfunction suspected²
 - CTA Pelvis with contrast (CPT® 72191) if large vessel vascular insufficiency is suspected following ultrasound.
 - Duplex ultrasound (CPT® 93980) to assess penile vasculature in Peyronie's disease¹
 - If male hypogonadism is suspected, See **Pituitary (HD-19)** in the Head Imaging Guidelines
- Functional MRI or PET studies are considered investigational for this indication.
- Priapism
 - Penile Doppler Ultrasound (CPT® 93980) if non-ischemic priapism is suspected
 - MRI likely does not have a role in the initial diagnosis of priapism given the time sensitive nature of diagnosis and management
 - In patients with persistent non-ischemic priapism where an embolization may be necessary CTA (CPT® 72191) or MRA pelvis (CPT® 72198) may be considered
 - Penial Doppler Ultrasound (CPT® 93980) may be considered post procedure for ischemic priapism

References (PV-17)

v2.0.2024

1. Nehra A, Alterowitz R, Culkin DJ, et al. Peyronie's Disease: AUA Guideline. *Journal of Urology*. 2015;194(3):745-753. doi:10.1016/j.juro.2015.05.098
2. Sikka SC, Hellstrom WJ, Brock G, Morales AM. Standardization of Vascular Assessment of Erectile Dysfunction. *The Journal of Sexual Medicine*. 2013;10(1):120-129. doi:10.1111/j.1743-6109.2012.02825.x
3. White C, Gulati M, Gomes A, Rajfer J, Raman S. Pre-embolization evaluation of high-flow priapism: magnetic resonance angiography of the penis. *Abdom Imaging*. 2013;38(3):588-97. doi: 10.1007/s00261-012-9936-9.
4. Arrichiello A, Angileri SA, Buccimazza G, et. al. Interventional radiology management of high flow priapism: review of the literature. *Acta Biomed*. 2020;91(10-S):e2020010. doi:10.23750/abm.v91i10-S.10233.
5. Bivalacqua TJ, Allen BK, Brock GB, et al. The diagnosis and management of recurrent ischemic priapism, priapism in sickle cell patients, and non-ischemic priapism: an AUA/SMSNA guideline. *J Urol*. 2022;208(1):43-52.

Penis–Soft Tissue Mass (PV-18)

Guideline

Penis-Soft Tissue Mass (PV-18.1)

References (PV-18)

Penis-Soft Tissue Mass (PV-18.1)

PV.PM.0018.1.A

v2.0.2024

- Penile ultrasound (CPT® 76857) for initial evaluation soft-tissue lesions of the penis, Duplex (Doppler) scan CPT® 93975 complete; CPT® 93976 limited) may be approved as an add-on.
- If primary penile cancer is suspected, biopsy is indicated
 - For further workup of biopsy confirmed penile cancer see **Cancers of External Genitalia – Initial Work-up/Staging (ONC-24.6)** in the Oncology Imaging Guidelines.
- Peyronie's Disease
 - Ultrasound (CPT® 76857) recommended
 - MRI Pelvis without and with contrast (CPT® 72197) if ultrasound is equivocal and surgery or injection therapy is being contemplated

References (PV-18)

v2.0.2024

1. Chipollini J, De la Rosa AH, Azizi M, Shayegan B, Zorn KC, Spiess PE. Patient presentation, differential diagnosis, and management of penile lesions. *Can Urol Assoc J*. 2019;13(2 Suppl 1):S2–S8. doi:10.5489/cuaj.5712
2. Rocher L, Glas L, Cluzel G, Ifergan J, Bellin M. Imaging tumours of the penis. *Diagnostic and Interventional Imaging*. 2012;93(4):319-328. doi:10.1016/j.diii.2012.01.020
3. Kirkham A. MRI of the penis. *The British Journal of Radiology*. 2012;85(special_issue_1). doi:10.1259/bjr/63301362
4. Bertolotto M, Pavlica P, Serafini G, Quaia E, Zappetti R. Painful Penile Induration: Imaging Findings and Management. *RadioGraphics*. 2009;29(2):477-493. doi:10.1148/rg.292085117
5. Prando D. New Sonographic Aspects of Peyronie Disease. *Journal of Ultrasound in Medicine*. 2009;28(2):217-232. doi:10.7863/jum.2009.28.2.217
6. Bilgutay AN, Pastuszak AW. Peyronie's Disease: A Review of Etiology, Diagnosis, and Management. *Current Sexual Health Reports*. 2015;7(2):117-131. doi:10.1007/s11930-015-0045-y

Male Pelvic Disorders (PV-19)

Guideline

Male Pelvic Disorders (PV-19.1)

References (PV-19)

Male Pelvic Disorders (PV-19.1)

PV.PE.0019.1.U

v2.0.2024

- Prostate
 - Prostate Disorders
 - Suspected Benign Prostatic Hypertrophy with obstructive voiding symptoms can undergo:
 - Transrectal ultrasound (CPT® 76872) or Pelvis transabdominal ultrasound (bladder and prostate [CPT® 76856 or CPT® 76857]).
 - Prostatitis with urinary retention or suspected abscess can undergo any of the following imaging studies:
 - Transrectal ultrasound (CPT® 76872) or Pelvis transabdominal ultrasound (bladder and prostate [CPT® 76856 or CPT® 76857])
 - CT Pelvis with contrast (CPT® 72193) or MRI Pelvis without contrast (CPT® 72195) or with and without contrast (CPT® 72197) if ultrasound is equivocal for abscess or mass
 - Prostate Artery Embolization (PAE)
 - MRA Pelvis (CPT® 72198) or CTA Pelvis (CPT® 72191) is indicated for evaluation of the pelvic vasculature if:
 - Prostate artery embolization is planned
- Testicular
 - Hematospermia, transrectal ultrasound (TRUS) (CPT® 76872) can be the initial imaging study in all cases.
 - MRI Pelvis without contrast (CPT® 72195) to evaluate:
 - Suspected hemorrhage within the seminal vesicles
 - Radiation injury, neoplasia
 - Failure of conservative treatment for 2 weeks
 - Abnormal findings on Transrectal ultrasound
- Rectal
 - Proctalgia Syndromes
 - Prior to advanced imaging, the evaluation of rectal/perineal pain should include:
 - Digital rectal examination (assess for mass, prostate, fissures, hemorrhoids, etc.)
 - Recent flexible sigmoidoscopy or colonoscopy subsequent to the start of reported symptoms to exclude inflammatory conditions or malignancy
 - Endoanal ultrasound (CPT® 76872), MRI Pelvis without and with contrast (CPT® 72197), or CT Pelvis with contrast (CPT® 72193) are appropriate after the above studies have been performed or if laboratory or clinical information suggest infection, abscess, or inflammation

- MRI (MRI Pelvis without contrast CPT[®] 72195) for Defecography is considered investigational/experimental by UHC
- Bladder
 - Work-up of interstitial cystitis/bladder pain syndrome (IC/BPS) may include history, physical exam, laboratory exam (urinalysis and urine culture), cystoscopy, and measurement of post void residual urine by bladder catheterization
 - Pelvic ultrasound (CPT[®] 76856 or CPT[®] 76857)
 - CT Pelvis with contrast (CPT[®] 72193) if ultrasound is equivocal for complicated interstitial cystitis/bladder pain syndrome (when ordered by specialist or any provider in consultation with the specialist)

Background and Supporting Information

- The proctalgia syndromes are characterized by recurrent episodes of rectal/perineal pain, and may be due to sustained contractions of the pelvic floor musculature.

References (PV-19)

v2.0.2024

1. Nickel JC. Prostatitis. *Canadian Urological Association Journal*. 2011;306-315. doi:10.5489/cuaj.11211
2. Hosseinzadeh K, Oto A, Allen BC, et al. ACR Appropriateness Criteria® Hematospermia. *Journal of the American College of Radiology*. 2017;14(5). doi:10.1016/j.jacr.2017.02.023
3. Zhao H, Luo J, Wang D, et al. The Value of Transrectal Ultrasound in the Diagnosis of Hematospermia in a Large Cohort of Patients. *Journal of Andrology*. 2011;33(5):897-903. doi:10.2164/jandrol.111.013318
4. Macdonald A, Burrell S. Infrequently Performed Studies in Nuclear Medicine: Part 2. *Journal of Nuclear Medicine Technology*. 2009;37(1):1-13. doi:10.2967/jnmt.108.057851
5. Hartman MS, Leyendecker JR, Friedman B, et al. ACR Appropriateness Criteria® Acute Onset of Scrotal Pain—Without Trauma, Without Antecedent Mass. Last review date: 2019. <https://acsearch.acr.org/docs/69363/Narrative/>
6. Friedman B, Leyendecker JR, Blaufox MD, et al. ACR Appropriateness Criteria® Lower Urinary Tract Symptoms: Suspicion of Benign Prostatic Hyperplasia Last review date: 2019. <https://acsearch.acr.org/docs/69368/Narrative/>
7. Wald A, Bharucha AE, Cosman BC, Whitehead WE. ACG Clinical Guideline: Management of Benign Anorectal Disorders. *American Journal of Gastroenterology*. 2014;109(8):1141-1157. doi:10.1038/ajg.2014.190
8. Kraemer S, Watson V, Peters KM. The Evaluation and Management of Interstitial Cystitis/Bladder Pain Syndrome. *EMJ Urol* 2019;7(1):75-82
9. Foster HE, Barry MJ, Dahm P et al: Surgical management of lower urinary tract symptoms attributed to benign prostatic hyperplasia: AUA Guideline. *J Urol* 2018, 200:612
10. Parsons JK, Dahm P, Kohler TS et al: Surgical management of lower urinary tract symptoms attributed to benign prostatic hyperplasia: AUA Guideline amendment 2020. *J Urol* 2020; 204: 799
11. Sandhu JS, Bixler BR, Dahm P, et al. Management of lower urinary tract symptoms attributed to benign prostatic hyperplasia (BPH): AUA Guideline amendment 2023. *J Urol*. 2023;10.1097/JU.0000000000003698. <https://doi.org/10.1097/JU.0000000000003698>
12. Dias US Jr, de Moura MRL, Viana PCC, de Assis AM, Marcelino ASZ, Moreira AM, Leite CC, Cerri GG, Carnevale FC, Horvat N. Prostatic Artery Embolization: Indications, Preparation, Techniques, Imaging Evaluation, Reporting, and Complications. *Radiographics*. 2021 Sep-Oct;41(5):1509-1530. doi: 10.1148/rg.2021200144. Epub 2021 Aug 20. PMID: 34415807; PMCID: PMC9394104
13. Vibhor Wadhwa, Timothy D McClure, Role of Imaging in Prostate Artery Embolization, *Seminars in Roentgenology*, Volume 56, Issue 4, 2021, Pages 410-415, ISSN 0037-198X, <https://doi.org/10.1053/j.ro.2021.08.007>.
14. Rostambeigi N, Golzarian J, Little MW. Updates on Preprocedural Evaluation and Patient Selection for Prostatic Artery Embolization. *Semin Intervent Radiol*. 2022 Dec 20;39(6):547-554. doi: 10.1055/s-0042-1760274. PMID: 36561799; PMCID: PMC9767769.

Scrotal Pathology (PV-20)

Guideline

Scrotal Pathology (PV-20.1)

Paratesticular and spermatic cord masses (PV-20.2)

Testicular Microlithiasis (PV-20.3)

References (PV-20)

Scrotal Pathology (PV-20.1)

PV.SP.0020.1.A

v2.0.2024

- Scrotal ultrasound (CPT® 76870) and/or Duplex (Doppler) ultrasound (CPT® 93975 or CPT® 93976) of the scrotum for initial evaluation of scrotal pain or mass
 - MRI Pelvis without and with contrast (CPT® 72197) or Tc-99m scrotal scintigraphy (CPT® 78761) if ultrasound is inconclusive.^{1,2}
- Scrotal ultrasound (CPT® 76870), MRI Pelvis without and with contrast (CPT® 72197), or CT Pelvis with contrast (CPT® 72193) for cryptorchidism/undescended testis in the adult.
- Scrotal ultrasound and/or Duplex (Doppler) ultrasound (CPT® 76870 and/or CPT® 93975 or CPT® 93976) of the scrotum with color flow mapping in supine and upright positions to assess venous reflux into plexus pampiniformis if varicocele suspected (for example, in inguinal hernia evaluation)
 - CT Abdomen and Pelvis with contrast (CPT® 74177) for right-sided varicocele, when there is suspicion for intra-abdominal pathology

Background and Supporting Information

- The causes of scrotal pain may include torsion, epididymitis, strangulated hernia, segmental testicular infarction, trauma, testicular tumor, and idiopathic scrotal edema.¹

Paratesticular and spermatic cord masses (PV-20.2)

PV.SP.0020.2.A

v2.0.2024

- Scrotal ultrasound (CPT® 76870) is the appropriate initial imaging procedure.
 - MRI Pelvis without and with contrast (CPT® 72197), exploration and biopsy are additional considerations if ultrasound is inconclusive.

Testicular Microlithiasis (PV-20.3)

PV.SP.0020.3.A
v2.0.2024

- Scrotal ultrasound (CPT® 76870) for initial evaluation
- Annual Scrotal ultrasound (CPT® 76870) follow-up, only if a risk factor is present which include:
 - Family history of germ cell tumor
 - Malescent
 - Orchidopexy
 - Testicular atrophy
- For Personal history of germ cell tumor See **Testicular, Ovarian and Extragonadal Germ Cell Tumors (ONC-20)** in the Oncology Imaging Guidelines

References (PV-20)

v2.0.2024

1. Hartman MS, Leyendecker JR, Friedman B, et al. ACR Appropriateness Criteria® Acute Onset of Scrotal Pain—Without Trauma, Without Antecedent Mass. Last review date: 2019. <https://acsearch.acr.org/docs/69363/Narrative/>
2. Kim W, Rosen MA, Langer JE, Banner MP, Siegelman ES, Ramchandani P. US—MR Imaging Correlation in Pathologic Conditions of the Scrotum. *RadioGraphics*. 2007;27(5):1239-1253. doi:10.1148/rg.275065172
3. Wolfman DJ, Marko J, Gould CF, Sesterhenn IA, Lattin GE. Mesenchymal Extratesticular Tumors and Tumorlike Conditions: From the Radiologic Pathology Archives. *RadioGraphics*. 2015;35(7):1943-1954. doi:10.1148/rg.2015150179
4. Tan IB, Ang KK, Ching BC, Mohan C, Toh CK, Tan MH. Testicular microlithiasis predicts concurrent testicular germ cell tumors and intratubular germ cell neoplasia of unclassified type in adults. *Cancer*. 2010;116(19):4520-4532. doi:10.1002/cncr.25231
5. Decastro BJ, Peterson AC, Costabile RA. A 5-Year Followup Study of Asymptomatic Men With Testicular Microlithiasis. *The Journal of Urology*. 2008;179(4):1420-1423. doi:10.1016/j.juro.2007.11.080
6. Winter TC, Kim B, Lowrance WT, Middleton WD. Testicular Microlithiasis: What Should You Recommend? *American Journal of Roentgenology*. 2016;206(6):1164-1169. doi:10.2214/ajr.15.15226
7. Richenberg J, Belfield J, Ramchandani P, et al. Testicular microlithiasis imaging and follow-up: guidelines of the ESUR scrotal imaging subcommittee. *European Radiology*. 2014;25(2):323-330. doi:10.1007/s00330-014-3437-x
8. Richenberg J, Brejt N. Testicular microlithiasis: is there a need for surveillance in the absence of other risk factors? *European Radiology*. 2012;22(11):2540-2546. doi:10.1007/s00330-012-2520-4
9. AIUM Practice Guideline for the Performance of Scrotal Ultrasound Examinations. *Journal of Ultrasound in Medicine*. 2015;34(8):1-5. doi:10.7863/ultra.34.8.15.13.0006
10. Parenti GC, Feletti F, Carnevale A, Uccelli L, Giganti M. Imaging of the scrotum: beyond sonography. *Insights Imaging*. 2018;9(2):137-148. doi:10.1007/s13244-017-0592-z.11
11. Stephenson A, Eggener SE, Bass EB, et al. Diagnosis and Treatment of Early Stage Testicular Cancer: AUA Guideline. *Journal of Urology*. 2019;202(2):272-281. doi:10.1097/ju.0000000000000318
12. Hodler J, et al. (eds.), *Diseases of the Abdomen and Pelvis 2018–2021*, IDKD Springer Series, https://doi.org/10.1007/978-3-319-75019-4_24

Fistulae, Abscess, and Pilonidal Cyst (PV-21)

Guideline

Fistula in Ano (PV-21.1)

Abscess (PV-21.2)

Pelvic Fistula (PV-21.3)

Pilonidal Cyst (PV-21.4)

References (PV-21)

Fistula in Ano (PV-21.1)

PV.PA.0021.1.A

v2.0.2024

- MRI Pelvis without and with contrast (CPT® 72197) is the preferred study.
 - If MRI cannot be performed, endoscopic ultrasound is superior, and thus preferential, to CT imaging.
 - CT Pelvis with contrast (CPT® 72193) is an inferior study to either of the above (accuracy of endoscopic ultrasound vs. CT for perianal fistula is 82% vs. 24%) and its use should be limited only to those circumstances in which MRI and endoscopic ultrasound cannot be performed.

Abscess (PV-21.2)

PV.PA.0021.2.A

v2.0.2024

- MRI Pelvis without and with contrast (CPT® 72197) is the preferred study
 - CT Pelvis with contrast (CPT® 72193) is supported as an alternative study if desired.
- For the evaluation of Perianal and Perirectal Disease related to Crohn's Disease, See **Perirectal/Perianal Disease (AB-23.3)** in the Abdomen Imaging Guidelines.

Pelvic Fistula (PV-21.3)

PV.PA.0021.3.A

v2.0.2024

- History and physical exam (to include pelvic and/or anorectal examination):
 - Rectovesicular Fistula:
 - MRI Pelvis with and without contrast (CPT® 72197) OR
 - CT Pelvis with contrast (CPT® 72193)
 - Vaginal Fistula:
 - Enterovaginal, Colovaginal, Rectovaginal or Anovaginal:
 - Anoscopy and/or proctoscopy
 - Endoanal ultrasound (rarely used)
 - MRI Pelvis with and without contrast (CPT® 72197) is the preferred initial modality for suspected enterovaginal fistula
 - CT Pelvis with contrast (CPT® 72193) can be considered if:
 - MRI contraindicated OR urgent evaluation of acute diverticulitis OR early postoperative period
 - Urinary Vaginal Fistula (Ureterovaginal, Vesicovaginal, or Urethrovaginal):
 - Cystoscopy
 - CT urography (CT Abdomen and Pelvis without and with contrast CPT® 74178) and/or CT cystography (CT Pelvis without contrast CPT® 72192) or
 - MRI Pelvis with and without contrast (CPT® 72197)

Background and Supporting Information

- A vaginal fistula is an abnormal communication between the vagina and either a portion of the digestive system or the urinary tract
 - Causes of vaginal fistula may include IBD, endometriosis, infection, tumor, radiation, obstetrical trauma and surgical injuries.
 - Symptoms of vaginal fistula-Persistent vaginitis, dyspareunia, perineal dermatitis, foul-smelling vaginal discharge, and/or urinary or fecal incontinence.
- A rectovesicular fistula is an abnormal communication between the rectum and the bladder.
 - Causes of rectovesicular fistula may include chronic infection, cancer, diverticulitis, IBD, radiation and surgical injuries.
 - Symptoms of rectovesicular fistula-Bubbles in the urine, brown or cloudy urine, blood in the urine, painful urination, recurrent urinary tract infection, and/or abdominal pain

Pilonidal Cyst (PV-21.4)

PV.PA.0021.4.A

v2.0.2024

- Advanced imaging is not indicated for pilonidal cyst disease⁹.
- For suspected osteomyelitis, see: **Infection/Osteomyelitis (MS-9)** in the Musculoskeletal Imaging Guidelines
- For abdominal fistulae, see: **Fistulae (AB-48)** in the Abdomen Imaging Guidelines
- For suspected spinal dysraphism, see: **Cutaneous Indications to Suspect Occult Spinal Dysraphism (PEDSP-4.2)** in the Pediatric Spine Imaging Guidelines

References (PV-21)

v2.0.2024

1. Ziech M, Felt-Bersma R, Stoker J. Imaging of Perianal Fistulas. *Clinical Gastroenterology and Hepatology*. 2009;7(10):1037-1045. doi:10.1016/j.cgh.2009.06.030
2. Vogel JD, Johnson EK, Morris AM, et al. Clinical Practice Guideline for the Management of Anorectal Abscess, Fistula-in-Ano, and Rectovaginal Fistula. *Diseases of the Colon & Rectum*. 2016;59(12):1117-1133. doi:10.1097/dcr.0000000000000733
3. Tonolini M. Elucidating vaginal fistulas on CT and MRI. *Insights into Imaging*. 2019;10(1). doi:10.1186/s13244-019-0812-9
4. VanBuren WM, Lightner AL, Kim ST, et al. Imaging and Surgical Management of Anorectal Vaginal Fistulas. *RadioGraphics*. 2018;38(5):1385-1401. doi:10.1148/rg.2018170167
5. Hancock KJ, Gajjar AH. Anorectal Disorders. *Obstetrics & Gynecology*. 2020;136(3):642-642. doi:10.1097/aog.0000000000004047
6. Levy AD, Liu PS, Kim DH, et al. ACR Appropriateness Criteria® Anorectal Disease. *Journal of the American College of Radiology*. 2021;18(11):S268-S282. doi:10.1016/j.jacr.2021.08.009
7. Fecal incontinence. ACOG Practice Bulletin No. 210. *Obstetrics & Gynecology*. 2019;133(4):e260-e273. (reaffirmed 2023) doi:10.1097/aog.0000000000003187
8. Berman L. Utility of magnetic resonance imaging in anorectal disease. *World Journal of Gastroenterology*. 2007;13(23):3153. doi:10.3748/wjg.v13.i23.3153
9. Johnson EK, Vogel JD, Cowan ML, Feingold DL, Steele SR. The American Society of Colon and Rectal Surgeons' clinical practice guidelines for the management of pilonidal disease. *Dis Colon Rectum*. 2019;62:146-157. doi:10.1097/DCR.0000000000001237.

Urinary Incontinence/Pelvic Prolapse/Fecal Incontinence (PV-22)

Guideline

- Urinary Incontinence – Initial Imaging (PV-22.1)
- Urinary Incontinence – Further Imaging (PV-22.2)
- Pelvic Prolapse (PV-22.3)
- Fecal Incontinence (PV-22.4)
- References (PV-22)

Urinary Incontinence – Initial Imaging (PV-22.1)

PV.IN.0022.1.A

v2.0.2024

- Initial Imaging, associated with other evaluations, are:
 - Non-Neurogenic Incontinence
 - Measurements of post void residual urine by Bladder ultrasound (CPT® 51798) OR Bladder catheterization
 - In addition to post void residual volume determination, screening for UTI should be considered
 - Neurogenic Incontinence
 - Ultrasound urinary tract (CPT® 76770 or CPT® 76775)

Background and Supporting Information

Urinary incontinence can be “stress,” “urgency,” or mixed; neurogenic or non-neurogenic; and complicated or uncomplicated. Neurogenic incontinence can occur from cerebral, spinal or peripheral neurological diseases.

Urinary Incontinence – Further Imaging (PV-22.2)

PV.IN.0022.2.A

v2.0.2024

- CT Abdomen and Pelvis, contrast as requested, or CT Pelvis, contrast as requested, for any of the following:
 - Abnormality on ultrasound that requires further evaluation
 - Complicated incontinence
 - Failed conservative treatment
 - Pain or dysuria
 - Hematuria
 - Recurrent infection
 - Previous radical pelvic surgery
 - Suspected fistula
 - Suspected mass
 - Previous pelvic or prostate irradiation
 - Suspected fistulae
 - Detecting ectopic ureters if ultrasound is non-diagnostic
 - Pre-operative planning for complicated incontinence when ordered by or in consultation with the operating physician

Background and Supporting Information

- For neurogenic urinary incontinence See **Red Flag Indications (SP-1.2)** and **Myelopathy (SP-7.1)** in the Spine Imaging Guidelines and **Dementia (HD-8.1)** and **Normal Pressure Hydrocephalus (NPH) (HD-8.4)** in the Head Imaging Guidelines

Pelvic Prolapse (PV-22.3)

PV.IN.0022.3.U

v2.0.2024

- Transvaginal (TV) ultrasound (CPT® 76830) and/or Transperineal ultrasound (CPT® 76872) is the initial study of choice
 - Pelvic ultrasound (CPT® 76856 or CPT® 76857) can be performed if requested as a complimentary study.
- Urodynamic testing may be helpful if there is incontinence with a stage II or greater prolapse or voiding dysfunction
- MRI Pelvis (CPT® 72195 or CPT® 72197) for the following:
 - Pelvic floor anatomy and pelvic organ prolapse evaluations if exam and TV ultrasound (CPT® 76830) and/or Pelvic ultrasound (CPT® 76856 or CPT® 76857) are equivocal; or
 - Pre-operative planning for complex organ prolapse when ordered by or in consultation with the operating physician; or
 - Persistent incontinence following surgery
- Mesh and Graft complications
 - Diagnostic evaluation for mesh and graft complications may include colonoscopy, cystoscopy, and/or urodynamics
 - Transvaginal (TV) ultrasound (CPT® 76830) and/or Pelvic ultrasound (CPT® 76856 or CPT® 76857), CT Abdomen and/or Pelvis, contrast as requested, MRI Pelvis without contrast or without and with contrast (CPT® 72195 or CPT® 72197) depending on the mesh and graft complication
- Sacral osteomyelitis may be a complication of sacrocolpopexy. MRI Pelvis with and without contrast (CPT® 72197) is indicated for lower back pain and/or suspected sacral osteomyelitis after this procedure.
- MRI (MRI Pelvis without contrast CPT® 72195) for Defecography is considered investigational/experimental by UHC.

Fecal Incontinence (PV-22.4)

PV.IN.0022.4.U

v2.0.2024

The evaluation of fecal incontinence generally proceeds as follows:

- Determine the severity of the incontinence (Bristol Stool Scale, Fecal Incontinence Severity Index, etc.)
- History and Physical to include digital rectal examination and perianal pinprick (to assess for neurogenic causes)
- Trial of conservative management
- Diagnostic Testing if symptoms persist to include:
 - Ano-rectal Manometry
 - Balloon Expulsion Test
 - Endoanal ultrasound (CPT® 76872) to confirm sphincter defects in individuals with suspected sphincter injury (e.g. history of vaginal delivery or anorectal surgery)
 - MRI Pelvis (CPT® 72197) can be considered if:
 - Ano-rectal manometry suggests weak sphincter pressures AND/OR there is an abnormal balloon expulsion test
- **AND**
 - There has been a failure of a recent trial of conservative management
- **AND**
 - Surgery is being considered
- MRI (MRI Pelvis without contrast (CPT® 72195) for Defecography is considered investigational/experimental by UHC.

Background and Supporting Information

With regards to fecal incontinence ACG Guidelines note that “the internal sphincter is visualized more clearly by endoanal ultrasound, whereas MRI is superior for discriminating between an external anal sphincter tear and a scar and for identifying external sphincter atrophy.

However, guidelines adopted by the American Society of Colon and Rectal Surgeons note that “Endoanal ultrasound is a useful and sensitive tool in the evaluation of patients with FI (fecal incontinence), especially when there is a history of vaginal delivery or anorectal surgery. Ultrasound can reliably identify internal and external sphincter defects that may be associated with sphincter dysfunction.” In addition, the guidelines note “Other modalities (eg, MRI) have shown substantial interobserver variability and, at this point, are likely inferior to ultrasound imaging, but they may provide additional information where endoanal ultrasound is unavailable.”

References (PV-22)

v2.0.2024

1. Wald A, Bharucha AE, Limketkai, B et al. ACG Clinical Guideline: Management of Benign Anorectal Disorders. *American Journal of Gastroenterology*. 2021;116(10). P 1987-2008.
2. Practice Bulletin No. 155. Urinary Incontinence in Women. *Obstetrics & Gynecology*. 2015;126(5). doi:10.1097/aog.0000000000001148 (Reaffirmed 2022)
3. Practice Bulletin No. 214. Pelvic Organ Prolapse. *Obstetrics & Gynecology*. 2019 (Reaffirmed 2021);134:126-42. doi:10.1097/aog.00000000000003519
4. Committee Opinion No. 694. Management of Mesh and Graft Complications in Gynecologic Surgery. *Obstetrics & Gynecology*. 2017 (Reaffirmed 2021);129(4). doi:10.1097/aog.0000000000002022
5. Paquette IM, Varma MG, Kaiser AM, Steele SR, Rafferty JF. The American Society of Colon and Rectal Surgeons' Clinical Practice Guideline for the Treatment of Fecal Incontinence. *Diseases of the Colon & Rectum*. 2015;58(7):623-636. doi:10.1097/dcr.0000000000000397
6. Chung DE, Yurteri-Kaplan LA, Asatiani T, Brennand EA, Wang A, Grimes CL. Female Pelvic Medicine & Reconstructive Surgery (FPMRS) challenges on behalf of the collaborative research in pelvic surgery consortium (CoRPS): managing complicated cases series 2: management of urinary incontinence in a neurogenic patient. *International Urogynecology Journal*. 2018;30(2):193-196. doi:10.1007/s00192-018-3806-0
7. Tan C, Geng J, Tang J, Yang X. The relationship between obstructed defecation and true rectocele in patients with pelvic organ prolapse. *Scientific Reports*. 2020;10(1). doi:10.1038/s41598-020-62376-2
8. Volløyhaug I, Rojas RG, Mørkved S, Salvesen KÅ. Comparison of transperineal ultrasound with POP-Q for assessing symptoms of prolapse. *International Urogynecology Journal*. 2018;30(4):595-602. doi:10.1007/s00192-018-3722-3
9. Evaluation of uncomplicated stress urinary incontinence in women before surgical treatment. Committee Opinion No. 603. *The American College of Obstetricians and Gynecologists*. Obstet Gynecol 2014;123:1403–7 (Reaffirmed 2020)
10. American College of Obstetricians and Gynecologists. ACOG practice bulletin no. 210: fecal incontinence. *Obstetrics & gynecology*. 2019 (Reaffirmed 2023); Apr;133(4):e260-73. doi: 10.1097/AOG.
11. Larouche M, Belzile E, Geoffrion R. Surgical Management of Symptomatic Apical Pelvic Organ Prolapse. *Obstetrics & Gynecology*. 2021;137(6):1061-1073. doi:10.1097/aog.00000000000004393
12. Gavlin A, Kierans AS, Chen J, Song C, Guniganti P, Mazzariol FS. Imaging and Treatment of Complications of Abdominal and Pelvic Mesh Repair. *RadioGraphics*. 2020;40(2):432-453. doi:10.1148/rg.2020190106

Patent Urachus (PV-23)

Guideline

Patent Urachus (PV-23.1)

References (PV-23)

Patent Urachus (PV-23.1)

PV.UR.0023.1.A

v2.0.2024

- Drainage from the umbilicus, redness around umbilicus, abdominal pain, or urinary tract infection from persistent fetal connection between the bladder and the umbilicus:
 - Ultrasound (CPT® 76856 or CPT® 76857 and/or CPT® 76700 or CPT® 76705) or voiding cystourethrography (VCUG) (CPT® 74455) for suspected patent urachus
 - CT Pelvis with contrast (CPT® 72193) or MRI Pelvis without contrast (CPT® 72195) or with and without contrast (CPT® 72197) if the ultrasound is equivocal or if additional imaging is needed for surgical planning if there is a suspected urachal carcinoma or other urachal abnormality.

References (PV-23)

v2.0.2024

1. Villavicencio CP, Adam SZ, Nikolaidis P, Yaghmai V, Miller FH. Imaging of the Urachus: Anomalies, Complications, and Mimics. *RadioGraphics*. 2016;36(7):2049-2063. doi:10.1148/rg.2016160062
2. Buddha S, Menias CO, Katabathina VS. Imaging of urachal anomalies. *Abdominal Radiology*. 2019;44(12):3978-3989. doi:10.1007/s00261-019-02205-x
3. Das JP, Vargas, HB, Lee A, Hutchingson B, et al. The urachus revisited: multimodal imaging of benign and malignant urachal pathology. *BR J Radiol*. 2020 Jun; 93 (1110): 20190118.
4. Yacoub JH, Clark JA, PAal EE, Manning MA. Approach to Cystic Lesions in the Abdomen and Pelvis, with Radiologic-Pathologic Correlation. *Radiographics*. Sep-Oct 2021; 41 (5): 1368-1386

Bladder Mass (PV-24)

Guideline

Bladder Mass (PV-24.1)

References (PV-24)

Bladder Mass (PV-24.1)

PV.BL.0024.1.A

v2.0.2024

- Bladder masses incidentally found on other imaging (ultrasound, cystoscopy or KUB):
 - CT Pelvis without contrast (CPT® 72192) for suspected bladder stone if initial imaging is equivocal or if surgery is planned
 - CT Pelvis with and without contrast (CPT® 72194) for suspected bladder diverticuli
- See **Oncology Imaging Guidelines** for biopsy confirmed or suspected malignancy

Background and Supporting Information

Symptoms of bladder mass may include hematuria, urgency, frequency, chronic urinary infection, obstruction or urinary retention.

References (PV-24)

v2.0.2024

1. Dighe MK, Bhargava P, Wright J. Urinary Bladder Masses. *Journal of Computer Assisted Tomography*. 2011;35(4):411-424. doi:10.1097/rct.0b013e31821c2e9d
2. Verma S, Rajesh A, Prasad SR, et al. Urinary Bladder Cancer: Role of MR Imaging. *RadioGraphics*. 2012;32(2):371-387. doi:10.1148/rg.322115125
3. Raman SP, Fishman EK. Bladder Malignancies on CT: The Underrated Role of CT in Diagnosis. *American Journal of Roentgenology*. 2014;203(2):347-354. doi:10.2214/ajr.13.12021
4. Shelmerdine SC, Lorenzo AJ, Gupta AA, Chavhan GB. Pearls and Pitfalls in Diagnosing Pediatric Urinary Bladder Masses. *RadioGraphics*. 2017;37(6):1872-1891. doi:10.1148/rg.2017170031

Ureteral and/or Bladder Trauma or Injury (PV-25)

Guideline

Ureteral and/or Bladder Trauma or Injury (PV-25.1)

References (PV-25)

Ureteral and/or Bladder Trauma or Injury (PV-25.1)

PV.BT.0025.1.A

v2.0.2024

- Abdominal and/or Pelvic ultrasound (CPT® 76700 and/or CPT® 76856) is supported if requested
- CT cystography (CT Pelvis without contrast CPT® 72192) is supported for suspected bladder injury
- CT Abdomen and Pelvis with OR with and without contrast (CPT® 74177 or CPT® 74178) if:
 - Suspected iatrogenic/operative injury OR
 - Blunt trauma and suspected bladder or ureteral injury with one or more of the following (See **Blunt Abdominal Trauma (AB-10.1)** in the Abdomen Imaging Guidelines):
 - Abdominal pain or tenderness
 - Pelvic or femur fracture
 - Hematocrit <30%
 - Hematuria
 - Non-examinable individual (intoxicated, less than fully conscious, Glasgow Coma Scale Score >13, etc.)
 - Evidence of abdominal wall trauma or seat-belt sign
 - Rapid deceleration injury

Background and Supporting Information

Bladder trauma: CT cystography- CT Pelvis without contrast allowing the radiologist or Urologist to instill contrast to r/o bladder injury and/or perforation.

Ureteral injury: *“Iatrogenic ureteral injuries can occur during gynecologic, obstetric, urologic, colorectal, general, or vascular surgery; gynecologic surgery accounts for more than half of all iatrogenic injuries.”*²

References (PV-25)

v2.0.2024

1. Ramchandani P, Buckler PM. Imaging of Genitourinary Trauma. *American Journal of Roentgenology*. 2009;192(6):1514-1523. doi:10.2214/ajr.09.2470
2. Morey AF, Broghammer JA, Hollowell CMP, McKibben MJ, Souter L. Urotrauma Guideline 2020: AUA Guideline. *Journal of Urology*. Published online October 14, 2020. doi:10.1097/ju.0000000000001408
3. Shyu JY, Khurana B, Soto JA, et al. ACR Appropriateness Criteria® Major Blunt Trauma. *Journal of the American College of Radiology*. 2020;17(5):S160-S174. doi:10.1016/j.jacr.2020.01.024
4. Chan DPN, Abujudeh HH, Cushing GL, Novelline RA. CT Cystography with Multiplanar Reformation for Suspected Bladder Rupture: Experience in 234 Cases. *American Journal of Roentgenology*. 2006;187(5):1296-1302. doi:10.2214/ajr.05.0971
5. Jansen JO, Yule SR, Loudon MA. Investigation of blunt abdominal trauma. *BMJ (Clinical research ed)*. 2008;336(7650):938-942. doi:10.1136/bmj.39534.686192.80

Gender Affirmation Surgery; Pelvic (PV-26)

Guideline

Gender Affirmation Surgery; Pelvic (PV-26.1)
References (PV-26)

Gender Affirmation Surgery; Pelvic (PV-26.1)

PV.GA.0026.1A

v2.0.2024

- Preoperative imaging is supported as outlined below if the individual has a health plan benefit covering pelvic gender affirmation surgery. Preoperative imaging is not supported if pelvic gender affirmation surgery is not a health plan covered benefit.
- Preoperative imaging:
 - Metoidioplasty
 - Preoperative imaging is not supported
 - Phalloplasty
 - Muscular flaps used for neophallus creation are generally obtained from anterior lateral thigh (pedicled flap) or forearm (radial free flap)
 - For planned radial free flap, upper extremity CT angiography (CPT® 73206) of anticipated donor site (unilateral) for evaluation of perforator anatomy.
 - For planned anterior lateral thigh flap, bilateral lower extremity CT angiogram (CPT® 73706)
 - If iodinated contrast allergy, MRA (contrast as requested)
 - Vaginoplasty
 - Preoperative imaging is not supported
- Postoperative complications:
 - Doppler ultrasound (CPT)
 - Monitoring of flap perfusion after phalloplasty for suspected vascular insufficiency
 - CT Abdomen and Pelvis OR CT Pelvis (contrast as requested - CPT® 74176, CPT® 74177, CPT® 74178, CPT® 72192, CPT® 72193, or CPT® 72194) for suspected postoperative complications
 - Complications after surgery may include hematoma, seroma, abscesses, fistula, urinary tract injury, etc. (See **Ureteral and/or Bladder Trauma or Injury (PV-25.1)** for ureteral and/or bladder injury)
 - MRI Pelvis with and without contrast (CPT® 72197)
 - Suspected fistula
 - Non diagnostic CT scan AND further imaging is needed for treatment planning

Background and Supporting Information

- Metoidioplasty-Metoidioplasty is a procedure using clitoral hypertrophy and clitoral release to form masculine-appearing external genitalia

- Phalloplasty-Phalloplasty includes the creation of a neophallus using muscular flaps
- Vaginoplasty-Vaginoplasty refers to the surgical creation of a vulva and vaginal canal

References (PV-26)

v2.0.2024

1. Coleman E, Bockting W, Botzer M, et al. Standards of Care for the Health of Transsexual, Transgender, and Gender-Nonconforming People, Version 7. *International Journal of Transgenderism*. 2012;13(4):165-232. doi:10.1080/15532739.2011.700873
2. Hassan O, Sun D, Jha P. Imaging in Gender Affirmation Surgery. *Current Urology Reports*. 2021;22(2). doi:10.1007/s11934-020-01029-3
3. Doo FX, Khorsandi A, Avanesian B, Bowers M, Somwaru AS. Gender Affirmation Surgery: A Primer on Imaging Correlates for the Radiologist. *American Journal of Roentgenology*. 2019;213(6):1194-1203. doi:10.2214/ajr.19.21686
4. Stowell JT, Horowitz JM, Thomas S. Gender-affirming surgical techniques, complications, and imaging considerations for the abdominal radiologist. *Abdom Radiol (NY)*. 2020 Jul;45(7):2036-2048. doi:10.1007/s00261-019-02398-1
5. Stowell JT, Grimstad FW, Kirkpatrick DL, et al. Imaging Findings in Transgender Patients after Gender-affirming Surgery. *RadioGraphics*. 2019;39(5):1368-1392. doi:10.1148/rg.2019190010
6. Health Care for Transgender and Gender Diverse Individuals. ACOG Committee Opinion No. 823. *Obstetrics & Gynecology*. 2021;137(3):e75-e88. doi:10.1097/aog.0000000000004294:e75-88

Table of Contents

Guideline

- General Guidelines (PN-1)
- Focal Neuropathy (PN-2)
- Polyneuropathy (PN-3)
- Brachial Plexus (PN-4)
- Lumbar and Lumbosacral Plexus (PN-5)
- Muscle Disorders (PN-6)
- Magnetic Resonance Neurography (MRN) (PN-7)
- Neuromuscular Disorders (PN-8)
- Peripheral Nerve Sheath Tumors (PNST) (PN-9)
- Nuclear Imaging (PN-10)

General Guidelines (PN-1)

Guideline

Abbreviations for Peripheral Nerve Disorders Imaging Guidelines

General Guidelines (PN-1.0)

References (PN-1)

Abbreviations for Peripheral Nerve Disorders Imaging Guidelines

PN.GG.Abbreviations.A

v1.0.2024

Abbreviations for Peripheral Nerve Disorders Imaging Guidelines	
AIDS	Acquired Immunodeficiency Syndrome
ALS	Amyotrophic Lateral Sclerosis
CIDP	Chronic Inflammatory Demyelinating Polyneuropathy
CNS	central nervous system
CPK	creatinine phosphokinase
CT	computed tomography
EMG	electromyogram
LEMS	Lambert-Eaton Myasthenic Syndrome
MG	myasthenia gravis
MRI	magnetic resonance imaging
MRN	magnetic resonance neurography
MRS	magnetic resonance spectroscopy
NCV	nerve conduction velocity
PET	positron emission tomography
PNS	peripheral nervous system
PNST	Peripheral Nerve Sheath Tumor
POEMS	Polyneuropathy, Organomegaly, Endocrinopathy, M-protein, Skin changes
TOS	Thoracic Outlet Syndrome

General Guidelines (PN-1.0)

PN.GG.0001.0.A

v1.0.2024

- A pertinent clinical evaluation is required before advanced imaging can be considered. The clinical evaluation should include a pertinent history and physical examination, including a neurological examination, (since the onset or change in symptoms), appropriate laboratory studies, non-advanced imaging modalities, and electromyography/nerve conduction (EMG/NCV) studies. Other meaningful technological contact (telehealth visit, telephone call or video call, electronic mail or messaging) since the onset or change in symptoms, by an established individual can serve as a pertinent clinical evaluation.
- Nerve conduction studies are often normal early in the disease course with changes occurring from one to four weeks after symptom onset in the majority of individuals. This will be taken into consideration on a case-by-case basis in regards to the EMG/NCV requirement in each section requirement of **Peripheral Nerve Disorders (PND) Imaging Guidelines**.
- During the current COVID-19 pandemic, with limited face-to-face visits, the electrodiagnostic (EMG/NCV) study requirements may be waived with necessity to be determined by the treating neurologist or team coordinating the individual's care.
- If imaging of peripheral nerves is indicated, ultrasound is the preferred modality for superficial peripheral nerves. MRI may be used for imaging deep nerves such as the lumbosacral plexus or nerves obscured by overlying bone such as the brachial plexus or for surgical planning. CT is limited to cases in which MRI is contraindicated.

References (PN-1)

v1.0.2024

1. Walker FO. Ultrasonography in Peripheral Nervous System Diagnosis. *Continuum (Minneap Minn)*. 2017;23(5):1276-1294. doi: 10.1212/con.0000000000000522.
2. Ohana M, Moser T, Moussaoui A, et al. Current and future imaging of the peripheral nervous system. *Diagn Interv Imaging*. 2014;95(1):17-26. doi: 10.1016/j.diii.2013.05.008.
3. Stoll G, Wilder-Smith E, Bendszus M. Imaging of the peripheral nervous system. *Handb Clin Neurol*. Published online 2013:137-153. doi: 10.1016/b978-0-444-52902-2.00008-4.
4. Russell JA. General Approach to Peripheral Nerve Disorders. *Continuum (Minneap Minn)*. 2017;23(5):1241-1262. doi: 10.1212/con.0000000000000519.
5. Kassardjian CD, Desai U, Narayanaswami P. Practical Guidance for Managing EMG Requests and Testing during the COVID-19 Pandemic. *Muscle Nerve*. Published online April 11, 2020. doi: 10.1002/mus.26891.
6. London ZN. A Structured Approach to the Diagnosis of Peripheral Nervous System Disorders. *Continuum (Minneap Minn)*. 2020;26(5):1130-1160. doi: 10.1212/con.0000000000000922.

Focal Neuropathy (PN-2)

Guideline

Focal Neuropathy (PN-2.1)

References (PN-2)

Focal Neuropathy (PN-2.1)

PN.FN.0002.1.A

v1.0.2024

Focal Disorder	EMG/NCV Initially?	Advanced Imaging
Carpal Tunnel Syndrome	YES	<ul style="list-style-type: none"> When EMG/NCV and clinical findings are equivocal AND only when requested for pre-operative planning, MRI Wrist without contrast (CPT® 73221) is indicated. See <u>Neck (Cervical Spine) Pain Without/With Neurological Features (Including Stenosis) and Trauma (SP-3)</u> in the Spine Imaging Guidelines.
Ulnar Neuropathy	YES	<p>After EMG/NCV, only ONE of the following is indicated if requested for surgical consideration:</p> <ul style="list-style-type: none"> MRI Upper Extremity Joint (Elbow or Wrist) without contrast (CPT® 73221), OR MRI Upper Extremity Non Joint (Forearm or Hand) without contrast (CPT® 73218)
Radial Neuropathy	YES	<ul style="list-style-type: none"> MRI Upper Arm or Forearm without contrast (CPT® 73218) in severe cases when surgery is being considered. MRI Upper Arm or Forearm without and with contrast (CPT® 73220) if there is a suspicion of a nerve tumor such as a neuroma.

Radial Neuropathy Notes: Leads to wrist drop with common sites of entrapment the inferior aspect of the humerus (Saturday night palsy) or the forearm (Posterior Interosseous Syndrome). Entrapment of the nerve at the wrist (Wartenberg syndrome or handcuff palsy) typically spares motor involvement and results only in sensory changes.

Trauma or fractures of the humerus, radius, or ulna can damage the radial nerve.

Focal Disorder	EMG/NCV Initially?	Advanced Imaging
Pudendal Neuropathy ⁽⁷⁻¹²⁾	NO	<ul style="list-style-type: none"> • Documented concern specifically for pudendal neuropathy, pudendal neuralgia, or pudendal entrapment: MRI Pelvis without contrast (CPT® 72195) OR MRI Pelvis without and with contrast (CPT® 72197) • If there is a contraindication to MRI and the above documented concern is present, then ONE of the following is indicated: <ul style="list-style-type: none"> • CT Pelvis without contrast (CPT® 72192) • CT Pelvis with contrast (CPT® 72193) • CT Pelvis without and with contrast (CPT® 72194) • For all other pelvic concerns, see the following Pelvic Imaging Guidelines (as indicated): <ul style="list-style-type: none"> • <u>Pelvic Pain/Dyspareunia Female (PV-11.1)</u> • <u>Impotence/Erectile Dysfunction (PV-17.1)</u> • <u>Male Pelvic Disorders (PV-19.1)</u> • <u>Scrotal Pathology (PV-20.1)</u>
<p>Pudendal Neuropathy Notes: Causes pain, sexual dysfunction, or sensory change in the genitals, perineum, and perianal region. May be caused from trauma, recurrent injury from exercise such as cycling, pelvic mass, or after viral infection (e.g., post-herpetic neuralgia).</p>		
Sciatic Neuropathy	YES	<ul style="list-style-type: none"> • MRI Pelvis without contrast (CPT® 72195) • CT Pelvis without contrast (CPT® 72192) is NOT routinely indicated due to lack of soft tissue contrast. • It should only be performed in the rare circumstance of contrast allergy and/or contraindication to MRI such as pacemaking device.

Focal Disorder	EMG/NCV Initially?	Advanced Imaging
<p>Sciatic Neuropathy Notes: May be caused by trauma to the gluteal area with hematoma, injection palsy, hip or pelvic fractures, or hip replacement (arthroplasty).</p> <p>Piriformis Syndrome involves entrapment of the sciatic nerve at the sciatic notch in the pelvis by a tight piriformis muscle band.</p>		
<p>Femoral Neuropathy</p>	<p>NO</p>	<ul style="list-style-type: none"> • MRI Pelvis without contrast (CPT® 72195)
<p>Femoral Neuropathy Notes: May occur as a complication of pelvic surgery in females or those on anticoagulants with retroperitoneal bleeding, or as a mononeuropathy in diabetics</p>		
<p>Meralgia Paresthetica</p>	<p>NO</p>	<ul style="list-style-type: none"> • MRI Pelvis without contrast (CPT® 72195) is indicated for ANY of the following scenarios: <ul style="list-style-type: none"> • Cases of diagnostic uncertainty • Pre-operative • CT Pelvis without contrast (CPT® 72192) is NOT routinely indicated due to lack of soft tissue contrast. • It should only be performed in the rare circumstance of contrast allergy and/or contraindication to MRI such as pacemaking device.
<p>Meralgia Paresthetica Notes: Sensory loss in the lateral femoral cutaneous nerve as it exits the pelvis under the inguinal ligament (lateral thigh without extension into lower leg), and is usually easily diagnosed based on a careful history and physical exam. EMG/NCV testing is often technically difficult and not required.</p>		
<p>Peroneal Neuropathy</p>	<p>YES</p>	<ul style="list-style-type: none"> • MRI Knee without contrast (CPT® 73721) OR MRI Lower Extremity other than joint without contrast (CPT® 73718) in severe cases when surgery is considered.
<p>Tarsal Tunnel Syndrome</p>	<p>N/A</p>	<ul style="list-style-type: none"> • See Foot (Tarsal Tunnel Syndrome) (MS-27) in the Musculoskeletal Imaging Guidelines.

References (PN-2)

v1.0.2024

1. Andreisek G, Crook DW, Burg D, Marincek B, Weishaupt D. Peripheral Neuropathies of the Median, Radial, and Ulnar Nerves: MR Imaging Features. *RadioGraphics*. 2006;26(5):1267-1287 doi: 10.1148/rg.265055712.
2. Linda DD, Harish S, Stewart BG, Finlay K, Parasu N, Rebello RP. Multimodality Imaging of Peripheral Neuropathies of the Upper Limb and Brachial Plexus. *RadioGraphics*. 2010;30(5):1373-1400. doi: 10.1148/rg.305095169.
3. Hobson-Webb LD, Juel VC. Common Entrapment Neuropathies. *Continuum (Minneapolis)*. 2017;23(2):487-511. doi: 10.1212/con.0000000000000452
4. Tsigoulis G, Alexandrov AV. Ultrasound in Neurology. *Continuum (Minneapolis)*. 2016;22(5):1655-1677. doi: 10.1212/con.0000000000000374.
5. Buchanan BK, Maini K, Varacallo M. Radial Nerve Entrapment. In: *StatPearls*. Treasure Island (FL): StatPearls Publishing; September 4, 2022. <https://pubmed.ncbi.nlm.nih.gov/28613749/>.
6. Kalia V, Jacobson JA. Imaging of Peripheral Nerves of the Upper Extremity. *Radiol Clin N Am*. 2019;57(5):1063-1071. doi: 10.1016/j.rcl.2019.04.001.
7. Kaur J, Leslie SW, Singh P. Pudendal Nerve Entrapment Syndrome. In: *StatPearls*. Treasure Island (FL): StatPearls Publishing; May 30, 2023.
8. Ploteau S, Cardaillac C, Perrouin-Verbe MA, Riant T, Labat JJ. Pudendal Neuralgia Due to Pudendal Nerve Entrapment: Warning Signs Observed in Two Cases and Review of the Literature. *Pain Physician*. 2016; 19(3): E449-E454.
9. Aoun F, Alkassis M, Tayeh GA, et al. Sexual dysfunction due to pudendal neuralgia: a systematic review. *Transl Androl Urol*. 2021;10(6):2500-2511. doi: 10.21037/tau-21-13.
10. Luesma MJ, Galé I, Fernando J. Diagnostic and therapeutic algorithm for pudendal nerve entrapment syndrome. Algoritmo diagnóstico y terapéutico del síndrome de atrapamiento del nervio pudendo. *Med Clin (Barc)*. 2021;157(2):71-78. doi: 10.1016/j.medcli.2021.02.012.
11. Labat JJ, Riant T, Robert R, Amarenco G, Lefaucheur JP, Rigaud J. Diagnostic criteria for pudendal neuralgia by pudendal nerve entrapment (Nantes criteria). *Neurourol Urodyn*. 2008;27(4):306-310. doi: 10.1002/nau.20505.
12. Levesque A, Baurant E, Quistrebert V, et al. Recommendations on the management of pudendal nerve entrapment syndrome: A formalised expert consensus. *Eur J Pain*. 2022;26(1):7-17. doi:10.1002/ejp.1861.

Polyneuropathy (PN-3)

Guideline

Polyneuropathy (PN-3.1)

References (PN-3)

Polyneuropathy (PN-3.1)

PN.PN.0003.1.A

v1.0.2024

Poly-Disorder	EMG/NCV Initially?	Advanced Imaging	Comments
Polyneuropathies with Central Nervous System (CNS) Involvement	YES	If clinical findings point to abnormalities in those areas, then ANY of the following are indicated: <ul style="list-style-type: none"><li data-bbox="699 716 924 926">• MRI Brain without and with contrast (CPT® 70553), AND/OR<li data-bbox="699 940 924 1192">• MRI Cervical Spine without and with contrast (CPT® 72156), AND/OR<li data-bbox="699 1207 924 1459">• MRI Thoracic Spine without and with contrast (CPT® 72157)	Examples: Guillain-Barré syndrome and Lyme disease

Poly-Disorder	EMG/NCV Initially?	Advanced Imaging	Comments
AIDS-Related Cytomegaloviral Neuropathy/Radiculopathy¹	YES	<ul style="list-style-type: none"> • MRI Lumbar Spine without and with contrast (CPT® 72158) • If concern for myelopathy, ANY of the following imaging are ALSO indicated: <ul style="list-style-type: none"> • MRI Cervical Spine without and with contrast (CPT® 72156), AND/OR • MRI Thoracic Spine without and with contrast (CPT® 72157) 	<ul style="list-style-type: none"> • Urinary retention and a clinically confusing picture in the legs. • For myelopathic signs and symptoms, see <u>Myelopathy (SP-7.1)</u>.
Chronic Inflammatory Demyelinating Polyneuropathy (CIDP)	YES	MRI Lumbar Spine without and with contrast (CPT® 72158) if uncertain following EMG/NCV. <ul style="list-style-type: none"> • See <u>Brachial Plexus (PN-4.1)</u>, <u>Lumbar and Lumbosacral Plexus (PN-5.1)</u>, and <u>Muscle Diseases (PN-6.2)</u> 	

Poly-Disorder	EMG/NCV Initially?	Advanced Imaging	Comments
Multifocal Motor Neuropathy	YES		If diagnosis is uncertain following EMG/NCV, MRI of the Brachial Plexus is supported with ONE of the following: <ul style="list-style-type: none"> • MRI Upper Extremity other than joint without and with contrast (CPT® 73220) • MRI Chest without and with contrast (CPT® 71552) • MRI Neck without and with contrast (CPT® 70543)
POEMS (Polyneuropathy, Organomegaly, Endocrinopathy, M-protein, Skin changes)	YES	Advanced imaging is for the non-neurological etiologies of this rare osteosclerotic plasmacytoma syndrome.	See Multiple Myeloma and Plasmacytomas (ONC-25) in the Oncology Imaging Guidelines.
Subacute Sensory Neuronopathy & Other Paraneoplastic Demyelinating Neuropathies	YES		<ul style="list-style-type: none"> • Advanced imaging should be guided by specific clinical concern (see relevant guideline). • For evaluation of suspected paraneoplastic syndromes, see Paraneoplastic Syndromes (ONC-30.3) in the Oncology Imaging Guidelines.

Background and Supporting Information

- Central Nervous System (CNS) Imaging (Brain and Spine) is not required for Polyneuropathy without CNS signs/symptoms.⁶
- Distal symmetric polyneuropathy is the most common pattern of generalized peripheral neuropathy. It is typically sensory predominant and may demonstrate neurological abnormalities including reduced or absent deep tendon reflexes (DTRs), reduced sensation to multiple testing modalities (vibration, proprioception, etc). In more advanced staging, mild motor weakness may be present. It is most often associated with diabetes and metabolic abnormalities. In the absence of atypical findings (such as asymmetrical presentation, significant weakness, or upper motor neuron exam findings such as hyperreflexia or spasticity), distal symmetric polyneuropathy does not require central nervous system (CNS) imaging.⁶

References (PN-3)

v1.0.2024

1. Harrison TB, Smith B. Neuromuscular Manifestations of HIV/AIDS. *J Clin Neuromuscul Dis.* 2011;13(2):68-84. doi: 10.1097/cnd.0b013e318221256f.
2. Eftimov F, Lucke IM, Querol LA, Rajabally YA, Verhamme C. Diagnostic challenges in chronic inflammatory demyelinating polyradiculoneuropathy. *Brain.* 2020;143(11):3214-3224. doi: 10.1093/brain/awaa265.
3. Saperstein D. Chronic Acquired Demyelinating Polyneuropathies. *Semin Neurol.* 2008;28(2):168-184. doi: 10.1055/s-2008-1062268.
4. Binks S, Uy C, Honnorat J, Irani SR. Paraneoplastic neurological syndromes: a practical approach to diagnosis and management. *Pract Neurol.* 2022;22(1):19-31. doi: 10.1136/practneurol-2021-003073.
5. Stoll G, Wilder-Smith E, Bendszus M. Imaging of the peripheral nervous system. *Handb Clin Neurol.* Published online 2013:137-153. doi: 10.1016/b978-0-444-52902-2.00008-4.
6. London ZN. A Structured Approach to the Diagnosis of Peripheral Nervous System Disorders. *Continuum (Minneap Minn).* 2020;26(5):1130-1160. doi: 10.1212/con.0000000000000922.

Brachial Plexus (PN-4)

Guideline

Brachial Plexus (PN-4.1)

References (PN-4)

Brachial Plexus (PN-4.1)

PN.BP.0004.1.A

v1.0.2024

- EMG/NCV examination is required prior to advanced imaging except in cases of malignant infiltration or radiation plexitis as detailed below.⁸⁻¹²

Brachial Plexus Imaging		
Indication	Imaging	Notes
Malignant infiltration (EMG Not required)	Any ONE of the following: <ul style="list-style-type: none"> MRI Upper Extremity other than joint without contrast (CPT® 73218) MRI Upper Extremity other than joint without and with contrast (CPT® 73220) MRI Chest without contrast (CPT® 71550) MRI Chest without and with contrast (CPT® 71552) MRI Neck without contrast (CPT® 70540) MRI Neck without and with contrast (CPT® 70543) 	
Radiation plexitis to rule out malignant infiltration (EMG not required)		
Neurogenic Thoracic Outlet Syndrome (TOS)¹⁰		
Preoperative work up requiring evaluation of the brachial plexus		
Brachial plexitis (Parsonage-Turner Syndrome or painful brachial amyotrophy)	<ul style="list-style-type: none"> Any ONE of the above <u>studies</u> AND	<ul style="list-style-type: none"> For concern for cervical radiculopathy, see <u>Neck (Cervical Spine) Pain Without/With Neurological Features (Including Stenosis) and Trauma (SP-3)</u> For details of brachial plexitis (Parsonage-Turner Syndrome), see <u>Background and Supporting Information.</u>
Traumatic injury¹³	<ul style="list-style-type: none"> If concern for radiculopathy, MRI Cervical Spine without contrast (CPT® 72141) 	

MRI Chest and Neck are inherently bilateral, whereas MRI Upper Extremity is unilateral.

- If MRI is not available or is contraindicated, CT offers the next highest level of anatomic visualization and can characterize local osseous or vascular anatomy and injury. In this circumstance, when the above criteria are met, only **ONE** of the following studies is indicated:
 - CT Neck Soft Tissue:** CT Neck without contrast (CPT® 70490); **or**, CT Neck with contrast (CPT® 70491); **or**, CT Neck without and with contrast (CPT® 70492)

- **CT Upper Extremity:** CT Upper Extremity without contrast (CPT® 73200); **or**, CT Upper Extremity with contrast (CPT® 73201); **or**, CT Upper Extremity without and with contrast (CPT® 73202)
- **CT Chest:** CT Chest without contrast (CPT® 71250); **or**, CT Chest with contrast (CPT® 71260); **or**, CT Chest without and with contrast (CPT® 71270)
- MRI should be performed prior to consideration of PET imaging.
 - For PET imaging, see **PET Imaging in Oncology (ONC-1.4)** in the Oncology Imaging Guidelines.

Background and Supporting Information

- Brachial plexitis (Parsonage-Turner syndrome or painful brachial amyotrophy) is a self-limited syndrome characterized by initial shoulder region pain followed by weakness of specific muscles in a pattern which does not conform to involvement of a single root or distal peripheral nerve.

References (PN-4)

v1.0.2024

1. Wittenberg KH, Adkins MC. MR Imaging of Nontraumatic Brachial Plexopathies: Frequency and Spectrum of Findings. *RadioGraphics*. 2000;20(4):1023-1032. doi: 10.1148/radiographics.20.4.g00j1091023
2. Bykowski J, Aulino JM, Berger KL, et al. ACR Appropriateness Criteria® Plexopathy. *J Am Coll Radiol*. 2017;14(5S):S225-S233. doi: 10.1016/j.jacr.2017.02.002.
3. Kori SH, Foley KM, Posner JB. Brachial plexus lesions in patients with cancer=100 cases. *Neurology*. 1981;31(1):45-50. doi: 10.1212/WNL.31.1.45.
4. Qayyum A, MacVicar AD, Padhani AR, Revell P, Husband JES. Symptomatic Brachial Plexopathy following Treatment for Breast Cancer: Utility of MR Imaging with Surface-Coil Techniques. *Radiology*. 2000;214(3):837-842. doi: 10.1148/radiology.214.3.r00mr11837.
5. Miller JD, Pruitt S, McDonald TJ. Acute brachial plexus neuritis: an uncommon cause of shoulder pain. *Am Fam Physician*. 2000;62(9):2067-2072.
6. Ohana M, Moser T, Moussaoui A, et al. Current and future imaging of the peripheral nervous system. *Diagn Interve Imaging*. 2014;95(1):17-26. doi: 10.1016/j.diii.2013.05.008.
7. Szaro P, McGrath A, Ciszek B, Geijer M. Magnetic resonance imaging of the brachial plexus. Part 1: Anatomical considerations, magnetic resonance techniques, and non-traumatic lesions. *Eur J Radiol Open*. 2022;9:100392. doi:10.1016/j.ejro.2021.100392.
8. Szaro P, Geijer M, Ciszek B, McGrath A. Magnetic resonance imaging of the brachial plexus. Part 2: Traumatic injuries. *Eur J Radiol Open*. 2022;9:100397. doi: 10.1016/j.ejro.2022.100397.
9. Magill ST, Brus-Ramer M, Weinstein PR, Chin CT, Jacques L. Neurogenic thoracic outlet syndrome: current diagnostic criteria and advances in MRI diagnostics. *Neurosurg*. 2015;39(3):E7. doi: 10.3171/2015.6.focus15219.
10. Mallouhi A, Marik W, Prayer D, Kainberger F, Bodner G, Kasprian G. 3T MR tomography of the brachial plexus: Structural and microstructural evaluation. *Eur J Radiol*. 2012;81(9):2231-2245. doi: 10.1016/j.ejrad.2011.05.021.
11. Gilcrease-Garcia BM, Deshmukh SD, Parsons MS. Anatomy, Imaging, and Pathologic Conditions of the Brachial Plexus. *RadioGraphics*. 2020;40(6):1686-1714. doi: 10.1148/rg.2020200012.
12. Wade RG, Takwoingi Y, Wormald JCR, et al. MRI for Detecting Root Avulsions in Traumatic Adult Brachial Plexus Injuries: A Systematic Review and Meta-Analysis of Diagnostic Accuracy. *Radiology*. 2019;293(1):125-133. doi: 10.1148/radiol.2019190218.

Lumbar and Lumbosacral Plexus (PN-5)

Guideline

Lumbar and Lumbosacral Plexus (PN-5.1)

References (PN-5)

Lumbar and Lumbosacral Plexus (PN-5.1)

PN.LP.0005.1.A

v1.0.2024

- EMG/NCV examination is required prior to advanced imaging.
 - EMG/NCV is **NOT** required if there is concern for malignant infiltration.
- For suspected lumbar and/or lumbosacral plexopathy, **ONE** of the following is indicated
 - MRI Pelvis without contrast (CPT® 72195) with fat suppression imaging, **OR**
 - MRI Pelvis without and with contrast (CPT® 72197) with fat suppression imaging, **OR**
 - MRI Abdomen without contrast (CPT® 74181) and MRI Pelvis without contrast (CPT® 72195) with fat suppression imaging, **OR**
 - MRI Abdomen without and with contrast (CPT® 74183) and MRI Pelvis without and with contrast (CPT® 72197) with fat suppression imaging
- If MRI is not available or is contraindicated, CT offers the next highest level of anatomic visualization and can characterize local osseous or vascular anatomy and injury. In this circumstance, when requested for suspected lumbar and/or lumbosacral plexopathy, **EITHER** of the following is indicated:
 - CT Pelvis with contrast (CPT® 72193), **OR**
 - CT Abdomen and Pelvis with contrast (CPT® 74177)
- If suspected lumbar and/or lumbosacral plexopathy is due to a traumatic injury, then MRI Lumbar Spine without contrast (CPT® 72148) is **ALSO** indicated.
 - See **Low Back (Lumbar Spine) Trauma (SP 6.2)**
- For PET imaging, see **PET Imaging in Oncology (ONC-1.4)** in the Oncology Imaging Guidelines.
 - However, EMG is not needed if concern for malignant infiltration
 - If MRI is contraindicated, CT offers the next highest level of anatomic visualization and can characterize local osseous or vascular anatomy and injury.

Background and Supporting Information

- Lumbar and lumbosacral plexopathy may be caused by any of the following:
 - Malignant infiltration
 - Radiation
 - Traumatic injury
 - Inflammation including sarcoidosis and infection
 - Toxic including iatrogenic during delivery (obstetric) or related to nerve blocks (ex. Botox®)
 - Metabolic including etiologies including diabetes

References (PN-5)

v1.0.2024

1. Bykowski J, Aulino JM, Berger KL, et al. ACR Appropriateness Criteria® Plexopathy. *J Am Coll Radiol*. 2017;14(5S):S225-S233. doi: 10.1016/j.jacr.2017.02.002.
2. Pinto MV, Ng PS, Howe BM, et al. Lumbosacral Radiculoplexus Neuropathy. *Neurology*. 2021;96(16):e2098-e2108. doi: 10.1212/wnl.00000000000011799.
3. Dyck PJB, Thaisetthawatkul P. Lumbosacral Plexopathy. *Continuum (Minneap Minn)*. 2014;20:1343-1358. doi: 10.1212/01.con.0000455877.60932.d3.

Muscle Disorders (PN-6)

Guideline

Neuromuscular Junction Disorders (PN-6.1)

Muscle Diseases (PN-6.2)

Gaucher Disease (Storage Disorders) (PN-6.3)

References (PN-6)

Neuromuscular Junction Disorders (PN-6.1)

PN.MD.0006.1.A

v1.0.2024

Myasthenia Gravis (MG)

Myasthenia Gravis (MG) is associated with thymic disease.

- After an established diagnosis of MG or when MG is suspected by a neurologist, rheumatologist, or ophthalmologist, ONE of the following is indicated^{1,4}:
 - CT Chest with contrast (CPT[®] 71260), **OR**
 - CT Chest without contrast (CPT[®] 71250), **OR**
 - MRI Chest without and with contrast (CPT[®] 71552), **OR**
 - MRI Chest without contrast (CPT[®] 71550)
- Repeat of **ANY ONE** of the above imaging studies is indicated if the initial imaging study was negative for **ANY** of the following scenarios:
 - Symptoms of chest mass
 - Rising anti-striated muscle antibody titers
 - Need for pre-operative evaluation (clinical presentation, electro-diagnostic studies, and antibody titers)

Lambert–Eaton Myasthenic Syndrome (LEMS)

Lambert–Eaton Myasthenic Syndrome (LEMS) is associated with malignancies, especially small cell lung cancer.

- For a suspected diagnosis, **ANY** of the following are indicated: CT Chest with contrast (CPT[®] 71260) **AND/OR** CT Abdomen and Pelvis with contrast (CPT[®] 74177)^{5,6}
 - See **Paraneoplastic Syndromes (ONC-30.3)**
- If initial CT was negative and there is persistent suspicion, **ANY** of the above imaging studies are indicated every 6 months for 2 years from date of initial negative imaging.²⁷

Stiff-Person Syndrome

Stiff-person syndrome is associated with cancers such as, but not limited to, small cell lung cancer, pancreatic neuroendocrine cancer, and breast cancer.^{7,8}

- If Stiff-person syndrome is suspected based on clinical findings, **ANY** of the following are indicated:
 - **Abdomen/Pelvis:** CT Abdomen and Pelvis with contrast (CPT® 74177) **or** CT Abdomen and Pelvis without and with contrast (CPT® 74178); **OR**, MRI Abdomen without and with contrast (CPT® 74183) **and** MRI Pelvis without and with contrast (CPT® 72197)
 - **Chest:** CT Chest with contrast (CPT® 71260) **or** CT Chest without contrast (CPT® 71250)
 - **Symptomatic Body Areas:** CT with contrast **or** MRI without and with contrast of any other symptomatic body areas

Background and Supporting Information

- Myasthenia gravis is an autoimmune disease of the neuromuscular junctions, manifested by fatigable weakness of the cranial nerves (examples - ocular: ptosis, diplopia; bulbar: dysphagia, dysarthria, dysphonia), as well as generalized limb weakness, depending on the severity of the disease. Associated antibodies: acetylcholine receptor (AChR), muscle specific kinase (MuSK).
- Lambert Eaton Myasthenic Syndrome (LEMS) is also an autoimmune disease affecting the neuromuscular junction presenting with ocular and bulbar symptoms and proximal limb weakness. Associated antibodies: P/Q voltage-gated calcium channel (VGCC).
- LEMS can occur as a paraneoplastic syndrome associated with malignancy (cancer-associated LEMS) or as an autoimmune phenomenon in the absence of malignancy (non-tumor LEMS). Between 50% and 60% of all LEMS cases are associated with malignancy, particularly small cell lung carcinoma (SCLC), although LEMS has been described in individuals with non–small cell and mixed-cell lung carcinomas, neuroendocrine tumors such as prostate cancer, thymoma, and lymphoproliferative disorders.⁵
- Stiff-person syndrome is an autoimmune disease associated with muscle spasm and muscle rigidity affecting the trunk and limb muscles. Associated antibodies: Glutamic acid decarboxylase (GAD).

Muscle Diseases (PN-6.2)

PN.MD.0006.2.A

v1.0.2024

- MRI may be helpful in demonstrating abnormalities in muscles that are difficult to examine or not clinically weak and can help distinguish between different types of muscle disease. MRI is also useful in determining sites for muscle biopsy.

Imaging for Muscle Disease		
Disease	Indication	Indication Imaging
Any Known or Suspected Muscle Disease	To plan muscle biopsy	Typically an affected muscle is imaged.
Myopathy or Myositis	Additional evaluation <u>after</u> clinical exam, EMG/NCV, OR labs	<ul style="list-style-type: none"> • Upper Extremity: MRI Upper Extremity other than joint without contrast (CPT® 73218); OR, MRI Upper Extremity other than joint without and with contrast (CPT® 73220)*
Inflammatory Muscle Diseases <ul style="list-style-type: none"> • Dermatomyositis • Polymyositis • Inclusion body myositis 	<ul style="list-style-type: none"> • Evaluation of differential diagnosis • Selection of biopsy site • Clinical concern for progression • Treatment monitoring • Detection of occult malignancy 	<p>AND/OR</p> <ul style="list-style-type: none"> • Lower Extremity: MRI Lower Extremity other than joint without contrast (CPT® 73718); OR, MRI Lower Extremity other than joint without and with contrast (CPT® 73720)* <p>* When indication column criteria are met, bilateral studies are supported if requested</p>

For interstitial lung disease associated with inflammatory myopathies, see

Interstitial Lung Disease (ILD)/Diffuse Lung Disease (DLD) (CH-11.1)

in the Chest Imaging Guidelines.

- For dermatomyositis and polymyositis with concern for occult neoplasm, see **Paraneoplastic Syndromes (ONC-30.3)** in the Oncology Imaging Guidelines.

Gaucher Disease (Storage Disorders) (PN-6.3)

PN.MD.0006.3.A

v1.0.2024

Imaging for Gaucher Disease

Initial Imaging

- MRI Lumbar Spine without contrast (CPT® 72148)
- Bilateral femurs with MRI Lower Extremity, other than joint, without contrast (CPT® 73718)
- MRI Abdomen without contrast (CPT® 74181)
- DXA scan
- CT Chest without contrast (CPT® 71250) for individuals with new or worsening pulmonary symptoms

Every 12 months

- To assess treatment response for individuals on enzyme replacement therapy or assess disease progression for individuals in surveillance
 - MRI Lumbar Spine without contrast (CPT® 72148)
 - Bilateral femurs with MRI Lower Extremity, other than joint, without contrast (CPT® 73718)
 - MRI Abdomen without contrast (CPT® 74181)
 - CT Chest without contrast (CPT® 71250) for individuals with documented pulmonary involvement

New or worsening pulmonary symptoms

- CT Chest without contrast (CPT® 71250)

DXA scans

- Every 12-24 months until it is normal
- Enzyme replacement therapy dose change
- Every 3 years

Acute bone pain

- X-ray
 - MRI of affected areas with and without contrast if x-ray is non-diagnostic or indicates the need for further imaging, such as equivocal for osteonecrosis, infection, or malignancy

- PET/CT imaging is considered **investigational** in the evaluation of Gaucher disease. ¹⁸F-FDG does not reliably detect Gaucher disease in the marrow, and other isotopes are not yet FDA-approved for clinical use.

Background and Supporting Information

- Gaucher disease is group of autosomal recessive inborn errors of metabolism characterized by lack of the enzyme acid β -glucuronidase with destructive ceramide storage in various tissues. Gaucher disease is a treatable disorder (enzyme replacement) in which the liver, spleen, and bone marrow/bones are the most affected organs. Diagnosis is established by decreased enzyme activity or genetic testing.
- Three major types of Gaucher disease are recognized:
 - **Type I** (non-neuropathic form or adult form): progressive hepatomegaly, splenomegaly, anemia and thrombocytopenia, and marked skeletal involvement; lungs and kidneys may also be involved, but central nervous system is spared
 - **Type II** (acute neuropathic form or infantile form): severe progressive neurological involvement and death by 2 to 4 years of age; hepatomegaly, splenomegaly, is also present (usually evident by 6 months of age)
 - **Type III**: type I with neurological involvement and slowly progressive disease. Onset may be present before two years of age with survival to the third or fourth decade of life.
- Additionally, there is a perinatal-lethal and a cardiovascular form. The cardiovascular form involves the heart, spleen and eyes. Note that cardiopulmonary complications may be present, with varying frequency and severity, in all subtypes.
- Individuals with Gaucher disease are at risk for osteonecrosis, osteomyelitis, and bony tumors

References (PN-6)

v1.0.2024

1. National Comprehensive Cancer Network® (NCCN®). NCCN Clinical Practice Guidelines in Oncology (NCCN Guidelines®): Thymoma and Thymic Carcinomas Version 1.2023. December 22, 2022. Referenced with permission from the NCCN Clinical Practice Guidelines in Oncology (NCCN Guidelines®) for Thymoma and Thymic Carcinomas V.1.2023. ©National Comprehensive Cancer Network, Inc. 2022. All rights reserved. Accessed July 28, 2023. The NCCN Guidelines® and illustrations herein may not be reproduced in any form for any purpose without the express written permission of the NCCN. To view the most recent and complete version of the NCCN Guidelines®, go online to NCCN.org.
2. Narayanaswami P, Sanders DB, Wolfe G, et al. International Consensus Guidance for Management of Myasthenia Gravis: 2020 Update. *Neurology*. 2021;96(3):114-122. doi: 10.1212/WNL.0000000000001124.
3. Hehir MK 2nd, Li Y. Diagnosis and Management of Myasthenia Gravis. *Continuum (Minneap Minn)*. 2022;28(6):1615-1642. doi: 10.1212/CON.0000000000001161.
4. Tuan PA, Vien MV, Dong HV, Sibell D, Giang BV. The Value of CT and MRI for Determining Thymoma in Patients with Myasthenia Gravis. *Cancer Control*. 2019;26(1):1073274819865281. doi: 10.1177/1073274819865281.
5. Raja SM. Lambert-Eaton Myasthenic Syndrome and Botulism. *Continuum (Minneap Minn)*. 2022;28(6):1596-1614. doi: 10.1212/CON.0000000000001205.
6. Kesner VG, Oh SJ, Dimachkie MM, Barohn RJ. Lambert-Eaton Myasthenic Syndrome. *Neurol Clin*. 2018;36(2):379-394. doi: 10.1016/j.ncl.2018.01.008.
7. Newsome SD, Johnson T. Stiff person syndrome spectrum disorders; more than meets the eye. *J Neuroimmunol*. 2022;369:577915. doi: 10.1016/j.jneuroim.2022.577915.
8. Dade M, Berzero G, Izquierdo C, et al. Neurological Syndromes Associated with Anti-GAD Antibodies. *Int J Mol Sci*. 2020;21(10):3701. Published 2020 May 24. doi: 10.3390/ijms21103701.
9. Manousakis G. Inflammatory Myopathies. *Continuum (Minneap Minn)*. 2022;28(6):1643-1662. doi: 10.1212/CON.0000000000001179.
10. Malartre S, Bachasson D, Mercy G, et al. MRI and muscle imaging for idiopathic inflammatory myopathies. *Brain Pathol*. 2021;31(3):e12954. doi: 10.1111/bpa.12954.
11. Goyal NA. Inclusion Body Myositis. *Continuum (Minneap Minn)*. 2022;28(6):1663-1677. doi: 10.1212/CON.0000000000001204.
12. Maas M, Poll LW, Terk MR. Imaging and quantifying skeletal involvement in Gaucher disease. *Br J Radiol*. 2002;75(suppl_1):A13-A24. doi: 10.1259/bjr.75.suppl_1.750013.
13. Giraldo P, Pocióvi M, Pérez-Calvo J, Rubio-Félix D, Giralt M. Report of the Spanish Gaucher's disease registry: clinical and genetic characteristics. *Haematologica*. 2000;85(8):792-799.
14. London ZN. A Structured Approach to the Diagnosis of Peripheral Nervous System Disorders. *Continuum (Minneap Minn)*. 2020;26(5):1130-1160. doi: 10.1212/CON.0000000000000922.
15. Silvestri NJ. A Symptoms and Signs Approach to the Patient with Neuromuscular Weakness. *Continuum (Minneap Minn)*. 2022;28(6):1580-1595. doi: 10.1212/CON.0000000000001150.
16. Pastores GM, Hughes DA. Gaucher Disease. In: Adam MP, Ardinger HH, Pagon RA, et al., eds. *GeneReviews® [Internet]*. 2000 Jul 27 [Updated 2018 Jun 21]. Seattle (WA): University of Washington, Seattle; 1993-2022. Available from: <https://www.ncbi.nlm.nih.gov/books/NBK1269/>.
17. Degnan AJ, Ho-Fung VM, Ahrens-Nicklas RC, et al. Imaging of non-neuronopathic Gaucher disease: recent advances in quantitative imaging and comprehensive assessment of disease involvement. *Insights Imaging*. 2019;10(1). doi: 10.1186/s13244-019-0743-5.
18. Kaplan P, Baris H, De Meirleir L, et al. Revised recommendations for the management of Gaucher disease in children. *Eur JPediatr*. 2012;172(4):447-458. doi: 10.1007/s00431-012-1771-z.
19. Simpson WL, Hermann G, Balwani M. Imaging of Gaucher Disease. *World J Radiol*. 2014;6(9):657-668. doi: 10.4329/wjr.v6.i9.657.
20. Leeuwenberg KE, van Alfen N, Christopher-Stine L, et al. Ultrasound can differentiate inclusion body myositis from disease mimics. *Muscle Nerve*. 2020;61(6):783-788. doi: 10.1002/mus.26875.
21. Tudorancea AD, Ciurea PL, Vreju AF, et al. A Study on Dermatomyositis and the Relation to Malignancy. *Curr Health Sci J*. 2021;47(3):377-382. doi: 10.12865/CHSJ.47.03.07.
22. Lancaster E. Paraneoplastic Disorders. *Continuum (Minneap Minn)*. 2017;23(6, Neuro-oncology):1653-1679. doi: 10.1212/CON.0000000000000542.
23. Guimaraes JB, Cavalcante WCP, Cruz IAN, et al. Musculoskeletal Ultrasound in Inclusion Body Myositis: A Comparative Study with Magnetic Resonance Imaging. *Ultrasound Med Biol*. 2021;47(8):2186-2192. doi: 10.1016/j.ultrasmedbio.2021.04.019.
24. Day JA, Bajic N, Gentili S, Patel S, Limaye V. Radiographic patterns of muscle involvement in the idiopathic inflammatory myopathies. *Muscle Nerve*. 2019;60(5):549-557. doi: 10.1002/mus.26660.

25. Pilania K, Jankharia B. Role of MRI in idiopathic inflammatory myopathies: a review article. *Acta Radiol.* 2022;63(2):200-213. doi: 10.1177/0284185121990305.
26. Guimarães JB, Nico MA, Omond AG, et al. Diagnostic Imaging of Inflammatory Myopathies: New Concepts and a Radiological Approach. *Curr Rheumatol Rep.* 2019;21(3):8. Published 2019 Feb 14. doi: 10.1007/s11926-019-0807.
27. Flanagan EP. Paraneoplastic Disorders of the Nervous System. *Continuum (Minneap Minn).* 2020; 26(6): 1602-1628. doi: 10.1212/CON.0000000000000941.

Magnetic Resonance Neurography (MRN) (PN-7)

Guideline

Magnetic Resonance Neurography (MRN) (PN-7.1)

References (PN-7)

Magnetic Resonance Neurography (MRN) (PN-7.1)

PN.MR.0007.1.A

v1.0.2024

- MRN is supported when **ALL** of the following criteria are met:
 - The study is to evaluate a traumatic or compressive focal neuropathy or a brachial plexus injury.
 - The study is requested by a neurosurgeon, orthopedic surgeon, neurologist, or podiatrist after an in-person clinical evaluation **AND** when surgery is being considered.
 - EMG/NCV has been performed and results provided.
 - The diagnosis remains unclear following prior imaging of the region with x-ray, ultrasound, or conventional imaging (CT or MRI).
 - For conventional imaging criteria, see **Focal Neuropathy (PN-2.1)** and **Brachial Plexus (PN-4.1)**.
- MRN is reported as **ONE** of the following:
 - Unlisted MRI procedure code (CPT® 76498), **OR**
 - MRI extremity with **ONE** of the following codes:
 - MRI Upper Extremity, other than joint, without contrast (CPT® 73218)
 - MRI Upper Extremity, other than joint, without and with contrast (CPT® 73220)
 - MRI Lower Extremity, other than joint, without contrast (CPT® 73718)
 - MRI Lower Extremity, other than joint, without and with contrast (CPT® 73720)
- MRN for **ANY** other indication is considered **NOT medically necessary** at this time, including for assessment of lumbosacral plexopathy, neuromuscular disease, and polyneuropathy.

Background and Supporting Information

Magnetic resonance neurography utilizes standard MRI equipment with sequences and technology that allow for optimized viewing of the peripheral nerve. MRN creates greater contrast between the nerve and other surrounding soft tissue to allow a detailed view of the nerve tissue and layers. This allows for more accurate diagnosis of the location and degree of nerve injury.

References (PN-7)

v1.0.2024

1. Chhabra A, Belzberg AJ, Rosson GD, et al. Impact of high resolution 3 tesla MR neurography (MRN) on diagnostic thinking and therapeutic patient management. *Eur Radiol.* 2016;26(5):1235-1244. doi: 10.1007/s00330-015-3958-y.
2. Chhabra A, Madhuranthakam AJ, Andreisek G. Magnetic resonance neurography: current perspectives and literature review. *Eur Radiol.* 2018;28(2):698-707. doi: 10.1007/s0030-017-4976-8.
3. Holzgrefe RE, Wagner ER, Singer AD, Daly CA. Imaging of the peripheral nerve: concepts and future direction of magnetic resonance neurography and ultrasound. *J Hand Surg Am.* 2019;44(12):1066-1079. doi: 10.1016/i.ihsa.2019.06.021.
4. Sneag DB, Queler S. Technological advancements in magnetic resonance neurography. *Curr Neurol Neurosci Rep.* 2019;19(10):75. Published 2019 Aug 24. doi: 10.1007/s11910-019-0996-x.

Neuromuscular Disorders (PN-8)

Guideline

Motor Neuron Disease/Amyotrophic Lateral Sclerosis (ALS) (PN-8.1)

Spinal Muscular Atrophy (PN-8.2)

Fasciculations (PN-8.3)

References (PN-8)

Motor Neuron Disease/Amyotrophic Lateral Sclerosis (ALS) (PN-8.1)

PN.ND.0008.1.A

v1.0.2024

- A neurological examination is **NOT** required for an individual with established diagnosis of motor neuron disease/ALS **or** when diagnosis is suspected by a neurologist, geneticist, or a physical medicine and rehabilitation (PM&R) specialist.
- For initial evaluation of suspected motor neuron disease/ALS, **ANY** of the following are indicated
 - **Brain:** MRI Brain without contrast (CPT® 70551) **or** MRI Brain without and with contrast (CPT® 70553), **AND/OR**
 - **Cervical Spine:** MRI Cervical Spine without contrast (CPT® 72141) **or** MRI Cervical Spine without and with contrast (CPT® 72156), **AND/OR**
 - **Thoracic Spine:** MRI Thoracic Spine without contrast (CPT® 72146) **or** MRI Thoracic Spine without and with contrast (CPT® 72157), **AND/OR**
 - **Lumbar Spine:** MRI Lumbar Spine without contrast (CPT® 72148) **or** MRI Lumbar Spine without and with contrast (CPT® 72158)
- Repeat imaging can be evaluated based on the appropriate **Spine Imaging Guidelines**.

Background and Supporting Information

- Evidence of lower motor neuron dysfunction in a muscle may include clinical examination of muscle weakness/wasting or EMG abnormalities to meet the criteria for the diagnosis of ALS.
- Motor Neuron Diseases (also known as Anterior Horn Cell Diseases) are heterogeneous and encompass either upper motor neurons, or lower motor neurons, or both. Upper motor neurons begin in the cerebral cortex and descend into the brainstem (corticobulbar), or spinal cord, where there is a connection to the lower motor neuron that exits the central nervous system and reaches out to the muscle.
 - The various types can be divided into the areas so affected:
 - Amyotrophic Lateral Sclerosis (Lou Gehrig's disease) – both Upper and Lower Motor Neurons
 - Primary Lateral Sclerosis – Upper Motor Neurons
 - Progressive Muscular Atrophy – Lower Motor Neurons
 - Progressive Bulbar Palsy – Rare and limited to bulbar muscles (muscles innervated by the Cranial Nerves – dysarthria and dysphagia)
 - Other rare conditions:
 - Monomelic Amyotrophy (Hirayama disease)
 - Spinal Bulbar Muscular Atrophy (Kennedy Disease)

- Signs of lower motor neuron pathology include weakness, fasciculations, atrophy, decreased muscle tone, decreased reflexes, and a plantar extensor response (Babinski sign).
- Signs of upper motor neuron pathology include weakness, increased muscle tone, increased reflexes, and a plantar flexor response.¹¹

Spinal Muscular Atrophy (PN-8.2)

PN.ND.0008.2.A

v1.0.2024

- Molecular genetic testing is the standard tool for diagnosis for the early consideration in any infant with weakness or hypotonia.
 - MRI is **NOT** supported for diagnosis in children, unless other diseases are being considered. See [Spinal Muscular Atrophy \(PEDPN-5.1\)](#).
- In individuals with adult-onset disease, the differential includes later-onset motor neuron disorders, such as ALS
 - For these conditions, advanced imaging is indicated when upper and lower motor neuron findings are present. For imaging, see [Motor Neuron Disease/Amyotrophic Lateral Sclerosis \(ALS\) \(PN-8.1\)](#).

Fasciculations (PN-8.3)

PN.ND.0008.3.A

v1.0.2024

Fasciculations are spontaneous, erratic movements of muscle that may be secondary to benign and non-benign etiologies.

- **ALL** of the following evaluations are required prior to advanced imaging:
 - **Clinical history** should include the time course of symptoms, any associated weakness, areas of involvement, as well as the presence or absence of pain, sensory loss, or sphincter dysfunction.
 - **EMG/NCV evaluation**
 - In the setting of clinical concern for radiculopathy, neuromuscular disorders, or muscle disorders, see the following imaging guidelines:
 - **Neuromuscular Junction Disorders (PN-6.1)**
 - **Muscle Diseases (PN-6.2)**
 - **Neck (Cervical Spine) Pain without and with Neurological Features (Including Stenosis) (SP-3.1)**
 - **Lower Extremity Pain with Neurological Features (Radiculopathy, Radiculitis, or Plexopathy and Neuropathy) with or without Low Back (Lumbar Spine) Pain (SP-6.1)**
 - **Laboratory evaluation** (e.g., complete blood count; comprehensive metabolic panel; serum calcium; thyroid function testing; vitamin B12 level; sed rate; ANA; rheumatoid factor; serum protein electrophoresis with immunofixation; Lyme testing; HIV testing; testing for heavy metals; etc.)
- For the presence of upper motor neuron signs (e.g. increased tone; hyperreflexia; presence of Babinski or Hoffman signs) to exclude mimics of non-benign etiologies of muscle fasciculations (i.e. motor neuron disease), **ANY** of the following CNS studies are indicated:
 - **Brain:** MRI Brain without contrast (CPT® 70551) **or** MRI Brain without and with contrast (CPT® 70553), **AND/OR**
 - **Cervical Spine:** MRI Cervical Spine without contrast (CPT® 72141) **or** MRI Cervical Spine without and with contrast (CPT® 72156), **AND/OR**
 - **Thoracic Spine:** MRI Thoracic Spine without contrast (CPT® 72146) **or** MRI Thoracic Spine without and with contrast (CPT® 72157)
- **Lumbar Spine:** Typically, lumbar spine imaging is **NOT** indicated unless there is sphincter involvement or there is a need to rule out lower motor etiologies in the lower extremities (e.g., lumbar radiculopathy). See the following Spine Imaging Guidelines:
 - **Red Flag Indications (SP-1.2)**
 - **Lower Extremity Pain with Neurological Features (Radiculopathy, Radiculitis, or Plexopathy and Neuropathy) with or without Low Back (Lumbar Spine) Pain (SP-6.1)**

References (PN-8)

v1.0.2024

1. Kollewe K, Körner S, Dengler R, Petri S, Mohammadi B. Magnetic resonance imaging in amyotrophic lateral sclerosis. *Neurol Res Int*. 2012;2012:608501. doi: 10.1155/2012/608501.
2. Filippi M, Agosta F, Abrahams S, et al. EFNS guidelines on the use of neuroimaging in the management of motor neuron diseases. *Eur J Neurol*. 2010;17(4):526-e20. doi: 10.1111/j.1468-1331.2010.02951.x.
3. Agosta F, Spinelli EG, Filippi M. Neuroimaging in amyotrophic lateral sclerosis: current and emerging uses. *Expert Rev Neurother*. 2018;18(5):395-406. doi: 10.1080/14737175.2018.1463160.
4. Garg N, Park SB, Vucic S, et al. Differentiating lower motor neuron syndromes. *J Neurol Neurosurg Psychiatry*. 2017;88(6):474-483. doi: 10.1136/jnnp-2016-313526.
5. Shefner JM, Al-Chalabi A, Baker MR, et al. A proposal for new diagnostic criteria for ALS. *Clin Neurophysiol*. 2020;131(8):1975-1978. doi: 10.1016/j.clinph.2020.04.005.
6. Glascock J, Sampson J, Haidet-Phillips A, et al. Treatment Algorithm for Infants Diagnosed with Spinal Muscular Atrophy through Newborn Screening. *J Neuromuscul Dis*. 2018;5(2):145-158. doi: 10.3233/JND-180304.
7. Silveira-Moriyama L, Paciorkowski AR. Genetic Diagnostics for Neurologists. *Continuum (Minneap Minn)*. 2018;24(1, Child Neurology):18-36. doi: 10.1212/CON.0000000000000556.
8. Hatcher-Martin JM, Adams JL, Anderson ER, et al. Telemedicine in neurology: Telemedicine Work Group of the American Academy of Neurology update. *Neurology*. 2020;94(1):30-38. doi:10.1212/WNL.0000000000008708
9. Prior TW, Leach ME, Finanger E. Spinal Muscular Atrophy. In: Adam MP, Everman DB, Mirzaa GM, et al., eds. *GeneReviews*® [Internet]. 2000 Feb 24; [Updated 2020 Dec 3]. Seattle (WA). University of Washington, Seattle. 1993-2022.
10. Filippakis A, Jara J, Ventura N, et al. A prospective study of benign fasciculation syndrome and anxiety. *Muscle Nerve*. 2018;58(6):852-854. doi: 10.1002/mus.26193.
11. Quinn C, Elman L. Amyotrophic Lateral Sclerosis and Other Motor Neuron Diseases. *Continuum (Minneap Minn)*. 2020;26(5):1323-1347. doi: 10.1212/CON.0000000000000911.

Peripheral Nerve Sheath Tumors (PNST) (PN-9)

Guideline

Peripheral Nerve Sheath Tumors (PNST) (PN-9.1)

References (PN-9)

Peripheral Nerve Sheath Tumors (PNST) (PN-9.1)

PN.NS.0009.1.A

v1.0.2024

PNST such as (Schwannomas or Neurofibromas) arise from Schwann cells or other connective tissue of the nerve. They can be located anywhere in the body.

- When PNST is suspected, the following advanced imaging is indicated:
 - Vestibular Schwannoma: MRI Brain without and with contrast (CPT® 70553)
 - See **Acoustic Neuroma and Other Cerebellopontine Angle Tumors (HD-33.1)** in the Head Imaging Guidelines.
 - Suspected Paraspinal Neurofibroma: **ANY** of the following imaging:
 - MRI Cervical Spine without and with contrast (CPT® 72156), **AND/OR**
 - MRI Thoracic Spine without and with contrast (CPT® 72157), **AND/OR**
 - MRI Lumbar Spine without and with contrast (CPT® 72158)
- Routine follow-up imaging is **NOT** indicated except in the following scenarios:
 - New symptoms or neurological findings develop
 - Post-operatively for **ANY** of the following scenarios:
 - At the discretion of or in consultation with the surgeon;
 - If the tumor was not completely removed and the imaging is requested to re-establish baseline
 - Malignant transformation is known **or** suspected. **ANY** of the following imaging is indicated for metastatic work-up:
 - CT Chest with contrast (CPT® 71260), **AND/OR**
 - CT Abdomen with contrast (CPT® 74160)
- For guidelines related to known malignancies in individuals with NF1, see the appropriate imaging guideline for the specific cancer type.

Background and Supporting Information

- The role of PET imaging in Peripheral Nerve Sheath Tumors is not well established yet.⁸
- Malignant transformation may be present in approximately 5% of Peripheral Nerve Sheath Tumors.

References (PN-9)

v1.0.2024

1. Ahlawat S, Blakeley JO, Langmead S, Belzberg AJ, Fayad LM. Current status and recommendations for imaging in neurofibromatosis type 1, neurofibromatosis type 2, and schwannomatosis. *Skelet Radiol*. 2019;49(2):199-219. doi: 10.1007/s00256-019-03290-1.
2. Soldatos T, Fisher S, Karri S, Ramzi A, Sharma R, Chhabra A. Advanced MR Imaging of Peripheral Nerve Sheath Tumors Including Diffusion Imaging. *Semin Musculoskelet Radiol*. 2015;19(02):179-190. doi: 10.1055/s-0035-1546823.
3. Zhang J, Li Y, Zhao Y, Qiao J. CT and MRI of superficial solid tumors. *Quant Imaging Med Surg*. 2018;8(2):232-251. doi: 10.21037/qims.2018.03.03.
4. Rosser T. Neurocutaneous Disorders. *Continuum (Minneap Minn)*. 2018;24(1):96-129. doi: 10.1212/con.0000000000000562.
5. Dare AJ, Gupta AA, Thippavong S, Miettinen M, Gladdy RA. Abdominal neoplastic manifestations of neurofibromatosis type 1. *Neuro-Oncol Adv*. 2020;2(Supplement_1):i124-i133. doi: 10.1093/nojnl/vdaa032.
6. Bruno F, Arrigoni F, Mariani S, et al. Advanced magnetic resonance imaging (MRI) of soft tissue tumors: techniques and applications. *Radiol Med*. 2019;124(4):243-252. doi: 10.1007/s11547-019-01035-7.
7. Ruggieri M, Polizzi A, Marceca GP, Catanzaro S, Praticò AD, Di Rocco C. Introduction to phacomatoses (neurocutaneous disorders) in childhood. *Childs Nerv Syst*. 2020;36(10):2229-2268. doi: 10.1007/s00381-020-04758-5.
8. Assadi M, Velez E, Najafi MH, Matcuk G, Gholamrezanezhad A. PET Imaging of Peripheral Nerve Tumors. *PET Clinics*. 2019;14(1):81-89. doi: 10.1016/j.cpet.2018.08.013.

Nuclear Imaging (PN-10)

Guideline

Nuclear Imaging (PN-10.1)

Nuclear Imaging (PN-10.1)

PN.NI.0010.1.A

v1.0.2024

- Nuclear Medicine
 - Nuclear medicine studies are **NOT** indicated in the evaluation of peripheral nerve disorders.

Table of Contents

Guideline

General Information

Abbreviations and Glossary for the PVD Imaging Guidelines

General Guidelines (PVD-1.0)

General Information (PVD-1.1)

Procedure Coding (PVD-1.2)

General Guidelines – Imaging (PVD-1.3)

Nuclear Medicine Imaging indications (PVD-10.1)

References

Genetic Predisposition to Arterial Disease

Screening for Suspected Peripheral Artery Disease/Aneurysmal Disease (PVD-2)

Cerebrovascular Imaging

Cerebrovascular and Carotid Disease - Initial Imaging (PVD-3.1)

Surveillance Imaging with NO History of Carotid Surgery or Intervention (PVD-3.2)

Surveillance Imaging WITH History of Carotid Surgery or Intervention (PVD-3.3)

References

Aortic Imaging

Aortic Disorders General Information (PVD-6.1)

Thoracic Aortic Aneurysm (TAA) (PVD-6.2)

Abdominal Aortic Aneurysm (AAA) (PVD-6.3)

Iliac Artery Aneurysm (IAA) (PVD-6.4)

Aortic and Arterial Dissection and Other Aortic Conditions (PVD-6.7)

Post Aortic Endovascular/Open Surgery Surveillance Studies (PVD-6.8)

Large Vessel Vasculitis (PVD-6.9)

Medium Vessel Vasculitis (PVD-6.10)

Small Vessel Vasculitis (PVD-6.11)

Peripheral Arterial Imaging

Upper Extremity PVD – Imaging (PVD-4.1)

Renovascular Hypertension/Renal Artery Stenosis (PVD-6.6)

Visceral Artery Aneurysm (PVD-6.5)

Median Arcuate Ligament Syndrome, Nutcracker Syndrome and other Abdominal Vascular Compression Syndromes (PVD-18)

Lower Extremity Artery Aneurysms (PVD-7.4)
Claudication and Critical Limb Ischemia (PVD-7.1)
Popliteal Artery Entrapment Syndrome (PVD-7.2)
Post-Procedure Surveillance Studies (PVD-7.3)
Arterial Imaging for Free Flaps in Reconstructive Surgery (PVD-7.5)
Arteriovenous Malformations (AVMs) (PVD-9.1)

Venous Imaging

Venous Imaging General Information (PVD-11)
Upper Extremity Venous – Imaging (PVD-4.2)
Acute Limb Swelling (PVD-12)
Chronic limb swelling due to chronic deep venous thrombosis (DVT)/May-Thurner syndrome (PVD-13)
Chronic limb swelling due to venous insufficiency/Venous stasis changes/Varicose veins (PVD-14)
Imaging for Hemodialysis Access (PVD-8)
IVC filters – Treatment (PVD-16.2)
Post iliac vein stenting/angioplasty (PVD-17.1)

General Information

Guideline

Abbreviations and Glossary for the PVD Imaging Guidelines

General Guidelines (PVD-1.0)

General Information (PVD-1.1)

Procedure Coding (PVD-1.2)

General Guidelines – Imaging (PVD-1.3)

Nuclear Medicine Imaging indications (PVD-10.1)

References

Abbreviations and Glossary for the PVD Imaging Guidelines

v1.0.2024

(See also: [Cardiac Imaging Guidelines Glossary](#))

Abbreviation	Definition
AAA	Abdominal aortic aneurysm
ABI	Ankle brachial index: a noninvasive, non-imaging test for arterial insufficiency – (see toe-brachial index below). This testing can also be done after exercise if resting results are normal.
Claudication	or Intermittent claudication : usually a painful cramping sensation of the legs with walking or severe leg fatigue
CLI	Critical Limb Ischemia
CTA	Computed tomography angiography
CTV	Computed tomography venography
DLCO	Diffusion capacity: defined as the volume of carbon monoxide transferred into the blood per minute per mmHg of carbon monoxide partial pressure
DVT	Deep venous thrombosis
ECG	Electrocardiogram
ENT	Ears, Nose, Throat
EVAR	Endovascular Aneurysm Repair
HbA1C	Hemoglobin A1C: test used to determine blood sugar control for individuals with diabetes
MRA	Magnetic resonance angiography
MRV	Magnetic resonance venography
PAD	Peripheral artery disease
PAH	Pulmonary artery hypertension
PFT	Pulmonary function tests
PVD	Peripheral vascular disease
PSV ratio	Peak systolic velocities
SVC	Superior vena cava
TEVAR	Thoracic Endovascular Aortic Repair
TIA	Transient ischemic attack

Abbreviation	Definition
TTE	Transthoracic echocardiogram
Toe-Brachial Index	Useful in individuals with ABI above the normal range due to non-compressible posterior tibial or dorsalis pedis arteries
V/Q Scan	Ventilation and perfusion scan

General Guidelines (PVD-1.0)

PVD.GG.0001.0.A

v1.0.2024

- A pertinent clinical evaluation, or meaningful technological contact (telehealth visit, telephone call, electronic mail or messaging), is required prior to considering advanced imaging, including relevant medical treatments and a vascular history and physical that includes (when applicable):
 - Palpation of pulses
 - Evaluation of lower extremities for presence of non-healing wounds or gangrene
 - Associated skin changes such as thickened nails, absence of hair in the feet or calves, cool extremities
 - Evaluation for the presence of arterial bruits
 - Appropriate laboratory studies
 - Non-advanced imaging modalities, such as recent ABIs (within 60 days) after symptoms started or worsened
- ABI should be measured first:
 - If normal, then further vascular studies are generally not indicated.
 - If clinical suspicion for PAD remains high with normal ABI's, exercise ABI's (CPT® 93924) can be performed on a treadmill to elicit ischemia
 - The TBI (toe-brachial index) is used to establish the diagnosis of PAD in the setting of non-compressible arteries (ABI ≥ 1.40) and may also be used to assess perfusion in individuals with suspected CLI (rest pain and/or non-healing wound)
- If a prior imaging study (Ultrasound, MRA, CTA, Catheter angiogram, etc.) has been completed for a condition, a follow-up, additional, or repeat study for the same condition is generally not indicated unless there has been a change in the individual's condition, previous imaging showed an indeterminate finding, or eviCore healthcare guidelines support routine follow-up imaging.
- Runoff studies (CPT® 75635 for CTA or CPT® 74185, CPT® 73725, and CPT® 73725 for MRA) image from the umbilicus to the feet
 - CTA Abdomen and lower extremities should be reported as CPT® 75635, rather than using the individual CPT® codes for the abdomen, pelvis, and legs
 - MRA Abdomen, MRA Pelvis and MRA Lower extremities should be reported as CPT® 74185, CPT® 73725, and CPT® 73725. The CPT® code for MRA Pelvis (CPT® 72198) should not be included in this circumstance.

General Information (PVD-1.1)

PVD.GG.0001.1.A

v1.0.2024

- Risk factors for vascular disease include:
 - Diabetes
 - Cigarette smoking
 - Hypertension
 - Hyperlipidemia
 - Age >50, with at least one risk factor, are considered “at risk” for vascular disease
 - See also: **Impotence/Erectile Dysfunction (PV-17)** in the Pelvis Imaging Guidelines.
- Signs and symptoms of peripheral arterial disease
 - Claudication (Cramping pain in the legs, most notably back of the calves but can involve hips or thighs, after walking which is relieved with rest but recurs at a predictable distance)
 - Symptoms that are not consistent with claudication include
 - Generalized leg pain
 - Nocturnal cramps
 - Pain that is not easily relieved after a few minutes of rest
 - Burning pain in feet
 - Critical limb ischemia
 - Rest pain: Pain in the foot (not leg) at rest, particularly at night when the leg is elevated. Pain is relieved by dangling the leg off the bed or moving to an upright position
 - Non-healing wounds: Wounds present for >2 weeks with little to no evidence of healing
 - Erectile dysfunction can be associated with vascular disease
- Claudication and critical limb ischemia have different natural histories. Claudication generally follows a benign indolent course. 70% of individuals with claudication will have the same symptoms after five years with no progression. Critical limb ischemia, on the other hand, is associated with a high rate of limb loss (25%) and death (35%) one year after presentation
- Simultaneous venous and arterial systems evaluation are unusual but are occasionally needed
- Post-angioplasty/reconstruction: follow-up imaging is principally guided by symptoms. See also:
 - **Post Aortic Endovascular/Open Surgery Surveillance Studies (PVD-6.8)**
 - **Post-Procedure Surveillance Studies (PVD-7.3)**

Procedure Coding (PVD-1.2)

PVD.GG.0001.2.A

v1.0.2024

Non-Invasive Physiologic Studies of Extremity Arteries	CPT®
<ul style="list-style-type: none"> Limited bilateral noninvasive physiologic studies of upper or lower extremity arteries. Non-invasive physiologic studies of upper or lower extremity arteries, single level, bilateral (e.g., ankle/brachial indices, Doppler waveform analysis, volume plethysmography, transcutaneous oxygen tension measurement). 	93922
<ul style="list-style-type: none"> Complete bilateral noninvasive physiologic studies of upper or lower extremity arteries, 3 or more levels. Non-invasive physiologic studies of upper or lower extremity arteries, multiple levels or with provocative functional maneuvers, complete bilateral study (e.g., segmental blood pressure measurements, segmental Doppler waveform analysis, segmental volume plethysmography, segmental transcutaneous oxygen tension measurements, measurements with postural provocative tests, measurements with reactive hyperemia). 	93923

- CPT® 93922 and CPT® 93923 can be requested and reported only once for the upper extremities and once for the lower extremities.
- CPT® 93922 and CPT® 93923 should not be ordered on the same request nor billed together for the same date of service.
- CPT® 93924 and CPT® 93922 and/or CPT® 93923 should not be ordered on the same request and should not be billed together for the same date of service.
- ABI studies performed with handheld dopplers, where there is no hard copy output for evaluation of bidirectional blood flow, are not reportable by these codes.

Non-Invasive Physiologic Studies of Extremity Arteries	CPT®
Non-invasive physiologic studies of lower extremity arteries, at rest and following treadmill stress testing, complete bilateral study.	93924

Arterial Duplex – Upper and Lower Extremities	CPT®
Duplex scan of lower extremity arteries or arterial bypass grafts; complete bilateral.	93925
<ul style="list-style-type: none"> A complete duplex scan of the lower extremity arteries includes examination of the full length of the common femoral, superficial femoral and popliteal arteries. The iliac, deep femoral, and tibioperoneal arteries may also be examined. 	
Duplex scan of lower extremity arteries or arterial bypass grafts; unilateral or limited study.	93926

Arterial Duplex – Upper and Lower Extremities		CPT®
<ul style="list-style-type: none"> The limited study is reported when only one extremity is examined or when less than a full examination is performed (e.g. only one or two vessels or follow-up). 		
Duplex scan of upper extremity arteries or arterial bypass grafts; complete bilateral.		93930
<ul style="list-style-type: none"> A complete duplex of the upper extremity arteries includes examination of the subclavian, axillary, and brachial arteries. The radial and ulnar arteries may also be included. 		
Duplex scan of upper extremity arteries or arterial bypass grafts; unilateral or limited study.		93931
<ul style="list-style-type: none"> The limited study is reported when only one extremity is examined or when less than a full examination is performed (e.g. only one or two vessels or follow-up). 		

Cerebrovascular Artery Studies		CPT®
Duplex scan of extracranial arteries; complete bilateral study.		93880
Duplex scan of extracranial arteries; unilateral or limited study.		93882
<ul style="list-style-type: none"> This study is often referred to as a “carotid ultrasound” or “carotid duplex”. Typically, it includes evaluation of the common, internal, and external carotid arteries. 		

Transcranial Doppler Studies		CPT®
Transcranial Doppler study of the intracranial arteries; complete study		93886
Transcranial Doppler study of the intracranial arteries; limited study		93888
Transcranial Doppler vasoreactivity study		93890
Transcranial Doppler study of the intracranial arteries; emboli detection without intravenous microbubble injection		93892
Transcranial Doppler study of the intracranial arteries; emboli detection with intravenous microbubble injection		93893

Venous Studies - Extremities		CPT®
Duplex scan of extremity veins, including responses to compression and other maneuvers; complete bilateral study.		93970
Duplex scan of extremity veins, including responses to compression and other maneuvers; unilateral or limited study.		93971

Venous Studies - Extremities	CPT®
<ul style="list-style-type: none"> • These codes are used to report studies of lower or upper extremity veins. • A complete bilateral study of the lower extremity veins includes examination of the common femoral, proximal deep femoral, great saphenous and popliteal veins. Calf veins may also be included. • A complete bilateral study of upper extremity veins includes examination of the subclavian, jugular, axillary, brachial, basilica, and cephalic veins. Forearm veins may also be included. 	

Visceral Vascular Studies	CPT®
Duplex scan of arterial inflow and venous outflow of abdominal, pelvic, scrotal contents and/or retroperitoneal organs; complete study.	93975
Duplex scan of arterial inflow and venous outflow of abdominal, pelvic, scrotal contents and/or retroperitoneal organs; limited study	93976
Duplex scan of aorta, inferior vena cava, iliac vasculature, or bypass grafts; complete study	93978
Duplex scan of aorta, inferior vena cava, iliac vasculature, or bypass grafts; unilateral or limited study	93979

Duplex for Hemodialysis Access	CPT®
Duplex scan of hemodialysis access (including arterial inflow, body of access and venous outflow).	93990
Duplex scan of arterial inflow and venous outflow for preoperative vessel assessment prior to creation of hemodialysis access; complete bilateral study	93985
Duplex scan of arterial inflow and venous outflow for preoperative vessel assessment prior to creation of hemodialysis access; complete unilateral study	93986

General Guidelines – Imaging (PVD-1.3)

PVD.GG.0001.3.A
v1.0.2024

- Imaging Studies:
 - Carotid studies MRA Neck (CPT® 70543) or CTA Neck (CPT® 70491) capture the area from the top of the aortic arch (includes the origin of the innominate artery, common carotid artery, and subclavian artery, which gives off the vertebral artery) to the base of the skull.
 - CTA or MRA Abdomen (CPT® 74175 or CPT® 74185) images from the diaphragm to the umbilicus or iliac crest
 - CTA or MRA Chest (CPT® 71275 or CPT® 71555) images from the base of the neck to the dome of the liver
 - Runoff studies (CPT® 75635 for CTA or CPT® 74185, CPT® 73725, and CPT® 73725 for MRA) image from the umbilicus to the feet
 - CTA Abdomen and lower extremities should be reported as CPT® 75635, rather than using the individual CPT® codes for the abdomen, pelvis, and legs
 - MRA Abdomen, MRA Pelvis and MRA Lower extremities should be reported as CPT® 74185, CPT® 73725, and CPT® 73725. The CPT® code for MRA Pelvis (CPT® 72198) should not be included in this circumstance
 - Studies used to quantify plaque morphology in noncoronary vessels (CPT® 0710T, CPT® 0711T, CPT® 0712T, CPT® 0713T) are considered experimental, investigational, or unproven.

Nuclear Medicine Imaging indications (PVD-10.1)

PVD.GG.0010.1.A

v1.0.2024

- Nuclear medicine studies are rarely used in the evaluation of peripheral vascular disorders but are indicated in the following circumstances:
 - Lymphoscintigraphy (CPT[®] 78195) is indicated for evaluation of lower extremity lymphedema when recent Doppler ultrasound of the lower extremity and abdomen are negative for valvular insufficiency.
 - Vascular flow imaging (CPT[®] 78445) is an obsolete study that has been replaced by MRA, CTA, or Duplex ultrasonography, and is not supported for any indication at this time.
 - Venous thrombosis imaging (CPT[®] 78456, CPT[®] 78457, and CPT[®] 75458) are obsolete studies that have been replaced by MRA, CTA, or Duplex ultrasonography, and are not supported for any indication at this time.
 - Indium 111 (¹¹¹In)-labeled white blood cell (WBC) or Gallium-67 citrate studies (CPT[®] 78800, CPT[®] 78801, CPT[®] 78802, or CPT[®] 78803) can be approved for evaluation of the following:
 - Mycotic aneurysms.
 - Vascular graft infection.
 - Infection of central venous catheter or other indwelling device.

References

v1.0.2024

1. Gerhard-Herman MD, Gornik HL, Barrett C, et al. 2016 AHA/ACC Guideline on the management of patients with lower extremity peripheral artery disease. *J Am Coll Cardiol*. 2017 Mar 69 (11):1467-1508.
2. Conte MS, Pomposelli FB, et al. Society for Vascular Surgery practice guidelines for atherosclerotic occlusive disease of the lower extremities: management of asymptomatic disease and claudication [published correction appears in *J Vasc Surg*. 2015 May;61(5):1382]. *J Vasc Surg*. 2015;61(3 Suppl):2S-41S. doi:10.1016/j.jvs.2014.12.009.
3. Aboyans V, Criqui MH, Abraham P, et al. Measurement and interpretation of the ankle-brachial index: a scientific statement from the American Heart Association [published correction appears in *Circulation*. 2013 Jan 1;127(1):e264]. *Circulation*. 2012;126(24):2890-2909.
4. Drachman DE, Beckman JA. The Exercise Ankle-Brachial Index: A Leap Forward in Noninvasive Diagnosis and Prognosis. *JACC Cardiovasc Interv*. 2015;8(9):1245-1247. doi:10.1016/j.jcin.2015.06.006.
5. Herraiz-Adillo Á, Cavero-Redondo I, Álvarez-Bueno C, Pozuelo-Carrascosa DP, Solera-Martínez M. The accuracy of toe brachial index and ankle brachial index in the diagnosis of lower limb peripheral arterial disease: A systematic review and meta-analysis. *Atherosclerosis*. 2020;315:81-92. doi:10.1016/j.atherosclerosis.2020.09.026.

Genetic Predisposition to Arterial Disease

Guideline

Screening for Suspected Peripheral Artery Disease/Aneurysmal Disease (PVD-2)

Screening for Suspected Peripheral Artery Disease/Aneurysmal Disease (PVD-2)

Guideline

PVD.GP.0002.A

Asymptomatic Screening (PVD-2.1)

v1.0.2024

Screening for Vascular related genetic connective tissue Disorders (PVD-2.2)

Screening for TAA with bicuspid aortic valves (PVD-2.3)

Screening for Vascular Related Disorders in Multisystemic Smooth Muscle Syndrome (MSMS)/Smooth Muscle Dysfunction Syndrome (SMDS)/

ACTA2 Mutations (PVD 2.4)

References

Asymptomatic Screening (PVD-2.1)

- Routine screening of asymptomatic individuals for PAD is not advised. Those with CVD risk factors should be placed on best medical management and should be questioned on symptoms of PAD at annual physicals.
- Currently, there is no evidence to demonstrate that screening all individuals with PAD for asymptomatic atherosclerosis in other arterial beds improves clinical outcome. ^{1 2 3}
- Resting ABI's may be indicated in individuals with abnormal pulse exams. ^{2,3}

Screening for Vascular related genetic connective tissue Disorders (PVD-2.2)

- Vascular related genetic connective tissue Disorders include:
 - Familial Aneurysm Syndromes
 - Fibromuscular Dysplasia
 - Spontaneous Coronary Artery Dissection (SCAD)
 - Ehlers-Danlos
 - Marfan
 - Loeys-Dietz
- Screening for Familial Syndromes in individuals with a positive family history (1st degree relative with dissection/TAA) but no known genetic syndrome/mutation, otherwise known as Suspected **Familial Aneurysm Syndrome**.
 - ECHO (CPT[®] 93306, CPT[®] 93307, or CPT[®] 93308) and chest x-ray for all First-degree relatives (parents, siblings, children) of individuals with TAA and/or dissection.

¹ Andras A, Ferket B. Screening for peripheral arterial disease. Cochrane Database Syst Rev. 2014;(4):CD010835. Published 2014 Apr 7. doi:10.1002/14651858.CD010835.pub2

² Firnhaber JM, Powell CS. Lower Extremity Peripheral Artery Disease: Diagnosis and Treatment [published correction appears in Am Fam Physician. 2019 Jul 15;100(2):74]. Am Fam Physician. 2019;99(6):362-369

³ US Preventive Services Task Force, Curry SJ, Krist AH, et al. Screening for Peripheral Artery Disease and Cardiovascular Disease Risk Assessment with the Ankle-Brachial Index:US Preventive Services Task Force Recommendation Statement. JAMA. 2018;320(2):177. doi:10.1001/jama.2018.8357

- Any imaging listed in the Table of Thoracic Aorta Imaging Options can be performed if these studies identify a TAA or are equivocal or do not visualize the ascending or descending aorta adequately.

Table of Thoracic Aorta Imaging Options

Description	CPT®
CT Chest without contrast	71250
CT Chest with contrast	71260
CTA Chest	71275
MRA Chest	71555
Transesophageal echocardiogram (TEE)	93312 or 93313 or 93314

- Studies can be repeated at 2 year intervals if prior results are negative
- Initial imaging for individuals with documented SCAD/fibromuscular dysplasia/Marfan/Loeys-Dietz/Ehlers-Danlos type IV:
 - On initial diagnosis of Ehlers-Danlos, Loeys Deitz or Marfans or SCAD or suspicion of fibromuscular dysplasia, full vascular imaging should be performed from head to pelvis with:
 - CTA or MRA Head (CPT® 70496 or CPT® 70546 or CPT® 70545)
 - CTA or MRA Neck (CPT® 70498 or CPT® 70548 or CPT® 70549)
 - CTA or MRA Chest or CT Chest with contrast
 - CTA Abdomen/Pelvis or MRA Abdomen/Pelvis (CPT® 74174) or (CPT® 74185 and CPT® 72198)
 - If there are no identified aneurysms or dissections, repeat imaging can be obtained at two-year intervals
- Surveillance imaging
 - If an aneurysm is identified in individuals with fibromuscular dysplasia, then the aneurysm can be surveilled per the typical timeframe as described in **Thoracic Aortic Aneurysm (TAA) (PVD-6.2)**, **Abdominal Aortic Aneurysm (PVD-6.3)**, **Iliac Artery Aneurysm (PVD- 6.4)**, and **Visceral Artery Aneurysm (PVD-6.5)**.
 - Follow-Up of aneurysms in individuals with documented SCAD/Marfan’s/Loeys-Dietz/Ehlers-Danlos type IV
 - Imaging can be performed every 6 months once an aneurysm has been identified until a decision has been made to repair.
 - Intracranial aneurysm – CTA or MRA Head (CPT® 70496 or 70544)
 - Aneurysm of a cervical artery – Carotid duplex or CTA or MRA neck if unable to fully visualize with carotid duplex
 - Thoracic aorta – CTA Chest (CPT® 71275) or CT Chest with (CPT® 71260) or without (CPT® 71250), MRA chest (CPT® 71555)
 - Abdominal aneurysm – Abdominal duplex (CPT® 93975/93976/93978/93979/76770/76775)

- Visceral aneurysm – These can be difficult to visualize on duplex. If not visible on duplex, can obtain a CTA or MRA Abdomen and Pelvis.

Background and supporting information

Fibromuscular dysplasia and spontaneous coronary artery dissection is diagnosed radiographically. Loeys-Dietz, Marfans, Ehlers-Danlos type IV are diagnosed with genetic testing.

Screening for TAA with bicuspid aortic valves (PVD-2.3)

- Screening in individuals with bicuspid aortic valve:
 - Screening, any requested imaging from the “Table of Thoracic Aorta Imaging Options” and/or ECHO (CPT® 93306, CPT® 93307, or CPT® 93308).

Table of Thoracic Aorta Imaging Options

Description	CPT®
CT Chest without contrast	71250
CT Chest with contrast	71260
CTA Chest	71275
MRA Chest	71555
Transesophageal echocardiogram (TEE)	93312 or 93313 or 93314

- Additional imaging such as Cardiac MRI, Cardiac CT, or CCTA is NOT generally indicated.
 - There is no evidence-based data to support screening relatives of individuals with bicuspid aortic valve for TAA except with echocardiogram.
 - Follow-up per TAA Follow-Up guidelines in **Thoracic Aortic Aneurysm (TAA) (PVD-6.2)**
- If no dilatation of the aortic root or ascending thoracic aorta is found, there is no evidence-based data to support continued surveillance imaging.

Screening for Vascular Related Disorders in Multisystemic Smooth Muscle Syndrome (MSMS)/Smooth Muscle Dysfunction Syndrome (SMDS)/ACTA2 Mutations (PVD 2.4)

Initial imaging

Upon initial genetic confirmation, all of the following studies can be approved:

- Transthoracic echocardiogram (TTE) (CPT® 93306)
- MRA Chest (CPT® 71555) or CTA Chest and CT Chest with contrast (CPT® 71275 and 71260)
- MRA Abdomen and Pelvis (CPT® 74185 and 72198) or CTA Abdomen and Pelvis (CPT® 74174)
- MRI Perfusion study Brain CPT® 70553
- MRA Head and Neck (CPT® 70544 or 70545 AND 70548)
- Ultrasound Upper extremity(ies) (CPT® 93930 or 93931) or CTA Upper extremity (CPT® 73206) or MRA Upper extremity (CPT® 73225)

Repeat testing

Repeat testing with any of the studies listed under initial imaging is indicated when there is documentation of new signs or symptoms.

Surveillance imaging

Surveillance imaging with any of the studies listed in initial imaging is indicated according to the following:

- Transthoracic echocardiogram repeat every 6 months
- Chest imaging can be repeated every 12 months starting at age 10
- Abdomen and pelvis imaging can be repeated every 12 months starting age 10
- Upper extremity imaging can be repeated every 12 months starting age 10
- MRI perfusion study Brain see **Dysfunction Syndrome (SMDS)/ACTA2 Mutations (PEDHD-12.8)**
- MRA Head and Neck see **Dysfunction Syndrome (SMDS)/ACTA2 Mutations (PEDHD-12.8)**

Background and supporting information

Smooth Muscle Dysfunction Syndrome presents as congenital mydriasis, a patent ductus arteriosus (PDA), pulmonary arterial hypertension (PAH) during infancy. Patients go on to developed aortic, peripheral arterial, and cerebrovascular disorders in childhood.

- Caused by heterozygous mutation of ACTA2. P.Arg179His

- Cases mostly due to de novo mutations, so imaging screening based on family history without genetic confirmation is not supported.
- Because radiation is a known risk factor for moyamoya disease. MRI/MRA Head is recommended instead of Computed Tomography (CT)/CTA

References

1. Andras A, Ferket B. Screening for peripheral arterial disease. *Cochrane Database Syst Rev.* 2014; (4):CD010835. Published 2014 Apr 7. doi:10.1002/14651858.CD010835.pub2.
2. Firnhaber JM, Powell CS. Lower Extremity Peripheral Artery Disease: Diagnosis and Treatment [published correction appears in *Am Fam Physician.* 2019 Jul 15;100(2):74]. *Am Fam Physician.* 2019;99(6):362-369.
3. US Preventive Services Task Force, Curry SJ, Krist AH, et al. Screening for Peripheral Artery Disease and Cardiovascular Disease Risk Assessment with the Ankle-Brachial Index:US Preventive Services Task Force Recommendation Statement. *JAMA.* 2018;320(2):177. doi:10.1001/jama.2018.8357.
4. Demo E, Rigelsky C, Rideout AL, et al. Genetics and Precision Medicine: Heritable Thoracic Aortic Disease. *Med Clin North Am.* 2019;103(6):1005-1019. doi:10.1016/j.mcna.2019.08.001.
5. Gornik HL, Persu A, Adlam D, et al. First International Consensus on the diagnosis and management of fibromuscular dysplasia [published correction appears in *Vasc Med.* 2019 Oct;24(5):475. *Vasc Med.* 2019;24(2):164-189. doi:10.1177/1358863X18821816.
6. Hayes SN, Kim ES, Saw J, et al. Spontaneous Coronary Artery Dissection: Current State of the Science: A Scientific Statement from the American Heart Association. *Circulation.* 2018;137(19). doi:10.1161/cir.0000000000000564.
7. Hiratzka LF, Bakris GL, Beckman JA, et al. 2010 ACCF/AHA/AATS/ACR/ASA/SCA/SCAI/SIR/STS/SVM guidelines for the diagnosis and management of patients with thoracic aortic disease. *J Am Coll Cardiol.* 2010; 55: e27-e129.
8. MacCarrick G, Black J, Bowdin S, et al. Loeys–Dietz syndrome: a primer for diagnosis and management. *Genet Med* (2014).16:576–587 doi:10.1038/gim.2014.11.
9. Olin JW, Gornik HL, Bacharach JM, et al. Fibromuscular Dysplasia: State of the Science and Critical Unanswered Questions. *Circulation.* 2014;129(9):1048-1078. doi:10.1161/01.cir.0000442577.96802.8c.
10. Persu A, Niepen PVD, Touzé E, et al. Revisiting Fibromuscular Dysplasia. *Hypertension.* 2016;68(4):832-839. doi:10.1161/hypertensionaha.116.07543.
11. Schoenhoff F, Schmidli J, Czerny M, Carrel TP. Management of aortic aneurysms in patients with connective tissue disease. *J Cardiovasc Surg (Torino).* 2013;54(1 Suppl 1):125-134.
12. Regalado ES, Mellor-Crummey L, De Backer J, et al. Clinical history and management recommendations of the smooth muscle dysfunction syndrome due to ACTA2 arginine 179 alterations. *Genet Med.* 2018;20(10):1206-1215. doi:10.1038/gim.2017.245.

Cerebrovascular Imaging

Guideline

Cerebrovascular and Carotid Disease - Initial Imaging (PVD-3.1)

Surveillance Imaging with NO History of Carotid Surgery or Intervention (PVD-3.2)

Surveillance Imaging WITH History of Carotid Surgery or Intervention (PVD-3.3)

References

Cerebrovascular and Carotid Disease - Initial Imaging (PVD-3.1)

PVD.CV.0003.1.A

v1.0.2024

- Duplex ultrasound (CPT® 93880 bilateral or CPT® 93882 unilateral) should generally be used to evaluate possible carotid artery disease, prior to considering advanced imaging, when ANY of the following apply:
 - Known or suspected retinal arterial emboli or Hollenhorst plaque
 - Pulsatile neck masses
 - Carotid or cervical bruit
 - Abnormal findings on physical exam of the carotid arteries (e.g., absent carotid pulses)
 - Preoperative evaluation of individuals with evidence of severe diffuse atherosclerosis, scheduled for major cardiovascular surgical procedures
 - Preoperative evaluation of individuals prior to elective cardiovascular surgery in individuals older than 65 years of age and in those with peripheral artery disease, history of cigarette smoking, history of stroke or TIA, or carotid bruit
 - Suspected Subclavian Steal Syndrome
 - See **Subclavian Steal Syndrome (CH-27)** in the Chest Imaging Guidelines
 - Blunt neck trauma in the absence of focal neurologic symptoms
 - Neurologic complaints after chiropractic neck manipulation
 - Vasculitis potentially involving carotid arteries, such as Takayasu's arteritis and fibromuscular dysplasia (FMD). In patients with neurologic symptoms and concern for cerebral vasculitis, see **Cerebral vasculitis (HD 22.1)**
 - Remote history of stroke or TIA (Greater than one month).
- Typical Symptoms of TIA/Stroke, see **Stroke/TIA (HD-21)** in the Head Imaging Guidelines
- CTA or MRA Neck is indicated for suspected internal carotid artery dissection, in individuals with **ANY** of the following mechanisms of injury or risk factors for arterial dissection:
 - Chiropractic manipulation of neck
 - Whiplash injury
 - Fibromuscular dysplasia/Marfan's
 - Stroke in the young (age ≤50)
- CTA or MRA Neck can be approved for suspected vertebrobasilar pathology:
 - Symptoms include:
 - Vertigo associated with nausea and vomiting
 - Diplopia
 - Loss of vision in one or both eyes

- Dysarthria
- Bifacial numbness
- Bilateral extremity weakness and/or numbness
- Acute changes in mental status
- Loss of consciousness
- Ataxia
- MRA or CTA of **both** Neck and Head are required to visualize the entire vertebral-basilar system for evaluation of posterior circulation disease. See **General Guidelines – CT and MR Angiography (HD-1.5)** in the Head Imaging Guidelines
- Surveillance imaging, post-stenting or known vertebrobasilar disease, interval determined by Vascular Specialist, Neurologist, or Neurosurgeon or any provider in consultation with a vascular specialist, neurologist, or neurosurgeon for ANY of the following:
 - Asymptomatic
 - Unchanged symptoms
 - New or worsening symptoms
- **After Intracranial Hemorrhage:**
 - Initial Imaging see **Head Trauma (HD-13.1)** in the Head Imaging Guidelines
 - Surveillance Imaging
 - Interval determined by neurosurgeon or neurologist or any provider in consultation with a neurologist or neurosurgeon.
- For Suspected Subclavian Steal Syndrome:
 - Initial imaging should be a carotid duplex
 - If initial duplex demonstrates high-grade stenosis or occlusion of the subclavian artery, advanced imaging is NOT indicated unless the individual is symptomatic with arm claudication or signs of hypo-perfusion of the vertebral artery with recurrent dizziness
 - Surveillance of subclavian arterial disease is NOT indicated if there has not been any intervention such as a carotid-subclavian bypass or subclavian stent
 - Advanced imaging, see **Subclavian Steal Syndrome – General (CH-27)** in the Chest Imaging Guidelines
- Carotid ultrasound screening in asymptomatic individuals due only to risk factors is **not** indicated.
- Repeat imaging of the cervical vessels (regardless of when the previous carotid imaging was performed) is indicated for new signs and symptoms consistent with carotid artery disease (e.g., TIA, amaurosis fugax, change in nature of a carotid bruit) using one of the following:
 - Duplex ultrasound (CPT® 93880 bilateral study or CPT® 93882 unilateral study)
 - MRA Neck with contrast (CPT® 70548) or without and with contrast (CPT® 70549)
 - CTA Neck (CPT® 70498)

Surveillance Imaging with NO History of Carotid Surgery or Intervention (PVD-3.2)

PVD.CV.0003.2.A

v1.0.2024

- Surveillance imaging is indicated once a year for individuals with fibromuscular dysplasia of the extracranial internal carotid arteries.
- Reporting standards for carotid stenosis varies widely. The most commonly used criteria, however, is noted in the chart below published by the Society of Radiology in 2003

Primary parameters			Additional Parameters	
% Stenosis	ICA PSV (cm/sec)	Plaque estimate (%)	ICA/CCA PSV ratio	ICA/EDV (cm/sec)
Normal	< 125	None	< 2.0	< 40
< 50	< 125	< 50	< 2.0	< 40
50-69	125-230	≥ 50	2.0-4.0	40-100
≥ 70 but less than near occlusion	> 230	> 50	> 4.0	> 100
Near occlusion	High, low, or undetectable	Visible	Variable	Variable
Total occlusion	undetectable	Visible- no detectable lesion	Not applicable	Not applicable

- If normal study, no routine follow-up imaging is indicated
- If <50% internal carotid stenosis
 - Duplex ultrasound (CPT® 93880 bilateral or CPT® 93882 unilateral) can be performed every **two** years
- Between 50% and 70% internal carotid stenosis

- Duplex ultrasound (CPT® 93880 bilateral or CPT® 93882 unilateral) can be performed annually.
- A repeat duplex (CPT® 93880 bilateral or CPT® 93882 unilateral) may be performed in three to six months until stability is reached when **one** of the following occurs:
 - Change in the character of the bruit
 - Duplex demonstrates rapid progression, including:
 - Doubling of peak systolic velocities in the internal carotid arteries
 - Increase of the ICA/CCA ratio
 - Heavy calcification in the internal carotid arteries
 - Thrombus in the internal carotid arteries
 - Ulcerated plaque in the internal carotid arteries
 - Echolucent plaque in the internal carotid arteries
- A one-time CTA Neck (CPT® 70498) or MRA Neck (CPT® 70548) is indicated to confirm degree of stenosis in individuals with ulcerated plaque or heavy calcification of the internal carotid artery seen on duplex.
- Internal carotid stenosis $\geq 70\%$ or ICA/CCA ratio >4
 - Duplex ultrasound (CPT® 93880 bilateral or CPT® 93882 unilateral) or MRA Neck with contrast (CPT® 70548) or CTA Neck (CPT® 70498) can be performed at the following intervals:
 - Every 6 months until one of the following occurs:
 - Intervention is performed
 - Decision is made to not intervene
 - MRA Neck with contrast (CPT® 70548) or CTA Neck (CPT® 70498) is indicated if duplex Ultrasound shows $\geq 70\%$ occlusion/stenosis of the internal carotid artery or the ICA/CCA ratio is >4.0 , even with a lower percentage of stenosis.
 - If carotid stent is planned
 - MRA Head (CPT® 70544, or CPT® 70545, or CPT® 70546) or CTA Head (CPT® 70496) can be added

Surveillance Imaging WITH History of Carotid Surgery or Intervention (PVD-3.3)

PVD.CV.0003.3.A

v1.0.2024

- Duplex ultrasound (CPT® 93880 bilateral or CPT® 93882 unilateral) is indicated post-carotid surgery or intervention at the following intervals:
 - 1 month after procedure
 - Every 6 months for 2 years after procedure
 - Then annually
- If $\geq 70\%$ residual internal carotid stenosis is seen on duplex at 1 month after procedure
 - Duplex ultrasound (CPT® 93880 bilateral or CPT® 93882 unilateral) or CTA Neck (CPT® 70498) or MRA Neck (CPT® 70548) is indicated at the following intervals:
 - Every 3-6 months for one year
 - Then annually or until decision is made to re-intervene.
- If $\geq 70\%$ residual internal carotid stenosis is seen on duplex at any time post-procedure, then
 - CTA Neck (CPT® 70498) or MRA Neck (CPT® 70548) is indicated for further evaluation and at six-month intervals until decision is made to re-intervene.

Background and Supporting Information

- Carotid intima-media thickness using duplex ultrasound imaging (Category III code 0126T) is not recommended in clinical practice for risk assessment for a first ASCVD event. Although outcomes data are lacking, Texas has adopted this method in Texas Heart Attack Preventive Screening Bill (HR 1290)
- Texas Heart Attack Preventive Screening Law (HR 1290) mandates that insurers in Texas cover either a calcium scoring study (CPT® 75571 or HCPCS S8092) or a carotid intima-media thickness study (ultrasound—Category III code 0126T) every five years for certain populations. To qualify, the following must apply:
 - Must be a member of a fully-insured Texas health plan.
 - Must be male sex assigned at birth age 45 to 75 or female sex assigned at birth age 55 to 75.
 - Must have either diabetes or a Framingham cardiac risk score of intermediate or higher.
 - Must not have had a calcium scoring study or a carotid intima-media thickness study within the past 5 years

- MRA Neck (CPT® 70548) or CTA Neck (CPT® 70498) may be indicated if ultrasound is technically difficult or confirmation of the degree of stenosis on ultrasound is needed because an interventional procedure is being considered

References

v1.0.2024

1. Aboyans V, Ricco J-B, Bartelink M-LEL, et al. 2017 ESC Guidelines on the Diagnosis and Treatment of Peripheral Arterial Diseases, in collaboration with the European Society for Vascular Surgery (ESVS). *European Heart Journal*. 2017;39(9):763-816. doi:10.1093/eurheartj/ehx095.
2. ACR–AIUM–SPR–SRU. AIUM Practice Parameter for the Performance of an Ultrasound Examination of the Extracranial Cerebrovascular System. *Journal of Ultrasound in Medicine*. 2016;35(9):1-11. doi:10.7863/ultra.35.9.1.
3. Salmela MB, Mortazavi S, Jagadeesan BD, et al. Expert Panel on Neurologic Imaging. ACR Appropriateness Criteria® Cerebrovascular Disease. *J Am Coll Radiol*. 2017;14(5S):S34-S61. doi:10.1016/j.jacr.2017.01.051.
4. Brott TG, Halperin JL, Abbara S, et al. 2011 ASA/ACCF/AHA/AANN/AANS/ACR/ASNR/CNS/SAIP/SCAI/SIR/SNIS/SVM/SVS Guideline on the Management of Patients with Extracranial Carotid and Vertebral Artery Disease. *J Am Coll Cardiol*. 2011;57(8). doi:10.1016/j.jacc.2010.11.006.
5. Aburahma AF, Srivastava M, Aburahma Z, et al. The value and economic analysis of routine postoperative carotid duplex ultrasound surveillance after carotid endarterectomy. *J Vasc Surg*. 2015;62(2):378-384. doi:10.1016/j.jvs.2015.03.023.
6. Derdeyn CP, Zipfel GJ, Albuquerque FC, et al. Management of Brain Arteriovenous Malformations: A Scientific Statement for Healthcare Professionals from the American Heart Association/American Stroke Association. *Stroke*. 2017;48(8). doi:10.1161/str.000000000000134.
7. Gerhard-Herman M, Gardin JM, Jaff M, Mohler E, Roman M, Naqvi TZ. Guidelines for Noninvasive Vascular Laboratory Testing: A Report from the American Society of Echocardiography and the Society of Vascular Medicine and Biology. *J Am Soc Echocardiogr*. 2006;19(8):955-972. doi:10.1016/j.echo.2006.04.019.
8. Goff DC, Lloyd-Jones DM, Bennett G, et al. 2013 ACC/AHA Guideline on the Assessment of Cardiovascular Risk. *Circulation*. 2014;129(25 suppl 2):s49-s73. doi:10.1161/01.cir.0000437741.48606.98.
9. Mohler ER, Gornik HL, Gerhard-Herman M, Misra S, Olin JW, Zierler RE. ACCF/ACR/AIUM/ASE/ASN/ICAVL/SCAI/SCCT/SIR/SVM/SVS 2012 Appropriate Use Criteria for Peripheral Vascular Ultrasound and Physiological Testing Part I: Arterial Ultrasound and Physiological Testing. *J Am Coll Cardiol*. 2012;60(3):242-276. doi:10.1016/j.jacc.2012.02.009.
10. Moresoli P, Habib B, Reynier P, et al. Carotid Stenting versus Endarterectomy for Asymptomatic Carotid Artery Stenosis. *Stroke*. 2017;48(8):2150-2157. doi:10.1161/strokeaha.117.016824.
11. Naylor A, Ricco J-B, Borst GD, et al. Editor's Choice – Management of Atherosclerotic Carotid and Vertebral Artery Disease: 2017 Clinical Practice Guidelines of the European Society for Vascular Surgery (ESVS). *Eur J Vasc Endovasc Surg*. 2018;55(1):3-81. doi:10.1016/j.ejvs.2017.06.021.
12. Hasan B, Farah M, Nayfeh T, et al. A systematic review supporting the Society for Vascular Surgery Guidelines on the management of carotid artery disease. *J Vasc Surg*. 2022;75(1S):99S-108S.e42. doi:10.1016/j.jvs.2021.06.001.
13. Shakarchi JA, Lowry D, Nath J, et al. Duplex ultrasound surveillance after carotid artery endarterectomy. *Journal of Vascular Surgery*. 2016;63(6):1647-1650. doi:10.1016/j.jvs.2016.01.054.

Aortic Imaging

Guideline

Aortic Disorders General Information (PVD-6.1)

Thoracic Aortic Aneurysm (TAA) (PVD-6.2)

Abdominal Aortic Aneurysm (AAA) (PVD-6.3)

Iliac Artery Aneurysm (IAA) (PVD-6.4)

Aortic and Arterial Dissection and Other Aortic Conditions (PVD-6.7)

Post Aortic Endovascular/Open Surgery Surveillance Studies (PVD-6.8)

Large Vessel Vasculitis (PVD-6.9)

Medium Vessel Vasculitis (PVD-6.10)

Small Vessel Vasculitis (PVD-6.11)

Aortic Disorders General Information (PVD-6.1)

PVD.AD.0006.1.A

v1.0.2024

Duplex ultrasound for visceral vascular studies	CPT®
Duplex scan of arterial inflow and venous outflow of abdominal, pelvic, scrotal contents and/or retroperitoneal organs; complete study.	93975
Duplex scan of arterial inflow and venous outflow of abdominal, pelvic, scrotal contents and/or retroperitoneal organs; limited study.	93976
Duplex scan of aorta, inferior vena cava, iliac vasculature, or bypass grafts; complete study.	93978
Duplex scan of aorta, inferior vena cava, iliac vasculature, or bypass grafts; unilateral or limited study.	93979
Ultrasound, abdominal aorta, real time, with image documentation, screening study for abdominal aortic aneurysm (AAA) for AAA screening	76706

- In clinical practice, CT, CTA, MRA are usually preferred to evaluate for stenosis of these vessels rather than ultrasound (Exception: Duplex ultrasound is indicated to rule out testicular or ovarian torsion or to evaluate an abdominal bruit or a pulsatile abdominal mass).
- Mesenteric Ischemia
 - See **Mesenteric/Colonic Ischemia (AB-6)** in the Abdomen Imaging Guidelines.

References

1. Bonci G, Steigner ML, et al. ACR Appropriateness Criteria® Thoracic Aorta Interventional Planning and Follow-Up. *J Am Coll Radiol.* 2017;14(11S):S570-S583. doi:10.1016/j.jacr.2017.08.042.
2. Kalva SP, Dill KE, et al. ACR Appropriateness Criteria® nontraumatic aortic disease. *J Thorac Imaging.* 2014;29(5):W85-W88. doi:10.1097/RTI.000000000000107.
3. Albornoz G, Coady MA, Roberts M, et al. Familial thoracic aortic aneurysms and dissections--incidence, modes of inheritance, and phenotypic patterns. *Ann Thorac Surg.* 2006;82(4):1400-1405. doi:10.1016/j.athoracsur.2006.04.098.
4. Anderson JL, Halperin JL, Albert N, et al. Management of Patients with Peripheral Artery Disease (Compilation of 2005 and 2011 ACCF/AHA Guideline Recommendations).. *J Am Coll Cardiol.* 2013;61(14):1555-1570. doi:10.1016/j.jacc.2013.01.004.
5. Bennett SJ, Dill KE, Hanley M, et al. ACR Appropriateness Criteria® Suspected Thoracic Aortic Aneurysm. *J Am Coll Radiol.* 2018;15(5). doi:10.1016/j.jacr.2018.03.031.
6. Chaikof EL, Dalman RL, Eskandari MK, et al. The Society for Vascular Surgery practice guidelines on the care of patients with an abdominal aortic aneurysm. *J Vasc Surg.* 2018;67(1). doi:10.1016/j.jvs.2017.10.044.
7. Elefteriades JA. Natural history of thoracic aortic aneurysms: indications for surgery, and surgical versus nonsurgical risks. *Ann Thorac Surg* 2002; 74: S1877-S1880.
8. Erben Y, Brownstein AJ, Rajaei S. Natural History of and Management of Splanchnic Artery Aneurysms in a Single Tertiary Referral Center. *J Vasc Surg* 2018 Oct; 68(4): 1079-1087.

9. Chaer RA, Abularrage CJ, Coleman DM, et al. The Society for Vascular Surgery clinical practice guidelines on the management of visceral aneurysms. *J Vasc Surg.* 2020;72(1S):3S-39S. doi:10.1016/j.jvs.2020.01.039.
10. Expert Panel on Cardiac Imaging. ACR Appropriateness Criteria® Acute Chest Pain -- Suspected Aortic Dissection. *American College of Radiology (ACR)*; 2014.
11. Collard M, Sutphin PD, Kalva SP, et al. Expert Panel on Vascular Imaging. ACR Appropriateness Criteria® Abdominal Aortic Aneurysm Follow-up (without Repair). *J Am Coll Radiol.* 2019;16(5S):S2-S6. doi:10.1016/j.jacr.2019.02.005.
12. Corey MR, Ergul EA, Cambria RP. The Natural History of Splanchnic Aneurysms and Outcome after Operative Intervention. *J Vasc Surg.* 2016 April 63 (4):949-57.
13. Dejaco C, Ramiro S, Duftner C, et al. EULAR recommendations for the use of imaging in large vessel vasculitis in clinical practice. *Annals of the Rheumatic Diseases.* 2018;77(5):636-643. doi:10.1136/annrheumdis-2017-212649.
14. Diercks D, Promes S, Schuur J, et al. American College of Emergency Physicians. Clinical policy: critical issues in the evaluation and management of adult patients with suspected acute nontraumatic thoracic aortic dissection. *Ann Emerg Med.* 2015 Jan; 65 (1) :32-42.
15. Francois CJ, Skulborstad EP, Majdalany BS, et al. Expert Panels on Vascular Imaging and Interventional Radiology. ACR Appropriateness Criteria® Abdominal Aortic Aneurysm: Interventional Planning and Follow-Up. *J Am Coll Radiol.* 2018;15(5S):S2-S12. doi:10.1016/j.jacr.2018.03.008.
16. Harvin HJ, Verma N, Nikolaidis P, et al. ACR Appropriateness Criteria® Renovascular Hypertension. *J Am Coll Radiol.* 2017;14(11). doi:10.1016/j.jacr.2017.08.040.
17. Hiratzka LF, Bakris GL, Beckman JA, et al. 2010 ACCF/AHA/AATS/ACR/ASA/SCA/SCAI/SIR/STS/SVM Guidelines for the diagnosis and management of patients with thoracic aortic disease. A Report of the American College of Cardiology Foundation/American Heart Association Task Force on Practice Guidelines, American Association for Thoracic Surgery, American College of Radiology, American Stroke Association, Society of Cardiovascular Anesthesiologists, Society for Cardiovascular Angiography and Interventions, Society of Interventional Radiology, Society of Thoracic Surgeons, and Society for Vascular Medicine [published correction appears in *J Am Coll Cardiol.* 2013 Sep 10;62(11):1039-40]. *J Am Coll Cardiol.* 2010;55(14):e27-e129. doi:10.1016/j.jacc.2010.02.015.
18. Kallianos KG, Burrell NS. Imaging Thoracic Aortic Aneurysm. *Radiol Clin North Am.* 2020;58(4):721-731. doi:10.1016/j.rcl.2020.02.009.
19. Loren F, Hiratzka MD, et al, 2010 ACCF/AHA/AATS/ACR/ASA/SCA/SCAI/SIR/STS/SVM Guidelines for the Diagnosis and Management of Patients with Thoracic Aortic Disease. *Circulation* 2010; 121: e266-e369.
20. Masuda Y1, Yamada Z, Morooka N, Watanabe S, Inagaki Y. Prognosis of patients with medically treated aortic dissections. *Circulation.* 1991 Nov;84(5 Suppl):III7-13.
21. Moser M, Setaro JF. Resistant or Difficult-to-Control Hypertension. *New England Journal of Medicine.* 2006;355(4):385-392. doi:10.1056/nejmcp041698.
22. Persu A, Giavarini A, Touzé E, et al. European consensus on the diagnosis and management of fibromuscular dysplasia. *Journal of Hypertension.* 2014;32(7):1367-1378. doi:10.1097/hjh.0000000000000213.
23. Sakamoto I, Sueyoshi E, Hazama S, et al. Endovascular treatment of iliac artery aneurysms. *Radiographics* October 2005;25:S213-S227.
24. Shiga T, Wajima Z, Apfel CC, Inoue T, Ohe Y. Diagnostic Accuracy of Transesophageal Echocardiography, Helical Computed Tomography, and Magnetic Resonance Imaging for Suspected Thoracic Aortic Dissection: Systematic Review and Meta-analysis. *Arch Intern Med* 2006; 166 (13): 1350-1356.
25. Alcantara S, Yang CK, Sasson J, et al. The evidence for nonoperative management of visceral artery dissections: a single-center experience. *Ann Vasc Surg.* 2015;29(1):103-108. doi:10.1016/j.avsg.2014.09.004.
26. Smith T, Quencer KB. Best Practice Guidelines: Imaging Surveillance After Endovascular Aneurysm Repair. *American Journal of Roentgenology.* 2020;214(5):1165-1174. doi:10.2214/ajr.19.22197.
27. Tadros TM, Klein MD, Shapira OM. Ascending aortic dilatation associated with bicuspid aortic valve. *Circulation* 2009; 119: 880-890.
28. Taimen K, Salomäki SP, Hohenthal U, et al. The Clinical Impact of Using 18F-FDG-PET/CT in the Diagnosis of Suspected Vasculitis: The Effect of Dose and Timing of Glucocorticoid Treatment. *Contrast Media & Molecular Imaging.* 2019;2019:1-8. doi:10.1155/2019/9157637.
29. van Bogerijen GH, Tolenaar JL, Rampoldi V, et al. Predictors of aortic growth in uncomplicated type B aortic dissection. *J Vasc Surg.* 2014 Apr;59(4):1134-43. doi: 10.1016/j.jvs.2014.01.042.
30. Whelton PK, Carey RM, Aronow WS, et al. 2017 ACC/AHA/AAPA/ABC/ACPM/AGS/APhA/ASH/ASPC/NMA/PCNA Guideline for the Prevention, Detection, Evaluation, and Management of High Blood Pressure in Adults: A Report of the American College of Cardiology/American Heart Association Task Force on Clinical Practice Guidelines. *Hypertension.* 2018;71(6). doi:10.1161/hyp.0000000000000065.

31. Zierler RE, Jordan WD, Lal BK, et al. The Society for Vascular Surgery practice guidelines on follow-up after vascular surgery arterial procedures. *J Vasc Surg* . 2018;68(1):256-284. doi:10.1016/j.jvs.2018.04.018.1.
32. Salim S, Machin M, Patterson BO, Bicknell C. The Management of Penetrating Aortic Ulcer. *Hearts*. 2020;1(1):5-13. doi:10.3390/hearts1010003.

Thoracic Aortic Aneurysm (TAA) (PVD-6.2)

PVD.AI.0006.2.A
v1.0.2024

- Advanced imaging with a CT or MR is preferred imaging for this diagnosis. Transesophageal echocardiogram (TEE) can also be indicated for initial imaging of ascending and descending thoracic aortic aneurysms. For repeat imaging or established thoracic aneurysms, TEE is indicated **only** when imaging with CT or MR is contraindicated.
- Given the diversity of studies, pathology, and provider preference, **ONE** of the imaging studies in the Table of Thoracic Aorta Imaging Options can be approved for Thoracic Aortic Aneurysm (TAA) as indicated in this section

Table of Thoracic Aorta Imaging Options	CPT®
CT Chest with contrast	71260
CT Chest without contrast	71250
CTA Chest	71275
MRA Chest	71555
TEE	93312- 93314

- For TAA associated with a dissection, please see section **Aortic Dissection and Other Aortic Conditions (PVD-6.7)**
- For suspected TAA, any requested imaging from the Table of Thoracic Aorta Imaging Options above:
 - Abnormalities identified on chest x-ray (abnormality including widened mediastinum, suspicious calcifications) or other imaging studies (fluoroscopy, MRI Spine, etc.) abnormality.
- For known TAA accompanied with chest pain or back pain and suspicion of rupture, any requested imaging from the Table of Thoracic Aorta Imaging Options above.
- For planning for pre-thoracic endovascular repair (TEVAR) of thoracic aorta disease.
 - CTA Chest, and/or Abdomen, and/or Pelvis (CPT® 71275, CPT® 74175, CPT® 72191, CPT® 74174); or
 - MRA Chest, and/or Abdomen, and/or Pelvis (CPT® 71555, CPT® 74185, CPT® 72198).
- For follow-up of ascending aortic aneurysms CTA Chest (CPT® 71275) or CT Chest (CPT® 71250 or CPT® 71260) or MRA chest (CPT® 71555)
 - Operative treatment is reasonable for asymptomatic individuals when the diameter of the arch exceeds 5.5 cm.
 - For individuals with ascending aortic aneurysms <4.0 cm in diameter

- Repeat imaging annually
- For individuals with ascending aortic aneurysms ≥ 4.0 cm
 - Repeat imaging 6 months.
 - TEE is indicated **only** when imaging with CT or MR is contraindicated
- For follow-up of descending aortic aneurysms, any requested imaging from the “Table of Thoracic Aorta Imaging Options” above for the following:
 - “Medically” treated/observation.
 - 3.5cm to 4.4 cm TAA can be followed annually.
 - ≥ 4.5 cm TAA can be followed every 6 months.
 - ≥ 3.0 cm TAA when there is concern for growth can have a one-time 3-month interval advanced imaging.
 - TEE is indicated **only** when imaging with CT or MR is contraindicated
- Screening in the presence of other aortic aneurysms.
 - In an individual with a known TAA, screening for AAA is indicated with an abdominal duplex. See **Abdominal Aortic Aneurysm (AAA) (PVD-6.3)**.
 - In an individual with a known AAA, screening for TAA is not supported by sufficient evidence.
- Screening in individuals with bicuspid aortic valve or familial TAA syndromes. See **Screening for TAA with bicuspid aortic valve (PVD-2.3)**. See **Screening for Vascular related genetic connective tissue Disorders (PVD-2.2)**

Background and Supporting Information

The thoracic aorta is generally divided into two segments: the ascending aorta, which includes the aortic root, aortic arch and ends just distal to the left subclavian artery and the descending aorta, which starts just distal to the left subclavian artery to the level of the diaphragm.

References

1. Bonci G, Steigner ML, et al. ACR Appropriateness Criteria® Thoracic Aorta Interventional Planning and Follow-Up. *J Am Coll Radiol*. 2017;14(11S):S570-S583. doi:10.1016/j.jacr.2017.08.042.
2. Kalva SP, Dill KE, et al. ACR Appropriateness Criteria® nontraumatic aortic disease. *J Thorac Imaging*. 2014;29(5):W85-W88. doi:10.1097/RTI.000000000000107.
3. Albornoz G, Coady MA, Roberts M, et al. Familial thoracic aortic aneurysms and dissections--incidence, modes of inheritance, and phenotypic patterns. *Ann Thorac Surg*. 2006;82(4):1400-1405. doi:10.1016/j.athoracsur.2006.04.098.
4. Anderson JL, Halperin JL, Albert N, et al. Management of Patients with Peripheral Artery Disease (Compilation of 2005 and 2011 ACCF/AHA Guideline Recommendations).. *J Am Coll Cardiol*. 2013;61(14):1555-1570. doi:10.1016/j.jacc.2013.01.004.
5. Bennett SJ, Dill KE, Hanley M, et al. ACR Appropriateness Criteria® Suspected Thoracic Aortic Aneurysm. *J Am Coll Radiol*. 2018;15(5). doi:10.1016/j.jacr.2018.03.031.
6. Chaikof EL, Dalman RL, Eskandari MK, et al. The Society for Vascular Surgery practice guidelines on the care of patients with an abdominal aortic aneurysm. *J Vasc Surg*. 2018;67(1). doi:10.1016/j.jvs.2017.10.044.

7. Elefteriades JA. Natural history of thoracic aortic aneurysms: indications for surgery, and surgical versus nonsurgical risks. *Ann Thorac Surg* 2002; 74: S1877-S1880.
8. Erben Y, Brownstein AJ, Rajaei S. Natural History of and Management of Splanchnic Artery Aneurysms in a Single Tertiary Referral Center. *J Vasc Surg* 2018 Oct; 68(4): 1079-1087.
9. Chaer RA, Abularrage CJ, Coleman DM, et al. The Society for Vascular Surgery clinical practice guidelines on the management of visceral aneurysms. *J Vasc Surg*. 2020;72(1S):3S-39S. doi:10.1016/j.jvs.2020.01.039.
10. Expert Panel on Cardiac Imaging. ACR Appropriateness Criteria® Acute Chest Pain -- Suspected Aortic Dissection. *American College of Radiology (ACR)*; 2014.
11. Collard M, Sutphin PD, Kalva SP, et al. Expert Panel on Vascular Imaging. ACR Appropriateness Criteria® Abdominal Aortic Aneurysm Follow-up (without Repair). *J Am Coll Radiol*. 2019;16(5S):S2-S6. doi:10.1016/j.jacr.2019.02.005.
12. Corey MR, Ergul EA, Cambria RP. The Natural History of Splanchnic Aneurysms and Outcome after Operative Intervention. *J Vasc Surg*. 2016 April 63 (4):949-57.
13. DeJaco C, Ramiro S, Duftner C, et al. EULAR recommendations for the use of imaging in large vessel vasculitis in clinical practice. *Annals of the Rheumatic Diseases*. 2018;77(5):636-643. doi:10.1136/annrheumdis-2017-212649.
14. Diercks D, Promes S, Schuur J, et al. American College of Emergency Physicians. Clinical policy: critical issues in the evaluation and management of adult patients with suspected acute nontraumatic thoracic aortic dissection. *Ann Emerg Med*. 2015 Jan; 65 (1) :32-42.
15. Francois CJ, Skulborstad EP, Majdalany BS, et al. Expert Panels on Vascular Imaging and Interventional Radiology. ACR Appropriateness Criteria® Abdominal Aortic Aneurysm: Interventional Planning and Follow-Up. *J Am Coll Radiol*. 2018;15(5S):S2-S12. doi:10.1016/j.jacr.2018.03.008.
16. Harvin HJ, Verma N, Nikolaidis P, et al. ACR Appropriateness Criteria® Renovascular Hypertension. *J Am Coll Radiol*. 2017;14(11). doi:10.1016/j.jacr.2017.08.040.
17. Hiratzka LF, Bakris GL, Beckman JA, et al. 2010 ACCF/AHA/AATS/ACR/ASA/SCA/SCAI/SIR/STS/SVM Guidelines for the diagnosis and management of patients with thoracic aortic disease. A Report of the American College of Cardiology Foundation/American Heart Association Task Force on Practice Guidelines, American Association for Thoracic Surgery, American College of Radiology, American Stroke Association, Society of Cardiovascular Anesthesiologists, Society for Cardiovascular Angiography and Interventions, Society of Interventional Radiology, Society of Thoracic Surgeons, and Society for Vascular Medicine [published correction appears in *J Am Coll Cardiol*. 2013 Sep 10;62(11):1039-40]. *J Am Coll Cardiol*. 2010;55(14):e27-e129. doi:10.1016/j.jacc.2010.02.015.
18. Kallianos KG, Burris NS. Imaging Thoracic Aortic Aneurysm. *Radiol Clin North Am*. 2020;58(4):721-731. doi:10.1016/j.rcl.2020.02.009.
19. Loren F, Hiratzka MD, et al. 2010 ACCF/AHA/AATS/ACR/ASA/SCA/SCAI/SIR/STS/SVM Guidelines for the Diagnosis and Management of Patients with Thoracic Aortic Disease. *Circulation* 2010; 121: e266-e369.
20. Masuda Y1, Yamada Z, Morooka N, Watanabe S, Inagaki Y. Prognosis of patients with medically treated aortic dissections. *Circulation*. 1991 Nov;84(5 Suppl):III7-13.
21. Moser M, Setaro JF. Resistant or Difficult-to-Control Hypertension. *New England Journal of Medicine*. 2006;355(4):385-392. doi:10.1056/nejmcp041698.
22. Persu A, Giavarini A, Touzé E, et al. European consensus on the diagnosis and management of fibromuscular dysplasia. *Journal of Hypertension*. 2014;32(7):1367-1378. doi:10.1097/hjh.0000000000000213.
23. Sakamoto I, Sueyoshi E, Hazama S, et al. Endovascular treatment of iliac artery aneurysms. *Radiographics* October 2005;25:S213-S227.
24. Shiga T, Wajima Z, Apfel CC, Inoue T, Ohe Y. Diagnostic Accuracy of Transesophageal Echocardiography, Helical Computed Tomography, and Magnetic Resonance Imaging for Suspected Thoracic Aortic Dissection: Systematic Review and Meta-analysis. *Arch Intern Med* 2006; 166 (13): 1350-1356.
25. Alcantara S, Yang CK, Sasson J, et al. The evidence for nonoperative management of visceral artery dissections: a single-center experience. *Ann Vasc Surg*. 2015;29(1):103-108. doi:10.1016/j.avsg.2014.09.004.
26. Smith T, Quencer KB. Best Practice Guidelines: Imaging Surveillance After Endovascular Aneurysm Repair. *American Journal of Roentgenology*. 2020;214(5):1165-1174. doi:10.2214/ajr.19.22197.
27. Tadros TM, Klein MD, Shapira OM. Ascending aortic dilatation associated with bicuspid aortic valve. *Circulation* 2009; 119: 880-890.
28. Taimen K, Salomäki SP, Hohenthal U, et al. The Clinical Impact of Using 18F-FDG-PET/CT in the Diagnosis of Suspected Vasculitis: The Effect of Dose and Timing of Glucocorticoid Treatment. *Contrast Media & Molecular Imaging*. 2019;2019:1-8. doi:10.1155/2019/9157637.
29. van Bogerijen GH, Tolenaar JL, Rampoldi V, et al. Predictors of aortic growth in uncomplicated type B aortic dissection. *J Vasc Surg*. 2014 Apr;59(4):1134-43. doi: 10.1016/j.jvs.2014.01.042.
30. Whelton PK, Carey RM, Aronow WS, et al. 2017 ACC/AHA/AAPA/ABC/ACPM/AGS/APhA/ASH/ASPC/NMA/PCNA Guideline for the Prevention, Detection,

Evaluation, and Management of High Blood Pressure in Adults: A Report of the American College of Cardiology/American Heart Association Task Force on Clinical Practice Guidelines. *Hypertension*. 2018;71(6). doi:10.1161/hyp.0000000000000065.

31. Zierler RE, Jordan WD, Lal BK, et al. The Society for Vascular Surgery practice guidelines on follow-up after vascular surgery arterial procedures. *J Vasc Surg* . 2018;68(1):256-284. doi:10.1016/j.jvs.2018.04.018.1.
32. Salim S, Machin M, Patterson BO, Bicknell C. The Management of Penetrating Aortic Ulcer. *Hearts*. 2020;1(1):5-13. doi:10.3390/hearts1010003.

Abdominal Aortic Aneurysm (AAA) (PVD-6.3)

PVD.AD.0006.3.A

v1.0.2024

Screen for AAA

- Ultrasound abdominal aorta with any of the studies from the table of Duplex ultrasound for visceral vascular studies in **Aortic Disorders General Information (PVD-6.1)** is the preferred initial imaging study to screen for AAA.
- One-time screening recommendations for AAA (Ultrasound CPT® 76706)
 - Individuals 65 to 75 years of age with a history of tobacco use.
 - Individuals older than 75 years with a history of tobacco use and in otherwise good health who have not previously received a screening ultrasound examination.
 - All first-degree relatives of individuals who present with an AAA and are between 65 and 75, or in those older than 75 in good health.
- AAA screening is reasonable with ultrasound (CPT® 76706, 93975, 93976, 93978, or 93979) if there is a documented thoracic aortic aneurysm; however, there is insufficient evidence to support the use of advanced imaging to screen for a thoracic aortic aneurysm in individuals with known abdominal aortic aneurysm.

Survey known AAA

- Ultrasound abdominal aorta with any of the studies from the table of Duplex ultrasound for visceral vascular studies in **Aortic Disorders General Information (PVD-6.1)** is the preferred initial imaging study to survey known AAA.
- Surveillance recommendations for AAA (CPT® 76706, 93975, 93976, 93978, 93979)
 - >2.5 cm but <3.0 cm: 10 years
 - 3.0 cm to 3.9 cm: 3 year intervals
 - 4.0 cm to 4.9 cm: every 12 months
 - 5.0 cm to 5.4 cm: every 6 months
 - >5.4 cm or aortic diameter has increased in size by 0.5 cm in six months, or at least 1 cm in a year may undergo more frequent monitoring and should be evaluated by a Vascular Specialist
- Additional Imaging
 - CT Abdomen and Pelvis with contrast (CPT® 74177), CT Abdomen and Pelvis without contrast (CPT® 74176), or CTA Abdomen and Pelvis (CPT® 74174), or CTA Abdomen (CPT® 74175), or CTA Pelvis (CPT® 72191).
 - Suspected or known AAA with recent-onset abdominal or back pain, particularly in the presence of a pulsatile epigastric mass or significant risk factors for AAA
 - Pre-operative imaging for AAA repair

Evaluate a pulsatile abdominal mass

- Ultrasound abdominal aorta with any of the studies from the table of Duplex ultrasound for visceral vascular studies in **Aortic Disorders General Information (PVD-6.1)** is the preferred initial imaging study to evaluate a pulsatile abdominal mass.
- Additional Imaging
 - CT Abdomen and Pelvis with contrast (CPT® 74177), CT Abdomen and Pelvis without contrast (CPT® 74176), or CTA Abdomen and Pelvis (CPT® 74174), or CTA Abdomen (CPT® 74175), or CTA Pelvis (CPT® 72191).
 - Suspected or known AAA with recent-onset abdominal or back pain, particularly in the presence of a pulsatile epigastric mass or significant risk factors for AAA
 - Pre-operative imaging for AAA repair

Obese Individual (BMI ≥35)

- CT Abdomen and Pelvis with contrast (CPT® 74177) or without contrast (CPT® 74176) can be substituted for US using the same timeline as a non-obese individual. Ultrasound abdominal aorta should ideally first be attempted to see if the image quality is adequate.

References

1. Bonci G, Steigner ML, et al. ACR Appropriateness Criteria® Thoracic Aorta Interventional Planning and Follow-Up. *J Am Coll Radiol*. 2017;14(11S):S570-S583. doi:10.1016/j.jacr.2017.08.042.
2. Kalva SP, Dill KE, et al. ACR Appropriateness Criteria® nontraumatic aortic disease. *J Thorac Imaging*. 2014;29(5):W85-W88. doi:10.1097/RTI.000000000000107.
3. Albornoz G, Coady MA, Roberts M, et al. Familial thoracic aortic aneurysms and dissections--incidence, modes of inheritance, and phenotypic patterns. *Ann Thorac Surg*. 2006;82(4):1400-1405. doi:10.1016/j.athoracsur.2006.04.098.
4. Anderson JL, Halperin JL, Albert N, et al. Management of Patients with Peripheral Artery Disease (Compilation of 2005 and 2011 ACCF/AHA Guideline Recommendations).. *J Am Coll Cardiol*. 2013;61(14):1555-1570. doi:10.1016/j.jacc.2013.01.004.
5. Bennett SJ, Dill KE, Hanley M, et al. ACR Appropriateness Criteria® Suspected Thoracic Aortic Aneurysm. *J Am Coll Radiol*. 2018;15(5). doi:10.1016/j.jacr.2018.03.031.
6. Chaikof EL, Dalman RL, Eskandari MK, et al. The Society for Vascular Surgery practice guidelines on the care of patients with an abdominal aortic aneurysm. *J Vasc Surg*. 2018;67(1). doi:10.1016/j.jvs.2017.10.044.
7. Elefteriades JA. Natural history of thoracic aortic aneurysms: indications for surgery, and surgical versus nonsurgical risks. *Ann Thorac Surg* 2002; 74: S1877-S1880.
8. Erben Y, Brownstein AJ, Rajae S. Natural History of and Management of Splanchnic Artery Aneurysms in a Single Tertiary Referral Center. *J Vasc Surg* 2018 Oct; 68(4): 1079-1087.
9. Chaer RA, Abularrage CJ, Coleman DM, et al. The Society for Vascular Surgery clinical practice guidelines on the management of visceral aneurysms. *J Vasc Surg*. 2020;72(1S):3S-39S. doi:10.1016/j.jvs.2020.01.039.
10. Expert Panel on Cardiac Imaging. ACR Appropriateness Criteria® Acute Chest Pain -- Suspected Aortic Dissection. *American College of Radiology (ACR)*; 2014.
11. Collard M, Sutphin PD, Kalva SP, et al. Expert Panel on Vascular Imaging. ACR Appropriateness Criteria® Abdominal Aortic Aneurysm Follow-up (without Repair). *J Am Coll Radiol*. 2019;16(5S):S2-S6. doi:10.1016/j.jacr.2019.02.005.
12. Corey MR, Ergul EA, Cambria RP. The Natural History of Splanchnic Aneurysms and Outcome after Operative Intervention. *J Vasc Surg*. 2016 April 63 (4):949-57.

13. DeJaco C, Ramiro S, Duftner C, et al. EULAR recommendations for the use of imaging in large vessel vasculitis in clinical practice. *Annals of the Rheumatic Diseases*. 2018;77(5):636-643. doi:10.1136/annrheumdis-2017-212649.
14. Diercks D, Promes S, Schuur J, et al. American College of Emergency Physicians. Clinical policy: critical issues in the evaluation and management of adult patients with suspected acute nontraumatic thoracic aortic dissection. *Ann Emerg Med*. 2015 Jan; 65 (1) :32-42.
15. Francois CJ, Skulborstad EP, Majdalany BS, et al. Expert Panels on Vascular Imaging and Interventional Radiology. ACR Appropriateness Criteria® Abdominal Aortic Aneurysm: Interventional Planning and Follow-Up. *J Am Coll Radiol*. 2018;15(5S):S2-S12. doi:10.1016/j.jacr.2018.03.008.
16. Harvin HJ, Verma N, Nikolaidis P, et al. ACR Appropriateness Criteria® Renovascular Hypertension. *J Am Coll Radiol*. 2017;14(11). doi:10.1016/j.jacr.2017.08.040.
17. Hiratzka LF, Bakris GL, Beckman JA, et al. 2010 ACCF/AHA/AATS/ACR/ASA/SCA/SCAI/SIR/STS/SVM Guidelines for the diagnosis and management of patients with thoracic aortic disease. A Report of the American College of Cardiology Foundation/American Heart Association Task Force on Practice Guidelines, American Association for Thoracic Surgery, American College of Radiology, American Stroke Association, Society of Cardiovascular Anesthesiologists, Society for Cardiovascular Angiography and Interventions, Society of Interventional Radiology, Society of Thoracic Surgeons, and Society for Vascular Medicine [published correction appears in *J Am Coll Cardiol*. 2013 Sep 10;62(11):1039-40]. *J Am Coll Cardiol*. 2010;55(14):e27-e129. doi:10.1016/j.jacc.2010.02.015.
18. Kallianos KG, Burris NS. Imaging Thoracic Aortic Aneurysm. *Radiol Clin North Am*. 2020;58(4):721-731. doi:10.1016/j.rcl.2020.02.009.
19. Loren F, Hiratzka MD, et al. 2010 ACCF/AHA/AATS/ACR/ASA/SCA/SCAI/SIR/STS/SVM Guidelines for the Diagnosis and Management of Patients with Thoracic Aortic Disease. *Circulation* 2010; 121: e266-e369.
20. Masuda Y1, Yamada Z, Morooka N, Watanabe S, Inagaki Y. Prognosis of patients with medically treated aortic dissections. *Circulation*. 1991 Nov;84(5 Suppl):III7-13.
21. Moser M, Setaro JF. Resistant or Difficult-to-Control Hypertension. *New England Journal of Medicine*. 2006;355(4):385-392. doi:10.1056/nejmcp041698.
22. Persu A, Giavarini A, Touzé E, et al. European consensus on the diagnosis and management of fibromuscular dysplasia. *Journal of Hypertension*. 2014;32(7):1367-1378. doi:10.1097/hjh.0000000000000213.
23. Sakamoto I, Sueyoshi E, Hazama S, et al. Endovascular treatment of iliac artery aneurysms. *Radiographics* October 2005;25:S213-S227.
24. Shiga T, Wajima Z, Apfel CC, Inoue T, Ohe Y. Diagnostic Accuracy of Transesophageal Echocardiography, Helical Computed Tomography, and Magnetic Resonance Imaging for Suspected Thoracic Aortic Dissection: Systematic Review and Meta-analysis. *Arch Intern Med* 2006; 166 (13): 1350-1356.
25. Alcantara S, Yang CK, Sasson J, et al. The evidence for nonoperative management of visceral artery dissections: a single-center experience. *Ann Vasc Surg*. 2015;29(1):103-108. doi:10.1016/j.avsg.2014.09.004.
26. Smith T, Quencer KB. Best Practice Guidelines: Imaging Surveillance After Endovascular Aneurysm Repair. *American Journal of Roentgenology*. 2020;214(5):1165-1174. doi:10.2214/ajr.19.22197.
27. Tadros TM, Klein MD, Shapira OM. Ascending aortic dilatation associated with bicuspid aortic valve. *Circulation* 2009; 119: 880-890.
28. Taimen K, Salomäki SP, Hohenthal U, et al. The Clinical Impact of Using 18F-FDG-PET/CT in the Diagnosis of Suspected Vasculitis: The Effect of Dose and Timing of Glucocorticoid Treatment. *Contrast Media & Molecular Imaging*. 2019;2019:1-8. doi:10.1155/2019/9157637.
29. van Bogerijen GH, Tolenaar JL, Rampoldi V, et al. Predictors of aortic growth in uncomplicated type B aortic dissection. *J Vasc Surg*. 2014 Apr;59(4):1134-43. doi: 10.1016/j.jvs.2014.01.042.
30. Whelton PK, Carey RM, Aronow WS, et al. 2017 ACC/AHA/AAPA/ABC/ACPM/AGS/APhA/ASH/ASPC/NMA/PCNA Guideline for the Prevention, Detection, Evaluation, and Management of High Blood Pressure in Adults: A Report of the American College of Cardiology/American Heart Association Task Force on Clinical Practice Guidelines. *Hypertension*. 2018;71(6). doi:10.1161/hyp.0000000000000065.
31. Zierler RE, Jordan WD, Lal BK, et al. The Society for Vascular Surgery practice guidelines on follow-up after vascular surgery arterial procedures. *J Vasc Surg* . 2018;68(1):256-284. doi:10.1016/j.jvs.2018.04.018.1.
32. Salim S, Machin M, Patterson BO, Bicknell C. The Management of Penetrating Aortic Ulcer. *Hearts*. 2020;1(1):5-13. doi:10.3390/hearts1010003.

Iliac Artery Aneurysm (IAA) (PVD-6.4)

PVD.AD.0006.4.A

v1.0.2024

- Ultrasound (CPT® 76882 or CPT® 93925) for evaluation of a suspected IAA
 - CT Pelvis with contrast (CPT® 72193) if ultrasound is equivocal.
 - Ultrasound for follow-up imaging annually if an aneurysm is ≥ 2 cm
- Additional Imaging
 - CT Abdomen and Pelvis with contrast (CPT® 74177), CT Abdomen and Pelvis without and with contrast (CPT® 74178), or CTA Abdomen and Pelvis (CPT® 74174) for preoperative imaging if endovascular or open repair is being considered

Background and Supporting Information

- Isolated IAA's are rare and are typically associated with AAA
- Approximately one third to one half of isolated IAA's are bilateral at time of presentation
- Abdominal Aortic aneurysm rupture usually occurs at a diameter of 5 cm or larger, whereas common iliac aneurysms that are less than 3 cm in diameter almost never rupture

References

1. Bonci G, Steigner ML, et al. ACR Appropriateness Criteria® Thoracic Aorta Interventional Planning and Follow-Up. *J Am Coll Radiol*. 2017;14(11S):S570-S583. doi:10.1016/j.jacr.2017.08.042.
2. Kalva SP, Dill KE, et al. ACR Appropriateness Criteria® nontraumatic aortic disease. *J Thorac Imaging*. 2014;29(5):W85-W88. doi:10.1097/RTI.000000000000107.
3. Albornoz G, Coady MA, Roberts M, et al. Familial thoracic aortic aneurysms and dissections--incidence, modes of inheritance, and phenotypic patterns. *Ann Thorac Surg*. 2006;82(4):1400-1405. doi:10.1016/j.athoracsur.2006.04.098.
4. Anderson JL, Halperin JL, Albert N, et al. Management of Patients with Peripheral Artery Disease (Compilation of 2005 and 2011 ACCF/AHA Guideline Recommendations). *J Am Coll Cardiol*. 2013;61(14):1555-1570. doi:10.1016/j.jacc.2013.01.004.
5. Bennett SJ, Dill KE, Hanley M, et al. ACR Appropriateness Criteria® Suspected Thoracic Aortic Aneurysm. *J Am Coll Radiol*. 2018;15(5). doi:10.1016/j.jacr.2018.03.031.
6. Chaikof EL, Dalman RL, Eskandari MK, et al. The Society for Vascular Surgery practice guidelines on the care of patients with an abdominal aortic aneurysm. *J Vasc Surg*. 2018;67(1). doi:10.1016/j.jvs.2017.10.044.
7. Elefteriades JA. Natural history of thoracic aortic aneurysms: indications for surgery, and surgical versus nonsurgical risks. *Ann Thorac Surg* 2002; 74: S1877-S1880.
8. Erben Y, Brownstein AJ, Rajaei S. Natural History of and Management of Splanchnic Artery Aneurysms in a Single Tertiary Referral Center. *J Vasc Surg* 2018 Oct; 68(4): 1079-1087.
9. Chaer RA, Abularrage CJ, Coleman DM, et al. The Society for Vascular Surgery clinical practice guidelines on the management of visceral aneurysms. *J Vasc Surg*. 2020;72(1S):3S-39S. doi:10.1016/j.jvs.2020.01.039.
10. Expert Panel on Cardiac Imaging. ACR Appropriateness Criteria® Acute Chest Pain -- Suspected Aortic Dissection. *American College of Radiology (ACR)*; 2014.

11. Collard M, Sutphin PD, Kalva SP, et al. Expert Panel on Vascular Imaging. ACR Appropriateness Criteria® Abdominal Aortic Aneurysm Follow-up (without Repair). *J Am Coll Radiol*. 2019;16(5S):S2-S6. doi:10.1016/j.jacr.2019.02.005.
12. Corey MR, Ergul EA, Cambria RP. The Natural History of Splanchnic Aneurysms and Outcome after Operative Intervention. *J Vasc Surg*. 2016 April 63 (4):949-57.
13. DeJaco C, Ramiro S, Duftner C, et al. EULAR recommendations for the use of imaging in large vessel vasculitis in clinical practice. *Annals of the Rheumatic Diseases*. 2018;77(5):636-643. doi:10.1136/annrheumdis-2017-212649.
14. Diercks D, Promes S, Schuur J, et al. American College of Emergency Physicians. Clinical policy: critical issues in the evaluation and management of adult patients with suspected acute nontraumatic thoracic aortic dissection. *Ann Emerg Med*. 2015 Jan; 65 (1) :32-42.
15. Francois CJ, Skulborstad EP, Majdalany BS, et al. Expert Panels on Vascular Imaging and Interventional Radiology. ACR Appropriateness Criteria® Abdominal Aortic Aneurysm: Interventional Planning and Follow-Up. *J Am Coll Radiol*. 2018;15(5S):S2-S12. doi:10.1016/j.jacr.2018.03.008.
16. Harvin HJ, Verma N, Nikolaidis P, et al. ACR Appropriateness Criteria® Renovascular Hypertension. *J Am Coll Radiol*. 2017;14(11). doi:10.1016/j.jacr.2017.08.040.
17. Hiratzka LF, Bakris GL, Beckman JA, et al. 2010 ACCF/AHA/AATS/ACR/ASA/SCA/SCAI/SIR/STS/SVM Guidelines for the diagnosis and management of patients with thoracic aortic disease. A Report of the American College of Cardiology Foundation/American Heart Association Task Force on Practice Guidelines, American Association for Thoracic Surgery, American College of Radiology, American Stroke Association, Society of Cardiovascular Anesthesiologists, Society for Cardiovascular Angiography and Interventions, Society of Interventional Radiology, Society of Thoracic Surgeons, and Society for Vascular Medicine [published correction appears in *J Am Coll Cardiol*. 2013 Sep 10;62(11):1039-40]. *J Am Coll Cardiol*. 2010;55(14):e27-e129. doi:10.1016/j.jacc.2010.02.015.
18. Kallianos KG, Burris NS. Imaging Thoracic Aortic Aneurysm. *Radiol Clin North Am*. 2020;58(4):721-731. doi:10.1016/j.rcl.2020.02.009.
19. Loren F, Hiratzka MD, et al, 2010 ACCF/AHA/AATS/ACR/ASA/SCA/SCAI/SIR/STS/SVM Guidelines for the Diagnosis and Management of Patients with Thoracic Aortic Disease. *Circulation* 2010; 121: e266-e369.
20. Masuda Y1, Yamada Z, Morooka N, Watanabe S, Inagaki Y. Prognosis of patients with medically treated aortic dissections. *Circulation*. 1991 Nov;84(5 Suppl):III7-13.
21. Moser M, Setaro JF. Resistant or Difficult-to-Control Hypertension. *New England Journal of Medicine*. 2006;355(4):385-392. doi:10.1056/nejmcp041698.
22. Persu A, Giavarini A, Touzé E, et al. European consensus on the diagnosis and management of fibromuscular dysplasia. *Journal of Hypertension*. 2014;32(7):1367-1378. doi:10.1097/hjh.0000000000000213.
23. Sakamoto I, Sueyoshi E, Hazama S, et al. Endovascular treatment of iliac artery aneurysms. *Radiographics* October 2005;25:S213-S227.
24. Shiga T, Wajima Z, Apfel CC, Inoue T, Ohe Y. Diagnostic Accuracy of Transesophageal Echocardiography, Helical Computed Tomography, and Magnetic Resonance Imaging for Suspected Thoracic Aortic Dissection: Systematic Review and Meta-analysis. *Arch Intern Med* 2006; 166 (13): 1350-1356.
25. Alcantara S, Yang CK, Sasson J, et al. The evidence for nonoperative management of visceral artery dissections: a single-center experience. *Ann Vasc Surg*. 2015;29(1):103-108. doi:10.1016/j.avsg.2014.09.004.
26. Smith T, Quencer KB. Best Practice Guidelines: Imaging Surveillance After Endovascular Aneurysm Repair. *American Journal of Roentgenology*. 2020;214(5):1165-1174. doi:10.2214/ajr.19.22197.
27. Tadros TM, Klein MD, Shapira OM. Ascending aortic dilatation associated with bicuspid aortic valve. *Circulation* 2009; 119: 880-890.
28. Taimen K, Salomäki SP, Hohenthal U, et al. The Clinical Impact of Using 18F-FDG-PET/CT in the Diagnosis of Suspected Vasculitis: The Effect of Dose and Timing of Glucocorticoid Treatment. *Contrast Media & Molecular Imaging*. 2019;2019:1-8. doi:10.1155/2019/9157637.
29. van Bogerijen GH, Tolenaar JL, Rampoldi V, et al. Predictors of aortic growth in uncomplicated type B aortic dissection. *J Vasc Surg*. 2014 Apr;59(4):1134-43. doi: 10.1016/j.jvs.2014.01.042.
30. Whelton PK, Carey RM, Aronow WS, et al. 2017 ACC/AHA/AAPA/ABC/ACPM/AGS/APhA/ASH/ASPC/NMA/PCNA Guideline for the Prevention, Detection, Evaluation, and Management of High Blood Pressure in Adults: A Report of the American College of Cardiology/American Heart Association Task Force on Clinical Practice Guidelines. *Hypertension*. 2018;71(6). doi:10.1161/hyp.0000000000000065.
31. Zierler RE, Jordan WD, Lal BK, et al. The Society for Vascular Surgery practice guidelines on follow-up after vascular surgery arterial procedures. *J Vasc Surg*. 2018;68(1):256-284. doi:10.1016/j.jvs.2018.04.018.1.
32. Salim S, Machin M, Patterson BO, Bicknell C. The Management of Penetrating Aortic Ulcer. *Hearts*. 2020;1(1):5-13. doi:10.3390/hearts1010003.

Aortic and Arterial Dissection and Other Aortic Conditions (PVD-6.7)

PVD.AD.0006.7.A

v1.0.2024

Imaging for Aortic conditions	CPT [®]
CT Chest, and/or Abdomen, and/or Pelvis	71260
	74177
	74160
	72193
CTA Chest, and/or Abdomen, and/or Pelvis	71275
	74175
	72191
	74174
MRA Chest, and/or Abdomen, and/or Pelvis	71555
	74185
	72198

- CTA or MRA of the entire aorta (including arch branches) and extending through the femoral arteries for suspected aortic dissection. Any of the following studies can be used if acute dissection is suspected:
 - CT Chest (CPT[®] 71260 or CPT[®] 71270) and/or one of the following:
 - CT Abdomen (CPT[®] 74160 or CPT[®] 74170) with or without and with contrast
 - CT Pelvis (CPT[®] 72193 or CPT[®] 72194) with or without and with contrast
 - CT Abdomen and Pelvis (CPT[®] 74177 or CPT[®] 74178) with or without and with contrast
 - CTA Chest (CPT[®] 71275) and/or **one** of the following:
 - CTA Abdomen (CPT[®] 74175)
 - CTA Pelvis (CPT[®] 72191)
 - CTA Abdomen and Pelvis (CPT[®] 74174)
 - MRA Chest and/or Abdomen and/or Pelvis (CPT[®] 71555 and/or CPT[®] 74185 and/or CPT[®] 72198)
- Chronic Aortic Dissections- 1/3 of individuals with chronic type B dissections that were not treated via open or endovascular repair will go on to develop aneurysmal disease requiring subsequent intervention.

- Advanced imaging of the affected segment of the aorta with any of the studies in above table **Imaging for Aortic conditions** can be performed as follows:
 - In individuals with a persistent false lumen or initial aortic diameter of ≥ 4 cm:
 - Every 6 months for two years until stability has been reached
 - Then annually
 - In individuals with initial aortic diameter of < 4 cm and/or a thrombosed false lumen:
 - Annually
 - Any time if the individual is symptomatic with chest pain, back pain or has any evidence of end organ ischemia: renal dysfunction, mesenteric ischemia or acute limb ischemia
- In individuals with Marfan syndrome/Loeys-Dietz/Ehlers-Danlos
 - As aneurysmal expansion within a dissection can occur rapidly, post-dissection imaging in these individuals is indicated as follows:
 - 1 month
 - 3 months
 - 6 months
 - 12 months
 - yearly thereafter
 - Depending on the location of the dissection the following may be approved:
 - CTA or MRA Head (CPT[®] 70496 or CPT[®] 70544)
 - Carotid duplex or CTA Neck or MRA Neck (CPT[®] 93980, CPT[®] 70498, or CPT[®] 70547)
 - CTA or MRA Chest (CPT[®] 71275 or CPT[®] 71555)
 - CTA Abdomen and Pelvis (CPT[®] 74174); or CTA or MRA Abdomen (CPT[®] 74175 or CPT[®] 74185); or CTA or MRA Pelvis (CPT[®] 72191 or CPT[®] 72198)
- Asymptomatic incidentally found arterial dissections not affecting the aorta including but not excluded to iliac arteries, visceral arteries, extracranial arteries can be imaged according to the general schedule:
 - Within one month of discovery
 - Six months
 - 12 months
 - No further imaging after 12 months if noted to be stable
- Asymptomatic penetrating aortic ulcers can be imaged according to the following time intervals:
 - Within one month of discovery
 - Three months
 - Six months
 - Twelve months
 - Annually until decision made to intervene

Background and Supporting Information

Classic symptoms of sharp, severe acute onset of retrosternal or interscapular chest pain is seen in 96% and is best adapted to the emergent setting. Chest x-ray is imprecise; any suspicion should be considered since up to 10% of individuals with aortic dissection present without classic symptoms.

References

1. Bonci G, Steigner ML, et al. ACR Appropriateness Criteria® Thoracic Aorta Interventional Planning and Follow-Up. *J Am Coll Radiol*. 2017;14(11S):S570-S583. doi:10.1016/j.jacr.2017.08.042.
2. Kalva SP, Dill KE, et al. ACR Appropriateness Criteria® nontraumatic aortic disease. *J Thorac Imaging*. 2014;29(5):W85-W88. doi:10.1097/RTI.000000000000107.
3. Albornoz G, Coady MA, Roberts M, et al. Familial thoracic aortic aneurysms and dissections--incidence, modes of inheritance, and phenotypic patterns. *Ann Thorac Surg*. 2006;82(4):1400-1405. doi:10.1016/j.athoracsur.2006.04.098.
4. Anderson JL, Halperin JL, Albert N, et al. Management of Patients with Peripheral Artery Disease (Compilation of 2005 and 2011 ACCF/AHA Guideline Recommendations).. *J Am Coll Cardiol*. 2013;61(14):1555-1570. doi:10.1016/j.jacc.2013.01.004.
5. Bennett SJ, Dill KE, Hanley M, et al. ACR Appropriateness Criteria® Suspected Thoracic Aortic Aneurysm. *J Am Coll Radiol*. 2018;15(5). doi:10.1016/j.jacr.2018.03.031.
6. Chaikof EL, Dalman RL, Eskandari MK, et al. The Society for Vascular Surgery practice guidelines on the care of patients with an abdominal aortic aneurysm. *J Vasc Surg*. 2018;67(1). doi:10.1016/j.jvs.2017.10.044.
7. Elefteriades JA. Natural history of thoracic aortic aneurysms: indications for surgery, and surgical versus nonsurgical risks. *Ann Thorac Surg* 2002; 74: S1877-S1880.
8. Erben Y, Brownstein AJ, Rajae S. Natural History of and Management of Splanchnic Artery Aneurysms in a Single Tertiary Referral Center. *J Vasc Surg* 2018 Oct; 68(4): 1079-1087.
9. Chaer RA, Abularrage CJ, Coleman DM, et al. The Society for Vascular Surgery clinical practice guidelines on the management of visceral aneurysms. *J Vasc Surg*. 2020;72(1S):3S-39S. doi:10.1016/j.jvs.2020.01.039.
10. Expert Panel on Cardiac Imaging. ACR Appropriateness Criteria® Acute Chest Pain -- Suspected Aortic Dissection. *American College of Radiology (ACR)*; 2014.
11. Collard M, Sutphin PD, Kalva SP, et al. Expert Panel on Vascular Imaging. ACR Appropriateness Criteria® Abdominal Aortic Aneurysm Follow-up (without Repair). *J Am Coll Radiol*. 2019;16(5S):S2-S6. doi:10.1016/j.jacr.2019.02.005.
12. Corey MR, Ergul EA, Cambria RP. The Natural History of Splanchnic Aneurysms and Outcome after Operative Intervention. *J Vasc Surg*. 2016 April 63 (4):949-57.
13. Dejaco C, Ramiro S, Duftner C, et al. EULAR recommendations for the use of imaging in large vessel vasculitis in clinical practice. *Annals of the Rheumatic Diseases*. 2018;77(5):636-643. doi:10.1136/annrheumdis-2017-212649.
14. Diercks D, Promes S, Schuur J, et al. American College of Emergency Physicians. Clinical policy: critical issues in the evaluation and management of adult patients with suspected acute nontraumatic thoracic aortic dissection. *Ann Emerg Med*. 2015 Jan; 65 (1) :32-42.
15. Francois CJ, Skulborstad EP, Majdalany BS, et al. Expert Panels on Vascular Imaging and Interventional Radiology. ACR Appropriateness Criteria® Abdominal Aortic Aneurysm: Interventional Planning and Follow-Up. *J Am Coll Radiol*. 2018;15(5S):S2-S12. doi:10.1016/j.jacr.2018.03.008.
16. Harvin HJ, Verma N, Nikolaidis P, et al. ACR Appropriateness Criteria® Renovascular Hypertension. *J Am Coll Radiol*. 2017;14(11). doi:10.1016/j.jacr.2017.08.040.
17. Hiratzka LF, Bakris GL, Beckman JA, et al. 2010 ACCF/AHA/AATS/ACR/ASA/SCA/SCAI/SIR/STS/SVM Guidelines for the diagnosis and management of patients with thoracic aortic disease. A Report of the American College of Cardiology Foundation/American Heart Association Task Force on Practice Guidelines, American Association for Thoracic Surgery, American College of Radiology, American Stroke Association, Society of Cardiovascular Anesthesiologists, Society for Cardiovascular Angiography and Interventions, Society of Interventional Radiology, Society of Thoracic Surgeons, and Society for Vascular

- Medicine [published correction appears in *J Am Coll Cardiol*. 2013 Sep 10;62(11):1039-40]. *J Am Coll Cardiol*. 2010;55(14):e27-e129. doi:10.1016/j.jacc.2010.02.015.
18. Kallianos KG, Burris NS. Imaging Thoracic Aortic Aneurysm. *Radiol Clin North Am*. 2020;58(4):721-731. doi:10.1016/j.rcl.2020.02.009.
 19. Loren F, Hiratzka MD, et al, 2010 ACCF/AHA/AATS/ACR/ASA/SCAI/SIR/STS/SVM Guidelines for the Diagnosis and Management of Patients with Thoracic Aortic Disease. *Circulation* 2010; 121: e266-e369.
 20. Masuda Y1, Yamada Z, Morooka N, Watanabe S, Inagaki Y. Prognosis of patients with medically treated aortic dissections. *Circulation*. 1991 Nov;84(5 Suppl):III7-13.
 21. Moser M, Setaro JF. Resistant or Difficult-to-Control Hypertension. *New England Journal of Medicine*. 2006;355(4):385-392. doi:10.1056/nejmcp041698.
 22. Persu A, Giavarini A, Touzé E, et al. European consensus on the diagnosis and management of fibromuscular dysplasia. *Journal of Hypertension*. 2014;32(7):1367-1378. doi:10.1097/hjh.0000000000000213.
 23. Sakamoto I, Sueyoshi E, Hazama S, et al. Endovascular treatment of iliac artery aneurysms. *Radiographics* October 2005;25:S213-S227.
 24. Shiga T, Wajima Z, Apfel CC, Inoue T, Ohe Y. Diagnostic Accuracy of Transesophageal Echocardiography, Helical Computed Tomography, and Magnetic Resonance Imaging for Suspected Thoracic Aortic Dissection: Systematic Review and Meta-analysis. *Arch Intern Med* 2006; 166 (13): 1350-1356.
 25. Alcantara S, Yang CK, Sasson J, et al. The evidence for nonoperative management of visceral artery dissections: a single-center experience. *Ann Vasc Surg*. 2015;29(1):103-108. doi:10.1016/j.avsg.2014.09.004.
 26. Smith T, Quencer KB. Best Practice Guidelines: Imaging Surveillance After Endovascular Aneurysm Repair. *American Journal of Roentgenology*. 2020;214(5):1165-1174. doi:10.2214/ajr.19.22197.
 27. Tadros TM, Klein MD, Shapira OM. Ascending aortic dilatation associated with bicuspid aortic valve. *Circulation* 2009; 119: 880-890.
 28. Taimen K, Salomäki SP, Hohenthal U, et al. The Clinical Impact of Using 18F-FDG-PET/CT in the Diagnosis of Suspected Vasculitis: The Effect of Dose and Timing of Glucocorticoid Treatment. *Contrast Media & Molecular Imaging*. 2019;2019:1-8. doi:10.1155/2019/9157637.
 29. van Bogaerijen GH, Tolenaar JL, Rampoldi V, et al. Predictors of aortic growth in uncomplicated type B aortic dissection. *J Vasc Surg*. 2014 Apr;59(4):1134-43. doi: 10.1016/j.jvs.2014.01.042.
 30. Whelton PK, Carey RM, Aronow WS, et al. 2017 ACC/AHA/AAPA/ABC/ACPM/AGS/APhA/ASH/ASPC/NMA/PCNA Guideline for the Prevention, Detection, Evaluation, and Management of High Blood Pressure in Adults: A Report of the American College of Cardiology/American Heart Association Task Force on Clinical Practice Guidelines. *Hypertension*. 2018;71(6). doi:10.1161/hyp.0000000000000065.
 31. Zierler RE, Jordan WD, Lal BK, et al. The Society for Vascular Surgery practice guidelines on follow-up after vascular surgery arterial procedures. *J Vasc Surg* . 2018;68(1):256-284. doi:10.1016/j.jvs.2018.04.018.1.
 32. Salim S, Machin M, Patterson BO, Bicknell C. The Management of Penetrating Aortic Ulcer. *Hearts*. 2020;1(1):5-13. doi:10.3390/hearts1010003.

Post Aortic Endovascular/Open Surgery Surveillance Studies (PVD-6.8)

PVD.AD.0006.8.A

v1.0.2024

Post-operative surveillance after TEVAR for any indication (PVD-6.8.1)

Post-operative surveillance after abdominal EVAR (endovascular aneurysm repair) (PVD-6.8.2)

Endovascular (Stent) Iliac Repair (PVD-6.8.3)

References (PVD-6.8)

- Aortic root/ascending aortic aneurysm/aortic dissection repair - post-operative echocardiography (TEE/TTE) is indicated:
 - Every three months for the first year
 - Every six months during the second year
 - Annually thereafter
- Open descending thoracic aortic aneurysm repair - **One** of the following post-operative studies [CT Chest with contrast (CPT® 71260) **or** CT Chest without contrast (CPT® 71250) **or** CTA Chest (CPT® 71275)], is indicated as follows:
 - 3-6 months post-procedure
 - 12 months post-procedure
 - Every two years thereafter
- Open Aortic Abdominal Aneurysm Repair - contrast and non-contrast enhanced CT of the entire aorta (CPT®74176, CPT® 74177, CPT® 74174):
 - Every 5-years
 - As requested to assess for suspected infection of the graft (see **Nuclear Medicine Imaging indications (PVD-10.1)** for nuclear medicine imaging for vascular graft infection).

Post-operative surveillance after TEVAR for any indication (PVD-6.8.1)

Imaging for post-operative TEVAR	CPT®
CT Chest, and/or Abdomen, and/or Pelvis	71260
	74177
	74160
	72193

Imaging for post-operative TEVAR	CPT®
CTA Chest, and/or Abdomen, and/or Pelvis	71275
	74175
	72191
	74174
MRA Chest, and/or Abdomen, and/or Pelvis	71555
	74185
	72198

- ANY of the above studies listed in the table can be performed at one month, six months, twelve months and then annually
- Abdomen and Pelvis imaging is indicated only if TEVAR performed for a dissection that extends into the abdomen or pelvis

Post-operative surveillance after abdominal EVAR (endovascular aneurysm repair) (PVD-6.8.2)

Imaging for post-operative abdominal EVAR	CPT®
CT Abdomen and/or Pelvis with contrast	74160
	72193
	74177
CT Abdomen and/or Pelvis without and with contrast	74170
	72194
	74178
CTA Abdomen and/or Pelvis	74175
	72191
	74174
MRA Abdomen and/or Pelvis	74185
	72198

- CT as per above coding as requested and color duplex ultrasound (CPT® 93975, CPT® 93976, CPT® 93978, or CPT® 93979) one month after EVAR
- If no endoleak, or sac enlargement, repeat **either** preferred CT or duplex ultrasound (**but not both**) at 12 months
- If a type II endoleak is observed 1 month after EVAR, may approve **BOTH at 6 months**:

- Any of the above CT with contrast
- Color duplex US
- If no endoleak or AAA sac enlargement is detected at 1 year after EVAR annual surveillance with:
 - Color duplex US
 - If DGUS is not available, any of the above CT can be performed
- If a type II endoleak is associated with an aneurysm sac that is shrinking or stable in size:
 - Continue surveillance with color duplex US every 6 months for 2 years
 - Annually thereafter.
- If US detects a new endoleak, graft migration, or aneurysm sac growth > 5mm:
 - Any of the above CT scan as requested.
 - Non-contrast CT of the entire aorta at 5-year intervals (CPT®74176)

Post-endoleak intervention surveillance imaging

Surveillance imaging after EVAR or any subsequent endoleak intervention is based on the most recent intervention unless it increases the frequency of interval imaging of prior established interval

For any subsequent interventions for endoleak repair, imaging can be obtained at 1 month with CT and then follow protocol as above.

Endovascular (Stent) Iliac Repair (PVD-6.8.3)

Imaging for endovascular iliac repair (stent)	CPT®
CT Pelvis	72193
	72194
CTA Pelvis	72191
MRA Pelvis	72198

- One of the above studies can be performed for endovascular iliac repair (stent)
- If performed in conjunction with EVAR, surveillance can follow the same schedule as EVAR.
- For isolated iliac artery aneurysm repair, surveillance can be performed with an arterial duplex (CPT® 93975, CPT® 93976, CPT® 93978, or CPT® 93979) or CT or MR as above if duplex unavailable:
 - Post-operatively within the first month
 - 6 months after endovascular treatment
 - Annually

References (PVD-6.8)

1. Bonci G, Steigner ML, et al. ACR Appropriateness Criteria® Thoracic Aorta Interventional Planning and Follow-Up. *J Am Coll Radiol*. 2017;14(11S):S570-S583. doi:10.1016/j.jacr.2017.08.042.
2. Kalva SP, Dill KE, et al. ACR Appropriateness Criteria® nontraumatic aortic disease. *J Thorac Imaging*. 2014;29(5):W85-W88. doi:10.1097/RTI.000000000000107.
3. Albornoz G, Coady MA, Roberts M, et al. Familial thoracic aortic aneurysms and dissections--incidence, modes of inheritance, and phenotypic patterns. *Ann Thorac Surg*. 2006;82(4):1400-1405. doi:10.1016/j.athoracsur.2006.04.098.
4. Bennett SJ, Dill KE, Hanley M, et al. ACR Appropriateness Criteria® Suspected Thoracic Aortic Aneurysm. *J Am Coll Radiol*. 2018;15(5). doi:10.1016/j.jacr.2018.03.031.
5. Chaikof EL, Dalman RL, Eskandari MK, et al. The Society for Vascular Surgery practice guidelines on the care of patients with an abdominal aortic aneurysm. *J Vasc Surg*. 2018;67(1). doi:10.1016/j.jvs.2017.10.044.
6. Elefteriades JA. Natural history of thoracic aortic aneurysms: indications for surgery, and surgical versus nonsurgical risks. *Ann Thorac Surg* 2002; 74: S1877-S1880.
7. Diercks D, Promes S, Schuur J, et al. American College of Emergency Physicians. Clinical policy: critical issues in the evaluation and management of adult patients with suspected acute nontraumatic thoracic aortic dissection. *Ann Emerg Med*. 2015 Jan; 65 (1) :32-42.
8. Francois CJ, Skulborstad EP, Majdalany BS, et al. Expert Panels on Vascular Imaging and Interventional Radiology. ACR Appropriateness Criteria® Abdominal Aortic Aneurysm: Interventional Planning and Follow-Up. *J Am Coll Radiol*. 2018;15(5S):S2-S12. doi:10.1016/j.jacr.2018.03.008.
9. Hiratzka LF, Bakris GL, Beckman JA, et al. 2010 ACCF/AHA/AATS/ACR/ASA/SCA/SCAI/SIR/STS/SVM Guidelines for the diagnosis and management of patients with thoracic aortic disease. A Report of the American College of Cardiology Foundation/American Heart Association Task Force on Practice Guidelines, American Association for Thoracic Surgery, American College of Radiology, American Stroke Association, Society of Cardiovascular Anesthesiologists, Society for Cardiovascular Angiography and Interventions, Society of Interventional Radiology, Society of Thoracic Surgeons, and Society for Vascular Medicine [published correction appears in *J Am Coll Cardiol*. 2010;55(14):e27-e129. doi:10.1016/j.jacc.2010.02.015.
10. Kallianos KG, Burris NS. Imaging Thoracic Aortic Aneurysm. *Radiol Clin North Am*. 2020;58(4):721-731. doi:10.1016/j.rcl.2020.02.009.
11. Loren F, Hiratzka MD, et al, 2010 ACCF/AHA/AATS/ACR/ASA/SCAI/SIR/STS/SVM Guidelines for the Diagnosis and Management of Patients with Thoracic Aortic Disease. *Circulation* 2010; 121: e266-e369.
12. Shiga T, Wajima Z, Apfel CC, Inoue T, Ohe Y. Diagnostic Accuracy of Transesophageal Echocardiography, Helical Computed Tomography, and Magnetic Resonance Imaging for Suspected Thoracic Aortic Dissection: Systematic Review and Meta-analysis. *Arch Intern Med* 2006; 166 (13): 1350-1356.
13. Smith T, Quencer KB. Best Practice Guidelines: Imaging Surveillance After Endovascular Aneurysm Repair. *American Journal of Roentgenology*. 2020;214(5):1165-1174. doi:10.2214/ajr.19.22197.
14. Zierler RE, Jordan WD, Lal BK, et al. The Society for Vascular Surgery practice guidelines on follow-up after vascular surgery arterial procedures. *J Vasc Surg* . 2018;68(1):256-284. doi:10.1016/j.jvs.2018.04.018.1.

Large Vessel Vasculitis (PVD-6.9)

PVD.AD.0006.9.A

v1.0.2024

Guideline

- Inflammatory Aortitis (PVD-6.9.1)
- Giant Cell Arteritis (GCA) (PVD-6.9.2)
- Takayasu Arteritis (PVD-6.9.3)
- References (PVD-6.9)

- Large vessel vasculitis is generally sub-grouped into three areas
 - Aortitis (Inflammatory Aortitis)
 - Giant Cell Vasculitis
 - Takayasu Arteritis

Inflammatory Aortitis (PVD-6.9.1)

Imaging for Inflammatory Aortitis	CPT®
CTA Chest	71275
MRA Chest	71555
CTA Pelvis	72191
MRA Pelvis	72198
CTA Abdomen and Pelvis	74174
CTA Abdomen	74175
MRA Abdomen	74185

Initial imaging

- Initial imaging with CTA or MRA of the affected body region is considered medically necessary after the following workup:
 - Lab studies: CBC, CMP, elevated inflammatory markers such as ESR or CRP
 - Clinical history suggestive of disease listed below in **Background and Supporting information**
 - PET/CT is considered **not medically necessary** for management of pediatric vasculitis at this time.

Repeat imaging

- Follow-up imaging with CTA or MRA of the affected body region is considered medically necessary for:
 - Change in signs/symptoms

- Known aneurysm monitoring
 - See **Aneurysm and AVM (HD-12)** in the Head Imaging Guidelines
 - See **Thoracic Aortic Aneurysms (PVD-6.2)**
 - See **Abdominal Aortic Aneurysms (PVD-6.3)**

Background and Supporting Information

Aortitis may be congenital (Marfan's, Hypermobility Syndromes, others) or acquired, including traumatic, atherosclerotic (dissecting aneurysm, other), infectious (syphilis, tuberculosis, other), neoplastic or inflammatory (Ankylosing Spondylitis, Giant Cell Arteritis, Cogan's, Relapsing Polychondritis, Behcet's Syndrome, Polyarteritis Nodosa, Granulomatous Polyangiitis, Lupoid, idiopathic, other).

Giant Cell Arteritis (GCA) (PVD-6.9.2)

Imaging for Giant Cell Arteritis	CPT®
CTA Chest	71275
MRA Chest	71555
CTA Pelvis	72191
MRA Pelvis	72198
CTA Abdomen and Pelvis	74174
CTA Abdomen	74175
MRA Abdomen	74185
MRA Head without contrast	70544
MRA Head with contrast	70545
MRA Neck without contrast	70547
MRA Neck with contrast	70548
CTA Neck	70498
PET/CT skull base to mid-thigh	78815

Initial imaging

- GCA may be subdivided into two basic types; Cranial and Extra-cranial
 - **Cranial GCA** is the more common type with temporal artery involvement. For predominantly Cranial GCA:
 - US (CPT® 93880 or CPT® 93882) of the temporal (and or axillary) arteries is the preferred modality. Ultrasound should be considered prior to advanced imaging.
 - MRA Head and/or MRA Neck (CPT® 70544, or CPT® 70545, or CPT® 70547, or CPT® 70548) may be considered when:

- Vascular trained ultrasonography is not available
- US is negative or equivocal with a clinical suspicion of GCA
- CT and PET are **not** currently recommended for the assessment of inflammation of cranial arteries.

Note For suspected cerebral vasculitis in individuals with neurologic symptoms, see **Cerebral Vasculitis (HD-22)** in the Head Imaging Guidelines

- **Extra-cranial GCA:** less commonly encountered. None of the “classic” clinical signs or symptoms of cranial GCA are present initially but may develop later.
 - Extra-cranial GCA is characterized by at least two or more of the following:
 - Jaw and/or upper extremity claudication
 - Fever/weight loss or fever of unknown origin (FUO) symptoms
 - New murmurs
 - Pulse asymmetry
 - Abdominal pain
 - Pulsatile mass
 - High inflammatory markers such as CRP or ESR > 50 mm/h
 - Imaging for aortic root, arch or abdomen involvement:
 - MRA Chest (CPT[®] 71555), MRA Neck (CPT[®] 70547), MRA Abdomen (CPT[®] 74185), CTA Chest (CPT[®] 71275), CTA Neck (CPT[®] 70498) or CTA Abdomen (CPT[®] 74175)
 - PET (CPT[®] 78815) is indicated if MRA or CTA are non-diagnostic and there is still suspicion for aortic root, arch or abdomen involvement

Repeat imaging

- Follow-up imaging is indicated for **any** of the following:
 - One-time documentation of remission or disease control
 - Change in signs/symptoms suggesting progression of disease
 - Although individuals with GCA can develop aortic aneurysms over time screening in the absence of signs or symptoms is not medically necessary
 - In individuals with known thoracic or abdominal aortic aneurysm:
 - See **Thoracic Aortic Aneurysm (TAA) (PVD-6.2)** for thoracic aneurysm surveillance
 - See **Abdominal Aortic Aneurysm (AAA) (PVD-6.3)** for abdominal aneurysm surveillance.
- Follow-up imaging is not routinely recommended for individuals in clinical and biochemical remission or without aneurysm/complication.

Background and supporting information

Giant Cell Arteritis is the most commonly encountered vasculitis in adults. Although classically thought of as a disease of the temporal arteries, aortic arch involvement is now recognized as a frequent complication (up to 50% of individuals) and responsible for many of the more serious morbidities encountered such as blindness.

Takayasu Arteritis (PVD-6.9.3)

Imaging for Takayasu Arteritis	CPT®
CTA Chest	71275
CTA Pelvis	72191
CTA Abdomen and Pelvis	74174
CTA Abdomen	74175
MRA Chest	71555
MRA Pelvis	72198
MRA Abdomen	74185

Initial imaging

- Initial imaging is indicated for signs and symptoms suggestive of disease such as absent radial pulse, difficulty obtaining BP in one arm, or unexplained hypertension.
- Any of the following modalities may be indicated for evaluation of Takayasu arteritis:
 - MRA of the affected body area(s) (contrast as requested)
 - CTA of the affected body area(s) (contrast as requested)
 - Ultrasound with Doppler of the affected body area(s)

Repeat imaging

Repeat imaging is indicated at the following intervals:

- Every 3 months to monitor treatment response during active treatment with systemic therapy.
- Annually for surveillance of known involved body areas to detect progressive vascular damage that may require intervention

References (PVD-6.9)

1. Anderson JL, Halperin JL, Albert N, et al. Management of Patients with Peripheral Artery Disease (Compilation of 2005 and 2011 ACCF/AHA Guideline Recommendations). *J Am Coll Cardiol.* 2013;61(14):1555-1570. doi:10.1016/j.jacc.2013.01.004.
2. Dejaco C, Ramiro S, Duftner C, et al. EULAR recommendations for the use of imaging in large vessel vasculitis in clinical practice. *Annals of the Rheumatic Diseases.* 2018;77(5):636-643. doi:10.1136/annrheumdis-2017-212649.
3. Persu A, Giavarini A, Touzé E, et al. European consensus on the diagnosis and management of fibromuscular dysplasia. *Journal of Hypertension.* 2014;32(7):1367-1378. doi:10.1097/hjh.0000000000000213.

4. Taimen K, Salomäki SP, Hohenthal U, et al. The Clinical Impact of Using 18F-FDG-PET/CT in the Diagnosis of Suspected Vasculitis: The Effect of Dose and Timing of Glucocorticoid Treatment. *Contrast Media & Molecular Imaging*. 2019;2019:1-8. doi:10.1155/2019/9157637.
5. Zierler RE, Jordan WD, Lal BK, et al. The Society for Vascular Surgery practice guidelines on follow-up after vascular surgery arterial procedures. *J Vasc Surg* . 2018;68(1):256-284. doi:10.1016/j.jvs.2018.04.018.1.
6. Muratore F, Pipitone N, Salvarani C, Schmidt WA. Imaging of vasculitis: State of the art. *Best Practice Research Clinical Rheumatology*. 2016;30(4):688-706. doi:10.1016/j.berh.2016.09.010.
7. Lensen KDF, Comans EFI, Voskuyl AE, et al. Large-Vessel Vasculitis: Interobserver Agreement and Diagnostic Accuracy of 18F-FDG-PET/CT. *BioMed Research International*. 2015;2015:1-8. doi:10.1155/2015/914692. .
8. Soussan M, Nicolas P, Schramm C, et al. Management of Large-Vessel Vasculitis With FDG-PET. *Medicine*. 2015;94(14). doi:10.1097/md.0000000000000622.
9. Besson FL, Parienti J-J, Bienvenu B, et al. Diagnostic performance of 18F-fluorodeoxyglucose positron emission tomography in giant cell arteritis: a systematic review and meta-analysis. *European Journal of Nuclear Medicine and Molecular Imaging*. 2011;38(9):1764-1772. doi:10.1007/s00259-011-1830-0.
10. Sivaraman V, Fels EC, and Ardoin SP. Vasculitis syndromes. *Nelson Textbook of Pediatrics*, Chapter 192. eds Kliegman RM, St. Geme JW III, Blum NJ, et al. 21st ed. Philadelphia, PA: Elsevier; 2020:1317-1327.
11. Soliman M, Laxer R, Manson D, et. al. Imaging of systemic vasculitis in childhood. *Pediatric Radiology*. 2015;45(8):1110-1125. doi:10.1007/s00247-015-3339-3.
12. Sharma AM, Singh S, Lewis JE. Diagnostic Approach in Patients With Suspected Vasculitis. *Techniques in Vascular and Interventional Radiology*. 2014;17(4):226-233. doi:10.1053/j.tvir.2014.11.002.
13. Ammirati E, Moroni F, Pedrotti P, et al. Non-Invasive Imaging of Vascular Inflammation. *Frontiers in Immunology*. 2014;5:1-15. doi:10.3389/fimmu.2014.00399.
14. Granata C, Damasio MB, Zaottini F, et al. Imaging of Childhood Vasculitis. *Radiologic Clinics of North America*. 2017;55(5):1131-1143. doi:10.1016/j.rcl.2017.05.001.
15. Broncano J, Vargas D, Bhalla S, Cummings KW, Raptis CA, Luna A. CT and MR Imaging of Cardiothoracic Vasculitis. *RadioGraphics*. 2018;38(4):997-1021. doi:10.1148/rg.2018170136.
16. Jennette JC, Falk RJ, Bacon PA, et al. 2012 Revised International Chapel Hill Consensus Conference Nomenclature of Vasculitides. *Arthritis & Rheumatism*. 2012;65(1):1-11. doi:10.1002/art.37715.
17. Ozen S, Pistorio A, Iusan SM, et al. EULAR/PRINTO/PRES criteria for Henoch-Schonlein purpura, childhood polyarteritis nodosa, childhood Wegener granulomatosis and childhood Takayasu arteritis: Ankara 2008. Part II: Final classification criteria. *Annals of the Rheumatic Diseases*. 2010;69(5):798-806. doi:10.1136/ard.2009.116657
18. Cui J, Huang LY, Guo J, Wu CR, Zhang B. Diagnosis and treatment of adult mixed-type Henoch-Schönlein purpura. *Cent Eur J Immunol*. 2019;44(2):138-143. doi:10.5114/ceji.2019.87064 .

Medium Vessel Vasculitis (PVD-6.10)

PVD.AD.0006.10.A

v1.0.2024

- There are two main types of medium-size vessel vasculitis:
 - Polyarteritis nodosa
 - Kawasaki disease

Kawasaki disease

- Imaging guidelines for Kawasaki Disease are addressed in **Kawasaki Disease (PEDCD-6)** in the Pediatric Cardiac imaging guideline
- Long-term routine surveillance imaging in asymptomatic Kawasaki disease is indicated as follows:

AHA risk level	Largest Aneurysm At Any Point	Largest Current Aneurysm	Routine Echo	Routine Stress Imaging	Routine Coronary Imaging
All			All risk levels 4-6 weeks after acute illness		
1	Normal	Normal	One echo 2- 12 months after acute illness	none	none
2	Dilation	Dilation	6 months One year If dilation remains echo every 2-5 years until resolves	None	None

AHA risk level	Largest Aneurysm At Any Point	Largest Current Aneurysm	Routine Echo	Routine Stress Imaging	Routine Coronary Imaging
		Normal	After acute illness: 2-12 months One echocardiogram at one year No echocardiogram after one year		
3.1	Small	Small	6 months 12 months then yearly	2-3 years	3-5 years
3.2	Small	Normal or dilated	6 months 12 months Then yearly	3-5 years	none
4.1	Medium	Medium	3 months 6 months 12 months Every 6-12 months after that	1-3 years	2-5 years
4.2	Medium	Small	6 months and 12 months, every 1 year	2-3 years	3-5 years
4.3	Medium	Normal Or Dilated	Every 1-2 years	2-4 years	none

AHA risk level	Largest Aneurysm At Any Point	Largest Current Aneurysm	Routine Echo	Routine Stress Imaging	Routine Coronary Imaging
5.1	Large	Large	1 month 3 months 6 months 9 months 12 months Then every 3-6 months	6-12 months	at 2-6 months, every 1-5 years
5.2	Large	Medium	Every 6-12 months	yearly	2-5 years
5.3	Large	Small	6-12 month	1-2 years	2-5 years
5.4	Large	Normal Or Dilation	1-2 years	2-5 years	none

Polyarteritis Nodosa

Initial imaging

Any **ONE** of the following modalities is indicated for documented clinical suspicion of Polyarteritis Nodosa:

- MRA of the affected body area(s) (contrast as requested)
- CTA of the affected body area(s) (contrast as requested)
- Ultrasound (US) with Doppler of the affected body area(s)

Repeat imaging

Imaging with MRA, CTA, or US with Doppler of the affected body area(s) is indicated for established Polyarteritis Nodosa as follows:

- Every 3 months during active treatment with systemic therapy to evaluate treatment response
- Annually for surveillance of known involved body areas to detect progressive vascular damage that may require intervention

Background and supporting information

- Based on AHA recommendations, the following classifications are used in risk stratification of coronary artery abnormalities⁴

⁴ Mccrindle BW, Rowley AH, Newburger JW, et al. Diagnosis, Treatment, and Long-Term Management of Kawasaki Disease: A

- Z-Score classification accounts for the effects of body size and age through use of baseline coronary dimensions adjusted for body surface area. The Z score value represents the number of standard deviation above the mean. (e.g., $z=0$ pt. has coronary artery dimension value equal to mean, $z=2$ person has value 2 standard deviation above the mean, based on age, gender, BSA).
- Coronary Artery Abnormalities Risk Classification based on Z-Score:
 - 1 - No involvement at any time point (Z score always <2)
 - 2 - Dilation only (Z score 2 to <2.5)
 - 3 - Small aneurysm (Z score ≥ 2.5 to <5)
 - 3.1 - Current or persistent
 - 3.2 - Decreased to dilation only or normal luminal dimension
 - 4 - Medium aneurysm (Z score ≥ 5 to <10 , and absolute dimension <8 mm)
 - 4.1 - Current or persistent
 - 4.2 - Decreased to small aneurysm
 - 4.3 - Decreased to dilation only or normal luminal dimension
 - 5 - Large and giant aneurysm (Z score ≥ 10 , or absolute dimension ≥ 8 mm)
 - 5.1 - Current or persistent
 - 5.2 - Decreased to medium aneurysm
 - 5.3 - Decreased to small aneurysm
 - 5.4 - Decreased to dilation only or normal luminal dimension
- Additional clinical features that may increase the long-term risk of myocardial ischemia
 - Greater length and distal location of aneurysms that increase the risk of flow stasis
 - Greater total number of aneurysms
 - Greater number of branches affected
 - Presence of luminal irregularities
 - Abnormal characterization of the vessel walls (calcification, luminal myofibroblastic proliferation)
 - Presence of functional abnormalities (impaired vasodilation, impaired flow reserve)
 - Absence or poor quality of collateral vessels
 - Previous revascularization performed
 - Previous coronary artery thrombosis
 - Previous myocardial infarction
 - Presence of ventricular dysfunction

Scientific Statement for Health Professionals from the American Heart Association. Circulation. 2017;135(17).
doi:10.1161/cir.0000000000000484.

Small Vessel Vasculitis (PVD-6.11)

PVD.AD.0006.11.A

v1.0.2024

Guideline

IgA vasculitis Henoch-Schönlein Purpura (HSP)
Granulomatosis with polyangiitis (GPA) formerly Wegener's
granulomatosis
Eosinophilic granulomatosis with polyangiitis (EGPA) formerly
Churg-Strauss Syndrome
Immune complex associated small-vessel vasculitis
References (PVD-6.9)

- Advanced imaging is not sensitive enough to detect changes in small vessels, and is not indicated for primary assessment of any small vessel vasculitis.
- End-organ damage occurs with several of the small vessel vasculitides. Advanced imaging indicated for the following:
 - Henoch-Schönlein Purpura (HSP)
 - Granulomatosis with polyangiitis (GPA, formerly known as Wegener's granulomatosis)
 - Eosinophilic granulomatosis with polyangiitis (EGPA, formerly known as ChurgStrauss Syndrome)
 - Immune complex associated small-vessel vasculitis [immunoglobulin A–associated vasculitis (IgAV)]

IgA vasculitis Henoch-Schönlein Purpura (HSP)

Initial imaging

Ultrasound (US) Abdomen (CPT® 76700) is indicated to evaluate possible gastrointestinal complications of known or suspected HSP including **any** of the following:

- Bowel wall edema and hemorrhage
- Intussusception

CT Abdomen with contrast (CPT® 74160) if additional information is needed after ultrasound for management

Repeat imaging

US Abdomen (CPT® 76700) is indicated for known HSP to evaluate new or worsening gastrointestinal symptoms

Background and Supporting Information

Henoch-Schönlein Purpura (HSP) is the most common vasculitis of childhood, mainly involving small blood vessels. .

Granulomatosis with polyangiitis (GPA) formerly Wegener's granulomatosis

Initial imaging

CT Sinuses (CPT® 70486) and/or CT Chest without contrast (CPT® 71250) or with contrast (CPT® 71260) is indicated to evaluate the extent of the disease

Repeat imaging

CT Sinuses (CPT® 70486) and/or CT Chest without contrast (CPT® 71250) or CT Chest with contrast (CPT® 71260) is indicated for **any** following:

- New or worsening clinical symptoms affecting the body area requested
- Assess response to medical therapy when a change in treatment regimen is being considered
- Annually-to evaluate the extent of disease

Eosinophilic granulomatosis with polyangiitis (EGPA) formerly Churg-Strauss Syndrome

Initial imaging

- CT Chest without contrast (CPT® 71250) or CT Chest with contrast (CPT® 71260) is indicated in the initial evaluation of Eosinophilic granulomatosis with polyangiitis (EGPA) formerly known as Churg-Strauss Syndrome.

Repeat imaging

- CT Chest without contrast (CPT® 71250) or CT Chest with contrast (CPT® 71260) is indicated for any of the following:
 - New or worsening clinical symptoms affecting the body area requested
 - Assess response to medical therapy when a change in treatment regimen is being considered
 - Annually-to evaluate the extent of disease

Immune complex associated small-vessel vasculitis

Initial imaging

- Doppler ultrasound (US) of the affected body part (most commonly abdomen) is indicated in the initial evaluation of immune complex associated small-vessel vasculitis

Repeat imaging

- Doppler ultrasound (US) of the affected body part (most commonly abdomen) is indicated in the following circumstances
 - New or worsening clinical symptoms affecting the body area requested
 - To assess response to medical therapy when a change in treatment is being considered
 - Annually-to evaluate the extent of disease

References (PVD-6.9)

1. Anderson JL, Halperin JL, Albert N, et al. Management of Patients with Peripheral Artery Disease (Compilation of 2005 and 2011 ACCF/AHA Guideline Recommendations). *J Am Coll Cardiol*. 2013;61(14):1555-1570. doi:10.1016/j.jacc.2013.01.004.
2. Dejaco C, Ramiro S, Duftner C, et al. EULAR recommendations for the use of imaging in large vessel vasculitis in clinical practice. *Annals of the Rheumatic Diseases*. 2018;77(5):636-643. doi:10.1136/annrheumdis-2017-212649.
3. Persu A, Giavarini A, Touzé E, et al. European consensus on the diagnosis and management of fibromuscular dysplasia. *Journal of Hypertension*. 2014;32(7):1367-1378. doi:10.1097/hjh.0000000000000213.
4. Taimen K, Salomäki SP, Hohenthal U, et al. The Clinical Impact of Using 18F-FDG-PET/CT in the Diagnosis of Suspected Vasculitis: The Effect of Dose and Timing of Glucocorticoid Treatment. *Contrast Media & Molecular Imaging*. 2019;2019:1-8. doi:10.1155/2019/9157637.
5. Zierler RE, Jordan WD, Lal BK, et al. The Society for Vascular Surgery practice guidelines on follow-up after vascular surgery arterial procedures. *J Vasc Surg*. 2018;68(1):256-284. doi:10.1016/j.jvs.2018.04.018.1.
6. Muratore F, Pipitone N, Salvarani C, Schmidt WA. Imaging of vasculitis: State of the art. *Best Practice Research Clinical Rheumatology*. 2016;30(4):688-706. doi:10.1016/j.berh.2016.09.010.
7. Lensen KDF, Comans EFI, Voskuyl AE, et al. Large-Vessel Vasculitis: Interobserver Agreement and Diagnostic Accuracy of 18F-FDG-PET/CT. *BioMed Research International*. 2015;2015:1-8. doi:10.1155/2015/914692.
8. Soussan M, Nicolas P, Schramm C, et al. Management of Large-Vessel Vasculitis With FDG-PET. *Medicine*. 2015;94(14). doi:10.1097/md.0000000000000622.
9. Besson FL, Parienti J-J, Bienvenu B, et al. Diagnostic performance of 18F-fluorodeoxyglucose positron emission tomography in giant cell arteritis: a systematic review and meta-analysis. *European Journal of Nuclear Medicine and Molecular Imaging*. 2011;38(9):1764-1772. doi:10.1007/s00259-011-1830-0.
10. Sivaraman V, Fels EC, and Ardoin SP. Vasculitis syndromes. *Nelson Textbook of Pediatrics*, Chapter 192. eds Kliegman RM, St. Geme JW III, Blum NJ, et al. 21st ed. Philadelphia, PA: Elsevier; 2020:1317-1327.
11. Soliman M, Laxer R, Manson D, et al. Imaging of systemic vasculitis in childhood. *Pediatric Radiology*. 2015;45(8):1110-1125. doi:10.1007/s00247-015-3339-3.
12. Sharma AM, Singh S, Lewis JE. Diagnostic Approach in Patients With Suspected Vasculitis. *Techniques in Vascular and Interventional Radiology*. 2014;17(4):226-233. doi:10.1053/j.tvir.2014.11.002.
13. Ammirati E, Moroni F, Pedrotti P, et al. Non-Invasive Imaging of Vascular Inflammation. *Frontiers in Immunology*. 2014;5:1-15. doi:10.3389/fimmu.2014.00399.
14. Granata C, Damasio MB, Zaottini F, et al. Imaging of Childhood Vasculitis. *Radiologic Clinics of North America*. 2017;55(5):1131-1143. doi:10.1016/j.rcl.2017.05.001.
15. Broncano J, Vargas D, Bhalla S, Cummings KW, Raptis CA, Luna A. CT and MR Imaging of Cardiothoracic Vasculitis. *RadioGraphics*. 2018;38(4):997-1021. doi:10.1148/rg.2018170136.
16. Jennette JC, Falk RJ, Bacon PA, et al. 2012 Revised International Chapel Hill Consensus Conference Nomenclature of Vasculitides. *Arthritis & Rheumatism*. 2012;65(1):1-11. doi:10.1002/art.37715.
17. Ozen S, Pistorio A, Iusan SM, et al. EULAR/PRINTO/PRES criteria for Henoch-Schonlein purpura, childhood polyarteritis nodosa, childhood Wegener granulomatosis and childhood Takayasu arteritis: Ankara 2008. Part II: Final classification criteria. *Annals of the Rheumatic Diseases*. 2010;69(5):798-806. doi:10.1136/ard.2009.116657
18. Cui J, Huang LY, Guo J, Wu CR, Zhang B. Diagnosis and treatment of adult mixed-type Henoch-Schönlein purpura. *Cent Eur J Immunol*. 2019;44(2):138-143. doi:10.5114/ceji.2019.87064.

Peripheral Arterial Imaging

Guideline

Upper Extremity PVD – Imaging (PVD-4.1)

Renovascular Hypertension/Renal Artery Stenosis (PVD-6.6)

Visceral Artery Aneurysm (PVD-6.5)

Median Arcuate Ligament Syndrome, Nutcracker Syndrome and other
Abdominal Vascular Compression Syndromes (PVD-18)

Lower Extremity Artery Aneurysms (PVD-7.4)

Claudication and Critical Limb Ischemia (PVD-7.1)

Popliteal Artery Entrapment Syndrome (PVD-7.2)

Post-Procedure Surveillance Studies (PVD-7.3)

Arterial Imaging for Free Flaps in Reconstructive Surgery (PVD-7.5)

Arteriovenous Malformations (AVMs) (PVD-9.1)

Upper Extremity PVD – Imaging (PVD-4.1)

PVD.AI.0004.1.A
v1.0.2024

Initial Imaging

- Arterial ultrasound upper extremities (CPT® 93930 or CPT® 93931) for signs and symptoms of arterial insufficiency including:
 - Arm or hand claudication, cramping or fatigue of the unilateral extremity with use or with raising limb overhead that is relieved with rest and is reproducible. See **Subclavian Steal Syndrome (CH-27)** in the Chest Imaging Guidelines
 - Systolic blood pressure differential between arms of >15mmHg. See **Subclavian Steal Syndrome (CH-27)** in the Chest Imaging Guidelines
 - Bluish discoloration of the hand or fingers
 - Unilateral cold, painful, pulseless hand
 - Non-healing wound (>2 weeks with no healing or evidence of healing) or frank gangrene
- CTA Upper extremity (CPT® 73206) or MRA of Upper extremity (CPT® 73225), **and/or** CTA Chest (CPT® 71275) or MRA Chest (CPT® 71555) for:
 - Abnormal results
 - Equivocal results
 - Pre-operative planning
- For suspected Fibromuscular Dysplasia of the brachial artery, appropriate studies include:
 - MRA Upper extremity (CPT® 73225)
 - CTA Upper extremity (CPT® 73206)
 - Arterial Ultrasound (CPT® 93930 bilateral study or CPT® 93931 unilateral study)

Post-revascularization

- Arterial Duplex (CPT® 93931) can be obtained following upper extremity arterial revascularization at:
 - Baseline (within one month)
 - 6 months
 - Then annually if stable
 - Anytime for new or worsening symptoms of arterial insufficiency

References (PVD-4)

1. Skeik N, Soo-Hoo SS, Porten BR, et al. Arterial Embolisms and Thrombosis in Upper Extremity Ischemia. *Vascular and Endovascular Surgery*. 2015;49(5-6):100-109. doi:10.1177/1538574415596740.
2. Desjardins B, Rybicki FJ, Kim HS, et al. ACR Appropriateness Criteria® Suspected Upper Extremity Deep Vein Thrombosis. *J Am Coll Radiol* 2012;9(9):613-619. doi:10.1016/j.jacr.2012.05.021.
3. Kraaijpoel N, Es NV, Porreca E, Büller HR, Nisio MD. The diagnostic management of upper extremity deep vein thrombosis: A review of the literature. *Thrombosis Research*. 2017;156:54-59. doi:10.1016/j.thromres.2017.05.035.
4. Hughes K, Cubangbang M, Blackman K, et al. Upper Extremity Bypass for Chronic Ischemia—A National Surgical Quality Improvement Program Study Database Study. *Vascular and Endovascular Surgery*. 2013;47(3):192-194. doi:10.1177/1538574413478472.

Renovascular Hypertension/Renal Artery Stenosis (PVD-6.6)

PVD.AI.0006.6.A
v1.0.2024

Initial imaging

- MRA Abdomen (CPT® 74185) or CTA Abdomen (CPT® 74175) or US kidney retroperitoneal (CPT® 76775) and/or Doppler (CPT® 93975, 93976, 93978, or 93979 if expertise is available) are indicated when there is documentation of **any** of the following:
 - Individual is adherent to full doses of three blood pressure medications (including a diuretic) yet has still not achieved goal
 - Sudden and persistent worsening of previously controlled hypertension
 - Onset of hypertension younger than 30 years of age
 - Malignant hypertension with coexistent evidence of acute end-organ damage (acute renal failure, new visual or neurological disturbance and/or advanced retinopathy) or flash pulmonary edema
 - Individuals who develop hypertension ($\geq 140/90$) within the first 20 weeks of pregnancy when hypertension persists >12 weeks post-partum
 - New or worsening renal function/increasing creatinine (especially after the administration of an ACE inhibitor or with angiotensin receptor blocking agent)
- Carotid duplex (CPT® 93880) is reasonable to screen for carotid involvement in individuals with documented or highly suspicious renal artery stenosis due to fibromuscular dysplasia (mostly women between 15 and 50 years of age).

Screening

CTA Abdomen (CPT® 74175) or MRA Abdomen (CPT® 74185) to screen for renovascular fibromuscular dysplasia in hypertensive individuals with documented cervicocephalic fibromuscular dysplasia. The assessment of other vascular beds should be considered if supported by suggestive symptoms or medical history.

Carotid duplex (CPT® 93880) is reasonable to screen for carotid involvement in individuals with documented or highly suspicious renal artery stenosis due to fibromuscular dysplasia (mostly women between 15 and 50 years of age)

Repeat imaging post revascularization

- CTA Abdomen (CPT® 74175), or MRA Abdomen (CPT® 74185), or CT Abdomen with contrast (CPT® 74160) is indicated after stent placement at the following intervals:
 - 1 month post-procedure

- 6 months post-procedure
- 12 months post-procedure
- Then annually

Background and Supporting Information

Renal artery revascularization has **not** been shown to be more effective than medical therapy in most situations and should not be pursued except in extreme cases, or if there is concern for Takayasu arteritis or fibromuscular dysplasia.

Gadolinium agents may be contraindicated in individuals with severe renal disease or on dialysis due to the risk of developing nephrogenic systemic sclerosis

References (PVD-6.6)

1. Harvin HJ, Verma N, Nikolaidis P, et al. ACR Appropriateness Criteria ® Renovascular Hypertension. *J Am Coll Radiol.* 2017;14(11). doi:10.1016/j.jacr.2017.08.040..
2. Moser M, Setaro JF. Resistant or Difficult-to-Control Hypertension. *N Engl J Med.* 2006;355(4):385-392. doi:10.1056/nejmcp041698.
3. Whelton PK, Carey RM, Aronow WS, et al. 2017 ACC/AHA/AAPA/ABC/ACPM/AGS/APhA/ASH/ASPC/NMA/PCNA Guideline for the Prevention, Detection, Evaluation, and Management of High Blood Pressure in Adults: A Report of the American College of Cardiology/American Heart Association Task Force on Clinical Practice Guidelines. *Hypertension.* 2018;71(6). doi:10.1161/hyp.000000000000065.
4. Hicks CW, Clark TWI, Cooper CJ, et al. Atherosclerotic Renovascular Disease: A KDIGO (Kidney Disease: Improving Global Outcomes) Controversies Conference. *Am J Kidney Dis.* 2022;79(2):289-301. doi:10.1053/j.ajkd.2021.06.025.

Visceral Artery Aneurysm (PVD-6.5)

PVD.AD.0006.5.A

v1.0.2024

- Treatment is generally indicated for visceral aneurysms ≥ 2 cm.
- Workup for suspected visceral artery aneurysm (spleen, kidney, liver or intestines) if calcifications seen on plain film imaging can include:
 - Ultrasound (CPT[®] 76700, 76705, 93975, 93976, 93978, or 93979), or
 - CTA Abdomen (CPT[®] 74175), or
 - CT Abdomen with contrast (CPT[®] 74160).
- Ultrasound (CPT[®] 76700, 76705, 93975, 93976, 93978, or 93979) **or** CTA Abdomen (CPT[®] 74175) **or** CT Abdomen with contrast (CPT[®] 74160) for further monitoring based on the intervals below or as determined by a vascular specialist or any provider in consultation with a vascular specialist:
 - Splenic artery aneurysms:
 - < 20 mm can be imaged every three years
 - 20mm to 29mm can be imaged annually
 - If ≥ 30 mm, they should be referred for treatment, either stent, excision or splenectomy
 - For all other visceral artery aneurysms:
 - Initial evaluation with six-month follow-up for one year
 - Further follow-up annually if no significant enlargement is seen
- CTA Abdomen (CPT[®] 74175), MRA Abdomen (CPT[®] 74185), or CT Abdomen with contrast (CPT[®] 74160) are indicated following stent placement at:
 - 1 month
 - 6 months
 - 12 months
 - Then every year

Background and Supporting Information

- Splenic artery aneurysms, the most common (60%), tend to exhibit very slow rates of growth, while the other visceral artery aneurysms are more unpredictable in their rate of growth with a greater tendency to rupture.
- Visceral Artery Aneurysms are defined by an increase of more than 50% of the original arterial diameter and include hepatic, renal and intestinal artery aneurysms.
- Vascular specialty consultation is beneficial in order to determine the time-frame to intervention.

References (PVD-6.5)

1. Alcantara S, Yank CK. The evidence for nonoperative management of visceral arterial dissections. A single center experience. *Annals of Vasc Surg* 2015; 29: 103–108.
2. Chaer R, Abularrage C, Coleman D et al. The Society for Vascular Surgery clinical practice guidelines on the management of visceral aneurysms. *Journal of Vasc Surg* 2020;72:3S-39S.

Median Arcuate Ligament Syndrome, Nutcracker Syndrome and other Abdominal Vascular Compression Syndromes (PVD-18)

PVD.AI.0018.A
v1.0.2024

Guideline

Median Arcuate Ligament Syndrome
Left Renal Vein Compression (“Nutcracker”) Syndrome

Median Arcuate Ligament Syndrome

Codes included

CPT®	Description
74175	Computed tomographic angiography, abdomen, with contrast material(s), including noncontrast images, if performed, and image postprocessing
74185	Magnetic resonance angiography, abdomen, with or without contrast material(s)
93975	Duplex scan of arterial inflow and venous outflow of abdominal, pelvic, scrotal contents and/or retroperitoneal organs; complete study
93976	Duplex scan of arterial inflow and venous outflow of abdominal, pelvic, scrotal contents and/or retroperitoneal organs; limited study

Initial Imaging

- Duplex Doppler Ultrasound of Mesenteric Arteries (CPT® 93975 or 93976) is indicated as the initial imaging
- CTA or MRA Abdomen (CPT® 74175 or 74185) is indicated for **either**:
 - US results are equivocal
 - Preoperative planning

Repeat imaging

- Surveillance imaging is not indicated post-operatively in the absence of abdominal symptoms.

Background and supporting information

A non-atherosclerotic cause of chronic mesenteric ischemia.

Patients are typically younger with an average age range of 30-50 years old and a female to male ratio of 4:1

Patients may have symptoms of postprandial abdominal pain, nausea, vomiting, food aversion, weight loss. Symptoms are nonspecific, so MALS may be considered a diagnosis of exclusion.

Imaging will demonstrate compression of the celiac artery by fibers of the median arcuate ligament, but this is a nonspecific finding and may be seen in the asymptomatic population.

Pathophysiologically related to foregut ischemic from compression of the celiac artery; may also be related to neuropathic pain secondary to compression of the celiac ganglion.

Treatment is generally surgical, via a variety of approaches.

References

1. Columbo JA, Trus T, Nolan B, et al. Contemporary management of median arcuate ligament syndrome provides early symptom improvement. *J Vasc Surg.* 2015;62(1):151-156. doi:10.1016/j.jvs.2015.01.050.
2. Goodall R, Langridge B, Onida S, Ellis M, Lane T, Davies AH. Median arcuate ligament syndrome. *J Vasc Surg.* 2020;71(6):2170-2176. doi:10.1016/j.jvs.2019.11.012.
3. Kim EN, Lamb K, Relles D, Moudgill N, DiMuzio PJ, Eisenberg JA. Median Arcuate Ligament Syndrome-Review of This Rare Disease. *JAMA Surg.* 2016;151(5):471-477. doi:10.1001/jamasurg.2016.0002.
4. Björck M, Koelemay M, Acosta S, et al. Editor's Choice - Management of the Diseases of Mesenteric Arteries and Veins: Clinical Practice Guidelines of the European Society of Vascular Surgery (ESVS). *Eur J Vasc Endovasc Surg.* 2017;53(4):460-510. doi:10.1016/j.ejvs.2017.01.010.
5. Expert Panels on Vascular Imaging and Gastrointestinal Imaging:, Ginsburg M, Obara P, et al. ACR Appropriateness Criteria® Imaging of Mesenteric Ischemia. *J Am Coll Radiol.* 2018;15(11S):S332-S340. doi:10.1016/j.jacr.2018.09.018.

Left Renal Vein Compression (“Nutcracker”) Syndrome

Codes included

CPT®	description
93975	Duplex scan of arterial inflow and venous outflow of abdominal, pelvic, scrotal contents and/or retroperitoneal organs; complete study
93976	Duplex scan of arterial inflow and venous outflow of abdominal, pelvic, scrotal contents and/or retroperitoneal organs; limited study
74174	Computed tomographic angiography, abdomen and pelvis, with contrast material(s), including noncontrast images, if performed, and image postprocessing
72198	Magnetic resonance angiography, pelvis, with or without contrast material(s)

CPT®	description
74185	Magnetic resonance angiography, abdomen, with or without contrast material(s)

Initial Imaging

- Abdominal duplex (CPT® 93975 or 93976) is indicated as the initial imaging to confirm left renal vein compression syndrome.
- CTV or MRV Abdomen and Pelvis (CPT® 74174) or (CPT® 74185 and 72198) is indicated for preoperative planning when left renal vein compression syndrome is confirmed by duplex ultrasound.

Repeat imaging

- Postoperative follow up imaging is not indicated in the absence of symptomatology.

Background and supporting information

Patients may present with symptoms related to compression of the left renal vein between the aorta and superior mesenteric artery. A less common presentation (“posterior nutcracker syndrome”) is related to compression of a retroaortic (or circumaortic) left renal vein between the aorta and vertebral body.

The radiologic finding may be asymptomatic or considered a normal variant.

Signs/symptoms may include hematuria, proteinuria, flank pain, pelvic congestion/ associated pain in females, varicocele in males.

There may be an overlap in symptom complex with patients who have pelvic congestion syndrome, iliac vein compression (May-Thurner).

There is no single accepted treatment modality. Approaches will range from conservative/medical (esp in younger patients), to endovascular, to open/laparoscopic/robotic surgical.

References

1. Velasquez CA, Saeyeldin A, Zafar MA, Brownstein AJ, Erben Y. A systematic review on management of nutcracker syndrome. *J Vasc Surg Venous Lymphat Disord*. 2018;6(2):271-278. doi:10.1016/j.jvsv.2017.11.005.
2. Ananthan K, Onida S, Davies AH. Nutcracker Syndrome: An Update on Current Diagnostic Criteria and Management Guidelines. *Eur J Vasc Endovasc Surg*. 2017;53(6):886-894. doi:10.1016/j.ejvs.2017.02.015.
3. Meissner MH, Khilnani NM, Labropoulos N, Gasparis AP, Gibson K, Greiner M, et al. The Symptoms-Varices-Pathophysiology classification of pelvic venous disorders: A report of the American Vein & Lymphatic Society International Working Group on Pelvic Venous Disorders. *J Vasc Surg Venous Lymphat Disord* 2021;9:568-84.
4. De Maeseneer MG, Kakkos SK, Aherne T, et al. Editor's Choice - European Society for Vascular Surgery (ESVS) 2022 Clinical Practice Guidelines on the Management of Chronic Venous Disease of the Lower Limbs [published correction appears in *Eur J Vasc Endovasc Surg*. 2022 Aug-Sep;64(2-3):284-285]. *Eur J Vasc Endovasc Surg*. 2022;63(2):184-267. doi:10.1016/j.ejvs.2021.12.024.

5. Gloviczki P, Comerota AJ, Dalsing MC, et al. The care of patients with varicose veins and associated chronic venous diseases: clinical practice guidelines of the Society for Vascular Surgery and the American Venous Forum. *J Vasc Surg*. 2011;53(5 Suppl):2S-48S. doi:10.1016/j.jvs.2011.01.079.

Lower Extremity Artery Aneurysms (PVD-7.4)

PVD.AI.0007.4.A

v1.0.2024

- For Iliac artery aneurysm see **Iliac Artery Aneurysm (IAA) (PVD-6.4)**
- Femoral artery aneurysm
 - Initial imaging
 - Ultrasound (CPT® 93925 bilateral study or CPT® 93926 unilateral study).
 - Surveillance imaging
 - Symptomatic true femoral aneurysms smaller than 2.5 cm in diameter
 - Ultrasound (CPT® 93926 unilateral study) annually
 - Symptomatic true femoral aneurysms larger than 2.5 cm
 - Ultrasound (CPT® 93926 unilateral study) every 6 months
 - Other imaging
 - CTA or MRA Lower extremity (CPT® 73706 or 73725 or 74198 or 75635):
 - Preoperative study for individuals with no plans for invasive angiography
 - Technically limited or abnormal ultrasound results
- Popliteal artery aneurysm
 - Initial imaging
 - Ultrasound (CPT® 93925 bilateral study or CPT® 93926 unilateral study) and Ultrasound to assess for a contralateral popliteal aneurysm and abdominal aortic aneurysm (CPT® 76770 or CPT® 76775)
 - Surveillance imaging
 - Ultrasound (CPT® 93926 unilateral study) annually
 - Post-interventional functional testing (ABI) (CPT® 93922) may be useful as clinically indicated
 - Other imaging
 - CTA or MRA (CPT® 73706 or 73725 or 74185 or 75635) for:
 - Preoperative study
 - Technically limited or abnormal ultrasound results

References (PVD-7.4)

1. Hall HA, Minc S, Babrowski T. Peripheral artery aneurysm. *Surg Clin North Am.* 2013;93(4):911-ix. doi:10.1016/j.suc.2013.04.008.
2. von Stumm M, Teufelsbauer H, Reichenspurner H, Debus ES. Two Decades of Endovascular Repair of Popliteal Artery Aneurysm--A Meta-analysis. *Eur J Vasc Endovasc Surg.* 2015;50(3):351-359. doi:10.1016/j.ejvs.2015.04.036
3. Kim TI, Sumpio BE. Management of Asymptomatic Popliteal Artery Aneurysms. *Int J Angiol.* 2019;28(1):5-10. doi:10.1055/s-0038-1676792.
4. Corriere MA, Guzman RJ. True and false aneurysms of the femoral artery. *Semin Vasc Surg.* 2005;18(4):216-223. doi:10.1053/j.semvascsurg.2005.09.008

Claudication and Critical Limb Ischemia (PVD-7.1)

PVD.AI.0007.1.A

v1.0.2024

- Resting ABI for initial evaluation of suspected PAD. This can be accomplished at the bedside as part of the physical examination or requested as CPT® 93922 (limited Doppler ultrasound) or CPT® 93923 (multi-level complete Doppler ultrasound)
 - CPT® 93923 may be performed once
 - Follow-up studies may be performed with CPT® 93922
 - Post-exercise ABI (CPT® 93924) can be performed if the resting ABI is >0.89 and PAD is still highly suspected clinically.
- History and physical suggestive of PAD include:
 - History
 - Claudication- reproducible calf or thigh cramping with exertion that is relieved completely with rest
 - Critical limb ischemia
 - Rest pain suggestive of ischemia-pain in the ball of foot when the leg is in an elevated position particularly at night
 - Distal non-healing wound or punched out ulcer with sharply demarcated edges present for >2 weeks with no evidence of healing, i.e. presence of granulation tissue
 - Physical Examination
 - Abnormal lower extremity pulse examination
 - Vascular bruit
 - Non-healing lower extremity wound
 - Lower extremity gangrene
 - Other suggestive lower extremity physical findings (e.g., elevation pallor/dependent rubor)
 - Atrophic nails, hair loss, shiny skin
- If resting ABI (CPT® 93922) is normal (0.9 to 1.3) and disease is still suspected:
 - Differentiate from “pseudoclaudication”. See **Lumbar Spinal Stenosis (SP-9)** in the Spine Imaging Guidelines
 - Re-measure ABI after exercise (CPT® 93924)
 - A TBI (toe-brachial index) may be used as further screening in individuals with ABI's ≥ 1.4
 - Advanced imaging is necessary only if there is consideration for invasive therapy not to confirm diagnosis

- Duplex ultrasound (CPT® 93925 bilateral study or CPT® 93926 unilateral study) and Doppler studies are adjuncts to abnormal ABI that may be used to identify location and extent of disease once there has been a decision for revascularization.
- MRA Aorta and Pelvic vessels, and Lower extremities (CPT® 74185, CPT® 73725 and CPT® 73725), **or** CTA with run-off (CPT® 75635) to further evaluate the lower extremity arteries for **ANY** of the following:
 - Potentially limb-threatening vascular disease evidenced by:
 - Skin breakdown
 - Non-healing ischemic ulcers
 - Resting leg pain
 - Gangrene
 - Blue Toe Syndrome:
 - Emboli from aortic plaque or mural thrombus
 - Hyperviscosity syndrome
 - Hypercoagulable states
 - Vasculitis
 - Preoperative planning for Intermittent claudication (i.e., non-limb threatening ischemia) **AND** there is documentation of both of the following:
 - Failed 3-months' conservative medical therapy (physician supervised walking/exercise program plus medical therapy)
 - Functional disability (e.g., exercise impairment sufficient to threaten the individual's employment or to require significant alterations in the individual's lifestyle)
 - CTA lower extremity (CPT® 73706) OR MRA lower extremity (CPT® 73725) can be approved for evaluation of PVD when aortoiliac disease is not a concern or the state of the aorta and iliac arteries is already known as documented in the clinical history

Note MRA Pelvis (CPT® 72198) should not be requested/billed with CPT® 74185, CPT® 73725 and CPT® 73725

Background and Supporting Information

Claudication symptoms usually remain stable (70% to 80% of individuals) and do not worsen or improve at rapid rates. Repeat studies to assess the efficacy of medical therapy are not indicated unless there is a negative change in clinical status for the purpose of preoperative planning such as worsening claudication or progression to critical limb ischemia.

References (PVD-7)

1. Dick F, Ricco J-B, Davies A.H, Cao P, et al. Chapter VI: Follow-up after Revascularization. *European Journal of Vascular and Endovascular Surgery*, Volume 42, Supplement 2, 2011 pp.S75-90.
2. Lane TRA et al. Post-Operative Surveillance after Open Peripheral Arterial Surgery. *Eur J Vasc Endovasc Surg*. Volume 42, Issue 1, July 2011. Pages 59-77.
3. Brooke BS, Beck AW, Kraiss LW, et al. Association of Quality Improvement Registry Participation with Appropriate Follow-up after Vascular Procedures. *JAMA Surgery*. 2018;153(3):216. doi:10.1001/jamasurg.2017.3942.
4. Rooke TW, Hirsch AT, Misra S, Sidawy AN, et al. 2011 ACCF/AHA focused update of the guideline for the management of patients with peripheral artery disease (updating the 2005 guideline): a report of the American College of Cardiology Foundation/American Heart Association Task Force on Practice Guidelines: developed in collaboration with the Society for Cardiovascular Angiography and Interventions, Society of Interventional Radiology, Society for Vascular Medicine, and Society for Vascular Surgery. American College of Cardiology Foundation/American Heart Association Task Force on Practice Guidelines., Society for Cardiovascular Angiography and Interventions., Society of Interventional Radiology., Society for Vascular Medicine., Society for Vascular Surgery. *J Vasc Surg*. 2011 Nov; 54(5):e32-58
5. Conte MS, Pomposelli FB, and Clair DG. Society for Vascular Surgery practice guidelines for atherosclerotic occlusive disease of the lower extremities: Management of asymptomatic disease and claudication. *J Vasc Surg*. March 2015;61(3):2S-41S.e1
6. Bui TD, Mills JL Sr, Inhnat DM et al. The natural history of duplex-detected stenosis after femoropopliteal endovascular therapy suggests questionable clinical utility of routine duplex surveillance. *J Vasc Surg*. 2012 Feb 55:2:346-352
7. Troutman DA, Madden NJ, Dougherty MJ, et al. Duplex Ultrasound Diagnosis of Failing Stent Grafts Placed for Occlusive Disease. *J Vasc Surg* 2014;70:1–5.
8. Humphries MD, Pevec WC, Laird JR, et.al. Early Duplex Scanning after Infrainguinal Endovascular Therapy. *J Vasc Surg* 2011; 53:353–8.
9. Zierler RE, Jordan WD, Lal BK, et al. The Society for Vascular Surgery practice guidelines on follow-up after vascular surgery arterial procedures. *J Vasc Surg*. 2018 Jul;68(1):256-284. doi: 10.1016/j.jvs.2018.04.018.
10. Cooper K, Majdalany BS, Kalva SP, et al. ACR Appropriateness Criteria® Lower Extremity Arterial Revascularization—Post-Therapy Imaging. *J Am Coll Radiol*. 2018;15:S104-S115.
11. Gerhard-Herman MD, Gornik HL, Barrett C, et al. 2016 AHA/ACC Guideline on the management of patients with lower extremity peripheral artery disease: a report of the American College of Cardiology/American Heart Association Task Force on Clinical Practice Guidelines. *Circulation*. 2017; 135: e726-e779.
12. Ahmed O, Hanley M, Bennett SJ, et al. ACR Appropriateness Criteria® Vascular claudication -Assessment for Revascularization. *J Am Coll Radiol*. 2017 May;14(5S):S372-S379. doi: 10.1016/j.jacr.2017.02.037.
13. Macedo TA, Johnson M, Hallett Jr JW, and Breen JF. Popliteal artery entrapment syndrome: role of imaging in the diagnosis. *AJR Am J Roentgen*. 2003 Nov;181(5):1259-1265. doi:10.2214/ajr.181.5.1811259.
14. Ahmed O, Hanley M, Bennett SJ, et al. ACR® Appropriateness Criteria Vascular Claudication-Assessment for Revascularization. *J Am Coll Radiol*. 2017;14(5):S372-S379. doi:10.1016/j.jacr.2017.02.037.

Popliteal Artery Entrapment Syndrome (PVD-7.2)

PVD.AI.0007.2.A

v1.0.2024

- Diagnosis of popliteal artery stenosis or occlusion due to compression by adjacent muscle and tendons:
 - Ultrasound (CPT® 93926 unilateral study), CTA Lower extremity (CPT® 73706), or MRA Lower extremity (CPT® 73725).
 - CT or MRI Lower Extremity (contrast as requested) if requested by the operating surgeon

Background and Supporting Information

Popliteal Artery Entrapment Syndrome is typically seen in young men (ages 20 to 40) but is not exclusive to this gender or age group.

References (PVD-7.2)

1. Hall HA, Minc S, Babrowski T. Peripheral artery aneurysm. *Surg Clin North Am.* 2013;93(4):911-ix. doi:10.1016/j.suc.2013.04.008.
2. von Stumm M, Teufelsbauer H, Reichenspurner H, Debus ES. Two Decades of Endovascular Repair of Popliteal Artery Aneurysm--A Meta-analysis. *Eur J Vasc Endovasc Surg.* 2015;50(3):351-359. doi:10.1016/j.ejvs.2015.04.036
3. Kim TI, Sumpio BE. Management of Asymptomatic Popliteal Artery Aneurysms. *Int J Angiol.* 2019;28(1):5-10. doi:10.1055/s-0038-1676792.
4. Corriere MA, Guzman RJ. True and false aneurysms of the femoral artery. *Semin Vasc Surg.* 2005;18(4):216-223. doi:10.1053/j.semvascsurg.2005.09.008

Post-Procedure Surveillance Studies (PVD-7.3)

PVD.AI.0007.3.A
v1.0.2024

- Scheduled Interval
 - ABI (CPT® 93922) following any revascularization procedure
 - ABI (CPT® 93922) or Duplex ultrasound (CPT® 93926 unilateral study) at each routine follow up is indicated generally after a history/physical has been performed
 - Further imaging studies such as CTA or MRA are indicated for worsening symptoms, an abnormal duplex or a significant reduction (>0.15) in the ABI

Indication	Imaging
Suprainguinal Revascularization, both open and endovascular therapy, including Aortobifem/iliofem/fem-fem bypass/iliac angioplasty/stent	<ul style="list-style-type: none"> • Clinical examination and ABI (CPT® 93922) with arterial duplex (CPT® 93978 or CPT® 93979) at: <ul style="list-style-type: none"> • Within 1 month • 6 months • 12 months • Then annually
Infrainguinal Open Revascularization (Femoral-popliteal, femoral-tibial, femoral-distal bypass)	
<ul style="list-style-type: none"> • With vein or autologous conduit 	<ul style="list-style-type: none"> • Clinical exam and ABI (CPT® 93922) with arterial duplex (CPT® 93978 or CPT® 93979) <ul style="list-style-type: none"> • Post-operatively • 3 months • 6 months • 12 months • Then annually
<ul style="list-style-type: none"> • With Prosthetic conduit (PTFE/Dacron) 	<ul style="list-style-type: none"> • Clinical exam and ABI (CPT® 93922) with arterial duplex (CPT® 93978 or CPT® 93979) <ul style="list-style-type: none"> • Post-operatively • 6 months • 12 months • Then annually

Indication	Imaging
Infrainguinal Endovascular Revascularization Femoropopliteal angioplasty/stent	<ul style="list-style-type: none"> • Clinical exam and ABI (CPT® 93922) with arterial duplex (CPT® 93978 or CPT® 93979): <ul style="list-style-type: none"> • Within 1 month • 3 month • Every 6 months for two years • Then annually

After suprainguinal intervention (PVD-7.3.1)

- One of the following studies: Arterial duplex, CTA Abdomen and Pelvis, CT Abdomen and Pelvis with contrast, CTA Aorta with lower extremity runoff, MRI Abdomen and Pelvis, MRA Abdomen and Pelvis, or MRA Aorta with lower extremity runoff for any **one** of the following:
 - Worsening signs or symptoms
 - Reduction of ABI >0.15
 - Peak systolic velocities or PSV ratio suggestive of high grade stenosis or in-stent re-stenosis

After infrainguinal intervention (PVD-7.3.2)

- CTA Lower Extremity (CPT® 73706) or MRA Lower Extremity (CPT® 73725) or CTA aorta with lower extremity runoff CPT® 75635) for any **one** of the following:
 - Worsening signs or symptoms
 - Reduction of ABI >0.15
 - Duplex suggestive of threatened graft
- If intervention was performed for a non-healing wound and wound has gone on to heal, no additional imaging is recommended for surveillance.
- Repeat arterial duplex imaging can be obtained for worsening clinical signs and symptoms such as the presence of a new wound or rest pain

References (PVD-7.3)

1. Dick F, Ricco J-B, Davies A.H, Cao P, et. al. Chapter VI: Follow-up after Revascularization. *European Journal of Vascular and Endovascular Surgery*, Volume 42, Supplement 2, 2011 pp.S75-90.
2. Lane TRA et al. Post-Operative Surveillance after Open Peripheral Arterial Surgery. *Eur J Vasc Endovasc Surg*. Volume 42, Issue 1, July 2011. Pages 59-77.
3. Brooke BS, Beck AW, Kraiss LW, et al. Association of Quality Improvement Registry Participation with Appropriate Follow-up after Vascular Procedures. *JAMA Surgery*. 2018;153(3):216. doi:10.1001/jamasurg.2017.3942.
4. Rooke TW, Hirsch AT, Misra S, Sidawy AN, et al. 2011 ACCF/AHA focused update of the guideline for the management of patients with peripheral artery disease (updating the 2005 guideline): a report of the American

- College of Cardiology Foundation/American Heart Association Task Force on Practice Guidelines: developed in collaboration with the Society for Cardiovascular Angiography and Interventions, Society of Interventional Radiology, Society for Vascular Medicine, and Society for Vascular Surgery. American College of Cardiology Foundation/American Heart Association Task Force on Practice Guidelines., Society for Cardiovascular Angiography and Interventions., Society of Interventional Radiology., Society for Vascular Medicine., Society for Vascular Surgery. *J Vasc Surg*. 2011 Nov; 54(5):e32-58
5. Conte MS, Pomposelli FB, and Clair DG. Society for Vascular Surgery practice guidelines for atherosclerotic occlusive disease of the lower extremities: Management of asymptomatic disease and claudication. *J Vasc Surg*. March 2015;61(3):2S-41S.e1
 6. Bui TD, Mills JL Sr, Inhnat DM et al. The natural history of duplex-detected stenosis after femoropopliteal endovascular therapy suggests questionable clinical utility of routine duplex surveillance. *J Vasc Surg*. 2012 Feb 55:2:346-352
 7. Troutman DA, Madden NJ, Dougherty MJ, et al. Duplex Ultrasound Diagnosis of Failing Stent Grafts Placed for Occlusive Disease. *J Vasc Surg* 2014;70:1–5.
 8. Humphries MD, Pevec WC, Laird JR, et.al. Early Duplex Scanning after Infrainguinal Endovascular Therapy. *J Vasc Surg* 2011; 53:353–8.
 9. Zierler RE, Jordan WD, Lal BK, et al. The Society for Vascular Surgery practice guidelines on follow-up after vascular surgery arterial procedures. *J Vasc Surg*. 2018 Jul;68(1):256-284. doi: 10.1016/j.jvs.2018.04.018.
 10. Cooper K, Majdalany BS, Kalva SP, et al. ACR Appropriateness Criteria[®] Lower Extremity Arterial Revascularization—Post-Therapy Imaging. *J Am Coll Radiol*. 2018;15:S104-S115.
 11. Gerhard-Herman MD, Gornik HL, Barrett C, et al. 2016 AHA/ACC Guideline on the management of patients with lower extremity peripheral artery disease: a report of the American College of Cardiology/American Heart Association Task Force on Clinical Practice Guidelines. *Circulation*. 2017; 135: e726-e779.
 12. Ahmed O, Hanley M, Bennett SJ, et al. ACR Appropriateness Criteria[®] Vascular claudication -Assessment for Revascularization. *J Am Coll Radiol*. 2017 May;14(5S):S372-S379. doi: 10.1016/j.jacr.2017.02.037.
 13. Macedo TA, Johnson M, Hallett Jr JW, and Breen JF. Popliteal artery entrapment syndrome: role of imaging in the diagnosis. *AJR Am J Roentgen*. 2003 Nov;181(5):1259-1265. doi:10.2214/ajr.181.5.1811259.

Arterial Imaging for Free Flaps in Reconstructive Surgery (PVD-7.5)

PVD.AI.0007.5.A

v1.0.2024

- For breast reconstruction preoperative planning. See **Breast Reconstruction (BR-3)** in the Breast Imaging Guidelines
- For head and neck reconstruction, CTA or MRA unilateral lower extremity (CPT® 73706 or 73725) of the harvest site is indicated for evaluation of perforator anatomy for planned fibular flap

References (PVD-7.4)

1. Hall HA, Minc S, Babrowski T. Peripheral artery aneurysm. *Surg Clin North Am.* 2013;93(4):911-ix. doi:10.1016/j.suc.2013.04.008.
2. von Stumm M, Teufelsbauer H, Reichenspurner H, Debus ES. Two Decades of Endovascular Repair of Popliteal Artery Aneurysm--A Meta-analysis. *Eur J Vasc Endovasc Surg.* 2015;50(3):351-359. doi:10.1016/j.ejvs.2015.04.036
3. Kim TI, Sumpio BE. Management of Asymptomatic Popliteal Artery Aneurysms. *Int J Angiol.* 2019;28(1):5-10. doi:10.1055/s-0038-1676792.
4. Corriere MA, Guzman RJ. True and false aneurysms of the femoral artery. *Semin Vasc Surg.* 2005;18(4):216-223. doi:10.1053/j.semvascsurg.2005.09.008

Arteriovenous Malformations (AVMs) (PVD-9.1)

PVD.AI.0009.1.A

v1.0.2024

- See **Pulmonary AVMs (CH-24.1)** in the Chest Imaging Guidelines
- See **Arteriovenous Malformations (AVMs) and Related Lesions (HD 12.2)** in the Head Imaging Guidelines
- See **Arteriovenous Malformations (AVMs) and Fistulas (PEDPVD-2.5)** in the Pediatric Peripheral Vascular Disease Imaging Guidelines
- See **Pelvic Pain/Dyspareunia, Female (PV-11.1)** in the Pelvis Imaging Guidelines

Initial imaging

- Ultrasound with Doppler is indicated as an initial examination for superficial lesions in the limbs.
 - Large lesion characterization may be limited by ultrasound imaging window.
 - Ultrasound is also limited in evaluating AVM relationship to airway or bony structures.

Evaluation and surveillance

- MRI without contrast or without and with contrast of the affected body part is the study of choice for abdominal AVMs and deep tissue (below the skin) AVM's in the limbs.
- MRA (contrast as requested) of the affected body part can be approved for evaluation and surveillance of known AVMs.
- It is unusual for both MRI and MRA to be necessary for routine treatment response or surveillance imaging of AVMs, but both may be approved for preoperative planning.
- CT and CTA can also be used to characterize AVMs and their relationship to normal structures but is generally not better than MRI and has associated radiation risks.
 - CT with contrast and/or CTA (contrast as requested) of the affected body part can be approved when MRI and/or MRA is inconclusive or contraindicated.

Post-embolization

- Advanced imaging can be approved one-time post-embolization to evaluate for successful resolution of the AVM.
- Additional imaging (same study performed pre-procedure or as requested by the treating provider) can be approved for treatment planning purposes if resolution of the AVM was not achieved.

Background and Supporting Information

Arteriovenous malformations are characterized by a network of multiple abnormal vascular channels interposed between enlarged feeding arteries and draining veins. The arteriovenous fistula has a single communication interposed between a feeding artery and a draining vein. The normal capillary bed is absent in both lesions. Both lesions may have an aggressive clinical course and are characterized by a reddish pulsatile mass which has a thrill or bruit. Though often recognized at birth, these lesions may grow and present near adolescence.

References

1. Pizzo PA, Poplack DG, Krishnamurthy R, Daldrup-Link HE, Jones JY, et. al. Imaging studies in the diagnosis and management of pediatric malignancies. In: Principles and Practice of Pediatric Oncology. Vol 7. Philadelphia: Wolters Kluwer; 2016:185-234.
2. Martin KL. Vascular disorders. *Nelson Textbook of Pediatrics*, Chapter 669. eds Kliegman R, St. Geme JW III, Blum NJ, et al. 21st ed. Philadelphia, PA: Elsevier; 2020:3461-3469.
3. Blei F, Guarini A. Current workup and therapy of infantile hemangiomas. *Clinics in Dermatology*. 2014;32(4):459-470. doi:10.1016/j.clindermatol.2014.02.001.
4. Cahill AM, Nijs ELF. Pediatric Vascular Malformations: Pathophysiology, Diagnosis, and the Role of Interventional Radiology. *CardioVascular and Interventional Radiology*. 2011;34(4):691-704. doi:10.1007/s00270-011-0123-0.
5. Bagrodia N, Defnet AM, Kandel JJ. Management of lymphatic malformations in children. *Current Opinion in Pediatrics*. 2015;27(3):356-363. doi:10.1097/mop.000000000000209.
6. Wassef M, Blei F, Adams D, et al. Vascular Anomalies Classification: Recommendations from the International Society for the Study of Vascular Anomalies. *Pediatrics*. 2015;136(1):e203-e214. doi:10.1542/peds.2014-3673.
7. Kutz AM, Aranibar L, Lobos N, Wortsman X. Color Doppler Ultrasound Follow-Up of Infantile Hemangiomas and Peripheral Vascularity in Patients Treated with Propranolol. *Pediatric Dermatology*. 2015;32(4):468-475. doi:10.1111/pde.12596.
8. Adams DM, Trenor CC, Hammill AM, et al. Efficacy and Safety of Sirolimus in the Treatment of Complicated Vascular Anomalies. *Pediatrics*. 2016;137(2). doi:10.1542/peds.2015-3257.
9. Snyder E, Puttgen K, Mitchell S, Ahlawat S, Tekes A. Magnetic Resonance Imaging of the Soft Tissue Vascular Anomalies in Torso and Extremities in Children: An Update with 2014 International Society for the Study of Vascular Anomalies Classification. *Journal of Computer Assisted Tomography*. 2017;42(2):167-177. doi:10.1097/rct.0000000000000675.
10. Merrow AC, Gupta A, Patel MN, Adams DM. 2014 Revised Classification of Vascular Lesions from the International Society for the Study of Vascular Anomalies: Radiologic-Pathologic Update. *RadioGraphics*. 2016;36(5):1494-1516. doi:10.1148/rg.2016150197.
11. Johnson CM, Navarro OM. Clinical and sonographic features of pediatric soft-tissue vascular anomalies part 1: classification, sonographic approach and vascular tumors. *Pediatric Radiology*. 2017;47(9):1184-1195. doi:10.1007/s00247-017-3885-y.
12. Johnson CM, Navarro OM. Clinical and sonographic features of pediatric soft-tissue vascular anomalies part 2: vascular malformations. *Pediatric Radiology*. 2017;47(9):1196-1208. doi:10.1007/s00247-017-3906-x.
13. Sadick M, Müller-Wille R, Wildgruber M, Wohlgemuth W. Vascular Anomalies (Part I): Classification and Diagnostics of Vascular Anomalies. *RöFo - Fortschritte auf dem Gebiet der Röntgenstrahlen und der bildgebenden Verfahren*. 2018;190(09):825-835. doi:10.1055/a-0620-8925.
14. Olivieri B, White CL, Restrepo R, et. al. Low-Flow Vascular Malformation Pitfalls: From Clinical Examination to Practical Imaging Evaluation—Part 2, Venous Malformation Mimickers. *American Journal of Roentgenology*. 2016;206(5):952-962. doi:10.2214/ajr.15.15794.
15. White CL, Olivieri B, Restrepo R, et.al. Low-Flow Vascular Malformation Pitfalls: From Clinical Examination to Practical Imaging Evaluation—Part 1, Lymphatic Malformation Mimickers. *American Journal of Roentgenology*. 2016;206(5):940-951. doi:10.2214/ajr.15.15793.

Venous Imaging

Guideline

Venous Imaging General Information (PVD-11)

Upper Extremity Venous – Imaging (PVD-4.2)

Acute Limb Swelling (PVD-12)

Chronic limb swelling due to chronic deep venous thrombosis (DVT)/

May-Thurner syndrome (PVD-13)

Chronic limb swelling due to venous insufficiency/Venous stasis changes/

Varicose veins (PVD-14)

Imaging for Hemodialysis Access (PVD-8)

IVC filters – Treatment (PVD-16.2)

Post iliac vein stenting/angioplasty (PVD-17.1)

Venous Imaging General Information (PVD-11)

PVD.VI.0011.A

v1.0.2024

Guideline

Abbreviations and glossary (PVD-11.1)

Venous imaging - General guidelines (PVD-11.2)

Procedure Coding (PVD-11.3)

References

Abbreviations and glossary (PVD-11.1)

Abbreviation	Definition
CTV	Computed Tomography Venography
DVT	Deep Venous Thrombosis
EVA	Endovenous ablation – a minimally invasive procedure using heat to obliterate the saphenous vein for the treatment of venous reflux
IVC	Inferior vena cava
May-Thurner’s	Syndrome of compression of the left iliac vein via an overlying right common iliac artery. The pulsations of the artery into the vein against the 5 th lumbar vertebrae can predispose to DVT
MRV	Magnetic Resonance Venography
Phlebectomy	Removal of a vein usually through a small incision
Post-thrombotic syndrome	Constellation of symptoms including chronic edema and pain that develops after a DVT
Sclerotherapy	Injection of an irritant into a vein to obliterate it
SEPS	Sub-fascial endoscopic perforator surgery
SVT	Superficial venous thrombosis
VVI	Venous Valvular Insufficiency – a study utilizing ultrasound to assess for the presence of reflux within the superficial and deep veins of the lower extremity.

Venous imaging - General guidelines (PVD-11.2)

- A current clinical evaluation (within 60 days), including medical treatments, are required prior to considering advanced imaging, which includes:
 - Relevant history and physical examination including:
 - The affected limb(s), the extent of the edema (calf and/or thigh), pitting or non-pitting. With regard to venous insufficiency, presence or absence of

- hyperpigmentation or other skin changes, ulcerations if applicable, size of varicosities if present as well as distribution
- Arterial examination to rule out phlegmasia alba/cerulea dolens which is comprised arterial flow secondary to extensive DVT if applicable
- Appropriate laboratory studies, for example d-dimer, if applicable
- Non-advanced imaging modalities, such as a venous duplex or venous valvular insufficiency study (VVI) after symptoms started or worsened
- Other meaningful contact (telephone call, electronic mail or messaging) by an established patient can substitute for a face-to-face clinical evaluation.
- **General Guidelines-Imaging (PVD-11.4)**
 - Venous duplex (CPT® 93970, CPT® 93971) of the limb is the initial imaging of choice
 - Follow-up duplex imaging (CPT® 93970, CPT® 93971) is not generally indicated to document resolution and should only be obtained for new signs/symptoms or for concerns of propagation of thrombus when the treatment plan would change (Insertion of IVC filter, change of anticoagulation, etc.)
 - Imaging studies
 - Venous duplex (CPT® 93970, CPT® 93971) should visualize the veins, with demonstration of the presence or absence of compressibility and venous flow.
 - Venous valvular insufficiency studies (CPT® 93970, CPT® 93971) visualize the veins of the lower extremity, assess for reflux (reversal of venous antegrade flow after valve closure) and measure its duration.
 - CTV or MRV Abdomen and Pelvis (CPT® 74174) or (CPT® 74185 and 72198) images with contrast involves taking images from the diaphragm to just below the inguinal ligament after a delay of a few minutes after IV contrast is administered to optimize filling and therefore visualization of the venous vasculature

Background and Supporting Information

Venous disease can be classified into three categories:

- **Veno-occlusive disease**
 - Types of thrombotic disease
 - Superficial venous thrombosis
 - Deep venous thrombosis
 - Iliac vein obstruction, unilateral or bilateral
 - May-Thurner's syndrome
 - Signs/Symptoms of veno-occlusive disease is generally sudden onset of pain and edema in the limb.

- Risk factors include age >40, obesity, pregnancy, prolonged immobility, post-surgery, and malignancy among others.
- Procedures related to veno-occlusive disease include:
 - Thrombolysis
 - Thrombectomy
 - Post-iliac vein stent/angioplasty
- **Venous insufficiency**
 - Types of venous insufficiency:
 - Superficial and deep venous reflux
 - Varicose veins
 - Reticular and spider veins.
 - Signs/symptoms of venous insufficiency include:
 - Chronic swelling in the leg that is relieved with elevation
 - Chronic swelling in the leg that is worse in the evenings
 - Aching or sense of heaviness in the leg
 - Hyperpigmentation of the calf particularly around the ankle
 - Itchy skin on legs and feet
 - Leather appearance of the skin of the calves
 - Skin ulcers in the calf particularly around the medial malleolus
 - Varicose veins
 - Spider veins/reticular veins/telangiectasias
 - Procedures related to the venous insufficiency include:
 - Endovenous laser ablation utilizing either chemical, laser or radio-frequency
 - Saphenous vein high ligation and stripping
 - Phlebectomy, stab or powered
 - Sclerotherapy, liquid or foam
- **Venous malformations**
 - Types of venous malformations include:
 - Arterio-venous malformations which can occur throughout the body
 - See **Pulmonary AVM (CH-24)** in the Chest imaging guidelines
 - See **Aneurysm and AVM (HD-12)** in the Head imaging guidelines
 - See **Pelvic Pain/Dyspareunia, Female (PV-11)** in the Pelvic imaging guidelines
 - Klippel-Trenaunay which affects primarily the lower extremity venous circulation and is characterized by varicose veins, limb size discrepancies, and port-wine stains.
 - Treatment includes:
 - Primarily embolization
 - Sclerotherapy

- Klippel-Trenaunay: treatment can include phlebectomy and sclerotherapy of symptomatic varicose veins provided they meet the criteria for intervention.

Procedure Coding (PVD-11.3)

Venous Studies – Extremities	CPT®
CTV Abdomen and Pelvis involves obtaining images from the diaphragm to just below the inguinal ligament after a delay of a few minutes after IV contrast is administered to optimize filling and therefore visualization of the venous vasculature.	74174
CTV Pelvis involves obtaining images from the top of the pelvic brim to the upper thighs or just below the inguinal ligament. The venogram portion is performed by obtaining images after a delay of a few minutes after IV contrast is administered to optimize filling and therefore visualization of the venous vasculature.	72191
MRV Abdomen and Pelvis involves taking images from the diaphragm to just below the inguinal ligament after a delay of a few minutes after IV contrast is administered to optimize filling and therefore visualization of the venous vasculature.	74185 and 72198
MRV Pelvis involves obtaining images from the top of the pelvic brim to the upper thighs or just below the inguinal ligament. The venogram portion is performed by obtaining images after a delay of a few minutes after IV contrast is administered to optimize filling and therefore visualization of the venous vasculature.	72198
Duplex scan of extremity veins, including responses to compression and other maneuvers; complete bilateral study.	93970
Duplex scan of extremity veins, including responses to compression and other maneuvers; unilateral or limited study.	93971
<ul style="list-style-type: none"> • These codes are used to report studies of lower or upper extremity veins. • A complete bilateral study of the lower extremity veins includes examination of the external iliac veins, common femoral, proximal deep femoral, great saphenous and popliteal veins. Calf veins may also be included. • A complete bilateral study of upper extremity veins includes examination of the subclavian, jugular, axillary, brachial, basilic, and cephalic veins. Forearm veins may also be included. 	
Duplex scan of aorta, inferior vena cava, iliac vasculature, or bypass grafts; complete study	93978
Duplex scan of extremity veins, including responses to compression and other maneuvers; unilateral or limited study.	93979

References

1. Ageno W, Haas S, Weitz JI, et al. Characteristics and Management of Patients with Venous Thromboembolism: The GARFIELD-VTE Registry. *Thromb Haemost.* 2019;119(2):319-327. doi:10.1055/s-0038-1676611.
2. Jones WS, Vemulapalli S, Parikh KS et al. Treatment Strategies for Patients with Lower Extremity Chronic Venous Disease (LECV). Agency for Healthcare Research and Quality (US); 2017 Apr.
3. Gloviczki P, Comerota AJ, Dalsing MD, et al. The care of patients with varicose veins and associated chronic venous diseases: Clinical practice guidelines of the Society for Vascular Surgery and the American Venous Forum. *J Vasc Surg.* 2011. 53(16S):1-47. doi:10.1016/j.jvs.2011.01.079.
4. Wolpert L, Rahmani O, Stein B, et al. Magnetic Resonance Venography in the Diagnosis and Management of May-Thurner syndrome. *Vasc Endovascular Surg.* 2002 Jan-Feb;36(1):51-7. doi:10.1177/153857440203600109.

Upper Extremity Venous – Imaging (PVD-4.2)

PVD.AI.0004.1.A

v1.0.2024

- For symptoms of venous insufficiency including but not limited to unilateral pain and swelling of the upper extremity
 - Venous duplex upper extremities (CPT® 93970 or CPT® 93971) should be performed initially
 - If duplex ultrasound is non-diagnostic:
 - MRV Upper extremity (CPT® 73225) and/or MRV Chest (CPT® 71555), or
 - CTV Upper extremity (CPT® 73206) and/or CTV Chest (CPT® 71275)
 - CTV Upper extremity (CPT® 73206) or MRV Upper extremity (CPT® 73225), and/or CTV Chest (CPT® 71275) or MRV Chest (CPT® 71555) can be performed if there is a history of exertion with the limb such as with weight lifting or in the presence of central venous access (port, PICC line, to name a few) with a negative venous duplex. See **Thoracic Outlet Syndrome (CH-31.1)** in the Chest Imaging Guidelines.
- For Superior Vena Cava Syndrome (upper extremity and facial symptoms) **one** of the following can be approved when stenting of the SVC is being considered:
 - CT Chest with contrast (CPT® 71260)
 - MRV Chest (CPT® 71555)
 - CTV Chest (CPT® 71275)

References (PVD-4)

1. Skeik N, Soo-Hoo SS, Porten BR, et al. Arterial Embolisms and Thrombosis in Upper Extremity Ischemia. *Vascular and Endovascular Surgery*. 2015;49(5-6):100-109. doi:10.1177/1538574415596740.
2. Desjardins B, Rybicki FJ, Kim HS, et al. ACR Appropriateness Criteria® Suspected Upper Extremity Deep Vein Thrombosis. *J Am Coll Radiol* 2012;9(9):613-619. doi:10.1016/j.jacr.2012.05.021.
3. Kraaijpoel N, Es NV, Porreca E, Büller HR, Nisio MD. The diagnostic management of upper extremity deep vein thrombosis: A review of the literature. *Thrombosis Research*. 2017;156:54-59. doi:10.1016/j.thromres.2017.05.035.
4. Hughes K, Cubangbang M, Blackman K, et al. Upper Extremity Bypass for Chronic Ischemia—A National Surgical Quality Improvement Program Study Database Study. *Vascular and Endovascular Surgery*. 2013;47(3):192-194. doi:10.1177/1538574413478472.

Acute Limb Swelling (PVD-12)

PVD.VI.0012.A

v1.0.2024

Guideline

- Superficial venous thrombosis (SVT) (PVD-12.1)
 - Acute deep venous thrombosis (DVT) (PVD-12.2)
 - Follow-up imaging of known DVT (PVD-12.3)
 - Follow-up imaging after venous surgery (PVD-12.4)
 - Generalized bilateral lower extremity edema (PVD-12.5)
- ## References

Superficial venous thrombosis (SVT) (PVD-12.1)

- The diagnosis of superficial venous thrombosis is generally made on the basis of physical examination.
 - Duplex ultrasound (CPT® 93970, CPT® 93971) is the initial imaging if the diagnosis is equivocal
 - Follow-up duplex ultrasound (CPT® 93970, CPT® 93971) is indicated only if thrombus in the superficial systems is encroaching onto the deep venous system (saphenofemoral or saphenopopliteal junction)

Background and Supporting Information

Superficial venous thrombosis (SVT) refers to acute or chronic thrombosis of the superficial veins in both the upper (cephalic and basilic veins) and lower extremities (greater [great] saphenous vein, lesser [small] saphenous vein, gastrocnemius and soleal veins). Treatment: Elevation and warm compresses until pain and swelling subsides.

Acute deep venous thrombosis (DVT) (PVD-12.2)

- Duplex ultrasound (CPT® 93970 bilateral study or CPT® 93971 unilateral study) is the initial imaging study for any suspected DVT
 - Deep venous thrombosis can present as
 - Symptomatic
 - Swelling
 - Pain
 - Warmth
 - Erythema
 - Pain with dorsiflexion of the foot (Homan's Sign)
 - Or with progression, such as phlegmasia cerulean dolens
 - Risk factors for DVT include age >40, obesity, malignancy, prolonged immobilization, hypercoagulability as well as those outlined in **Pulmonary Embolism (PE) (CH-25)** in Chest Imaging Guidelines.

- CTA/CTV Abdomen and pelvis with contrast can be performed to rule out IVC thrombus secondary to the filter when there is acute bilateral lower extremity swelling in an individual with a history of an IVC filter in place.
- When there is concern for proximal DVT (iliofemoral):
 - Focused abdominal duplex can generally visualize the iliac veins and IVC to determine the absence or presence of iliac vein thrombus in an individual. If the results are equivocal or indeterminate:
 - CTV or MRV Abdomen and Pelvis with contrast (CPT® 74174 or CPT® 74185 and CPT® 73725) can be performed.
- For request concerning abdominal vein thrombosis, see **Abdominal Veins other than Hepatic and Portal Veins (AB-43.2)** in the Abdomen Imaging Guidelines
- For proximal DVT's (iliac vein DVT's or in cases of phlegmasia (extensive DVT compromising arterial inflow), thrombectomy (rarely performed) or thrombolysis can be performed.
- If the cause of the DVT is found to be due to May-Thurner, iliac vein angioplasty followed by stenting of the left iliac vein is generally performed. See **May-Thurner Syndrome (PVD-13.3)**

Background and Supporting Information

Deep venous thrombosis is characterized by thrombosis of a deep vein in either the upper (brachial, axillary, subclavian veins) or the lower extremity (peroneal, posterior tibial, popliteal, femoral or iliac veins).

Follow-up imaging of known DVT (PVD-12.3)

- Duplex ultrasound (CPT® 93970 bilateral study or CPT® 93971 unilateral study) can be repeated in order to rule out proximal extension of a calf vein DVT in those individuals who cannot be anticoagulated, most commonly after recent surgery. Time interval for follow-up study includes:
 - One week after the initial diagnosis.
 - Serial imaging (up to 3 studies) over the first three weeks if calf DVT is not treated.
- Imaging during or to terminate long-term anticoagulation therapy to determine venous recanalization is not supported by evidence. Repeat imaging to make decisions on whether or not to continue or terminate anticoagulation is not indicated.

Follow-up imaging after venous surgery (PVD-12.4)

- Venous duplex (CPT® 93971 unilateral study) of the treated limb is indicated to rule out a DVT within seven days of endovenous ablation.
- Follow-up routine imaging is **not indicated** after other venous procedures including:
 - Saphenous vein ligation and stripping
 - Phlebectomy
 - Sclerotherapy

Generalized bilateral lower extremity edema (PVD-12.5)

Bilateral lower extremity edema is multifactorial. Prior to any request for advanced imaging, a workup for causes of the edema should be instituted including echocardiogram to rule out congestive heart failure and laboratory studies to exclude renal insufficiency and liver disease. The following imaging is indicated based on the suspected cause of the edema:

- Suspected abdominal or pelvic pathology
 - Abdominal ultrasound or duplex is the initial imaging
 - CT Abdomen and Pelvis or CT pelvis either with or without contrast can be performed if abdominal US is equivocal or indeterminate
- Suspected chronic venous insufficiency
 - A venous duplex CPT[®] 93970 (bilateral) or CPT[®] 93971 (unilateral) is indicated to evaluate for venous reflux.
- Suspected lymphedema
 - When initial noninvasive studies, such as ultrasound, are negative for venous valvular insufficiency **either** of the following advanced imaging studies is indicated:
 - Lymphoscintigraphy (CPT[®] 78195)
 - MRI lymphangiography (CPT[®] 73718)

References

1. Lim W, Gal GL, Bates SM, et al. American Society of Hematology 2018 guidelines for management of venous thromboembolism: diagnosis of venous thromboembolism. *Blood Advances*. 2018;2(22):3226-3256. doi:10.1182/bloodadvances.2018024828.
2. American College of Phlebology. Treatment of Superficial Venous Disease of the Lower Leg Guidelines. American Vein & Lymphatic Society. <http://www.phlebology.org/member-resources/publications/treatment-superficial-venous-disease-lower-leg-guidelines>. Published 2016.
3. American College of Phlebology. Duplex Ultrasound Imaging of Lower Extremity Veins in Chronic Venous Disease. American Vein & Lymphatic Society. <http://www.phlebology.org/member-resources/publications/duplex-ultrasound-imaging-lower-extremity-veins-chronic-venous-disease>. Published 2012.
4. Healy DA, Kimura S, Power D, et al. A Systematic Review and Meta-analysis of Thrombotic Events Following Endovenous Thermal Ablation of the Great Saphenous Vein. *European Journal of Vascular and Endovascular Surgery*. 2018;56(3):410-424. doi:10.1016/j.ejvs.2018.05.008.
5. Jacobs CE, Pinzon MM, Orozco J, et al. Deep Venous Thrombosis after Saphenous Endovenous Radiofrequency Ablation: Is it Predictable? *Annals of Vascular Surgery*. 2014;28(3):679-685. doi:10.1016/j.avsg.2013.08.012.
6. Liu N, Wang C, Sun M. Noncontrast three-dimensional magnetic resonance imaging vs lymphoscintigraphy in the evaluation of lymph circulation disorders: A comparative study. *J Vasc Surg*. 2005;41(1):69-75. doi:10.1016/j.jvs.2004.11.013.

Chronic limb swelling due to chronic deep venous thrombosis (DVT)/May-Thurner syndrome (PVD-13)

PVD.VI.0013.A

v1.0.2024

Guideline

Chronic DVT with incompletely lysed or residual DVT (PVD-13.1)

Post-thrombotic syndrome (PVD-13.2)

May-Thurner syndrome (PVD-13.3)

Pelvic congestion syndrome (PVD-13.4)

References

Chronic DVT with incompletely lysed or residual DVT (PVD-13.1)

Individuals with incompletely lysed or residual DVT can develop post-thrombotic syndrome that can be characterized as chronic edema, venous stasis changes, pain and in advanced cases venous stasis ulceration.

- Imaging is indicated to evaluate for iliac venous obstruction from incompletely lysed thrombus in individuals with a history of proximal (iliofemoral) DVT who have developed post thrombotic syndrome.
 - Initial imaging is duplex (CPT® 93970 bilateral study or CPT® 93971 unilateral study)
 - Either a CTV or MRV Abdomen and Pelvis (CPT® 74174) or (CPT® 74185 and 72198) OR CTV Pelvis (CPT® 72191) or MRV Pelvis (CPT® 72198), or venography for treatment planning purposes.
- Imaging for post-thrombotic syndrome is only indicated for **either**:
 - Signs and symptoms suggestive of a new acute DVT
 - Preoperative planning for iliac vein/stenting for suspected iliac vein stenosis or occlusion

Background and Supporting Information

- Chronic deep venous thrombosis is defined as an acute DVT that is greater than 14 days old.
- Incompletely lysed DVT can cause luminal narrowing of the vein restricting venous outflow leading to stenosis or occlusion and /or can lead to valve dysfunction resulting in reflux of venous blood retrograde towards gravity. Both pathologies ultimately lead to chronic edema which can cause chronic pain and venous stasis disease.
 - The mainstay of treatment for chronic deep venous thrombosis is compression stockings

- Selected individuals may be a candidate for iliac vein angioplasty/stenting.

Post-thrombotic syndrome (PVD-13.2)

- Imaging for post-thrombotic syndrome is indicated when:
 - There are signs and symptoms suggestive of a new acute DVT
 - For preoperative planning for iliac vein/stenting in the setting of known iliac venous obstruction in those with a history of a proximal (iliofemoral) DVT.
- Imaging for post-thrombotic syndrome is NOT indicated for chronic swelling that has not changed in severity or character

May-Thurner syndrome (PVD-13.3)

- CTV or MRV Abdomen and Pelvis (CPT[®] 74174, or 74185 and 72198) OR CTV Pelvis or MRV Pelvis (CPT[®] 72191 or 72198) can be approved in individuals with a history of **one** of the following:
 - Left lower extremity iliac DVT
 - Persistent left lower extremity edema OR varicose veins OR venous stasis ulcer despite treatment of superficial venous disease in that extremity
 - Persistent left lower extremity edema OR varicose vein OR venous stasis ulcer in the absence of saphenous vein reflux.
- Imaging and/or prophylactic treatment of May-Thurner syndrome, in the absence of acute or chronic DVT **OR** chronic left lower extremity edema and its sequelae such as varicose veins or venous stasis ulcers, is **NOT** considered medically necessary

Background and Supporting Information

In approximately 25% of people, the right iliac artery overlies the left iliac vein over the fifth lumbar vertebrae and its pulsations can compress the vein increasing the risk of DVT in the left extremity.

- Treatment is with iliac vein angioplasty/stenting

Pelvic congestion syndrome (PVD-13.4)

- Signs and symptoms of pelvic congestion syndrome include:
 - Chronic pelvic pain OR post-coital discomfort >6 months.
 - Associated symptoms can include the presence of labial varicosities OR heavy menstrual periods.
- Initial imaging is via transvaginal or pelvic ultrasound to exclude other pathologies of chronic pelvic pain
- CT Venogram of the abdomen/pelvis or MRA of the abdomen/pelvis is indicated if initial ultrasound is inconclusive or non-diagnostic.

References

1. Eberhardt RT and Raffetto JD. Chronic Venous Insufficiency. *Circulation*. 2005; 111: 2398-2409.
2. Partsch H, Flour M, Smith PC, et al. Indications for compression therapy in venous and lymphatic disease. Consensus based on experimental data and scientific evidence. *Int Angiol*. 2008;27:193-219.
3. Nayak L, Vedantham S. Multifaceted Management of the Postthrombotic Syndrome. *Seminars in Interventional Radiology*. 2012: 29:1.

4. Christof T, Kaltenmeier, Erben Y, et al. Systematic review of May-Thurner syndrome with emphasis on gender differences. *J Vasc Surg Venous Lymphat Disord*. 2018;6(3):399-407.
5. Rossi FH, Kambara AM, Izukawa NM, et al. Randomized double-blinded study comparing medical treatment versus iliac vein stenting in chronic venous disease. *J Vasc Surg Venous Lymphat Disord*. 2018;6(2):183-191.
6. Sermathanasawadi N, Pruekprasert K, Pitaksantayothin W, et al. Prevalence, risk factors, and evaluation of ilio caval obstruction in advanced chronic venous insufficiency. *J Vasc Surg Venous Lymphat Disord*. 2019 May;7(3):441-447.
7. Vedantham S, Kahn SR, Goldhaber SZ, Comerota AJ, et al. Endovascular therapy for advanced post-thrombotic syndrome: Proceedings from a multidisciplinary consensus panel. *Vasc Med*. 2016 Aug;21(4):400-7.
8. O'Brian M and Gillespie B. Diagnosis and treatment of the pelvic congestion syndrome. *Journal of Vascular Surgery. Venos and Lymphatic Disorders*. 2015. 3(1):96-106.
9. Brown CL, Rizer M et al. Pelvic Congestion Syndrome: Systematic Review of Treatment Success. *Semin Intervent Radiol*. 2018 Mar;35(1):35-40.

Chronic limb swelling due to venous insufficiency/Venous stasis changes/Varicose veins (PVD-14)

PVD.VI.0014.A

v1.0.2024

Guideline

Venous Reflux (PVD-14.2)

References

Venous Reflux (PVD-14.2)

- Diagnosis is made with a venous valvular insufficiency study (CPT® 93970 bilateral study or CPT® 93971 unilateral study) which documents the presence of reflux (>500ms) in the greater saphenous vein as well as the size of the refluxing vein (3-15mm).
- Treatment of superficial venous reflux is amenable to intervention in selected individuals who are symptomatic and have failed conservative therapy. A duplex ultrasound (CPT® 93970 bilateral study or CPT® 93971 unilateral study) demonstrating the presence of pathologic reflux within the greater and lesser saphenous veins should be undertaken within the last six months. Vein size should be documented.
- A post-ablation venous ultrasound (CPT® 93970 bilateral study or CPT® 93971 unilateral study) is indicated within seven days post-procedure. If thrombus is noted within the saphenofemoral junction, repeat imaging can be performed within seven days to assess for propagation into the deep system.
- Ultrasound mapping or monitoring techniques are considered medically necessary only to initially determine the extent and configuration of symptomatic varicosities or valvular insufficiency. Post-procedure assessment by imaging techniques is inappropriate to confirm efficacy or outcome of the procedure.

Background and Supporting Information

Venous insufficiency — General information

- Venous insufficiency is characterized by failure of the venous blood to flow in its normal antegrade path of flow and instead reflux backwards by the force of gravity usually secondary to malfunction of the venous valves.
- Risk factors include previous DVT, obesity, female sex assigned at birth, hereditary, and environmental factors such as prolonged standing on a hard surface.
- Venous insufficiency loosely includes the diagnosis of venous reflux, varicose veins, venous stasis ulcers and spider/reticular veins.

Venous reflux

- Symptoms of venous reflux include chronic edema, pain, and venous stasis ulcerations. Symptoms of venous reflux can be ameliorated with compression therapy with graded compression stockings, elevation, avoidance of prolonged standing and weight loss. Venous reflux can be seen in both the deep and superficial venous systems. Reflux within the deep system is not amenable to intervention.
- Treatment of deep venous reflux is via active compression with compression stocks, pneumatic pumps or specialized dressings such as Unna boots.
- Treatment of symptomatic superficial venous reflux is via endovenous laser radiofrequency ablation of the greater or lesser saphenous vein resulting in closure of the vein allowing for venous blood to be rerouted to the deep venous system.
- Treatment of symptomatic superficial venous reflux can also be treated via saphenous vein ligation and stripping which has fallen out of favor but can be performed for a tortuous or enlarged (>15mm) greater or lesser saphenous vein. One complication of endovenous ablation is deep venous thrombosis.

Varicose Veins

- If the varicosities remain symptomatic despite conservative therapy, varicose veins are treated with sclerotherapy or phlebectomy generally on the basis of size.
- Varicose veins are defined as enlarged, tortuous veins visible under the skin. Symptoms associated with varicose veins include aching and heaviness of the legs and pain/discomfort over the varicosities. Varicose veins can exist both in the absence and presence of venous reflux.
- Treatment involves conservative therapy such as compression stockings, avoidance of prolonged standing, intermittent elevation, weight loss (if applicable) and exercise which relieves the distention of the varicose veins ameliorating the symptoms.

Spider veins/reticular veins

- Spider veins are formed by the dilation of a cluster of blood vessels within the dermis – generally <3mm in diameter. Diagnosis is via physical examination. Spider veins are usually asymptomatic but can cause aching, burning and tenderness in the area overlying the abnormal veins. Spider veins can exist in the absence or presence of venous reflux. The presence of spider veins should not be an indication for treatment of venous reflux.
- Treatment of spider veins is generally cosmetic except in certain cases and can be treated with sclerotherapy.

References

1. Gloviczki P, Comerota AJ, Dalsing MC, et al. The care of patients with varicose veins and associated chronic venous diseases: clinical practice guidelines of the Society for Vascular Surgery and the American Venous Forum. *J Vasc Surg*. 2011;53(5 Suppl):2S-48S. doi:10.1016/j.jvs.2011.01.079.
2. Wittens C, Davies A, Bækgaard N, et al. Editor's Choice – Management of Chronic Venous Disease. *Eur J Vasc Endovasc Surg*. 2015;49(6):678-737. doi:10.1016/j.ejvs.2015.02.007.
3. Piazza G. Varicose veins. *Circulation*. 2014;130(7):582-587. doi:10.1161/CIRCULATIONAHA.113.008331.
4. Jones WS, Vemulapalli S, Parikh KS, et al. Treatment Strategies for Patients with Lower Extremity Chronic Venous Disease (LECVD). Technology Assessment Program. Project ID: DVTT0515. (Prepared by the Duke University Evidence-based Practice Center under Contract No. 290-2015-00004-I). Rockville, MD: Agency for Healthcare Research and Quality; April 2017.

5. National Institute for Health and Care Excellence (NICE). Varicose veins in the legs: the diagnosis and management of varicose veins. NICE Clinical Guideline: Methods, evidence and recommendations. London: National Institute for Health and Care Excellence (UK). July, 2013.
6. Kahn SR, M'lan CE, Lamping DL, et al. Relationship between clinical classification of chronic venous disease and patient-reported quality of life: results from an international cohort study. *J Vasc Surg*. 2004;39(4):823-828. doi:10.1016/j.jvs.2003.12.007.
7. Khilnani NM. Duplex ultrasound evaluation of patients with chronic venous disease of the lower extremities. *AJR Am J Roentgenol*. 2014;202(3):633-642. doi:10.2214/AJR.13.11465.
8. King T, Coulomb G, Goldman A, et al. Experience with concomitant ultrasound guided foam sclerotherapy and endovenous laser treatment in chronic venous disorder and its influence on Health Related Quality of Life: interim analysis of more than 1000 consecutive procedures. *International Angiology*. 2009;28 (4):289 -297.
9. Lurie F, Kistner RL. Trends in patient reported outcomes of conservative and surgical treatment of primary chronic venous disease contradict current practices. *Annals of Surgery*. 2011 Aug;254(2):363-367. DOI: 10.1097/sla.0b013e31821d4a5f.
10. Meissner MH, Moneta G, Burnand K, et al. The hemodynamics and diagnosis of venous disease. *J Vasc Surg*. 2007;46 Suppl S:4S-24S. doi:10.1016/j.jvs.2007.09.043.
11. Smith JJ, Garratt AM, Guest M, Greenhalgh RM, Davies AH. Evaluating and improving health-related quality of life in patients with varicose veins. *J Vasc Surg*. 1999;30(4):710-719. doi:10.1016/s0741-5214(99)70110-2.

Imaging for Hemodialysis Access (PVD-8)

PVD.AI.0008.0.A

v1.0.2024

Guideline

Arterial Evaluation and Venous Mapping Prior to AV Fistula (PVD-8.1)

Hemodialysis access imaging (PVD-8.2)

References (PVD-8)

Arterial Evaluation and Venous Mapping Prior to AV Fistula (PVD-8.1)

- Imaging prior to AV fistula creation:
 - For vessel mapping CPT® 93985 or 93986
 - MRA Upper Extremity (CPT® 73225) may be needed if duplex imaging is equivocal
- Arterial evaluation to assess arterial suitability (size, degree of stenosis and calcification) prior to AV fistula creation may be indicated
 - CPT® 93930 or CPT® 93931 can be used to report upper extremity arterial evaluation
- Venous mapping (CPT® 93970 or CPT® 93971) to assess venous suitability prior to AV fistula creation may be indicated

Hemodialysis access imaging (PVD-8.2)

- Indications for Duplex ultrasound (CPT® 93990) of hemodialysis access include but are not limited to:
 - Individuals with decreased flow rates during hemodialysis.
 - Development of arm swelling or discomfort after access placement surgery or a hemodialysis session.
 - Prolonged immaturity of a surgically created AV fistula.
 - Suspected pseudoaneurysm.
 - Suspected AV fistula or graft stenosis.
 - Known or suspected fluid collection adjacent to an AV fistula or graft.
 - One Duplex US (CPT® 93990) can be performed after a surgically created AV fistula for assessment, although it is not generally needed.
- Central venous stenosis can cause new dialysis access to fail to mature or cause the premature failure of existing fistulas/grafts.
- CT Chest with contrast (CPT® 71260), or CTA Chest (CPT® 71275), or MRA Chest (CPT® 71555) is indicated when there is documentation of either:
 - Signs and symptoms of central venous stenosis including:
 - Arm swelling
 - Presence of numerous collateral veins

- Prolonged bleeding from dialysis puncture sites
- A history of pacemaker placement or previous tunneled dialysis graft, regardless of signs and symptoms.

References (PVD-8)

1. Sidawy AN, Spergel LM, Besarab A, et al. The Society for Vascular Surgery: Clinical practice guidelines for the surgical placement and maintenance of arteriovenous hemodialysis access. *J Vasc Surg.* 2008;48(5). doi:10.1016/j.jvs.2008.08.042.
2. Schmidli J, Widmer MK, Basile C, et al. Editor's Choice – Vascular Access: 2018 Clinical Practice Guidelines of the European Society for Vascular Surgery (ESVS). *Eur J Vasc Endovasc Surg.* 2018;55(6):757-818. doi:10.1016/j.ejvs.2018.02.001
3. Kundu S. Central venous disease in hemodialysis patients: prevalence, etiology and treatment. *Journal of Vascular Access.* 2010;11(1):1-7.

IVC filters – Treatment (PVD-16.2)

PVD.VI.0016.A

v1.0.2024

- IVC filter insertion
 - An initial venous duplex can be performed to assess for the presence of thrombus in the femoral vein which would affect the approach (transjugular or transfemoral)
 - Advanced imaging is not indicated
- CT Abdomen and Pelvis with contrast CPT® 74177 for ANY of the following:
 - A KUB demonstrates tilting of the filter or malposition of one of the filter thongs
 - New **bilateral** lower extremity swelling (venous duplex should be performed first)
 - Filter present for >12 months, with documentation stating intent to remove

Background and Supporting Information

- IVC filters are placed in individuals with known DVT that cannot be anti-coagulated, individuals with poor pulmonary reserve and high risk for DVT, or prophylaxis in trauma and surgical individuals.
- Most IVC filters inserted are retrievable and should be removed as soon as clinically feasible. After 12 months, removal of IVC filters can become technically more difficult.

References

1. Abdul-Haq R, Almaroof B, Chen BL, Panneton JM, Parent FN. Endovenous Laser Ablation of Great Saphenous Vein and Perforator Veins Improves Venous Stasis Ulcer Healing. *Annals of Vascular Surgery*. 2013;27(7):932-939. doi:10.1016/j.avsg.2012.09.014.
2. Ageno W, Haas S, Weitz JI, et al. Characteristics and Management of Patients with Venous Thromboembolism: The GARFIELD-VTE Registry. *Thromb Haemost*. 2019;119(2):319-327. doi:10.1055/s-0038-1676611.
3. American College of Phlebology. Duplex Ultrasound Imaging of Lower Extremity Veins in Chronic Venous Disease. American Vein & Lymphatic Society. http://www.phlebology.org/member-resources/publications/duplex-ultrasound-imaging-lower-extremity-veins-chronic-venous-disease_Published 2012.
4. American College of Phlebology. Treatment of Superficial Venous Disease of the Lower Leg Guidelines. American Vein & Lymphatic Society. <http://www.phlebology.org/member-resources/publications/treatment-superficial-venous-disease-lower-leg-guidelines>. Published 2016.
5. Biemans AA, Kockaert M, Akkersdijk GP, et al. Comparing endovenous laser ablation, foam sclerotherapy, and conventional surgery for great saphenous varicose veins. *J Vasc Surg*. 2013;58(3):727-34.e1. doi:10.1016/j.jvs.2012.12.074.
6. Brittenden J, Cotton SC, Elders A, et al. Clinical effectiveness and cost-effectiveness of foam sclerotherapy, endovenous laser ablation and surgery for varicose veins: results from the Comparison of LAser, Surgery and foam Sclerotherapy (CLASS) randomised controlled trial. *Health Technol Assess*. 2015;19(27):1-342. doi:10.3310/hta19270.
7. Christof T, Kaltenmeier, Erben Y, et al. Systematic review of May-Thurner syndrome with emphasis on gender differences. *J Vasc Surg Venous Lymphat Disord*. 2018;6(3):399-407.
8. Eberhardt RT and Raffetto JD. Chronic Venous Insufficiency. *Circulation*. 2005; 111: 2398-2409.

9. Glociczki P, Comerota AJ, Dalsing MD, et al. The care of patients with varicose veins and associated chronic venous diseases: Clinical practice guidelines of the Society for Vascular Surgery and the American Venous Forum. *J Vasc Surg*. 2011. 53(16S):1-47. doi:10.1016/j.jvs.2011.01.079.
10. Harlander-Locke M, Lawrence PF, Alktaifi A, Jimenez JC, Rigberg D, Derubertis B. The impact of ablation of incompetent superficial and perforator veins on ulcer healing rates. *J Vasc Surg*. 2012;55(2):458-464. doi:10.1016/j.jvs.2011.08.054.
11. Healy DA, Kimura S, Power D, et al. A Systematic Review and Meta-analysis of Thrombotic Events Following Endovenous Thermal Ablation of the Great Saphenous Vein. *European Journal of Vascular and Endovascular Surgery*. 2018;56(3):410-424. doi:10.1016/j.ejvs.2018.05.008.
12. Jacobs CE, Pinzon MM, Orozco J, et al. Deep Venous Thrombosis after Saphenous Endovenous Radiofrequency Ablation: Is it Predictable? *Annals of Vascular Surgery*. 2014;28(3):679-685. doi:10.1016/j.avsg.2013.08.012.
13. Jones WS, Vemulapalli S, Parikh KS et al. Treatment Strategies for Patients with Lower Extremity Chronic Venous Disease (LECV). Agency for Healthcare Research and Quality (US); 2017 Apr.
14. Jones WS, Vemulapalli S, Parikh KS, et al. Treatment Strategies for Patients with Lower Extremity Chronic Venous Disease (LECV). Technology Assessment Program. Project ID: DVTT0515. (Prepared by the Duke University Evidence-based Practice Center under Contract No. 290-2015-00004-I). Rockville, MD: Agency for Healthcare Research and Quality; April 2017.
15. Kahn SR, M'lan CE, Lamping DL, et al. Relationship between clinical classification of chronic venous disease and patient-reported quality of life: results from an international cohort study. *J Vasc Surg*. 2004;39(4):823-828. doi:10.1016/j.jvs.2003.12.007.
16. Khilnani NM. Duplex ultrasound evaluation of patients with chronic venous disease of the lower extremities. *AJR Am J Roentgenol*. 2014;202(3):633-642. doi:10.2214/AJR.13.11465.
17. King T, Coulomb G, Goldman A, et al. Experience with concomitant ultrasound guided foam sclerotherapy and endovenous laser treatment in chronic venous disorder and its influence on Health Related Quality of Life: interim analysis of more than 1000 consecutive procedures. *International Angiology*. 2009;28 (4):289 -297.
18. Lawrence PF, Alktaifi A, Rigberg D, Derubertis B, Gelabert H, Jimenez JC. Endovenous ablation of incompetent perforating veins is effective treatment for recalcitrant venous ulcers. *J Vasc Surg*. 2011;54(3):737-742. doi:10.1016/j.jvs.2011.02.068.
19. Lim W, Gal GL, Bates SM, et al. American Society of Hematology 2018 guidelines for management of venous thromboembolism: diagnosis of venous thromboembolism. *Blood Advances*. 2018;2(22):3226-3256. doi:10.1182/bloodadvances.2018024828.
20. Liu N, Wang C, Sun M. Noncontrast three-dimensional magnetic resonance imaging vs lymphoscintigraphy in the evaluation of lymph circulation disorders: A comparative study. *J Vasc Surg*. 2005;41(1):69-75. doi:10.1016/j.jvs.2004.11.013.
21. Lurie F, Kistner RL. Trends in patient reported outcomes of conservative and surgical treatment of primary chronic venous disease contradict current practices. *Annals of Surgery*. 2011 Aug;254(2):363-367. DOI: 10.1097/sla.0b013e31821d4a5f.
22. Meissner MH, Moneta G, Burnand K, et al. The hemodynamics and diagnosis of venous disease. *J Vasc Surg*. 2007;46 Suppl S:4S-24S. doi:10.1016/j.jvs.2007.09.043.
23. National Institute for Health and Care Excellence (NICE). Varicose veins in the legs: the diagnosis and management of varicose veins. NICE Clinical Guideline: Methods, evidence and recommendations. London: National Institute for Health and Care Excellence (UK). July, 2013.
24. Nayak L, Vedantham S. Multifaceted Management of the Postthrombotic Syndrome. *Seminars in Interventional Radiology*. 2012; 29:1.
25. Partsch H, Flour M, Smith PC, et al. Indications for compression therapy in venous and lymphatic disease. Consensus based on experimental data and scientific evidence. *Int Angiol*. 2008;27:193-219.
26. Piazza G. Varicose veins. *Circulation*. 2014;130(7):582-587. doi:10.1161/CIRCULATIONAHA.113.008331.
27. Poblete H, Elias S. Venous Ulcers: New Options in Treatment: Minimally Invasive Vein Surgery. *The Journal of the American College of Certified Wound Specialists*. 2009;1(1):12-19. doi:10.1016/j.jcws.2008.10.004.
28. Proebstle TM, Alm BJ, Göckeritz, et al. Five-year results from the prospective European multicenter cohort study on radiofrequency segmental thermal ablation for incompetent great saphenous veins. *BJS*. 2015; 102: 212-218. doi:10.1002/bjs.9679.
29. Rossi FH, Kambara AM, Izukawa NM, et al. Randomized double-blinded study comparing medical treatment versus iliac vein stenting in chronic venous disease. *J Vasc Surg Venous Lymphat Disord*. 2018;6(2):183-191.
30. Sermathanasawadi N, Pruekprasert K, Pitaksantayothin W, et al. Prevalence, risk factors, and evaluation of ilio caval obstruction in advanced chronic venous insufficiency. *J Vasc Surg Venous Lymphat Disord*. 2019 May;7(3):441-447.
31. Smith JJ, Garratt AM, Guest M, Greenhalgh RM, Davies AH. Evaluating and improving health-related quality of life in patients with varicose veins. *J Vasc Surg*. 1999;30(4):710-719. doi:10.1016/s0741-5214(99)70110-2.
32. van der Velden SK, Biemans AA, De Maeseneer MG, et al. Five-year results of a randomized clinical trial of conventional surgery, endovenous laser ablation and ultrasound-guided foam sclerotherapy in patients with great saphenous varicose veins. *Br J Surg*. 2015;102(10):1184-1194.

33. Vedantham S, Kahn SR, Goldhaber SZ, Comerota AJ, et al. Endovascular therapy for advanced post-thrombotic syndrome: Proceedings from a multidisciplinary consensus panel. *Vasc Med*. 2016 Aug;21(4):400-7.
34. Washington State Health Care Authority. Selected Treatments for Varicose Veins, A Health Technology Assessment. Prepared by Hayes, Inc. Final Report: April 2017.
35. Weiss RA, Weiss MA, Eimpunth S, et al. Comparative Outcomes of Different Endovenous Thermal Ablation Systems on Great and Small Saphenous Vein Insufficiency: Long-Term Results. *Lasers in Surgery and Medicine*. 2015; 47: 156-160. Aortic Disorders General Information.
36. Wittens C, Davies A, Bækgaard N, et al. Editor's Choice – Management of Chronic Venous Disease. *Eur J Vasc Endovasc Surg*. 2015;49(6):678-737. doi:10.1016/j.ejvs.2015.02.007.
37. Wolpert L, Rahmani O, Stein B, et al. Magnetic Resonance Venography in the Diagnosis and Management of May-Thurner syndrome. *Vasc Endovascular Surg*. 2002 Jan-Feb;36(1):51-7. doi:10.1177/153857440203600109.

Post iliac vein stenting/angioplasty (PVD-17.1)

PVD.VI.0017.A

v1.0.2024

Iliac venous stents can be placed after thrombolysis for DVT associated with May-Thurner's syndrome, DVT associated with extrinsic compression or for post thrombotic iliac obstruction.

- Arterial duplex (CPT® 93975, 93976, 93978, 93979) can be obtained for:
 - Surveillance of iliac venous stents
 - Worsening signs or symptoms including increased edema when stent malfunction is suspected
 - Postoperatively within the first month, at six months, twelve months and then annually
- CTV or MRV Abdomen and Pelvis can be obtained for an abnormal or indeterminate duplex

References

1. Washington State Health Care Authority. Selected Treatments for Varicose Veins, A Health Technology Assessment. Prepared by Hayes, Inc. Final Report: April 2017.
2. Proebstle TM, Alm BJ, Göckeritz, et al. Five-year results from the prospective European multicenter cohort study on radiofrequency segmental thermal ablation for incompetent great saphenous veins. *BJS*. 2015; 102: 212-218. doi:10.1002/bjs.9679.
3. Weiss RA, Weiss MA, Eimpunth S, et al. Comparative Outcomes of Different Endovenous Thermal Ablation Systems on Great and Small Saphenous Vein Insufficiency: Long-Term Results. *Lasers in Surgery and Medicine*. 2015; 47: 156-160. Aortic Disorders General Information.
4. Brittenden J, Cotton SC, Elders A, et al. Clinical effectiveness and cost-effectiveness of foam sclerotherapy, endovenous laser ablation and surgery for varicose veins: results from the Comparison of LAser, Surgery and foam Sclerotherapy (CLASS) randomised controlled trial. *Health Technol Assess*. 2015;19(27):1-342. doi:10.3310/hta19270.
5. Biemans AA, Kockaert M, Akkersdijk GP, et al. Comparing endovenous laser ablation, foam sclerotherapy, and conventional surgery for great saphenous varicose veins. *J Vasc Surg*. 2013;58(3):727-34.e1. doi:10.1016/j.jvs.2012.12.074.
6. van der Velden SK, Biemans AA, De Maeseneer MG, et al. Five-year results of a randomized clinical trial of conventional surgery, endovenous laser ablation and ultrasound-guided foam sclerotherapy in patients with great saphenous varicose veins. *Br J Surg*. 2015;102(10):1184-1194. doi:10.1002/bjs.9867.
7. Rasmussen L, Lawaetz M, Serup J, et al. Randomized clinical trial comparing endovenous laser ablation, radiofrequency ablation, foam sclerotherapy, and surgical stripping for great saphenous varicose veins with 3-year follow-up. *J Vasc Surg Venous Lymphat Disord*. 2013;1(4):349-356. doi:10.1016/j.jvsv.2013.04.008.
8. Brittenden J, Cotton SC, Elders A, et al. A randomized trial comparing treatments for varicose veins. *N Engl J Med*. 2014; 371(13): 1218-1227. doi:10.1056/NEJMoa1400781.
9. Venermo M, Saarinen J, Eskelinen E, et al. Randomized clinical trial comparing surgery, endovenous laser ablation and ultrasound-guided foam sclerotherapy for the treatment of great saphenous varicose veins. *Br J Surg*. 2016;103(11):1438-1444. doi:10.1002/bjs.10260.

Table of Contents

Guideline

- General Guidelines (SP-1)
- Imaging Techniques (SP-2)
- Neck (Cervical Spine) Pain Without/With Neurological Features (Including Stenosis) and Trauma (SP-3)
- Upper Back (Thoracic Spine) Pain Without/With Neurological Features (Including Stenosis) and Trauma (SP-4)
- Low Back (Lumbar Spine) Pain/Coccydynia without Neurological Features (SP-5)
- Lower Extremity Pain with Neurological Features (Radiculopathy, Radiculitis, or Plexopathy and Neuropathy) With or Without Low Back (Lumbar Spine) Pain (SP-6)
- Myelopathy (SP-7)
- Lumbar Spine Spondylolysis/Spondylolisthesis (SP-8)
- Lumbar Spinal Stenosis (SP-9)
- Sacro-Iliac (SI) Joint Pain, Inflammatory Spondylitis/Sacroiliitis and Fibromyalgia (SP-10)
- Spinal Compression Fractures (SP-11)
- Spinal Pain in Cancer Patients (SP-12)
- Spinal Canal/Cord Disorders (e.g. Syringomyelia) (SP-13)
- Spinal Deformities (e.g. Scoliosis/Kyphosis) (SP-14)
- Post-Operative Spinal Disorders (SP-15)
- Other Imaging Studies and Procedures Related to the Spine Imaging Guidelines (SP-16)
- Nuclear Medicine (SP-17)

General Guidelines (SP-1)

Guideline

Procedure Codes Associated with Spine Imaging

General Guidelines (SP-1.0)

General Considerations (SP-1.1)

Red Flag Indications (SP-1.2)

Definitions (SP-1.3)

References (SP-1)

Procedure Codes Associated with Spine Imaging

SP.GG.ProcedureCodes.A
v2.0.2024

MRI/MRA	CPT®
MRI Cervical without contrast	72141
MRI Cervical with contrast	72142
MRI Cervical without and with contrast	72156
MRI Thoracic without contrast	72146
MRI Thoracic with contrast	72147
MRI Thoracic without and with contrast	72157
MRI Lumbar without contrast	72148
MRI Lumbar with contrast	72149
MRI Lumbar without and with contrast	72158
MRA Spinal Canal	72159
MRI Pelvis without contrast	72195
MRI Pelvis with contrast	72196
MRI Pelvis without and with contrast	72197
MR Spectroscopy	76390
Magnetic resonance spectroscopy, determination and localization of discogenic pain (cervical, thoracic, or lumbar); acquisition of single voxel data, per disc, on biomarkers (ie, lactic acid, carbohydrate, alanine, laal, propionic acid, proteoglycan, and collagen) in at least 3 discs	0609T
Magnetic resonance spectroscopy, determination and localization of discogenic pain (cervical, thoracic, or lumbar); transmission of biomarker data for software analysis	0610T
Magnetic resonance spectroscopy, determination and localization of discogenic pain (cervical, thoracic, or lumbar); postprocessing for algorithmic analysis of biomarker data for determination of relative chemical differences between discs	0611T
Magnetic resonance spectroscopy, determination and localization of discogenic pain (cervical, thoracic, or lumbar); interpretation and report	0612T

CT	CPT[®]
CT Cervical without contrast	72125
CT Cervical with contrast (Post-Myelography CT)	72126
CT Cervical without and with contrast	72127
CT Thoracic without contrast	72128
CT Thoracic with contrast (Post-Myelography CT)	72129
CT Thoracic without and with contrast	72130
CT Lumbar without contrast (Post-Discography CT)	72131
CT Lumbar with contrast (Post-Myelography CT)	72132
CT Lumbar without and with contrast	72133
CT Pelvis without contrast	72192
CT Pelvis with contrast	72193
CT Pelvis without and with contrast	72194

Ultrasound	CPT[®]
Spinal canal ultrasound	76800

Nuclear Medicine	CPT[®]
Bone Marrow Imaging, Limited	78102
Bone Marrow Imaging, Multiple	78103
Bone Marrow Imaging, Whole Body	78104
Bone or Joint Imaging, Limited	78300
Bone or Joint Imaging, Multiple	78305
Bone Scan, Whole Body	78306
Bone Scan, 3 Phase Study	78315
Radiopharmaceutical localization of tumor, inflammatory process or distribution of radiopharmaceutical agent(s) (includes vascular flow and blood pool imaging, when performed); planar, single area (e.g., head, neck, chest, pelvis), single day imaging	78800
Radiopharmaceutical localization of tumor, inflammatory process or distribution of radiopharmaceutical agent(s) (includes vascular flow and blood pool imaging, when performed); planar, 2 or more areas (e.g., abdomen and pelvis, head and chest), 1 or more days imaging or single area imaging over 2 or more days	78801

Nuclear Medicine	CPT [®]
Radiopharmaceutical localization of tumor, inflammatory process or distribution of radiopharmaceutical agent(s) (includes vascular flow and blood pool imaging, when performed); planar, whole body, single day imaging	78802
Radiopharmaceutical localization of tumor, inflammatory process or distribution of radiopharmaceutical agent(s) (includes vascular flow and blood pool imaging, when performed); tomographic (SPECT), single area (e.g., head, neck, chest, pelvis), single day imaging	78803
Radiopharmaceutical localization of tumor, inflammatory process or distribution of radiopharmaceutical agent(s) (includes vascular flow and blood pool imaging, when performed); tomographic (SPECT) with concurrently acquired computed tomography (CT) transmission scan for anatomical review, localization and determination/detection of pathology, single area (e.g., head, neck, chest, pelvis), single day imaging	78830
Radiopharmaceutical localization of tumor, inflammatory process or distribution of radiopharmaceutical agent(s) (includes vascular flow and blood pool imaging, when performed); tomographic (SPECT), minimum 2 areas (e.g., pelvis and knees, abdomen and pelvis), single day imaging, or single area imaging over 2 or more days	78831

General Guidelines (SP-1.0)

SP.GG.0001.0.A

v2.0.2024

- Before advanced diagnostic imaging can be considered, there must be an in-person clinical evaluation as well as a clinical re-evaluation after a trial of failed conservative therapy; the clinical re-evaluation may consist of an in-person evaluation or other meaningful contact with the provider's office such as email, web or telephone communications.
- An in-person clinical evaluation for the current episode of the condition is required to have been performed before advanced imaging is considered. This may have been either the initial clinical evaluation or a clinical re-evaluation.
- The in-person clinical evaluation should include a relevant history and physical examination (including a detailed neurological examination), appropriate laboratory studies, non-advanced imaging modalities, results of manual motor testing, the specific dermatomal distribution of altered sensation, reflex examination, and nerve root tension signs (e.g., straight leg raise test, slump test, femoral nerve tension test). *The clinical evaluation must be in-person; other forms of meaningful contact (telephone call, electronic mail, telemedicine, or messaging) are not acceptable as an in-person evaluation.*
 - For those spinal conditions/disorders for which the Spine Imaging Guidelines require a plain x-ray of the spine prior to consideration of an advanced imaging study, the plain x-ray must be performed after the current episode of symptoms started or changed and results need to be available to the requesting provider of the advanced imaging study (see: **Anatomic Guidelines [SP-2.1]**).
- Clinical re-evaluation is required prior to consideration of advanced diagnostic imaging to document failure of significant clinical improvement following a recent (within 3 months) six week trial of provider-directed treatment. Clinical re-evaluation can include documentation of an in-person encounter or documentation of other meaningful contact with the requesting provider's office by the individual (e.g., telephone call, electronic mail, telemedicine, or messaging).
 - Provider-directed treatment may include education, activity modification, NSAIDs (non-steroidal anti-inflammatory drugs), narcotic and non-narcotic analgesic medications, oral or injectable corticosteroids, a provider-directed home exercise/stretching program, cross-training, avoidance of aggravating activities, physical/occupational therapy, spinal manipulation, interventional pain procedures and other pain management techniques.
- Any bowel/bladder abnormalities or emergent or urgent indications should be documented at the time of the initial clinical evaluation and clinical re-evaluation.
- Altered sensation to pressure, pain, and temperature should be documented by the specific anatomic distribution (e.g., dermatomal, stocking/glove or mixed distribution).
- Motor deficits (weakness) should be defined by the specific myotomal distribution (e.g., weakness of toe flexion/extension, knee flexion/extension, ankle dorsi/plantar

flexion, wrist dorsi/palmar flexion) and gradation of muscle testing should be documented as follows:

Grading of Manual Muscle Testing	
0	No muscle activation
1	Trace muscle activation, such as a twitch, without achieving full range of motion
2	Muscle activation with gravity eliminated, achieving full range of motion
3	Muscle activation against gravity, full range of motion
4	Muscle activity against gravity some resistance, full range of motion
5	Muscle activation against examiner's full resistance, full range of motion

- Pathological reflexes (e.g. Hoffmann's, Babinski, and Chaddock sign) should be reported as positive or negative.
- Asymmetric reflexes and reflex examination should be documented as follows:

Grading of Reflex Testing	
0	No response
1+	A slight but definitely present response
2+	A brisk response
3+	A very brisk response without clonus
4+	A tap elicits a repeating reflex (clonus)

- Advanced diagnostic imaging is often urgently indicated and may be necessary if serious underlying spinal and/or non-spinal disease is suggested by the presence of certain patient factors referred to as "red flags." See: **Red Flag Indications (SP-1.2)**.
- Spinal specialist evaluation can be helpful in determining the need for advanced diagnostic imaging, especially for individuals following spinal surgery.
- The need for repeat advanced diagnostic imaging should be carefully considered and may not be indicated if prior advanced diagnostic imaging has been performed. Requests for simultaneous, similar studies such as spinal MRI and CT need to be documented as required for preoperative surgical planning. These studies may be helpful in the evaluation of complex failed spinal fusion cases or needed for preoperative surgical planning when the determination of both soft tissue and bony anatomy is required.

- Serial advanced imaging, whether CT or MRI, for surveillance of healing or recovery from spinal disease is not supported by the currently available scientific evidence-based medicine for the majority of spinal disorders.
 - Requests for repeat imaging may be considered on a case-by-case basis (e.g. concern for delayed union or non-union of spinal fracture, pseudoarthrosis of fusion, etc.)
- Advanced imaging is generally unnecessary for resolved or improving spinal pain and/or radiculopathy.
- Advanced diagnostic imaging has not been shown to be of value in individuals with stable, longstanding spinal pain without neurological features or without clinically significant or relevant changes in symptoms or physical examination findings.
- Anatomic regions of the spine/pelvis that are included in the following MRI and CT advanced diagnostic imaging studies:
 - Cervical spine: from the skull base/foramen magnum through T1
 - Thoracic spine: from C7 through L1
 - Lumbar spine: from T12 through mid-sacrum
 - Pelvis: includes hips, sacroiliac joints, sacrum, coccyx
- CT or MRI of the cervical and thoracic spine will image the entire spinal cord since the end of the spinal cord or conus medullaris usually ends at L1 in adults. Therefore, lumbar spine imaging is not needed when the goal is to image only the spinal cord unless there is known or suspected low lying conus medullaris (e.g. tethered cord).

General Considerations (SP-1.1)

SP.GG.0001.1.A

v2.0.2024

- See: [General Guidelines \(SP-1.0\)](#)

Background and Supporting Information

Straight leg raise test (also known as the Lasegue’s test) – With the individual in the supine position, the hip medially rotated and adducted, and the knee extended, the examiner flexes the hip until the individual complains of pain or tightness in the back or back of the leg. If the pain is primarily back pain, it is less specific whereas if the pain is primarily in the leg, it is more likely nerve root irritation/radiculopathy. Disc herniation or pathology causing pressure between the two extremes are more likely to cause pain in both areas. The examiner then slowly and carefully drops the leg back (extends it) slightly until the individual feels no pain or tightness. The individual is then asked to flex the neck so the chin is on the chest, or the examiner may dorsiflex the individual’s foot, or both actions may be done simultaneously. Both of these maneuvers are considered to be provocative tests for neurological tissue.

Slump test – The individual is seated on the edge of the examination table with the legs supported, the hips in neutral position, and the hands behind the back. The examination is performed in sequential steps. First, the individual is asked to “slump” the back into thoracic and lumbar flexion. The examiner maintains the individual’s chin in neutral position to prevent neck and head flexion. The examiner then uses one arm to apply overpressure across the shoulders to maintain flexion of the thoracic and lumbar spines. While this position is held, the individual is asked to actively flex the cervical spine and head as far as possible (i.e., chin to chest). The examiner then applies overpressure to maintain flexion of all three parts of the spine (cervical, thoracic, and lumbar) using the hand of the same arm to maintain overpressure in the cervical spine. With the other hand, the examiner then holds the individual’s foot in maximum dorsiflexion. While the examiner holds these positions, the individual is asked to actively straighten the knee as much as possible. The test is repeated with the other leg and then with both legs at the same time. If the individual is unable to fully extend the knee because of pain, the examiner releases the overpressure to the cervical spine and the individual actively extends the neck. If the knee extends further, the symptoms decrease with neck extension, or the positioning of the individual increases the individual’s symptoms, then the test is considered positive.

Femoral nerve tension test (also known as the prone knee bending test) – The individual lies prone while the examiner passively flexes the knee as far as possible so that the individual’s heel rests against the buttock. At the same time, the examiner should ensure that the individual’s hip is not rotated. If the examiner is unable to flex the individual’s knee past 90 degrees because of a pathological condition in the hip, the test may be performed by passive extension of the hip while the knee is flexed as much as possible. The flexed knee position should be maintained for 45 to 60 seconds. Unilateral neurological pain in the lumbar area, buttock, and/or posterior thigh may

indicate an L2 or L3 nerve root lesion. Pain in the anterior thigh indicates tight quadriceps muscles or stretching of the femoral nerve.

Hoffmann's sign – The examiner holds the individual's middle finger and briskly flicks the distal phalanx. A positive test is noted if the interphalangeal joint of the thumb of the same hand flexes.

Babinski's sign – The examiner runs a sharp instrument along the plantar surface of the foot from the calcaneus along the lateral border to the forefoot. A positive test occurs with extension of the great toe with flexion and splaying of the other toes. A negative test occurs with no movement of the toes at all or uniform bunching up of the toes.

Chaddock sign – The examiner strokes the lateral malleolus. A positive test occurs with extension of the great toe.

Red Flag Indications (SP-1.2)

SP.GG.0001.2.A
v2.0.2024

Red Flag Indications are intended to represent the potential for life or limb threatening conditions. Red Flag Indications are clinical situations in which localized spine pain and associated neurological features are likely to reflect serious underlying spinal and/or non-spinal disease and warrant exception to the requirement for documented failure of six weeks of provider-directed treatment. Advanced diagnostic imaging of the symptomatic level is appropriate and/or work-up for a non-spinal source of spine pain for Red Flag Indications.

- Red Flag Indications include:
 - Motor Weakness
 - Aortic Aneurysm or Dissection
 - Cancer
 - Cauda Equina Syndrome
 - Fracture
 - Infection
 - Severe Radicular Pain

Motor Weakness

(See: Grading of Manual Muscle Testing and Reflex Testing in [General Guidelines \[SP-1.0\]](#))

History, Symptoms or Physical Exam Findings (Initial clinical evaluation required within the last 60 days)	Advanced Diagnostic Imaging
Clinical presentation including one or more of the following: <ul style="list-style-type: none"> • Motor weakness of grade 3/5 or less of specified muscle(s); • New onset foot drop; • Acute bilateral lower extremity weakness; • Progressive objective motor /sensory/deep tendon reflex deficits on clinical re-evaluation. 	MRI of the relevant spinal level without contrast or MRI of the relevant spinal level without and with contrast

Aortic Aneurysm or Dissection

History, Symptoms or Physical Exam Findings (Initial clinical evaluation required within the last 60 days)	Advanced Diagnostic Imaging
<ul style="list-style-type: none"> • New onset of back and/or abdominal pain in an individual with a known AAA; <i>or</i> • Acute dissection is suspected. 	No spine imaging indicated, see: <u>Aortic Disorders, Renal Vascular Disorders and Visceral Artery Aneurysms (PVD-6)</u> in the Peripheral Vascular Disease Imaging Guidelines

Cancer

History, Symptoms or Physical Exam Findings (Initial clinical evaluation required within the last 60 days)	Advanced Diagnostic Imaging
There is clinical suspicion of spinal malignancy AND ONE or more of the following: <ul style="list-style-type: none"> • Night pain • Uncontrolled or unintended weight loss • Pain unrelieved by change in position • Age >70 years • Severe and worsening spinal pain despite a reasonable (generally after 1 week) trial of provider-directed treatment with re-evaluation 	ONE of the following: <ul style="list-style-type: none"> • MRI of the relevant spinal level without contrast • MRI of the relevant spinal level without and with contrast • CT of the relevant spinal level without contrast • CT Myelogram of the relevant spinal level

History, Symptoms or Physical Exam Findings (Initial clinical evaluation required within the last 60 days)	Advanced Diagnostic Imaging
<p>ANY of the following:</p> <p>Known malignancy(ies) and acute spinal cord compression from primary or metastatic spinal neoplastic disease is suspected by history and physical examination</p> <p>OR</p> <p>Individual with a known history of cancer AND metastatic or Stage IV cancer with new onset back pain</p> <p>OR</p> <p>Individual with known history of cancer AND back pain AND suspicion of spinal malignancy</p>	<p>See: <u>Spinal/Vertebral Metastases (ONC-31.6)</u> in the Oncology Imaging Guidelines</p>

Cauda Equina Syndrome

History, Symptoms or Physical Exam Findings (Initial clinical evaluation required within the last 60 days)	Advanced Diagnostic Imaging
<p>Clinical presentation including one or more of the following:</p> <ul style="list-style-type: none"> • Acute onset of bilateral sciatica; • Perineal sensory loss (“saddle anesthesia”); • Decreased anal sphincter tone; • New onset bowel/bladder incontinence; • Otherwise unexplained acute urinary retention. 	<p>MRI Lumbar Spine without contrast (CPT® 72148) or MRI Lumbar Spine without and with contrast (CPT® 72158)</p>

Fracture

History, Symptoms or Physical Exam Findings (Initial clinical evaluation required within the last 60 days)	Advanced Diagnostic Imaging
<ul style="list-style-type: none"> Clinical suspicion of a pathological spinal fracture. <ul style="list-style-type: none"> Advanced imaging is indicated after x-ray; no conservative treatment is needed. 	See: <u>Spinal Compression Fractures (SP-11.1)</u> for appropriate imaging studies
<ul style="list-style-type: none"> Clinical suspicion of a spinal fracture after trauma <ul style="list-style-type: none"> Advanced imaging is indicated after x-ray; no conservative treatment is needed. 	See: <u>Neck (Cervical Spine) Trauma (SP-3.2), Upper Back (Thoracic Spine) Trauma (SP-4.2), or Low Back (Lumbar Spine) Trauma (SP-6.2)</u> for appropriate imaging studies
<ul style="list-style-type: none"> Clinical suspicion of a spinal fracture related to ankylosing spondylitis or DISH <ul style="list-style-type: none"> Advanced imaging is indicated <i>without</i> x-ray or conservative treatment. 	See: <u>Neck (Cervical Spine) Trauma (SP-3.2), Upper Back (Thoracic Spine) Trauma (SP-4.2), Low Back (Lumbar Spine) Trauma (SP-6.2), or Inflammatory Spondylitis (SP-10.2)</u> for appropriate imaging studies

Infection

History, Symptoms or Physical Exam Findings (Initial clinical evaluation required within the last 60 days)	Advanced Diagnostic Imaging
<p>There is a clinical suspicion of spinal infection (e.g., disc space infection, epidural abscess or spinal osteomyelitis) and one or more of the following:</p> <ul style="list-style-type: none"> • Fever; • History of IV drug use; • Recent bacterial infection (UTIs, pyelonephritis, pneumonia); • Recent spinal intervention (e.g., surgery, pain injection, or stimulator implantation); • Immunocompromised states; • Long term use of systemic glucocorticoids; • Organ transplant recipient taking anti-rejection medication; • Diabetes mellitus; • HIV/AIDS; • Chronic dialysis; • Immunosuppressant therapy; • Neoplastic involvement of the spine; • Laboratory values indicative of infection (e.g., elevated WBC, ESR, CRP, positive cultures); • Decubitus ulcer or wound overlying spine; • Abnormal x-ray or CT suspicious for infection 	<p>ONE of the following:</p> <ul style="list-style-type: none"> • MRI of the relevant spinal level without and with contrast • MRI without contrast • 3-phase bone scan complete spine • Gallium scan whole body • CT Spine area of interest with IV contrast • CT Spine area of interest without IV contrast
<p>There is a clinical suspicion of spinal infection (e.g., disc space infection, epidural abscess or spinal osteomyelitis) and one or more of the following:</p> <ul style="list-style-type: none"> • New neurologic deficit on physical examination • Cauda equina syndrome 	<p>ONE of the following:</p> <ul style="list-style-type: none"> • MRI of the relevant spinal level without and with contrast • MRI without contrast • CT Spine area of interest with IV contrast • CT Spine area of interest without IV contrast

Severe Radicular Pain

All of the following must be present (Initial clinical evaluation required within the last 60 days)	Advanced Diagnostic Imaging
<ul style="list-style-type: none">• Severe radicular pain in a specified spinal nerve root distribution (minimum 9/10 on the VAS); and• Documented significant functional loss at work or at home; and• Severity of pain unresponsive to a minimum of seven (7) days of provider-directed treatment; and• Treatment plan includes one of the following:<ul style="list-style-type: none">• Transforaminal epidural steroid injection (TFESI) at any level(s); or• Interlaminar epidural steroid injection (ILESI) at the cervical or thoracic levels; or• A plan for urgent/emergent spinal surgery; or• A plan for an urgent/emergent referral to/consultation from a spine specialist (Interventional Pain physician or Spine Surgeon)	MRI of the relevant spinal level without contrast or MRI without and with contrast

Definitions (SP-1.3)

SP.GG.0001.3.A

v2.0.2024

- **Radiculopathy**, for the purpose of this policy, is defined as the presence of pain resulting in significant functional limitations (i.e., diminished quality of life and impaired, age-appropriate activities of daily living), dysaesthesia(s) or paraesthesia(s) reported by the individual in a specified dermatomal distribution of an involved named spinal root(s) and **ONE or MORE** of the following:
 - Loss of strength of specific named muscle(s) or myotomal distribution(s) or demonstrated on detailed neurologic examination (within the prior 3 months), concordant with nerve root compression of the involved named spinal nerve root(s).
 - Altered sensation to light touch, pressure, pin prick or temperature demonstrated on a detailed neurologic examination (within the prior 3 months) in the sensory distribution concordant with nerve root compression of the involved named spinal nerve root(s).
 - Diminished, absent or asymmetric reflex(es) on a detailed neurologic examination (within the prior 3 months) concordant with nerve root compression of the involved named spinal nerve root(s).
 - Either of the following:
 - A concordant radiologist's interpretation of an advanced diagnostic imaging study (MRI or CT) of the spine demonstrating compression of the involved named spinal nerve root(s) or foraminal stenosis at the concordant level(s) (Performed within the prior 12 months).
 - Electrodiagnostic studies (EMG/NCV's) diagnostic of nerve root compression of the involved named spinal nerve root(s). (Performed within the prior 12 months).
- **Radicular pain** is pain which radiates to the upper or lower extremity along the course of a spinal nerve root, typically resulting from compression, inflammation and/or injury to the nerve root.
- **Radiculitis** is defined, for the purpose of this policy, as radicular pain without objective neurological findings.

References (SP-1)

v2.0.2024

1. el Barzouhi A, Vleggeert-Lankamp C, Lycklama à Nijeholt GJ, et al. Magnetic resonance imaging in follow-up assessment of sciatica. *N Engl J Med*. 2013;368(11):999-1007. doi:10.1056/NEJMoa1209250.
2. Deyo RA, Dieh AK, Rosenthal M. Reducing roentgenography use. *Arch Intern Med*. 1987;147(1):141-145. doi:10.1001/archinte.1987.00370010139029.
3. Deyo RA, Rainville J, Kent DL. What can the history and physical examination tell us about low back pain? *JAMA*. 1992; 268(6):760-765. doi:10.1001/jama.1992.03490060092030.
4. Panagopoulos J, Hush J, Steffens D, Hancock, MJ. Do MRI findings change over a period of up to 1 year in patients with low back pain and/or sciatica? *Spine*. 2017;42(7):504-512. doi:10.1097/BRS.0000000000001790.
5. Fabiano V, Franchino G, Napolitano M, et. al. Utility of magnetic resonance imaging in the follow-up of children affected by acute osteomyelitis. *Curr Pediatr Res*. 2017;21(2):354-358.
6. Gilbert FJ, Grant AM, Gillan MG, et al. Low back pain: influence of early MR imaging or CT on treatment and outcome - multicenter randomized trial. *Radiology*. 2004;231:343-351. doi:10.1148/radiol.2312030886.
7. Hoppenfeld S. *Physical Examination of the Spine and Extremities*. Upper Saddle River: Prentice Hall; 1976.
8. Magee DJ. *Orthopedic Physical Assessment*. 4th ed. Philadelphia, PA:Saunders; 2002.
9. Hutchins TA, Peckham M, Shah LM, et. al. Expert Panel on Neurologic Imaging. ACR Appropriateness Criteria®: Low Back Pain. American College of Radiology (ACR); Date of Origin: 1996. Revised: 2021. <http://acsearch.acr.org/docs/69483/Narrative/>.
10. Patrick N, Emanski E, Knaub MA. Acute and chronic low back pain. *Med Clin North Am*. 2016;100(1):169-81.
11. Reinius WR. *Clinician's Guide to Diagnostic Imaging*. New York, NY: Springer; 2014. doi:10.1007/978-1-4614-8769-2.
12. Sharma H, Lee SWJ, Cole AA. The management of weakness caused by lumbar and lumbosacral nerve root compression. *J Bone Joint Surg Br*. 2012;94-B(11):1442-1447. doi:10.1302/0301-620X.94B11.29148.
13. Stiell IG, Clement CM, McKnight RD, et al. The Canadian c-spine rule versus the NEXUS low-risk criteria in patients with trauma. *N Engl J Med*. 2003;349:2510-2518. doi:10.1056/NEJMoa031375.
14. Underwood M, Buchbinder R. Red flags for back pain. *BMJ*. 2013;347:f7432. doi:10.1136/bmj.f7432.
15. Verhagen A, Downie A, Popal N, et al. Red flags presented in current low back pain guidelines: a review. *Eur Spine J*. 2016; 25:2788-2802. doi:10.1007/s00586-016-4684-0.
16. Visconti AJ, Biddle J, Solomon M. Follow-up imaging for vertebral osteomyelitis a teachable moment. *JAMA*. 2014;174(2):184. doi:10.1001/jamainternmed.2013.12742.
17. Tsiang JT, Kinzy TG, Thompson N, et al. Sensitivity and specificity of patient-entered red flags for lower back pain. *The Spine Journal*. 2019;19(2):293-300. doi:10.1016/j.spinee.2018.06.342.
18. Ortiz AO, Levit A, Shah LM, et. al. Expert Panel on Neurologic Imaging. ACR Appropriateness Criteria®: Suspected Spine Infection. American College of Radiology (ACR); Date of Origin: 2021. <https://acsearch.acr.org/docs/3148734/Narrative/>.
19. Naqvi U, Sherman AI. Muscle Strength Grading. In: StatPearls [Internet]. Treasure Island (FL): StatPearls Publishing; 2022. <https://www.ncbi.nlm.nih.gov/books/NBK436008/>.
20. Le HV, Wick JB, Van BW, Klineberg EO. Diffuse idiopathic skeletal hyperostosis of the spine: pathophysiology, diagnosis, and management. *J Am Acad Orthop Surg*. 2021;29:1044-1051. doi:10.5435/JAAOS-D-20-01344.
21. Goodwin ML, Buchowski JM, Sciubba DM. Why x-rays? The importance of radiographs in spine surgery. *The Spine Journal*. 2022;22(11):1759-1767. doi:10.1016/j.spinee.2022.07.102.

Imaging Techniques (SP-2)

Guideline

Anatomic Guidelines (SP-2.1)

MRI of the Spine (SP-2.2)

CT of the Spine (SP-2.3)

CT/Myelography (SP-2.4)

Imaging of Intervertebral Discs (SP-2.5)

Ultrasound of the Spinal Canal (SP-2.6)

Limitations of Spinal Imaging in Degenerative Disorders (SP-2.7)

Miscellaneous Spinal Lesions (SP-2.8)

MRA Spinal Canal (SP-2.9)

Spine PET/CT (SP-2.10)

Cone-beam CT (SP-2.11)

3D Rendering (SP-2.12)

References (SP-2)

Anatomic Guidelines (SP-2.1)

SP.IM.0002.1.A

v2.0.2024

- Anatomic regions of the spine/pelvis that are included in the following MRI and CT advanced diagnostic imaging studies:
 - Cervical spine: from the skull base/foramen magnum through T1
 - Thoracic spine: from C7 through L1
 - Lumbar spine: from T12 through mid-sacrum
 - Pelvis: includes hips, sacroiliac joints, sacrum, coccyx
- CT or MRI cervical and thoracic spine will image the entire spinal cord since the end of the spinal cord or conus medullaris usually ends at L1 in adults. Therefore, lumbar spine imaging is not needed when the goal is to image only the spinal cord unless there is known or suspected low lying conus medullaris (e.g. tethered cord).
- The results of plain x-rays performed after the current episode of symptoms started or changed need to be available to the requesting provider of the advanced imaging study for the following conditions:
 - See: **Spinal Compression Fractures (SP-11)**
 - See: **Lumbar Spine Spondylolysis/Spondylolisthesis (SP-8)**
 - See: **Inflammatory Spondylitis (SP-10.2)**
 - See: **Neck (Cervical Spine) Trauma (SP-3.2), Upper Back (Thoracic Spine) Trauma (SP-4.2), and Low Back (Lumbar Spine) Trauma (SP-6.2)**
 - See: **Coccydynia without Neurological Features (SP-5.2)**
 - See: **Spinal Deformities (e.g. Scoliosis/Kyphosis) (SP-14) and Spinal Dysraphism (PEDSP-4)** in the Pediatric Spine Imaging Guidelines
 - See: **Sacro-Iliac (SI) Joint Pain, Inflammatory Spondylitis/Sacroiliitis and Fibromyalgia (SP-10)**
 - See: **Post-Operative Spinal Disorders (SP-15)**

MRI of the Spine (SP-2.2)

SP.IM.0002.2.A

v2.0.2024

- See: **Procedure Codes Associated with Spine Imaging**
- For MR Spectroscopy, all spine uses are considered experimental and investigational
 - See: **Imaging of Intervertebral Discs (SP-2.5)**
- MRI Spine is performed either without contrast, with contrast *or* without and with contrast. A “with contrast” study alone is appropriate only to complete a study begun without contrast. Contrast is generally not indicated for most disc and nerve root disorders, fractures and degenerative disease.
- MRI Spine indications include:
 - Evaluation of disc disease, spinal cord and nerve root disorders and most other spinal conditions including evaluation of congenital anomalies of the spine and spinal cord
 - Suspicion for or surveillance of known spine/spinal canal/spinal cord neoplastic disease
 - Suspicion, diagnosis of or surveillance of spinal infections, multiple sclerosis or other causes of myelitis, syringomyelia, cauda equina syndrome or other “red flag” indications. See: **Red Flag Indications (SP-1.2)**.
 - Preoperative evaluation to define abnormal or variant spinal anatomy that could influence the outcome of a potential surgical procedure. See: **Prior to Spine Surgery (SP-16.1)**.
 - Spinal imaging for individuals having undergone recent spinal surgery e.g., laminectomy, discectomy, spinal decompression, when history and physical examination is suspicious for hematoma, post-surgical infection, or cerebrospinal fluid (CSF) leak.

Positional MRI:

- Positional MRI is also referred to as dynamic, weight-bearing or kinetic MRI. Currently, there is inadequate scientific evidence to support the medical necessity of this study. As such, it should be considered experimental or investigational.

CT of the Spine (SP-2.3)

SP.IM.0002.3.A
v2.0.2024

- See: **Procedure Codes Associated with Spine Imaging**
- CT Spine indications include:
 - Contraindication to MRI
 - CT (contrast as requested) can be approved when ANY of the following MRI contraindications are documented:
 - Implanted ferromagnetic materials
 - Electronically, magnetically or mechanically activated implanted devices that are not determined by the manufacturer as MRI compatible/conditional
 - CT without contrast, or CT without and with contrast (even if MRI has already been performed), for any spinal trauma/fractures, especially spinal trauma/fractures that could result in spinal instability and spinal cord/spinal nerve compression
 - CT without contrast, or CT without and with contrast (even if MRI has already been performed), for spinal neoplastic disease – primary or metastatic
 - CT without contrast, or CT without and with contrast (even if MRI has already been performed), in conjunction with myelography or discography (see: **CT/Myelography [SP-2.4]** and **Imaging of Intervertebral Discs [SP-2.5]**)
 - CT without contrast, or CT without and with contrast (even if MRI has already been performed), for preoperative evaluation to define abnormal or variant bony spinal anatomy that could influence the outcome of a potential surgical procedure (see: **Prior to Spine Surgery [SP-16.1]**)
 - CT without contrast, or CT without and with contrast, (even if MRI has already been performed), to assess spinal fusions when pseudoarthrosis is suspected (not to be used for routine post-operative assessment where x-rays are sufficient and/or there are no concordant clinical signs or symptoms)
 - CT without contrast, or CT without and with contrast (even if MRI has already been performed), for congenital, developmental or acquired spinal deformity (see: **Spinal Deformities [e.g. Scoliosis/Kyphosis] [SP-14]**)
 - CT without contrast, or CT without and with contrast, for spondylolysis when routine x-rays are negative and/or MRI is equivocal, indeterminate or non-diagnostic (see: **Lumbar Spine Spondylolysis/Spondylolisthesis [SP-8]**)
 - CT without contrast, or CT without and with contrast, to evaluate calcified lesions, (e.g., osteophytes, ossification of the posterior longitudinal ligament [OPLL])

CT/Myelography (SP-2.4)

SP.IM.0002.4.U

v2.0.2024

- See: **Procedure Codes Associated with Spine Imaging**
- CT/Myelography is generally unnecessary as an initial study when a diagnostic quality MRI has been obtained.
- CT/Myelography indications include:
 - To clarify equivocal, indeterminate or non-diagnostic MRI findings or to further evaluate the significance of multiple spinal abnormalities.
 - When an MRI is contraindicated (see: **CT of the Spine [SP-2.3]**).
 - Preoperative planning for spine surgery, (e.g., multilevel spinal stenosis or when a previous MRI is insufficient, equivocal, indeterminate or non-diagnostic). (see: **Prior to Spine Surgery (SP-16.1)**)
 - Evaluation after previous spinal surgery when an MRI without and with contrast is contraindicated or MRI results are equivocal, indeterminate or non-diagnostic.
 - United Healthcare authorizes only the post-myelogram CT (i.e., CPT® 72126, CPT® 72129, and CPT® 72132) and not any other myelogram-related procedure codes (i.e., CPT® 72265 or CPT® 62284).

Imaging of Intervertebral Discs (SP-2.5)

SP.IM.0002.5.A

v2.0.2024

Post-lumbar Discography CT:

- eviCore authorizes only the post-lumbar discography CT procedure codes and not any other discography-related procedure codes. A post-lumbar discography CT is considered medically necessary following an approved discography and ALL of the following apply:
 - A post-discography CT is coded as without contrast.
 - A CT Lumbar Spine without contrast (CPT® 72131) is appropriate if verified to be performed as a post-discography CT.
 - When a post-discography CT is requested and the discography has already been approved eviCore will issue authorization for the post-discography CT procedure codes.

Magnetic Resonance Spectroscopy:

- Magnetic Resonance Spectroscopy (MRS) involves the analysis of the levels of certain chemicals in pre-selected voxels (small regions) on an MRI scan done at the same time.
 - MRS (CPT® 76390, 0609T, 0610T, 0611T, and 0612T) is considered experimental and investigational for all spine imaging uses at this time.

Background and Supporting Information

- Provocative Discography/CT and MR Spectroscopy lumbar spine are procedures purported to diagnose (or rule-out) a discogenic “pain generator” i.e., the source of non-specific axial spinal pain. These diagnostic studies, when reported as positive, are often used as an indication for spinal fusion in individuals with non-specific axial back pain.
- The following uses of discography are considered controversial:
 - To identify a symptomatic pseudoarthrosis in a failed spinal fusion
 - To identify which of two herniated discs seen on MRI is symptomatic when not determined clinically or otherwise
 - To confirm the discogenic nature of pain in an individual with an abnormal disc seen on MRI and to rule out pain from an adjacent disc level
 - To confirm the presumptive diagnosis of “internal disc disruption”
 - Discography of the cervical and/or thoracic spine
- The following uses of MR Spectroscopy lumbar spine are considered controversial:
 - To identify which of two herniated discs seen on MRI is symptomatic when not determined clinically or otherwise

- To confirm the discogenic nature of pain in an individual with an abnormal disc seen on MRI and to rule out pain from an adjacent disc level
- To confirm the presumptive diagnosis of “internal disc disruption”

Ultrasound of the Spinal Canal (SP-2.6)

SP.IM.0002.6.A
v2.0.2024

- Spinal canal ultrasound (CPT® 76800) describes the evaluation of the spinal cord (canal and contents) most often performed in newborns, infants, young children and intraoperatively.
- CPT® 76800 describes evaluation of the entire spine and should not be reported multiple times for imaging of different areas of the spinal canal.
- CPT® 76998, rather than CPT® 76800, should be used to report intraoperative spinal canal ultrasound (ultrasonic guidance). Intraoperative use of spinal ultrasound (CPT® 76998) would not require prior authorization by eviCore.

Indications for spinal canal ultrasound (CPT® 76800):

- This study is generally limited to infants, newborns and young children because of incomplete ossification of the vertebral segments surrounding the spinal cord, including the assessment of CSF in the spinal canal and for image-guided lumbar puncture.
- When ossification of the vertebral segments is incomplete for evaluation of suspected or known tethered cord (see: **Tethered Cord [PEDSP-5]** in the Pediatric Spine Imaging Guidelines).
- Evaluation of suspected occult and non-occult spinal dysraphism (see: **Spinal Dysraphism [PEDSP-4]** in the Pediatric Spine Imaging Guidelines).
- Evaluation of spinal cord tumors, vascular malformations and cases of birth-related trauma.
- Contraindicated for use in the adult spine for the assessment of spinal pain, radiculopathy, facet inflammation, nerve root inflammation, disc herniation, and soft tissue conditions surrounding the adult spine other than for superficial masses.

Limitations of Spinal Imaging in Degenerative Disorders (SP-2.7)

SP.IM.0002.7.A

v2.0.2024

- Non-specific axial spinal pain is ubiquitous. Advanced diagnostic imaging infrequently identifies the source of the spinal pain (pain generator).
- Incidental findings on MRI and CT, including bulging, protruding, extruding or herniated discs, are often non-concordant, asymptomatic and increase in incidence as the spine ages.
- In individuals with poorly defined clinical presentations, “abnormal” spinal advanced diagnostic imaging results are infrequently clinically concordant, significant, material or substantive and may even lead to inappropriate treatment.
- Performing advanced spinal imaging based only on the presence of spinal degenerative findings identified on x-rays is not generally indicated in individuals who are either asymptomatic or present with non-specific axial spinal pain.

Miscellaneous Spinal Lesions (SP-2.8)

SP.IM.0002.8.A

v2.0.2024

Vertebral body hemangiomas:

- Vertebral body hemangiomas are common and are generally benign and incidental findings on plain x-rays and advanced diagnostic imaging studies.
- If the appearance of a vertebral body hemangioma is typical on plain x-ray, further spinal advanced diagnostic imaging is not usually required, unless there are associated neurologic symptoms or signs on physical examination.
- If the appearance of a vertebral body hemangioma is atypical on plain x-ray, with or without neurological signs or symptoms on physical exam, MRI without contrast or MRI without and with contrast is indicated.
- Occasionally, MRI may be equivocal, indeterminate or non-diagnostic and CT without contrast of the spinal area is indicated to help clarify the diagnosis.
- No follow-up imaging is necessary once the diagnosis of a vertebral body hemangioma is established without neurological features.

Tarlov cysts:

- Tarlov cysts are most often cystic dilatations of nerve root sleeves in the lumbar spine and sacrum.
- Controversy exists as to whether Tarlov cysts can result in neurologic signs and symptoms but they can result in erosion of the adjacent bone.
- Usually Tarlov cysts are benign, incidental findings on advanced diagnostic imaging studies. Further evaluation of a known or suspected Tarlov cyst can be performed with an MRI Lumbar Spine without and with contrast study (CPT[®] 72158) or CT/Myelography Lumbar Spine (CPT[®] 72132).

Other spinal lesions:

- MRI without and with contrast or a CT without contrast is appropriate if:
 - Other spinal lesions are seen on routine x-rays or a non-contrast MRI; **and**
 - These additional advanced imaging studies are recommended by a spine specialist or radiologist to further characterize or diagnose the lesion; **or**
 - Required for surgical planning.

MRA Spinal Canal (SP-2.9)

SP.IM.0002.9.A
v2.0.2024

- MRA Spine imaging is utilized infrequently.
- Cerebrospinal Fluid (CSF) flow studies using MRI are included in CPT® codes 70551, 70552, and 70553 and should not be coded or reported separately.

Indications may include:

- Suspected spinal cord arteriovenous malformation (AVM) or arteriovenous fistula (AVF):
 - MRI Spine of the relevant spine region without and with contrast should be the initial imaging study.
 - If suspicion for a spinal AVM or AVF is high based upon the results of the MRI Spine, catheter angiography is recommended (CPT® 72159 or CPT® 70496).
- Subarachnoid hemorrhage where no brain aneurysm has been previously identified
 - Catheter angiography (CPT® 70496) should be performed and is the most definitive study to define possible spinal pathology resulting in a spinal canal subarachnoid hemorrhage.
 - See: **General Guidelines – CT and MR Angiography (CTA and MRA) (HD-1.5)** in the Head Imaging Guidelines
 - See: **Intracranial Aneurysms (HD-12.1)** in the Head Imaging Guidelines
- Preoperative planning
 - MRA Spinal canal may be useful in identifying major intercostal feeder vessels to the spinal cord prior to surgical procedures that might interfere with this blood supply. However, catheter angiography (CPT® 72159) is generally a more definitive study for this purpose.

Spine PET/CT (SP-2.10)

SP.IM.0002.10.A

v2.0.2024

- At the present time there is controversy regarding spine PET/CT due to inadequate scientific evidence to support the medical necessity of PET/CT for the routine assessment of spinal disorders, other than for neoplastic disease.
- See: **Spinal/Vertebral Metastases (ONC-31.6)** in the Oncology Imaging Guidelines
- Spine PET/CT should be considered experimental or investigational.

Cone-beam CT (SP-2.11)

SP.IM.0002.11.A

v2.0.2024

- Cone-beam CT for imaging of the cervical spine should be considered experimental or investigational.

3D Rendering (SP-2.12)

SP.IM.0002.12.A

v2.0.2024

- See: **3D Rendering (MS-3)** in the Musculoskeletal Imaging Guidelines

References (SP-2)

v2.0.2024

1. American Academy of Neurology. Review of the literature on spinal ultrasound for the evaluation of back pain and radicular disorders. Report of the Therapeutics and Technology Assessment Subcommittee of the American Academy of Neurology. *Neurology*. 1998; 51:343-344. Reaffirmed July 13, 2013.
2. Weishaupt D, Schmid MR, Zanetti M, et al. Positional MR imaging of the lumbar spine: does it demonstrate nerve root compromise not visible at conventional MR imaging? *Radiology*. 2000;215:247-253.
3. Zhang L, Zeitoun D, Rangel A, et al. Preoperative evaluation of the cervical spondylotic myelopathy with flexion-extension magnetic resonance imaging. *Spine Journal*. 2011; 36(17): E1134-E1139.
4. Deyo RA, Dieh AK, Rosenthal M. Reducing roentgenography use. *Arch Intern Med*. 1987;147(1):141-145. doi:10.1001/archinte.1987.00370010139029.
5. North American Spine Society (NASS). Diagnosis and treatment of lumbar disc herniation with radiculopathy. Technical Report. 2012. Available at: <https://www.spine.org/researchclinicalcare/qualityimprovement/clinicalguidelines.aspx>.

Neck (Cervical Spine) Pain Without/With Neurological Features (Including Stenosis) and Trauma (SP-3)

Guideline

Neck (Cervical Spine) Pain without and with Neurological Features
(Including Stenosis) (SP-3.1)

Neck (Cervical Spine) Trauma (SP-3.2)

References (SP-3)

Neck (Cervical Spine) Pain without and with Neurological Features (Including Stenosis) (SP-3.1)

SP.NP.0003.1.A
v2.0.2024

All of the following are required prior to advanced imaging:

- Initial clinical evaluation performed.
- A face-to-face evaluation within the last 60 days.
- The initial evaluation is not required within the last 60 days if another face-to-face evaluation was performed in that time frame. This may be satisfied by the initial evaluation, re-evaluation or another visit.
- Failure of recent (within 3 months) 6-week trial of provider-directed treatment (unless presence of a red flag as defined in **Red Flag Indications [SP-1.2]**)
- Clinical re-evaluation after treatment period (may consist of a face-to-face evaluation or other meaningful contact (see also: **General Guidelines [SP-1.0]**)

Advanced Diagnostic Imaging:	MRI Cervical Spine, without contrast (CPT® 72141)
Comments:	CT Cervical Spine without contrast (CPT® 72125) OR CT Myelography (CPT® 72126) is appropriate when MRI is contraindicated.

Neck (Cervical Spine) Trauma (SP-3.2)

SP.NP.0003.2.A
v2.0.2024

All of the following are required prior to advanced imaging:

- Initial clinical evaluation performed.
- A face-to-face evaluation within the last 60 days.
- The initial evaluation is not required within the last 60 days if another face-to-face evaluation was performed in that time frame. This may be satisfied by the initial evaluation, re-evaluation or another visit.
- Failure of recent (within 3 months) 6-week trial of provider-directed treatment (unless presence of a red flag as defined in **Red Flag Indications [SP-1.2]**)
- Clinical re-evaluation after treatment period (may consist of a face-to-face evaluation or other meaningful contact (see also: **General Guidelines [SP-1.0]**)
- Results of plain x-rays of the cervical spine performed after the current episode of symptoms started or changed need to be available to the requesting provider (not required for high risk mechanisms as below**)

Advanced Diagnostic Imaging:	MRI Cervical Spine without contrast (CPT® 72141) OR CT Cervical Spine without contrast (CPT® 72125): For individuals with ankylosing spondylitis or DISH (diffuse idiopathic skeletal hyperostosis), both MRI of the whole spine (CPT® 72141, 72146, and/or 72148) and CT of the whole spine (CPT® 72125, 72128, and/or 72131) can be approved. Plain x-rays and a 6 week trial of provider-directed treatment and clinical evaluation are <u>NOT</u> required.
Comments:	<p>Plain x-rays are required for suspected fracture in non-high risk injuries.</p> <p>Plain x-rays and a 6 week trial of provider-directed treatment and clinical re-evaluation are NOT required for individuals with a high risk factor(s) for suspected cervical spine injury within the last 3 months (See below**).</p>

**High risk factors of suspected cervical spine injury may include:

- Long term use of systemic glucocorticoids
- History of prior low energy fractures
- History of low bone mineral density
- Age ≥65 years
- Head trauma and/or maxillofacial trauma
- Pedestrian in a motor vehicle accident
- Fall from elevation ≥3 feet/5 stairs

- Diving accident
- Head-on motor vehicle collision without/with airbag deployment
- Rollover motor vehicle collision
- Ejection from the vehicle in a motor vehicle collision
- High speed of the vehicle at the time of collision
- Not wearing a seatbelt/shoulder harness in a motor vehicle collision
- Minor direct/indirect trauma to the cervical spine/maxillofacial areas in individuals with ankylosing spondylitis or DISH

Background and Supporting Information

- Pain radiation patterns from the cervical spine area into the thoracic spine area do not necessarily justify the addition of thoracic spine advanced diagnostic imaging.
- Cervical radiculopathy is often confused with shoulder disorders, brachial plexopathy, peripheral nerve entrapment and/or motor/sensory neuropathies. Electrodiagnostic testing (EMGs/NCVs) is generally used to confirm, not establish, a diagnosis of peripheral nerve entrapment and/or a motor/sensory neuropathy based upon history and physical examination findings. Electrodiagnostic testing is often considered when advanced imaging of the spine does not reveal neurocompressive pathology and/or after 6 weeks of unimproved symptoms of extremity pain, weakness, numbness and/or tingling.
- Individuals with ankylosing spondylitis or DISH are at high risk of cervical spine fractures even with minor direct/indirect trauma to the cervical spine which can result in quadriparesis/quadriplegia

References (SP-3)

v2.0.2024

1. Thompson WL, Stiell IG, Clement CM, et al. Association of injury mechanism with the risk of cervical spine fractures. *CJEM*. 2009;11(1):14-22.
2. Bogduk N, Karasek M. Precision diagnosis and treatment of back and neck pain. *Continuum: Pain and Palliative Care*. 2005;11(6):94-136.
3. Levin KH, Covington ED, Devereaux MW, et al. Neck and back pain part A. *Continuum*. 2001;7(1):142-151.
4. Werner, B, Samartzis, D, Shen, F. Spinal fractures in patients with ankylosing spondylitis: etiology, diagnosis and management. *JAAOS*. 2016;24(4):241-249.
5. Koivikko MP, Koskinen SK. MRI of cervical spine injuries complicating ankylosing spondylitis. *Skeletal Radiology*. 2008;37(9):813-819.
6. Hoffman JR, Mower WR, Wolfson AB, Todd KH, Zucker MI. Validity of a set of clinical criteria to rule out injury to the cervical spine in patients with blunt trauma. National Emergency X-Radiography. Utilization Study Group. *N Engl J Med*. 2000;343(2):94-99.
7. Daffner RH, Weissman BN, Wippold FJ, et. al. Expert Panels on Musculoskeletal and Neurologic Imaging. ACR Appropriateness Criteria®: Suspected Spine Trauma. American College of Radiology (ACR); Date of Origin: 1999. Last Review: 2018.
8. Newman JS, Weissman BN, Angevine PD, et. al. Expert Panel on Musculoskeletal Imaging. ACR Appropriateness Criteria®: Chronic Neck Pain. American College of Radiology (ACR); Date of Origin: 1998. Revised: 2018. <https://acsearch.acr.org/docs/69426/Narrative/>.
9. Bernard SA, Kransdorf MJ, Beaman FD, et. al. Expert Panel on Musculoskeletal Imaging. ACR Appropriateness Criteria®: Chronic Back Pain: Suspected Sacroiliitis/Spondyloarthropathy. American College of Radiology (ACR); Date of Origin: 2016. Revised: 2021. <https://acsearch.acr.org/docs/3094107/Narrative/>.
10. Lantsman CD, Barkay G, Friedlander A, Barbi M, Stern M, Eshed I. Whole spine CT scan for the detection of acute spinal fractures in Diffuse Idiopathic Skeletal Hyperostosis patients who sustained low-energy trauma. *Spine*. 2020;45(19):1348-1353. doi:10.1097/BRS.0000000000003536.
11. Saragiotto BT, Maher CG, Lin CC, Verhagen AP, Goergen S, Michaleff ZA. Canadian C-spine rule and the National Emergency X-Radiography Utilization Study (NEXUS) for detecting clinically important cervical spine injury following blunt trauma. *Cochrane Database Syst Rev*. 2018;2018(4):CD012989. doi:10.1002/14651858.CD012989.
12. Le HV, Wick JB, Van BW, Klineberg EO. Diffuse idiopathic skeletal hyperostosis of the spine: pathophysiology, diagnosis, and management. *J Am Acad Orthop Surg*. 2021;29:1044-1051. doi:10.5435/JAAOS-D-20-01344.

Upper Back (Thoracic Spine) Pain Without/With Neurological Features (Including Stenosis) and Trauma (SP-4)

Guideline

Upper Back (Thoracic Spine) Pain without and with Neurological Features (Including Stenosis) (SP-4.1)

Upper Back (Thoracic Spine) Trauma (SP-4.2)

References (SP-4)

Upper Back (Thoracic Spine) Pain without and with Neurological Features (Including Stenosis) (SP-4.1)

SP.TS.0004.1.A
v2.0.2024

All of the following are required prior to advanced imaging:

- Initial clinical evaluation performed.
- A face-to-face evaluation within the last 60 days.
- The initial evaluation is not required within the last 60 days if another face-to-face evaluation was performed in that time frame. This may be satisfied by the initial evaluation, re-evaluation or another visit.
- Failure of recent (within 3 months) 6-week trial of provider-directed treatment (unless presence of a red flag as defined in **Red Flag Indications [SP-1.2]**).
- Clinical re-evaluation after treatment period (may consist of a face-to-face evaluation or other meaningful contact (see also: **General Guidelines [SP-1.0]**).

Advanced Diagnostic Imaging:	MRI Thoracic Spine without contrast (CPT® 72146)
Comments:	A CT Thoracic spine without contrast (CPT® 72128) OR CT Myelography (CPT® 72129) is appropriate when MRI is contraindicated.

Upper Back (Thoracic Spine) Trauma (SP-4.2)

SP.TS.0004.2.A

v2.0.2024

All of the following are required prior to advanced imaging:

- Initial clinical evaluation performed.
- A face-to-face evaluation within the last 60 days.
- The initial evaluation is not required within the last 60 days if another face-to-face evaluation was performed in that time frame. This may be satisfied by the initial evaluation, re-evaluation or another visit.
- Failure of recent (within 3 months) 6-week trial of provider-directed treatment (unless presence of a red flag as defined in **Red Flag Indications (SP-1.2)**, e.g. fracture).
- Clinical re-evaluation after treatment period (may consist of a face-to-face evaluation or other meaningful contact (see also: **General Guidelines (SP-1.0)**).
- Results of plain x-rays of thoracic spine performed after the current episode of symptoms started or changed need to be available to the requesting provider

Advanced Diagnostic Imaging:	MRI Thoracic Spine without contrast (CPT® 72146) OR CT Thoracic Spine without contrast (CPT® 72128)
Comments:	For individuals with ankylosing spondylitis or DISH (diffuse idiopathic skeletal hyperostosis), both MRI of the whole spine (CPT® 72141, 72146, and/or 72148) and CT of the whole spine (CPT® 72125, 72128, and/or 72131) can be approved. Plain x-rays and a 6 week trial of provider-directed treatment and clinical evaluation are <u>NOT</u> required

Background and Supporting Information

- Thoracic radiculopathy presents with pain radiation from the thoracic spine around the trunk. At upper thoracic spine levels, the pain radiation is from the thoracic spine around the rib cage following the sensory distribution of an intercostal nerve.
- Advanced diagnostic imaging is generally not appropriate in evaluation of axial low back pain with radiation toward the thoracic region unless there are documented clinical features indicating a thoracic spine disorder.

References (SP-4)

v2.0.2024

1. Nadgir R, Yousem DM. *Neuroradiology: the requisites*. Philadelphia, PA: Elsevier; 2017.
2. Daffner RH, Weissman BN, Wippold FJ, et. al. Expert Panels on Musculoskeletal and Neurologic Imaging. ACR Appropriateness Criteria®: *Suspected Spine Trauma*. American College of Radiology (ACR); Date of Origin: 1999. Last Review: 2018. <https://acsearch.acr.org/docs/69359/Narrative/>.
3. Lantsman CD, Barkay G, Friedlander A, Barbi M, Stern M, Eshed I. Whole spine CT scan for the detection of acute spinal fractures in Diffuse Idiopathic Skeletal Hyperostosis patients who sustained low-energy trauma. *Spine*. 2020;45(19):1348-1353. doi:10.1097/BRS.0000000000003536.
4. Le HV, Wick JB, Van BW, Klineberg EO. Diffuse idiopathic skeletal hyperostosis of the spine: pathophysiology, diagnosis, and management. *J Am Acad Orthop Surg*. 2021;29:1044-1051. doi:10.5435/JAAOS-D-20-01344.

Low Back (Lumbar Spine) Pain/Coccydynia without Neurological Features (SP-5)

Guideline

Low Back (Lumbar Spine) Pain without Neurological Features (SP-5.1)

Coccydynia without Neurological Features (SP-5.2)

References (SP-5)

Low Back (Lumbar Spine) Pain without Neurological Features (SP-5.1)

SP.LB.0005.1.A

v2.0.2024

All of the following are required prior to advanced imaging:

- Initial clinical evaluation performed.
- A face-to-face evaluation within the last 60 days.
- The initial evaluation is not required within the last 60 days if another face-to-face evaluation was performed in that time frame. This may be satisfied by the initial evaluation, re-evaluation or another visit.
- Failure of recent (within 3 months) 6-week trial of provider-directed treatment (unless presence of a red flag as defined in **Red Flag Indications (SP-1.2)**).
- Clinical re-evaluation after treatment period (may consist of a face-to-face evaluation or other meaningful contact (see also: **General Guidelines (SP-1.0)**))

Advanced Diagnostic Imaging:	MRI Lumbar Spine without contrast (CPT® 72148)
Comments:	A CT Lumbar spine without contrast (CPT® 72131) or CT Myelography (CPT® 72132) is appropriate when MRI is contraindicated

Coccydynia without Neurological Features (SP-5.2)

SP.LB.0005.2.A

v2.0.2024

All of the following are required prior to advanced imaging:

- Initial clinical evaluation performed.
- A face-to-face evaluation within the last 60 days.
- The initial evaluation is not required within the last 60 days if another face-to-face evaluation was performed in that time frame. This may be satisfied by the initial evaluation, re-evaluation or another visit.
- Failure of recent (within 3 months) 6-week trial of provider-directed treatment (unless presence of a red flag as defined in **Red Flag Indications (SP-1.2)**, e.g. fracture).
- Clinical re-evaluation after treatment period (may consist of a face-to-face evaluation or other meaningful contact (see also: **General Guidelines (SP-1.0)**)
- Plain x-rays of the sacrum/coccyx are negative for fracture.

Advanced Diagnostic Imaging:	MRI Pelvis without contrast (CPT® 72195)
Comments:	A CT Pelvis without contrast (CPT® 72192) when MRI is contraindicated.

Background and Supporting Information

Coccydynia is often reported by individuals as “tailbone” pain that is usually idiopathic or post-traumatic and generally follows a benign course.

References (SP-5)

v2.0.2024

1. Puhakka KB. Magnetic resonance imaging of sacroiliitis in early seronegative spondyloarthropathy. Abnormalities correlated to clinical and laboratory findings. *Rheumatology*. 2003;43(2):234-237. doi:10.1093/rheumatology/keh008.
2. Rao, RD, Smuck M. Orthopaedic Knowledge Update 4: Spine, AAOS, 41:477-478.
3. American Academy of Orthopedic Surgeons (AAOS) clinical guidelines on low back pain/sciatica (acute) (phase I and II). Clinical Practice Guidelines.
4. NASS Task Force on clinical guidelines. Herniated disc. In: *Phase III clinical guidelines for multidisciplinary spine care specialists*. Unremitting low back pain. 1st ed. Burr Ridge, IL: North American Spine Society; 2000.
5. Chou R, Qaseem A, Owens DK, et al. Diagnostic imaging for low back pain: Advice for high-value health care from the American College of Physicians. *Ann Intern Med*. 2011;154:181-189.
6. Roudsari B, Jarvik JG. Lumbar spine MRI for low back pain: indications and yield. *AJR*. 2010;195:550-559.
7. Weinstein JN, Lurie JD, Tosteson TD, et al. Surgical versus nonoperative treatment for lumbar disc herniation. *Spine*. 2008;33(25):2789-2800.
8. Chou R, Qaseem A, Snow V, et al. Diagnosis and treatment of low back pain: a joint clinical practice guideline from the American College of Physicians and the American Pain Society. *Ann Intern Med*. 2007;147:478-491.
9. Levin KH, Covington ED, Devereaux MW, et al. Neck and back pain part A. *Continuum*. 2001;7(1):142-151.
10. Roudsari B, Jarvik JG. Lumbar spine MRI for low back pain: indications and yield. *American Journal of Roentgenology*. 2010;195(3):550-559. doi:10.2214/ajr.10.4367.
11. Cherkin DC, Deyo RA, Battié M, Street J, Barlow W. A comparison of physical therapy, chiropractic manipulation, and provision of an educational booklet for the treatment of patients with low back pain. *New England Journal of Medicine*. 1998;339(15):1021-1029. doi:10.1056/nejm199810083391502.
12. Lieberman JR, ed. AAOS comprehensive orthopaedic review 2009. Rosemont, IL.: AAOS (American Academy of Orthopaedic Surgeons); 2009.
13. Deyo RA, Mirza SK, Turner JA, et al. Overtreating chronic back pain: time to back off? *J Am Board Fam Med*. 2009;22(1):62-68.
14. Jarvik JG, Deyo R. Diagnostic evaluation of low back pain with emphasis on imaging. *Ann Intern Med*. 2000;137:586-597.
15. Gillan MGC, Gilbert FJ, Andrew JE. Influence of imaging on clinical decision making in the treatment of low back pain. *Radiol*. 2001;220:393-395.
16. Deyo RA, Weinstein JN. Low back pain. *N Engl J Med*. 2001;344(5):363-370.
17. Carragee EJ. Persistent low back pain. *N Engl J Med*. 2005;352:1891-1898.
18. Sheybani EF, Khanna G, White AJ, Demertzis JL. Imaging of juvenile idiopathic arthritis: a multimodality approach. *Radiographics*. 2013;33(5):1253-1273.
19. Restropo R, Lee EY, Babyn PS. Juvenile idiopathic arthritis: Current practical imaging assessment with emphasis on magnetic resonance imaging. *Radiol Clin N Am*. 2013;51:703-719.
20. Landewe RBM, Hermann KGA, Van Der Heijde DMFM, Baraliakos X, et al. Scoring sacroiliac joints by magnetic resonance imaging. A multiple-reader reliability experiment. *The Journal of Rheumatology*. 2005;32:10.
21. Lambert RGW, Salonen D, Rahman P, Inman RD, et al. Adalimumab significantly reduces both spinal and sacroiliac joint inflammation in patients with ankylosing spondylitis. *Arthritis & Rheumatism*. 2007;56(12):4005-4014.
22. Modic M, Obuchowski N, Ross J, et al. Acute low back pain and radiculopathy: MR imaging findings and their prognostic role and effect on outcome. *Neuroradiology*. 2005;237:597-604. doi:10.1148/radiol.2372041509.
23. Jarvik JG, Gold LS, Comstock BA, et al. Association of early imaging for back pain with clinical outcomes in older patients. *JAMA*. 2015;313(11):1143-1153. doi:10.1001/jama.2015.1871.
24. Ayers JW, Leas EC, Dredze M, et al. Clinicians' perceptions of barriers to avoiding inappropriate imaging for low back pain-knowing is not enough. *JAMA*. 2014;311(14):1399-1400. doi:10.1001/jamainternmed.2016.6274.
25. Panagopoulos J, Hush J, Steffens D, et al. Do MRI findings change over a period of up to 1 year in patients with low back pain and/or sciatica. *Spine Journal*. 2017;42:504-512. doi:10.1097/BRS.0000000000001790.
26. Gilbert FJ, Grant AM, Gillan MG, et al. Low back pain: influence of early MR imaging or CT on treatment and outcome-multicenter randomized trial. *Radiology*. 2004; 231:343-351. doi:10.1148/radiol.2312030886.
27. Kerry S, Hilton S, Dundas D, et al. Radiography for low back pain: a randomized controlled trial and observational study in primary care. *British Journal of General Practice*. 2002;52:469-474.

28. Djais N, Kalim H. The role of lumbar spine radiography in the outcomes of patients with simple acute low back pain. *APLAR Journal of Rheumatology*. 2005;8:45-50.
29. Patel ND, Broderick DF, Burns J, et. al. Expert Panel on Neurologic Imaging. ACR Appropriateness Criteria®: Low Back Pain. *American College of Radiology (ACR)*; Date of Origin: 1996. Revised: 2021. <https://acsearch.acr.org/docs/69483/Narrative/>.
30. Deyo RA, Rainville J, Kent DL. What can the history and physical examination tell us about low back pain? *JAMA*. 1992;268(6):760-765.
31. Patrick N, Emanski E, Knaub MA. Acute and Chronic Low Back Pain. *Med Clin N Am*. 2016; 100:169–181.
32. Chutkan NB, Lipson AC, Lisi AJ, et. al. Evidence-based clinical guidelines for multidisciplinary spine care: diagnosis and treatment of low back pain. Burr Ridge, IL: North American Spine Society. 2020.

Lower Extremity Pain with Neurological Features (Radiculopathy, Radiculitis, or Plexopathy and Neuropathy) With or Without Low Back (Lumbar Spine) Pain (SP-6)

Guideline

Lower Extremity Pain with Neurological Features (Radiculopathy, Radiculitis, or Plexopathy and Neuropathy) with or without Low Back (Lumbar Spine) Pain (SP-6.1)

Low Back (Lumbar Spine) Trauma (SP-6.2)

References (SP-6)

Lower Extremity Pain with Neurological Features (Radiculopathy, Radiculitis, or Plexopathy and Neuropathy) with or without Low Back (Lumbar Spine) Pain (SP-6.1)

SP.LE.0006.1.A
v2.0.2024

All of the following are required prior to advanced imaging:

- Initial clinical evaluation performed.
- A face-to-face evaluation within the last 60 days.
- The initial evaluation is not required within the last 60 days if another face-to-face evaluation was performed in that time frame. This may be satisfied by the initial evaluation, re-evaluation or another visit.
- Failure of recent (within 3 months) 6-week trial of provider-directed treatment (unless presence of a red flag as defined in **Red Flag Indications (SP-1.2)**).
- Clinical re-evaluation after treatment period (may consist of a face-to-face evaluation or other meaningful contact (see also: **General Guidelines (SP-1.0)**).

Advanced Diagnostic Imaging:	MRI Lumbar Spine without contrast (CPT® 72148)
Comments:	A CT Lumbar spine without contrast (CPT® 72131) OR CT Myelography (CPT® 72132) is appropriate when MRI is contraindicated. See also: Lumbar Spinal Stenosis (SP-9.1)

Low Back (Lumbar Spine) Trauma (SP-6.2)

SP.LE.0006.2.A

v2.0.2024

All of the following are required prior to advanced imaging:

- Initial clinical evaluation performed.
- A face-to-face evaluation within the last 60 days.
- The initial evaluation is not required within the last 60 days if another face-to-face evaluation was performed in that time frame. This may be satisfied by the initial evaluation, re-evaluation or another visit.
- Failure of recent (within 3 months) 6-week trial of provider-directed treatment (unless presence of a red flag as defined in **Red Flag Indications (SP-1.2)**).
- Clinical re-evaluation after treatment period (may consist of a face-to-face evaluation or other meaningful contact (see also: **General Guidelines (SP-1.0)**).
- Results of plain x-rays of the lumbar spine performed after the current episode of symptoms started or changed need to be available to the requesting provider

Advanced Diagnostic Imaging:	MRI Lumbar Spine without contrast (CPT® 72148) OR MRI Lumbar Spine without and with contrast (CPT® 72158) OR CT Lumbar Spine without contrast (CPT® 72131) OR CT myelogram (CPT® 72132)
Comments:	For individuals with ankylosing spondylitis or DISH (diffuse idiopathic skeletal hyperostosis), both MRI of the whole spine (CPT® 72141, 72146, and/or 72148) and CT of the whole spine (CPT® 72125, 72128, and/or 72131) can be approved. Plain x-rays and a 6 week trial of provider-directed treatment and clinical evaluation are NOT required.

- Definitions of radiculopathy, radiculitis and radicular pain: See **Definitions (SP-1.3)**
- Sciatic Neuropathy, Femoral Neuropathy, Peroneal Neuropathy and Meralgia Paresthetica: See **Focal Neuropathy (PN-2)** in the Peripheral Nerve Disorders Imaging Guidelines
- Lumbar and/or Lumbosacral Plexopathy: See **Lumbar and Lumbosacral Plexus (PN-5)** in the Peripheral Nerve Disorders Imaging Guidelines
- Advanced imaging of the hip or pelvis is not generally required in the evaluation of apparent lumbar radiculopathy unless a separate recognized indication for such studies is documented. See: **Hip (MS-24)** in the Musculoskeletal Imaging Guidelines.

References (SP-6)

v2.0.2024

1. Puhakka KB, Jurik AG, Schiottz-Christensen B, et al. Magnetic resonance imaging of sacroiliitis in early seronegative spondyloarthritis. Abnormalities associated to clinical and laboratory findings. *Rheumatology*. 2004;43(2):234-237.
2. Rao, RD, Smuck M. Orthopaedic Knowledge Update 4: *Spine*. AAOS. 41:477-478.
3. American Academy of Orthopedic Surgeons (AAOS) clinical guidelines on low back pain/sciatica (acute) (phase I and II). Clinical Practice Guidelines.
4. NASS Task Force on clinical guidelines. *Herniated disc*. In: Phase III clinical guidelines for multidisciplinary spine care specialists. Unremitting low back pain. 1st ed. Burr Ridge, IL: North American Spine Society; 2000.
5. Chou R. Diagnostic imaging for low back pain: advice for high-value health care from the American College of Physicians. *Annals of Internal Medicine*. 2011;154(3):181-189. doi:10.7326/0003-4819-154-3-201102010-00008.
6. Roudsari B, Jarvik JG. Lumbar spine MRI for low back pain: indications and yield. *American Journal of Roentgenology*. 2010;195(3):550-559. doi:10.2214/ajr.10.4367.
7. Weinstein JN, Lurie JD, Tosteson TD, et al. Surgical versus nonsurgical treatment for lumbar degenerative spondylolisthesis. *New England Journal of Medicine*. 2007;356(22):2257-2270. doi:10.1056/nejmoa070302.
8. Chou R, Qaseam A, Snow V, et al. Diagnosis and treatment of low back pain: A joint clinical practice guideline from the American College of Physicians and the American Pain Society. *Ann Intern Med* 2007;147:478-491.
9. Levin KH, Covington ED, Devereaux MW, et al. Neck and back pain part A. *Continuum*. 2001;7(1):142-151.
10. Cherkin DC, Deyo RA, Battié M, Street J, Barlow W. A comparison of physical therapy, chiropractic manipulation, and provision of an educational booklet for the treatment of patients with low back Pain. *New England Journal of Medicine*. 1998;339(15):1021-1029. doi:10.1056/nejm199810083391502.
11. Lieberman JR, ed. *AAOS comprehensive orthopaedic review 2009*. Rosemont, IL: AAOS (American Academy of Orthopaedic Surgeons); 2009.
12. Deyo RA, Mirza SK, Turner JA, et al. Overtreating chronic back pain: time to back off? *J Am Board Fam Med*. 2009;22(1):62-68.
13. Jarvik JG, Deyo R. Diagnostic evaluation of low back pain with emphasis on imaging. *Ann Intern Med*. 2000;137:586-597.
14. Gillan MGC, Gilbert FJ, Andrew JE. Influence of imaging on clinical decision making in the treatment of low back pain. *Radiol*, 2001; 220:393-395.
15. Deyo RA, Weinstein JN. Low back pain. *N Engl J Med*. 2001;344(5):363-370.
16. Carragee EJ. Persistent low back pain. *N Engl J Med*. 2005;352:1891-1898.
17. Sheybani EF, Khanna G, White AJ, Demertzis JL. Imaging of juvenile idiopathic arthritis: A multimodality approach. *Radiographics*. 2013;33(5):1253-1273.
18. Restropo R, Lee EY, Babyn PS. Juvenile idiopathic arthritis: Current practical imaging assessment with emphasis on magnetic resonance imaging. *Radiol Clin N Am*. 2013;51:703-719.
19. Landewe RBM, Hermann KGA, Van Der Heijde DMFM, Baraliakos X, et al. Scoring sacroiliac joints by magnetic resonance imaging. A multiple-reader reliability experiment. *The Journal of Rheumatology*. 2005;32:10.
20. Lambert RGW, Salonen D, Rahman P, Inman RD, et al. Adalimumab significantly reduces both spinal and sacroiliac joint inflammation in patients with ankylosing spondylitis. *Arthritis & Rheumatism*. 2007; 56(12):4005-4014.
21. Panagopoulos J, Hush J, Steffens D, et al. Do MRI findings change over a period of up to 1 year in patients with low back pain and/or sciatica. *Spine Journal*. 2017;42:504-512. doi:10.1097/BRS.0000000000001790.
22. Gilbert FJ, Grant AM, Gillan MG, et al. Low back pain: influence of early MR imaging or CT on treatment and outcome-multicenter randomized trial. *Radiology*. 2004;231:343-351. doi:10.1148/radiol.2312030886.
23. Modic M, Obuchowski N, Ross J, et al. Acute low back pain and radiculopathy: MR imaging findings and their prognostic role and effect on outcome. *Neuroradiology*. 2005;237:597-604. doi:10.1148/radiol.2372041509.
24. Barzouhi A, Vleggeert-Lankamp C, Lycklama a Nijehold G, et al. Magnetic resonance imaging in follow-up assessment of sciatica. *N Engl J Med*. 2013;368;11:999-1007.
25. Deyo RA, Rainville J, Kent DL. What can the history and physical examination tell us about low back pain? *JAMA*. 1992;268(6): 760-765.

26. Hutchins TA, Peckham M, Shah LM, et. al. Expert Panel on Neurologic Imaging. ACR Appropriateness Criteria®: Low Back Pain. American College of Radiology (ACR); Date of Origin: 1996. Revised: 2021. <https://acsearch.acr.org/docs/69483/Narrative/>.
27. Daffner RH, Weissman BN, Wippold FJ, et. al. Expert Panels on Musculoskeletal and Neurologic Imaging. ACR Appropriateness Criteria®: Suspected Spine Trauma. American College of Radiology (ACR); Date of Origin: 1999. Revised: 2018. <https://acsearch.acr.org/docs/69359/Narrative/>.
28. Lantsman CD, Barkay G, Friedlander A, Barbi M, Stern M, Eshed I. Whole spine CT scan for the detection of acute spinal fractures in Diffuse Idiopathic Skeletal Hyperostosis patients who sustained low-energy trauma. *Spine*. 2020;45(19):1348-1353. doi:10.1097/BRS.0000000000003536.
29. Chutkan NB, Lipson AC, Lisi AJ, et. al. Evidence-based clinical guidelines for multidisciplinary spine care: diagnosis and treatment of low back pain. Burr Ridge, IL: North American Spine Society. 2020.
30. Le HV, Wick JB, Van BW, Klineberg EO. Diffuse idiopathic skeletal hyperostosis of the spine: pathophysiology, diagnosis, and management. *J Am Acad Orthop Surg*. 2021;29:1044-1051. doi:10.5435/JAAOS-D-20-01344.
31. Chou R, Fu R, Carrino JA, Deyo RA. Imaging strategies for low-back pain: systematic review and meta-analysis. *Lancet*. 2009;373:462-472.

Myelopathy (SP-7)

Guideline

Myelopathy (SP-7.1)

References (SP-7)

Myelopathy (SP-7.1)

SP.MI.0007.1.A

v2.0.2024

- Myelopathy is the development of abnormal spinal cord function with long tract signs usually secondary to spinal cord compression, but also inflammation (transverse myelitis, MS, etc.), neoplastic disease or spinal cord infarction.
 - For imaging of transverse myelitis, see: **Transverse Myelitis (HD-16.4)** in the Head Imaging Guidelines
- Examination findings may include loss of manual dexterity, spastic legs, ataxia with hyperreflexia, upgoing toes (positive Babinski), Hoffmann's sign, sustained clonus, Lhermitte's sign, crossed radial reflex, inverted radial reflex, and/or finger escape sign. Sensory level and urinary incontinence/retention may be seen.
 - Advanced imaging is generally appropriate in the initial evaluation of documented or reasonably suspected myelopathy.
- X-rays are not required for advanced imaging in individuals with potential myelopathy regardless of any history of spine surgery, trauma, or other reasons which may otherwise require x-rays (e.g., **Neck (Cervical Spine) Trauma (SP-3.2)**, **Upper Back (Thoracic Spine) Trauma (SP-4.2)**, **Post-Operative Spinal Disorders (SP-15)**).
- Conservative treatment is not a requirement for advanced imaging in individuals with potential myelopathy.
- MRI Cervical and Thoracic Spine without contrast, or without and with contrast, are appropriate for:
 - Evaluation of reasonably suspected myelopathy
 - Post-traumatic syrinx with increased spinal pain or a worsening neurological symptoms
 - Sustained, prominent, and unexplained Lhermitte's sign
 - Unexplained Babinski's or Hoffmann's signs
 - Unexplained hyperreflexia
 - Unexplained bilateral motor weakness
- MRI Cervical, Thoracic, and Lumbar Spine without contrast, or without and with contrast, are appropriate for:
 - Suspected tethered cord and/or low lying conus medullaris.
- CT without contrast, or CT with contrast (myelography), can also be considered for either of the following:
 - An alternative to MRI, when MRI is contraindicated
 - In addition to MRI, for surgical planning

Background and Supporting Information

Lhermitte's sign – With the individual in the long leg sitting position on the examination table, the examiner passively flexes the individual's head and one hip simultaneously with the leg kept straight. A positive test occurs if there is sharp pain down the spine and into the upper or lower extremities.

Babinski's sign – The examiner runs a sharp instrument along the plantar surface of the foot from the calcaneus along the lateral border to the forefoot. A positive test occurs with extension of the great toe with flexion and splaying of the other toes. A negative test occurs with no movement of the toes at all or uniform bunching up of the toes.

Hoffman's sign – The examiner holds the individual's middle finger and briskly flicks the distal phalanx. A positive test is noted if the interphalangeal joint of the thumb of the same hand flexes.

References (SP-7)

v2.0.2024

1. Green C, Butler J, Eustace S, Poynton A, Obyrne JM. Imaging Modalities for Cervical Spondylotic Stenosis and Myelopathy. *Advances in Orthopedics*. 2012;2012:1-4. doi:10.1155/2012/908324.
2. Avadhani A, Rajasekaran S, Shetty AP. Comparison of prognostic value of different MRI classifications of signal intensity change in cervical spondylotic myelopathy. *Spine Journal*. 2010;10:475-485.
3. Harada T, Tsuji Y, Mikami Y et al. The clinical usefulness of preoperative dynamic MRI to select decompression levels for cervical spondylotic myelopathy. *Magnetic Resonance Imaging*. 2010;28:820-826.
4. Ohshio I, Hatayama K, Takahara M, Nagashima K. Correlation between histopathologic features and magnetic resonance images of spinal cord lesions. *Spine*. 1993;18:1140-1149.
5. Roth CJ, Angevine PD, Aulino JM, et. al. Expert Panel on Neurologic Imaging. ACR Appropriateness Criteria®: Myelopathy. American College of Radiology (ACR); Date of Origin: 1996. Revised: 2020. <https://acsearch.acr.org/docs/69484/Narrative/>.
6. Zhang L, Zeitoun D, Rangel A, et al. Preoperative evaluation of the cervical spondylotic myelopathy with flexion-extension magnetic resonance imaging. *Spine Journal*. 2011;36(17): E1134-E1139.
7. Magee DJ. *Orthopedic Physical Assessment*. 4th ed. Philadelphia, PA: Saunders; 2002.
8. Hoppenfeld S. *Physical Examination of the Spine and Extremities*. Upper Saddle River: Prentice Hall; 1976.
9. Hellmann MA, Djaldetti, Luckman J, Dabby R. Thoracic sensory level as a false localizing sign in cervical spinal cord and brain lesions. *Clin Neurol Neurosug*. 2013;115(1):54-56. doi:10.1016/j.clineuro.2012.04.011.
10. American College of Radiology. ACR-ASNR-SCBT-MR-SSR practice parameter for the performance of magnetic resonance imaging (MRI) of the adult spine. 2001; revised 2018. Available at: <https://www.acr.org/-/media/ACR/Files/Practice-Parameters/MR-Adult-Spine.pdf?la=en>.

Lumbar Spine Spondylolysis/ Spondylolisthesis (SP-8)

Guideline

Spondylolysis (SP-8.1)

Spondylolisthesis (SP-8.2)

References (SP-8)

Spondylolysis (SP-8.1)

SP.SP.0008.1.A
v2.0.2024

Results of plain x-rays performed after the current episode of symptoms started or changed need to be available to the requesting provider, unless otherwise specified below.

Indication	Imaging Study
<ul style="list-style-type: none"> Plain x-rays are negative, equivocal, or indeterminate AND Clinical suspicion of spondylolysis is high 	99mTc-MDP SPECT bone scan (CPT® 78803)
<ul style="list-style-type: none"> Negative SPECT bone scan, OR evaluation of a lesion seen on SPECT bone scan 	MRI Lumbar Spine without contrast (CPT® 72148) OR CT Lumbar Spine without contrast (CPT®72131)
<ul style="list-style-type: none"> Documented need for preoperative planning 	MRI Lumbar Spine without contrast (CPT® 72148) AND/OR CT Lumbar Spine without contrast (CPT®72131)
<ul style="list-style-type: none"> Failure of 6 weeks of provider-directed conservative treatment (which may include immobilization with a spinal orthosis) with clinical re-evaluation 	MRI Lumbar Spine without contrast (CPT® 72148) OR CT Lumbar Spine without contrast (CPT®72131)
<ul style="list-style-type: none"> Evaluation for stress reaction in bone, to visualize nerve roots 	MRI Lumbar Spine without contrast (CPT® 72148)
<ul style="list-style-type: none"> Any of the above indications, and MRI is contraindicated 	CT Lumbar Spine without contrast (CPT®72131)
<ul style="list-style-type: none"> Evaluation of bony anatomy 	CT Lumbar Spine without contrast (CPT®72131)
<ul style="list-style-type: none"> Monitor healing of a pars interarticularis fracture that was determined to have healing potential on a prior CT (i.e., non-sclerotic lesion) 	CT Lumbar Spine without contrast (CPT® 72131) of the symptomatic spinal level

- For pediatric spondylolysis, see: **Spondylolysis (PEDSP-2.4)** in the Pediatric Spine Imaging Guidelines
- Bony healing cannot be achieved non-surgically in an established well defined isthmic pars interarticularis defect whether it is developmental or the result of a pars interarticularis fracture non-union. Repeat advanced diagnostic imaging is not medically necessary in this setting.

Background and Supporting Information

- Spondylolysis is most often an incidental finding on plain x-rays, and advanced imaging is generally not indicated.
- MRI is not appropriate in the early diagnosis of spondylolysis due to the potential for false negative results.

Spondylolisthesis (SP-8.2)

SP.SP.0008.2.A

v2.0.2024

- CT Lumbar Spine without contrast (CPT® 72131) or MRI Lumbar Spine without contrast (CPT® 72148) can be considered after plain x-ray (results of plain x-rays performed after the current episode of symptoms started or changed need to be available to the requesting provider) for the following:
 - Failure of 6 week trial of provider-directed treatment and clinical re-evaluation (see also: **General Guidelines [SP-1.0]**); **or**
 - Preoperative evaluation; **or**
 - See: **Red Flag Indications (SP-1.2)**

Background and Supporting Information

- Stress reactions and stress fractures of the pars interarticularis are most common in athletes and others whose activities involve repetitive flexion/extension loading of the lumbar spine and may be acute or chronic and unilateral or bilateral. Pars interarticularis defects can be an incidental finding on plain x-rays and is frequently asymptomatic.
- Spondylolisthesis is the forward (anterolisthesis) or backward (retrolisthesis, usually not clinically significant) displacement of one vertebra in relation to an adjacent vertebra, most commonly at L4-5 and L5-S1, although other levels of the spine may be involved. Spondylolisthesis is often an incidental finding on plain x-ray and is frequently asymptomatic.

References (SP-8)

v2.0.2024

1. Rao, RD, Smuck M. Orthopaedic Knowledge Update 4: Spine. *AAOS*. 41:477-478.
2. Lieberman JR, ed. *AAOS comprehensive orthopaedic review 2009*. Rosemont, IL.: AAOS (American Academy of Orthopaedic Surgeons); 2009. 771-775.
3. Kuhns BD, Kouk S, Buchanan C, et al. Sensitivity of magnetic resonance imaging in the diagnosis of mobile and non-mobile L4-5 degenerative spondylolisthesis. *The Spine Journal*; 2014. doi:10.1016/j.spinee.2014.08.006.
4. Foreman P, et al. L5 spondylolysis/spondylolisthesis: a comprehensive review with an anatomic focus. *Childs Nerv Syst*. 2013;29:209-16.
5. Harvey CJ, et. The radiological investigation of lumbar spondylolysis. *Clin Radiol*. 1998;53:723-28.
6. Kruse D, Lemmen B. Spine injuries in the sport of gymnastics. *Curr Sports Med Rep*. 2009;8:20-28.
7. Standaert CJ, Herring SA. Spondylolysis: a critical review. *British Journal of Sports Medicine*. 2000;34:415-422.
8. Leone A, et al. Lumbar spondylolysis: a review. *Skeletal Radiol*. 2011;40:683-700.
9. Kobayashi A, et al. Diagnosis of radiographically occult lumbar spondylolysis in young athletes by magnetic resonance imaging. *Am J Sports Med*. 2013;41:169-76.
10. Fujii K, Katoh S, Sairyo K, et al. Union of defects in the pars interarticularis of the lumbar spine in children and adolescents: the radiologic outcome after conservative treatment. *J Bone Joint Surg Br*. 2004;86:225-31.
11. Puhakka KB, Jurik AG, Schiottz-Christensen B, et. al. Magnetic resonance imaging of sacroiliitis in early seronegative spondyloarthritis. Abnormalities correlated to clinical and laboratory findings. *Rheumatology*. 2004;43(2):234-237.

Lumbar Spinal Stenosis (SP-9)

Guideline

Lumbar Spinal Stenosis (SP-9.1)

References (SP-9)

Lumbar Spinal Stenosis (SP-9.1)

SP.ST.0009.1.A

v2.0.2024

- MRI Lumbar Spine without contrast (CPT® 72148) or CT Lumbar Spine without contrast (CPT® 72131) is appropriate for those individuals with clinical suspicion of lumbar spinal stenosis if:
 - Failure of 6 week trial of provider-directed treatment and clinical re-evaluation (see also: **General Guidelines (SP-1.0)**); **or**
 - Red Flag Indications (see: **Red Flag Indications (SP-1.2)**); **or**
 - Severe symptoms of neurogenic claudication restricting normal activity or requiring the frequent use of narcotic analgesics
- A CT/Myelogram Lumbar Spine (CPT® 72132) may also be considered for individuals who have failed 6-weeks of provider-directed treatment if requested by the operating surgeon for surgical planning, especially for multi-level lumbar spinal stenosis.

Background and Supporting Information

Lumbar spinal stenosis refers to a decrease in the space available for the neural elements within the spinal canal that include spinal nerve roots and the cauda equina. It is usually a degenerative condition of the aging spine which can be asymptomatic or a common cause of buttock/low back and/or leg pain (neurogenic claudication) in this population. Neurogenic claudication is a common symptom of lumbar spinal stenosis that is aggravated by walking, especially down hills or stairs, with prolonged standing and is often relieved by sitting and bending forward. Neurogenic claudication should be differentiated from vascular claudication (leg/calf pain) that is often aggravated by walking and relieved fairly rapidly by stopping and rest. The differential diagnosis for lumbar spinal stenosis should include peripheral vascular disease, hip disorders and peripheral neuropathy.

References (SP-9)

v2.0.2024

1. Patel ND, Broderick DF, Burns J, et al. Expert Panel on Neurologic Imaging. ACR Appropriateness Criteria®: Low Back Pain. American College of Radiology (ACR); Date of Origin: 1996. Revised: 2021. <https://acsearch.acr.org/docs/69483/Narrative/>.
2. North Am Spine Society, Clinical guidelines for multidisciplinary spine care specialists: spinal stenosis. Version 1.02002. <http://www.guideline.gov>.
3. Highlights from the 2007 North American Spine Society Meeting. Sg2 Web Seminar, November 8, 2007.
4. Tosteson ANA, Lurie JD, Tosteson TD, et al. Surgical treatment of spinal stenosis with and without degenerative spondylolisthesis: cost-effectiveness after 2 years. *Ann Intern Med*. 2008;149(12):845-853.
5. Katz JN, Harris MB. Clinical practice. Lumbar spinal stenosis. *N Engl J Med*. 2008;358:818-825.
6. Deyo RA, Rainville J, Kent DL. What can the history and physical examination tell us about low back pain? *JAMA*. 1992; 268(6):760-765.
7. Devin CJ, McCullough KA, Morris BJ, et al. Hip-spine syndrome. *J Am Acad Orthop Surg*. 2012;20:434-442.

Sacro-Iliac (SI) Joint Pain, Inflammatory Spondylitis/Sacroiliitis and Fibromyalgia (SP-10)

Guideline

Sacro-Iliac (SI) Joint Pain/Sacroiliitis (SP-10.1)

Inflammatory Spondylitis (SP-10.2)

Fibromyalgia (SP-10.3)

References (SP-10)

Sacro-Iliac (SI) Joint Pain/Sacroiliitis (SP-10.1)

SP.SI.0010.1.A

v2.0.2024

- CT Pelvis without contrast (CPT® 72192) or MRI Pelvis without contrast (CPT® 72195) is appropriate if:
 - Initial plain x-rays are equivocal or not diagnostic; **and**
 - Failure of 6 weeks of provider-directed treatment and clinical re-evaluation (see also: **General Guidelines (SP-1.0)**); **or**
 - Any ONE of the following:
 - Fractures of the sacrum or sacroiliac joint(s); **or**
 - See: **Red Flag Indications (SP-1.2)**; **or**
 - Preoperative planning
- MRI Pelvis without and with contrast as indicated for pediatric individuals with juvenile idiopathic arthritis.
- Suspicion of neoplastic, inflammatory, or infectious disease:
 - MRI Pelvis without and with contrast (CPT® 72197) or MRI Pelvis without contrast (CPT® 72195)
 - CT Pelvis without contrast (CPT® 72192) if MRI is contraindicated
- See: **Rheumatoid Arthritis (RA) and Inflammatory Arthritis (MS-15.1)** in the Musculoskeletal Imaging Guidelines

Inflammatory Spondylitis (SP-10.2)

SP.SI.0010.2.A
v2.0.2024

- Initial plain x-rays are equivocal or not diagnostic:
 - MRI without and with contrast or MRI without contrast of the affected spinal region
 - CT without contrast of the affected spinal region if MRI is contraindicated
- Follow up imaging for treatment response or disease progression:
 - Repeat plain x-rays of the SI joints, or SI joints and spine area of interest
 - MRI without and with contrast of spine area of interest, or MRI SI joints without contrast, or MRI SI joints and MRI without and with contrast spine area of interest if x-rays show no progression of disease
- For those with documented ankylosing spondylitis or DISH (diffuse idiopathic skeletal hyperostosis) and spine pain following trauma, plain x-rays are not required prior to advanced imaging.
 - See: **Neck Trauma (SP-3.2)**, **Upper Back Trauma (SP-4.2)**, **Low Back Trauma (SP-6.2)**

Fibromyalgia (SP-10.3)

SP.DI.0010.3.A

v2.0.2024

- Advanced diagnostic imaging is not supported by the scientific evidence for the evaluation and treatment of fibromyalgia.

Background and Supporting Information

- Sacroiliitis can present with pain localized to the SI joint or referred pain to the buttock and/or posterior thigh without neurologic signs or symptoms. Affected individuals can often point to the SI joint as the pain source. Provocative and/or therapeutic SI joint anesthetic/corticosteroid injections can have diagnostic value.
- There is no evidence demonstrating that advanced diagnostic imaging substantiates changes to individual management decisions in individuals with proven SI joint disorders when visible on routine plain x-rays.
- MRI has shown inflammatory changes in the SI joints prior to visible x-ray changes in several studies. However, the ability of MRI to characterize inflammation in early ankylosing spondylitis, the ability of MRI to predict erosive changes, and the value of monitoring treatment effects using serial MRI studies remains controversial and investigational in adults.

References (SP-10)

v2.0.2024

1. Puhakka KB, Jurik AG, Schiøtz-Christensen B, et al. Magnetic resonance imaging of sacroiliitis in early seronegative spondylarthropathy. Abnormalities correlated to clinical and laboratory findings. *Rheumatology* 2004;43:234-237.
2. Dreyfuss P, Dreyer SJ, Cole A, et al. Sacroiliac joint pain. *Am Acad Orthop Surg*. 2004;12:255-265.
3. Maigne JY, Tamalet B. Standardized radiologic protocol for the study of common coccygodynia and characteristics of the lesions observed in the sitting position. Clinical elements differentiating luxation, hypermobility, and normal mobility. *Spine*. 1996;21:2588-2593.
4. Maigne JY, Doursounian L, Chatellier G. Causes and mechanisms of common coccydynia: role of BMI and coccygeal trauma. *Spine*. 2000;25:3072-3079.
5. Landewe RBM, Hermann KGA, Van Der Heijde DMFM, Baraliakos X, et al. Scoring sacroiliac joints by magnetic resonance imaging. A multiple-reader reliability experiment. *The Journal of Rheumatology*. 2005;32:10.
6. Lambert RGW, Salonen D, Rahman P, Inman RD, et al. Adalimumab significantly reduces both spinal and sacroiliac joint inflammation in patients with ankylosing spondylitis. *Arthritis & Rheumatism*. 2007;56(12):4005-4014.
7. Sheybani EF, Khanna G, White AJ, Demertzis JL. Imaging of juvenile idiopathic arthritis: a multimodality approach. *Radiographics*. 2013;33(5):1253-1273.
8. Restropo R, Lee EY, Babyn PS. Juvenile idiopathic arthritis: Current practical imaging assessment with emphasis on magnetic resonance imaging. *RadiolClin N Am*. 2013;51:703-719.
9. Deyo RA, Rainville J, Kent DL. What can the history and physical examination tell us about low back pain? *JAMA*. 1992;268(6):760-765.
10. Bernard SA, Kransdorf MJ, Beaman FD, et. al. Expert Panel on Musculoskeletal Imaging. ACR Appropriateness Criteria®: Chronic Back Pain: Suspected Sacroiliitis/Spondyloarthropathy. American College of Radiology (ACR); Date of Origin: 2016. Revised: 2021. <https://acsearch.acr.org/docs/3094107/Narrative/>.
11. Lantsman CD, Barkay G, Friedlander A, Barbi M, Stern M, Eshed I. Whole spine CT scan for the detection of acute spinal fractures in Diffuse Idiopathic Skeletal Hyperostosis patients who sustained low-energy trauma. *Spine*. 2020;45(19):1348-1353. doi:10.1097/BRS.0000000000003536.
12. Czuczman GJ, Mandell JC, Wessell DE, et. al. Expert Panel on Musculoskeletal imaging. ACR Appropriateness Criteria®: Inflammatory Back Pain: Known or Suspected Axial Spondyloarthritis. American College of Radiology (ACR); Revised: 2021. <https://acsearch.acr.org/docs/3148734/Narrative/>.
13. Le HV, Wick JB, Van BW, Klineberg EO. Diffuse idiopathic skeletal hyperostosis of the spine: pathophysiology, diagnosis, and management. *J Am Acad Orthop Surg*. 2021;29:1044-1051. doi:10.5435/JAAOS-D-20-01344.

Spinal Compression Fractures (SP-11)

Guideline

Spinal Compression Fractures (SP-11.1)

References (SP-11)

Spinal Compression Fractures (SP-11.1)

SP.FX.0011.1.A

v2.0.2024

Individuals with no history of malignancy

- MRI without contrast, CT without contrast, or whole body bone scan (CPT® 78306), SPECT (CPT® 78803), or SPECT/CT (CPT® 78830) of the affected spinal region is indicated after plain x-ray evaluation **and** the location of the individual's spinal pain is concordant with the spinal x-rays for any ONE of the following:
 - X-rays reveal a new spinal compression fracture; **or**
 - X-rays are non-diagnostic and severe spinal pain persists for more than one week in an individual already predisposed to low energy/insufficiency fractures; **or**
 - The acuity of the spinal compression fracture deformity on plain x-ray is indeterminate, **or**
 - Surgical planning following known insufficiency spinal compression fractures in individuals who are candidates for kyphoplasty, vertebroplasty or other spine surgical procedures

Individuals with a history of malignancy

- For individuals with new symptomatic or asymptomatic vertebral compression fractures on radiographs, please refer to the cancer-specific guidelines within the General Oncology Imaging Guidelines for appropriate imaging studies.
- See also: **Red Flag Indications (SP-1.2)**

Background and Supporting Information

Insufficiency/low energy spinal compression fractures of the spine occur due to the lack of structural integrity to withstand physiologic loads and minor spinal trauma. Low bone mineral density is the primary etiology for most of these fractures but could also occur in the setting of other bone disease and medical conditions, in addition to neoplastic disease and infection. Sudden localized back pain, with or without trauma, is a typical presentation of insufficiency/low energy spinal compression fractures and can often be an incidental finding on plain x-rays and can be asymptomatic.

References (SP-11)

v2.0.2024

1. Hutchins TA, Peckham M, Shah LM, et. al. Expert Panel on Neurologic Imaging. ACR Appropriateness Criteria®: *Low Back Pain*. American College of Radiology (ACR); Date of Origin: 1996. Revised: 2021. <http://acsearch.acr.org/docs/69483/Narrative/>.
2. McConnell CT, Wippold FJ, Ray CE, et. al. Expert Panels on Neurologic Imaging, Interventional Radiology, and Musculoskeletal Imaging. ACR Appropriateness Criteria®: *Management of Vertebral Compression Fractures*. American College of Radiology (ACR); Date of Origin: 2010. Revised: 2022. <https://acsearch.acr.org/docs/70545/Narrative/>.
3. Old JL, Calvert M. Vertebral compression fractures in the elderly. *Am Fam Physician*. 2004;69:111-116.
4. Brunton S, Carmichael B, Gold D, et al. Vertebral compression fractures in primary care. *J Fam Practice*. 2005 Sept. (Supplement):781-788.
5. McCarthy J, Davis A. Diagnosis and management of vertebral compression fractures. *Am Fam Physician*. 2016 94:44-50.
6. Deyo RA, Rainville J, Kent DL. What can the history and physical examination tell us about low back pain? *JAMA*. 1992;268(6):760-765.

Spinal Pain in Cancer Patients (SP-12)

Guideline

Spinal Pain in Cancer Patients (SP-12)

Spinal Pain in Cancer Patients (SP-12)

SP.CA.0012.A

v2.0.2024

- For guidelines regarding advanced diagnostic imaging in this clinical setting, See **Spinal/Vertebral Metastases (ONC-31.6)**

Spinal Canal/Cord Disorders (e.g. Syringomyelia) (SP-13)

Guideline

Initial Imaging Pathway (SP-13.1)

Follow-up Imaging (SP-13.2)

References (SP-13)

Initial Imaging Pathway (SP-13.1)

SP.CD.0013.1.A

v2.0.2024

- MRI Cervical Spine without contrast or without and with contrast (CPT® 72141 or CPT® 72156) and MRI Thoracic Spine without contrast or without and with contrast (CPT® 72146 or CPT® 72157) is appropriate when syringomyelia is suspected.
- Once a syrinx is identified by prior imaging, the following are appropriate:
 - MRI Brain without contrast (CPT® 70551) to evaluate for syringobulbia **AND**
 - MRI Cervical Spine without contrast or without and with contrast (CPT® 72141 or CPT® 72156) if not already performed **AND**
 - MRI Thoracic Spine without contrast or without and with contrast (CPT® 72146 or CPT® 72157) and MRI Lumbar Spine without contrast or without and with contrast (CPT® 72148 or CPT® 72158) to define the lower most extent of the syrinx or to identify a skip lesion.

Follow-up Imaging (SP-13.2)

SP.CD.0013.2.A

v2.0.2024

- MRI Cervical Spine without contrast (CPT® 72141) and MRI Brain without contrast (CPT® 70551) and/or MRI Thoracic Spine without contrast (CPT® 72146) when involved
 - If there is a concern for malignancy, imaging can be performed without and with contrast
 - Annual imaging until non-progression of the syringomyelia is established
 - Following surgical treatment (including posterior fossa decompression)
 - Advanced diagnostic imaging every three years for life can be performed once non-progression of the syringomyelia is established
 - Repeat advanced diagnostic imaging is appropriate when there is evidence of neurologic deterioration

Background and Supporting Information

Syringomyelia may begin to form in childhood but rarely becomes symptomatic before the adult years.

References (SP-13)

v2.0.2024

1. Mancall ER. Syringomyelia. In: Rowland LP, ed. *Merritt's Neurology*. 11th ed. Philadelphia, PA: Lippincott; 2005:870-874.
2. Tsitouras V, Sgouros S. Syringomyelia and tethered cord in children. *Childs Nerv Syst*. 2013;29:1625-1634. doi:10.1007/s00381-013-2180-y.
3. Roth CJ, Angevine PD, Aulino JM, et. al. Expert Panel on Neurologic Imaging. ACR Appropriateness Criteria®: *Myelopathy*. American College of Radiology (ACR); Date of Origin: 1996. Revised: 2020. <https://acsearch.acr.org/docs/69484/Narrative/>.

Spinal Deformities (e.g. Scoliosis/Kyphosis) (SP-14)

Guideline

Spinal Deformities (e.g. Scoliosis/Kyphosis) (SP-14.1)

Revision Anterior Spinal Deformity Surgery (SP-14.2)

References (SP-14)

Spinal Deformities (e.g. Scoliosis/Kyphosis) (SP-14.1)

SP.SC.0014.1.A

v2.0.2024

- MRI without contrast, MRI without and with contrast, or CT/Myelography if MRI is contraindicated of the affected spinal regions is appropriate after plain x-rays (e.g., Cobb radiographs) of the affected spinal regions have been performed and results are available to the requesting provider:
 - For preoperative evaluation; **or**
 - For cases of congenital scoliosis and other atypical curves that may be associated with spinal canal/cord pathology such as tethered cord, syringomyelia, diastematomyelia, or tumors; **or**
 - For cases of scoliosis and/or kyphosis when there are associated neurologic signs and symptoms on physical examination; **or**
 - Scoliosis with a convex left thoracic curve due to a high association of a convex left thoracic curve with underlying spinal canal/cord pathology
- CT of the affected spinal regions (contrast as requested) is appropriate in cases with a complex osseous deformity for preoperative evaluation
- CTA or MRA is not medically necessary for preoperative planning for initial anterior spinal surgery for surgical correction of spinal deformities

Revision Anterior Spinal Deformity Surgery (SP-14.2)

SP.SC.0014.2.A**v2.0.2024**

- If requested by the operating surgeon, the following studies can be performed for preoperative planning for revision of anterior thoracic or lumbar spinal surgery:
 - CTA Pelvis (CPT® 72191) and/or CTA Abdomen (CPT® 74175); **or**
 - MRA Pelvis (CPT® 72198) and/or MRA Abdomen (CPT® 74185)

Background and Supporting Information

- Scoliosis is defined as a curvature of the spine in the coronal plane. Scoliosis can involve any or all levels of the spine but generally involves the thoracic and/or lumbar spine. Scoliosis initially occurs in the pediatric and adolescent population and persists throughout life. If scoliosis begins in adulthood, it is usually secondary to neurologic disorders (e.g., posttraumatic paralysis) or degenerative spondylosis. Sagittal plane spinal deformity (e.g., kyphosis, hyperlordosis) may be associated with scoliosis.

References (SP-14)

v2.0.2024

1. Boas SR. Kyphoscoliosis: Adolescent Idiopathic Scoliosis and Congenital Scoliosis. In: Kliegman RM, Behrman RE, Jenson HB, et al, eds. *Nelson Textbook of Pediatrics*. 18th ed. Philadelphia, PA: Elsevier; 2007:1843-1844.
2. Spiegel DA, Hosalkar HS, Dormans JP. The Spine. In: Kliegman RM, Behrman RE, Jenson HB, et al., eds. *Nelson Textbook of Pediatrics*. 18th ed. Philadelphia, PA: Elsevier; 2007:2811-2815.
3. Do T, Frasc C, Burke S, et al. Clinical value of routine preoperative magnetic resonance imaging in adolescent idiopathic scoliosis. *J Bone Joint Surg Am*. 2001;83:577-579.
4. Dobbs MB, Lenke LG, Szymanski DA, et al. Prevalence of neural axis abnormalities in patients with infantile idiopathic scoliosis. *J Bone Joint Surg Am*. 2002;84:2230-2234.
5. Rao, RD, Smuck M. Orthopaedic Knowledge Update 4: Spine. *AAOS*. 41:477-478.
6. Lieberman JR. AAOS comprehensive orthopaedic review. Rosemont, IL.: *American Academy of Orthopaedic Surgeons*; 2009.
7. Pollak AN, Ficke JR. Extremity war injuries: Challenges in definitive reconstruction. *J Am Acad Orthop Surg*. 2008;16(11):407-417.
8. Swiontkowski MF. The journal of bone and joint surgery. *JBJS*. 1993;75A(9):1308-1317.
9. Bach HG, Goldberg BA. Posterior Capsular Contracture of the Shoulder. *J Am Acad Orthop Surg*. 2006;14(5):101-112.
10. Hedequist, D., Emans, J. Congenital scoliosis. *J Am Acad Orthop Surg*. 2004;12:266-275.
11. Gstottner M, Godny B, Petersen J., et al. CT angiography for anterior lumbar spine access: High radiation exposure and low clinical relevance. *Clin Orthop Relat Res*. 2011;469(3):819-824.
12. Kim H, Kim HS, Moon ES, et al. Scoliosis Imaging: what radiologists should know. *Radiographics*. 2010;30:1823-1842.

Post-Operative Spinal Disorders (SP-15)

Guideline

Greater than Six Months Post-Operative (SP-15.1)

Routine Post-Fusion Imaging (SP-15.2)

Prolonged Intractable Pain Following Spinal Surgery Within Six Months (SP-15.3)

Revision Anterior Fusion Surgery (SP-15.4)

References (SP-15)

Greater than Six Months Post-Operative (SP-15.1)

SP.OP.0015.1.A

v2.0.2024

- Following plain x-rays of the affected spinal regions post-surgical with results available to the requesting provider, MRI without and with contrast, MRI without contrast, or CT without contrast of the affected spinal region(s) is appropriate when:
 - Individual is more than six months post-operative; **and**
 - No significant improvement after a recent (within 3 months) six week trial of provider-directed treatment with clinical re-evaluation; **or**
 - See: **Red Flag Indications (SP-1.2)**
- See: **Nuclear Medicine (SP-17)** for nuclear medicine imaging when MRI/CT are nondiagnostic in back pain with suspected failed fusion surgery

Routine Post-Fusion Imaging (SP-15.2)

SP.OP.0015.2.A

v2.0.2024

- Following a clinically successful spinal fusion, advanced diagnostic imaging is generally not indicated.
- **PET** is not currently indicated for the routine assessment of spinal fusions or unsuccessful spine surgery (see also: **Spine PET (SP-2.10)**).

Prolonged Intractable Pain Following Spinal Surgery Within Six Months (SP-15.3)

SP.OP.0015.3.A
v2.0.2024

- Following plain x-rays of the affected spinal regions post-surgical with results available to the requesting provider, MRI without and with contrast of the affected spinal region(s) is appropriate if there are residual, new, recurrent, or worsening symptoms related to the surgical site.
 - CT without contrast, or CT with contrast (Myelography) of the affected spinal region(s) if MRI is contraindicated.

Revision Anterior Fusion Surgery (SP-15.4)

SP.OP.0015.4.A

v2.0.2024

- If requested by the operating surgeon, the following studies for preoperative planning prior to surgical revision of a thoracic or lumbar anterior spinal arthrodesis:
 - CTA Pelvis (CPT® 72191) and/or CTA Abdomen (CPT® 74175); *or*
 - MRA Pelvis (CPT® 72198) and/or MRA Abdomen (CPT® 74185)

References (SP-15)

v2.0.2024

1. Hayashi D, Roemer FW, Mian A, Gharaibeh M, et al. Imaging features of post-operative complications after spinal surgery and instrumentation. *AJR*. 2012;199:W123-W129.
2. Thakkar RS, Malloy JP, Thakkar SC, Carrino JA, Khanna AJ. Imaging the post-operative spine. *Rad Clin North Am*. 2012;50:731-747.
3. Kathuria S. Post-vertebral augmentation spine imaging. *Neuroimaging Clin N Am*. 2014;24(2):337-347.
4. Savage JW, Schroeder GD, Anderson PA. Vertebroplasty and kyphoplasty for the treatment of osteoporotic vertebral compression fractures. *J Am Acad Orthop Surg*. 2014;22:653-664.
5. Gstottner M, Godny B, Petersen J., et al. CT angiography for anterior lumbar spine access: high radiation exposure and low clinical relevance. *Clin Orthop Relat Res*. 2011;469(3):819-824.

Other Imaging Studies and Procedures Related to the Spine Imaging Guidelines (SP-16)

Guideline

Prior to Spine Surgery (SP-16.1)

Prior to Interventional Spinal Injections (SP-16.2)

Prior to Spinal Cord Stimulator (SCS) Placement/Removal (SP-16.3)

Following Vertebral Augmentation Procedures (SP-16.4)

References (SP-16)

Prior to Spine Surgery (SP-16.1)

SP.OI.0016.1.A

v2.0.2024

- Advanced imaging needed for surgical planning (e.g., MRI and/or CT) should be performed within the past six (6) months for preoperative planning prior to spine surgery when the criteria for advanced imaging studies of the spine are met as otherwise stated in the Spine Imaging Guidelines. (See: **MRI of the Spine [SP-2.2]**, **CT of the Spine [SP-2.3]**, **CT/Myelography [SP-2.4]**)
- MRA and CTA are generally not indicated for preoperative planning of initial anterior spinal surgery unless abnormal vasculature is known or reasonably anticipated.

Prior to Interventional Spinal Injections (SP-16.2)

SP.OI.0016.2.A

v2.0.2024

- Advanced diagnostic imaging studies of the spine are not required prior to facet joint injections, medial branch blocks or radiofrequency ablations unless the criteria for advanced imaging studies of the spine are met as otherwise stated in the Spine Imaging Guidelines.
- Advanced diagnostic imaging studies of the cervical spine and/or thoracic spine are indicated within twenty-four (24) months prior to interlaminar or transforaminal epidural steroid injections of the cervical and/or thoracic spine when the criteria for advanced imaging studies of the spine are met as otherwise stated in the Spine Imaging Guidelines.
- Advanced diagnostic imaging studies of the lumbar spine are indicated prior to transforaminal epidural steroid injections of the lumbar spine when the criteria for advanced imaging studies of the spine are met as otherwise stated in the Spine Imaging Guidelines.
- Advanced diagnostic imaging studies of the lumbar spine are not required prior to lumbar spine interlaminar or caudal epidural steroid injections unless the criteria for advanced imaging studies of the spine are met as otherwise stated in the Spine Imaging Guidelines.
- For an individual with evidence of symptomatic spinal stenosis, MRI or CT with or without myelography demonstrating severe spinal stenosis at the level to be treated within the past twenty-four (24) months is required for an initial trial of a transforaminal, interlaminar or caudal epidural steroid injection when ALL of the following criteria are met:
 - Diagnostic evaluation has ruled out other potential causes of pain
 - Significant functional limitations resulting in diminished quality of life and impaired age-appropriate activities of daily living (ADLs)
 - Failure of at least four (4) weeks of conservative treatment (e.g., exercise, physical methods including physical therapy and/or chiropractic care, NSAIDs, and/or muscle relaxants)
- See: **Red Flag Indications (SP-1.2)** for severe radicular pain

Prior to Spinal Cord Stimulator (SCS) Placement/Removal (SP-16.3)

SP.OI.0016.3.A

v2.0.2024

- MRI Thoracic Spine without contrast (CPT® 72146) is generally the study of choice prior to SCS placement. CT Thoracic Spine without contrast (CPT® 72128) **OR** CT/Myelography Thoracic Spine (CPT® 72129) are acceptable alternatives.
- Imaging of the lumbar spine is not indicated for placement nor removal of spinal cord stimulators.

Following Vertebral Augmentation Procedures (SP-16.4)

SP.OI.0016.4.A

v2.0.2024

- CT without contrast of the affected spinal region(s) within 24 hours post-procedure to evaluate neurologic sequelae resulting from cement extravasation

Background and Supporting Information

- MRI has not been shown to change the outcome of interventional pain procedures in recent scientific evidence-based studies and without substantial change in the clinical picture or intervening surgery. Repeat advanced diagnostic imaging studies are not necessary with each spinal injection or series of spinal injections.

References (SP-16)

v2.0.2024

1. Cohen SP, Gupta A, Strassels SA, et al. Effect of MRI on treatment results or decision making in patients with lumbosacral radiculopathy referred for epidural steroid injections. *Arch Intern Med*. 2012;172:134-142. doi:10.1001/archinternmed.2011.593.
2. North American Spine Society (NASS) Coverage Committee. *Lumbar Epidural Injections: Defining Appropriate Coverage Positions*. About Coverage Recommendations. <https://www.spine.org/PolicyPractice/CoverageRecommendations/AboutCoverageRecommendations.aspx>.
3. Rathmell JP, Benzon HT, Dreyfuss P, et al. Safeguards to prevent neurologic complications after epidural steroid injections. *Anesthesiology*. 2015;122(5):974-984. doi:10.1097/aln.0000000000000614.
4. Ghahreman A, Ferch R, Bogduk N. The efficacy of transforaminal injection of steroids for the treatment of lumbar radicular pain. *Pain Medicine*. 2010;11:1149-1168.
5. Ghaly RF, Lissounov A, Candido KD, Knezevic NN. Should routine MRI of the lumbar spine be required prior to lumbar epidural steroid injection for sciatica pain? *Surg Neuro Int*. 2015;6:48.
6. Benzon HT, Huntoon MA, Rathmell JP. Improving the safety of epidural steroid injections. *JAMA*. 2015;313:1713-1714.
7. Cohen SP, Maus T. Point/Counterpoint-The need for magnetic resonance imaging before epidural corticosteroid injection. *American Academy of Physical Medicine and Rehabilitation*. 2013;5:230-237.
8. Shim E, Lee JW, Lee E, et al. Fluoroscopically guided epidural injections of the cervical and lumbar spine. *RadioGraphics*. 2017; 37:537-561.

Nuclear Medicine (SP-17)

Guideline

Nuclear Medicine (SP-17)

Reference (SP-17)

Nuclear Medicine (SP-17)

SP.FX.0017.A

v2.0.2024

- For evaluation of suspected loosening of orthopedic implants, when recent plain x-ray is nondiagnostic:
 - Bone scan (CPT® 78315) **OR**
 - Distribution of Radiopharmaceutical Agent SPECT (CPT® 78803, or 78831) **OR**
 - SPECT/CT (CPT® 78830)
- Back pain with suspected failed fusion surgery, with suspected painful pseudoarthrosis and MRI/CT are nondiagnostic:
 - Radiopharmaceutical Localization SPECT (CPT® 78803, or 78831) **OR**
 - SPECT/CT (CPT® 78830)
- Any of the following studies are indicated for initial evaluation of suspected osteomyelitis:
 - Bone scan (one of CPT® codes: 78300, 78305, 78306, or 78315) **OR**
 - Distribution of Radiopharmaceutical Agent SPECT (CPT® 78803) **OR**
 - Nuclear Bone Marrow imaging (one of CPT® codes: 78102, 78103, or 78104) **OR**
 - Radiopharmaceutical inflammatory imaging (one of CPT® codes: 78800, 78801, 78802) **OR**
 - Distribution Of Radiopharmaceutical Agent SPECT (CPT® 78803 or 78831) **OR**
 - SPECT/CT (CPT® 78830 or 78832)
- For follow-up imaging, any of the following studies are indicated for evaluation of response to treatment in established osteomyelitis. The appropriate follow-up advanced imaging time frame will depend on the nature of the underlying disease and prior imaging:
 - Bone scan (one of CPT® codes: 78300, 78305, 78306, or 78315) **OR**
 - Nuclear Bone Marrow imaging (one of CPT® codes: 78102, 78103, or 78104)
- For evaluation of facet arthropathy in individuals with ankylosing spondylitis, osteoarthritis, or rheumatoid arthritis:
 - Radiopharmaceutical Localization Inflammatory Imaging (one of CPT® codes: 78800, 78801, 78802, or 78803) **OR**
 - Distribution Of Radiopharmaceutical Agent SPECT (CPT® 78803) **OR**
 - SPECT/CT (CPT® 78830)
- For the evaluation of back pain and suspected spondylolysis:
 - Radiopharmaceutical Agent SPECT (CPT® 78803 or 78831) **OR**
 - SPECT/CT (CPT® 78830)

- SPECT has been described to identify spinal pain generators, pseudoarthrosis of spinal fusion or hardware failure when conventional advanced diagnostic imaging studies are inconclusive, non-diagnostic or equivocal.
 - Requests for SPECT for these indications will be reviewed on a case-by-case basis.
- For the evaluation of a new symptomatic compression fracture identified on radiographs or CT, and no known malignancy:
 - Whole body bone scan with add on SPECT (CPT® 78803) or SPECT/CT (CPT® 78830)
 - See also: **Spinal Compression Fractures (SP-11.1)**

Reference (SP-17)

v2.0.2024

1. Patel ND, Broderick DF, Burns J, et. al. Expert Panel on Neurologic Imaging. ACR Appropriateness Criteria®: *Low Back Pain*. American College of Radiology (ACR); Date of Origin: 1996. Revised: 2021. <https://acsearch.acr.org/docs/69483/Narrative/>.

Pediatric Abdomen Imaging Guidelines

Procedure Codes Associated with Abdomen Imaging
General Guidelines (PEDAB-1)
Generalized Abdominal Pain (PEDAB-2)
Right Lower Quadrant Pain (PEDAB-3)
Flank Pain, Renal Stone (PEDAB-4)
Urinary Tract Infection (UTI) (PEDAB-5)
Pediatric Acute Gastroenteritis (PEDAB-6)
Hematuria (PEDAB-7)
Right Upper Quadrant Pain (PEDAB-8)
Inflammatory Bowel Disease, Crohn Disease, or Ulcerative Colitis (PEDAB-9)
Abdominal Sepsis (Suspected Abdominal Abscess) (PEDAB-10)
Postoperative Pain within 60 Days Following Abdominal Surgery (PEDAB-11)
Constipation, Diarrhea, and Irritable Bowel Syndrome (PEDAB-12)
Abdominal Mass (PEDAB-13)
Renovascular Hypertension and Other Secondary Causes of Hypertension (PEDAB-14)
Liver Lesion Characterization (PEDAB-15)
Liver Disease (PEDAB-16)
Adrenal Lesions (PEDAB-17)
Hemochromatosis (PEDAB-18)
Indeterminate Renal Lesion (PEDAB-19)
Hydronephrosis (PEDAB-20)
Polycystic Kidney Disease (PEDAB-21)
Blunt Abdominal Trauma (PEDAB-22)
Hernias (PEDAB-23)
Abdominal Lymphadenopathy (PEDAB-24)
Left Upper Quadrant Pain (PEDAB-25)
Spleen (PEDAB-26)
Intussusception (PEDAB-27)
Bowel Obstruction (PEDAB-28)
Left Lower Quadrant Pain (PEDAB-29)
Celiac Disease (Sprue) (PEDAB-30)
Transplant (PEDAB-31)
Gaucher Disease (PEDAB-32)

**Vomiting Infant, Malrotation, and Hypertrophic Pyloric Stenosis
(PEDAB-33)**

Pancreatitis (PEDAB-34)

Procedure Codes Associated with Abdomen Imaging	
MRI	CPT®
MRI Abdomen without contrast	74181
MRI Abdomen with contrast (rarely used)	74182
MRI Abdomen without and with contrast	74183
Unlisted MRI procedure (for radiation planning or surgical software)	76498
MRA	CPT®
MRA Abdomen	74185
CT	CPT®
CT Abdomen without contrast	74150
CT Abdomen with contrast	74160
CT Abdomen without and with contrast	74170
CT Abdomen and Pelvis without contrast	74176
CT Abdomen and Pelvis with contrast	74177
CT Abdomen and Pelvis without and with contrast	74178
CT Guidance for Needle Placement (Biopsy, Aspiration, Injection, etc.)	77012
CT Guidance for and monitoring of Visceral Tissue Ablation	77013
CT Guidance for Placement of Radiation Therapy Fields	77014
Unlisted CT procedure (for radiation planning or surgical software)	76497
CTA	CPT®
CTA Abdomen	74175
CTA Abdomen and Pelvis	74174
Nuclear Medicine	CPT®
PET Imaging; limited area (this code not used in pediatrics)	78811
PET Imaging: skull base to mid-thigh (this code not used in pediatrics)	78812
PET Imaging: whole body (this code not used in pediatrics)	78813
PET with concurrently acquired CT; limited area (this code rarely used in pediatrics)	78814
PET with concurrently acquired CT; skull base to mid-thigh	78815
PET with concurrently acquired CT; whole body	78816
Adrenal Nuclear Imaging Cortex and/or Medulla	78075
Spleen Imaging Only with or without Vascular Flow	78185
Liver Imaging Static	78201
Liver Imaging with Vascular Flow	78202
Liver and Spleen Imaging Static	78215
Liver and Spleen Imaging with Vascular Flow	78216
Hepatobiliary System Imaging, Including Gallbladder When Present	78226

Hepatobiliary System Imaging, Including Gallbladder When Present; with Pharmacologic Intervention, Including Quantitative Measurement(s) When Performed	78227
Gastric Mucosa Imaging	78261
Gastroesophageal Reflux Study	78262
Gastric Emptying Study	78264
GI Bleeding Scintigraphy	78278
Gastrointestinal Protein Loss	78282
Intestinal Imaging	78290
Peritoneal-Venous Shunt Patency	78291
Kidney Imaging (Nuclear) Static	78700
Kidney Imaging (Nuclear) with Vascular Flow	78701
Kidney Flow and Function, Single Study without Pharmacologic Intervention	78707
Kidney Imaging with Vascular Flow and Function with Pharmacological Intervention, Single	78708
Kidney Imaging with Vascular Flow and Function with and without Pharmacological Intervention, Multiple	78709
Nuclear Non-imaging Renal Function	78725
Ureteral Reflux Study (Radiopharmaceutical Voiding Cystogram)	78740
Radiopharmaceutical Localization Imaging Limited area	78800
Radiopharmaceutical Localization Imaging Whole Body	78802
Radiopharmaceutical Localization Imaging SPECT	78803
Ultrasound	CPT®
Ultrasound, abdomen; complete	76700
Ultrasound, abdomen; limited	76705
Ultrasound, abdominal wall	76705
Ultrasound, retroperitoneal; complete	76770
Ultrasound, retroperitoneal; limited	76775
Ultrasound, transplanted kidney (with duplex Doppler)	76776
Duplex scan of arterial inflow and venous outflow of abdominal, pelvic, scrotal contents and/or retroperitoneal organs; complete study	93975
Duplex scan of arterial inflow and venous outflow of abdominal, pelvic, scrotal contents and/or retroperitoneal organs; limited study	93976
Duplex scan of aorta, inferior vena cava, iliac vasculature, or bypass grafts; complete	93978
Duplex scan of aorta, inferior vena cava, iliac vasculature, or bypass grafts; limited	93979

General Guidelines (PEDAB-1)

General Guidelines (PEDAB-1.0)

Pediatric Abdominal Imaging Age Considerations (PEDAB-1.1)

Pediatric Abdomen Imaging Appropriate Clinical Evaluation and Conservative Treatment (PEDAB-1.2)

Pediatric Abdomen Imaging Modality General Considerations (PEDAB-1.3)

General Guidelines (PEDAB-1.0)

- A pertinent clinical evaluation since the onset or change in symptoms including a detailed history, physical examination, appropriate laboratory studies and basic imaging such as plain radiography or ultrasound should be performed prior to considering advanced imaging (CT, MR, Nuclear Medicine), unless the individual is undergoing guideline-supported scheduled imaging evaluation. A meaningful technological contact (telehealth visit, telephone call, electronic mail or messaging) since the onset or change in symptoms can serve as a pertinent clinical evaluation.
- These guidelines are based upon using advanced imaging to answer specific clinical questions that will affect individual management. Imaging is not indicated if the results will not affect individual management decisions. Standard medical practice would dictate continuing conservative therapy prior to advanced imaging in individuals who are improving on current treatment programs.
- Unless otherwise stated in a specific guideline section, the use of advanced imaging to screen asymptomatic individuals for disorders involving the abdomen is not supported. Advanced imaging should only be approved in individuals who have documented active clinical signs or symptoms of disease.
- Unless otherwise stated in a specific guideline section, repeat imaging studies of the same body area are not necessary unless there is evidence for progression of disease, new onset of disease, and/or documentation of how repeat imaging will affect individual management or treatment decisions.
- Ultrasound should be the initial imaging study of choice in most children with abdominal conditions and should be done prior to advanced imaging.
 - ◆ For those individuals who do require advanced imaging after ultrasound, ultrasound can be very beneficial in selecting the proper modality, body area, image sequences, and contrast level that will provide the most definitive information for the individual.
 - ◆ CPT® codes vary by body area and presence or absence of Doppler imaging and are included in the table at the beginning of this guideline.

Red Flags

- Children with abdominal pain **AND** ANY of the following red flag signs or symptoms require additional investigation. The initial ultrasound is not required. Additional labs may be helpful but are not required.
 - ◆ Pain that wakes the child from sleep
 - ◆ Unexplained fever (T >100.4°F)
 - ◆ History of malignancy with a likelihood or propensity to metastasize to abdomen
 - ◆ Dysphagia
 - ◆ GI bleeding
 - ◆ Significant vomiting
 - ◆ Elevated WBC per the testing laboratory's range
 - ◆ Low WBC (absolute neutrophil count <1000)
 - ◆ Guarding, rebound tenderness, or other peritoneal signs
 - ◆ Severe chronic diarrhea or nocturnal diarrhea in a toilet-trained child
 - ◆ Failure to thrive, involuntary weight loss, or delay in linear growth or pubertal development
 - ◆ Family history of inflammatory bowel disease, familial polyposis syndrome, celiac disease, or peptic ulcer disease
 - ◆ Abdominal mass, hepatomegaly, and/or splenomegaly on exam
 - ◆ Jaundice
 - ◆ Perianal disease
 - ◆ Suspected or confirmed COVID-19 infection with concern for multisystem inflammatory syndrome in children (MIS-C)
 - ◆ Failure to respond to 4 weeks of recent (within 60 days) provider directed conservative care
- See the condition-specific sections for when the above list of exclusionary criteria apply and lead directly to advanced imaging.
- The appropriate advanced imaging for the condition is listed in the condition-specific section.

Pediatric Abdominal Imaging Age Considerations (PEDAB-1.1)

- Many conditions affecting the abdomen in the pediatric population are different diagnoses than those occurring in the adult population. For those diseases that occur in both pediatric and adult populations, differences may exist in management due to individual age, comorbidities, and differences in disease natural history between children and adults.
- Individuals age 18 years old and younger¹³ should be imaged according to the Pediatric Abdomen Imaging Guidelines if discussed. Any conditions not specifically discussed in the Pediatric Abdomen Imaging Guidelines should be imaged according to the General Abdomen Imaging Guidelines. Individuals age >18 years old should be imaged according to the General Abdomen Imaging Guidelines, except where directed otherwise by a specific guideline section.

Pediatric Abdomen Imaging Appropriate Clinical Evaluation and Conservative Treatment (PEDAB-1.2)

- See: **General Guidelines (PEDAB-1.0)**

Pediatric Abdomen Imaging Modality General Considerations (PEDAB-1.3)

- Ultrasound
 - ◆ See: **General Guidelines (PEDAB-1.0)**
- MRI
 - ◆ MRI Abdomen is generally performed without and with contrast (CPT® 74183) unless the individual has a documented contraindication to gadolinium or otherwise stated in a specific guideline section.
 - ◆ Due to the length of time required for MRI acquisition and the need to minimize individual movement, anesthesia is usually required for almost all infants (except neonates) and young children (age <7 years) as well as older children with delays in development or maturity. This anesthesia may be administered via oral or intravenous routes. In this individual population, MRI sessions should be planned with a goal of minimizing anesthesia exposure by adhering to the following considerations:
 - MRI procedures can be performed without and/or with contrast use as supported by these condition-based guidelines. If intravenous access will already be present for anesthesia administration and there is no contraindication for using contrast, imaging without and with contrast may be appropriate if requested. By doing so, the requesting provider may avoid repetitive anesthesia administration to perform an MRI with contrast if the initial study without contrast is inconclusive.
 - Recent evidence-based literature demonstrates the potential for gadolinium deposition in various organs including the brain, after the use of MRI contrast.
 - The U.S. Food and Drug Administration (FDA) has noted that there is currently no evidence to suggest that gadolinium retention in the brain is harmful and restricting gadolinium-based contrast agents (GBCAs) use is not warranted at this time. It has been recommended that GBCA use should be limited to circumstances in which additional information provided by the contrast agent is necessary and the necessity of repetitive MRIs with GBCAs should be assessed.
 - If multiple body areas are supported by eviCore’s guidelines for the clinical condition being evaluated, MRI of all necessary body areas should be obtained concurrently in the same session.
 - ◆ The presence of surgical hardware or implanted devices may preclude MRI.
 - The selection of best examination may require coordination between the provider and the imaging service. CT may be the procedure of choice in these cases.

➤ CT

- ◆ CT Abdomen typically extends from the dome of the diaphragm to the upper margin of the sacroiliac joints, and CT Abdomen and Pelvis extends from the dome of the diaphragm through the ischial tuberosities.
 - In general, CT Abdomen is appropriate when evaluating solid abdominal organs.
 - In general, CT Abdomen and Pelvis is appropriate when evaluating inflammatory or infectious processes, hematuria, or conditions that appear to involve both the abdomen and the pelvis.
 - In some cases, especially in follow-up of a known finding, it may be appropriate to limit the exam to the region of concern to reduce radiation exposure.
- ◆ The contrast level in pediatric CT imaging is specific to the clinical indication, as listed in the specific guideline sections.
- ◆ CT Abdomen or Abdomen and Pelvis may be indicated for further evaluation of abnormalities suggested on prior US or MRI studies.
- ◆ CT may be indicated without prior MRI or US as indicated in specific sections of these guidelines.
- ◆ CT should not be used to replace MRI in an attempt to avoid sedation unless listed as a recommended study in a specific guideline section.
- ◆ The selection of the best examination may require coordination between the provider and the imaging service.

➤ Nuclear Medicine

- ◆ Nuclear medicine studies are commonly used in evaluation of the pediatric kidney and gallbladder. Other less common indications exist as well:
 - Esophageal motility study (CPT® 78258) and/or Gastroesophageal reflux study (CPT® 78262) is indicated in the evaluation of gastroesophageal reflux.
- ◆ Nuclear intestinal imaging (preferred code for Meckel's Scan, CPT® 78290) or Gastric mucosa imaging (alternate code for Meckel's scan, CPT® 78261) is indicated for the following:
 - Suspected Meckel's diverticulum
 - Gastric mucosa imaging (CPT® 78261) is also indicated for:
 - Barrett's esophagus
 - Thoracic masses suspected of containing gastric mucosa
- ◆ Gastric emptying study (CPT® 78264) is indicated for evaluation of either suspected delayed or rapid gastric emptying.
- ◆ Gastric emptying study with small bowel transit (CPT® 78265) is indicated for evaluation of suspected abnormalities in both total and regional times for gastrointestinal transit of the small bowel.
- ◆ Gastric emptying study with small bowel and colon transit (CPT® 78266) is indicated for evaluation of suspected abnormalities in both total and regional times for gastrointestinal transit to the colon.
- ◆ Gastrointestinal bleeding scintigraphy (CPT® 78278) is indicated for evaluation of brisk active GI bleeding with indeterminate endoscopy.
- ◆ Gastrointestinal protein loss study (CPT® 78282) is indicated for decreased serum albumin or globulins and no evidence of GI bleeding.

- ◆ Peritoneal-venous shunt patency study (CPT® 78291) is indicated for evaluation of shunt patency and function in a individual with ascites.
- ◆ Nuclear renal imaging (CPT® 78701, CPT® 78707, CPT® 78708, or CPT® 78709) is indicated for evaluation of the following:
 - Renal transplant follow-up
 - Kidney salvage vs. nephrectomy surgical decisions
 - Acute renal failure with no evidence of obstruction on recent ultrasound
 - Chronic renal failure to estimate prognosis for recovery
- 3D Rendering
 - ◆ 3D Rendering indications in pediatric abdomen imaging are identical to those in the general imaging guidelines. See: **3D Rendering (Preface-4.1)** in the Preface Imaging Guidelines.

The guidelines listed in this section for certain specific indications are not intended to be all-inclusive; clinical judgment remains paramount and variance from these guidelines may be appropriate and warranted for specific clinical situations.

References

1. Bridges MD. ACR–SPR Practice parameter for the performance and interpretation of magnetic resonance imaging (MRI). Revised 2022 (Resolution 8).
2. Karmazyn BK, John SD, Siegel MJ, et al. ACR–ASER–SCBT-MR–SPR Practice parameter for the performance of pediatric computed tomography (CT). Last review date: 2019 (Resolution 6).
3. Reighard C, Junaid S, Jackson WM, et al. Anesthetic exposure during childhood and neurodevelopmental outcomes: a systematic review and meta-analysis. *JAMA Netw Open*. 2022;5(6):e2217427. doi:10.1001/jamanetworkopen.202217427.
4. Abell TL, Camilleri M, Donohoe K, et al. Consensus Recommendations for Gastric Emptying Scintigraphy: A Joint Report of the American Neurogastroenterology and Motility Society and the Society of Nuclear Medicine. *The American Journal of Gastroenterology*. 2008;103(3):753-763. doi:10.1111/j.1572-0241.2007.01636.x.
5. Raju GS, Gerson L, Das A, Lewis B. American Gastroenterological Association (AGA) Institute Medical Position Statement on Obscure Gastrointestinal Bleeding. *Gastroenterology*. 2007;133(5):1694-1696. doi:10.1053/j.gastro.2007.06.008.
6. Zuckerman GR, Prakash C, Askin MP, Lewis BS. AGA technical review on the evaluation and management of occult and obscure gastrointestinal bleeding. *Gastroenterology*. 2000;118(1):201-221. doi:10.1016/s0016-5085(00)70430-6.
7. Morton KA, Clark PB, Christensen CR, et al. Diagnostic nuclear medicine. *Amirsys*. 2000 1st Ed. Chapter 8, pp 122-125.
8. Fraum TJ, Ludwig DR, Bashir MR, Fowler KJ. Gadolinium-based contrast agents: A comprehensive risk assessment. *Journal of Magnetic Resonance Imaging*. 2017;46(2):338-353. doi:10.1002/jmri.25625
9. Update on FDA approach to safety issue of gadolinium retention after administration of gadolinium-based contrast agents available at <https://www.fda.gov/media/116492/download>.
10. Blumfield E, Swenson DW, Iyer RS, Stanescu AL. Gadolinium-based contrast agents — review of recent literature on magnetic resonance imaging signal intensity changes and tissue deposits, with emphasis on pediatric patients. *Pediatric Radiology*. 2019;49(4):448-457. doi:10.1007/s00247-018-4304-8.
11. Implementation Guide: Medicaid State Plan Eligibility Groups Mandatory Coverage Infants and Children under Age 19 Guidance Portal. <https://www.hhs.gov/guidance/document/implementation-guide-medicaid-state-plan-eligibility-eligibility-groups-aeu-mandatory-2>.
12. Baluch, A., Shewayish, S. (2019). Neutropenic Fever. In: Velez, A., Lamarche, J., Greene, J. (eds) *Infections in Neutropenic Cancer Patients*. Springer, Cham. https://doi.org/10.1007/978-3-030-21859-1_8.

Generalized Abdominal Pain (PEDAB-2)

- Chronic abdominal pain is a common complaint among children and adolescents. Functional abdominal pain disorders, including functional abdominal pain and functional dyspepsia (including symptoms of epigastric pain, burning, postprandial fullness, early satiety), are conditions in which there is no structural or organic disease.
- Children with no red flag signs or symptoms, normal physical examination, and normal laboratory studies (preliminary labs may include CBC, electrolytes, lipase, amylase, urinalysis, ESR, CRP, LFTs, and/or stool for blood and stool culture if diarrhea) should initially be evaluated by ultrasound (CPT® 76700 or CPT® 76705) and treated conservatively.
 - ◆ Gastroenterology (GI) specialist evaluation or consultation is helpful in determining the need for advanced imaging in these cases.
 - ◆ CT Abdomen (CPT® 74160) or Abdomen and Pelvis (CPT® 74177) with contrast are indicated if there are any red flag signs or symptoms (as listed in **General Guidelines (AB-1.0)**)
- Children with abdominal pain that can be localized to a particular area of the abdomen should be imaged according to the relevant guideline section:
 - ◆ **Right Lower Quadrant Pain (PEDAB-3)**
 - ◆ **Flank Pain, Renal Stone (PEDAB-4)**
 - ◆ **Right Upper Quadrant Pain (PEDAB-8)**
 - ◆ **Left Upper Quadrant Pain (PEDAB-25)**
 - ◆ **Left Lower Quadrant Pain (PEDAB-29)**

References

1. Magbool A and Liacouras CA. Major symptoms and signs of digestive tract disorders. Nelson Textbook of Pediatrics, Chapter 322. eds Kliegman RM, St. Geme JW III, Blum NJ, Shah SS, Tasker RC, Wilson KM. 21st edition. 2020, pp 1902-1912.
2. Magbool A and Liacouras CA, Functional Gastrointestinal Disorders. Nelson Textbook of Pediatrics, Chapter 368. eds Kliegman RM, St. Geme JW III, Blum NJ, Shah SS, Tasker RC, Wilson KM. 21st edition 2020, pp 2041-2045.
3. Reust CE, Williams A. Acute abdominal pain in children. Am Fam Physician. 2016 May 15;93(10):830-6.
4. Cogley JR, O'Connor SC, Houshyar R, Dulaimy KA. Emergent Pediatric US: What Every Radiologist Should Know. RadioGraphics. 2012;32(3):651-665. doi:10.1148/rg.323115111.
5. Sanchez TR, Corwin MT, Davoodian A, Stein-Wexler R. Sonography of Abdominal Pain in Children. Journal of Ultrasound in Medicine. 2016;35(3):627-635. doi:10.7863/ultra.15.04047.
6. Harwood R, Partridge R, Minford J, Almond S. Paediatric abdominal pain in the time of COVID-19: a new diagnostic dilemma. J Surg Case Rep. 2020;2020(9):rjaa337. doi:10.1093/jscr/rjaa337.
7. Noda S, Ma J, Romberg EK, Hernandez RE, Ferguson MR. Severe COVID-19 initially presenting as mesenteric adenopathy. Pediatr Radiol. 2021;51(1):140-143. doi:10.1007/s00247-020-04789-9.
8. Caro-Domínguez P, Navallas M, Rianza-Martin L, Ghadimi Mahani M, et. al. Imaging findings of multisystem inflammatory syndrome in children associated with COVID-19. Pediatr Radiol. 2021;51(1):140-143. doi:10.1007/s00247-021-05065-0.
9. Koppen IJ, Nurko S, Saps M, Di Lorenzo C, Benninga MA. The pediatric Rome IV criteria: what's new? Expert Rev Gastroenterol Hepatol. 2017;11(3):193-201. doi:10.1080/17474124.2017.1282820.
10. Sahn B, Eze OP, Edelman MC, Chougar CE, Thomas RM, Schleien CL, Weinstein T. Features of Intestinal Disease Associated With COVID-Related Multisystem Inflammatory Syndrome in Children. J Pediatr Gastroenterol Nutr. 2021 Mar 1;72(3):384-387.

Right Lower Quadrant Pain (PEDAB-3)

- The presence of any red flag findings per **PEDAB-1.0: General Guidelines** precludes adjudication based on any other criteria.
- Ultrasound (CPT® 76700 or CPT® 76705) is indicated as the initial examination. If positive or negative for appendicitis, no further imaging is necessary.
 - ◆ If the appendix is not visualized on ultrasound and the white blood cell count is not elevated, no further imaging is necessary in nearly all cases, although the referring physician should make the final determination of the need for advanced imaging.
- CT Abdomen and Pelvis with contrast (CPT® 74177), CT Abdomen and Pelvis without contrast (CPT® 74176), MRI Abdomen and Pelvis without contrast (CPT® 74181 and CPT® 72195), or MRI Abdomen and Pelvis without and with contrast (CPT® 74183 and CPT® 72197) is indicated for any of the following:
 - ◆ Individuals who are overweight (BMI $\geq 85^{\text{th}}$ percentile for age)
 - ◆ Insufficient local ultrasound expertise exists
 - ◆ Ultrasound findings are inconclusive¹⁴
- If the appendix is absent, follow guidelines in: **Generalized Abdominal Pain (PEDAB-2)**

Background and Supporting Information

- CDC BMI Calculator for children ([BMI Calculator Child and Teen | Healthy Weight | CDC](#))

References

1. Aiken JJ. Acute Appendicitis. *Nelson Textbook of Pediatrics, Chapter 370*. eds Kliegman RM, Stanton BF, St. Geme JW III, et al. 21st edition 2020. pp 2048-2054.
2. Aspelund G, Fingeret A, Gross E, et al. Ultrasonography/MRI Versus CT for Diagnosing Appendicitis. *Pediatrics*. 2014;133(4):586-593. doi:10.1542/peds.2013-2128.
3. Moore MM, Gustas CN, Choudhary AK, et al. MRI for clinically suspected pediatric appendicitis: an implemented program. *Pediatric Radiology*. 2012;42(9):1056-1063. doi:10.1007/s00247-012-2412-4.
4. Kotagal M, Richards MK, Chapman T, et al. Improving ultrasound quality to reduce computed tomography use in pediatric appendicitis: the Safe and Sound campaign. *The American Journal of Surgery*. 2015;209(5):896-900. doi:10.1016/j.amjsurg.2014.12.029.
5. Kotagal M, Richards MK, Flum DR, Acierno SP, Weinsheimer RL, Goldin AB. Use and accuracy of diagnostic imaging in the evaluation of pediatric appendicitis. *Journal of Pediatric Surgery*. 2015;50(4):642-646. doi:10.1016/j.jpedsurg.2014.09.080.
6. Cohen B, Bowling J, Midulla P, et al. The non-diagnostic ultrasound in appendicitis: is a non-visualized appendix the same as a negative study? *Journal of Pediatric Surgery*. 2015;50(6):923-927. doi:10.1016/j.jpedsurg.2015.03.012.
7. Bachur RG, Levy JA, Callahan MJ, Rangel SJ, Monuteaux MC. Effect of Reduction in the Use of Computed Tomography on Clinical Outcomes of Appendicitis. *JAMA Pediatrics*. 2015;169(8):755. doi:10.1001/jamapediatrics.2015.0479.
8. Dibble EH, Swenson DW, Cartagena C, Baird GL, Herliczek TW. Effectiveness of a Staged US and Unenhanced MR Imaging Algorithm in the Diagnosis of Pediatric Appendicitis. *Radiology*. 2018;286(3):1022-1029. doi:10.1148/radiol.2017162755.
9. Koberlein GC, Trout AT, Rigsby CK, et al. ACR Appropriateness Criteria® Suspected Appendicitis-Child. *Journal of the American College of Radiology*. 2019;16(5). doi:10.1016/j.jacr.2019.02.022.
10. Repplinger MD, Pickhardt PJ, Robbins JB, et al. Prospective Comparison of the Diagnostic Accuracy of MR Imaging versus CT for Acute Appendicitis. *Radiology*. 2018;288(2):467-475. doi:10.1148/radiol.2018171838.
11. Harwood R, Partridge R, Minford J, Almond S. Paediatric abdominal pain in the time of COVID-19: a new diagnostic dilemma. *J Surg Case Rep*. 2020;2020(9):rjaa337. doi:10.1093/jscr/rjaa337.
12. Imler D, Keller C, Sivasankar S, et al. Magnetic resonance imaging versus ultrasound as the initial imaging modality for pediatric and young adult patients with suspected appendicitis. *Acad Emerg Med*. 2017;24(5):569-577. doi:10.1111/acem.13180.
13. Jennings R, Guo H, Goldin A, Wright DR. Cost-effectiveness of imaging protocols for suspected appendicitis. *Pediatrics*. 2020;145(2):e20191352. doi:10.1542/peds.2019-1352.
14. AlFrah Y, Robinson T, Stein N, Kam A, Flageole H. Quality assurance and performance improvement project for suspected appendicitis. *Pediatr Qual Saf*. 2020;5(3):e290. doi:10.1097/pq9.0000000000000290.
15. Wolfe C, Halsey-Nichols M, Ritter K, McCoin N. Abdominal pain in the emergency department: how to select the correct imaging for diagnosis. *Open Access Emerg Med*. 2022;14:335-345. doi:10.2147/OAEM.S342724.

Flank Pain, Renal Stone (PEDAB-4)

- The presence of any red flag findings per **PEDAB-1.0: General Guidelines** precludes adjudication based on any other criteria.
- Flank Pain imaging indications in pediatric individuals are very similar to those for adult individuals. See: **Flank Pain, Rule Out or Known Renal/Ureteral Stone (AB-4)** in the Abdomen Imaging Guidelines.
 - ◆ Ultrasound (CPT® 76770 or CPT® 76775) is the preferred initial study in children
 - ◆ CT Abdomen and Pelvis without contrast (CPT® 74176) is indicated if ultrasound is inconclusive.
 - ◆ MRI Abdomen (CPT® 74183) and Pelvis (CPT® 72197) without and with contrast is indicated if CT is inconclusive or if significant concern for radiation exposure from frequent CT use for a particular individual.
 - ◆ If hematuria is present, see: **Hematuria (PEDAB-7)** for imaging guidelines.
- Nuclear kidney imaging (CPT® 78707, CPT® 78708, CPT® 78709, or CPT® 78803) is indicated for evaluation of recurrent flank pain when CT and ultrasound are non-diagnostic, or for suspected obstructive uropathy.

References

1. American College of Radiology ACR Appropriateness Criteria® Acute onset of flank pain-Suspicion of stone disease (Urolithiasis) Revised 2015. <https://acsearch.acr.org/docs/69362/Narrative/>.
2. doi:10.1097/ruq.0b013e3182625974.
3. Kim CK, Biyyam DR, Becker MD, et al. ACR–SPR Practice parameter for the performance of renal scintigraphy. Revised 2017 (Resolution 29).
4. Tekgül S, Dogan HS, Kočvara R, et al. European Association of Urology. *European Society for Paediatric Urology. Guidelines on Paediatric Urology* 2015 with limited text update March 2017.
5. Mendichovszky I, Solar BT, Smeulders N, Easty M, Biassoni L. Nuclear Medicine in Pediatric Nephro-Urology: An Overview. *Seminars in Nuclear Medicine*. 2017;47(3):204-228. doi:10.1053/j.semnuclmed.2016.12.002.
6. Dillman JR, Rigsby CK, Iyer RS, Alazraki AL, Anupindi SA, Brown BP, Chan SS, Dorfman SR, Falcone RA, Garber MD, Nguyen JC. ACR Appropriateness Criteria® Hematuria-Child. *Journal of the American College of Radiology*. 2018 May 31;15(5):S91-103.
7. Bowen DK, Tasian GE. Pediatric Stone Disease. *Urologic Clinics of North America*. 2018;45(4):539-550. doi:10.1016/j.ucl.2018.06.002.

Urinary Tract Infection (UTI) (PEDAB-5)

Upper Urinary Tract (PEDAB-5.1)

Lower Urinary Tract (PEDAB-5.2)

Upper Urinary Tract (PEDAB-5.1)

- Ultrasound evaluation (CPT® 76770 or CPT® 76775) is initial imaging for all children with first time to diagnose hydronephrosis, pyelonephritis, or congenital renal anomaly.
 - ◆ If hydronephrosis is present, this should be further evaluated with voiding cystourethrography (VCUG), to evaluate for vesicoureteral reflux.
 - In boys, this is generally accomplished using fluoroscopic imaging and iodinated contrast to exclude urethral abnormalities.
 - In girls, Ureteral Reflux Study (Radiopharmaceutical Voiding Cystogram) (CPT® 78740) or fluoroscopic VCUG may be performed.¹⁵
 - Contrast Enhanced Voiding Urosonography (CeVUS) may also be utilized at institutions with expertise in this modality.¹⁵
- Diuretic renography using Tc-99m MAG 3 (CPT® 78707, CPT® 78708, or CPT® 78709) for:¹
 - ◆ Differentiating a dilated non-obstructed urinary system from a true stenosis (e.g., UPJ obstruction; ureteral-vesical junction [UVJ] obstruction).
 - ◆ Quantifying renal parenchymal function.
 - ◆ Ultrasound findings that are compatible with a multicystic dysplastic kidney to evaluate function of the affected kidney or a ureteral-pelvic junction (UPJ) obstruction of the contralateral kidney.
 - ◆ Diagnostic evaluation of upper tract dilatation when VCUG is negative.
 - ◆ Renal function evaluation in individuals with hydronephrosis.
- CT is sensitive in diagnosing pyelonephritis and has a role in evaluation of renal abscess or unusual complications such as xanthogranulomatous pyelonephritis but has no role in the routine evaluation of UTI.
 - ◆ CT Abdomen and Pelvis with contrast (CPT® 74177) is appropriate to evaluate the entire genitourinary tract for congenital abnormalities of distal tracts in complicated pyelonephritis.¹⁵
- Magnetic resonance urography (MRU) (CPT® 74183 and CPT® 72197), is not a first-line test for the routine evaluation of a UTI, but may be appropriate (where available) for investigation of a dilated upper urinary tract.
 - ◆ NOTE: MRU requires sedation in young children.
 - ◆ MRU can also quantitate renal function.
- Technetium-99m-dimercaptosuccinic acid (Tc-99m DMSA) scintigraphy (CPT® 78700, CPT® 78701, or CPT® 78803), is sensitive for evaluation of renal cortical damage.^{11, 13}
 - ◆ DMSA scintigraphy is indicated for:
 - Individuals with atypical or recurrent febrile acute urinary tract infections.¹¹
 - Atypical findings may include poor response to antibiotics, elevated creatinine, poor urine stream, or non E-coli organism.
 - Individuals with febrile urinary tract infections older than 5 years of age with known vesicoureteral reflux.¹⁴
 - For detection of post-pyelonephritic renal scarring at least 6 months after the documented upper tract UTI in high-risk individuals with recurrent UTIs.¹³

- Radiopharmaceutical nuclear medicine imaging (CPT® 78800, CPT® 78801, CPT® 78802, CPT® 78803, CPT® 78830, CPT® 78831, or CPT® 78832) is indicated for evaluation of suspected pyelonephritis or diffuse interstitial nephritis.
- Nuclear non-imaging renal function study (CPT® 78725) is a quantitative study that can be used to evaluate renal function.
- Children with atypical (poor response to antibiotics within 48 hours, sepsis, poor urine stream, raised creatinine, or non-E. coli UTI) or recurrent febrile UTI may be imaged with US kidneys and bladder (CPT® 76770 or CPT® 76775) (preferred) and/or Voiding cystourethrography (CPT® 78740).

Lower Urinary Tract (PEDAB-5.2)

- Ultrasound evaluation (CPT® 76770 or CPT® 76775) is initial imaging for all children with first time UTI to diagnose hydronephrosis, pyelonephritis, or congenital renal anomaly.
 - ◆ Fluoroscopic Voiding cystourethrography (VCUG) is indicated for detection of possible vesico-ureteral reflux (VUR) in neonates or young children when hydronephrosis is seen on ultrasound.
- The American Academy of Pediatrics clinical practice guidelines no longer recommend routine VCUG for infants and young children from 2 to 24 months of age after the first febrile UTI.
 - ◆ The current recommendation is to postpone the VCUG until the second febrile UTI UNLESS there are:
 - Atypical or complex clinical circumstances.
 - Renal/bladder ultrasound reveals hydronephrosis, scarring, or obstructive uropathy.
- Vesicoureteral Reflux (VUR)
 - ◆ Fluoroscopic VCUG is typically performed for diagnosis and grading of VUR, and should be the first modality used for diagnosis.
 - ◆ Ureteral Reflux Study (Radiopharmaceutical Voiding Cystogram) (CPT® 78740), fluoroscopic VCUG, or CeVUS may be used for follow up imaging of VUR¹⁵
- Male individuals with first UTI should be evaluated with fluoroscopic VCUG studies rather than radionuclide cystography, to visualize the male urethra for possible abnormalities such as posterior urethral valves, strictures, or diverticula.
- For female individuals, radionuclide cystography (CPT® 78740) or fluoroscopic VCUG, may be used as the initial study.
- MR urography is indicated for evaluation of ectopic distal ureteral insertion, or other complex lower urinary tract anatomy.
- Siblings of individuals with known vesicoureteral reflux can undergo Ureteral Reflux Study (Radiopharmaceutical Voiding Cystogram) (CPT® 78740) if they have renal scarring on ultrasound or history of UTI and no prior evaluation for VUR.

References

1. Bartel TB, Dhingra J, Nadel HR, et al. ACR–ACNM–SPR practice parameter for the performance of renal scintigraphy. *Am Coll Radiol*. Revised 2020. <https://www.acr.org/-/media/ACR/Files/Practice-Parameters/MR-SoftTissue-Tumors.pdf>.
2. Urinary Tract Infection: Clinical Practice Guideline for the Diagnosis and Management of the Initial UTI in Febrile Infants and Children 2 to 24 Months. *Pediatrics*. 2011;128(3):595-610. doi:10.1542/peds.2011-1330.
3. Elder JS. Urinary tract infections. *Nelson Textbook of Pediatrics, Chapter 538*. eds Kliegman RM, Stanton BF, St. Geme JW III, et al. 20th edition. 2016, pp 2556-2562.
4. Jackson EC. Urinary Tract Infections in Children: Knowledge Updates and a Salute to the Future. *Pediatrics in Review*. 2015;36(4):153-166. doi:10.1542/pir.36-4-153.
5. Peters CA, Skoog SJ, Arant BS, et al. Management and screening of primary vesicoureteral reflux in children. American Urological Association. Published 2010. Reviewed and Validity Confirmed 2017.
6. Fettich J, Colarinha P, Fischer S, et al. Guidelines for direct radionuclide cystography in children. *European Journal of Nuclear Medicine and Molecular Imaging*. 2003;30(5). doi:10.1007/s00259-003-1137-x.
7. Mendichovszky I, Solar BT, Smeulders N, Easty M, Biassoni L. Nuclear Medicine in Pediatric Nephro-Urology: An Overview. *Seminars in Nuclear Medicine*. 2017;47(3):204-228. doi:10.1053/j.semnuclmed.2016.12.002.
8. Riccabona M. Imaging in childhood urinary tract infection. *La radiologia medica*. 2015;121(5):391-401. doi:10.1007/s11547-015-0594-1.
9. Karmazyn BK, Alazraki AL, Anupindi SA, et. al. Expert Panel on Pediatric Imaging. ACR Appropriateness Criteria® Urinary Tract Infection–Child. Revised 2017. *J Am Coll Radiol*. 2017;14:S362-S371. doi:10.1016/j.jacr.2017.02.028. <https://acsearch.acr.org/docs/69444/Narrative/>.
10. Buettcher M, Trueck J, Niederer-Loher A, et. al. Swiss consensus recommendations on urinary tract infections in children. *European journal of pediatrics*. 2021;180(3):663-74.
11. Vali R, Armstrong IS, Bar-Sever Z, et. al. SNMMI procedure standard/EANM practice guideline on pediatric [99mTc] Tc-DMSA renal cortical scintigraphy: an update. *Clinical and Translational Imaging*. 2022;4:1-2.
12. Ergun R, Sekerci CA, Tanidir Y, et. al. Abnormal DMSA renal scan findings and associated factors in older children with vesicoureteral reflux. *International Urology and Nephrology*. 2021;53(10):1963-8.
13. ACR–SPR practice parameter for the performance of fluoroscopic and sonographic voiding cystourethrography in children. Revised 2019 (Resolution 10). Available at: <https://www.acr.org/-/media/ACR/Files/Practice-Parameters/voidingcysto.pdf?la=en>
14. Smith, A, Nickoladis P, Kharu G., et. al. American College of Radiology Expert Panel on Urological Imaging. ACR Appropriateness Criteria® Acute Pyelonephritis. *Am Coll Radiol (ACR)*; Revised 2022. <https://acsearch.acr.org/docs/69489/Narrative/>.

Pediatric Acute Gastroenteritis (PEDAB-6)

- Advanced imaging is not indicated in pediatric acute gastroenteritis, unless there is a concern for diagnosis other than acute gastroenteritis. See specific symptom/diagnosis sections listed below.
- CT Abdomen and Pelvis with contrast (CPT® 74177) is indicated if abdominal red flag symptoms are present as listed in **General Guidelines (PEDAB-1.0)**.
- Additional imaging studies will depend on the specific symptoms. See the following sections for additional imaging guidelines:
 - ◆ **Generalized Abdominal Pain (PEDAB-2)** in the Pediatric Abdomen Imaging Guidelines
 - ◆ **Right Lower Quadrant Pain (PEDAB-3)** in the Pediatric Abdomen Imaging Guidelines
 - ◆ **Right Upper Quadrant Pain (PEDAB-8)** in the Pediatric Abdomen Imaging Guidelines
 - ◆ **Inflammatory Bowel Disease, Crohn Disease, or Ulcerative Colitis (PEDAB-9)** in the Pediatric Abdomen Imaging Guidelines
 - ◆ **Constipation, Diarrhea, and Irritable Bowel Syndrome (PEDAB-12)** in the Pediatric Abdomen Imaging Guidelines
 - ◆ **Abdominal mass (PEDAB-13)** in the Pediatric Abdomen Imaging Guidelines
 - ◆ **Left Upper Quadrant (PEDAB-25)** in the Pediatric Abdomen Imaging Guidelines
 - ◆ **Intussusception (PEDAB-27)** in the Pediatric Abdomen Imaging Guidelines
 - ◆ **Bowel Obstruction (PEDAB-28)** in the Pediatric Abdomen Imaging Guidelines
 - ◆ **Left Lower Quadrant Pain (PEDAB-29)** in the Pediatric Abdomen Imaging Guidelines

References

1. Kotloff KL. Acute gastroenteritis in children. *Nelson Textbook of Pediatrics. Chapter 366.* eds Kliegman RM, St. Geme JW III, Blum NJ, Shah SS, Tasker RC, Wilson KM. 21st edition. 2020, pp 2012-2032.

Hematuria (PEDAB-7)

Hematuria is a relatively common complaint in pediatric individuals, and the imaging considerations are different from those occurring in adult individuals.

- Ultrasound kidneys (CPT® 76770 or CPT® 76775) and bladder (CPT® 76856 or CPT® 76857) for asymptomatic gross hematuria or microscopic hematuria with proteinuria present.
- No imaging is appropriate for asymptomatic microscopic hematuria without proteinuria.
- For painful hematuria and no recent trauma, ANY of the following studies can be approved:
 - ◆ CT Abdomen and Pelvis without contrast (CPT® 74176)
 - ◆ Ultrasound kidneys (CPT® 76770 or CPT® 76775)
 - ◆ Ultrasound bladder (CPT® 76856 or CPT® 76857)
- For hematuria and recent trauma, the following studies are indicated:
 - ◆ CT Abdomen and Pelvis with contrast (CPT® 74177)
 - ◆ CT Cystography (CT Pelvis with bladder contrast – CPT® 72193), if gross hematuria is present and pelvic fracture or traumatic bladder injury is suspected.

References

1. Dillman JR, Rigsby CK, Iyer RS, Alazraki AL, Anupindi SA, Brown BP, Chan SS, Dorfman SR, Falcone RA, Garber MD, Nguyen JC. ACR Appropriateness Criteria® Hematuria-Child. Journal of the American College of Radiology. 2018 May 31;15(5):S91-103.
2. Flores FX. Clinical evaluation of the child with hematuria. Nelson Textbook of Pediatrics. Chapter 536. eds Kliegman RM, St. Geme JW III, Blum NJ, Shah SS, Tasker RC, Wilson KM. 21st edition 2020, pp 2718-2720.
3. ACR Appropriateness Criteria® Hematuria-Child. Revised 2018.

Right Upper Quadrant Pain (PEDAB-8)

- The presence of any red flag findings per **General Guidelines (PEDAB-1.0)** precludes adjudication based on any other criteria.
- Right upper quadrant pain imaging indications in pediatric individuals are very similar to those for adult individuals. See: **Abdominal Pain (AB-2)** in the Abdomen Imaging Guidelines.
 - ◆ US abdomen (CPT® 76700) and/or Nuclear medicine imaging of the hepatobiliary system (HIDA scan, CPT® 78226 or CPT® 78227) for initial diagnosis for:
 - Suspicion of acute cholecystitis or acalculous cholecystitis (symptoms may include RUQ pain with fever, elevated white blood cell count, positive Murphy sign).
 - Suspicion of stones and bile duct obstruction (symptoms may include RUQ pain, no fever, normal white blood cell count)
 - Ultrasound results are not needed prior to nuclear medicine imaging of the hepatobiliary system (HIDA scan, CPT® 78226)¹
 - ◆ MRI Abdomen with and without contrast (CPT® 74183) or CT Abdomen with contrast (CPT® 74160) when either US or NM is equivocal.
 - ◆ In individuals with complaints of RUQ pain with no fever and an ultrasound shows only gallstones, MRI Abdomen without contrast (CPT® 74181), MRI Abdomen without and with contrast (CPT® 74183) or Nuclear medicine imaging of the hepatobiliary system (HIDA scan, CPT® 78226) is indicated to exclude other sources of pain.

References

1. Kambadakone A, Santillan C, Kim D, et al. ACR Appropriateness Criteria® Right Lower Quadrant Pain—Suspected Appendicitis. Revised 2022. <https://acsearch.acr.org/docs/69357/Narrative/>.
2. Gerard PS, Biyyam DR, Brown RKJ, et al. ACR-SPR practice parameter for the performance of hepatobiliary scintigraphy. *ACR Practice Parameters*. Revised 2021 (Resolution 22).

Inflammatory Bowel Disease, Crohn Disease, or Ulcerative Colitis (PEDAB-9)

- Enterography is the most appropriate advanced imaging study for individuals with inflammatory bowel disease (IBD).
 - ◆ MR enterography (CPT® 74183 and CPT® 72197) is generally preferred over CT when possible to avoid radiation exposure for children

Children with Suspected Crohn Disease

Clinical features including weight loss, loose stools, vomiting, and intermittent abdominal pain. Small bowel imaging can provide important information to guide treatment relating to presence, severity, and extent of Crohn's disease and its complications. Initial evaluation typically includes laboratory evaluation and upper and lower endoscopy.

- MR Enterography (CPT® 74183 and CPT® 72197), CT Enterography (CPT® 74177), or MRI Abdomen and Pelvis without and with contrast (CPT® 74183 and CPT® 72197) for ANY of the following:¹
 - ◆ To detect severity and distribution of inflammatory changes
 - ◆ Identify complications (such as fistulizing disease or abscess formation)
- MR Enterography (CPT® 74183 and CPT® 72197) or CT Enterography (CPT® 74177) for evaluation of chronic abdominal pain associated with diarrhea due to concern for inflammatory bowel disease if:
 - ◆ There is a positive family history of inflammatory bowel disease **OR**
 - ◆ There are endoscopy or colonoscopy findings suggestive of inflammatory bowel disease **OR**
 - ◆ Elevated inflammatory markers (fecal lactoferrin $\leq 4.0\text{ug/g}$, CRP $>0.5\text{mg/dL}$, or fecal calprotectin $\geq 50\text{ug/g}$) **OR**
 - ◆ Diagnosis is still in doubt after colonoscopy and evaluation of inflammatory markers, and Crohn's disease is suspected
- MR Enterography (CPT® 74183 and CPT® 72197) or CT Enterography (CPT® 74177) is indicated prior to endoscopy if requested by or in consultation with the physician who will be performing the endoscopy.⁶
- MRI Pelvis with contrast (CPT® 72196) or MRI Pelvis without and with contrast (CPT® 72197) is indicated for the following:¹
 - ◆ Concern for perianal fistula or abscess
- See: **IBD (Crohn's Disease or Ulcerative Colitis) (AB-23.1)** in the Abdomen Imaging Guidelines for additional information regarding serologic markers

Children with Established IBD

- MR Enterography (CPT® 74183 and CPT® 72197), CT Enterography (CPT® 74177), or MRI Abdomen and Pelvis without and with contrast (CPT® 74183 and CPT® 72197), is indicated for ANY of the following:¹
 - ◆ Monitoring response to disease-modifying treatment on an annual basis or when treatment change is being considered
 - ◆ Individuals with new or worsening symptoms or suspected complications including abscess, perforation, fistula, or obstruction
- CT Abdomen and Pelvis with contrast (CPT® 74177) is indicated if requested (instead of CTE or MRE) for ANY of the following:¹
 - ◆ New or worsening symptoms
 - ◆ Suspected complications including abscess, perforation, fistula, or obstruction
- MRI Pelvis with contrast (CPT® 72196) or MRI Pelvis without and with contrast (CPT® 72197) is indicated for the following:¹
 - ◆ Concern for perianal fistula or abscess

References

1. Moore MM, Gee MS, Iyer RS, et. al. ACR Appropriateness Criteria® Crohn Disease-Child. *J Am Coll Radiol*. 2022;19(5S):S19-S36.
2. Duigenan S, Gee MS. Imaging of Pediatric Patients With Inflammatory Bowel Disease. *American Journal of Roentgenology*. 2012;199(4):907-915. doi:10.2214/ajr.11.7966.
3. Grossman AB and Baldassano RN. Inflammatory bowel disease. *Nelson Textbook of Pediatrics, Chapter 336*. eds Kliegman RM, Stanton BF, St. Geme JW III, et al. 20th edition. 2016, pp 1819-1831.
4. Maltz R, Podberesky DJ, Saeed SA. Imaging modalities in pediatric inflammatory bowel disease. *Current Opinion in Pediatrics*. 2014;26(5):590-596. doi:10.1097/mop.000000000000131.
5. Schooler GR, Hull NC, Mavis A, Lee EY. MR Imaging Evaluation of Inflammatory Bowel Disease in Children: Magnetic Resonance Imaging Clinics of North America. 2019;27(2):291-300. doi:10.1016/j.mric.2019.01.007.
6. Bruining DH, Zimmermann EM, Loftus EV Jr, Sandborn WJ, Sauer CG, Strong SA. Consensus recommendations for evaluation, interpretation, and utilization of computed tomography and magnetic resonance enterography in patients with small bowel Crohn's disease. *Radiology*. 2018;154(4):1172-1194. doi:10.1148/radiol.2018171737.

Abdominal Sepsis (Suspected Abdominal Abscess) (PEDAB-10)

- Abdominal sepsis imaging indications in pediatric individuals are identical to those for adult individuals.
 - ◆ See: **Abdominal Sepsis (Suspected Abdominal Abscess) (AB-3)** in the Abdomen Imaging Guidelines.

Postoperative Pain within 60 Days Following Abdominal Surgery (PEDAB-11)

- CT Abdomen and Pelvis with contrast (CPT® 74177) is indicated in individuals with suspected postoperative complications (e.g. bowel obstruction, abscess, anastomotic leak, etc.).
 - ◆ Children can also be evaluated with ultrasound (CPT® 76700 or CPT® 76705) initially (especially in small children or in thin older children) or MRI Abdomen and Pelvis without and with contrast (CPT® 74183 and CPT® 72197).
 - ◆ Because MRI may not be practical for the timely evaluation of post-operative abscesses, MRI should only replace CT when the study can be completed in a similar time frame as CT.
- Radiopharmaceutical nuclear medicine imaging (CPT® 78800, CPT® 78801, CPT® 78802, CPT® 78803, CPT® 78830, CPT® 78831, or CPT® 78832) is indicated for evaluation of any of the following:
 - ◆ Peritonitis
 - ◆ Postoperative fever without localizing signs or symptoms
- Beyond 60 days postoperatively, see: **Generalized Abdominal Pain (PEDAB-2)**.

References

1. Chang KJ, Marin DM, Kim DH, et al. Suspected small bowel obstruction. *ACR Appropriateness Criteria*®. Date of origin: 1996. Last review date: 2019.
2. Yagmhai V, Rosen MP, Lalani T, et al. Acute (nonlocalized) abdominal pain and fever or suspected abdominal abscess. *ACR Appropriateness Criteria*®. Date of origin: 1996. Last review date: 2012.
3. Vries EFJD, Roca M, Jamar F, Israel O, Signore A. Guidelines for the labelling of leucocytes with 99mTc-HMPAO. *European Journal of Nuclear Medicine and Molecular Imaging*. 2010;37(4):842-848. doi:10.1007/s00259-010-1394-4.

Constipation, Diarrhea, and Irritable Bowel Syndrome (PEDAB-12)

- Constipation and diarrhea are extremely common complaints in children. The overwhelming majority of individuals do not require advanced imaging for evaluation of constipation or diarrhea.
- Irritable bowel is rare in young children, but more common in adolescents. The overwhelming majority of individuals do not require advanced imaging for evaluation of irritable bowel syndrome.
 - ◆ In most cases, causes of constipation can be excluded based on a careful history and physical examination. Advanced Imaging should be performed if warning signs of other diseases are present.
- Constipation associated with additional signs or symptoms:
 - ◆ CT Abdomen (CPT® 74160) or Abdomen and Pelvis (CPT® 74177) with contrast are indicated if there are any red flag signs or symptoms (as listed in **General Guidelines (AB-1.0)**)
 - ◆ Clinical suspicion of tethered cord based on abnormal physical findings over the spine, abnormal neurological exam, or symptoms refractory to provider-directed treatment for at least 3 months⁶ (See: **Tethered Cord (PEDSP-5)** in the Pediatric Spine Imaging Guidelines).
- Diarrhea associated with additional signs or symptoms:
 - ◆ CT Abdomen (CPT® 74160) or Abdomen and Pelvis (CPT® 74177) with contrast are indicated if there are any red flag signs or symptoms (as listed in **General Guidelines (AB-1.0)**)
- Irritable bowel syndrome associated with additional signs or symptoms:
 - ◆ CT Abdomen (CPT® 74160) or Abdomen and Pelvis (CPT® 74177) with contrast are indicated if there are any red flag signs or symptoms (as listed in **General Guidelines (AB-1.0)**)
- A barium enema and rectal biopsy are indicated for diagnosis of Hirschsprung disease in children with features suggestive of this disorder. MRI Pelvis without and with contrast (CPT® 72197) may be indicated in post-operative patients who have signs of complications related to treatment to assess the position of the pulled-through bowel, the sphincter muscles, and the area of the posterior urethra.

References

1. Maqbool A, and Liacouras CA. Major symptoms and signs of digestive tract disorders. *Nelson Textbook of Pediatrics*, Chapter 332. eds Nelson Textbook of Pediatrics, Chapter XXX eds Kliegman RM, St. Geme JW III, Blum NJ, Shah SS, Tasker RC, Wilson KM. 21st edition 2020, pp 1902-1912.
2. Maqbool A and Liacouras CA, Functional Gastrointestinal Disorders. *Nelson Textbook of Pediatrics*, Chapter 368. eds Kliegman RM, St. Geme JW III, Blum NJ, Shah SS, Tasker RC, Wilson KM. 21st edition 2020, pp 2041-2045.
3. Maqbool A and Liacouras CA. Encopresis and functional constipation. *Nelson Textbook of Pediatrics, Chapter 335.3* eds Kliegman RM, St. Geme JW III, Blum NJ, Shah SS, Tasker RC, Wilson KM. 21st edition. 2020. pp 1958-1961.
4. Kotloff KL Acute Gastroenteritis in Children. *Nelson Textbook of Pediatrics, Chapter 366*. eds Kliegman RM, St. Geme JW III, Blum NJ, Shah SS, Tasker RC, Wilson KM. 21st edition. 2020, p 2033-2041.
5. Zella GC, Israel EJ. Chronic Diarrhea in Children. *Pediatrics in Review*. 2012;33(5):207-218. doi:10.1542/pir.33-5-207.
6. Hasosah M. Chronic refractory constipation in children: Think beyond stools. *Glob Pediatr Health*. 2021;8. doi:10.1177/2333794X211048739.

Abdominal Mass (PEDAB-13)

Abdominal Wall Mass (PEDAB-13.1)

Intra-Abdominal Mass (PEDAB-13.2)

Abdominal Wall Mass (PEDAB-13.1)

- For initial imaging of a newly discovered abdominal wall mass, ANY of the following studies are indicated:
 - ◆ Ultrasound (CPT® 76700 or CPT® 76705)
 - ◆ MRI Abdomen without contrast (CPT® 74181) or without and with contrast (CPT® 74183)
 - ◆ MRI Pelvis without contrast (CPT® 72195) or without and with contrast (CPT® 72197) may be added to MRI Abdomen if below the umbilicus
- If ultrasound and/or MRI are inconclusive or insufficient for preoperative planning, ANY of the following studies are indicated:
 - ◆ CT Abdomen with contrast (CPT® 74160) or without contrast (CPT® 74150)
 - ◆ CT Abdomen and Pelvis with contrast (CPT® 74177) or without contrast (CPT® 74176) if below the umbilicus

Intra-Abdominal Mass (PEDAB-13.2)

- Ultrasound (CPT® 76700) should be the initial imaging study for children with an intra-abdominal mass.
 - ◆ US with Doppler (CPT® 93975) can also be used to evaluate vascular supply.⁵
- Additional imaging studies will be determined by the results of the ultrasound, and will depend on the location and organ involvement associated with the mass as well as history, physical exam, and laboratory findings. See the following sections for additional imaging guidelines:
 - ◆ **General Guidelines (PEDONC-1)** in the Pediatric Oncology Imaging Guidelines
 - ◆ **Pediatric Lymphomas (PEDONC-5)** in the Pediatric Oncology Imaging Guidelines
 - ◆ **Neuroblastoma (PEDONC-6)** in the Pediatric Oncology Imaging Guidelines
 - ◆ **Pediatric Renal Tumors (PEDONC-7)** in the Pediatric Oncology Imaging Guidelines
 - ◆ **Pediatric Germ Cell Tumors (PEDONC-10)** in the Pediatric Oncology Imaging Guidelines
 - ◆ **Pediatric Liver Tumors (PEDONC-11)** in the Pediatric Oncology Imaging Guidelines
 - ◆ **Pediatric Adrenocortical Carcinoma (PEDONC-14)** in the Pediatric Oncology Imaging Guidelines
 - ◆ **Liver Lesion Characterization (PEDAB-15)**
 - ◆ **Adrenal Lesions (PEDAB-17)**
 - ◆ **Indeterminate Renal Lesion (PEDAB-19)**
 - ◆ **Spleen (PEDAB-26)**

References

1. Allen-Rhoades W and Steuber CP. Clinical assessment and differential diagnosis of the child with suspected cancer. *Principles and Practice of Pediatric Oncology*. eds Pizzo PA and Poplack DG. 7th edition 2016. pp. 101-111.
2. Malkan AD, Loh A, Bahrami A, et al. An Approach to Renal Masses in Pediatrics. *Pediatrics*. 2014;135(1):142-158. doi:10.1542/peds.2014-1011.
3. Crane GL, Hernanz-Schulman M. Current Imaging Assessment of Congenital Abdominal Masses in Pediatric Patients. *Seminars in Roentgenology*. 2012;47(1):32-44. doi:10.1053/j.ro.2011.07.004.
4. Chung EM, Graeber AR, Conran RM. Renal Tumors of Childhood: Radiologic-Pathologic Correlation Part 1. The 1st Decade: From the Radiologic Pathology Archives. *RadioGraphics*. 2016;36(2):499-522. doi:10.1148/rg.2016150230.
5. Chung EM, Lattin GE, Fagen KE, et al. Renal Tumors of Childhood: Radiologic-Pathologic Correlation Part 2. The 2nd Decade: From the Radiologic Pathology Archives. *RadioGraphics*. 2017;37(5):1538-1558. doi:10.1148/rg.2017160189.
6. Kim HHR, Hull NC, Lee EY, Phillips GS. Pediatric abdominal masses: Imaging guidelines and recommendations. *Radiol Clin North Am*. 2022;60(1):113-129. doi:10.1016/j.rcl.2021.08.008.

Renovascular Hypertension and Other Secondary Causes of Hypertension (PEDAB-14)

- Clinical evaluation for suspected hypertension should include repeated blood pressure measurements (generally ≥3 measurements).
 - ◆ Trained health care professionals in the office setting should make a diagnosis of hypertension (HTN) if a child or adolescent has auscultatory-confirmed blood pressure (BP) readings ≥95th percentile at 3 different visits.¹³
 - ◆ Blood pressure may be obtained in-clinic, at home, or by using a wearable ambulatory blood pressure measurement (ABPM) device that records blood pressure at frequent intervals during normal activities and is downloaded later for computer analysis.

For Children Aged 1-<13 years	For Children Aged ≥13 years
Normal BP: <90 th Percentile	Normal BP: <120/<80 mm Hg
Elevated BP: ≥90th percentile to <95th percentile or 120/80 mm Hg to <95th percentile (whichever is lower)	Elevated BP: 120/<80 to 129/<80 mm Hg
Stage 1 HTN: ≥95th percentile to <95th percentile + 12 mmHg, or 130/80 to 139/89 mm Hg (whichever is lower)	Stage 1 HTN: 130/80 to 139/89 mm Hg
Stage 2 HTN: ≥95th percentile + 12 mm Hg, or ≥140/90 mm Hg (whichever is lower)	Stage 2 HTN: ≥140/90 mm Hg

Table from [13]

- ANY of the following studies are indicated for initial evaluation of a pediatric individual with suspected secondary hypertension:
 - ◆ Doppler or Duplex Ultrasound (CPT® 93975 or CPT® 93976)
 - ◆ Complete retroperitoneal Ultrasound (CPT® 76770)
 - ◆ Captopril renography (CPT® 78709) has largely been abandoned in clinical practice, replaced by CTA and MRA Abdomen, but may be supported for unusual circumstances.

Other considerations for imaging evaluation:

- CTA Abdomen (CPT® 74175) or MRA Abdomen (CPT® 74185)¹⁴ is indicated for pediatric individuals with hypertension to exclude fibromuscular dysplasia or other blood-flow restricting lesions of the renal arteries and suprarenal aorta.³
- Children with high clinical suspicion for renin-mediated hypertension should undergo additional imaging whether Doppler US findings are positive or negative due to poor sensitivity for detecting distal intrarenal or accessory renal artery stenosis.³ CTA has high sensitivity and specificity.¹⁴
- Echocardiography (CPT® 93306) is indicated at initial evaluation to screen for cardiac abnormalities, coarctation of the aorta, and end-organ damage such as left ventricular hypertrophy.
- Nuclear renal imaging (CPT® 78707, CPT® 78708, or CPT® 78709) is indicated for evaluation of the following:
 - ◆ Severe hypertension with progressive renal insufficiency or failure to respond to three-drug therapy
 - ◆ Malignant or accelerated hypertension

- ◆ Acute worsening of previously stable hypertension
- ◆ Diastolic BP >100 in an individual <35 years old
- ◆ New onset severe hypertension
- ◆ Hypertension in presence of asymmetric kidneys
- ◆ Hypertension in presence of acute elevation in creatinine either unexplained or after treatment with ACE inhibitor
- ◆ Abdominal bruit
- ◆ Recurrent acute pulmonary edema and hypertension
- ◆ Hypokalemia with normal or elevated plasma renin level in absence of diuretic therapy
- ◆ Hypertension with known neurofibromatosis

References

1. Castelli PK, Dillman JR, Smith EA, Vellody R, Cho K, Stanley JC. Imaging of Renin-Mediated Hypertension in Children. *American Journal of Roentgenology*. 2013;200(6). doi:10.2214/ajr.12.9427.
2. Chhadia S, Cohn RA, Vural G, Donaldson JS. Renal Doppler evaluation in the child with hypertension: a reasonable screening discriminator? *Pediatric Radiology*. 2013;43(12):1549-1556. doi:10.1007/s00247-013-2741-y.
3. Castelli PK, Dillman JR, Kershaw DB, Khalatbari S, Stanley JC, Smith EA. Renal sonography with Doppler for detecting suspected pediatric renin-mediated hypertension – is it adequate? *Pediatric Radiology*. 2013;44(1):42-49. doi:10.1007/s00247-013-2785-z.
4. Harvin HJ, Verma N, Nikolaidis P, et al. Renovascular hypertension. ACR Appropriateness Criteria®. Revised 2017.
5. Trautmann A, Roebuck DJ, McLaren CA, Brennan E, Marks SD, Tullus K. Non-invasive imaging cannot replace formal angiography in the diagnosis of renovascular hypertension. *Pediatric Nephrology*. 2016;32(3):495-502. doi:10.1007/s00467-016-3501-7.
6. Lande MB. Systemic hypertension. Nelson Textbook of Pediatrics, Chapter 445. eds Kliegman RM, Stanton BF, St. Geme JW III, et al. 20th edition 2016, pp 2294-2303.
7. Brady TM. Hypertension. *Pediatrics in Review*. 2012;33(12):541-552. doi:10.1542/pir.33-12-541.
8. Ilivitzki A, Glozman L, Alfonso RL, Ofer A, Razi NB, Shapira MR. Sonographic evaluation of renovascular hypertension in the pediatric population: State-of-the-art. *Journal of Clinical Ultrasound*. 2017;45(5):282-292. doi:10.1002/jcu.22467.
9. Mendichovszky I, Solar BT, Smeulders N, Easty M, Biassoni L. Nuclear Medicine in Pediatric Nephro-Urology: An Overview. *Seminars in Nuclear Medicine*. 2017;47(3):204-228. doi:10.1053/j.semnuclmed.2016.12.002.
10. Ingelfinger JR. The Child or Adolescent with Elevated Blood Pressure. *New England Journal of Medicine*. 2014;370(24):2316-2325. doi:10.1056/nejmcp1001120.
11. Kim CK, Biyyam DR, Becker MD, et al. ACR–SPR Practice Guideline for the Performance of Renal Scintigraphy. Revised 2017 (Resolution 29).
12. Tekgül S, Dogan HS, Kočvara R, et al. European Association of Urology. European Society for Paediatric Urology. Guidelines on Paediatric Urology 2015 with limited text update March 2017.
13. Flynn JT, Kaelber DC, Baker-Smith CM, et al. Clinical Practice Guideline for Screening and Management of High Blood Pressure in Children and Adolescents. *Pediatrics*. 2017;140(3):e20171904. doi:10.1542/peds.2017-3035.
14. Fleury AS, Durand RE, Cahill AM, et al. Validation of computed tomography angiography as a complementary test in the assessment of renal artery stenosis: a comparison with digital subtraction angiography. *Pediatr Radiol* 2021;51:2507–2520. doi:10.1007/s00247-021-05145-1.

Liver Lesion Characterization (PEDAB-15)

- ***High risk individuals⁹:**
 - ◆ Prematurity
 - ◆ Low birth weight
 - ◆ Underlying chronic liver disease
 - ◆ Beckwith Weidman syndrome
 - ◆ Familial adenomatous polyposis
 - ◆ Trisomy 18
 - ◆ Portosystemic shunts
 - ◆ Aicardi syndrome
 - ◆ Hereditary tyrosinemia
 - ◆ Bile salt export pump deficiency
- Pediatric-specific imaging considerations includes:
 - ◆ US Abdomen (CPT[®] 76700 or CPT[®] 76705) is the initial study of choice in children. MRI is preferred over CT when possible to reduce radiation exposure.
- Liver lesion discovered on US:
 - ◆ Any high risk individual*
 - MRI Abdomen without and with contrast (CPT[®] 74183) or CT Abdomen with contrast (CPT[®] 74160)
 - ◆ Indeterminate liver lesion <3cm
 - Contrast-Enhanced US (CEUS, CPT[®] 76978, CPT[®] 76979)
 - If after Contrast-Enhanced US the lesion remains indeterminate or not fully characterized:
 - MRI Abdomen without and with contrast (CPT[®] 74183) or CT Abdomen with contrast (CPT[®] 74160)
 - ◆ Indeterminate liver lesion >3cm
 - MRI Abdomen without and with contrast (CPT[®] 74183) or CT Abdomen with contrast (CPT[®] 74160)
- Liver lesion discovered on CT (non-contrast or single-contrast) or non-contrast MRI
 - ◆ Indeterminate Liver Lesion <3cm
 - Contrast-Enhanced US (CEUS, CPT[®] 76978, CPT[®] 76979)
 - If, after Contrast-Enhanced US, the lesion remains indeterminate or not fully characterized
 - MRI Abdomen without and with contrast (CPT[®] 74183) or CT Abdomen with contrast (CPT[®] 74160)
 - ◆ Indeterminate Liver Lesion >3cm
 - MRI Abdomen without and with contrast (CPT[®] 74183) or CT Abdomen with contrast (CPT[®] 74160)
- For the imaging of specific focal liver lesions:
 - ◆ Suspected hepatic adenoma:
 - MRI is considered the best technique for characterization. Follow-up imaging can be CT Abdomen (CPT[®] 74160 or CPT[®] 74170) or MRI Abdomen (CPT[®]

- 74183) every 6 months for 2 years, and then annually, to establish any growth patterns and assess for malignant transformation.
- ◆ Hepatic Hemangioma
 - Limited abdominal US in 6-12 months
 - If stable or decreasing in size: Surveillance 6-12 months until 2 years. After 2 years, no further follow-up is indicated unless it becomes symptomatic
 - If increasing in size: follow-up 3-6 months or biopsy
 - See below for pre-operative considerations
 - ◆ Focal Nodular Hyperplasia (FNH):
 - MRI Abdomen (CPT® 74183) or CT Abdomen (CPT® 74160 or CPT® 74170) to confirm a diagnosis of FNH. The use of Eovist contrast is often diagnostic in differentiating FNH from other lesions seen on MRI or CT.
 - Additional follow-up is limited abdominal US in 6-12 months
 - If stable or decreasing in size: Surveillance 6-12 months until 2 years. After 2 years, no further follow-up is indicated unless it becomes symptomatic.
 - In adolescent females diagnosed with FNH who are continuing to use oral contraceptives: Additional follow-up is annual US for 2 to 3 years. Follow-up with CT or MRI can be done if the lesion is not adequately visualized on US.
 - If increasing in size: follow-up 3-6 months or biopsy
 - ◆ Hepatic cysts:
 - Asymptomatic, simple cysts
 - Limited abdominal US in 6-12 months
 - If stable or decreasing in size: Surveillance 6-12 months until 2 years. After 2 years, no further follow-up is indicated unless it becomes symptomatic
 - If increasing in size: follow-up 3-6 months or biopsy
 - For complicated cysts (US shows internal septations, fenestrations, calcifications, irregular walls, as well as the presence of daughter cysts):
 - MRI Abdomen (CPT® 74183) or CT Abdomen (CPT® 74160 or CPT® 74170) can be performed

- Additional scenarios and follow-up imaging for an Indeterminate lesion:
 - ◆ Indeterminate lesion <1cm in high-risk individuals* on US, CT, or unenhanced MRI not specifically dealt with in the above guidelines:
 - If **biopsy cannot be performed**, follow-up MRI can be obtained in 3-6 months. Additional imaging in this setting can be considered on an individual basis. This timeframe would also apply if the lesion is indeterminate and an MRI with Eovist is requested for further evaluation in this setting
- Nuclear medicine liver imaging (ONE of CPT® codes: CPT® 78201, CPT® 78202, CPT® 78803, CPT® 78215, or CPT® 78216) is rarely performed, but can be approved for the following when ultrasound, CT, and MRI are unavailable or contraindicated:
 - ◆ Evaluation of liver mass, trauma, or suspected focal nodular hyperplasia (FNH)
 - ◆ Differentiation of hepatic hemangioma from FNH
 - ◆ Diffuse hepatic disease or elevated liver function tests
 - ◆ Suspected accessory spleen (CPT® 78215 or CPT® 78216 only)

Background and Supporting Information

- For liver lesions in children, it is important to differentiate between benign incidental versus malignant lesions.

TABLE 1. Risk factors for malignant liver tumors in children [7-9]

◆ Hepatoblastoma	◆ Hepatocellular carcinoma
◆ Prematurity	◆ Liver cirrhosis
◆ Low birth weight	◆ Chronic hepatitis B and C
◆ BWS and other overgrowth syndromes	◆ Hereditary tyrosinemia
◆ Familial adenomatous polyposis	◆ Portosystemic shunts
◆ Trisomy 18	◆ Bile salt export pump deficiency
◆ Portosystemic shunts	
◆ Aicardi syndrome	

Data from [7–9]. BWS = Beckwith-Wiedemann syndrome

References

1. Hegde SV, Dillman JR, Lopez MJ, Strouse PJ. Imaging of multifocal liver lesions in children and adolescents. *Cancer Imaging*. 2012;12(3):516-529. doi:10.1102/1470-7330.2012.0045.
2. Fernandez-Pineda I. Differential diagnosis and management of liver tumors in infants. *World Journal of Hepatology*. 2014;6(7):486. doi:10.4254/wjh.v6.i7.486.
3. Siegel MJ, Masand PM. Liver. In: Siegel MJ, editor. *Pediatric Sonography*. 5th ed, Philadelphia, Wolters Kluwer, 2019. p 211-272.
4. Squires JE and Balistreri WF. Evaluation of patients with possible liver dysfunction. *Nelson Textbook of Pediatrics*, Chapter 382.1. eds Kliegman RM, St. Geme JW III, Blum NJ, Shah SS, Tasker RC, Wilson KM. 21st edition. 2020, pp 2089-2092.
5. Chung EM, Cube R, Lewis RB, Conran RM. Pediatric Liver Masses: Radiologic-Pathologic Correlation Part 1. Benign Tumors. *RadioGraphics*. 2010;30(3):801-826. doi:10.1148/rg.303095173.
6. Shamir SB, Kurian J, Kogan-Liberman D, Taragin BH. Hepatic Imaging in Neonates and Young Infants: State of the Art. *Radiology*. 2017;285(3):763-777. doi:10.1148/radiol.2017170305.
7. Bernard O, Franchi-Abella S, Branchereau S, et al. Congenital portosystemic shunts in children: recognition, evaluation, and management. *Semin Liver Dis*. 2012;32:273-87.
8. Kalish JM, Doros L, Helman LJ, et al. Surveillance recommendations for children with overgrowth syndromes and predisposition to wilms tumors and hepatoblastoma. *Clin Cancer Res*. 2017;23:e115-22.
9. Karmazyn B, Rao GS, Johnstone L, et. al. Diagnosis and follow-up of incidental liver lesions in children. *Journal of Pediatric Gastroenterology and Nutrition*. 2022;74(3):320-327.

Liver Disease (PEDAB-16)

Pediatric Liver Failure and Cirrhosis (PEDAB 16.1)

Biliary Disease (PEDAB 16.2)

Pediatric Liver Failure and Cirrhosis (PEDAB 16.1)

- Elevated liver function testing imaging indications in pediatric individuals are very similar to those for adult individuals. See: **Abnormal Liver Chemistries (AB-30)** in the Abdomen Imaging Guidelines.
- Causes of liver failure or cirrhosis in pediatric individuals are different from adults, and are frequently idiopathic, but commonly due to ONE of the following:
 - ◆ Biliary dysfunction (biliary atresia, cystic fibrosis, etc.)
 - ◆ Metabolic disease
 - ◆ Post-infectious
- Liver ultrasound (CPT® 76700) with duplex Doppler (CPT® 93975) is indicated as an initial study for individuals prior to approving CT or MRI for pediatric individuals.
 - ◆ MRI Abdomen without and with contrast (CPT® 74183) is indicated for evaluation of ultrasound findings that are inconclusive or technically limited, and is preferred over CT when possible to reduce radiation exposure.
- Repeat liver ultrasound (CPT® 76705) with duplex Doppler (CPT® 93975) is indicated in pediatric individuals in the following circumstances:
 - ◆ Known chronic liver dysfunction or cirrhosis of any cause may be reimaged on an annual basis in the absence of new or worsening findings
 - ◆ New or worsening findings on history, physical exam, or laboratory results that suggest progression of liver disease
 - ◆ Doppler ultrasound liver (CPT® 93975 or CPT® 93976) is indicated when portal venous congestion or portal hypertension is suspected
- Nuclear medicine liver imaging (ONE of CPT® codes: CPT® 78201, CPT® 78202, CPT® 78803, CPT® 78215, or CPT® 78216) is rarely performed, but can be approved for the following when ultrasound, CT, and MRI are unavailable or contraindicated:
 - ◆ Diffuse hepatic disease or elevated liver function tests

References

1. Squires JE and Balistreri WF. Evaluation of patients with possible liver dysfunction. *Nelson Textbook of Pediatrics, Chapter 382.1*. eds Kliegman RM, St. Geme JW III, Blum NJ, Shah SS, Tasker RC, Wilson KM. 21st edition 2020, pp 2089-2092.
2. Fusillo S, Rudolph B. Nonalcoholic Fatty Liver Disease. *Pediatrics in Review*. 2015;36(5):198-206. doi:10.1542/pir.36-5-198.
3. Rijn RV, Nieveelstein R. Paediatric ultrasonography of the liver, hepatobiliary tract and pancreas. *European Journal of Radiology*. 2014;83(9):1570-1581. doi:10.1016/j.ejrad.2014.03.025.
4. Paranjape SM, Mogayzel PJ. Cystic Fibrosis. *Pediatrics in Review*. 2014;35(5):194-205. doi:10.1542/pir.35-5-194
5. Royal HD, Brown ML, Drum DE, et al. Society of Nuclear Medicine Procedure guideline for hepatic and splenic imaging 3.0, version 3.0, approved July 20, 2003.

Biliary Disease (PEDAB 16.2)

- The definition of conjugated hyperbilirubinemia is serum conjugated bilirubin >1mg/dL if total bilirubin <5.0 or greater than 20 percent of total bilirubin if total bilirubin >5.0mg/dL. Obstructive causes of liver disease need to be evaluated. Additional labs may include total and fractionated bilirubin, AST, ALT, Alk Phos, GGT, and/or urinalysis.
- Ultrasound Abdomen (CPT® 76700 or CPT® 76705) is initial imaging study of choice
- Advanced imaging such as CT, MRI is rarely indicated unless otherwise indicated below.
- After initial ultrasound:
 - ◆ If Biliary Atresia is suspected:
 - Hepatobiliary System imaging (HIDA scan) can be approved if requested by surgeon before liver biopsy
 - Liver biopsy is diagnostic
 - Advanced imaging such as CT, MRI is rarely indicated
 - ◆ If Choledochal cyst is suspected:
 - CT Abdomen with contrast (CPT® 74160) or MRI/MRCP (CPT® 74183 or CPT® 74181) can be approved.
 - For preoperative assessment: MRI/MRCP (CPT® 74183 or CPT® 74181) can be approved
 - ◆ If primary biliary disease such as Primary sclerosing cholangitis or primary biliary cholangitis is suspected:
 - CT Abdomen with contrast (CPT® 74160) or MRI/MRCP (CPT® 74183 or CPT® 74181) can be approved.

References

1. Soares KC, Goldstein SD, Ghaseb MA, Kamel I, Hackam DJ, Pawlik TM. Pediatric choledochal cysts: diagnosis and current management. *Pediatr Surg Int*. 2017 Jun;33(6):637-650. doi: 10.1007/s00383-017-4083-6. Epub 2017 Mar 31. PMID: 28364277.
2. Abbey P, Kandasamy D, Naranje P. Neonatal Jaundice. *Indian J Pediatr*. 2019 Sep;86(9):830-841. doi: 10.1007/s12098-019-02856-0. Epub 2019 Feb 21. PMID: 30790186.

Adrenal Lesions (PEDAB-17)

- Adrenal masses in infants and young children usually present as palpable abdominal masses or are detected on in utero US. In the neonates, the common masses are adrenal hemorrhage and neuroblastoma. Abdominal US is the initial imaging study of choice.
 - ◆ If an adrenal mass is detected, it can often be adequately evaluated with short interval follow-up retroperitoneal ultrasound (CPT® 76770) in 7 to 10 days.
 - If repeat ultrasound is concerning for neuroblastoma or there is high clinical concern for neuroblastoma, MRI Abdomen without and with contrast (CPT® 74183) or CT Abdomen without and with contrast (CPT® 74170) are indicated to confirm the diagnosis. MRI is preferred over CT when possible to reduce radiation exposure. If these studies, confirm neuroblastoma ¹²³I-Metaiodobenzylguanidine (MIBG) scintigraphy is indicated for staging.
 - ◆ Neuroblastoma is the most common primary adrenal tumor in pediatric individuals between day 1 and 5 years of age. See: **Neuroblastoma (PEDONC-6)** in the Pediatric Oncology Imaging Guidelines.
- Additional adrenal imaging considerations include the following:
 - ◆ Adrenal Nuclear Imaging of the cortex and/or medulla (CPT® 78075) is indicated for the following:
 - Distinguishing adrenal adenoma from adrenal hyperplasia.
 - Evaluation of suspected pheochromocytoma or paraganglioma.
 - MIBG preferred (ONE of CPT® codes: CPT® 78800, CPT® 78801, CPT® 78802, CPT® 78803, or CPT® 78804).
 - For known pheochromocytoma or paraganglioma, see: **Neuroendocrine Cancers and Adrenal Tumors (ONC-15)** in the Oncology Imaging Guidelines.
 - Evaluation of suspected neuroblastoma, ganglioneuroblastoma, or ganglioneuroma.
 - MIBG preferred (ONE of CPT® codes: CPT® 78800, CPT® 78801, CPT® 78802, CPT® 78803, or CPT® 78804 or hybrid SPECT/CT CPT® 78830, CPT® 78831, or CPT® 78832), see: **Neuroblastoma (PEDONC-6)** in the Pediatric Oncology Imaging Guidelines.
 - History of multiple endocrine neoplasia syndromes: See **Multiple Endocrine Neoplasias (MEN) (PEDONC-2.8)** in the Pediatric Oncology Imaging Guidelines.
 - History of neurofibromatosis: See **Neurofibromatosis 1 and 2 (NF1 and NF2) (PEDONC-2.3)** in the Pediatric Oncology Imaging Guidelines
 - History of von Hippel-Lindau disease: See **Von Hippel-Lindau Syndrome (VHL) (PEDONC-2.10)** in the Pediatric Oncology Imaging Guidelines

References

1. Gawande, R, Castenaeda, R and Daldrup-Link, H. Adrenal hemorrhage in pearls and pitfalls. *Pediatric imaging: variants and other difficult diagnoses*. eds. Heike E, Daldrup-Link, and Newman B. Cambridge University Press, Apr 24, 2014.
2. Moreira SG, Pow-Sang JM. Evaluation and Management of Adrenal Masses. *Cancer Control*. 2002;9(4):326-334. doi:10.1177/107327480200900407.
3. Sharp SE, Gelfand MJ, Shulkin BL. Pediatrics: Diagnosis of Neuroblastoma. *Seminars in Nuclear Medicine*. 2011;41(5):345-353. doi:10.1053/j.semnuclmed.2011.05.001.
4. Bombardieri E, Giammarile F, Aktolun C, et al. 131I/123I-Metaiodobenzylguanidine (mIBG) scintigraphy: procedure guidelines for tumour imaging. *European Journal of Nuclear Medicine and Molecular Imaging*. 2010;37(12):2436-2446. doi:10.1007/s00259-010-1545-7.
5. Chrisoulidou A, Kaltsas G, Ilias I, Grossman AB. The diagnosis and management of malignant pheochromocytoma and paraganglioma. *Endocrine-Related Cancer*. 2007;14(3):569-585. doi:10.1677/erc-07-0074.
6. Ganguly A. Primary Aldosteronism. *New England Journal of Medicine*. 1998;339(25):1828-1834. doi:10.1056/nejm199812173392507
7. Orth DN. Cushings Syndrome. *New England Journal of Medicine*. 1995;332(12):791-803. doi:10.1056/nejm199503233321207.
8. Siegel MJ, Chung EM. Adrenal gland, pancreas, and other retroperitoneal structures. In Siegel MJ, editor. *Pediatric sonography*. 5th ed. Philadelphia, Wolters Kluwer, 2019. p 467-512.
9. White PC. Congenital adrenal hyperplasia and related disorders. *Nelson Textbook of Pediatrics*, Chapter 594. eds Kliegman RM, St. Geme JW III, Blum NJ, Shah SS, Tasker RC, Wilson KM. 21st edition. 2020, pp 2970-2979.
10. Sargar KM, Khanna G, Bowling RH. Imaging of Nonmalignant Adrenal Lesions in Children. *RadioGraphics*. 2017;37(6):1648-1664. doi:10.1148/rg.2017170043.

Hemochromatosis (PEDAB-18)

Hereditary (Primary) Hemochromatosis (PEDAB-18.1)

Transfusion-Associated (Secondary) Hemochromatosis (PEDAB-18.2)

Hereditary (Primary) Hemochromatosis (PEDAB-18.1)

- Hereditary hemochromatosis imaging indications in pediatric individuals are identical to those for adult individuals. See: **Hereditary (Primary) Hemochromatosis (HH) and Other Iron Storage Diseases (AB-11.2)** in the Abdomen Imaging Guidelines.

Transfusion-Associated (Secondary) Hemochromatosis (PEDAB-18.2)

- Transfusion-associated hemochromatosis is a common complication of exposure to repeated red blood cell transfusions. This can occur in any individual with exposure to >20 transfusion episodes, but is most common among sickle cell disease, thalassemia, bone marrow failure (aplastic anemia, Fanconi anemia, etc.), oncology patients, and hematopoietic stem cell transplant patients.
- T2* MRI has been well established in the determination of organ iron burden in transfusion-associated hemochromatosis. Contrast use is not necessary for evaluation of iron burden. The following studies are indicated for evaluation of transfusion-associated hemochromatosis:
 - ◆ MRI Abdomen without contrast (CPT® 74181) for liver iron evaluation.
 - ◆ MRI Cardiac without contrast (CPT® 75557) for cardiac iron evaluation.
 - ◆ MRI Chest without contrast (CPT® 71550) can be approved as a single study to evaluate both heart and liver iron burden.
 - ◆ CPT® 74181 and CPT® 75557 can be approved alone, or together.
 - ◆ If requested, CPT® 71550 will evaluate both heart and liver and should not be approved with any other codes.
- Screening MRI is indicated every 12 months for chronically transfused individuals at risk of hemochromatosis.
- Imaging is indicated every 3 months for treatment response in individuals receiving active treatment (chelation and/or phlebotomy).

References

1. Evidence-Based Management of Sickle Cell Disease: Expert Panel Report, 2014. *Pediatrics*. 2014;134(6). doi:10.1542/peds.2014-2986.
2. Chavhan GB, Babyn PS, Thomas B, Shroff MM, Haacke EM. Principles, Techniques, and Applications of T2*-based MR Imaging and Its Special Applications. *RadioGraphics*. 2009;29(5):1433-1449. doi:10.1148/rg.295095034.
3. Children's Oncology Group. Long-term follow-up guidelines for survivors of childhood, adolescent, and young adult cancers. Version 4.0 – October 2013, Monrovia, CA.

Indeterminate Renal Lesion (PEDAB-19)

- Indeterminate renal lesion characterization imaging indications in pediatric individuals are very similar to those for adult individuals. See: **Indeterminate Renal Lesion (AB-35)** in the Abdomen Imaging Guidelines.
- Indeterminate renal lesion imaging indications in pediatric individuals are uncommon and are usually cysts or congenital anomalies.
- Pediatric-specific imaging considerations include the following:
 - ◆ Pediatric renal cysts have a lower risk of malignant progression than do renal cysts in adults.
 - ◆ CT Abdomen with contrast (CPT® 74160) or MRI Abdomen without and with contrast (CPT® 74183) is indicated for individuals who have simple cysts but are symptomatic and surgical intervention is being considered.
 - ◆ CT Abdomen without and with contrast (CPT® 74170) or MRI Abdomen without and with contrast (CPT® 74183) is indicated for pediatric individuals with complex renal cyst identified on ultrasound.
 - ◆ For individuals with congenital anomalies, nuclear medicine studies with diuretic renography (CPT® 78708 or CPT® 78709) can be performed to determine function and cystography to determine presence of associated reflux.
 - ◆ Individuals with solid renal masses should be imaged according to guidelines in section **Pediatric Renal Tumors (PEDONC-7)** in the Pediatric Oncology Imaging Guidelines.

References

1. Karmazyn B, Tawadros A, Delaney L, et al. Ultrasound classification of solitary renal cysts in children. *Journal of Pediatric Urology*. 2015;11(3). doi:10.1016/j.jpuro.2015.03.001.
2. Kim CK, Biyyam DR, Becker MD, et al. ACR–SPR Practice parameter for the performance of renal scintigraphy. Revised 2017 (Resolution 29).
3. Mandell GA, Egli DF, Gilday DL, et al. Society of Nuclear Medicine, Procedure guideline for renal cortical scintigraphy in children, Version 3.0, approved June 20, 2003.

Hydronephrosis (PEDAB-20)

Hydronephrosis is a relatively common finding in pediatric individuals, with the following imaging considerations:

- Retroperitoneal ultrasound (CPT® 76770) for:
 - ◆ Prenatal hydronephrosis within the first week of life, and again at 1-6 months of age.
 - ◆ Known hydronephrosis every 3 to 12 months
 - This imaging represents a guideline-supported, scheduled follow-up imaging evaluation, as described in **Clinical Information (PREFACE-3)** in the Preface Imaging Guidelines. A current evaluation (within 60 days) would not be required for authorization.
- Hydronephrosis associated with urinary tract infection or vesicoureteral reflux, see: **Urinary Tract Infection (UTI) (PEDAB-5)** for imaging guidelines.
- Individuals with obstructive uropathy (including ureteropelvic junction obstruction (UPJO), ureterovesical junction obstruction (UVJO), and bladder outlet obstruction) can be evaluated with retroperitoneal ultrasound (CPT® 76770), and diuretic renography (CPT® 78707, CPT® 78708, or CPT® 78709) for preoperative planning and postoperatively at 3 to 12 months.
 - ◆ If hydronephrosis has resolved on postoperative imaging then no further routine imaging is indicated.
- Magnetic resonance urography (MRU) (CPT® 74183 and CPT® 72197) is rarely indicated, but can be approved in individuals with inconclusive ultrasound and diuretic renography.
- CT Abdomen with contrast (CPT® 74160) is rarely indicated, but can be approved in individuals with inconclusive ultrasound and a suspected vascular cause of UPJO.

References

1. Darge K, Siegel MJ. Kidney. In: Seigel MJ, editor Pediatric Sonography, 5th ed, Philadelphia, Wolters Kluwer, 2019. p 396-466.
2. Sinha A, Bagga A, Krishna A, et al. Revised guidelines on management of antenatal hydronephrosis. Indian Journal of Nephrology. 2013;23(2):83. doi:10.4103/0971-4065.109403.
3. Dervoort KV, Lasky S, Sethna C, et al. Hydronephrosis in Infants and Children: Natural History and Risk Factors for Persistence in Children Followed by a Medical Service. Clinical medicine Pediatrics. 2009;3. doi:10.4137/cmped.s3584.
4. Hsi RS, Holt SK, Gore JL, Lendvay TS, Harper JD. National Trends in Followup Imaging after Pyeloplasty in Children in the United States. Journal of Urology. 2015;194(3):777-782. doi:10.1016/j.juro.2015.03.123.
5. Elder JS. Obstruction of the urinary tract. Nelson Textbook of Pediatrics, Chapter 555. eds Kliegman RM, St. Geme JW III, Blum NJ, Shah SS, Tasker RC, Wilson KM. 21st edition. 2020, pp 2800-2810.
6. Nguyen HT, Benson CB, Bromley B, et al. Multidisciplinary consensus on the classification of prenatal and postnatal urinary tract dilation (UTD classification system). Journal of Pediatric Urology. 2014;10(6):982-998. doi:10.1016/j.jpuro.2014.10.002.
7. Chow JS, Koning JL, Back SJ, Nguyen HT, Phelps A, Darge K. Classification of pediatric urinary tract dilation: the new language. Pediatric Radiology. 2017;47(9):1109-1115. doi:10.1007/s00247-017-3883-0.
8. Brown BP, Simoneaux SF, Dillman JR, Rigsby CK, Iyer RS, Alazraki AL, Bardo DM, Chan SS, Chandra T, Dorfman SR, Garber MD. ACR Appropriateness Criteria® Antenatal Hydronephrosis—Infant. Journal of the American College of Radiology. 2020 Nov 1;17(11):S367-79.

Polycystic Kidney Disease (PEDAB-21)

- Abdominal ultrasound (CPT® 76700) or retroperitoneal ultrasound (CPT® 76770) for clinical concern of polycystic kidney disease, or for screening individuals who are at risk for autosomal dominant polycystic kidney disease (ADPKD).

References

1. Devarajan P. Autosomal Recessive polycystic kidney disease. Nelson Textbook of Pediatrics, Chapter 541.2. eds Kliegman RM, St. Geme JW III, Blum NJ, Shah SS, Tasker RC, Wilson KM. 21st edition 2020, pp 2744-2747.
2. Devarajan P. Autosomal dominant polycystic kidney disease. Nelson Textbook of Pediatrics, Chapter 541.3. eds Kliegman RM, St. Geme JW III, Blum NJ, Shah SS, Tasker RC, Wilson KM. 21st edition 2020, p 2747-2748.
3. Gimpel C, Avni EF, Breysen L, et al. Imaging of Kidney Cysts and Cystic Kidney Diseases in Children: An International Working Group Consensus Statement. Radiology. 2019;290(3):769-782. doi:10.1148/radiol.2018181243.

Blunt Abdominal Trauma (PEDAB-22)

- Blunt abdominal trauma imaging indications in pediatric individuals are identical to those for adult individuals. See: **Blunt Abdominal Trauma (AB-10.1)** in the Abdomen Imaging Guidelines.

Hernias (PEDAB-23)

- Hernia imaging indications in pediatric individuals are identical to those for adult individuals. See: **Hernias (AB-12)** in the Abdomen Imaging Guidelines.

Abdominal Lymphadenopathy (PEDAB-24)

- Abdominal lymphadenopathy imaging indications in pediatric individuals are identical to those for adult individuals. See: **Abdominal Lymphadenopathy (AB-8)** in the Abdomen Imaging Guidelines.

Left Upper Quadrant Pain (PEDAB-25)

- Left upper quadrant pain imaging indications in pediatric individuals are identical to those for adult individuals. See: **Abdominal Pain (AB-2)** in the Abdomen Imaging Guidelines.
- Nuclear medicine spleen imaging (CPT® 78185) is rarely performed, but can be approved for left upper quadrant pain when neither ultrasound nor CT is available.

References

1. Royal HD, Brown ML, Drum DE, et al. Society of Nuclear Medicine Procedure guideline for hepatic and splenic imaging 3.0, version 3.0, approved July 20, 2003.

Spleen (PEDAB-26)

- Spleen imaging indications in pediatric individuals are very similar to those for adult individuals. See: **Spleen (AB-34)** in the Abdomen Imaging Guidelines.
- Nuclear medicine spleen imaging (CPT® 78185) is rarely performed, but can be approved for the following indications when CT is unavailable:
 - ◆ Splenic trauma.
 - ◆ Evaluation of splenic function.
 - ◆ Suspected splenic mass, cyst, abscess, infarct, or metastasis.
 - ◆ Radiation treatment planning.
 - ◆ Asplenia.
 - ◆ Suspected functional accessory spleen:
 - Can approve CPT® 78215 or CPT® 78216 instead of CPT® 78185, if requested.
- Pediatric-specific imaging considerations include the following:
 - ◆ MRI is preferred over CT when possible to reduce radiation exposure.

References

1. Brandow AM and Camitta BM. Splenomegaly. Nelson Textbook of Pediatrics, Chapter 513. eds Kliegman RM, St. Geme JW III, Blum NJ, Shah SS, Tasker RC, Wilson KM. 21st edition. 2020, pp. 2619-2620.
2. Brandow AM and Camitta BM. Hyposplenism, splenic trauma, and splenectomy. Nelson Textbook of Pediatrics, Chapter 514. eds Kliegman RM, St. Geme JW III, Blum NJ, Shah SS, Tasker RC, Wilson KM. 21st edition. 2020, pp. 2621-2622
3. Navarro OM, Siegel MJ. Spleen and Peritoneal Cavity. In: Siegel MJ, editor. Pediatric Sonography, 5th ed. Philadelphia. Wolters Kluwer. 2019. p 304-345.

Intussusception (PEDAB-27)

- Intussusception, telescoping of one bowel loop into another, is a frequent cause of abdominal pain in young children. It may be associated with bloody stool. Plain x-rays (supine and left lateral decubitus views) should be performed initially to exclude mass or bowel obstruction from other causes and to detect possible bowel perforation, which may be an indication for emergent surgical intervention.
 - ◆ Ultrasound (CPT® 76700 or CPT® 76705) is indicated as an initial study if there is a strong suspicion for intussusception, but if negative, plain x-rays of the abdomen should follow.
 - ◆ In some institutions, Ultrasound guidance (CPT® 76942) may be used for reduction of colonic or ileocolic intussusception. Generally, this is an urgent or emergent procedure and may not require prior authorization.

References

1. Maqbool A and Liacouras CA. Intussusception. Nelson Textbook of Pediatrics, Chapter 359.3. eds Kliegman RM, St. Geme JW III, Blum NJ, Shah SS, Tasker RC, Wilson KM. 21st edition. 2020, pp 1965-1967.
2. Edwards EA, Pigg N, Courtier J, Zapala MA, Mackenzie JD, Phelps AS. Intussusception: past, present and future. *Pediatric Radiology*. 2017;47(9):1101-1108. doi:10.1007/s00247-017-3878-x.
3. Coley BDBD. Caffey's Pediatric Diagnostic Imaging. Philadelphia, PA: Elsevier; 2019. Chapter 107, pp1040-1049.
4. Atweh LA, Naffaa L, Barakat A, Baassiri A. Imaging Acute Non-Traumatic Abdominal Pathologies in Pediatric Patients: A Pictorial Review. *Journal of Radiology Case Reports*. 2019;13(7). doi:10.3941/jrcr.v13i7.3443.

Bowel Obstruction (PEDAB-28)

Bowel Obstruction (PEDAB-28.1)

- Suspected high-grade obstruction
 - ◆ MRI Abdomen and Pelvis without and with contrast (CPT® 74183 and CPT® 72197) is preferred to avoid unnecessary radiation exposure
 - ◆ CT Abdomen and Pelvis with contrast (CPT® 74177) can be approved if MRI is not readily available
- Suspected intermittent or low-grade small bowel obstruction
 - ◆ MRI Abdomen and Pelvis without and with contrast (CPT® 74183 and CPT® 72197) is preferred to avoid unnecessary radiation exposure
 - ◆ CT Abdomen and Pelvis with contrast (CPT® 74177) can be approved if MRI is not readily available
 - ◆ If the etiology or level of suspected intermittent or low-grade small bowel obstruction remains undetermined and additional imaging is needed after CT Abdomen and Pelvis:
 - CT Enteroclysis (CPT® 74176 or 74177) or
 - CT Enterography (CPT® 74177) or
 - MR Enteroclysis (CPT® 74183 and CPT® 72197) or
 - MR Enterography (CPT® 74183 and CPT® 72197)
- Small bowel obstruction suspected to be secondary to Crohn's Disease
 - ◆ See: **Inflammatory Bowel Disease, Crohn Disease, or Ulcerative Colitis (PEDAB-9)**

References

1. Expert Panel on Gastrointestinal Imaging. ACR Appropriateness Criteria® suspected small-bowel obstruction. *American College of Radiology (ACR)*; 2019
2. Paulson EK, Thompson WM. Review of Small-Bowel Obstruction: The Diagnosis and When to Worry. *Radiology*. 2015;275(2):332-342. doi:10.1148/radiol.15131519.
3. Mullan CP, Siewert B, Eisenberg RL. Small Bowel Obstruction. *American Journal of Roentgenology*. 2012;198(2). doi:10.2214/ajr.10.4998.

Left Lower Quadrant Pain (PEDAB-29)

Diverticulitis is the most common cause of left lower quadrant pain in adults but is extremely rare in children.

- CT Abdomen and Pelvis (CPT® 74177) with contrast is indicated if there are any red flag signs or symptoms (as listed in **General Guidelines (AB-1.0)**)
- In the absence of red flags, advanced imaging is rarely helpful in the initial evaluation of these individuals. Consultation with gastroenterologist can be helpful in determining the appropriate diagnostic pathway.
 - ◆ Pelvic ultrasound (CPT® 76856) is the initial imaging study of choice for children for detecting gynecologic abnormalities that may cause left lower quadrant pain.
 - ◆ For male individuals or if ultrasound is inconclusive, advanced imaging may be appropriate for management as directed by gastroenterological evaluation or consultation

References

1. Maqbool A, and Liacouras CA. Major symptoms and signs of digestive tract disorders. Nelson Textbook of Pediatrics, Chapter 332. eds Nelson Textbook of Pediatrics, Chapter XXX eds Kliegman RM, St. Geme JW III, Blum NJ, Shah SS, Tasker RC, Wilson KM. 21st edition 2020, pp 1902-1912.
2. Maqbool A and Liacouras CA, Functional Gastrointestinal Disorders. Nelson Textbook of Pediatrics, Chapter 368. eds Kliegman RM, St. Geme JW III, Blum NJ, Shah SS, Tasker RC, Wilson KM. 21st edition 2020, pp 2041-2045.

Celiac Disease (Sprue) (PEDAB-30)

- Celiac disease imaging indications in pediatric individuals are identical to those for adult individuals. See: **Celiac Disease (Sprue) (AB-24)** in the Abdomen Imaging Guidelines.

Transplant (PEDAB-31)

- Liver and kidney transplant imaging indications in pediatric individuals are identical to those for adult individuals. See: **Transplant (AB-42)** in the Abdomen Imaging Guidelines.
- For post-transplant lymphoproliferative disorder in pediatric individuals, see: **Pediatric Aggressive Mature B-Cell Non-Hodgkin Lymphomas (NHL) (PEDONC-5.3)** in the Pediatric Oncology Imaging Guidelines.

Gaucher Disease (PEDAB-32)

See: **Gaucher Disease (PEDPN-4)** in the Pediatric Peripheral Nerve Disorders Imaging Guidelines.

Vomiting Infant, Malrotation, and Hypertrophic Pyloric Stenosis (PEDAB-33)

- Vomiting in infants is generally classified as either bilious (implying obstruction distal to the Sphincter of Oddi) or non-bilious.
- Bilious vomiting may be a true emergency, as some of the conditions causing this could result in compromise of blood supply to the intestines, a potentially life-threatening situation.
- Nonbilious vomiting in otherwise healthy infants may be imaged with Upper GI series (UGI)
- Suspected malrotation is an indication for emergent imaging. If malrotation with mid-gut volvulus is suspected, acute abdominal series (Chest X-ray and abdominal views, including supine and upright or supine and left lateral decubitus views), followed by UGI series (preferred) and/or Ultrasound abdomen, limited (CPT® 76705) should be performed. If the abdominal X-rays suggest distal bowel obstruction, water soluble contrast enema should be considered.
- Hypertrophic Pyloric Stenosis is an idiopathic condition wherein the circular muscle controlling emptying of the stomach thickens causing a relative obstruction of the gastric outlet. The condition can occur at any age (including occasionally in adults), but the typical child is male, aged 2 to 6 weeks. Projectile non-bilious vomiting is the most common presenting complaint, but the description of projectile vomiting is subjective. The differential diagnosis for non-bilious vomiting includes common conditions such as viral gastroenteritis and gastro-esophageal reflux.
 - ◆ Infants with projectile non-bilious vomiting should be evaluated with Ultrasound abdomen, limited (CPT® 76705). If initial studies are not diagnostic, repeat studies should be performed, as frequently as daily until the vomiting resolves or the diagnosis is made. UGI series may be useful as a confirmatory test, may be preferred if ultrasound expertise is not available for this condition, or if the clinical presentation is atypical for Hypertrophic Pyloric Stenosis. Ultrasound is preferred when available, as it involves no contrast or ionizing radiation use.

References

1. Hunter AK and Liacouras CA. Hypertrophic pyloric stenosis. Nelson Textbook of Pediatrics. Chapter 329.1. eds Kliegman RM, Stanton BF, St. Geme JW III, et al. 20th edition. 2016, pp 1797-1799.
2. Hunter AK and Liacouras CA, Malrotation. Nelson Textbook of Pediatrics. Chapter 330.3. eds Kliegman RM, Stanton BF, St. Geme JW III, et al. 20th edition. 2016, pp 1803-1804.
3. Zhou L-Y, Li S-R, Wang W, et al. Usefulness of Sonography in Evaluating Children Suspected of Malrotation. Journal of Ultrasound in Medicine. 2015;34(10):1825-1832. doi:10.7863/ultra.14.10017.
4. Hwang J-Y. Emergency ultrasonography of the gastrointestinal tract of children. Ultrasonography. 2017;36(3):204-221. doi:10.14366/usg.16052.
5. Atweh LA, Naffaa L, Barakat A, Baassiri A. Imaging Acute Non-Traumatic Abdominal Pathologies in Pediatric Patients: A Pictorial Review. Journal of Radiology Case Reports. 2019;13(7). doi:10.3941/jrcr.v13i7.3443.
6. Coley BDBD. Caffey's Pediatric Diagnostic Imaging. Philadelphia, PA: Elsevier; 2019. Chapters 100 and 102.
7. American College of Radiology ACR Appropriateness Criteria® Vomiting in Infants. Revised 2020. <https://acsearch.acr.org/docs/69445/Narrative/>.

Pancreatitis (PEDAB-34)

Acute Pancreatitis (PEDAB 34.1)

Chronic Pancreatitis (PEDAB 34.2)

Acute Pancreatitis (PEDAB 34.1)

- The presence of any red flag findings per **General Guidelines (PEDAB-1.0)** precludes adjudication based on any other criteria.
 - ◆ If red flag is present (as per **General Guidelines (PEDAB-1.0)**), then CT Abdomen and Pelvis with contrast (CPT® 74177), CT Abdomen with contrast (CPT® 74160), or MRI/MRCP (CPT® 74183 or CPT® 74181) is indicated²
- Initial imaging
 - ◆ Abdominal US (CPT® 76700 or CPT® 76705) can be approved
 - ◆ If ultrasound performed and is nondiagnostic due to technical limitation (obesity, overlying gas, etc.), or if ultrasound is negative and there is continued clinical suspicion of acute pancreatitis MRI/MRCP (CPT® 74183 or CPT® 74181) can be approved.
 - CT Abdomen and Pelvis with contrast (CPT® 74177) or CT Abdomen with contrast (CPT® 74160) if MRI/MRCP cannot be performed
 - ◆ CT Abdomen and Pelvis with contrast (CPT® 74177) can be approved for management of acute pancreatitis in the following situations:
 - Evaluation of known or suspected complications of acute pancreatitis
 - To characterize degree of organization of collections before intervention
- Abdominal US (CPT® 76700 or CPT® 76705) can be used to follow known fluid collections for resolution or progression
- Acute Recurrent Pancreatitis (ARP)
 - ◆ MRI/MRCP (CPT® 74183 or CPT® 74181) can be approved
 - To identify structural or obstructive causes.
 - To assess for progression to chronic pancreatitis
 - ◆ In a child who requires sedation for imaging, it is reasonable to alternate MRI/MRCP with Abdominal US (CPT® 76700 or CPT® 76705) or CT Abdomen with contrast (CPT® 74160) for serial monitoring of acute recurrent pancreatitis as recommended by or in consultation with a gastroenterologist or pancreatic specialist.

Background and Supporting Information

- The role of imaging is to identify findings at diagnosis, assess for local complications, identify potential etiologies, monitor evolution of local complications, plan and guide interventions.

Chronic Pancreatitis (PEDAB 34.2)

- The role of imaging is to contribute to or establish initial diagnosis, stage/monitor disease, assess for superimposed acute pancreatitis, identify potential etiologies of chronic pancreatitis, characterize secretory function, and/or plan for surgical intervention
- If chronic pancreatitis is suspected:
 - ◆ MRI Abdomen without and with contrast (CPT® 74183) may be approved.
 - CT Abdomen and Pelvis with contrast (CPT® 74177) or CT Abdomen with contrast (CPT® 74160) may be approved if MRI cannot be performed
- Abdominal US (CPT® 76700 or CPT® 76705) may be approved to evaluate suspected or known episode of acute pancreatitis in a child with chronic pancreatitis.
 - ◆ CT Abdomen and Pelvis with contrast (CPT® 74177) or CT Abdomen with contrast (CPT® 74160) or MRI/MRCP (CPT® 74183 or CPT® 74181) may be approved in the following situations:
 - If ultrasound is negative and imaging diagnosis of acute pancreatitis is needed
 - If planning endoscopic or surgical interventions

References

1. Trout AT, Anupindi SA, Freeman AJ, et. al. North American Society for Pediatric Gastroenterology, Hepatology and Nutrition and the Society for Pediatric Radiology joint position paper on noninvasive imaging of pediatric pancreatitis: literature summary and recommendations. *J Pediatr Gastroenterol Nutr.* 2021;72(1):151-167.
2. Trout AT, Ayyala RS, Murati MA, et. Al. . Current state of imaging of pediatric pancreatitis: *AJR* expert panel narrative review. *AJR Am J Roentgenol.* 2021;217(2):265-277. doi:10.2214/AJR.21.25508.

Table of Contents

Guideline

General Information

General Guidelines (PEDCD-1.0)

Congenital Heart Disease

Congenital Heart Disease General Information (PEDCD-2.1)

Congenital Heart Disease Coding (PEDCD-2.2)

Congenital Heart Disease Modality Considerations (PEDCD-2.3)

Imaging and Surveillance per Congenital lesion (PEDCD-2.4)

Atrial Defects-Secundum ASD, PFO, and Partial anomalous pulmonary venous return (PAPVR), Sinus Venosus defect (PEDCD-2.4.1)

VSD (PEDCD-2.4.2)

AVSD (Atrioventricular canal, endocardial cushion defect) (PEDCD-2.4.3)

PDA (Patent ductus arteriosus) (PEDCD-2.4.4)

TAPVR Total anomalous pulmonary venous return (PEDCD-2.4.5)

Ebstein anomaly and TV dysplasia (PEDCD-2.4.6)

Pulmonary Stenosis (PS) (PEDCD-2.4.7)

Pulmonary Atresia with intact septum (PAIVS) (PEDCD-2.4.8)

Mitral valve disease (PEDCD-2.4.9)

LVOT lesions (PEDCD-2.4.10)

Aortic Coarctation and IAA (interrupted aortic arch) (PEDCD-2.4.11)

Coronary Anomalies (PEDCD-2.4.12)

Tetralogy of Fallot (TOF) (PEDCD-2.4.13)

Double Outlet Right Ventricle (DORV) (PEDCD-2.4.14)

D-Loop Transposition of the Great Arteries (D-Loop TGA) (PEDCD-2.4.15)

Congenitally Corrected Transposition of the Great Arteries (ccTGA, LTGA) (PEDCD-2.4.16)

Truncus Arteriosus (PEDCD-2.4.17)

Single Ventricle (SV) (PEDCD-2.4.18)

Eisenmenger and PHT (with CHD)- (PEDCD-2.4.19)

References (PEDCD-2)

Condition Specific Imaging

Multisystem Inflammatory Syndrome in Children (MIS-C) (PEDCD-12)

Heart Murmur (PEDCD-3.1)

Chest Pain General (PEDCD-4.1)

Syncope (PEDCD-5.1)

Pediatric Pulmonary Hypertension General (PEDCD-7.1)
Evaluation of Pericardial Effusion or Diagnosis of Pericardial Tamponade (PEDCD-9.5)
Kawasaki Disease (PEDCD-6)

Echocardiography

Transthoracic Echocardiography (TTE) Coding (PEDCD-8.1)
Initial Transthoracic Echocardiography (TTE) Indications (PEDCD-8.2)
Repeat Transthoracic Echocardiography Indications (PEDCD-8.3)
Transesophageal Echocardiography (TEE) (PEDCD-8.4)
Fetal Echo (PEDCD-8.5)
References (PEDCD-8)

Computed Tomography

CT Heart and Coronary Computed Tomography Angiography (CCTA) General Considerations (PEDCD-10.1)
Indications for CCTA (CPT® 75574) (PEDCD-10.3)
Indications for Cardiac CT (CPT® 75572) (PEDCD-10.4)
Indications for Chest CTA with Cardiac CT or CTA (PEDCD-10.5)
References (PEDCD-10)

Magnetic Resonance Imaging

Cardiac MRI Coding (PEDCD-9.2)
Indications for Cardiac MRI (PEDCD-9.3)
Indications for Chest MRA for Congenital heart disease (PEDCD-9.4)
References (PEDCD-9)

Diagnostic Heart Catheterization

Cardiac Catheterization General Information (PEDCD-11.1)
Cardiac Catheterization Indications (PEDCD-11.2)
References (PEDCD-11)

General Information

Guideline

General Guidelines (PEDCD-1.0)

General Guidelines (PEDCD-1.0)

CDP.GG.0001.0.A

v1.0.2024

Heart disease in the pediatric population involves predominantly congenital lesions. Pediatric individuals can have acquired heart disease unique to children. For those diseases which occur in both pediatric and adult populations, differences exist in management due to individual age, comorbidities, and differences in disease natural history between children and adults.

Pediatric Cardiac Imaging Appropriate Clinical Evaluation

- Prior to considering advanced imaging (CT, MR, Nuclear Medicine) or echocardiogram, a pertinent clinical evaluation should be performed, including the following (both):
 - A detailed history, physical examination or meaningful technological contact (telehealth visit, telephone call, electronic mail or messaging)
 - A review of appropriate diagnostic studies (laboratory, EKG, echo, and other diagnostic imaging)
- A recent clinical evaluation is not needed prior to advanced imaging (CT, MR, Nuclear Medicine) or echocardiogram if **any** of the following apply:
 - Individual is undergoing guideline-supported scheduled imaging evaluation
 - Echocardiogram is being performed at the first cardiology visit for an appropriate indication as stated in these guidelines
 - Routine imaging is anticipated at the next visit (e.g., one year follow-up echo for a 10 year old with a VSD)
- Advanced imaging of the heart and echocardiogram are medically necessary in any of the following:
 - Individuals who have documented active clinical signs or symptoms of disease involving the heart
 - As follow-up for findings on echocardiograms.
 - See **Initial Transthoracic Echocardiography (TTE) Indications (PEDCD-8.2)** for indications for initial echos in asymptomatic individuals
- Repeat imaging studies of the heart are **not** indicated unless one of the following applies:
 - Repeat imaging is indicated in a specific guideline section
 - There is evidence for progression of disease
 - There is new onset of disease with documentation of how repeat imaging will affect individual management or treatment decisions
 - See **Repeat Transthoracic Echocardiography Indications (PEDCD-8.3)** for indications for repeat echos in asymptomatic individuals

- Asymptomatic individuals with exposure to cardiotoxic drugs can have serial echocardiograms as per **Cardiotoxicity and Echocardiography (PEDONC-19.2)** in the Pediatric Oncology Imaging Guideline
- Advanced imaging and echocardiogram is **not** indicated, in the absence of other appropriate indications listed in these guidelines, for **any** of the following:
 - Individuals starting ADHD medications
 - To screen asymptomatic individuals for disorders involving the heart

Pediatric Cardiac Imaging Modality General Considerations

- MRI
 - MRI and MRA studies are frequently indicated for evaluation of congenital heart defects not well visualized on echocardiography, thoracic arteries and veins not visualized on echocardiography, cardiomyopathies, and right ventricular disease, as well as in follow-up for these indications.
 - Due to the length of time for image acquisition and the need for the individual to be motionless during the acquisition, anesthesia is required for almost all infants and young children (age <7 years), as well as older children with delays in development or maturity. In this population, MRI imaging sessions should be planned with a goal of avoiding a short-interval repeat anesthesia exposure due to insufficient information using the following considerations:
 - MRI is typically performed without and with contrast.
 - If multiple body areas are supported for the clinical condition being evaluated, MRI of all necessary body areas should be obtained concurrently in the same anesthesia session.
- CT
 - CT is primarily used to evaluate the coronary and great vessels in congenital heart disease if cardiac MR is contraindicated.
 - Coding considerations are listed in **CT Heart and Coronary Computed Tomography Angiography (CCTA) – Other Indications (PEDCD-10)**
- Ultrasound
 - Echocardiography is the primary modality used to evaluate the anatomy and function of the pediatric heart, and is generally indicated before considering other imaging modalities.
 - Coding considerations are listed in **Echocardiography - Other Indications (PEDCD-8)**
- Nuclear Medicine
 - SPECT, PET stress may be indicated for individuals with anomalous CA, angina chest pain, and follow-up for Kawasaki and MIS-C. See specific sections for those indications.
 - Multi Gated Acquisition (MUGA) studies (CPT® 78472, CPT® 78473, CPT® 78481, CPT® 78483, CPT® 78494, or CPT® 78496) are rarely performed in pediatrics, but can be approved for the following:

- Certain pediatric oncology individuals when echocardiography is insufficient: See: for imaging guidelines.
- Quantitation of left ventricular function when recent echocardiogram shows ejection fraction of <50% and MUGA results will impact acute patient care decisions.
- SPECT/CT fusion imaging involves SPECT (MPI) imaging and CT for optimizing location, accuracy, and attenuation correction combines functional and anatomic information.
 - There is currently no evidence-based data to formulate appropriateness criteria for SPECT/CT fusion imaging.
 - Combined use of nuclear imaging, including SPECT, along with diagnostic CT (fused SPECT/CT) is considered investigational.
- Central C-V Hemodynamics (CPT® 78414) is not an imaging study and is an outdated examination
- Cardiac Shunt Detection (CPT® 78428) is rarely performed in pediatrics but can be approved for individuals in whom Cardiac MR is not diagnostic
 - Calculation of left and right ventricular ejection fractions
 - Assessment of wall motion
 - Quantitation of right to left shunts
- Myocardial Tc-99m Pyrophosphate Imaging
 - Infarct Avid Myocardial Imaging studies (CPT® 78466, CPT® 78468, and CPT® 78469), historically this method of imaging the myocardium, Myocardial Tc-99m Pyrophosphate Imaging, was used to identify recent infarction, hence, the term "infarct-avid scan." Although still available, the sensitivity and specificity for identifying infarcted myocardial tissue is variable and the current use for this indication is limited
 - CPT® 78466, CPT® 78468, and CPT® 78469, CPT® 78800 or CPT® 78803 may be used, for identification of myocardial ATTR (transthyretin) amyloidosis. See **Myocardial Tc-99m Pyrophosphate Imaging (CD-3.7)** and **Cardiac Amyloidosis (CD-3.8)**

MUGA (Multi Gated Acquisition) – Blood Pool Imaging	CPT®
Myocardial Imaging, infarct avid, planar, qualitative or quantitative	78466
Myocardial Imaging, infarct avid, planar, qualitative or quantitative with ejection fraction by first pass technique	78468
Myocardial Imaging, infarct avid, planar, qualitative or quantitative tomographic SPECT with or without quantification	78469
Radiopharmaceutical Localization Imaging Limited area	78800
Radiopharmaceutical Localization Imaging SPECT	78803
Note: When reporting CPT® 78803, planar imaging of a limited area or multiple areas should be included with the SPECT	

Supporting Information

Individuals who are <18 years old should be imaged according to the Pediatric Cardiac Imaging Guidelines and the general Cardiac Imaging Guidelines. Individuals who are age ≥18 years should be imaged according to the Cardiac Imaging Guidelines, except where directed otherwise by a specific guideline section. Adult individuals who also have congenital heart disease should be imaged by **Adult Congenital Heart Disease (CD-11)** in the general Cardiac Imaging Guidelines.

The guidelines listed in this section for certain specific indications are not intended to be all-inclusive; clinical judgment remains paramount and variance from these guidelines may be appropriate and warranted for specific clinical situations.

Procedure Codes Associated with Cardiac or PVD Imaging

MRI/MRA	CPT®
Cardiac magnetic resonance imaging for morphology and function without contrast material	75557
Cardiac magnetic resonance imaging for morphology and function without contrast material; with stress imaging	75559
Cardiac magnetic resonance imaging for morphology and function without contrast material(s), followed by contrast material(s) and further sequences	75561
Cardiac magnetic resonance imaging for morphology and function without contrast material(s), followed by contrast material(s) and further sequences; with stress imaging	75563
Cardiac magnetic resonance imaging for velocity flow mapping (List separately in addition to code for primary procedure)	75565

CT	CPT®
Computed tomography, heart, without contrast material, with quantitative evaluation of coronary calcium	75571
Computed tomography, heart, with contrast material, for evaluation of cardiac structure and morphology (including 3D image postprocessing, assessment of cardiac function, and evaluation of venous structures, if performed)	75572
Computed tomography, heart, with contrast material, for evaluation of cardiac structure and morphology in the setting of congenital heart disease (including 3D image postprocessing, assessment of LV cardiac function, RV structure and function and evaluation of venous structures, if performed)	75573

CT	CPT®
Noninvasive estimated coronary fractional flow reserve (FFR) derived from coronary computed tomography angiography data using computation fluid dynamics physiologic simulation software analysis of functional data to assess the severity of coronary artery disease; data preparation and transmission, analysis of fluid dynamics and simulated maximal coronary hyperemia, generation of estimated FFR model, with anatomical data review in comparison with estimated FFR model to reconcile discordant data, interpretation and report	0501T
Noninvasive estimated coronary fractional flow reserve (FFR) derived from coronary computed tomography angiography data using computation fluid dynamics physiologic simulation software analysis of functional data to assess the severity of coronary artery disease; data preparation and transmission	0502T
Noninvasive estimated coronary fractional flow reserve (FFR) derived from coronary computed tomography angiography data using computation fluid dynamics physiologic simulation software analysis of functional data to assess the severity of coronary artery disease; analysis of fluid dynamics and simulated maximal coronary hyperemia, and generation of estimated FFR model	0503T
Noninvasive estimated coronary fractional flow reserve (FFR) derived from coronary computed tomography angiography data using computation fluid dynamics physiologic simulation software analysis of functional data to assess the severity of coronary artery disease; anatomical data review in comparison with estimated FFR model to reconcile discordant data, interpretation and report	0504T
CTA	CPT®
Computed tomographic angiography, heart, coronary arteries and bypass grafts (when present), with contrast material, including 3D image postprocessing (including evaluation of cardiac structure and morphology, assessment of cardiac function, and evaluation of venous structures, if performed)	75574
Computed tomographic angiography, abdominal aorta and bilateral iliofemoral lower extremity runoff, with contrast material(s), including noncontrast images, if performed, and image postprocessing	75635
Nuclear Medicine	CPT®
Determination of central c-v hemodynamics (non-imaging) (eg, ejection fraction with probe technique) with or without pharmacologic intervention or exercise, single or multiple determinations	78414
Cardiac shunt detection	78428

Nuclear Medicine	CPT [®]
Myocardial imaging, positron emission tomography (PET), metabolic evaluation study (including ventricular wall motion[s] and/or ejection fraction[s], when performed), single study; with concurrently acquired computed tomography transmission scan	78429
Myocardial imaging, positron emission tomography (PET), perfusion study (including ventricular wall motion[s] and/or ejection fraction[s], when performed); single study, at rest or stress (exercise or pharmacologic), with concurrently acquired computed tomography transmission scan	78430
Myocardial imaging, positron emission tomography (PET), perfusion study (including ventricular wall motion[s] and/or ejection fraction[s], when performed); multiple studies at rest and stress (exercise or pharmacologic), with concurrently acquired computed tomography transmission scan	78431
Myocardial imaging, positron emission tomography (PET), combined perfusion with metabolic evaluation study (including ventricular wall motion[s] and/or ejection fraction[s], when performed), dual radiotracer (eg, myocardial viability);	78432
Myocardial imaging, positron emission tomography (PET), combined perfusion with metabolic evaluation study (including ventricular wall motion[s] and/or ejection fraction[s], when performed), dual radiotracer (eg, myocardial viability); with concurrently acquired computed tomography transmission scan	78433
Absolute quantitation of myocardial blood flow (AQMBF), positron emission tomography (PET), rest and pharmacologic stress (List separately in addition to code for primary procedure)	78434
Myocardial perfusion imaging, tomographic (SPECT) (including attenuation correction, qualitative or quantitative wall motion, ejection fraction by first pass or gated technique, additional quantification, when performed); single study, at rest or stress (exercise or pharmacologic)	78451
Myocardial perfusion imaging, tomographic (SPECT) (including attenuation correction, qualitative or quantitative wall motion, ejection fraction by first pass or gated technique, additional quantification, when performed); multiple studies, at rest and/or stress (exercise or pharmacologic) and/or redistribution and/or rest reinjection	78452
Myocardial perfusion imaging, planar (including qualitative or quantitative wall motion, ejection fraction by first pass or gated technique, additional quantification, when performed); single study, at rest or stress (exercise or pharmacologic)	78453
Myocardial perfusion imaging, planar (including qualitative or quantitative wall motion, ejection fraction by first pass or gated technique, additional quantification, when performed); multiple studies, at rest and/or stress (exercise or pharmacologic) and/or redistribution and/or rest reinjection	78454

Nuclear Medicine	CPT®
Myocardial imaging, positron emission tomography (PET), metabolic evaluation study (including ventricular wall motion and/or ejection fraction, when performed), single study	78459
Myocardial imaging, infarct avid, planar; qualitative or quantitative	78466
Myocardial imaging, infarct avid, planar; with ejection fraction by first pass technique	78468
Myocardial imaging, infarct avid, planar; tomographic SPECT with or without quantification	78469
Cardiac blood pool imaging, gated equilibrium; planar, single study at rest or stress (exercise and/or pharmacologic), wall motion study plus ejection fraction, with or without additional quantitative processing	78472
Cardiac blood pool imaging, gated equilibrium; multiple studies, wall motion study plus ejection fraction, at rest and stress (exercise and/or pharmacologic), with or without additional quantification	78473
Cardiac blood pool imaging (planar), first pass technique; single study, at rest or with stress (exercise and/or pharmacologic), wall motion study plus ejection fraction, with or without quantification	78481
Cardiac blood pool imaging (planar), first pass technique; multiple studies, at rest and with stress (exercise and/or pharmacologic), wall motion study plus ejection fraction, with or without quantification	78483
Myocardial imaging, positron emission tomography (PET), perfusion (including ventricular wall motion and/or ejection fraction, when performed); single study at rest or stress (exercise or pharmacologic)	78491
Myocardial imaging, positron emission tomography (PET), perfusion (including ventricular wall motion and/or ejection fraction, when performed); multiple studies at rest and/or stress (exercise or pharmacologic)	78492
Cardiac blood pool imaging, gated equilibrium, SPECT, at rest, wall motion study plus ejection fraction, with or without quantitative processing	78494
Cardiac blood pool imaging, gated equilibrium, single study, at rest, with right ventricular ejection fraction by first pass technique (List separately in addition to code for primary procedure)	78496
Quantitative differential pulmonary perfusion, including imaging when performed	78597
Quantitative differential pulmonary perfusion and ventilation (eg, aerosol or gas), including imaging when performed	78598
Radiopharmaceutical localization of tumor, inflammatory process or distribution of radiopharmaceutical agent(s) (includes vascular flow and blood pool imaging, when performed); planar, single area (eg, head, neck, chest, pelvis), single day imaging	78800

Nuclear Medicine	CPT®
Radiopharmaceutical localization of tumor, inflammatory process or distribution of radiopharmaceutical agent(s) (includes vascular flow and blood pool imaging, when performed); planar, 2 or more areas (eg, abdomen and pelvis, head and chest), 1 or more days imaging or single area imaging over 2 or more days	78801
Radiopharmaceutical localization of tumor, inflammatory process or distribution of radiopharmaceutical agent(s) (includes vascular flow and blood pool imaging, when performed); planar, whole body, single day imaging	78802
Radiopharmaceutical localization of tumor, inflammatory process or distribution of radiopharmaceutical agent(s) (includes vascular flow and blood pool imaging, when performed); tomographic (SPECT), single area (eg, head, neck, chest, pelvis), single day imaging	78803
Radiopharmaceutical localization of tumor, inflammatory process or distribution of radiopharmaceutical agent(s) (includes vascular flow and blood pool imaging, when performed); planar, whole body, requiring 2 or more days imaging	78804
Radiopharmaceutical localization of tumor, inflammatory process or distribution of radiopharmaceutical agent(s) (includes vascular flow and blood pool imaging, when performed); tomographic (SPECT) with concurrently acquired computed tomography (CT) transmission scan for anatomical review, localization and determination/detection of pathology, single area (eg, head, neck, chest, pelvis), single day imaging	78830
Myocardial sympathetic innervation imaging, planar qualitative and quantitative assessment	0331T
Myocardial sympathetic innervation imaging, planar qualitative and quantitative assessment; with tomographic SPECT	0332T

Ultrasound	CPT®
Transthoracic echocardiography for congenital cardiac anomalies; complete	93303
Transthoracic echocardiography for congenital cardiac anomalies; follow-up or limited study	93304
Echocardiography, transthoracic, real-time with image documentation (2D), includes M-mode recording, when performed, complete, with spectral Doppler echocardiography, and with color flow Doppler echocardiography	93306
Echocardiography, transthoracic, real-time with image documentation (2D), includes M-mode recording, when performed, complete, without spectral or color Doppler echocardiography	93307
Echocardiography, transthoracic, real-time with image documentation (2D), includes M-mode recording, when performed, follow-up or limited study	93308

Ultrasound	CPT®
Echocardiography, transesophageal, real-time with image documentation (2D) (with or without M-mode recording); including probe placement, image acquisition, interpretation and report	93312
Echocardiography, transesophageal, real-time with image documentation (2D) (with or without M-mode recording); placement of transesophageal probe only	93313
Echocardiography, transesophageal, real-time with image documentation (2D) (with or without M-mode recording); image acquisition, interpretation and report only	93314
Transesophageal echocardiography for congenital cardiac anomalies; including probe placement, image acquisition, interpretation and report	93315
Transesophageal echocardiography (TEE) for congenital cardiac anomalies; placement of transesophageal probe only	93316
Transesophageal echocardiography for congenital cardiac anomalies; placement of transesophageal probe only	93317
3D echocardiographic imaging and postprocessing during transesophageal echocardiography, or during transthoracic echocardiography for congenital cardiac anomalies, for the assessment of cardiac structure(s) (eg, cardiac chambers and valves, left atrial appendage, interatrial septum, interventricular septum) and function, when performed (List separately in addition to code for echocardiographic imaging) Code with (93303-93304, 93312, 93314, 93315, 93317, 93350-93351)	+93319
Doppler echocardiography, pulsed wave and/or continuous wave with spectral display (List separately in addition to codes for echocardiographic imaging); complete	+93320
Doppler echocardiography, pulsed wave and/or continuous wave with spectral display (List separately in addition to codes for echocardiographic imaging); follow-up or limited study (List separately in addition to codes for echocardiographic imaging)	+93321
Doppler echocardiography color flow velocity mapping (List separately in addition to codes for echocardiography)	+93325
Echocardiography, transthoracic, real-time with image documentation (2D), includes M-mode recording, when performed, during rest and cardiovascular stress test using treadmill, bicycle exercise and/or pharmacologically induced stress, with interpretation and report;	93350

Ultrasound	CPT®
Echocardiography, transthoracic, real-time with image documentation (2D), includes M-mode recording, when performed, during rest and cardiovascular stress test using treadmill, bicycle exercise and/or pharmacologically induced stress, with interpretation and report; including performance of continuous electrocardiographic monitoring, with supervision by a physician or other qualified health care professional	93351
Use of echocardiographic contrast agent during stress echocardiography (List separately in addition to code for primary procedure)	+93352
Myocardial strain imaging using speckle tracking-derived assessment of myocardial mechanics (List separately in addition to codes for echocardiography imaging)	+93356
Transthoracic echocardiography with contrast, or without contrast followed by with contrast, for congenital cardiac anomalies; complete	C8921
Transthoracic echocardiography with contrast, or without contrast followed by with contrast, for congenital cardiac anomalies; follow-up or limited study	C8922
Transthoracic echocardiography with contrast, or without contrast followed by with contrast, real-time with image documentation (2D), includes M-mode recording, when performed, complete, without spectral or color doppler echocardiography	C8923
Transthoracic echocardiography with contrast, or without contrast followed by with contrast, real-time with image documentation (2D), includes M-mode recording when performed, follow-up or limited study	C8924
Transesophageal echocardiography (TEE) with contrast, or without contrast followed by with contrast, real time with image documentation (2D) (with or without M-mode recording); including probe placement, image acquisition, interpretation and report	C8925
Transesophageal echocardiography (TEE) with contrast, or without contrast followed by with contrast, for congenital cardiac anomalies; including probe placement, image acquisition, interpretation and report	C8926
Transthoracic echocardiography with contrast, or without contrast followed by with contrast, real-time with image documentation (2D), includes M-mode recording, when performed, during rest and cardiovascular stress test using treadmill, bicycle exercise and/or pharmacologically induced stress, with interpretation and report	C8928
Transthoracic echocardiography with contrast, or without contrast followed by with contrast, real-time with image documentation (2D), includes M-mode recording, when performed, complete, with spectral doppler echocardiography, and with color flow doppler echocardiography	C8929

Ultrasound	CPT®
Transthoracic echocardiography, with contrast, or without contrast followed by with contrast, real-time with image documentation (2D), includes M-mode recording, when performed, during rest and cardiovascular stress test using treadmill, bicycle exercise and/or pharmacologically induced stress, with interpretation and report; including performance of continuous electrocardiographic monitoring, with physician supervision	C8930
Myocardial contrast perfusion echocardiography, at rest or with stress, for assessment of myocardial ischemia or viability (List separately in addition to code for primary procedure)	+0439T

Cardiac Cath Procedure	CPT®
Congenital Heart Disease Code "Set"	93593-93597
Right heart catheterization for congenital heart defect(s) including imaging guidance by the proceduralist to advance the catheter to the target zone; normal native connections	93593
Right heart catheterization for congenital heart defect(s) including imaging guidance by the proceduralist to advance the catheter to the target zone; abnormal native connections	93594
Left heart catheterization for congenital heart defect(s) including imaging guidance by the proceduralist to advance the catheter to the target zone, normal or abnormal native connections	93595
Right and left heart catheterization for congenital heart defect(s) including imaging guidance by the proceduralist to advance the catheter to the target zone(s); normal native connections	93596
Right and left heart catheterization for congenital heart defect(s) including imaging guidance by the proceduralist to advance the catheter to the target zone(s); abnormal native connections	93597
Anomalous coronary arteries, patent foramen ovale, mitral valve prolapse, and bicuspid aortic valve	93451-93464, 93566-93568
RHC without LHC or coronaries	93451
LHC without RHC or coronaries	93452
RHC and retrograde LHC without coronaries	93453
Native coronary artery catheterization;	93454
with bypass grafts	93455

Cardiac Cath Procedure	CPT®
with RHC	93456
with RHC and bypass grafts	93457
with LHC	93458
with LHC and bypass grafts	93459
with RHC and LHC	93460
with RHC and LHC and bypass grafts	93461
LHC by trans-septal or apical puncture	+93462
Angiography of non-coronary arteries and veins performed as a distinct service	Select appropriate codes from the Radiology and Vascular Injection Procedures sections.

References

1. Karmazyn BK, John SD, Siegel MJ, et al. ACR–ASER–SCBT–MR–SPR Practice parameter for the performance of pediatric computed tomography (CT). *Am Coll Radiology (ACR)*. Revised 2014 (Resolution 3). <https://www.acr.org/-/media/ACR/Files/Practice-Parameters/ct-ped.pdf?la=en>.
2. Bridges MD, Berland LL, Kirby AB, et al. ACR Practice Parameter for performing and interpreting magnetic resonance imaging (MRI). *Am Coll Radiology (ACR)*. Revised 2017 (Resolution 10). <https://www.acr.org/-/media/ACR/Files/Practice-Parameters/mr-perf-interpret.pdf?la=en>.
3. Sorantin E and Heinzl B. What every radiologist should know about paediatric echocardiography. *Eur J Radiol*. 2014 Sep;83(9):1519-1528.
4. Ing C, DiMaggio C, Whitehouse A, et al. Long-term differences in language and cognitive function after childhood exposure to anesthesia. *Pediatrics*. 2012 Aug;130(3):e476-e485.
5. Monteleone M, Khandji A, Cappell J, et al. Anesthesia in children: perspectives from nonsurgical pediatric specialists. *J Neurosurg Anesthesiol*, 2014 Oct 01;26(4):396-398.
6. DiMaggio C, Sun LS, and Li G. Early childhood exposure to anesthesia and risk of developmental and behavioral disorders in a sibling birth cohort. *Anesth Analg*, 2011 Nov;113(5):1143-1151.
7. Moss AJ, Adams FH, Allen HD, et al. Moss and Adams' Heart Disease in Infants, Children, and Adolescents: Including the Fetus and Young Adult. Philadelphia: Wolters Kluwer; 2016
8. Lai WW, Geva T, Shirali GS, et al. Guidelines and Standards for Performance of a Pediatric Echocardiogram: A Report from the Task Force of the Pediatric Council of the American Society of Echocardiography. *J Am Soc Echocardiogr*. 2006;19(12):1413-1430. doi:10.1016/j.echo.2006.09.001.
9. Doherty JU, Kort S, Mehran R, Schoenhagen P, et al. ACC/AATS/AHA/AYSE/ASNC/HRS/SCAI/SCCT/SCMR/STS 2017 Appropriate Use Criteria for Multimodality Imaging in Valvular Heart Disease. *J Nuc Cardiol*. 2017;24(6):2043-2063.
10. Chowdhury D, Gurvitz M, Anderson J, et al. Development of Quality Metrics in Ambulatory Pediatric Cardiology. *JACC: J Am Coll Cardiol*. 2017 Feb, 69 (5) 541-555. doi: 10.1016/j.jacc.2016.11.043.
11. Valente AM, Cook S, Festa P, et al. Multimodality Imaging Guidelines for Patients with Repaired Tetralogy of Fallot: A Report from the American Society of Echocardiography. *J Am Soc Echocardiogr*. 2014;27(2):111-141. doi:10.1016/j.echo.2013.11.009.
12. Simpson J, Lopez L, Acar P, et al. Three-dimensional Echocardiography in Congenital Heart Disease: An Expert Consensus Document from the European Association of Cardiovascular Imaging and the American Society of Echocardiography. *J Am Soc Echocardiogr*. 2017;30(1):1-27. doi:10.1016/j.echo.2016.08.022.
13. Cohen MS, Eidem BW, Cetta F, et al. Multimodality Imaging Guidelines of Patients with Transposition of the Great Arteries: A Report from the American Society of Echocardiography Developed in Collaboration with the Society for Cardiovascular Magnetic Resonance and the Society of Cardiovascular Computed Tomography. *J Am Soc Echocardiogr*. 2016;29(7):571-621. doi:10.1016/j.echo.2016.04.002.
14. Silvestry FE, Cohen MS, Armsby LB, et al. Guidelines for the Echocardiographic Assessment of Atrial Septal Defect and Patent Foramen Ovale: From the American Society of Echocardiography and Society for Cardiac Angiography and Interventions. *J Am Soc Echocardiogr*. 2015;28(8):910-958. doi:10.1016/j.echo.2015.05.015.

15. Paridon SM. Clinical Stress Testing in the Pediatric Age Group: A Statement from the American Heart Association Council on Cardiovascular Disease in the Young, Committee on Atherosclerosis, Hypertension, and Obesity in Youth. *Circulation*. 2006;113(15):1905-1920. doi:10.1161/CIRCULATIONAHA.106.17437D.
16. Gidding SS, Champagne MA, Ferranti SDD, et al. The Agenda for Familial Hypercholesterolemia. *Circulation*. 2015;132(22):2167-2192. doi:10.1161/CIR.0000000000000297.
17. National Cancer Institute. Radiation Risks and Pediatric Computed Tomography. National Cancer Institute. <http://www.cancer.gov/about-cancer/causes-prevention/risk/radiation/pediatric-ct-scans>. Published September 4, 2018.
18. Hundley WG, Bluemke DA, Finn JP, et al. ACCF/ACR/AHA/NASCI/SCMR 2010 Expert Consensus Document on Cardiovascular Magnetic Resonance. *Circulation*. 2010;121(22):2462-2508. doi:10.1161/cir.0b013e3181d44a8f.

Congenital Heart Disease

Guideline

- Congenital Heart Disease General Information (PEDCD-2.1)
- Congenital Heart Disease Coding (PEDCD-2.2)
- Congenital Heart Disease Modality Considerations (PEDCD-2.3)
- Imaging and Surveillance per Congenital lesion (PEDCD-2.4)
 - Atrial Defects-Secundum ASD, PFO, and Partial anomalous pulmonary venous return (PAPVR), Sinus Venosus defect (PEDCD-2.4.1)
 - VSD (PEDCD-2.4.2)
 - AVSD (Atrioventricular canal, endocardial cushion defect) (PEDCD-2.4.3)
 - PDA (Patent ductus arteriosus) (PEDCD-2.4.4)
 - TAPVR Total anomalous pulmonary venous return (PEDCD-2.4.5)
 - Ebstein anomaly and TV dysplasia (PEDCD-2.4.6)
 - Pulmonary Stenosis (PS) (PEDCD-2.4.7)
 - Pulmonary Atresia with intact septum (PAIVS) (PEDCD-2.4.8)
 - Mitral valve disease (PEDCD-2.4.9)
 - LVOT lesions (PEDCD-2.4.10)
 - Aortic Coarctation and IAA (interrupted aortic arch) (PEDCD-2.4.11)
 - Coronary Anomalies (PEDCD-2.4.12)
 - Tetralogy of Fallot (TOF) (PEDCD-2.4.13)
 - Double Outlet Right Ventricle (DORV) (PEDCD-2.4.14)
 - D-Loop Transposition of the Great Arteries (D-Loop TGA) (PEDCD-2.4.15)
 - Congenitally Corrected Transposition of the Great Arteries (ccTGA, LTGA) (PEDCD-2.4.16)
 - Truncus Arteriosus (PEDCD-2.4.17)
 - Single Ventricle (SV) (PEDCD-2.4.18)
 - Eisenmenger and PHT (with CHD)- (PEDCD-2.4.19)
- References (PEDCD-2)

Congenital Heart Disease General Information (PEDCD-2.1)

CDP.CHD.0002.1.A

v1.0.2024

- Congenital heart disease accounts for the majority of cardiac problems occurring in the pediatric population. Individuals may be diagnosed any time spanning prenatal evaluation to adolescence. For individuals over 18 years of age, see **Adult Congenital Heart Disease (CD-11)** in the Cardiac Imaging Guidelines.
- There are a number of variables that influence the modality and timing of imaging individuals with congenital heart disease, which results in a high degree of individuality in determining the schedule for imaging these individuals, including:
 - Gestational age
 - Individual's age
 - Physiologic effects of the defect
 - Status of interventions (catheterization and surgical)
 - Rate of individual's growth
 - Stability of the defect on serial imaging
 - Comorbid conditions
 - Activity level
- Age definitions for pediatric individuals (for purpose of these guidelines)
 - Infant 0-12 months
 - Subcategory of infant: Neonate or newborn 0-28 days
 - Child 1-18 years
 - Subcategory of child: Adolescent 11-18 years
 - "Children" refers to all pediatric individuals ages 0-18 years
- Newborns (neonates) have special considerations as they have potentially rapidly changing physiology
 - Newborns with any concerns for ductal dependent lesion can have echocardiograms at any frequency
 - Newborns have changes in pulmonary vascular resistance that can affect clinical status rapidly, and may require more frequent imaging.
 - Neonatal physiology can extend to the first couple of months of life.
 - Newborns can have one repeat echo, if prior echocardiogram is abnormal or equivocal (either in the hospital or as newborn outpatient)
- Individuals can have an echocardiogram at that time for **Change in clinical status and/or new concerning signs or symptoms**. This can include:
 - Shortness of breath
 - Fatigue
 - Chest discomfort

- Percentile weight loss
- Weight gain
- Poor feeding
- Tachypnea
- Tachycardia
- CHF signs on exam
- Change in EKG, Pulse ox, laboratory values
- An additional study can be approved prior to the next routine interval, to assess for more rapid change, if the change in clinical status involves the echocardiogram itself, such as:
 - Increasing stenosis gradient
 - Increasing regurgitation amount
 - Increasing pulmonary vascular resistance
 - Decreased ventricular function
 - Change in ductal status
- In individuals that can have both Cardiac MR or Cardiac CT and/or MRA Chest or CTA Chest, this is abbreviated as CMR/CT-MRA/CCTA
- Individuals with medication adjustments may require additional imaging at that time.
 - Pediatric dosing tends to be mg/kg or mcg/kg. Adjusting the dose to the same mg/kg would not be considering a dosing change for imaging.
 - Because dose adjustments are done by weight, and infants are growing rapidly, they can have changing physiology, pulmonary vascular resistance, ductal size and weight changes, dose response and may require more than one echo during a medication adjustment.
- Heart surgery
 - TTE is indicated one month prior to heart surgery. Depending on lesion, MR/CT Cardiac and/or Chest may also be included.
 - Can have an echocardiogram within one month post-operative
 - Cardiac MRI/CCT if prior echo is equivocal
- MRA/CTA Chest can be performed if prior echo is equivocal and there are issues regarding aortic arch or pulmonary arteries or veins
- In individuals who have a documented equivocal echocardiogram due to a technical factor (i.e., poor acoustic windows due to body habitus) which will likely be present on subsequent echocardiograms, a Cardiac MR/CT, or MRA/CTA Chest, may be done with the frequency of echoes, if done instead of an echo.
- MRA/CTA Chest if thoracic issue not seen on echo
- For routine non-invasive imaging for a specific lesion see **Imaging and Surveillance per Congenital lesion (PEDCD-2.4)**
- For catheterizations see section **Cardiac Catheterization (PEDCD-11)**
- **Individuals with Pulmonary hypertension with CHD** should be reviewed for both their lesion and for PHT in section **Pediatric Pulmonary Hypertension (PEDCD-7)**

Congenital Heart Disease Coding (PEDCD-2.2)

CDP.CHD.0002.2.A
v1.0.2024

Congenital Heart Disease Echocardiography Coding (PEDCD-2.2.1)

- **Any** of the following echocardiography code combinations are appropriate for re-evaluation of individuals with known congenital heart disease:
 - CPT® 93303, CPT® 93320, and CPT® 93325
 - CPT® 93304, CPT® 93321, and CPT® 93325
 - CPT® 93303
 - CPT® 93304
- CPT® 93306 is not indicated in the evaluation of known congenital heart disease.

Congenital Heart Disease imaging per modality (PEDCD-2.2.2)

Echocardiogram

- Transthoracic echocardiogram (TTE)
 - TTE for congenital cardiac anomalies; complete (CPT® 93303)
 - TTE for congenital cardiac anomalies; limited study (CPT® 93304)
 - TTE (2D) m-mode recording, complete, with spectral and color flow doppler echocardiography (CPT® 93306)
 - TTE (2D) with or without m-mode recording; complete (CPT® 93307)
 - TTE (2D) with or without m-mode recording; limited study (CPT® 93308)
- Transesophageal echocardiogram (TEE)
 - TEE (2D) including probe placement, imaging, interpretation, and report (CPT® 93312)
 - TEE for congenital cardiac anomalies; including probe placement, imaging, interpretation, and report (CPT® 93315)

MRI

- Cardiac (CMR)
 - Cardiac MRI for morphology and function without contrast (CPT® 75557)
 - Cardiac MRI for morphology and function without and with contrast (CPT® 75561)
 - Cardiac magnetic resonance imaging for velocity flow mapping (List separately in addition to code for primary procedure) (CPT® 75565)
- MRI Chest
 - MRI Chest without contrast (CPT® 71550)

- MRI Chest with contrast (CPT® 71551)
- MRI Chest with & without contrast (CPT® 71552)
- MRI Angiography (MRA)
 - MRA Chest (excluding myocardium) with or without contrast (CPT® 71555)

CT

- Cardiac (CCT)
 - CT, Heart, with contrast material, for evaluation of cardiac structure and morphology (CPT® 75572)
 - CT, Heart, with contrast material, for evaluation of cardiac structure and morphology in the setting of congenital heart disease (CPT® 75573)
- CT Angiography-Cardiac (CCTA)
 - CTA Heart, coronary arteries and bypass grafts (when present), with contrast, including 3D image post processing (CPT® 75574)
- CT-Chest
 - CT Thorax without contrast (CPT® 71250)
 - CT Thorax with contrast (CPT® 71260)
 - CT Thorax without & with contrast (CPT® 71270)
- CT Angiography-Chest (CTA Chest)
 - CTA Chest without and with contrast (CPT® 71275)

Stress Imaging (echo, MRI, MPI)

- Stress echo
 - Echocardiography (TTE), (2D), with or without m-mode, during rest and cardiovascular stress, with interpretation and report (CPT® 93350)
 - Echocardiography (TTE), (2D), m-mode, during rest and cardiovascular stress test using treadmill, bicycle exercise and/or pharmacologically induced stress, with interpretation (CPT® 93351)
- Stress MRI
 - Cardiac MRI for morphology and function without contrast, with stress imaging (CPT® 75559)
 - Cardiac MRI for morphology and function without and with contrast, with stress imaging (CPT® 75563)
- Myocardial perfusion imaging (MPI)
 - MPI, tomographic (SPECT) including attenuation correction, qualitative or quantitative wall motion, ejection fraction by first pass or gated technique, additional quantification, when performed); single study, at rest or stress (exercise or pharmacologic) (CPT® 78451)
 - MPI, tomographic (SPECT) (including attenuation correction, qualitative or quantitative wall motion, ejection fraction by first pass or gated technique, additional quantification, when performed); multiple studies, at rest and/or stress

(exercise or pharmacologic) and/or redistribution and/or rest reinjection (CPT® 78452)

Pulmonary perfusion imaging

- Pulmonary perfusion imaging (e.g., particulate) (CPT® 78580)
- Pulmonary ventilation (e.g., aerosol or gas) and perfusion imaging (CPT® 78582)
- Quantitative differential pulmonary perfusion, including imaging when performed (CPT® 78597)
- Quantitative differential pulmonary perfusion and ventilation (e.g., aerosol or gas), including imaging when performed (CPT® 78598)

Congenital Heart Disease Modality Considerations (PEDCD-2.3)

CDP.CHD.0002.3.A

v1.0.2024

- Echocardiography is the primary imaging modality used for diagnosing and monitoring congenital heart disease and is generally required before other imaging modalities are indicated unless otherwise indicated in a specific guideline section.
- Cardiac MRI either without contrast (CPT® 75557) or without and with contrast (CPT® 75561) is indicated, when a recent echocardiogram is inconclusive, needs confirmation of findings, or does not completely define the disease (for subsequent follow-up studies, a recent echocardiogram is not a requirement):
 - CPT® 75565 is also indicated for individuals with valvular disease or a need to evaluate intracardiac blood flow. These individuals will usually have CPT® 93320 and CPT® 93325 performed with their echocardiography studies.
 - MRA Chest (CPT® 71555) may be added if the aorta or pulmonary artery needs to be visualized beyond the root, or if aortopulmonary collaterals, pulmonary veins, or systemic veins need to be visualized.
 - MRA Chest alone (CPT® 71555) should be performed if the individual cannot cooperate with full cardiac MRI exam.
- MRA Chest (CPT® 71555) is indicated for assessment of the great arteries, pulmonary veins, and systemic chest veins with inconclusive recent echocardiography findings, including the following:
 - Coarctation of the aorta
 - Tetralogy of Fallot
 - Anomalous pulmonary veins
 - Transposition of the great arteries
 - Truncus arteriosus
 - Vascular rings and other lesions of the great arteries, with inconclusive recent echocardiography findings
- CT imaging is indicated when recent echocardiogram is inconclusive:
 - Report CPT® 75574 for evaluating coronary artery anomalies
 - Report CPT® 75573 for congenital heart disease
 - CPT® 71275 Determination of vascular extra-cardiac anatomy in individuals with complex congenital heart disease
 - Pulmonary artery (PA) and Pulmonary vein (PV) assessment
- CTA Chest (CPT® 71275) is indicated with inconclusive recent echocardiography findings to assess:
 - Coarctation of the aorta
 - Tetralogy of Fallot
 - Anomalous pulmonary veins and other lesions of the great arteries

- Vascular rings
- Pulmonary perfusion imaging
 - Pulmonary perfusion imaging (e.g., particulate) (CPT® 78580)(CPT® 78582) (CPT® 78597)(CPT® 78598)
 - In individuals with congenital heart disease or suspected congenital heart diseases, who have clinical questions regarding relative pulmonary blood flow, can have perfusion imaging

Imaging and Surveillance per Congenital lesion (PEDCD-2.4)

CDP.CHD.0002.4.A

v1.0.2024

- Echocardiography is often repeated frequently throughout a pediatric individual's life, and can generally be approved regardless of symptoms based on the lesion and age of the individual. These are listed in sections in sections below.
 - Modifiers following guidelines.
 - Some congenital conditions may require more frequent testing, especially with more complex heart disease, congestive heart failure, obstructive heart lesions, ductal dependent lesions, changes in clinical status, repeat interventions, and/or in neonates
 - Any individual being treated for heart failure, with consideration for changing medical regimen can have an echocardiogram
- Echocardiography is performed during the physician office visit, and these studies should not be denied because of lack of contact within 60 days.
- Adults 18 years and older who also have congenital heart disease should be imaged according to **Adult Congenital Heart Disease (CD-11)** and the general Cardiac Imaging Guidelines.

Atrial Defects-Secundum ASD, PFO, and Partial anomalous pulmonary venous return (PAPVR), Sinus Venosus defect (PEDCD-2.4.1)

CDP.CHD.0241.A

v1.0.2024

See section on AVSD in **AVSD (Atrioventricular canal, Endocardial cushion defect) (PEDCD-2.4.3) for primum ASD**

PFO (Patent Foramen Ovale)

- Routine surveillance in an asymptomatic individual with PFO is not indicated
 - PFO is a normal variant
 - In infants, a PFO that is difficult to distinguish from an ASD can be imaged with the same guidelines as used in a small unrepaired ASD (with congenital echo).
 - Individuals with PFOs may have an additional indication for an echo and can be imaged according to the echocardiogram guidelines in **Repeat Transthoracic Echocardiography Indications (PEDCD-8.3)** and **Frequency of echocardiography testing (CD-2.3)** in the general Cardiac Imaging Guidelines.
- Follow-up imaging with an echocardiogram is indicated when there is documentation of the following:
 - New cardiac symptoms
 - A concern that the last echo was equivocal for other cardiac issues
 - Question of a clot/embolism that has gone across the PFO
 - Prior echo did not differentiate the PFO from a secundum ASD
- TTE (CPT® 93306- non congenital echocardiogram) is indicated when an individual with a prior history of PFO requires an echocardiogram for any new reason
- Preoperative for PFO closure
 - TTE or TEE
 - Closure is rare in children but may be indicated in individuals with transient ischemic attacks or strokes with suspected atrial level shunt
 - CMR/CT-CMRA/CTA if unclear findings from echocardiogram.
- Intra-procedural PFO
 - Intra-procedural TEE (CPT® 93355) is not in scope for this program
- Post procedure PFO closure
 - Post-surgical imaging as follows (PFO generally requires less frequent monitoring post device than ASDs):
 - TTE one time within 30 days of closure

- TTE one time within 6 months of PFO closure
- TTE or TEE is indicated at any time post procedure when there is concern for **any** of the following:
 - Infection
 - Malposition
 - Embolization
 - Persistent shunt
- If persistent shunt TTE is indicated every 3 months until the finding is stable or there is a need for intervention

ASD and PAPVR asymptomatic isolated atrial septal defect (ASD)

This section reference secundum ASD, sinus Venosus, ASD and unobstructed partial anomalous pulmonary venous return

- Any surgical status
 - TTE is indicated for any of the following:
 - Initial evaluation of a change in clinical status and/or new concerning signs or symptoms
 - Prior to planned cardiac intervention
 - Repeat any time prior to next allowed study if concern for elevated pulmonary vascular resistance/Pulmonary hypertension
 - CMR/CT-CMRA/CTA
 - If anomalous vein or SV defect cannot be assessed on echo
 - To assess shunt or RV for considering of surgery, or if echocardiogram equivocal
- Unrepaired
 - Newborn with isolated ASD can have one repeat TTE within 2 months
 - Small asymptomatic isolated ASD with no pulmonary hypertension can have TTE as follows:
 - Infant <6 months every three months
 - Infant ≥6 months, repeat at one year.
 - Child Every 3 years
 - Routine surveillance for ≥moderate ASD or PAPVR >1 vein
 - Infant every 3 months
 - Echo (TTE) every 1 year
- Prior to planned repair of ASD
 - TTE and/or TEE
 - MRI if any residual issues unanswered by echo
- Prior to planned SV defect or PAPVR
 - TTE and/or TEE

- CMR/CT-CMRA/CTA
- Post- ASD closure with device
 - TTE post device closure
 - 1 week
 - 1 month
 - Every 3 months
 - 1 year
 - Every 2 years
 - May repeat TTE every 3 months until the finding is stable or there is a need for intervention if there is significant residual shunt, valvular or ventricular dysfunction, arrhythmias, and/or pulmonary hypertension
- Post-surgical closure of ASD
 - TTE
 - Within the first month
 - Within the 1st year
 - Every 2 years after the first year study
 - May repeat TTE every 3 months until the finding is stable or there is a need for intervention if significant residual shunt, valvular or ventricular dysfunction, arrhythmias, and/or pulmonary hypertension.

VSD (PEDCD-2.4.2)

CDP.CHD.0242.A

v1.0.2024

All

TTE is indicated for any of the following:

- with change in clinical status and/or new concerning signs or symptoms
- Prior to planned cardiac intervention

Unrepaired

TTE

- Small muscular VSD, No Symptoms, No pulmonary hypertension
 - Newborn 1 repeat within 2 months
 - Infancy every 6 months
 - Childhood every 3 years
- Small VSD in location other than muscular
 - Newborn 1 repeat TTE within 2 months
 - Infant TTE every 6 months
 - Child TTE every year.
- Moderate or large VSD on medical management
 - Newborn TTE every 2 weeks
 - infant every 1 month
 - Child <2 years old TTE every 3 months
 - Child >2 years old TTE every year.

Post Repair VSD

TTE

- One study within one month of surgery
- One study within one year of surgery,
- After first year of surgery, every 2 years
- Following surgical or device closure in an individual with significant residual shunt, valvular or ventricular dysfunction, arrhythmias, and/or pulmonary hypertension.
 - Child –TTE every 3 months
 - Adolescent- TTE every 6 months

AVSD (Atrioventricular canal, endocardial cushion defect) (PEDCD-2.4.3)

CDP.CHD.0243.A

v1.0.2024

Any surgical status

TTE is indicated for any of the following:

- Change in clinical status and/or new concerning signs or symptoms
- Prior to planned cardiac intervention

Unrepaired

- Partial/transitional Atrioventricular canal (AVC)
 - Newborn one addition study next 2 months.
 - TTE
 - Infancy every 3 months in infancy
 - Child <2 years every 6 months
 - Child ≥2 years, 1 year
- Complete AVC
 - TTE
 - Newborn, TTE repeat within first month
 - Infant <6 weeks, TTE every 2 weeks.
 - Infant ≥6 weeks, TTE monthly

Repaired (TTE)

- Within one month of surgery
- Within 1 year
- Then annually
- May repeat TTE every 3 months until the finding is stable or there is a need for intervention if residual shunt, valvular LV dysfunction, LVOT obstruction, arrhythmia, arrhythmia or PHT, symptoms of heart failure

PDA (Patent ductus arteriosus) (PEDCD-2.4.4)

CDP.CHD.0244.A

v1.0.2024

Any surgical status

TTE is indicated for any of the following:

- Initial evaluation of a change in clinical status and/or new concerning signs or symptoms
- Prior to planned cardiac intervention

Unrepaired

- Newborn, one repeat TTE in newborn period
 - None, if spontaneously closed
- >1-year-old
 - No Routine surveillance in an asymptomatic individual with a trivial, silent PDA
- Infant
 - Small PDA: TTE every 3 months
 - \geq Moderate PDA: TTE every month
- Child
 - Small PDA: every 1 year
 - Moderate PDA: every 6 months
- Adolescent every 3 years

Post PDA device

- Post procedure surveillance (TTE)
 - One echo in first 30 days
 - Annually for first 2 years
 - Every 5 years after first 2 years
- Post procedure LPA stenosis or aortic obstruction
 - Child
 - TTE annually
 - MRA/CTA Chest, or (lung perfusion for LPA stenosis) if questions remain unanswered after TTE
 - Adolescents
 - Every two years TTE and

- MRA/CTA Chest, or (lung perfusion for LPA stenosis) if questions remain unanswered after TTE

TAPVR Total anomalous pulmonary venous return (PEDCD-2.4.5)

CDP.CHD.0245.A

v1.0.2024

Any surgical status

- TTE, TEE, CMR/CT-CMRA/CTA, Lung perfusion scan are indicated for any of the following:
 - Change in clinical status and/or new concerning signs or symptoms
 - Prior to planned cardiac intervention

Unrepaired

- No restrictions

Repaired

- TTE one Post procedure evaluation first 30 days
- TTE every 3 months in infancy
- Child: every 1 year
- Adolescence: TTE every 2 years

Ebstein anomaly and TV dysplasia (PEDCD-2.4.6)

CDP.CHD.0246.A

v1.0.2024

Any surgical status

- TTE, TEE, CMR/CT-CMRA/CTA are indicated for any of the following:
 - Change in clinical status and/or new concerning signs or symptoms
 - Prior to planned repair or intervention

Unrepaired

- Newborn Repeat study within 30 days.
- Infant
 - Trivial TR is a normal finding
 - Mild TR- TTE every year
 - \geq Moderate TR- TTE every 3 months
- Child
 - Mild TR every year TTE
 - \geq Moderate every 6 months

Repaired (TTE)

- Post-op within 30 days
- TTE once a year
- TTE every 6 months if valvular or ventricular dysfunction, or arrhythmias
- Child: every year
- Adolescent: every 2 years
- Every 3 months if CHF or atrial arrhythmias

Pulmonary Stenosis (PS) (PEDCD-2.4.7)

CDP.CHD.0247.A
v1.0.2024

Any surgical status

- TTE is indicated for any of the following:
 - Change in clinical status and/or new concerning signs or symptoms
 - Prior to planned cardiac procedure
 - If increasing gradient, 1 additional study prior to next allowed study
 - PS in Williams syndrome: See **LVOT lesions (PEDCD-2.4.10)**

Unrepaired

- Neonate
 - TTE repeat study within 30 days
- Infant PS asymptotic (any severity)
 - TTE every 3 months
- Child
 - TTE every 1 year
- Adolescent
 - TTE every 2 years
 - MRA/CTA Chest if pulmonary artery dilation every 3 years

Post procedure (TTE)

- Within 30 days
- Infant
 - TTE every 3 months
- Child
 - TTE 1 year
 - Moderate or severe sequelae TTE every 6 months
- Adolescent
 - TTE every 2 years
- Any individual with heart failure, TTE every 3 months

Pulmonary Atresia with intact septum (PAIVS) (PEDCD-2.4.8)

CDP.CHD.0248.A

v1.0.2024

Any surgical status

TTE is indicated for any of the following:

- Prior to planned repair
- Change in clinical status and/or new concerning signs or symptoms

Post procedural: Palliation

- TTE
 - 1 within 30 days
 - Every 1 month until repaired

Post procedural: Complete Repair

- TTE within 30 days post-op
- Any age
 - TTE every three months for CHF
- Infant
 - TTE at 3 months in asymptomatic infant
- Child
 - TTE annually
 - Every 6 months if moderate sequelae
- Adolescent
 - CMR/CT and/or CMRA/CTA every 3 years

Mitral valve disease (PEDCD-2.4.9)

CDP.CHD.0249.A

v1.0.2024

Any surgical status

- TTE is indicated for any of the following:
 - Prior to planned surgery
 - Initial evaluation of change in clinical status and/or new concerning signs or symptoms

Unrepaired congenital mitral valve stenosis

- Infant in first three months of life
 - Weekly TTE
- After 3 months (TTE)
 - Every 3 months if mild MS
 - Every month if \geq moderate MS
- Child (TTE)
 - With moderate MS every 3 months until a decision is made to intervene
 - Child with mild symptoms annually

Unrepaired: Congenital Mitral Regurgitation (MR) including Mitral Valve Prolapse

- Infant
 - TTE every 6 months an asymptomatic infant with mild MR
 - TTE every month in asymptomatic infant with \geq moderate MR
- Child
 - TTE every 2 years with mild MR, normal LV size and systolic function
 - TTE every 6 months with \geq moderate MR
 - TTE every 3 years in an asymptomatic with MVP and mild MR

Post procedure, surgical or catheter based

- TTE within 30 days
- Infant
 - TTE every 3 months, mild MS or MR, and no LV dysfunction
 - TTE every month in \geq moderate MS or MR, dilated LV, and no LV dysfunction
- Child
 - TTE annually
 - In a child with normal prosthetic mitral valve function and no LV dysfunction

- In a child with mild MS or MR, and no LV dysfunction
- TTE every 3 months
 - In a child with \geq moderate MS or MR, dilated LV, and no LV dysfunction
 - In a child with prosthetic mitral valve or ventricular dysfunction, and/or arrhythmias

LVOT lesions (PEDCD-2.4.10)

CDP.CHD.2410.A

v1.0.2024

Subvalvular Aortic stenosis

Any surgical status

- TTE, TEE, Cardiac MR/CT are indicated for any of the following:
 - Initial evaluation of change in clinical status and/or new concerning signs or symptoms
 - Preoperative
- If aortic dimension z score >2
 - TTE or Chest CTA/MRA every 2 years if stable z score
 - TTE or Chest CTA/MRA every 6 months if increasing z score

Unrepaired

- Newborn- No restrictions
- Infant TTE
 - 1 monthly for any subvalvular AS, but \leq mild AR
- Child
 - TTE one per year if mild AS and no AR
 - TTE every 6 months \geq moderate subvalvular AS and/or mild AR
 - Routine surveillance (6–12 months) in an asymptomatic child with \geq moderate AS and/or \geq moderate AR

Repaired

- Infant
 - TTE within 30 days
 - TTE every 3 months \leq mild MS and or AR
 - TTE every 1 month \geq moderate AS or AR
- Child
 - TTE every 1 year \leq Mild AS or AR
 - TTE every 6 months \geq moderate AS or AR
 - TTE every 3 months if heart failure

Aortic Valve Stenosis and/or regurgitation/ BAV (Bicuspid Aortic Valve)

Any surgical status

- TTE, TEE, Cardiac MR/CT are indicated for any of the following:
 - Initial evaluation of change in clinical status and/or new concerning signs or symptoms
 - Preoperative

Unrepaired

- Infant <3 months
 - TTE 1 per week
- Infant >3 months
 - TTE every 3 months
 - TTE every 1 month, if \geq moderate AS or AR
- Child
 - TTE every 1 year with mild AS/AR and no aortic dilation
 - TTE every 6 months with moderate AS/AR, or aortic dilation.
 - TTE every 3 years if BAV with trivial or mild valvular dysfunction and no aortic root dilation
 - Every 6 months in any as with increasing z-score aortic root ascending aorta

Post procedural

- Within 30 days TTE
- Infant
 - Every 1 month following neonatal intervention with \geq moderate AS or AR or LV dysfunction
 - Every 3 months \leq mild AS/AR and no LV dysfunction
- Child (TTE)
 - 6 months echo if \geq moderate AS or AR
 - 1-year echo if \leq mild AS or AR, and/or normal prosthetic valve
 - Every 3 months if CHF or Ventricular dysfunction

Supravalvular AS

Any surgical status

- TTE, TEE, Cardiac MR/CT, Chest MRA/CTA are indicated for any of the following:
 - Initial evaluation of change in clinical status and/or new concerning signs or symptoms
 - Preoperative
 - Williams syndrome
 - Individuals with Williams syndrome can be screened/evaluated for arch abnormalities and pulmonary artery abnormalities and coronary artery abnormalities with the same intervals as TTE referenced below.
 - Stress imaging can be done at initial evaluation and for cardiac symptoms, change in clinical status and/or new concerning signs or symptoms

Unrepaired

- Infant
 - TTE every 3 months
- Child
 - TTE every 1 year
 - TTE every 6 months if moderate AS

Post-operative (TTE)

- Within 30 days
- Every 2 years in mild to moderate AS
- Every 6 months if \geq moderate AS

Aortic Coarctation and IAA (interrupted aortic arch) (PEDCD- 2.4.11)

CDP.CHD.2411.A

v1.0.2024

All individuals

- TTE, MRA/CTA Chest are indicated for any of the following:
 - Initial evaluation of change in clinical status and/or new concerning signs or symptoms
 - Prior to planned surgery/intervention
- Cardiac MR/CT is indicated for any of the following:
 - Initial evaluation of change in clinical status and/or new concerning signs or symptoms
 - Prior to planned surgery/intervention if any issues remain not answered on echo

Unrepaired Aortic Coarctation

- Newborn, TTE weekly if assessing for ductal closure
- Infant with mild coarctation in absence of PDA
 - Echo every 3 months
- Child with mild coarctation
 - Echo every 1 year
 - MRA Chest, CTA Chest every 3 years

Post procedure: surgical or catheter based

- TTE
 - Within 30 days of procedure
 - Every 3 months if mild or no sequelae in first year
 - Every 6 months if mild or no sequelae in the second year
 - Every 1 year after the second year
 - Every 3 months at any time if CHF symptoms or \geq moderate sequelae
 - MRA/CTA Chest every 3 years (include Cardiac MR/CT if issues not clarified on echo)

Coronary Anomalies (PEDCD-2.4.12)

CDP.CHD.2412.A

v1.0.2024

- CCTA or cardiac MRI is indicated for evaluating coronary artery anomalies and other complex congenital heart disease of cardiac chambers or great vessels
 - CPT® 75574 for evaluating coronary artery anomalies
 - CPT® 75573 for congenital heart disease
 - CTA Chest (CPT® 71275) can be added to evaluate great vessels
- Congenital anomalies of the coronary arteries are an important cause of sudden death in pediatric individuals. Coronary arteries may arise from the wrong coronary artery cusp leading to ischemic changes during exercise. These lesions may be found incidentally during a murmur evaluation. Anomalous coronary arteries may be seen on echocardiogram during an evaluation for chest pain or syncope or palpitations. In addition, individuals with no echocardiographic findings but symptoms concerning for angina chest pain may require stress testing.
 - Individuals who have positive echocardiographic findings, regardless of symptoms, and individuals who have classical typical angina chest pain regardless of echocardiographic findings, may require treadmill stress testing, stress imaging, of advanced imaging such as Cardiac MRI, Stress echocardiogram, PET, Cardiac CT, and/or cardiac catheterization.
- Congenital coronary anomalies include abnormal origin of a coronary artery from the PA, anomalous aortic origin of a coronary artery from a different aortic sinus of Valsalva (left coronary artery from the right sinus of Valsalva or right coronary artery from the left sinus of Valsalva), coronary arteriovenous fistula, and coronary artery ostial atresia, all in the setting of normal conotruncal anatomy.
 - Any surgical status
 - Prior to planned surgery, or change in clinical status and/or new concerning signs or symptoms
 - TTE
 - CMR or CCT
 - Can initially include MRA/CTA Chest.
 - If the origin of the coronaries arteries is below the sinus of Valsavla then a chest study is not needed on subsequent imaging.
 - If the origin of the coronary artery is not at the level of the sinus of Valsalva, a MRA/CTA Chest can be included when MR/CT imaging is required
 - Stress imaging- to assess the need for surgery
 - Unrepaired
 - Routine surveillance every 2 years in an asymptomatic individual with anomalous right coronary artery from the left aortic sinus
 - TTE
 - Stress imaging

- Although typically repaired, in the event that a repair is not completed, anomalous left coronary artery from the right coronary sinus can have imaging
 - TTE annually
 - Stress imaging annually
- Routine surveillance in an asymptomatic individual with small coronary fistula
 - TTE- every 2 years
- Routine surveillance in an asymptomatic individual with moderate or large coronary fistula
 - TTE annually
- Post-procedural: surgical or catheter
 - TTE
 - Within 30 days of procedure
 - Monthly the first year following repair
 - Every 3 months after first year of surgery
 - Annually after the second year of surgery
 - Every 3 months if ventricular dysfunction
 - Stress testing
 - EKG stress testing without imaging may be indicated in the first post year, and every 1-2 years depending on level of activity.
 - Stress testing with imaging
 - First postoperative year
 - If EKG stress test positive or equivocal
- Change in clinical status and/or new concerning signs or symptoms
- Individuals with congenital heart disease such as TOF, Truncus Arteriosus, and TGA have increased incidence of coronary artery anomalies
- Individuals with Williams syndrome can have coronary artery stenosis
- Individuals with confirmed coronary artery anomalies may require repeat imaging based on the clinical scenario
- CCTA to rule out anomalous coronary artery should be limited to one of the following:
 - Individuals who need to have an anomalous coronary artery mapped prior to an invasive procedure.
 - Individuals who have not had a previous imaging study that clearly demonstrates an anomalous coronary artery
 - Individuals with a history that includes one or more of the indications in **Indications for CCTA (CPT® 75574) (PEDCD-10.3)**

Tetralogy of Fallot (TOF) (PEDCD-2.4.13)

CDP.CHD.2413.A
v1.0.2024

Any surgical status

- TTE, CMR/CT-CMRA/CTA
 - Initial evaluation of change in clinical status and/or new concerning signs or symptoms
 - Evaluation prior to planned pulmonary valve replacement, cardiac intervention, or surgery

Unrepaired

- Newborn-TTE no limits
- Infant
 - 1 per month

Post procedure palliation

- 1 per month following palliative procedure prior to complete repair, valvuloplasty, PDA and/or RVOT stenting, or shunt placement before complete repair

Post-operative TOF (initial repair)

- TTE
 - Within 30 days of repair
 - Child-12 months
 - Adolescence every 24 months
 - Every 6 months in an individual with valvular dysfunction other than pulmonary valve, RVOT obstruction, branch pulmonary artery stenosis, arrhythmias, or presence of an RV-to-PA conduit
 - TTE every 3 months if CHF
- Cardiac MR/CT, MRA/CTA Chest every
 - Routine surveillance (36 months) in an individual with PR and preserved ventricular function
 - 12 months if moderate (≥ 150 mL/m²) or progressive (increase of >25 mL/m²) RV dilatation or dysfunction (RVEF $\leq 48\%$ or $\geq 6\%$ decrease in EF) or nearing imaging criteria for PVR.

Post-surgical or catheter based pulmonary valve replacement

- TTE
 - Within 30 days follow-up
 - 1 and 6 months after replacement
 - One year post procedure
 - Annually after replacement
 - Every 6 months if RV-to-PA conduit dysfunction, valvular or ventricular dysfunction, branch pulmonary artery stenosis, or arrhythmias
 - Every 3 months if CHF symptoms
- CMR/CT-CMRA/CTA every 2 years

Double Outlet Right Ventricle (DORV) (PEDCD-2.4.14)

CDP.CHD.2414.A

v1.0.2024

Any surgical status

- TTE, CMR/CT-CMRA/CTA are indicated for any of the following:
 - Initial evaluation of change in clinical status and/or new concerning signs or symptoms
 - Evaluation prior to repair

Unrepaired

- TTE
 - Newborn no limit
 - Monthly infant with balanced systemic and pulmonary circulation
 - Every 3 months child with balanced circulation

Postoperative

- TTE
 - Within 30 days
 - First year post-op every 6 months
 - After one year, TTE every 1 year
 - TTE 3 months in an individual with valvular or ventricular dysfunction, right or left ventricular outflow tract obstruction, branch pulmonary artery stenosis, arrhythmias, or presence of an RV-to-PA conduit, heart failure.
- Cardiac MR/CT, MRA/CTA Chest
 - 3 years for asymptomatic individual

D-Loop Transposition of the Great Arteries (D-Loop TGA) (PEDCD-2.4.15)

CDP.CHD.2415.A

v1.0.2024

Any surgical status

- **TTE, CMR/CT-CMRA/CTA, stress imaging** are indicated for any of the following:
 - Initial evaluation of change in clinical status and/or new concerning signs or symptoms
 - Any time after procedure involving coronary arteries
- **CMR/CT-CMRA/CTA** every 5 years.

Unrepaired (TTE)

- No Limits

Post arterial switch

- TTE
 - Within 30 days of repair
 - Infant: every one month
 - Child: every 3 months
 - Child with \geq moderate sequelae: TTE every three 3 months (moderate valvular or ventricular dysfunction, right or left ventricular outflow tract obstruction, branch pulmonary artery stenosis, or arrhythmias)
- Routine CMR/CT
 - Every 3 years
 - Every year if neo AI
- MRA/CTA Chest
 - Every 3 years
 - Every year if neo AI or aortic dilation
- Stress imaging
 - 1 routine test after arterial switch at any time

Post Rastelli

- TTE
 - Within 30 days
 - Every three months following procedure for one year
 - Child Every 6 months following the first year after repair if no or mild sequelae
 - Adolescent annually
 - Every three months if moderate valvular dysfunction, LVOT obstruction, presence of an RV-to-PA conduit, branch, pulmonary artery stenosis, or arrhythmias, or heart failure
- CMR/CT-CMRA/CTA every 3 years

Post atrial switch

- TTE Every 1 year if mild to no symptoms
 - Every 3 months TTE, and CMR MRA CCT CTA if \geq moderate systemic AV, valve regurgitation, systemic RV dysfunction, LVOT obstruction, or arrhythmias, or CHF.
 - Routine **CMR/CT-CMRA/CTA** every 3 years

Congenitally Corrected Transposition of the Great Arteries (ccTGA, LTGA) (PEDCD-2.4.16)

CDP.CHD.2416.A

v1.0.2024

Any surgical status

- TTE, TEE, **CMR/CT-CMRA/CTA** are indicated for any of the following:
 - Change clinical status and/or new concerning signs or symptoms
 - Preoperative evaluation (typically within one month)
- CMR/CT-CMRA/CTA every 3 years

Unrepaired

- TTE
 - Newborn-Weekly
 - Infant
 - Every 3 months if no cardiac symptoms and only mild findings
 - Every 1 month if cardiac symptoms and moderate findings
 - Child
 - <2 years every 3 months
 - >2 years every 1 year
 - Every 6 months if \geq moderate AV regurg
 - Every 3 months if CHF symptoms
 - CMR/CT-CMRA/CTA
 - Every 3 years

Postoperative: Anatomic Repair

- TTE
 - Post-operative evaluation (within 30 days)
 - Every 3 months within a year following repair in an asymptomatic individual with no or mild sequelae
 - Every 1 year after the first year following repair in an asymptomatic individual with no or mild sequelae
 - Every 6 months if valvular or ventricular dysfunction, right or left ventricular outflow tract obstruction, or presence of a RV-to-PA conduit
 - Every 3 months if CHF symptoms
- CMR/CT-CMRA/CTA
 - Every 3 years

Postoperative: Physiological Repair with VSD Closure and/or LV-to-PA Conduit

- TTE
 - Postoperative evaluation (within 30 days)
 - Every 3 months within a year following repair in an asymptomatic individual with no or mild sequelae
 - Annually in an asymptomatic individual with no or mild sequelae
 - Every 3 months if in an individual with \geq moderate systemic AV valve regurgitation, systemic RV dysfunction, and/or LV-to-PA conduit dysfunction, or with CHF symptoms
- CMR/CT-CMRA/CTA every 3 months in an individual with \geq moderate systemic AV valve regurgitation, systemic RV dysfunction, and/or LV-to-PA conduit dysfunction, or with CHF symptoms

Truncus Arteriosus (PEDCD-2.4.17)

CDP.CHD.2417.A

v1.0.2024

Any surgical status

- TTE, CMR/CT-CMRA/CTA are indicated for any of the following:
 - Initial evaluation of change in clinical status and/or new concerning signs or symptoms
 - Prior to planned intervention or surgery

Postoperative

- TTE
 - Within 30 days
 - Monthly in first year after surgery
 - After first year every 6 months
 - Every 3 months if
 - ≥moderate truncal stenosis or regurgitation
 - Residual VSD or RV to PA conduit or Branch PA obstruction
 - Symptoms of CHF
- CMR/CT-CMRA/CTA
 - Annually if ≥moderate Truncal stenosis or regurgitation

Single Ventricle (SV) (PEDCD-2.4.18)

CDP.CHD.2418.A

v1.0.2024

SV references individuals not amenable to biventricular repair, including but not limited to hypoplastic left heart syndrome, tricuspid atresia, Double inlet left ventricle, mitral atresia, unbalanced AVSD, and forms of PA/IVS

Any surgical status

- Any/All: **TTE, TEE, CMR/CT-CMRA/CTA, and cardiac catheterization (CPT® 93593, 93594, 93595, or 93597)** are indicated for any of the following:
 - Change clinical status and/or new concerning signs or symptoms
 - Preoperative evaluation (typically within one month)

Unrepaired SV

- TTE allowed one study per week

Stage 1 palliation (TTE)

- Often called Norwood or Sano, or hybrid cath procedure
- Routine weekly TTE

Stage 2 palliation (TTE)

- Often referred to as Glenn procedure
- Within 30 days after surgical or cath intervention
- 1 per month in infant or child

Stage III, also called Fontan

- TTE within 30 days
- TTE every three months within first post-op year
- Every 6 months after first year
- Every 3 years allow **CMR/CCT-MRA/CTA**
- TTE every 3 months until the finding is stable or there is a need for intervention if there is valvular dysfunction, arrhythmias, heart failure

Surveillance

Cardiac catheterization is indicated for all Single Ventricles once every 10 years

Eisenmenger and PHT (with CHD)- (PEDCD-2.4.19)

CDP.CHD.2419.A

v1.0.2024

PHT without CHD is covered in section **Pediatric Pulmonary Hypertension (PEDCD-7)**

These are in addition to studies supported by lesion

Any surgical status

- TTE, CMR/CT-CMRA/CTA are indicated for any of the following:
 - Change clinical status and/or new concerning signs or symptoms
 - Preoperative evaluation (typically within one month)

Initial evaluation (TTE)

- Change in clinical status and/or new concerning signs or symptoms
- Before and after PHT therapy

Eisenmenger Syndrome (ES) individual

- TTE every 6 months

PHT associate with CHD

- Unrepaired individuals with evidence of elevated pulmonary vascular resistance can have echocardiograms based on the frequency requested by the provider
- TTE and Cardiac CMR/CCT for changes in change in pulmonary arterial hypertension-targeted therapy in an individual with postoperative PH
- TTE every 3 months in postoperative stable child with PHT

References (PEDCD-2)

v1.0.2024

1. Kliegman R, Lye PS, Bordini BJ, et al. *Nelson Pediatric Symptom-Based Diagnosis*. Philadelphia, PA: Elsevier; 2018.
2. Riveros R and Riveros-Perez E. Perioperative considerations for children with right ventricular dysfunction. *Seminars in Cardiothoracic and Vascular Anesthesia*. 2015 Jul 10;19(3):187–202.
3. Lai WW, Geva T, Shirali GS, et al. Guidelines and Standards for Performance of a Pediatric Echocardiogram: A Report from the Task Force of the Pediatric Council of the American Society of Echocardiography. *J Am Soc Echocardiogr*. 2006;19(12):1413-1430. doi:10.1016/j.echo.2006.09.001.
4. Prakash A, Powell AJ, Geva T. Multimodality Noninvasive Imaging for Assessment of Congenital Heart Disease. *Circulation: Cardiovascular Imaging*. 2010;3(1):112-125. doi:10.1161/CIRCIMAGING.109.875021.
5. Simpson J, Lopez L, Acar P, et al. Three-dimensional Echocardiography in Congenital Heart Disease: An Expert Consensus Document from the European Association of Cardiovascular Imaging and the American Society of Echocardiography. *J Am Soc Echocardiogr*. 2017;30(1):1-27. doi:10.1016/j.echo.2016.08.022
6. Truong UT, Kutty S, Broberg CS, Sahn DJ. Multimodality Imaging in Congenital Heart Disease: an Update. *Current Cardiovascular Imaging Reports*. 2012;5(6):481-490. doi:10.1007/s12410-012-9160-6.
7. Wernovsky G, Rome JJ, Tabbutt S, et al. Guidelines for the Outpatient Management of Complex Congenital Heart Disease. *Congenital Heart Disease*. 2006;1(1-2):10-26. doi:10.1111/j.1747-0803.2006.00002.x.
8. Valente AM, Cook S, Festa P, et al. Multimodality Imaging Guidelines for Patients with Repaired Tetralogy of Fallot: A Report from the American Society of Echocardiography. *J Am Soc Echocardiogr*. 2014;27(2):111-141. doi:10.1016/j.echo.2013.11.009.
9. Margossian R, Schwartz ML, Prakash A, et al. Comparison of Echocardiographic and Cardiac Magnetic Resonance Imaging Measurements of Functional Single Ventricular Volumes, Mass, and Ejection Fraction (from the Pediatric Heart Network Fontan Cross-Sectional Study) A list of participating institutions and investigators appears in the Appendix. *The American Journal of Cardiology*. 2009;104(3):419-428. doi:10.1016/j.amjcard.2009.03.058.
10. Hundley WG, Bluemke DA, Finn JP, et al. ACCF/ACR/AHA/NASCI/SCMR 2010 Expert Consensus Document on Cardiovascular Magnetic Resonance. *Circulation*. 2010;121(22):2462-2508. doi:10.1161/cir.0b013e3181d44a8f.
11. Silvestry FE, Cohen MS, Armsby LB, et al. Guidelines for the Echocardiographic Assessment of Atrial Septal Defect and Patent Foramen Ovale: From the American Society of Echocardiography and Society for Cardiac Angiography and Interventions. *J Am Soc Echocardiogr*. 2015;28(8):910-958. doi:10.1016/j.echo.2015.05.015.
12. Franklin RCG, Béland MJ, Colan SD, et al. Nomenclature for Congenital and Paediatric Cardiac Disease: the International Paediatric and Congenital Cardiac Code (IPCCC) and the Eleventh Iteration of the International Classification of Diseases (ICD-11). *Cardiology in the Young*. 2017;27(10):1872-1938. doi:10.1017/s1047951117002244.
13. Cohen MS, Eidem BW, Cetta F, et al. Multimodality Imaging Guidelines of Patients with Transposition of the Great Arteries: A Report from the American Society of Echocardiography Developed in Collaboration with the Society for Cardiovascular Magnetic Resonance and the Society of Cardiovascular Computed Tomography. *J Am Soc Echocardiogr*. 2016;29(7):571-621. doi:10.1016/j.echo.2016.04.002.
14. Canobbio MM, Warnes CA, Aboulhosn J, et al. Management of Pregnancy in Patients with Complex Congenital Heart Disease: A Scientific Statement for Healthcare Professionals From the American Heart Association. *Circulation*. 2017;135(8). doi:10.1161/cir.0000000000000458.
15. Hare GFV, Ackerman MJ, Evangelista J-AK, et al. Eligibility and Disqualification Recommendations for Competitive Athletes with Cardiovascular Abnormalities: Task Force 4: Congenital Heart Disease. *J Am Coll Cardiol*. 2015;66(21):2372-2384. doi:10.1016/j.jacc.2015.09.036.
16. Giglia T, Stagg A. Infant Single Ventricle Monitoring Program (ISVMP): Outpatient Interstage Pathway: Stage I Discharge to Second Operation. Clinical Pathways Program. <https://www.chop.edu/clinical-pathway/single-ventricle-fetus-or-newborn-clinical-pathway>. Published July 2011. Accessed July 26, 2019. Revised January 2018.
17. Sachdeva R, Valente AM, Armstrong AK, et al. ACC/AHA/ASE/HRS/ISACHD/SCAI/SCCT/SCMR/SOPE 2020 Appropriate Use Criteria for Multimodality Imaging During the Follow-Up Care of Patients with Congenital Heart Disease. *J Am Coll Cardiol*. 2020;75(6):657-703. doi:10.1016/j.jacc.2019.10.002.
18. MacCarrick G, Black JH 3rd, Bowdin S, et al. Loeys-Dietz syndrome: a primer for diagnosis and management. *Genet Med*. 2014;16(8):576–587. doi:10.1038/gim.2014.11.
19. Loeys BL, Dietz HC. Loeys-Dietz Syndrome. GeneReviews® [Internet]. <https://www.ncbi.nlm.nih.gov/books/NBK1133/>. Published March 1, 2018.
20. Caglayan AO, Dundar M. Inherited diseases and syndromes leading to aortic aneurysms and dissections. *European Journal of Cardio-Thoracic Surgery*. 2009;35(6):931-940. doi:10.1016/j.ejcts.2009.01.006. Collins

- RT. Cardiovascular Disease in Williams Syndrome. *Circulation*. 2013;127(21):2125-2134. doi:10.1161/circulationaha.112.000064.
21. D'hondt S, Damme TV, Malfait F. Vascular phenotypes in nonvascular subtypes of the Ehlers-Danlos syndrome: a systematic review. *Genetics in Medicine*. 2017;20(6):562-573. doi:10.1038/gim.2017.138.
 22. Hiratzka LF, Creager MA, Isselbacher EM, et al. Surgery for Aortic Dilatation in Patients with Bicuspid Aortic Valves. *J Am Coll Cardiol*. 2016;67(6):724-731. doi:10.1016/j.jacc.2015.11.006.
 23. Knadler JJ, Lemaire S, McKenzie ED, et al. Thoracic Aortic, Aortic Valve, and Mitral Valve Surgery in Pediatric and Young Adult Patients With Marfan Syndrome: Characteristics and Outcomes. *Seminars in Thoracic and Cardiovascular Surgery*. 2019;31(4):818-825. doi:10.1053/j.semtcvs.2019.06.005.
 24. Landis BJ, Ware SM, James J, Shikany AR, Martin LJ, Hinton RB. Clinical Stratification of Pediatric Patients with Idiopathic Thoracic Aortic Aneurysm. *J Pediatr*. 2015;167(1):131-137. doi:10.1016/j.jpeds.2015.02.042.
 25. Oner T, Akgun G, Ergin SO, Karadag H, Yucel IK, Celebi A. Risk Factors Associated with Ascending Aortic Aneurysms and Aortic Elasticity Parameters in Children with a Bicuspid Aortic Valve. *Pediatric Cardiology*. 2019;40(5):980-986. doi:10.1007/s00246-019-02102-6.
 26. Maron BJ, Zipes DP, Kovacs RJ. Eligibility and Disqualification Recommendations for Competitive Athletes with Cardiovascular Abnormalities: Preamble, Principles, and General Considerations. *J Am Coll Cardiol*. 2015;66(21):2343-2349. doi:10.1016/j.jacc.2015.09.032.
 27. Meester JAN, Verstraeten A, Schepers D, et al. Differences in manifestations of Marfan syndrome, Ehlers-Danlos syndrome, and Loays-Dietz syndrome. *Annals of Cardiothoracic Surgery*. 2017;6(6):582-594. doi:10.21037/acs.2017.11.03.
 28. Otto CM, Nishimura RA, Bonow RO, et al. 2020 ACC/AHA Guideline for the Management of Patients With Valvular Heart Disease: A Report of the American College of Cardiology/American Heart Association Joint Committee on Clinical Practice Guidelines. *Circulation*. 2021;143(5):e72-e227. doi:10.1161/cir.0000000000000923.
 29. Bonow RO, O'Gara PT, Adams DH, et al. 2020 Focused Update of the 2017 ACC Expert Consensus Decision Pathway on the Management of Mitral Regurgitation. *J Am Coll Cardiol*. 2020;75(17):2236-2270. doi:10.1016/j.jacc.2020.02.005.
 30. Nishimura RA, O'Gara PT, Bavaria JE, et al. 2019 AATS/ACC/ASE/SCAI/STS Expert Consensus Systems of Care Document: A Proposal to Optimize Care for Patients With Valvular Heart Disease: A Joint Report of the American Association for Thoracic Surgery, American College of Cardiology, American Society of Echocardiography, Society for Cardiovascular Angiography and Interventions, and Society of Thoracic Surgeons. *J Am Soc Echocardiogr*. 2019;32(6):683-707. doi:10.1016/j.echo.2019.02.016.
 31. Doherty JU, Kort S, Mehran R, et al. ACC/AATS/AHA/ASE/ASNC/HRS/SCAI/SCCT/SCMR/STS 2019 Appropriate Use Criteria for Multimodality Imaging in the Assessment of Cardiac Structure and Function in Nonvalvular Heart Disease. *J Am Coll Cardiol*. 2019;73(4):488-516. doi:10.1016/j.jacc.2018.10.038.
 32. Rychik J, Atz AM, Celermajer DS, et al. Evaluation and Management of the Child and Adult With Fontan Circulation: A Scientific Statement From the American Heart Association [published online ahead of print, 2019 Jul 1]. *Circulation*. 2019;CIR0000000000000696. doi:10.1161/CIR.0000000000000696.

Condition Specific Imaging

Guideline

Multisystem Inflammatory Syndrome in Children (MIS-C) (PEDCD-12)

Heart Murmur (PEDCD-3.1)

Chest Pain General (PEDCD-4.1)

Syncope (PEDCD-5.1)

Pediatric Pulmonary Hypertension General (PEDCD-7.1)

Evaluation of Pericardial Effusion or Diagnosis of Pericardial Tamponade (PEDCD-9.5)

Kawasaki Disease (PEDCD-6)

Multisystem Inflammatory Syndrome in Children (MIS-C) (PEDCD-12)

CDP.CS.0012.A

v1.0.2024

MIS-C General Information (PEDCD-12.1)

SARS-CoV-2 (COVID 19) is usually mild in children. Some children develop a severe inflammatory disease that can present in a similar way to Kawasaki disease or toxic shock syndrome. This syndrome has been defined by the US Centers for Disease Control and Prevention as multisystem inflammatory syndrome in children (MIS-C).

These guidelines are intended for use in the outpatient management of cardiac findings of MIS-C. Additional information can be found in [PEDHD-12.7](#) for the outpatient management of head imaging.

MIS-C Indications for Cardiac Imaging (PEDCD-12.2)

MIS-C Initial Cardiac Imaging (PEDCD-12.2.1)

- When there is concern for MIS-C, as in atypical or incomplete Kawasaki (see [Kawasaki Disease - Acute Phase \(PEDCD-6.2\)](#)) echo (TTE) can be approved
- A cardiac MRI can be approved at the time of diagnosis when there are issues that can affect treatment management not answered by other testing
- Cardiac CCTA can be done if there is incomplete visualization of the coronary arteries
- Repeat echocardiograms may be required and approved if either:
 - Treatment decisions will be affected by results (e.g., treating with IVIg)
 - There are new signs or symptoms

MIS-C Repeat Cardiac Imaging (PEDCD-12.2.2)

The following imaging guidelines reference outpatient management of individuals who have been discharged from the hospital after stability for MIS-C has been established.

- An echo (TTE) can be approved at the time of presentation and followed by serial echos (TTE) until stabilization has been achieved for any of the following:
 - New cardiac signs, symptoms, or findings
 - Evidence of recurrence of MIS-C
 - Changes in medication
- Serial echos can be approved based on the ordering cardiologist's discretion or the treating medical provider in consultation with a cardiologist when there is documented cardiac dysfunction.

- Individuals who are discharged from the hospital after MIS-C and have stable findings can have an echo (TTE):
 - Within 1 week of discharge
 - 4 weeks post-discharge
 - At 6 months post-discharge
 - One year post-discharge
- Cardiac CCTA can be done if there is incomplete visualization of the coronary arteries
- A routine cardiac MRI can be done once after 3 months in an individual with evidence of cardiac involvement (e.g., symptoms, EKG, labs, or echocardiogram)
- Individuals with changes, or unanswered questions, on echo (TTE) may have a Cardiac MRI based on **Cardiac MRI and MRA Chest – Indications (excluding Stress MRI) (CD-5.2)** in the cardiac imaging guidelines

Individuals with dilated coronary arteries can have imaging based on the AHA Kawasaki guidelines.

AHA risk level	Largest Aneurysm At Any Point	Largest Current Aneurysm	Routine Echo	Routine Stress Imaging	Routine Coronary Imaging
All			All risk levels 4-6 weeks after acute illness		
1	Normal	Normal	One echo 2-12 months after acute illness	none	none
2	Dilation	Dilation	6 months One year If dilation remains echo every 2-5 years until resolves	None	None
		Normal	After acute illness: 2-12 months One echocardiogram at one year No echocardiogram after one year		
3.1	Small	Small	6 months 12 months Then yearly	2-3 years	3-5 years

AHA risk level	Largest Aneurysm At Any Point	Largest Current Aneurysm	Routine Echo	Routine Stress Imaging	Routine Coronary Imaging
3.2	Small	Normal or dilated	6 months 12 months Then yearly	3-5 years	none
4.1	Medium	Medium	3 months 6 months 12 months Every 6-12 months after that	1-3 years	2-5 years
4.2	Medium	Small	6 months and 12 months, every 1 year	2-3 years	3-5 years
4.3	Medium	Normal Or Dilated	Every 1-2 years	2-4 years	none
5.1	Large	Large	1 month 3 months 6 months 9 months 12 months Then every 3-6 months	6-12 months	at 2-6 months, every 1-5 years
5.2	Large	Medium	Every 6-12 months	yearly	2-5 years
5.3	Large	Small	6-12 month	1-2 years	2-5 years
5.4	Large	Normal Or Dilation	1-2 years	2-5 years	none

Symptomatic individuals

- Echocardiogram can be performed at any time with new or progressing cardiac symptoms
- Stress imaging when there are new or progressing symptoms of ischemia or ventricular dysfunction
- Invasive or coronary imaging coronary angiography (CT, MRI, invasive) when the above studies are positive, inconclusive, or otherwise lead to a conclusion that intervention is needed

References

1. Information for Healthcare Providers about Multisystem Inflammatory Syndrome in Children (MIS-C). Centers for Disease Control and Prevention. <https://www.cdc.gov/mis-c/hcp/>. Published February 17, 2021.
2. Ahmed M, Advani S, Moreira A, et al. Multisystem inflammatory syndrome in children: A systematic review. *EClinicalMedicine*. 2020;26:100527. doi:10.1016/j.eclim.2020.100527.
3. Lee PY, Day-Lewis M, Henderson LA, et al. Distinct clinical and immunological features of SARS-CoV-2-induced multisystem inflammatory syndrome in children. *J Clin Invest*. 2020;130(11):5942-5950. doi:10.1172/jci141113.
4. Choi NH, Fremed M, Starc T, et al. MIS-C and Cardiac Conduction Abnormalities. *Pediatrics*. 2020;146(6). doi:10.1542/peds.2020-009738.
5. Dionne A, Mah DY, Son MB, et al. Atrioventricular Block in Children with Multisystem Inflammatory Syndrome. *Pediatrics*. 2020;146(5). doi:10.1542/peds.2020-009704.
6. McMurray JC, May JW, Cunningham MW, Jones OY. Multisystem Inflammatory Syndrome in Children (MIS-C), a Post-viral Myocarditis and Systemic Vasculitis—A Critical Review of Its Pathogenesis and Treatment. *Front Pediatr*. 2020;8. doi:10.3389/fped.2020.626182.
7. Multisystem Inflammatory Syndrome in Children (MIS-C). Centers for Disease Control and Prevention. <https://www.cdc.gov/mis-c/>. Published February 25, 2021.
8. Kaushik S, Aydin SI, Derespina KR, et al. Multisystem Inflammatory Syndrome in Children Associated with Severe Acute Respiratory Syndrome Coronavirus 2 Infection (MIS-C): A Multi-institutional Study from New York City. *J Pediatr*. 2020;224:24-29. doi:10.1016/j.jpeds.2020.06.045.
9. Feldstein LR, Rose EB, Horwitz SM, et al. Multisystem Inflammatory Syndrome in U.S. Children and Adolescents. *N Engl J Med*. 2020;383(4):334-346. doi:10.1056/nejmoa2021680.
10. Ebina-Shibuya R, Namkoong H, Shibuya Y, Horita N. Multisystem Inflammatory Syndrome in Children (MIS-C) with COVID-19: Insights from simultaneous familial Kawasaki Disease cases. *Int J Infect Dis*. 2020;97:371-373. doi:10.1016/j.ijid.2020.06.014.
11. Valverde I, Singh Y, Sanchez-de-Toledo J, et al. Acute Cardiovascular Manifestations in 286 Children With Multisystem Inflammatory Syndrome Associated With COVID-19 Infection in Europe. *Circulation*. 2021;143(1):21-32. doi:10.1161/circulationaha.120.050065.
12. Alsaied T, Tremoulet AH, Burns JC, et al. Review of Cardiac Involvement in Multisystem Inflammatory Syndrome in Children. *Circulation*. 2021;143(1):78-88. doi:10.1161/CIRCULATIONAHA.120.049836.
13. Sperotto F, Friedman KG, Son MB, VanderPluym CJ, Newburger JW, Dionne A. Cardiac manifestations in SARS-CoV-2-associated multisystem inflammatory syndrome in children: a comprehensive review and proposed clinical approach. *European Journal of Pediatrics*. 2020;180(2):307-322. doi:10.1007/s00431-020-03766-6.
14. Friedman KG, Harrild DM, Newburger JW. Cardiac Dysfunction in Multisystem Inflammatory Syndrome in Children. *Journal of the American College of Cardiology*. 2020;76(17):1962-1964. doi:10.1016/j.jacc.2020.09.002.
15. McCrindle BW, Rowley AH, Newburger JW, et al. Diagnosis, Treatment, and Long-Term Management of Kawasaki Disease: A Scientific Statement for Health Professionals From the American Heart Association. *Circulation*. 2017;135(17). doi:10.1161/cir.0000000000000484
16. Belhadjer Z, Méot M, Bajolle F, et al. Acute Heart Failure in Multisystem Inflammatory Syndrome in Children in the Context of Global SARS-CoV-2 Pandemic. *Circulation*. 2020;142(5):429-436. doi:10.1161/circulationaha.120.048360.

Heart Murmur (PEDCD-3.1)

CDP.CS.003.1.A

v1.0.2024

When evaluating an individual with a murmur for the first time, it will not be known whether the individual has congenital heart disease or not.

Initial pediatric TTE combinations

Cardiologist only submits charges for the procedure actually performed
CPT® 93303, CPT® 93306, CPT® 93320, and CPT® 93325
CPT® 93303, CPT® 93320, and CPT® 93325
CPT® 93303, CPT® 93306
CPT® 93306 (CPT® 93320 and CPT® 93325 are included with CPT® 93306 and should not be approved separately)

- Any one of the above echocardiography code combinations is indicated for evaluation of either:
 - Any pathologic murmur
 - Any innocent murmur with associated cardiac signs or symptoms
- Repeat echocardiography is not indicated if the initial echocardiogram was normal and the murmur has not changed in quality.

Background and supporting information

- Heart murmurs are extremely common in pediatric individuals. The thinner chest wall in children allows clearer auscultation of blood flowing through the chambers of the heart, which may result in a murmur on physical exam.
- The majority of murmurs are innocent and do not require further evaluation. More than 30% of children may have an innocent murmur detected during physical examination. Innocent murmurs are typically systolic ejection murmurs with a vibratory or musical quality, and generally change in quality when the individual changes position.
- Other types of murmurs can be pathologic and require additional evaluation, usually by a pediatric cardiologist. Echocardiography is indicated, and is performed as part of the office visit.

References

1. Nelson Textbook of Pediatrics, 20th Edition, Robert M. Kliegman, MD, Bonita M.D. Stanton, MD, Joseph St. Geme, MD and Nina F Schor, MD, PhD, p2182 to p2292.
2. Campbell RM, Douglas PS, Eidem BW, Lai WW, Lopez L, Sachdeva R. ACC/AAP/AHA/ASE/HRS/SCAI/SCCT/SCMR/SOPE 2014 Appropriate Use Criteria for Initial Transthoracic Echocardiography in Outpatient Pediatric Cardiology. *Journal of the American College of Cardiology*. 2014;64(19):2039-2060. doi:10.1016/j.jacc.2014.08.003.

3. Lai WW, Geva T, Shirali GS, et al. Guidelines and Standards for Performance of a Pediatric Echocardiogram: A Report from the Task Force of the Pediatric Council of the American Society of Echocardiography. *Journal of the American Society of Echocardiography*. 2006;19(12):1413-1430. doi:10.1016/j.echo.2006.09.001.
4. Allen HD, Shaddy RE, Penny DJ, Cetta F, Feltes TF. Moss and Adams' Heart Disease in Infants, Children, and Adolescents: Including the Fetus and Young Adult. 9th ed. Philadelphia, PA: Wolters Kluwer; 2016.
5. Prakash A, Powell AJ, Geva T. Multimodality Noninvasive Imaging for Assessment of Congenital Heart Disease. *Circulation: Cardiovascular Imaging*. 2010;3(1):112-125. doi:10.1161/circimaging.109.875021.
6. Danford DA, McNamara DG. Innocent murmurs and heart sounds. In: The Science and Practice of Pediatric Cardiology, 2nd ed, Garson AJ, Bricker JT, Fisher DJ, Neish SR (Eds), Williams & Wilkins, Baltimore 1998. p.220ff DF, McNamara GG. History and physical examination of the cardiovascular system. In: The Science and Practice of Pediatric Cardiology, 2nd ed, Garson AJ, Bricker JT, Fisher DJ, Neish SR (Eds), Williams and Wilkins, Baltimore 1998. p.693nn rrr

Chest Pain General (PEDCD-4.1)

CDP.CS.0004.1.A

v1.0.2024

Initial pediatric TTE combinations

Cardiologist only submits charges for the procedure actually performed
CPT® 93303, CPT® 93306, CPT® 93320, and CPT® 93325
CPT® 93303, CPT® 93320, and CPT® 93325
CPT® 93303, CPT® 93306
CPT® 93306 (CPT® 93320 and CPT® 93325 are included with CPT® 93306 and should not be approved separately)

- Any one of the TTE combinations above is indicated for pediatric individuals with chest pain and one or more of the following:
 - Exertional chest pain
 - Non-exertional chest pain with abnormal EKG
 - Chest pain with signs or symptoms of pericarditis
 - First-degree relative with sudden unexplained death or cardiomyopathy
 - Recent onset of fever
 - Recent illicit drug use
 - Other signs or symptoms of cardiovascular disease
- Repeat echocardiography is not indicated if the initial echocardiogram is normal unless one of the following conditions is present:
 - Increased severity or change in quality of the chest pain
 - New signs or symptoms of cardiovascular disease other than pain
 - New abnormality on EKG
- Cardiac MR or cardiac CT is indicated for chest pain if prior evaluation suggests:
 - Any coronary artery abnormalities
 - Cardiomyopathy
 - Myocarditis
- Chest MRA or CTA if pulmonary embolism or aortic dissection is suspected
- Stress imaging is indicated if other imaging suggests coronary artery abnormality, or ETT suggests ischemia. EKG is uninterpretable. Any indication in section **Stress Testing with Imaging – Indications (CD 1.4)** in the Cardiac Imaging Guidelines. This can include Stress SPECT, echo or MR

Background and supporting information

Chest pain in pediatric individuals is caused by a cardiac etiology in <5% of cases, yet causes great anxiety for parents resulting in requests for testing.

Individuals with CP may undergo an exercise stress test without imaging.

Echocardiography is performed as part of the office visit. When evaluating an individual for the first time, it will not be known whether the individual has congenital heart disease or not. The cardiologist only submits charges for the procedure actually performed.

References

1. Kliegman R, Nelson WE. *Nelson Textbook of Pediatrics*. 20th ed. Philadelphia, PA: Elsevier; 2016.
2. Friedman KG, Alexander ME. Chest Pain and Syncope in Children: A Practical Approach to the Diagnosis of Cardiac Disease. *The Journal of Pediatrics*. 2013;163(3). doi:10.1016/j.jpeds.2013.05.001.
3. Campbell RM, Douglas PS, Eidem BW, Lai WW, Lopez L, Sachdeva R. ACC/AAP/AHA/ASE/HRS/SCAI/SCCT/SCMR/SOPE 2014 Appropriate Use Criteria for Initial Transthoracic Echocardiography in Outpatient Pediatric Cardiology. *Journal of the American College of Cardiology*. 2014;64(19):2039-2060. doi:10.1016/j.jacc.2014.08.003.
4. Allen HD, Shaddy RE, Penny DJ, Cetta F, Feltes TF. *Moss and Adams' Heart Disease in Infants, Children, and Adolescents: Including the Fetus and Young Adult*. 9th ed. Philadelphia, PA: Wolters Kluwer; 2016
5. Friedman KG, Kane DA, Rathod RH, et al. Management of pediatric chest pain using a standardized assessment and management plan. *Pediatrics* 2011; 128:239.
6. Friedman KG, Alexander ME. Chest Pain and Syncope in Children: A Practical Approach to the Diagnosis of Cardiac Disease. *The Journal of Pediatrics*. 2013;163(3). doi:10.1016/j.jpeds.2013.05.001.
7. Barbut G, Needleman JP. Pediatric Chest Pain. *Pediatr Rev*. 2020;41(9):469-480. doi:10.1542/pir.2019-0058.

Syncope (PEDCD-5.1)

CDP.CS.0005.1.A

v1.0.2024

Initial pediatric TTE combinations

Cardiologist only submits charges for the procedure actually performed
CPT® 93303, CPT® 93306, CPT® 93320, and CPT® 93325
CPT® 93303, CPT® 93320, and CPT® 93325
CPT® 93303, CPT® 93306
CPT® 93306 (CPT® 93320 and CPT® 93325 are included with CPT® 93306 and should not be approved separately)

- Echocardiography is not indicated for most individuals with isolated syncope.
- Echocardiography is indicated for pediatric individuals with syncope and one or more of the following:
 - Exertional syncope
 - Unexplained post-exertional syncope
 - Abnormal EKG
 - Absence of prodromal symptoms
 - Presence of preceding palpitations within seconds of loss of consciousness
 - Lack of a prolonged upright posture
 - Syncope in response to auditory or emotional
 - First-degree relative with any of the following before age 50:
 - Sudden cardiac arrest or death
 - Pacemaker or implantable defibrillator placement
 - First-degree relative with cardiomyopathy
 - Known congenital heart disease
 - History of Kawasaki disease, or other coronary pathology.
 - Pathologic murmur, irregular rhythm, gallop, or click on physical examination
- Repeat echocardiography is not indicated if the initial echocardiogram is normal unless one of the following conditions is present:
 - Increased severity or change in quality of the syncope
 - New signs or symptoms of cardiovascular disease other than syncope
 - Family of history of sudden death, cardiomyopathy
 - New abnormality on EKG
- Cardiac MR or Cardiac CT is indicated for chest pain if prior evaluation suggests any coronary artery abnormalities, cardiomyopathy, myocarditis
- MRA or CTA Chest if pulmonary embolism or aortic dissection is suspected

- Stress imaging (SPECT, echo or MR) is indicated (any);
 - If other imaging suggests coronary artery abnormality
 - ETT suggests ischemia
 - EKG is uninterpretable
 - Any indication in section **Stress Testing with Imaging – Indications (CD 1.4)** in the Cardiac Imaging Guidelines

Background and supporting information

Syncope in pediatric individuals is common, with up to 15% of individuals experiencing at least one episode by age 21. Syncope is caused by neurocardiogenic syndrome (vasovagal syncope) in 75% to 80% of cases, which is a benign and self-limiting condition. Despite this, syncope causes great anxiety for parents resulting in requests for testing.

Individuals with CP may undergo an exercise stress test without imaging.

References

1. Kliegman R, Nelson WE. Nelson Textbook of Pediatrics. 20th ed. Philadelphia, PA: Elsevier; 2016.
2. Friedman KG, Alexander ME. Chest Pain and Syncope in Children: A Practical Approach to the Diagnosis of Cardiac Disease. *The Journal of Pediatrics*. 2013;163(3). doi:10.1016/j.jpeds.2013.05.001.
3. Campbell RM, Douglas PS, Eidem BW, Lai WW, Lopez L, Sachdeva R. ACC/AAP/AHA/ASE/HRS/SCAI/SCCT/SCMR/SOPE 2014 Appropriate Use Criteria for Initial Transthoracic Echocardiography in Outpatient Pediatric Cardiology. *Journal of the American College of Cardiology*. 2014;64(19):2039-2060. doi:10.1016/j.jacc.2014.08.003.
4. Cannon B, Wackel P. Syncope. *Pediatrics in Review*. 2016;37(4):159-168. doi:10.1542/pir.2014-0109.
5. Allen HD, Shaddy RE, Penny DJ, Cetta F, Feltes TF. Moss and Adams' Heart Disease in Infants, Children, and Adolescents: Including the Fetus and Young Adult. 9th ed. Philadelphia, PA: Wolters Kluwer; 2016.
6. Shen W-K, Sheldon RS, Benditt DG, et al. 2017 ACC/AHA/HRS guideline for the evaluation and management of patients with syncope: a report of the American College of Cardiology/American Heart Association Task Force on Clinical Practice Guidelines and the Heart Rhythm Society. *Circulation*. 2017;136:e60–e122. DOI: 10.1161/CIR.0000000000000499.
7. Winder MM, Marietta J, Kerr LM, et al. Reducing Unnecessary Diagnostic Testing in Pediatric Syncope: A Quality Improvement Initiative. *Pediatr Cardiol*. 2021. doi:10.1007/s00246-021-02567-4.

Pediatric Pulmonary Hypertension General (PEDCD-7.1)

CDP.CS.0007.1.A

v1.0.2024

- Pulmonary hypertension in children can be caused by cardiac, pulmonary, or systemic diseases, and idiopathic disease occurs as well.
- Chest x-ray, EKG, and echocardiography (CPT® 93306, or CPT® 93303, with CPT® 93320, and CPT® 93325, see: **Transthoracic Echocardiography (TTE) Coding (PEDCD-8.1)** for echocardiography coding considerations) for initial evaluation if pulmonary hypertension is suspected.
- Repeat echocardiography intervals are variable depending on age of individual, etiology, and severity.
 - After a comprehensive initial evaluation, echocardiograms using PH-specific protocols may be performed every 4 to 6 months.
 - Echocardiography is indicated at any time for new or worsening symptoms or to evaluate a recent change in therapy.
 - Right heart and /or left heart catheterization may be utilized for PAH individuals, including before and after initiation of PAH-targeted therapy, and for individuals with concomitant congenital heart disease
- CT Chest (CPT® 71250) may be indicated in addition to CTA Chest (CPT® 71275) or MRA Chest (CPT® 71555) for initial evaluation of all pediatric individuals with pulmonary hypertension to evaluate for pulmonary vascular or interstitial disease, or other intrathoracic causes.
- Cardiac MRI without and with contrast (CPT® 75561) is indicated for evaluation of inconclusive echocardiogram findings, or for monitoring right ventricular function during follow-up.
- Stress echocardiograms may be indicated (as in the general cardiac imaging guidelines) see **Stress Echocardiography – Indications other than ruling out CAD (CD-2.7)** in the Cardiac Imaging Guidelines.

References

1. Abman SH, Hansmann G, Archer SL, et al. Pediatric Pulmonary Hypertension. *Circulation*. 2015;132(21):2037-2099. doi:10.1161/cir.0000000000000329.
2. Latus H, Kuehne T, Beerbaum P, et al. Cardiac MR and CT imaging in children with suspected or confirmed pulmonary hypertension/pulmonary hypertensive vascular disease. Expert consensus statement on the diagnosis and treatment of paediatric pulmonary hypertension. The European Paediatric Pulmonary Vascular Disease Network, endorsed by ISHLT and DGPK. *Heart*. 2016;102(Suppl 2):ii30-ii35. doi:10.1136/heartjnl-2015-308246.
3. Allen HD, Shaddy RE, Penny DJ, Cetta F, Feltes TF. Moss and Adams' Heart Disease in Infants, Children, and Adolescents: Including the Fetus and Young Adult. 9th ed. Philadelphia, PA: Wolters Kluwer; 2016.
4. Galiè N, Humbert M, Vachiery J-L, et al. 2015 ESC/ERS Guidelines for the diagnosis and treatment of pulmonary hypertension. *European Respiratory Journal*. 2015;46(4):903-975. doi:10.1183/13993003.01032-2015.

Evaluation of Pericardial Effusion or Diagnosis of Pericardial Tamponade (PEDCD-9.5)

CDP.CS.0009.5.A

v1.0.2024

- Echocardiogram is the initial imaging study of choice to evaluate pericardial effusions or diagnose pericardial tamponade.
- If a specific clinical question is left unanswered by another recent imaging study **and** the answer to the clinical question will affect the management of the individual's clinical condition, contrast-enhanced cardiac MRI is useful for evaluating:
 - Pericarditis
 - Neoplastic effusion
 - Tamponade
 - Myocardial infiltration
- Cancers that can metastasize to the pericardium or myocardium and can cause a malignant effusion include lung, breast, renal cell, lymphoma and melanoma.

References

1. Nelson Textbook of Pediatrics, 20th Edition, Robert M. Kliegman, MD, Bonita M.D. Stanton, MD, Joseph St. Geme, MD and Nina F Schor, MD, PhD, p2182 to p2292.
2. Atweh LA, Orth RC, Guillerman RP, Zhang W, Kan JH. MR imaging of children and young adults with classic findings of osteonecrosis on unenhanced MR images: do contrast-enhanced sequences help? *Pediatric Radiology*. 2013;43(11):1502-1506. doi:10.1007/s00247-013-2714-1.
3. Cohen MS, Eidem BW, Cetta F, et al. Multimodality Imaging Guidelines of Patients with Transposition of the Great Arteries: A Report from the American Society of Echocardiography Developed in Collaboration with the Society for Cardiovascular Magnetic Resonance and the Society of Cardiovascular Computed Tomography. *Journal of the American Society of Echocardiography*. 2016;29(7):571-621. doi:10.1016/j.echo.2016.04.002.
4. Adler Y, Charron P, Imazio M, et al. 2015 ESC Guidelines for the diagnosis and management of pericardial diseases. *European Heart Journal*. 2015;36(42):2921-2964. doi:10.1093/eurheartj/ehv318.
5. Allen HD, Shaddy RE, Penny DJ, et. al TF. Moss and Adams' Heart Disease in Infants, Children, and Adolescents: Including the Fetus and Young Adult. 9th ed. Philadelphia, PA: Wolters Kluwer; 2016.
6. Hundley WG, Bluemke DA, Finn JP, et al. ACCF/ACR/AHA/NASCI/SCMR 2010 Expert Consensus Document on Cardiovascular Magnetic Resonance. *Circulation*. 2010;121(22):2462-2508. doi:10.1161/cir.0b013e3181d44a8f.
7. Cohen MS, Eidem BW, Cetta F, et al. Multimodality Imaging Guidelines of Patients with Transposition of the Great Arteries: A Report from the American Society of Echocardiography Developed in Collaboration with the Society for Cardiovascular Magnetic Resonance and the Society of Cardiovascular Computed Tomography. *Journal of the American Society of Echocardiography*. 2016;29(7):571-621. doi:10.1016/j.echo.2016.04.002.
8. Valente AM, Cook S, Festa P, et al. Multimodality Imaging Guidelines for Patients with Repaired Tetralogy of Fallot: A Report from the American Society of Echocardiography. *Journal of the American Society of Echocardiography*. 2014;27(2):111-141. doi:10.1016/j.echo.2013.11.009.
9. Feingold B, Mahle WT, Auerbach S, et al. Management of Cardiac Involvement Associated With Neuromuscular Diseases: A Scientific Statement From the American Heart Association. *Circulation*. 2017;136(13). doi:10.1161/cir.0000000000000526.
10. Mah ML, Cripe L, Slawinski MK, et al. Duchenne and Becker muscular dystrophy carriers: Evidence of cardiomyopathy by exercise and cardiac MRI testing. *International Journal of Cardiology*. 2020;316:257-265. doi:10.1016/j.ijcard.2020.05.052.
11. Power LC, O'Grady GL, Hornung TS, Jefferies C, Gusso S, Hofman PL. Imaging the heart to detect cardiomyopathy in Duchenne muscular dystrophy: A review. *Neuromuscular Disorders*. 2018;28(9):717-730. doi:10.1016/j.nmd.2018.05.011.

12. Hor KN, Mah ML, Johnston P, Cripe TP, Cripe LH. Advances in the diagnosis and management of cardiomyopathy in Duchenne muscular dystrophy. *Neuromuscular Disorders*. 2018;28(9):711-716. doi:10.1016/j.nmd.2018.06.014.
13. Buddhe S, Cripe L, Friedland-Little J, et al. Cardiac Management of the Patient With Duchenne Muscular Dystrophy. *Pediatrics*. 2018;142(Supplement 2). doi:10.1542/peds.2018-0333i.
14. Birnkrant DJ, Bushby K, Bann CM, et al. Diagnosis and management of Duchenne muscular dystrophy, part 2: respiratory, cardiac, bone health, and orthopaedic management. *The Lancet Neurology*. 2018;17(4):347-361. doi:10.1016/s1474-4422(18)30025-5.

Kawasaki Disease (PEDCD-6)

CDP.CS.0006.A

v1.0.2024

Guideline

- Kawasaki Disease Initial Imaging (PEDCD-6.1)
- Kawasaki Disease - Acute Phase (PEDCD-6.2)
- Kawasaki Disease - Chronic Phase (PEDCD-6.3)

Kawasaki Disease Initial Imaging (PEDCD-6.1)

- Echocardiography (CPT® 93306) is indicated for initial assessment for suspected or known Kawasaki disease
 - Coronary CTA (CPT® 75574), Cardiac MRI without contrast (CPT® 75557), Cardiac MRI without and with contrast (CPT® 75561), or MRA Chest (CPT® 71555) are indicated for evaluation of inconclusive echocardiogram findings, or significant coronary artery abnormalities.
 - Screening of other body areas for aneurysms is not routinely indicated in Kawasaki disease, but MRA or CTA (contrast as requested) of the affected body area can be approved for evaluation of signs or symptoms suggesting aneurysm development.
 - See acute and chronic phase for imaging

Background and supporting information

- Kawasaki disease (KD) is the leading cause of acquired pediatric cardiac disease in the developed world. It is an acute febrile illness characterized by a medium vessel vasculitis, which predominantly affects the coronary arteries.
 - Individuals who do not fulfill the diagnostic criteria for classic KD may be considered to have incomplete (atypical) KD.
 - If Kawasaki disease is strongly suspected, treatment will often begin even before cardiac evaluation, since early treatment is associated with a lower risk for coronary aneurysm development.

Kawasaki Disease - Acute Phase (PEDCD-6.2)

- Echocardiography should be performed when the diagnosis of KD is considered
 - Uncomplicated individuals, echocardiography can be repeated after treatment **both**:
 - Within 1 to 2 weeks
 - Within 4 to 6 weeks
 - For individuals with important and evolving coronary artery abnormalities (Z score >2.5) detected during the acute illness, more frequent echocardiography

- (at least twice per week) should be performed until luminal dimensions have stopped progressing to determine the risk for and presence of thrombosis.
- Expanding large or giant aneurysms:
 - Twice per week while dimensions are expanding rapidly
 - Once weekly after dimension is stabilized for the first 45 days of illness
 - Then monthly until the third month after illness onset
- It is reasonable to obtain advanced imaging studies such as computed tomographic angiography (CTA), cardiac magnetic resonance imaging (CMRI), or invasive angiography on individuals' severe proximal coronary artery abnormalities in the acute phase when results will impact management decisions.
- Transesophageal echocardiography, invasive angiography, CMRI, and CTA can be of value in the assessment of selected individuals but are not routinely indicated for diagnosis and management of the acute illness.
 - Invasive angiography is rarely performed during the acute illness.
 - Transesophageal echocardiography, CTA, and CMRI can be useful for the evaluation of older children and adolescents when both:
 - Visualization of the coronary arteries with Transthoracic echocardiography (TTE) is inadequate and
 - Results will impact immediate management decisions.
- Evaluation of potential aneurysmal involvement in other arterial beds can be assessed with CMRI, CTA, and, rarely, invasive angiography after recovery from the acute illness for individuals with severe coronary artery involvement or symptoms or signs, such as the presence of a pulsatile axillary mass.
- Atypical or incomplete Kawasaki. Echo is indicated when atypical KD is being considered, may require repeat echocardiograms if treatment decisions will be affected by results (e.g., treating with IVIg), if new signs or symptoms (such as typical peeling) develop.

Background and supporting information

- The acute phase of Kawasaki disease (KD) can last up to 4-6 weeks from the onset of fever until acute systemic inflammation has resolved and coronary artery dimensions are no longer expanding
- Based on AHA recommendations, the following classifications are used in risk stratification of coronary artery abnormalities¹
 - Z-Score classification accounts for the effects of body size and age through use of baseline coronary dimensions adjusted for body surface area. The Z score value represents the number of standard deviation above the mean. (e.g., z=0 pt. has coronary artery dimension value equal to mean, z=2 person has value 2 standard deviation above the mean, based on age, gender, BSA).
 - Coronary Artery Abnormalities Risk Classification based on Z-Score:

¹ Mccrindle BW, Rowley AH, Newburger JW, et al. Diagnosis, Treatment, and Long-Term Management of Kawasaki Disease: A Scientific Statement for Health Professionals from the American Heart Association. *Circulation*. 2017;135(17). doi:10.1161/cir.0000000000000484.

- 1 - No involvement at any time point (Z score always <2)
- 2 - Dilation only (Z score 2 to <2.5)
- 3 - Small aneurysm (Z score ≥ 2.5 to <5)
 - 3.1 - Current or persistent
 - 3.2 - Decreased to dilation only or normal luminal dimension
- 4 - Medium aneurysm (Z score ≥ 5 to <10, and absolute dimension <8 mm)
 - 4.1 - Current or persistent
 - 4.2 - Decreased to small aneurysm
 - 4.3 - Decreased to dilation only or normal luminal dimension
- 5 - Large and giant aneurysm (Z score ≥ 10 , or absolute dimension ≥ 8 mm)
 - 5.1 - Current or persistent
 - 5.2 - Decreased to medium aneurysm
 - 5.3 - Decreased to small aneurysm
 - 5.4 - Decreased to dilation only or normal luminal dimension
- Additional clinical features that may increase the long-term risk of myocardial ischemia
 - Greater length and distal location of aneurysms that increase the risk of flow stasis
 - Greater total number of aneurysms
 - Greater number of branches affected
 - Presence of luminal irregularities
 - Abnormal characterization of the vessel walls (calcification, luminal myofibroblastic proliferation)
 - Presence of functional abnormalities (impaired vasodilation, impaired flow reserve)
 - Absence or poor quality of collateral vessels
 - Previous revascularization performed
 - Previous coronary artery thrombosis
 - Previous myocardial infarction
 - Presence of ventricular dysfunction

Kawasaki Disease - Chronic Phase (PEDCD-6.3)

- Long-term management begins at the end of the acute illness, usually at 4 to 6 weeks after fever onset. Management is based on two pieces of data:
 - The dimensions of the largest aneurysm at any point during the disease
 - The dimensions of the largest current aneurysm
- Additional risk factors that may be considered for imaging
 - Greater length and distal location of aneurysms that increase the risk of flow stasis
 - Greater total number of aneurysms
 - Greater number of branches affected

- Presence of luminal irregularities
- Abnormal characterization of the vessel wall (calcification, luminal myofibroblastic proliferation)
- Presence of functional abnormalities (impaired vasodilation, impaired flow reserve)
- Absence or poor quality of collateral vessels
- Previous revascularization performed
- Previous coronary artery thrombosis
- Previous myocardial infarction
- Presence of ventricular dysfunction
- Long term routine surveillance in asymptomatic imaging for Kawasaki disease-see chart

Long term routine surveillance in asymptomatic imaging for Kawasaki disease

AHA risk level	Largest Aneurysm At Any Point	Largest Current Aneurysm	Routine Echo	Routine Stress Imaging	Routine Coronary Imaging
All			All risk levels 4-6 weeks after acute illness		
1	Normal	Normal	One echo 2-12 months after acute illness	none	none
2	Dilation	Dilation	6 months One year If dilation remains echo every 2-5 years until resolves	None	None

AHA risk level	Largest Aneurysm At Any Point	Largest Current Aneurysm	Routine Echo	Routine Stress Imaging	Routine Coronary Imaging
		Normal	After acute illness: 2-12 months One echocardiogram at one year No echocardiogram after one year		
3.1	Small	Small	6 months 12 months then yearly	2-3 years	3-5 years
3.2	Small	Normal or dilated	6 months 12 months Then yearly	3-5 years	none
4.1	Medium	Medium	3 months 6 months 12 months Every 6-12 months after that	1-3 years	2-5 years
4.2	Medium	Small	6 months and 12 months, every 1 year	2-3 years	3-5 years
4.3	Medium	Normal Or Dilated	Every 1-2 years	2-4 years	none

AHA risk level	Largest Aneurysm At Any Point	Largest Current Aneurysm	Routine Echo	Routine Stress Imaging	Routine Coronary Imaging
5.1	Large	Large	1 month 3 months 6 months 9 months 12 months Then every 3-6 months	6-12 months	at 2-6 months, every 1-5 years
5.2	Large	Medium	Every 6-12 months	yearly	2-5 years
5.3	Large	Small	6-12 month	1-2 years	2-5 years
5.4	Large	Normal Or Dilation	1-2 years	2-5 years	none

Symptomatic individuals

- Echocardiogram can be performed at any time with new or progressing cardiac symptoms
- Stress imaging when there are new or progressing symptoms of ischemia or ventricular dysfunction
- Invasive or coronary imaging Coronary angiography (CT, MRI, invasive) when the above studies are positive, inconclusive, or otherwise lead to a conclusion that intervention is needed

***Adapted from: Mccrindle BW, Rowley AH, Newburger JW, et al. Diagnosis, Treatment, and Long-Term Management of Kawasaki Disease: A Scientific Statement for Health Professionals from the American Heart Association. Circulation. 2017;135(17). doi:10.1161/cir.0000000000000484*

References

1. Kliegman R, Nelson WE. *Nelson Textbook of Pediatrics*. 20th ed. Philadelphia, PA: Elsevier; 2016.
2. Son MBF, Newburger JW. Kawasaki Disease. *Pediatrics in Review*. 2013;34(4):151-162. doi:10.1542/pir.34-4-151.
3. Campbell RM, Douglas PS, Eidem BW, Lai WW, Lopez L, Sachdeva R. ACC/AAP/AHA/ASE/HRS/SCAI/SCCT/SCMR/SOPE 2014 Appropriate Use Criteria for Initial Transthoracic Echocardiography in Outpatient Pediatric Cardiology. *Journal of the American College of Cardiology*. 2014; 64(19):2039-2060. doi:10.1016/j.jacc.2014.08.003.
4. Mccrindle BW, Rowley AH, Newburger JW, et al. Diagnosis, Treatment, and Long-Term Management of Kawasaki Disease: A Scientific Statement for Health Professionals from the American Heart Association. *Circulation*. 2017; 135(17). doi:10.1161/cir.0000000000000484.

5. Mccrindle BW, Rowley AH, Newburger JW, et al. Diagnosis, Treatment, and Long-Term Management of Kawasaki Disease: A Scientific Statement for Health Professionals from the American Heart Association. *Circulation*. 2017;135(17). doi:10.1161/cir.0000000000000484.

Echocardiography

Guideline

- Transthoracic Echocardiography (TTE) Coding (PEDCD-8.1)
- Initial Transthoracic Echocardiography (TTE) Indications (PEDCD-8.2)
- Repeat Transthoracic Echocardiography Indications (PEDCD-8.3)
- Transesophageal Echocardiography (TEE) (PEDCD-8.4)
- Fetal Echo (PEDCD-8.5)
- References (PEDCD-8)

Transthoracic Echocardiography (TTE) Coding (PEDCD-8.1)

CDP.000.8.2.A
v1.0.2024

- CPT® codes for echocardiography are listed in **General Guidelines (PEDCD-1)**

Echocardiogram coding notes	CPT®
<ul style="list-style-type: none"> • The most commonly performed study is a complete transthoracic echocardiogram with spectral and color flow Doppler (CPT® 93306). <ul style="list-style-type: none"> • CPT® 93306 includes CPT® 93320 and CPT® 93325, so those codes should not be approved along with CPT® 93306. 	93306
<ul style="list-style-type: none"> • Doppler codes (CPT® 93320, CPT® 93321, and CPT® 93325) are add-on codes and are assigned in addition to code for the primary procedure, and should not be approved alone. 	+93320 +93321 +93325
<ul style="list-style-type: none"> • For a 2D transthoracic echocardiogram without Doppler, report CPT® 93307. 	93307
<ul style="list-style-type: none"> • A limited transthoracic echocardiogram is reported with CPT® 93308. <ul style="list-style-type: none"> • Limited transthoracic echocardiogram should be billed if the report does not “evaluate or document the attempt to evaluate” all of the required structures. • Unlike CPT® 93306, the Doppler CPT® 93321 and CPT® 93325 are not included with CPT® 93308. • CPT® 93321 (not CPT® 93320) should be reported with CPT® 93308 if Doppler is included in the study. • CPT® 93325 should also be reported with CPT® 93308 if color flow Doppler is included in the study. 	93308
<ul style="list-style-type: none"> • For individuals with known congenital heart disease, a limited transthoracic echocardiogram is reported with CPT® 93304, +/- CPT® 93321 and CPT® 93325. 	93304

- Providers performing an **initial** echo on a pediatric individual will not know what procedure codes they will be reporting until the initial study is completed.
 - If congenital heart disease is found on the initial echo, a complete echo is reported with codes CPT® 93303, CPT® 93320, and CPT® 93325 because CPT® 93303 does NOT include Doppler and color flow mapping.
 - If no congenital issue is discovered, then CPT® 93306 is reported alone and includes 2-D, Doppler and color flow mapping.
- Since providers may not know the appropriate code/s that will be reported at the time of the pre-authorization request, they may request multiple codes.

- The following echocardiography code combinations for any **initial** echocardiogram:
 - CPT® 93303, CPT® 93306, CPT® 93320, and CPT® 93325
 - CPT® 93303, CPT® 93306
 - CPT® 93306
 - CPT® 93320 and CPT® 93325 are included with CPT® 93306 and should not be approved separately.
- Post-service audits may be completed to ensure proper claims submission.
- Correct coding for subsequent echocardiograms
 - If an individual is being followed for known congenital heart disease, and an echocardiogram is indicated, the appropriate codes are (CPT® 93303 or 93304) in addition to appropriate doppler codes(CPT® 93320 or 93321) and CPT® 93325
 - If an individual has documented normal anatomy, or acquired heart disease, and an echocardiogram is indicated, non-congenital codes are appropriate CPT® 93306 (includes all Doppler codes) or CPT® 93308 with CPT® 93321 and CPT® 93325
 - For individuals with newborn physiology (e.g., ASD versus PFO, or PDA) the final echocardiogram that documents normal anatomy can be coded as congenital. However, any subsequent echocardiograms after that, which would be completed for a new indication, (e.g., shortness of breath) would be coded as non-congenital

Initial Transthoracic Echocardiography (TTE) Indications (PEDCD-8.2)

CDP.000.8.2.A

v1.0.2024

- In addition to indications listed in previous guideline sections, initial TTE evaluation is indicated for any of the following:
 - Any signs/symptoms that are possibly cardiac in nature, including (but not limited to) central cyanosis, dyspnea, edema, poor peripheral pulses, feeding difficulty, decreased urine output, hepatomegaly, or desaturation on pulse oximetry.
 - Abnormal EKG or cardiac biomarkers
 - Abnormal chest x-ray suggesting cardiovascular disease
 - First-degree relative with any of the following before age 50:
 - Sudden cardiac arrest or death
 - Pacemaker or implantable defibrillator placement
 - First-degree relative with cardiomyopathy
 - Supraventricular Tachycardia (SVT), Ventricular Tachycardia, or Premature Ventricular Contractions (PVCs)
 - Known or suspected valvular dysfunction
 - Persistent systemic hypertension
 - Individuals with new onset hypertension
 - TTE indicated to assess for cardiac target organ damage (LV mass, geometry, and function) at the time of consideration of pharmacologic treatment of systemic hypertension
 - Obesity (BMI >30) with additional cardiovascular risk factors
 - Stroke
 - Renal failure
 - Preoperative evaluation of individuals with chest wall deformities or scoliosis
 - Known or suspected vascular ring
 - Planned administration of cardiotoxic chemotherapy
 - Generally anthracyclines (doxorubicin, daunorubicin, mitoxantrone, idarubicin, epirubicin)
 - Planned radiation therapy involving heart muscle or hematopoietic stem cell transplant
 - Sickle cell disease or other hemoglobinopathy causing chronic anemia
 - Known or suspected vasculitis, acute rheumatic fever, or other systemic autoimmune disease
 - Aortopathy (such as Marfan, Ehlers-Danlos, Loeys-Dietz)
 - Positive personal diagnosis

- First degree relative
- Positive gene
- Finding suggestive of aortopathy such as x-ray showing aortic dilation
- Muscular dystrophy
 - Positive personal diagnosis
 - First degree relative
 - Positive gene
 - Any findings suggestive of MD, such as neurological exam
- Cardiomyopathy
 - Diagnosed by other modality (such as cardiac MR)
 - First degree relative
 - Positive genetic testing
 - Findings suggestive of, such as cardiomegaly on x-ray
- Metabolic, mitochondrial, and storage disorders
 - Positive personal diagnosis
 - First degree relative
 - Positive genetic testing
 - Findings suggestive of on exam or lab findings
- Abnormalities of cardiac or other viscera situs
- Signs, symptoms, or blood culture suggestive of endocarditis
- Known or suspected mass lesion involving the heart or great vessels
- Known or suspected clot in atrium or ventricle
- Known or suspected pulmonary hypertension
- Known or suspected pericardial effusion
- Complications during prenatal development:
 - Known or suspected cardiovascular abnormality on fetal echocardiogram
 - Maternal phenylketonuria (PKU)
 - Maternal diabetes with no fetal echo
 - Maternal teratogen exposure
 - Maternal infection during pregnancy with potential cardiac sequelae
- Genetic abnormality known to be associated with cardiovascular disease such as
 - Down syndrome
 - Turner syndrome
 - 22q11 deletion syndrome
 - Williams syndrome
 - Noonan syndrome
- First-degree relative family history of:
 - Unexplained sudden death before age 50
 - Hypertrophic cardiomyopathy

- Non-ischemic dilated cardiomyopathy
- Genetic abnormality known to be associated with cardiovascular disease
- Congenital left-sided heart lesion
- Heritable pulmonary arterial hypertension

Repeat Transthoracic Echocardiography Indications (PEDCD-8.3)

CDP.EC.0008.3.A

v1.0.2024

- Repeat echocardiograms may be required for individuals with no new symptoms.
- In addition to indications listed in previous guideline sections, repeat TTE evaluation is indicated for any of the following:
 - In an individual with known cardiac disease and a previously normal echocardiogram when there is documentation of any of the following:
 - New or worsening cardiac symptoms
 - New EKG abnormality
 - Newly recognized family history suggestive of heritable heart disease
 - In an individual with prior normal evaluation
 - New or worsening symptoms
 - New EKG finding
 - New murmur
 - New finding of inheritable disease in first-degree relative
 - Individuals with first-degree family history of cardiomyopathy (such as, hypertrophic, dilated, arrhythmogenic) or aortopathy.
 - Repeat echo every 12 months
 - Repeat echo can be done at the additional intervals when the family history or gene mutation is associated with neonatal or fetal disease:
 - At birth
 - Within the first 6 weeks
 - At 3 months
 - At 6 months
 - At one year
 - Then yearly
 - Repeat imaging is **not** indicated in individuals with first degree relative with known mutation when **both** of the following apply:
 - Individual has been tested and does not have that mutation
 - Individual has a normal echocardiogram
 - If there are abnormal findings on screening/surveillance imaging, a repeat echo is allowed to assess stability of findings
 - Individual with a phenotype positive cardiomyopathy (with or without a positive gene) can be imaged as follows:
 - Infants (under one year)

- TTE is indicated at frequency requested by pediatric cardiology or provider in consultation with pediatric cardiology
- Children (over one year) yearly testing is indicated as follows:
 - Repeat TTE every 12 months
 - Repeat TTE to assess stability at discretion of pediatric cardiology, or provider in consultation with pediatric cardiology, after any new or changed clinical finding.
 - TTE at any time with documented new or changing symptoms.
- Individual with a known mutation associated with cardiomyopathy or aortopathy and no previous abnormal imaging
 - Repeat echo every 12 months
 - Individuals whose gene mutation is associated with neonatal or fetal disease or there is a family history of neonatal or fetal disease can have repeat echo at the following intervals:
 - At birth
 - Within the first 6 weeks
 - Then at 3 months
 - At 6 months
 - At one year
 - Then yearly
 - If there are abnormal findings on screening/surveillance imaging, a repeat echo is allowed to assess stability of findings.
 - Individuals who are status post heart transplant can have echocardiograms repeated as often as requested by heart transplant team.
 - Every 12 months for individuals receiving active therapy for ventricular hypertrophy, valvular dysfunction, cardiomyopathy
 - One time repeat TTE can be approved at 6 months to assess response to a change in therapy
 - Every 12 months for individuals with chronic pericardial effusions
 - Every 12 months routine surveillance in asymptomatic individuals with muscular dystrophy (may be replaced by cardiac MRI CPT® 75557 or 75561 at 6 years of life)
 - Every 12 months for sickle cell disease or other hemoglobinopathy causing chronic anemia and one of the following:
 - High-risk genotype (Hgb SS or Sβ⁰, severe thalassemia, etc.)
 - History of acute chest syndrome or intrinsic lung disease
 - History of stroke
 - Receiving chronic transfusion therapy
 - As needed for monitoring cardiotoxicity during chemotherapy administration
 - After completion of chemotherapy and/or radiation therapy. See **Cardiotoxicity and Echocardiography (PEDONC-19.2)** for imaging guidelines.

- Aortopathies- see **Thoracic Aortic Disease (PEDPVD-4.1)** in the Pediatric Peripheral Vascular Disease Imaging Guidelines
- TTE follow-up for systemic hypertension
 - Individuals with evidence of end organ damage (Includes LVH, or decreased EF) can have echo every 6 months until echocardiogram normalizes.
 - Individuals without LV target organ injury (no LVH, normal EF) at initial echocardiographic assessment, repeat echocardiography at yearly intervals may be considered in those with persistent hypertension. (stage 2 HTN, or chronic stage 1 HTN incompletely treated (noncompliance or drug resistance))

Transesophageal Echocardiography (TEE) (PEDCD-8.4)

CDP.EC.0008.4.A

v1.0.2024

- Transesophageal echocardiography imaging indications in pediatric individuals are identical to those for adult individuals. See [Transesophageal Echocardiography \(TEE\) – Indications \(CD-2.5\)](#) in the Cardiac Imaging Guidelines.

Fetal Echo (PEDCD-8.5)

CDP.EC.0008.5.A

v1.0.2024

Fetal Echocardiography - coding

- Supported fetal echocardiography (echo) codes include:
 - Initial Fetal Echo, CPT® 76825 and Doppler Echo CPT® 76827 are performed only once per fetus/per facility (i.e. Maternal Fetal Medicine versus Pediatric Cardiology request)
 - Follow-up-Fetal echo and/or Follow-up Doppler echo (CPT® 76826/CPT® 76828)
 - CPT® 93325 for Doppler color flow velocity mapping
- An initial fetal echo is usually not performed prior to 16 weeks.
- Doppler echo procedure codes (CPT® 76827 or CPT® 76828) include the evaluation of veins, arteries, and valves. Guidelines do not support the billing of additional codes (CPT® 76820 and/or CPT® 76821)

Background and Supporting Information

- The minimal use of color Doppler (CPT® 93325) alone, when performed for anatomical structure identification during a standard ultrasound procedure, is not separately reimbursable

Fetal Echocardiography - Indications for Fetal Conditions

Initial Fetal echocardiography (CPT® 76825) and/or Doppler echocardiography (CPT® 76827) with or without Doppler color flow velocity mapping (CPT® 93325) can be performed if ≥16 weeks, for the indications listed below (See **Fetal Echocardiography – Coding (OB-12.1)**):

Fetal Echocardiography - Indications for Fetal Conditions

- Known or suspected abnormal fetal cardiac evaluation on fetal anatomic scan.
 - Known or suspected abnormality must be documented as hard copy or acknowledged verbally by provider of known or suspected fetal cardiac evaluation
 - Suboptimal cardiac evaluation alone is not an indication for fetal echogram. If the 4-chamber view is adequate and there is no other suspicion of a cardiac abnormality, a fetal echocardiogram is not considered medically necessary. A follow up ultrasound (CPT® 76815 or CPT® 76816) is indicated for suboptimal visualization. If the follow-up ultrasound fails to show a 4-chamber view or there is suspicion of a cardiac abnormality, fetal echocardiogram is indicated.
- Fetal cardiac arrhythmia; persistent fetal tachycardia or bradycardia

Fetal Echocardiography - Indications for Fetal Conditions

- Major fetal extra-cardiac anomaly
- Fetal Echo is NOT indicated for an isolated soft marker found on routine imaging including:
 - Choroid plexus cyst, or
 - Echogenic intra-cardiac foci, or
 - Thickened nuchal fold (≥ 6 mm at 15 to 20 weeks), or
 - Absent or hypoplastic nasal bone, or
 - Echogenic bowel, or
 - Shortened long bones, or
 - Pyelectasis
- Congenital heart disease (CHD) in a 1st degree relative of the fetus (i.e. CHD in the mother, father, or sibling of the fetus) or a half-sibling of the fetus
- Known fetal chromosomal abnormalities (fetal aneuploidy) or ultrasound findings of a suspected chromosomal abnormality (excluding soft markers as only ultrasound findings)
 - Early onset FGR (<32 weeks) may be a sign of fetal aneuploidy^{11,12}
- Single umbilical artery
- Chorioangioma or Umbilical cord varix (if suspicion of fetal hydrops)
- Fetal intra-abdominal venous anomaly (persistent right umbilical vein)
- Fetal effusion (pericardial, pleural effusion, ascites, etc.)
- Fetal hydrops, See **Alloimmunization/Rh Isoimmunization/Other Causes of Fetal Anemia/Parvo/Hydrops (OB-16)**
- Monochorionic twins/TTTS
- Abnormal Fetal Nuchal Translucency scan (NT ≥ 3.0 mm or above the 95th percentile for the CRL) during current pregnancy.
- Abnormal ductus venosus waveform⁵
- Fetal echocardiography may be indicated with severe or unexplained polyhydramnios, or if there are also other suspicious findings on an anatomy scan

Fetal Echocardiography - Indications for Maternal Conditions

Initial Fetal echocardiography (CPT® 76825) and/or Doppler echocardiography (CPT® 76827) with or without Doppler color flow velocity mapping (CPT® 93325) can be performed if ≥ 16 weeks, for the indications listed below (See **Fetal Echocardiography – Coding (OB-12.1)**):

Maternal Conditions:

- Maternal pre-gestational DM or early diagnosed GDM (1st or early 2nd trimester)
- Maternal gestational diabetes mellitus, if HbA1C >6% [in the third trimester (≥32 weeks)]
- Maternal connective tissue disease (SLE, RA, Sjogrens) with Anti-Ro/SSA or anti-La/SSB antibodies present
 - Weekly follow-up Fetal echocardiography (CPT® 76826) and/or Doppler fetal echocardiography (CPT® 76828) or CPT® 76815 from the 18th through the 26th week of pregnancy and then every other week until 30 weeks
- Phenylketonuria
- Infections associated with cardiac anomalies (such as parvovirus, Rubella, Coxsackie virus)
- Genetic conditions associated with CHD in a first degree relative of the fetus (e.g. Marfan syndrome, 22q11.2 deletion syndrome (DiGeorge Syndrome) or Noonan syndrome)
- Prior child with CHD born to mother and/or father of the fetus⁵
- Pregnancy conceived by assisted reproductive technology:¹
 - In Vitro Fertilization (IVF)
 - Intracytoplasmic sperm injection (ICSI)¹

Background and supporting information

If diabetes is diagnosed prior to pregnancy or in the first or early second trimester (typically before 20 weeks gestation) with standard diagnostic criteria of: HbA1C ≥6.5%, fasting plasma glucose ≥126 mg/dL, or 2-hour glucose ≥200 mg/dL on a 75-g oral glucose tolerance test, then image as above

For those with GDM on medication, if HbA1c levels are >6%, fetal echocardiogram in the third trimester to assess for ventricular hypertrophy can be performed.

In cases of extreme obesity (BMI≥40-50) where the 4-chamber view is inadequately documented after 2 separate ultrasound visits with MFM, fetal echo can be performed.

With positive SSA/SSB antibodies, the most vulnerable period for the fetus is during the period from 18 to 24 weeks gestation. Normal sinus rhythm can progress to complete block in seven days during this high-risk period. New onset of heart block is less likely during the 26th through the 30th week, and it rarely develops after 30 weeks of pregnancy.

Fetal Echocardiography - Indications for Medication or Drug Exposure

Initial Fetal echocardiography (CPT® 76825) and/or Doppler echocardiography (CPT® 76827) with or without Doppler color flow velocity mapping (CPT® 93325) can be performed if ≥16 weeks, for the indications listed below (See **Fetal Echocardiography – Coding (OB-12.1)**):

- Ace inhibitors
- Alcohol (excessive quantities)
- Anti-seizure medication, e.g. carbamazepine, hydantoin, valproate
- Folate antagonists (methotrexate)
- Lithium
- NSAIDS (Ibuprofen, Indomethacin) 2nd and 3rd trimester
- Paroxetine (Paxil)
- Retinoids (e.g Isotretinoin, Retinoic acid, Vitamin A -over 10,000 IU per day, etc.)
- Thalidomide
- Venlafaxine (Effexor)
- This may not be an all-inclusive list, however, exposure to other potential teratogens associated with cardiac anomalies in the fetus are typically adequately assessed with a detailed fetal anatomy ultrasound. (CPT® 76811) (See **Potentially Teratogenic Medications/Substances (OB 10.1)**)

References (PEDCD-8)

v1.0.2024

1. Campbell RM, Douglas PS, Eidem BW, Lai WW, Lopez L, Sachdeva R. ACC/AAP/AHA/ASE/HRS/SCAI/SCCT/SCMR/SOPE 2014 Appropriate Use Criteria for Initial Transthoracic Echocardiography in Outpatient Pediatric Cardiology. *J Am Coll Cardiol*. 2014;64(19):2039-2060. doi:10.1016/j.jacc.2014.08.003.
2. Ambrusko SJ, Gunawardena S, Sakara A, et al. Elevation of tricuspid regurgitant jet velocity, a marker for pulmonary hypertension in children with sickle cell disease. *Pediatric Blood & Cancer*. 2006;47(7):907-913. doi:10.1002/pbc.20791.
3. Klings ES, Machado RF, Barst RJ, et al. An Official American Thoracic Society Clinical Practice Guideline: Diagnosis, Risk Stratification, and Management of Pulmonary Hypertension of Sickle Cell Disease. *American Journal of Respiratory and Critical Care Medicine*. 2014;189(6):727-740. doi:10.1164/rccm.201401-0065st.
4. Evidence-Based Management of Sickle Cell Disease: Expert Panel Report, 2014. *Pediatrics*. 2014;134(6). doi:10.1542/peds.2014-2986.
5. Allen HD, Shaddy RE, Penny DJ, Cetta F, Feltes TF. Moss and Adams' Heart Disease in Infants, Children, and Adolescents: Including the Fetus and Young Adult. 9th ed. Philadelphia, PA: Wolters Kluwer; 2016.
6. Flynn JT, Kaelber DC, Baker-Smith CM, et al. Clinical Practice Guideline for Screening and Management of High Blood Pressure in Children and Adolescents. *Pediatrics*. 2017;140(3). doi:10.1542/peds.2017-1904.
7. Sweet M, Taylor MR, Mestroni L. Diagnosis, prevalence, and screening of familial dilated cardiomyopathy. *Expert Opin Orphan Drugs*. 2015;3(8):869-876. doi:10.1517/21678707.2015.1057498.
8. TeRiele, Anneline, James, Cynthia, Approach to family screening in arrhythmogenic right ventricular dysplasia/ Cardiomyopathy. *European Heart Journal* (2016) 37, 755-763 doi:10.1093/eurheartj/ehv387.
9. Ommen SR, Mital S, Burke MA, et al. 2020 AHA/ACC Guideline for the Diagnosis and Treatment of Patients With Hypertrophic Cardiomyopathy: A Report of the American College of Cardiology/American Heart Association Joint Committee on Clinical Practice Guidelines. *J Am Coll Cardiol*. 2020;76(25):e159-e240. doi:10.1016/j.jacc.2020.08.045.

References (Fetal echo)

1. Donofrio MT, Moon-Grady AJ, Hornberger LK, et al. Diagnosis and Treatment of Fetal Cardiac Disease. *Circulation*. 2014;129(21):2183-2242. doi:10.1161/01.cir.0000437597.44550.5d
2. Brucato A. Prevention of congenital heart block in children of SSA-positive mothers. *Rheumatology*. 2008;47(Supplement 3):iii35-iii37. doi:10.1093/rheumatology/ken153
3. McBride KL, Garg V. Impact of Mendelian inheritance in cardiovascular disease. *Annals of the New York Academy of Sciences*. 2010;1214(1):122-137. doi:10.1111/j.1749-6632.2010.05791.x
4. Reddy UM, Abuhamad AZ, Levine D, et al. Fetal imaging: executive summary of a joint Eunice Kennedy Shriver National Institute Child Health and Human Development, Society for Maternal-Fetal Medicine, American Institute of Ultrasound in Medicine, American College of Obstetricians and Gynecologists, American College of Radiology, Society of Pediatric Radiology, and Society of Radiologists in Ultrasound Fetal Imaging Workshop. *Obstet Gynecol Survey*. 2014;69(8):453-455
5. Lee W, Allan L, Carvalho JS, et al. ISUOG consensus statement: what constitutes a fetal echocardiogram? *Ultrasound in Obstetrics and Gynecology*. 2008;32(2):239-242. doi:10.1002/uog.6115
6. Friedman DM, Kim MY, Copel JA, et al. Utility of Cardiac Monitoring in Fetuses at Risk for Congenital Heart Block. The PR Interval and Dexamethasone Evaluation (PRIDE) Prospective Study. *Circulation*. 2008;117(4):485-493. doi:10.1161/circulationaha.107.707661
7. AIUM Practice Parameter for the Performance of Fetal Echocardiography. *Journal of Ultrasound in Medicine*. 2019;39(1). doi:10.1002/jum.15188
8. Sammaritano LR, Bermas BL, Chakravarty EE, et al. 2020 American College of Rheumatology Guideline for the Management of Reproductive Health in Rheumatic and Musculoskeletal Diseases. *Arthritis Care & Research*. 2020;72(4):461-488. doi:10.1002/acr.24130
9. Jenkins KJ, Correa A, Feinstein JA, et al. Noninherited Risk Factors and Congenital Cardiovascular Defects: Current Knowledge. *Circulation*. 2007;115(23):2995-3014. doi:10.1161/circulationaha.106.183216
10. Anderson KN, Lind JN, Simeone RM, Bobo WV, Mitchell AA, Riehle-Colarusso T, Polen KN, Reefhuis. Maternal Use of Specific Antidepressant Medications During Early Pregnancy and the Risk of Selected Birth Defects. *JAMA Psychiatry*. 2020 Aug 5;77(12):1246-55. doi: 10.1001/jamapsychiatry.2020.2453
11. ACOG Practice Bulletin No. 227: Fetal Growth Restriction. *Obstet Gynecol*. 2021;137(2):e16-e28 doi: 10.1097/AOG.0000000000004251
12. Martins JG, Biggio, JR, Abuhamad, A. Society for Maternal-Fetal Medicine (SMFM) Consult Series #52: Diagnosis and Management of Fetal Growth Restriction. 2020 doi:10.1016/j.ajog.2015.01.059

13. Turan S, Asoglu MR, Ozdemir H, Seger L, Turan OM. Accuracy of the Standardized Early Fetal Heart Assessment in Excluding Major Congenital Heart Defects in High-Risk Population: A Single-Center Experience. J Ultrasound Med. 2022 Apr;41(4):961-969. doi: 10.1002/jum.15782. Epub 2021 Jul 20.

Computed Tomography

Guideline

CT Heart and Coronary Computed Tomography Angiography (CCTA)

General Considerations (PEDCD-10.1)

Indications for CCTA (CPT® 75574) (PEDCD-10.3)

Indications for Cardiac CT (CPT® 75572) (PEDCD-10.4)

Indications for Chest CTA with Cardiac CT or CTA (PEDCD-10.5)

References (PEDCD-10)

CT Heart and Coronary Computed Tomography Angiography (CCTA) General Considerations (PEDCD-10.1)

CDP.CT.0010.1.A

v1.0.2024

- Metal artifact reduces the accuracy of CCTA. Devices that can cause this issue include but are not limited to:
 - Surgical clips
 - Pacemaker devices
 - Defibrillator devices
 - Tissue expanders
- Cardiac testing that does not involve exposure to ionizing radiation should be strongly considered.

Radiation Dose (PEDCD-10.2)

- ACR–NASCI–SPR Practice Parameter for the Performance and Interpretation of Cardiac Computed Tomography (CT) states “Cardiac CT should be performed only for a valid medical indication and with the minimum radiation exposure that provides diagnostic image quality”
- ACR–NASCI–SPR Practice Parameter for the Performance of Quantification of Cardiovascular Computed Tomography (Ct) And Magnetic Resonance Imaging (MRI) states, “In younger patients, MRI may be the preferred modality, particularly when functional assessment with CT would require retrospective ECG gating and relatively high radiation doses. Further, the use of time-resolved MRA and phase contrast MRI methods offer significant advantages whose relative importance will depend on the specific application”
 - See table: Practice Estimate of Effective Radiation Dose chart for Selected Imaging Studies in **General Guidelines (CD-1)** in the general Cardiac Imaging Guidelines

Indications for CCTA (CPT® 75574) (PEDCD-10.3)

CDP.CT.0010.3.A

v1.0.2024

- In addition to indications listed in previous guideline sections, CCTA is indicated for any of the following, when a recent TTE and/or MRI is inconclusive:
 - Persistent exertional chest pain and normal stress test
 - Full sibling(s) with history of sudden death syndrome before age 30 or with documented anomalous coronary artery
 - Resuscitated sudden death and contraindication to conventional coronary angiography
 - Unexplained new onset of heart failure if CCTA will replace conventional invasive coronary angiography
 - Documented ventricular tachycardia (6 beat runs or greater) if CCTA will replace conventional invasive coronary angiography
 - Equivocal coronary artery anatomy on conventional cardiac catheterization
 - In infants: otherwise unexplained dyspnea, tachypnea, wheezing, episodic pallor, irritability, sweating, poor feeding, and/or failure to thrive
 - The presence of other congenital heart disease is not a separate indication for CCTA to rule out anomalous coronary artery (except when coronary artery surgery is pending, i.e., Transposition of the great arteries, Tetralogy of Fallot, Truncus arteriosus, aortic root surgery)
 - Evaluation of the arterial supply and venous drainage in children with bronchopulmonary sequestration
- See **Coronary Anomalies (PEDCD-2.4.12)**

Indications for Cardiac CT (CPT® 75572) (PEDCD-10.4)

CDP.CT.0010.4.A

v1.0.2024

- In addition to indications listed in previous guideline sections, CCT is indicated for any of the following, when a recent TTE and/or MRI is inconclusive:
 - Cardiac or pericardial mass
 - Pericarditis
 - Complications of cardiac surgery or evaluation of post-operative anatomy
 - Cardiac thrombus in individuals with technically limited TTE, TEE, or MRI
 - Clinical suspicion of arrhythmogenic right ventricular dysplasia (ARVD) or arrhythmogenic cardiomyopathy (ARVC)
 - Native aortic abnormalities if echocardiogram is indeterminate
 - Intracardiac anatomy unclear after TTE or CMRI
 - A CTA Chest may also be indicated during a Cardiac CT if there are issues regarding the chest vessels that are inconclusive after echocardiogram or Cardiac MRI

Indications for Chest CTA with Cardiac CT or CTA (PEDCD-10.5)

CDP.CT.0010.5.A

v1.0.2024

- A Chest CTA may be indicated in individuals who require Cardiac CT or Cardiac CTA when:
 - A TTE or MRI is inconclusive for issues regarding chest vasculature
 - Routine imaging is indicated based on **Imaging and Surveillance per Congenital lesion (PEDCD-2.4)**

References (PEDCD-10)

v1.0.2024

1. Nelson Textbook of Pediatrics, 20th Edition, Robert M. Kliegman, MD, Bonita M.D. Stanton, MD, Joseph St. Geme, MD and Nina F Schor, MD, PhD p2182 to p2292.
2. American College of Radiology. ACR–ASER–SCBT–MR–SPR Practice Parameter for the Performance of Pediatric Computed Tomography (CT). American College of Radiology | Practice Parameters by Modality: <https://www.acr.org/Clinical-Resources/Practice-Parameters-and-Technical-Standards/Practice-Parameters-by-Modality>. Published 2014.
3. American College of Radiology. ACR–NASCI–SPR Practice Parameter for the Performance of Quantification of Cardiovascular Computed Tomography (CT) and Magnetic Resonance Imaging (MRI). American College of Radiology | Practice Parameters by Modality. <https://www.acr.org/-/media/ACR/Files/Practice-Parameters/Quant-CardiacCT-MR.pdf>. Published 2017.
4. Einstein AJ, Henzlova MJ, and Rajagopalan S. Estimating risk of cancer associated with radiation exposure from 64-slice computer tomography coronary angiography. *JAMA*. 2007;298(3):317-323.
5. Baumgartner H, Bonhoeffer P, Groot NMSD, et al. ESC Guidelines for the management of grown-up congenital heart disease (new version 2010): The Task Force on the Management of Grown-up Congenital Heart Disease of the European Society of Cardiology (ESC). *European Heart Journal*. 2010;31(23):2915-2957. doi:10.1093/eurheartj/ehq249.
6. Bhatt AB, Foster E, Kuehl K, et al. Congenital Heart Disease in the Older Adult. *Circulation*. 2015;131(21):1884-1931. doi:10.1161/cir.0000000000000204.
7. Feltes TF, Bacha E, Beekman RH, et al. Indications for Cardiac Catheterization and Intervention in Pediatric Cardiac Disease: A Scientific Statement from the American Heart Association. *Circulation*. 2011;123(22):2607-2652. doi:10.1161/cir.0b013e31821b1f10.
8. Warnes CA, Williams RG, Bashore TM, et al. ACC/AHA 2008 Guidelines for the Management of Adults with Congenital Heart Disease. *Circulation*. 2008;118(23). doi:10.1161/circulationaha.108.190690.
9. Cifra B, Dragulescu A, Border WL, Mertens L. Stress echocardiography in paediatric cardiology. *European Heart Journal – Cardiovascular Imaging*. 2015;16(10):1051-1059. doi:10.1093/ehjci/jev159.
10. Allen HD, Shaddy RE, Penny DJ, Cetta F, Feltes TF. Moss and Adams' Heart Disease in Infants, Children, and Adolescents: Including the Fetus and Young Adult. 9th ed. Philadelphia, PA: Wolters Kluwer; 2016. American College of Radiology. ACR–NASCI–SPR Practice Parameter for the Performance and Interpretation of Cardiac Computed Tomography (CT). American College of Radiology | American College of Radiology. <https://www.acr.org/Clinical-Resources/Practice-Parameters-and-Technical-Standards/Practice-Parameters-by-Modality>. Published 2017.
11. American College of Radiology. Practice Parameters by Modality: ACR–NASCI–SPR Practice Parameter for the Performance and Interpretation of Cardiac Computed Tomography (CT). American College of Radiology | American College of Radiology. <https://www.acr.org/Clinical-Resources/Practice-Parameters-and-Technical-Standards/Practice-Parameters-by-Modality>. Published 2016.

Magnetic Resonance Imaging

Guideline

Cardiac MRI Coding (PEDCD-9.2)

Indications for Cardiac MRI (PEDCD-9.3)

Indications for Chest MRA for Congenital heart disease (PEDCD-9.4)

References (PEDCD-9)

Cardiac MRI Coding (PEDCD-9.2)

CDP.MR.0009.2.A

v1.0.2024

Cardiac Imaging Procedure Codes	
Cardiac MRI	CPT®
Cardiac magnetic resonance imaging for morphology and function without contrast.	75557
Cardiac magnetic resonance imaging for morphology and function without and with contrast and further sequences.	75561
Cardiac magnetic resonance imaging for morphology and function without contrast; with stress imaging (rarely used in pediatrics).	75559
Cardiac magnetic resonance imaging for morphology and function without and with contrast and further sequences; with stress imaging (rarely used in pediatrics).	75563
Cardiac magnetic resonance imaging for velocity flow mapping (List separately in addition to code for primary procedure).	+75565

- Only one procedure code from the set: CPT® 75557, CPT® 75559, CPT® 75561, and CPT® 75563 should be reported per session.
- Only one flow velocity measurement (CPT® +75565) should be reported per session.

Indications for Cardiac MRI (PEDCD-9.3)

CDP.MR.0009.3.A

v1.0.2024

- In addition to indications listed in previous guideline sections, Cardiac MRI (CPT® 75557 or 75561) evaluation is indicated for any of the following, when a recent TTE is inconclusive:
 - Assessment of global ventricular function and mass if a specific clinical question is left unanswered by recent TTE and the MRI results will affect management of the individual's condition
 - Individuals with complex congenital heart disease (e.g., Tetralogy of Fallot [TOF], single ventricle, truncus arteriosus, Transposition of the Great Arteries [TGA]) may require a baseline MRI, or routine Cardiac MRI, especially as they approach their teenage years, due to poor imaging windows on echocardiogram, and the need for specific clinical information not seen on prior echocardiograms due to these known limitations. Once these individuals reach age 18, they can be imaged by adult congenital heart disease guideline.
 - Clinical suspicion of arrhythmogenic right ventricular dysplasia (ARVD) or arrhythmogenic cardiomyopathy (ARVC).
 - For pericardial disease (including constrictive pericarditis, restrictive pericarditis, and perimyocarditis), MRI should not be utilized to diagnose pericarditis but only to answer the question regarding possible constriction or restriction suggested clinically or by other techniques (TTE, etc.)
 - MRI without and with contrast (CPT® 75561) is considered the optimal test for this disorder.
 - Evaluate cardiac tumor or mass
 - MRI without and with contrast (CPT® 75561) is considered the optimal test for this disorder.
 - Evaluate anomalous coronary artery
 - MRI without and with contrast (CPT® 75561) or CCTA (CPT® 75574) after echocardiogram is considered the optimal test for this disorder.
 - For Fabry's disease, late enhancement MRI may predict the effect of enzyme replacement therapy on myocardial changes that occur with this disease.
 - MRI without and with contrast (CPT® 75561) is considered the preferred test for this disorder.
 - Cardiac MRI (CPT® 75557 or 75561) can be performed to evaluate individuals with congenital cardiomyopathy (muscular dystrophy, glycogen storage disease, fatty acid oxidation disorders, mitochondrial disorders, etc.) or unexplained cases of cardiomyopathy in order to characterize the myocardium.
 - Cardiac stress perfusion study (CPT® 75559 or CPT® 75563) can be considered on a case by case basis for individuals with any of the following:

- Anomalous coronary artery
- Kawasaki disease
- TGA
- Ross operation
- Other disorder with the potential for coronary ischemia
- Individuals in whom an exercise stress test (EST) without imaging is indicated but the individual is not able to perform an EST.
- Individuals in whom an exercise stress test (EST) is equivocal, positive, or concern for a false negative
- Assessment of cardiac iron overload such as in hemochromatosis, thalassemia, sickle cell (either CPT® 75557 or CPT® 71550, T2* MRI, contrast not necessary).
 - Screening imaging may be approved every 12 months
 - Imaging may be approved every 3 months for treatment response in individuals receiving active treatment (chelation +/- phlebotomy)
 - Frequently performed along with MRI Abdomen (CPT® 74181) to assess liver iron deposition. See **Transfusion-Associated (Secondary) Hemochromatosis (PEDAB-18.2)** in the Pediatric Abdomen Imaging Guidelines.
- Asymptomatic individuals with Duchenne Muscular Dystrophy (DMD)
 - MRI Cardiac for DMD **either** CPT® 75557 or CPT® 75561 is indicated for surveillance if done in place of TTE every year starting at 6 years of age
 - Female carriers would not typically be imaged until ≥18 years of age and should be imaged according to general Cardiac Imaging Guidelines
 - CPT® 75565 or CPT® 71555 would not be indicated unless there was an independent indication for either of those codes.

Indications for Chest MRA for Congenital heart disease (PEDCD-9.4)

CDP.00.A
v1.0.2024

- For Familial Aortopathies see **Thoracic Aortic Disease (PEDPVD-4.1)** in the Pediatric Peripheral Vascular Disease Imaging Guidelines
- For individuals with known CHD for routine imaging **Imaging and Surveillance per Congenital lesion (PEDCD-2.4)**
- For individuals who have both cardiac and ascending aorta abnormalities (e.g., truncus arteriosus), the following studies may be indicated following an inconclusive TTE:
 - Cardiac MRI (CPT® 75557 or CPT® 75561)
 - And MRI Chest (CPT® 71552) or MRA Chest (CPT® 71555) if aorta is involved
- For individuals with aortic abnormalities without cardiac abnormalities (i.e. normal intracardiac anatomy, but coarctation or peripheral pulmonary artery stenosis), the following studies may be indicated following an inconclusive TTE:
 - MRI Chest (CPT® 71552)
 - MRA Chest (CPT® 71555)
- MRA Chest (CPT® 71555) is indicated for individuals with cardiomyopathy or isolated abnormal intracardiac anatomy, when there are inconclusive images on echocardiogram related to chest vessels (e.g. aortic arch, pulmonary arteries, pulmonary veins, systemic veins).

References (PEDCD-9)

v1.0.2024

1. Nelson Textbook of Pediatrics, 20th Edition, Robert M. Kliegman, MD, Bonita M.D. Stanton, MD, Joseph St. Geme, MD and Nina F Schor, MD, PhD, p2182 to p2292.
2. Atweh LA, Orth RC, Guillerman RP, Zhang W, Kan JH. MR imaging of children and young adults with classic findings of osteonecrosis on unenhanced MR images: do contrast-enhanced sequences help? *Pediatric Radiology*. 2013;43(11):1502-1506. doi:10.1007/s00247-013-2714-1.
3. Cohen MS, Eidem BW, Cetta F, et al. Multimodality Imaging Guidelines of Patients with Transposition of the Great Arteries: A Report from the American Society of Echocardiography Developed in Collaboration with the Society for Cardiovascular Magnetic Resonance and the Society of Cardiovascular Computed Tomography. *Journal of the American Society of Echocardiography*. 2016;29(7):571-621. doi:10.1016/j.echo.2016.04.002.
4. Adler Y, Charron P, Imazio M, et al. 2015 ESC Guidelines for the diagnosis and management of pericardial diseases. *European Heart Journal*. 2015;36(42):2921-2964. doi:10.1093/eurheartj/ehv318.
5. Allen HD, Shaddy RE, Penny DJ, et al. TF. Moss and Adams' Heart Disease in Infants, Children, and Adolescents: Including the Fetus and Young Adult. 9th ed. Philadelphia, PA: Wolters Kluwer; 2016.
6. Hundley WG, Bluemke DA, Finn JP, et al. ACCF/ACR/AHA/NASCI/SCMR 2010 Expert Consensus Document on Cardiovascular Magnetic Resonance. *Circulation*. 2010;121(22):2462-2508. doi:10.1161/cir.0b013e3181d44a8f.
7. Cohen MS, Eidem BW, Cetta F, et al. Multimodality Imaging Guidelines of Patients with Transposition of the Great Arteries: A Report from the American Society of Echocardiography Developed in Collaboration with the Society for Cardiovascular Magnetic Resonance and the Society of Cardiovascular Computed Tomography. *Journal of the American Society of Echocardiography*. 2016;29(7):571-621. doi:10.1016/j.echo.2016.04.002.
8. Valente AM, Cook S, Festa P, et al. Multimodality Imaging Guidelines for Patients with Repaired Tetralogy of Fallot: A Report from the American Society of Echocardiography. *Journal of the American Society of Echocardiography*. 2014;27(2):111-141. doi:10.1016/j.echo.2013.11.009.
9. Feingold B, Mahle WT, Auerbach S, et al. Management of Cardiac Involvement Associated With Neuromuscular Diseases: A Scientific Statement From the American Heart Association. *Circulation*. 2017;136(13). doi:10.1161/cir.0000000000000526.
10. Mah ML, Cripe L, Slawinski MK, et al. Duchenne and Becker muscular dystrophy carriers: Evidence of cardiomyopathy by exercise and cardiac MRI testing. *International Journal of Cardiology*. 2020;316:257-265. doi:10.1016/j.ijcard.2020.05.052.
11. Power LC, O'Grady GL, Hornung TS, Jefferies C, Gusso S, Hofman PL. Imaging the heart to detect cardiomyopathy in Duchenne muscular dystrophy: A review. *Neuromuscular Disorders*. 2018;28(9):717-730. doi:10.1016/j.nmd.2018.05.011.
12. Hor KN, Mah ML, Johnston P, Cripe TP, Cripe LH. Advances in the diagnosis and management of cardiomyopathy in Duchenne muscular dystrophy. *Neuromuscular Disorders*. 2018;28(9):711-716. doi:10.1016/j.nmd.2018.06.014.
13. Buddhe S, Cripe L, Friedland-Little J, et al. Cardiac Management of the Patient With Duchenne Muscular Dystrophy. *Pediatrics*. 2018;142(Supplement 2). doi:10.1542/peds.2018-0333i.
14. Birnkrant DJ, Bushby K, Bann CM, et al. Diagnosis and management of Duchenne muscular dystrophy, part 2: respiratory, cardiac, bone health, and orthopaedic management. *The Lancet Neurology*. 2018;17(4):347-361. doi:10.1016/s1474-4422(18)30025-5.

Diagnostic Heart Catheterization

Guideline

Cardiac Catheterization General Information (PEDCD-11.1)

Cardiac Catheterization Indications (PEDCD-11.2)

References (PEDCD-11)

Cardiac Catheterization General Information (PEDCD-11.1)

CDP.DHC.0011.1.A

v1.0.2024

Cardiac Catheterization Procedure Codes	
Cardiac Cath Procedures	CPT®
Congenital Heart Disease Code "Set"	93593-93597
Right heart catheterization for congenital heart defect(s) including imaging guidance by the proceduralist to advance the catheter to the target zone; normal native connections	93593
Right heart catheterization for congenital heart defect(s) including imaging guidance by the proceduralist to advance the catheter to the target zone; abnormal native connections	93594
Left heart catheterization for congenital heart defect(s) including imaging guidance by the proceduralist to advance the catheter to the target zone, normal or abnormal native connections	93595
Right and left heart catheterization for congenital heart defect(s) including imaging guidance by the proceduralist to advance the catheter to the target zone(s); normal native connections	93596
Right and left heart catheterization for congenital heart defect(s) including imaging guidance by the proceduralist to advance the catheter to the target zone(s); abnormal native connections	93597
Anomalous coronary arteries, patent foramen ovale, mitral valve prolapse, and bicuspid aortic valve	93451-93464, 93566-93568
RHC without LHC or coronaries	93451
LHC without RHC or coronaries	93452
RHC and retrograde LHC without coronaries	93453

Cardiac Catheterization Procedure Codes	
Cardiac Cath Procedures	CPT®
Native coronary artery catheterization;	93454
with bypass grafts	93455
with RHC	93456
with RHC and bypass grafts	93457
with LHC	93458
with LHC and bypass grafts	93459
with RHC and LHC	93460
with RHC and LHC and bypass grafts	93461
LHC by trans-septal or apical puncture	+93462
Angiography of non-coronary arteries and veins performed as a distinct service	Select appropriate codes from the Radiology and Vascular Injection Procedures sections.
CPT® 93593 to 93597 are appropriate for invasive evaluation of congenital heart disease	

- These guidelines apply to individuals with stable conditions and who are not in the acute setting. Individuals in acute settings or with unstable angina should be handled as medical emergencies.
- Pediatric catheterizations are done for many purposes, including diagnosis and intervention of congenital and acquired heart disease.
- When device placement is planned (ASD/VSD device, transcatheter valve implantation, PDA device), the procedure codes for those devices include all cardiac catheterization(s), intraprocedural contrast injection(s), fluoroscopic radiological supervision and interpretation, and imaging guidance performed to complete the procedure. A diagnostic cath may be considered on a case-by-case basis if there are unanswered issues via noninvasive imaging.
- A right heart cath can be approved for pulmonary artery interventions (e.g., stents, coils).

Cardiac Catheterization Indications (PEDCD-11.2)

CDP.DHC.0011.2.A

v1.0.2024

- Diagnostic catheterization is indicated:
 - When other advanced imaging has failed to resolve a clinical issue and results will impact the individual's management
 - For example, a cath to assess ventricular pressures and shunt to determine if VSD surgery is required
 - For preoperative assessment in complex heart disease
 - Norwood procedure
 - Bidirectional Glenn shunt
 - Fontan procedure
 - Pulmonary atresia
 - Pulmonary hypertension
 - During some interventions such as:
 - Valvuloplasty
 - Pulmonary artery or vein stents
 - Assessment of individuals who are status post heart transplant
 - See **Kawasaki Disease Initial Imaging (PEDCD-6.1)** for specific intervals in Kawasaki Disease
 - On an individual who is having a device placed when:
 - A diagnostic catheterization, or stenting is needed in addition to the device
 - The diagnostic catheterization is indicated separate from the device placement
 - Individuals with anomalous coronary arteries, or with syndromes associated with abnormal coronary arteries (i.e., Williams syndrome) or acquired CAD (i.e., KD-see **Kawasaki Disease Initial Imaging (PEDCD-6.1)**)
 - When diagnostic images are not adequate or evaluation or treatment decision
 - Preoperative for cardiac surgery
 - New symptoms concerning for ischemia

References (PEDCD-11)

v1.0.2024

1. Optum360®EncoderPro.com. EncoderPro.com Online Medical Coding Software | Optum360Coding.com. <https://www.encoderpro.com>. Published 2019.
2. Feltes TF, Bacha E, Beekman RH, et al. Indications for Cardiac Catheterization and Intervention in Pediatric Cardiac Disease: A Scientific Statement from the American Heart Association. *Circulation*. 2011;123(22):2607-2652. doi:10.1161/cir.0b013e31821b1f10.
3. LaDisa JF, Taylor CA, Feinstein JA. (2006) Endovascular Treatment Strategies for Coarctation of the Aorta. In: Rousseau H, Verhoye JP, Heautot JF. (eds) Thoracic Aortic Diseases. Springer, Berlin, Heidelberg.
4. Bergersen L, Foerster S, Marshall AC, Meadows J. *Congenital Heart Disease The Catheterization Manual*. New York, NY: Springer US; 2009.

Table of Contents

Guideline

- General Guidelines (PEDCH-1)
- Lymphadenopathy (PEDCH-2)
- Mediastinal Mass (PEDCH-3)
- Hemoptysis (PEDCH-4)
- Cystic Fibrosis and Bronchiectasis (PEDCH-5)
- Bronchiolitis (PEDCH-6)
- Pneumonia (PEDCH-7)
- Solitary Pulmonary Nodule (PEDCH-8)
- Positive PPD or Tuberculosis (PEDCH-9)
- Asthma (PEDCH-10)
- Pectus Deformities (PEDCH-11)
- Breast Masses (PEDCH-12)
- Vascular Malformations (PEDCH-13)
- Congenital Chest Diseases (PEDCH-14)

General Guidelines (PEDCH-1)

Guideline

Procedure Codes Associated with Chest Imaging

General Guidelines (PEDCH-1.0)

Pediatric Chest Imaging Age Considerations (PEDCH-1.1)

Pediatric Chest Imaging Modality General Considerations (PEDCH-1.3)

References (PEDCH-1)

Procedure Codes Associated with Chest Imaging

CHP.GG.ProcedureCodes.A
v1.0.2024

MRI	CPT®
MRI Chest without contrast	71550
MRI Chest with contrast (rarely used)	71551
MRI Chest without and with contrast	71552
Unlisted MRI procedure (for radiation planning or surgical software)	76498

MRA	CPT®
MRA Chest (non-cardiac)	71555

CT	CPT®
CT Chest without contrast	71250
CT Chest with contrast	71260
CT Chest without and with contrast (rarely used)	71270
CT Guidance for Placement of Radiation Therapy Fields	77014
Unlisted CT procedure (for radiation planning or surgical software)	76497

CTA	CPT®
CTA Chest (non-coronary)	71275

Nuclear Medicine	CPT®
PET Imaging; limited area (this code not used in pediatrics)	78811
PET Imaging; skull base to mid-thigh (this code not used in pediatrics)	78812
PET Imaging; whole body (this code not used in pediatrics)	78813
PET with concurrently acquired CT; limited area (this code rarely used in pediatrics)	78814
PET with concurrently acquired CT; skull base to mid-thigh	78815
PET with concurrently acquired CT; whole body	78816
Pulmonary Ventilation (e.g., Aerosol or Gas) Imaging	78579
Pulmonary Perfusion Imaging	78580
Pulmonary Ventilation (e.g., Aerosol or Gas) and Perfusion Imaging	78582

Nuclear Medicine	CPT[®]
Quantitative Differential Pulmonary Perfusion, Including Imaging When Performed	78597
Quantitative Differential Pulmonary Perfusion and Ventilation (e.g., Aerosol or Gas), Including Imaging When Performed	78598

Ultrasound	CPT[®]
Ultrasound, chest (includes mediastinum, chest wall, and upper back)	76604
Ultrasound, axilla	76882
Ultrasound, breast; <i>unilateral</i> , including axilla when performed; complete	76641
Ultrasound, breast; <i>unilateral</i> , including axilla when performed; limited	76642

General Guidelines (PEDCH-1.0)

CHP.GG.0001.0.A

v1.0.2024

- A pertinent clinical evaluation since the onset or change in symptoms, including a detailed history, physical examination, and appropriate laboratory, and basic imaging such as plain radiography or ultrasound should be performed prior to considering advanced imaging (CT, MRI, Nuclear Medicine), unless the individual is undergoing guideline-supported scheduled imaging evaluation. A meaningful technological contact (telehealth visit, telephone call, electronic mail or messaging) since the onset or change in symptoms can serve as a pertinent clinical evaluation.
- Unless otherwise stated in a specific guideline section, the use of advanced imaging to screen asymptomatic individuals for disorders involving the chest is not supported. Advanced imaging of the chest is only supported in individuals who have documented active clinical signs or symptoms of disease involving the chest.
- Unless otherwise stated in a specific guideline section, repeat imaging studies of the chest are not necessary unless there is evidence for progression of disease, new onset of disease, and/or documentation of how repeat imaging will affect individual management or treatment decisions.

Pediatric Chest Imaging Age Considerations (PEDCH-1.1)

CHP.GG.0001.1.A

v1.0.2024

- Many conditions affecting the chest in the pediatric population are different diagnoses than those occurring in the adult population. For those diseases which occur in both pediatric and adult populations, differences may exist in management due to individual age, comorbidities, and differences in disease natural history between children and adults.
- Individuals who are 18 years old or younger¹⁵ should be imaged according to the Pediatric Chest Imaging Guidelines if discussed. Any conditions not specifically discussed in the Pediatric Chest Imaging Guidelines should be imaged according to the General Chest Imaging Guidelines. Individuals who are >18 years old should be imaged according to the General Chest Imaging Guidelines, except where directed otherwise by a specific guideline section.

Pediatric Chest Imaging Modality General Considerations (PEDCH-1.3)

CHP.GG.0001.3.A

v1.0.2024

- MRI
 - MRI Chest is generally performed without and with contrast (CPT® 71552) unless the individual has a documented contraindication to gadolinium or otherwise stated in a specific guideline section.
 - Due to the length of time required for MRI acquisition and the need to minimize individual movement, anesthesia is usually required for almost all infants (except neonate) and young children (age <7 years), as well as older children with delays in development or maturity. This anesthesia may be administered via oral or intravenous routes. In this individual population, MRI sessions should be planned with a goal of minimizing anesthesia exposure by adhering to the following considerations:
 - MRI procedures can be performed without and/or with contrast use as supported by these condition-based guidelines. If intravenous access will already be present for anesthesia administration and there is no contraindication for using contrast, imaging without and with contrast may be appropriate if requested. By doing so, the requesting provider may avoid repetitive anesthesia administration to perform an MRI with contrast if the initial study without contrast is inconclusive.
 - Recent evidence-based literature demonstrates the potential for gadolinium deposition in various organs including the brain, after the use of MRI contrast.
 - The U.S. Food and Drug Administration (FDA) has noted that there is currently no evidence to suggest that gadolinium retention in the brain is harmful and restricting gadolinium-based contrast agents (GBCAs) use is not warranted at this time. It has been recommended that GBCA use should be limited to circumstances in which additional information provided by the contrast agent is necessary and the necessity of repetitive MRIs with GBCAs should be assessed.
 - If multiple body areas are supported by the guidelines for the clinical condition being evaluated, MRI of all necessary body areas should be obtained concurrently.
 - The presence of surgical hardware or implanted devices may preclude MRI.
 - The selection of best examination may require coordination between the provider and the imaging service.
- CT
 - CT Chest is generally performed either with contrast (CPT® 71260) or without contrast (CPT® 71250).

- There are no generally accepted pediatric indications for CT Chest without and with contrast (CPT® 71270).
- CT should not be used to replace MRI in an attempt to avoid sedation unless listed as a recommended study in a specific guideline section.
- The selection of best examination may require coordination between the provider and the imaging service.
- Ultrasound
 - Ultrasound chest (CPT® 76604) or axilla (CPT® 76882) is indicated as an initial study for evaluating adenopathy, palpable chest wall lesions, pleural effusion or thickening, patency of thoracic vasculature, and diaphragm motion abnormalities.
 - For those individuals who do require advanced imaging, ultrasound can be very beneficial in selecting the proper modality, body area, image sequences, and contrast level that will provide the most definitive information for the individual.
- Nuclear Medicine
 - Nuclear medicine studies other than PET/CT are rarely used in evaluation of the pediatric chest.
 - Pulmonary Ventilation-Perfusion Imaging (CPT® 78582) has been replaced by CTA Chest (CPT® 71275) or CT Chest with contrast (CPT® 71260), but are appropriate for evaluation of suspected pulmonary embolism if CT is unavailable.
 - See **Pulmonary Embolism (PE) (CH-25.1)** in the Chest Imaging Guidelines.
 - Pulmonary Perfusion Imaging (CPT® 78580) are generally not appropriate in lieu of CPT® 78582 for initial evaluation of suspected pulmonary embolism, but is appropriate for follow up of an equivocal or positive recent ventilation-perfusion lung scan (CPT® 78582) to evaluate for interval change.
 - Pulmonary Ventilation Imaging (CPT® 78579) are not appropriate in lieu of CPT® 78582 for evaluation of suspected pulmonary embolism, but is appropriate for additional evaluation of an abnormal perfusion-only scan (CPT® 78580).
 - Pulmonary split crystal function study (CPT® 78597 or CPT® 78598), also known as Quantitative Differential Pulmonary Perfusion, is indicated for preoperative planning of segmental, lobar, or lung resection.
 - Quantitative Differential Pulmonary Perfusion Lung Scan (CPT® 78597 or CPT® 78598), can be performed for post lung transplant individuals to detect regional perfusion abnormalities.
 - Radiopharmaceutical nuclear medicine imaging of an inflammatory process (CPT® 78800, CPT® 78801, CPT® 78802, or CPT® 78803) is rarely performed, but is indicated for evaluation of sarcoidosis or toxicity from drug toxicity (cyclophosphamide, busulfan, bleomycin, amiodarone, or nitrofurantoin).
- 3D Rendering
 - 3D Rendering indications in pediatric chest imaging are identical to those in the general imaging guidelines. See **3D Rendering (Preface-4.1)** in the Preface Imaging Guidelines.

The guidelines listed in this section for certain specific indications are not intended to be all-inclusive; clinical judgment remains paramount and variance from these guidelines may be appropriate and warranted for specific clinical situations.

References (PEDCH-1)

v1.0.2024

1. Siegel MJ. Chest. In: *Pediatric Sonography*. Philadelphia. Wolters Kluwer. 2018;156-195.
2. ACR Practice parameter for performing and interpreting of magnetic resonance imaging (MRI). Revised 2017. (Resolution 10).
3. ACR-ASER-SCBT-MR-SPR Practice Parameter for the Performance of Pediatric Computed Tomography (CT). Revised 2019. (Resolution 6).
4. Trinavarat P and Riccabonna M. Potential of ultrasound in the pediatric chest. *Eur J Radiol*. 2014;83(9):1507-1518.
5. Goh Y, Kapur J. Sonography of the pediatric chest. *J Ultrasound Med*. 2016 May;35(5):1067-1080.
6. Reighard C, Junaid S, Jackson WM, et al. Anesthetic Exposure During Childhood and Neurodevelopmental Outcomes. *JAMA Netw Open*. 2022;5(6):e2217427. doi: 10.1001/jamanetworkopen.2022.17427.
7. Nevin MA. Chapter 407: Pulmonary embolism, infarction, and hemorrhage. In: Kliegman RM, Stanton BF, St. Geme JW III, et al., eds. *Nelson Textbook of Pediatrics*. 20th ed. 2016;2123-2128.
8. Kirsch J, Brown KJ, Henry TS, et al. Suspected pulmonary embolism. *ACR Appropriateness Criteria*® . Revised 2016.
9. Drescher FS, Chandrika S, Weir ID, et al. Effectiveness and acceptability of a computerized decision support system using modified wells criteria for evaluation of suspected pulmonary embolism. *Ann Emerg Med*. 2011 Jun;57(6):613-621.
10. Morton KA, Clark PB, et al. Diagnostic imaging: nuclear medicine. *Amirsys*. 2013;(4):2-15.
11. ACR-SPR-STR Practice Parameter for the Performance of Pulmonary Scintigraphy. Revised 2018. (Resolution 30).
12. Blumfield E, Swenson DW, Iyer RS, Stanescu AL. Gadolinium-based contrast agents — review of recent literature on magnetic resonance imaging signal intensity changes and tissue deposits, with emphasis on pediatric patients. *Pediatr Radiol*. 2019;49(4):448-457. doi: 10.1007/s00247-018-4304-8.
13. Fraum TJ, Ludwig DR, Bashir MR, Fowler KJ. Gadolinium-based contrast agents: A comprehensive risk assessment. *J Magn Reson Imaging*. 2017;46(2):338-353. doi: 10.1002/jmri.25625.
14. Update on FDA approach to safety issue of gadolinium retention after administration of gadolinium-based contrast agents. Available at: <https://www.fda.gov/media/116492/download>. September 20, 2018.
15. Implementation Guide: Medicaid State Plan Eligibility Eligibility Groups Mandatory Coverage Infants and Children under Age 19. Available at: <https://www.hhs.gov/guidance/document/implementation-guide-medicaid-state-plan-eligibility-eligibility-groups-aeu-mandatory-2>. Issue date: July 14, 2017.

Lymphadenopathy (PEDCH-2)

Guideline

Lymphadenopathy (PEDCH-2.1)

Reference (PEDCH-2)

Lymphadenopathy (PEDCH-2.1)

CHP.LY.0002.1.A

v1.0.2024

- Axillary lymphadenopathy imaging indications in pediatric individuals are identical to those for adult individuals. See **Axillary Lymphadenopathy (and Mass) (CH-2.2)** in the Chest Imaging Guidelines.
- Supraclavicular adenopathy in pediatric individuals is almost always pathologic, and advanced imaging is indicated prior to excisional biopsy. Fine needle aspiration, while common in adults prior to advanced imaging, is inappropriate for evaluating lymphadenopathy in pediatric individuals. ANY of the following studies are appropriate for evaluation of supraclavicular adenopathy in children:
 - CT Chest with contrast (CPT® 71260)
 - MRI Chest without and with contrast (CPT® 71552)
 - Ultrasound Chest (CPT® 76604)
- If malignancy is suspected, see the appropriate imaging guidelines as below:
 - Lymphoma: **Pediatric Lymphomas (PEDONC-5)** in the Pediatric Oncology Imaging Guidelines.
 - Soft tissue sarcoma: **Pediatric Soft Tissue Sarcomas (PEDONC-8)** in the Pediatric Oncology Imaging Guidelines.
 - Neuroblastoma: **Neuroblastoma (PEDONC-6)** in the Pediatric Oncology Imaging Guidelines.

Reference (PEDCH-2)

v1.0.2024

1. Allen-Rhoades W and Steuber CP. Clinical assessment and differential diagnosis of the child with suspected cancer. In: Pizzo PA, Poplack DG, eds. *Principles and Practice of Pediatric Oncology*. 7th ed. 2015;101-111.

Mediastinal Mass (PEDCH-3)

Guideline

Mediastinal Mass (PEDCH-3.1)

References (PEDCH-3)

Mediastinal Mass (PEDCH-3.1)

CHP.MM.0003.1.A

v1.0.2024

- The causes of mediastinal masses in children are generally different than those in adults, and the imaging considerations are different. Up to half of all pediatric mediastinal masses are malignant.⁷
- Chest x-ray is indicated as an initial study for all individuals with suspected mediastinal mass.
- CT Chest with contrast (CPT[®] 71260) is indicated for any pediatric individual with a mediastinal mass identified on chest x-ray.
 - Masses can be very large and anterior masses frequently cause compression of the trachea and/or mediastinal blood vessels.
- MRI Chest without and with contrast (CPT[®] 71552) is indicated for any pediatric individual with:
 - A posterior (paravertebral) mediastinal mass on CT Chest that invades the spinal canal
 - CT findings are inconclusive regarding specific anatomy
 - MRI should not be used for individuals with large anterior mediastinal masses if anesthesia is necessary to complete the study.
- PET/CT (CPT[®] 78815) is indicated prior to biopsy in pediatric individuals if lymphoma is known or strongly suspected or there is evidence of tracheal compression on CT imaging. See **Pediatric Lymphoma (PEDONC-5)** in the Pediatric Oncology Imaging Guidelines.
- MIBG (CPT[®] 78800, CPT[®] 78802, CPT[®] 78803, or CPT[®] 78804) is indicated and is supported prior to biopsy in pediatric individuals if neuroblastoma is known or strongly suspected. See **Neuroblastoma (PEDONC-6)** in the Pediatric Oncology Imaging Guidelines.
- Ultrasound chest (CPT[®] 76604) is appropriate in children younger than 5 years old to distinguish prominent but otherwise normal thymus from true mediastinal mass.
- A single repeat CT Chest with contrast (CPT[®] 71260) is appropriate to confirm stability and avoid biopsy for individuals with NONE of the following features:
 - Anterior mediastinal mass
 - Enlarged lymph nodes anywhere in the imaging field
 - Lymphopenia
 - Pleural effusion

References (PEDCH-3)

v1.0.2024

1. Thacker PG, Mahani MG, Heider A, et al. Imaging evaluation of mediastinal masses in children and adults. *J Thorac Imaging*. 2015;30(4):247-264.
2. Mullen EA and Gratijs EJ. Oncologic emergencies. In: Orkin SH, Fisher DE, Ginsburg D, et al., eds. *Nathan and Oski's Hematology and Oncology of Infancy and Childhood*. 8th ed. 2015:2267-2291.
3. Trinavarat P and Riccabonna M. Potential of ultrasound in the pediatric chest. *Eur J Radiol*. 2014; 83(9):1507-1518.
4. Naeem F, Metzger ML, Arnold SR, et al. Distinguishing benign mediastinal masses from malignancy in a histoplasmosis-endemic region. *J Pediatr*. 2015;167(2):409-415.
5. Manson DE. Magnetic resonance imaging of the mediastinum, chest wall and pleura in children. *Pediatr Radiol*. 2016;46(6):902-915.
6. *American College of Radiology ACR Appropriateness Criteria*® Imaging of Mediastinal Masses. Revised 2020.
7. Sreedher G, Tadros SS, Janitz E. Pediatric mediastinal masses. *Pediatr Radiol*. Published online June 8, 2022. doi: 10.1007/s00247-022-05409-4.

Hemoptysis (PEDCH-4)

Guideline

Hemoptysis – Imaging (PEDCH-4.1)

References (PEDCH-4)

Hemoptysis – Imaging (PEDCH-4.1)

CHP.BL.0004.1.A

v1.0.2024

- True hemoptysis is rare in pediatric individuals, and a detailed history, physical examination, and appropriate laboratory studies should be performed prior to considering advanced imaging.
 - Aspirated blood from epistaxis or emesis frequently presents as hemoptysis, and history and physical examination will aid in this assessment.
- Chest x-ray is indicated as an initial study for stable individuals.
 - Advanced imaging is not indicated for individuals with epistaxis and a normal chest radiograph and no personal or family history of underlying lung disease or bleeding disorder.
 - CT Chest with contrast (CPT® 71260) is indicated for all other pediatric individuals with hemoptysis.
 - CT Chest without contrast (CPT® 71250) for individuals with a documented allergy to CT contrast or significant renal dysfunction.
- MRI is not indicated in the evaluation of pediatric hemoptysis.

References (PEDCH-4)

v1.0.2024

1. Gupta A, Sands M, Chauhan NR. Massive hemoptysis in pulmonary infections: bronchial artery embolization. *J Thorac Dis.* 2018;10(S28):S3458-S3464. doi: 10.21037/jtd.2018.06.147.
2. Nevin MA. Chapter 436: Pulmonary embolism, infarction, and hemorrhage. In: Kliegman RM, St. Geme JW III, Blum NJ, Shah SS, Tasker RC, Wilson KM, eds. *Nelson Textbook of Pediatrics.* 21st ed. 2020:2309-2314.

Cystic Fibrosis and Bronchiectasis (PEDCH-5)

Guideline

Cystic Fibrosis (PEDCH-5.1)

Bronchiectasis Not Associated with Cystic Fibrosis (PEDCH-5.2)

References (PEDCH-5)

Cystic Fibrosis (PEDCH-5.1)

CHP.CF.0005.1.A

v1.0.2024

- Chest x-ray is the primary study for initial evaluation of acute clinical symptoms in individuals with cystic fibrosis.
- CT Chest without contrast (CPT® 71250) or with contrast (CPT® 71260) is indicated for the following (without initial chest x-ray):
 - Hemoptysis
 - Pneumonia worsening despite antibiotic therapy
 - Pleural effusion or empyema
 - Suspected fungal pneumonia
 - Monitoring treatment changes on bronchiectasis
 - Expiratory CT for evaluating small airways disease
 - Pre- and post-lung transplant evaluation
- Low dose CT Chest without contrast (CPT® 71250) is indicated **every 2 years** for monitoring of bronchiectasis and small airways disease.
- Cystic fibrosis associated liver disease develops in 5-10% of individuals with cystic fibrosis. Advanced imaging may be appropriate if concerned for liver disease. See **Liver Disease (PEDAB-16)** in the Pediatric Abdomen Imaging Guidelines.

Bronchiectasis Not Associated with Cystic Fibrosis (PEDCH-5.2)

CHP.CF.0005.2.A

v1.0.2024

- Bronchiectasis not associated with cystic fibrosis is rare in pediatric individuals, and imaging indications are identical to those for adult individuals. See **Bronchiectasis (CH-7.1)** in the Chest Imaging Guidelines.

References (PEDCH-5)

v1.0.2024

1. Egan M, Shechter MS, Voynow JA. Cystic fibrosis. Chapter 432. In: Kliegman RM, St. Geme JW III, Blum NJ, Shah SS, Tasker RC, Wilson KM, eds. *Nelson Textbook of Pediatrics*. 21st ed. 2020:2282-2297.
2. Szczesniak R, Turkovic L, Andrinopoulou E-R, Tiddens HA. Chest imaging in cystic fibrosis studies: What counts, and can be counted? *J Cyst Fibros*. 2017;16(2):175-185. doi: 10.1016/j.jcf.2016.12.008.
3. Paranjape SM and Mogayzel Jr PJ. Cystic fibrosis. *Pediatr Rev*. 2014; 35 (5):194-205.
4. Tiddens HAM, Stick SM, and Davis S. Multi-modality monitoring of cystic fibrosis lung disease: the role of chest computed tomography. *Paediatr Resp Rev*. 2014; 15(1):92-97.
5. Murphy KP, Maher MM, Oconnor OJ. Imaging of Cystic Fibrosis and Pediatric Bronchiectasis. *AJR Am J Roentgenol*. 2016;206(3):448-454. doi: 10.2214/ajr.15.14437.
6. Lasker OJ. Bronchiectasis. Chapter 430. In: Kliegman RM, St. Geme JW III, Blum NJ, Shah SS, Tasker RC, Wilson KM, eds. *Nelson Textbook of Pediatrics*. 21st ed. 2020:2278-2280.

Bronchiolitis (PEDCH-6)

Guideline

Bronchiolitis (PEDCH-6.1)

References (PEDCH-6)

Bronchiolitis (PEDCH-6.1)

CHP.BR.0006.1.A

v1.0.2024

Bronchiolitis is a self-limiting viral infection causing inflammation of the small airways, most common in infants under 12 months of age.

- Chest x-rays are indicated when there is a clinical suspicion of pneumonia or other complications.
- Advanced imaging is not indicated for routine evaluation or monitoring of bronchiolitis, but CT Chest with contrast (CPT® 71260) is appropriate for the following:
 - Pleural effusion or empyema on recent chest x-ray
 - Immunocompromised individual with acute pulmonary symptoms
 - Abnormality on recent chest x-ray suggesting condition other than bronchiolitis

References (PEDCH-6)

v1.0.2024

1. House SA, Ralston SL. Chapter 418: Wheezing in infants: bronchiolitis. In: Kliegman RM, St. Geme JW III, Blum NJ, Shah SS, Tasker RC, Wilson KM, eds. *Nelson Textbook of Pediatrics*. 21st ed. 2020:2217-2220.
2. Chang AB, Bush A, Grimwood K. Bronchiectasis in children: diagnosis and treatment. *Lancet*. 2018;392(10150):866-879. doi: 10.1016/s0140-6736(18)31554-x.
3. Darras KE, Roston AT, Yewchuk LK. Imaging Acute Airway Obstruction in Infants and Children. *RadioGraphics*. 2015;35(7):2064-2079. doi: 10.1148/rg.2015150096.

Pneumonia (PEDCH-7)

Guideline

Pneumonia (PEDCH-7.1)

Coronavirus Disease 2019 (COVID-19) (PEDCH-7.2)

References (PEDCH-7)

Pneumonia (PEDCH-7.1)

CHP.PN.0007.1.A

v1.0.2024

- Pneumonia imaging indications in pediatric individuals are very similar to those for adult individuals. See **Pneumonia (CH-13.1)** in the Chest Imaging Guidelines.
- Pediatric-specific imaging considerations include the following:
 - Chest x-ray and/or Ultrasound chest (CPT® 76604) is indicated when the individual's condition does not respond to standard therapy.
 - CT Chest with contrast (CPT® 71260) for immunocompromised individuals with acute pulmonary symptoms.
 - CT Chest without contrast (CPT® 71250) or with contrast (CPT® 71260) for individuals with recurrent lower respiratory tract infections.
 - Ultrasound chest (CPT® 76604) for evaluation of complicated or recurrent childhood pneumonia.

Coronavirus Disease 2019 (COVID-19) (PEDCH-7.2)

CHP.PN.0007.2.A

v1.0.2024

- Pediatric imaging for COVID-19 positive individuals are similar to those for adult individuals. See **Coronavirus Disease 2019 (COVID-19) (CH-13.2)** in the Chest Imaging Guidelines.
- Pediatric-specific imaging considerations include the following:
 - Chest x-ray is the initial imaging test for all pediatric individuals
 - For concerns involving **Multisystem Inflammatory Syndrome in Children (MIS-C)** see **(PEDCD-12)**

References (PEDCH-7)

v1.0.2024

1. Kelly MS and Sandora TJ. Chapter 428: Community-acquired pneumonia. In: Kliegman RM, St. Geme JW III, Blum NJ, Shah SS, Tasker RC, Wilson KM, eds. *Nelson Textbook of Pediatrics*. 21st ed. 2020:2266-2274.
2. O'Grady K-AF, Torzillo PJ, Frawley K, Chang AB. The radiological diagnosis of pneumonia in children. *Pneumonia*. 2014;5(S1):38-51. doi: 10.15172/pneu.2014.5/482.
3. Andronikou S, Goussard P, Sorantin E. Computed tomography in children with community-acquired pneumonia. *Pediatr Radiol*. 2017;47(11):1431-1440. doi: 10.1007/s00247-017-3891-0.
4. Stadler JAM, Andronikou S, Zar HJ. Lung ultrasound for the diagnosis of community-acquired pneumonia in children. *Pediatr Radiol*. 2017;47(11):1412-1419. doi: 10.1007/s00247-017-3910-1.
5. El-Saied MM, Mohie El Deen ZM, Askar GA. Recurrent Pneumonia in Children Admitted to Assiut University Children Hospital. Magnitude of the Problem and Possible Risk Factors. *Med Res J*. 2019;4(1):13-24. doi: 10.5603/mrj.a2019.0001.
6. Pereda MA, Chavez MA, Hooper-Miele CC, et al. Lung ultrasound for the diagnosis of pneumonia in children: a meta-analysis. *Pediatrics*. 2015;135(4):714-722
7. Goh Y and Kapur J. Sonography of the pediatric chest. *J Ultrasound Med*. 2016; 35 (5):1067-1080
8. American College of Radiology ACR Appropriateness Criteria® Pneumonia in the Immunocompetent Child. New 2019.
9. Tsou PY, Chen KP, Wang YH, et al. Diagnostic Accuracy of Lung Ultrasound Performed by Novice Versus Advanced Sonographers for Pneumonia in Children: A Systematic Review and Meta-analysis. *Acad Emerg Med*. 2019;26(9):1074-1088. doi: 10.1111/acem.13818.
10. Foust AM, McAdam AJ, Chu WC, et al. Practical guide for pediatric pulmonologists on imaging management of pediatric patients with COVID-19. *Pediatr Pulmonol*. 2020;55(9):2213-2224. doi: 10.1002/ppul.24870.
11. Nino G, Zember J, Sanchez-Jacob R, Gutierrez MJ, Sharma K, Linguraru MG. Pediatric Lung Imaging Features of Covid-19: A Systematic Review and Meta-Analysis. *Pediatr Pulmonol*. Published online September 14, 2020. doi: 10.1002/ppul.25070.
12. Wang J, Mo Y, Su Y, et al. Computed tomography features of COVID-19 in children. *Medicine*. 2021;100(38):e22571. doi: 10.1097/md.00000000000022571.

Solitary Pulmonary Nodule (PEDCH-8)

Guideline

Solitary Pulmonary Nodule (PEDCH-8.1)

References (PEDCH-8)

Solitary Pulmonary Nodule (PEDCH-8.1)

CHP.PM.0008.1.A
v1.0.2024

The Fleischner Society guidelines for solitary pulmonary nodule management do not apply to pediatric individuals. An incidental solitary pulmonary nodule in a child representing a primary lung carcinoma has never been reported in the literature. Similarly, an extrathoracic malignancy presenting with an incidental solitary pulmonary nodule in an otherwise healthy child is very rare.

- CT Chest with contrast (CPT® 71260) as a one-time evaluation for all children with a pulmonary nodule incidentally discovered on other imaging.
- Follow up imaging of incidental solitary pulmonary nodules in asymptomatic healthy children is not necessary.⁶
 - Follow up imaging is indicated for the following:
 - Immunocompromised individuals
 - Malignancy (see below)
 - Invasive infection
 - New or worsening pulmonary symptoms
- Children with a malignant solid tumor who have pulmonary nodules of any size should have imaging according to the guideline section for the specific cancer type. See **Pediatric Oncology Imaging Guidelines** for specific imaging indications.
- This guideline section does not apply to multiple pulmonary nodules, which are imaged according to the underlying disorder in pediatric individuals.

Background and Supporting Information

A **nodule** is any pulmonary or pleural lesion that is a discrete, spherical opacity 2-30 mm in diameter surrounded by normal lung tissue. A larger nodule is called a mass. Entities that are not nodules, and are considered benign, include non-spherical linear, sheet-like, two-dimensional or scarring opacities.

References (PEDCH-8)

v1.0.2024

1. Assefa D and Atlas A. Natural history of incidental pulmonary nodules in children. *Pediatr Pulmonol.* 2015;50(5):456-459.
2. Westra SJ, Broday AS, Mahani MG, et al. The incidental pulmonary nodule in a child, Part 1; recommendations from the SPR Thoracic Imaging Committee regarding characterization, significance, and follow up. *Pediatr Radiol.* 2015;45(5):628-633.
3. Westra SJ, Thacker PG, Podberesky DJ, et al. The incidental pulmonary nodule in a child, Part 2; commentary and suggestions for clinical management, risk communication and prevention. *Pediatr Radiol.* 2015;45(5):634-639.
4. Strouse PJ. The incidental pulmonary nodule in a child: a conundrum. *Pediatr Radiol.* 2015;45(5):627.
5. Kanne J, Jensen L, Mohammed T, et al. Expert Panel on Thoracic Imaging. ACR Appropriateness Criteria® radiographically detected solitary pulmonary nodule. [Online publication]. Reston (VA): American College of Radiology (ACR); 2012.
6. Liang TI and Lee EY. Pediatric Pulmonary Nodules. Imaging Guidelines and Recommendations. *Radiol Clin N Am.* 2022;60:55-67.

Positive PPD or Tuberculosis (PEDCH-9)

Guideline

Positive PPD or Tuberculosis (PEDCH-9.1)

References (PEDCH-9)

Positive PPD or Tuberculosis (PEDCH-9.1)

CHP.TB.0009.1.A
v1.0.2024

- Positive PPD and tuberculosis imaging indications in pediatric individuals are similar to those for adult individuals.
 - See **PPD or TB (Mycobacterium tuberculosis and Nontuberculous Mycobacterial Pulmonary Disease [NTM-PD]) (CH-14.1)** in the Chest Imaging Guidelines.
- Pediatric-specific imaging considerations include the following:
 - MRI Spine with and without contrast is appropriate at symptomatic levels in individuals with concern for spinal involvement of tuberculosis.

Background and Supporting Information

- Chest x-ray can be useful as the initial imaging study when TB is suspected⁵

References (PEDCH-9)

v1.0.2024

1. Cameron LH, Starke, JR. Chapter 242: Tuberculosis (*Mycobacterium tuberculosis*). In: Kliegman RM, St. Geme JW III, Blum NJ, Shah SS, Tasker RC, Wilson KM, eds. *Nelson Textbook of Pediatrics*. 21st ed. 2020:1564-1582.
2. Sodhi KS, Bhalla AS, Mahomed N, Laya BF. Imaging of thoracic tuberculosis in children: current and future directions. *Pediatr Radiol*. 2017;47(10):1260-1268. doi: 10.1007/s00247-017-3866-1.
3. Skoura E, Zumla A, Bomanji J. Imaging in tuberculosis. *Int J Infect Dis*. 2015;32:87-93. doi: 10.1016/j.ijid.2014.12.00.7
4. Concepcion NDP, Laya BF, Andronikou S, et al. Standardized radiographic interpretation of thoracic tuberculosis in children. *Pediatr Radiol*. 2017;47(10):1237-1248. doi: 10.1007/s00247-017-3868-z.
5. Andronikou S, Miranda-Schaeubinger M, Goussard P, et al. Changes in the Role of Chest Radiographs for Diagnosing and Managing Children with Tuberculosis: the 2022 World Health Organization Consolidated Guidelines on Tuberculosis. *Pediatr Radiology*. 2023;53:566-570. doi: 10.1007/s00247-022-05544-y.

Asthma (PEDCH-10)

Guideline

Asthma (PEDCH-10.1)

References (PEDCH-10)

Asthma (PEDCH-10.1)

CHP.AS.0010.1.A

v1.0.2024

- Chest x-ray and/or Ultrasound chest (CPT® 76604) is indicated when the individual's condition does not respond to standard therapy, to identify complications, such as pneumonia or to rule out other causes of respiratory distress.
- Advanced imaging is not indicated for routine evaluation or monitoring of asthma, but CT Chest without (CPT® 71250) or with (CPT® 71260) contrast is appropriate for the following:
 - Pleural effusion or empyema on recent chest x-ray
 - Immunocompromised individual with acute pulmonary symptoms
 - Abnormality on recent chest x-ray suggesting condition other than asthma, including suspected foreign body
 - Asthma and poor response to bronchodilators or conventional inhaled corticosteroid therapy in whom associated conditions, such as allergic bronchopulmonary aspergillosis and eosinophilic pneumonia can mimic asthma

References (PEDCH-10)

v1.0.2024

1. Liu AH, Spahn JD, and Sicherer SH. Chapter 169: Childhood asthma. In: Kliegman RM, St. Geme JW III, Blum NJ, Shah SS, Tasker RC, Wilson KM, eds. *Nelson Textbook of Pediatrics*. 21st ed. 2020:1186-1209.
2. Ash SY, Diaz AA. The role of imaging in the assessment of severe asthma. *Curr Opin Pulmon Med*. 2017;23(1):97-102. doi: 10.1097/mcp.0000000000000341.
3. Allie EH, Dingle HE, Johnson WN, et al. ED chest radiography for children with asthma exacerbation is infrequently associated with change of management. *Am J Emerg Med*. 2018;36(5):769-773. doi: 10.1016/j.ajem.2017.10.009.
4. Darras KE, Roston AT, Yewchuk LK. Imaging Acute Airway Obstruction in Infants and Children. *RadioGraphics*. 2015;35(7):2064-2079. doi: 10.1148/rg.2015150096.
5. *American College of Radiology ACR Appropriateness Criteria*® Pneumonia in the Immunocompetent Child. New 2019.

Pectus Deformities (PEDCH-11)

Guideline

Pectus Deformities (PEDCH-11.1)

References (PEDCH-11)

Pectus Deformities (PEDCH-11.1)

CHP.PD.0011.1.A

v1.0.2024

- CT Chest without contrast (CPT® 71250), MRI Chest with and without contrast (CPT® 71552), or MRI Chest without contrast (CPT® 71550) is indicated in individuals with a pectus deformity for:
 - Preoperative planning
 - Significant cardiac displacement after chest x-ray and echocardiography (CPT® 93306)
 - Evidence of pulmonary impingement after chest x-ray and pulmonary function tests (PFTs) if there is increasing shortness of breath
 - Note: It may not be possible to obtain PFTs in children younger than 9 years old.
 - Evaluation of congenital heart disease or Marfan's syndrome when suspected in those individuals with pectus deformities

References (PEDCH-11)

v1.0.2024

1. Buziashvili D, Gopman JM, Weissler H, Bodenstein L, Kaufman AJ, Taub PJ. An Evidence-Based Approach to Management of Pectus Excavatum and Carinatum. *Ann Plast Surg.* 2019;82(3):352-358. doi: 10.1097/sap.0000000000001654.
2. Frantz FW. Indications and guidelines for pectus excavatum repair. *Curr Opin Pediatr.* 2011;23(4):486-491.
3. Koumbourlis AC. Chest wall abnormalities and their clinical significance in childhood. *Paediatr Resp Rev.* 2014;15(3):246-255.
4. Dore M, Junco PT, Bret M, et al. Advantages of cardiac magnetic resonance imaging for severe pectus excavatum assessment in children. *Eur J Pediatr Surg.* 2017.
5. Marcovici PA, Losasso BE, Kruk P, Dwek JR. MRI for the evaluation of pectus excavatum. *Pediatr Radiol.* 2011;41(6):757-758. doi: 10.1007/s00247-011-2031-5.
6. Junco PT, Bret M, Cervantes MG, et al. Advantages of Cardiac Magnetic Resonance Imaging for Severe Pectus Excavatum Assessment in Children. *Eur J Pediatr Surg.* 2017;28(01):034-038. doi: 10.1055/s-0037-1604427.

Breast Masses (PEDCH-12)

Guideline

Breast Masses (PEDCH-12.1)

Breast Masses (PEDCH-12.1)

CHP.MS.0012.1.A

v1.0.2024

See **Pediatric Breast Masses (PEDONC-17)** in the Pediatric Oncology Imaging Guidelines.

Vascular Malformations (PEDCH-13)

Guideline

Vascular Ring (PEDCH-13.1)

Other Vascular Malformations (PEDCH-13.2)

References (PEDCH-13)

Vascular Ring (PEDCH-13.1)

CHP.VM.0013.1.A

v1.0.2024

Vascular rings generally present with either respiratory symptoms (stridor, wheezing, tachypnea, cough) or feeding difficulties (dysphagia, slow feeding, hyperextension of the head while feeding, weight loss, failure to thrive), but can also be discovered incidentally on imaging obtained for other purposes.

- Chest x-ray is the recommended initial study in individuals with respiratory symptoms. A chest x-ray is not needed for individuals diagnosed with a vascular ring on prenatal imaging studies.
- Barium esophagram is the recommended initial study in individuals with feeding difficulties.
- CT Chest with contrast (CPT® 71260), CTA Chest (CPT® 71275) or MRA Chest (CPT® 71555) in individuals with known or suspected vascular ring after prenatal imaging studies, chest x-ray, or barium esophagram.
- Echocardiogram is appropriate to rule out associated congenital heart disease.
 - CPT® 93303, CPT® 93306, CPT® 93320, and CPT® 93325 is appropriate for initial evaluation of individuals with vascular ring and no prior echocardiograms.

Other Vascular Malformations (PEDCH-13.2)

CHP.VM.0013.2.A
v1.0.2024

See **Pulmonary Arteriovenous Malformations (PEDCH-14.2)** for Pulmonary AVMs.

See **Vascular Anomalies (PEDPVD-2)** in the Pediatric Peripheral Vascular Disease Imaging Guidelines.

References (PEDCH-13)

v1.0.2024

1. Licari A, Manca E, Rispoli GA, et al. Congenital vascular rings: a clinical challenge for the pediatrician. *Pediatr Pulmonol*. 2015;50 (5): 511-524.
2. Poletto E, Mallon MG, Stevens RM, et al. Imaging review of aortic vascular rings and pulmonary sling. *J Am Osteopath Coll Radiol*. 2017;6(2): 5-14.
3. Hanneman K, Newman B, Chan F. Congenital Variants and Anomalies of the Aortic Arch. *RadioGraphics*. 2017;37(1):32-51. doi: 10.1148/rg.2017160033.
4. Etesami M, Ashwath R, Kanne J, Gilkeson RC, Rajiah P. Computed tomography in the evaluation of vascular rings and slings. *Insights Imaging*. 2014;5(4):507-521. doi: 10.1007/s13244-014-0343-3.
5. Backer CL, Mongé MC, Popescu AR, Eltayeb OM, Rastatter JC, Rigsby CK. Vascular rings. *Semin Pediatr Surg*. 2016;25(3):165-175. doi: 10.1053/j.sempedsurg.2016.02.009.
6. Sommburg O, Helling-Bakki A, Alrajab A, et al. Assessment of Suspected Vascular Rings and Slings and/or Airway Pathologies Using Magnetic Resonance Imaging Rather Than Computed Tomography. *Respiration*. 2018;97(2):108-118. doi: 10.1159/000492080.
7. Hart A, Lee EY. Pediatric Chest Disorders: Practical Imaging Approach to Diagnosis. *IDKD Springer Series Diseases of the Chest, Breast, Heart and Vessels*. 2019-2022. 2019:107-125. doi:10.1007/978-3-030-11149-6_10.

Congenital Chest Diseases (PEDCH-14)

Guideline

- Congenital Cystic Lung Diseases (PEDCH-14.1)
- Pulmonary Arteriovenous Malformations (PEDCH-14.2)
- Congenital Diaphragmatic Hernia (PEDCH-14.3)
- References (PEDCH-14)

Congenital Cystic Lung Diseases (PEDCH-14.1)

CHP.CD.0014.1.A

v1.0.2024

- This section includes common congenital cystic lung lesions such as:
 - Bronchogenic cyst
 - Congenital pulmonary airway malformation (congenital cystic adenomatoid malformation)
 - Congenital lobar overinflation
- CT Chest with contrast (CPT® 71260) is appropriate when a cystic lung lesion is suspected.
- MRI Chest with and without contrast (CPT® 71552) is appropriate if CT is inconclusive or if requested for pre-operative planning.

Background and Supporting Information

- Cystic lung disease may be first identified on prenatal ultrasound, or discovered incidentally on chest x-ray.

Pulmonary Arteriovenous Malformations (PEDCH-14.2)

CHP.CD.0014.2.A

v1.0.2024

- Pulmonary arteriovenous malformations (PAVMs) are vascular structures that most commonly result from abnormal communication between pulmonary arteries and pulmonary veins.
 - Chest x-ray are indicated as an initial imaging modality for individuals with known AVMs, or individuals presenting with hypoxemia and/or hemoptysis.
 - CTA or MRA is appropriate in individuals with known AVM or abnormal chest x-ray suggesting AVM for treatment planning.

Congenital Diaphragmatic Hernia (PEDCH-14.3)

CHP.CD.0014.3.A

v1.0.2024

- Congenital Diaphragmatic hernia (CDH) is a defect in the diaphragm which may allow the abdominal organs to enter the chest cavity, and may lead to compromised pulmonary function or may be associated with congenital heart disease.
 - Over 90% of the hernias occur in the posterolateral diaphragm (Bochdalek hernia) typically on the left side.
 - Most of the rest of the hernias are in the anteromedial diaphragm (Morgagni hernia).
- The vast majority of CDH are diagnosed prenatally (see **Fetal MRI [PV-15.1]** in the Pelvis Imaging Guidelines), or as an inpatient shortly after delivery.
- If there is clinical concern for CDH, chest x-ray and/or US Chest (CPT® 76604) is indicated as the initial imaging study.
- CT Chest with contrast (CPT® 71260) or MRI Chest with and without contrast (CPT® 71552) is appropriate when chest x-ray and/or US are inconclusive, or if requested for treatment planning.¹¹

References (PEDCH-14)

v1.0.2024

1. Chowdhury MM, Chakraborty S. Imaging of congenital lung malformations. *Semin Pediatr Surg.* 2015;24(4):168-175.
2. Blatter JA, Finder JD. Chapter 423: Congenital Disorders of the Lung. In: Kliegman RM, Stanton BF, St. Geme JW III, Schor NF, eds. *Nelson Textbook of Pediatrics.* 20th ed. 2016:2228-2233.
3. Blatter JA, Finder JD. Chapter 423: Congenital Disorders of the Lung. In: Kliegman RM, St. Geme JW III, Blum NJ, Shah SS, Tasker RC, Wilson KM, eds. *Nelson Textbook of Pediatrics.* 21st ed. 2020.
4. Liszewski MC, Lee EY. Neonatal Lung Disorders: Pattern Recognition Approach to Diagnosis. *AJR Am J Roentgenol.* 2018;210(5):964-975. doi: 10.2214/ajr.17.19231.
5. Hanley M, Ahmed O, Chandra A, et al. ACR Appropriateness Criteria Clinically Suspected Pulmonary Arteriovenous Malformation. *J Am Coll Radiol.* 2016;13(7):796-800. do: 10.1016/j.jacr.2016.03.020.
6. Hosman AE, Gussem EMD, Balemans WAF, et al. Screening children for pulmonary arteriovenous malformations: Evaluation of 18 years of experience. *Pediatr Pulmonol.* 2017;52(9):1206-1211. doi: 10.1002/ppul.23704.
7. Restrepo R, Lee EY. Chapter 61: The Diaphragm. In: Coley B, Saunders E., eds. *Caffey's Pediatric Diagnostic Imaging.* Philadelphia PA. 2013:587-592.
8. Ahlfeld SK. Chapter 122.10: Diaphragmatic Hernia. In: Kliegman RM, St. Geme JW III, Blum NJ, Shah SS, Tasker RC, Wilson KM, eds. *Nelson Textbook of Pediatrics.* 21st ed. 2020:944-946.
9. Karmazyn B, Shold AJ, Delaney LR, et al. Ultrasound evaluation of right diaphragmatic eventration and hernia. *Pediatr Radiol.* 2019;49(8):1010-1017. doi: 10.1007/s00247-019-04417-1.
10. Corsini I, Parri N, Coviello C, Leonardi V, Dani C. Lung ultrasound findings in congenital diaphragmatic hernia. *Eur J Pediatr.* 2019;178(4):491-495. doi: 10.1007/s00431-019-03321-y.
11. Brown, B., Eklund, M., Mehollin-Ray, A. Congenital Diaphragmatic Hernia. In: Otero, H.J., Kaplan, S.L., Medina, L.S., Blackmore, C.C., Applegate, K.E., eds. *Evidence-Based Imaging in Pediatrics. Evidence-Based Imaging.* Springer, Cham. Published online 2022 Nov;1-7. doi: 10.1007/978-3-030-38095-3_45-1.

Table of Contents

Guideline

- General Guidelines (PEDHD-1)
- Specialized Imaging Techniques (PEDHD-2)
- Pediatric Headache (PEDHD-3)
- Pediatric Head and Face Trauma (PEDHD-4)
- Sinusitis and Allergic Rhinitis (PEDHD-5)
- Epilepsy and Other Seizure Disorders (PEDHD-6)
- Macrocephaly, Microcephaly, and Hydrocephalus (PEDHD-7)
- Craniosynostosis (PEDHD-8)
- Chiari and Skull Base Malformations (PEDHD-9)
- Intracranial Aneurysms and AVM (PEDHD-10)
- Syncope (PEDHD-11)
- Pediatric Stroke (PEDHD-12)
- Benign Brain Lesions (PEDHD-13)
- Pediatric Demyelinating Diseases (PEDHD-14)
- Pituitary Dysfunction (PEDHD-15)
- Pediatric Ear Disorders (PEDHD-16)
- Autism Spectrum Disorders (PEDHD-17)
- Behavioral and Psychiatric Disorders (PEDHD-18)
- Developmental Disorders (PEDHD-19)
- Ataxia (PEDHD-20)
- Epistaxis (PEDHD-21)
- Pseudotumor Cerebri (PEDHD-22)
- Cranial Neuropathies (PEDHD-23)
- Pediatric Sleep Disorders (PEDHD-24)
- Temporomandibular Joint (TMJ)/Dental/Maxillofacial Imaging in Children (PEDHD-25)
- Movement Disorders including Tourette's Syndrome (PEDHD-26)
- Tuberous Sclerosis (PEDHD-27)
- Von Hippel-Lindau Syndrome (VHL) (PEDHD-28)
- CNS Infection (PEDHD-29)
- Scalp and Skull Lesions (PEDHD-30)
- Eye Disorders (PEDHD-31)

General Guidelines (PEDHD-1)

Guideline

Procedure Codes Associated with Head Imaging

General Guidelines (PEDHD-1.0)

Pediatric Head Imaging Age Considerations (PEDHD-1.1)

Pediatric Head Imaging Appropriate Clinical Evaluation (PEDHD-1.2)

Pediatric Head Imaging Modality General Considerations (PEDHD-1.3)

General Guidelines-Other Imaging Situations (PEDHD-1.4)

References (HDP-1)

Procedure Codes Associated with Head Imaging

HDP.GG.Codes.A

v1.0.2024

Procedure Codes Associated with Head Imaging	
MRI	CPT®
MRI Brain without contrast	70551
MRI Brain with contrast (rarely used)	70552
MRI Brain without and with contrast	70553
MRI Orbit, Face, Neck without contrast	70540
MRI Orbit, Face, Neck with contrast (rarely used)	70542
MRI Orbit, Face, Neck without and with contrast	70543
MRI Temporomandibular Joint (TMJ)	70336
Functional MRI Brain not requiring physician or psychologist	70554
Functional MRI Brain requiring physician or psychologist	70555
MR Spectroscopy	76390
Unlisted MRI procedure (for radiation planning or surgical software)	76498
MRA	CPT®
MRA Head without contrast	70544
MRA Head with contrast	70545
MRA Head without and with contrast	70546
MRA Neck without contrast	70547
MRA Neck with contrast	70548
MRA Neck without and with contrast	70549
CT	CPT®
CT Head without contrast	70450
CT Head with contrast	70460
CT Head without and with contrast	70470

Procedure Codes Associated with Head Imaging	
CT Orbits without contrast (includes temporal bone and mastoid)	70480
CT Orbits with contrast (includes temporal bone and mastoid)	70481
CT Orbits without and with contrast (includes temporal bone and mastoid)	70482
CT Maxillofacial without contrast (includes sinuses, jaw, and mandible)	70486
CT Maxillofacial with contrast (includes sinuses, jaw, and mandible)	70487
CT Maxillofacial without and with contrast (includes sinuses, jaw, and mandible)	70488
CT Neck without contrast (includes jaw, and mandible)	70490
CT Neck with contrast (includes jaw, and mandible)	70491
CT Neck without and with contrast (includes jaw, and mandible)	70492
CT Guidance for Stereotactic Localization (used for sinus surgery planning)	77011
CT Guidance for Placement of Radiation Therapy Fields	77014
Unlisted CT procedure (for radiation planning or surgical software)	76497
CTA	CPT®
CTA Head	70496
CTA Neck	70498

Nuclear Medicine	CPT®
PET Brain Metabolic Evaluation	78608
PET Brain Perfusion Evaluation	78609
PET with concurrently acquired CT; limited area (this code rarely used in pediatrics)	78814
PET with concurrently acquired CT; whole body	78816
Brain Scintigraphy Static Limited	78600
Brain Scintigraphy Limited with Vascular Flow	78601

Brain Scintigraphy Complete Static	78605
Brain Scintigraphy Complete with Vascular Flow	78606
Brain Imaging Vascular Flow	78610
Cisternogram	78630
Cerebrospinal Ventriculography	78635
Shunt Evaluation	78645
CSF Leakage Detection	78650
Radiopharmaceutical Dacryocystography	78660
Ultrasound	CPT®
Echoencephalography (Head or Cranial Ultrasound)	76506
Ophthalmic ultrasound, diagnostic; B-scan & quantitative A-scan performed same encounter	76510
Ophthalmic ultrasound, diagnostic; quantitative A-scan only	76511
Ophthalmic ultrasound, diagnostic; B-scan	76512
Ophthalmic ultrasound, diagnostic; anterior segment ultrasound, immersion (water bath) B-scan	76513
Ophthalmic ultrasound, diagnostic; corneal pachymetry, unilateral or bilateral	76514
Ophthalmic biometry by ultrasound, A-scan	76516
Ophthalmic biometry by ultrasound, A-scan, with lens power calculation	76519
Ophthalmic ultrasonic foreign body localization	76529
Soft tissues of head and neck Ultrasound (thyroid, parathyroid, parotid, etc.)	76536
Transcranial Doppler study of the intracranial arteries; complete study	93886
Transcranial Doppler study of the intracranial arteries; limited study	93888
Transcranial Doppler study of the intracranial arteries; vasoreactive study	93890
Transcranial Doppler study of the intracranial arteries; emboli detection without intravenous microbubble injection	93892
Transcranial Doppler study of the intracranial arteries;; emboli detection with intravenous microbubble injection	93893
Duplex scan of extracranial arteries; complete bilateral study	93880
Duplex scan of extracranial arteries; unilateral or limited study	93882

Non-invasive physiologic studies of extracranial arteries, complete bilateral study

93875

General Guidelines (PEDHD-1.0)

HDP.GG.0001.0.A

v1.0.2024

- A pertinent clinical evaluation including a detailed history, physical examination with a thorough neurologic examination since the onset or change in signs and/or symptoms²⁹, appropriate laboratory studies and basic imaging such as plain radiography or ultrasound should be performed prior to considering advanced imaging (CT, MR, Nuclear Medicine), unless the individual is undergoing guideline-supported scheduled imaging evaluation. A meaningful technological contact (telehealth visit, telephone call, electronic mail or messaging) since the onset or change in signs and/or symptoms²⁹, can serve as a pertinent clinical evaluation.
 - A detailed neurological exam is required prior to advanced imaging except in the following scenarios:
 - Individual is undergoing a guideline-supported scheduled follow-up imaging evaluation
 - Tinnitus, TMJ, Sinus or mastoid disease, ear pain, hearing loss, eye disease, papilledema³⁰, dental requests and epistaxis. (A relevant physical exam is still required.)
 - The request is from a neurologist, neurosurgeon, endocrinologist, otolaryngologist, or ophthalmologist who has evaluated the individual since onset of symptoms.
- Unless otherwise stated in a specific guideline section, the use of advanced imaging to screen asymptomatic individuals for disorders involving the head is not supported. Advanced imaging of the head is only indicated in individuals who have documented active clinical signs or symptoms of disease involving the head.
- Unless otherwise stated in a specific guideline section, repeat imaging studies of the head are not necessary unless there is evidence for progression of disease, new onset of disease, and/or documentation of how repeat imaging will affect individual management or treatment decisions.

Pediatric Head Imaging Age Considerations (PEDHD-1.1)

HDP.GG.0001.1.A

v1.0.2024

- Many conditions affecting the head in the pediatric population are different diagnoses than those occurring in the adult population. For those diseases which occur in both pediatric and adult populations, minor differences may exist in management due to individual age, comorbidities, and differences in disease natural history between children and adults.
- Individuals who are 18 years old or younger³¹ and any conditions not specifically discussed in the General Head Imaging Guidelines should be imaged according to the Pediatric Head Imaging Guidelines. Any conditions not specifically discussed in the Pediatric Head Imaging Guidelines should be imaged according to the General Head Imaging Guidelines. Individuals who are >18 years old should be imaged according to the General Head Imaging Guidelines, except where directed otherwise by a specific guideline section.

Pediatric Head Imaging Appropriate Clinical Evaluation (PEDHD-1.2)

HDP.GG.0001.2.A

v1.0.2024

Requests for Studies with Overlapping Fields

- There are many CPT® codes for imaging the head that have significantly overlapping fields. In the majority of cases where multiple head CPT® codes are requested, only one CPT® code is appropriate unless there is clear documentation of a need for the additional codes to cover all necessary body areas.
- See **General Guidelines - Anatomic Issues (HD-1.1)** in the Head Imaging Guidelines for the correct coding of these studies.

Pediatric Head Imaging Modality General Considerations (PEDHD-1.3)

HDP.GG.0001.3.A

v1.0.2024

- MRI
 - MRI is the preferred modality for imaging the pediatric head unless otherwise stated in a specific guideline section.
 - Due to the length of time required for MRI acquisition and the need to minimize individual movement, anesthesia is usually required for almost all infants (except neonates) and young children (age <7 years) as well as older children with delays in development or maturity. This anesthesia may be administered via oral or intravenous routes. In this individual population, MRI sessions should be planned with a goal of minimizing anesthesia exposure by adhering to the following considerations:
 - MRI procedures can be performed without and/or with contrast use as supported by these condition based guidelines. If intravenous access will already be present for anesthesia administration and there is no contraindication for using contrast, imaging without and with contrast may be appropriate if requested. By doing so, the requesting provider may avoid repetitive anesthesia administration to perform an MRI with contrast if the initial study without contrast is inconclusive.
 - Recent evidence based literature demonstrates the potential for gadolinium deposition in various organs including the brain, after the use of MRI contrast.
 - The U.S. Food and Drug Administration (FDA) has noted that there is currently no evidence to suggest that gadolinium retention in the brain is harmful and restricting gadolinium-based contrast agents (GBCAs) use is not warranted at this time. It has been recommended that GBCA use should be limited to circumstances in which additional information provided by the contrast agent is necessary and the necessity of repetitive MRIs with GBCAs should be assessed.
 - If multiple body areas are supported by eviCore guidelines for the clinical condition being evaluated, MRI/MRA of all necessary body areas should be obtained concurrently in the same anesthesia session.
- CT
 - CT is generally inferior to MRI for imaging the pediatric head, but has specific indications in which it is the preferred modality listed in specific sections of these guidelines.
 - CT should not be used to replace MRI in an attempt to avoid sedation unless listed as a recommended study in a specific guideline section.
 - CT Head without contrast (CPT[®] 70450) may be indicated for:
 - Mass effect

- Blood/blood products
- Urgent/emergent settings due to availability and speed of CT
- Trauma
- Recent hemorrhage, whether traumatic or spontaneous
- Bony structures of the head evaluations including dystrophic calcifications
- Hydrocephalus evaluation and follow-up
 - Some centers use limited non-contrast “fast or rapid MRI” (CPT® 70551) to minimize radiation exposure in children - these requests are appropriate.
- Prior to lumbar puncture in individuals with cranial complaints
- Scenarios in which MRI is contraindicated (i.e. pacemakers, ICDs, cochlear implants, aneurysm clips, orbital metallic fragments, etc.)
- CT and MR Angiography (CTA and MRA) Head and Neck
 - MRA Head may be performed without contrast (CPT® 70544), with contrast (CPT® 70545), or without and with contrast (CPT® 70546).
 - CTA Head is performed without and with contrast (CPT® 70496).
 - MRA Neck may be done either without contrast (CPT® 70547), with contrast (CPT® 70548), or without and with contrast (CPT® 70549), depending on facility preference and protocols and type of scanner.
 - CTA Neck is done with and without contrast (CPT® 70496)
- Indications for CTA and MRA Head and Neck vessels include, but are not limited to the following:
 - MRA is the preferred study in children unless contraindicated:
 - Pulsatile tinnitus
 - Hemifacial spasm if consideration for surgical decompression
 - Evaluation of stroke or TIA (See **Pediatric Stroke Initial Imaging (PEDHD-12.2)**, **Pediatric Stroke Subsequent Imaging (PEDHD-12.3)**, **Moyamoya Disease (PEDHD-12.4)**, **Sickle Cell Disease (PEDHD-12.5)** and **CNS Vasculitis and Stroke (PEDHD-12.6)** including collateral assessment)
 - Follow up of known cerebral artery stenosis
 - Trigeminal neuralgia failed medical therapy
 - Cerebral sinus thrombosis suspected with increased intracranial pressure (refractory headaches, papilledema, diagnosis of pseudotumor cerebri)
 - Aneurysm suspected with acute “thunderclap” headache syndrome and appropriate screening or evaluation of known subarachnoid hemorrhage and pseudoaneurysms (may be appropriate to limit CTA to include only the head to avoid unnecessary radiation to the individual) (See **Pediatric Intracranial Aneurysms (PEDHD-10.1)**)
 - Noninflammatory vasculopathy, including radiation vasculopathy (See **Long Term Pediatric Cancer Survivors (PEDONC-19)** in the Pediatric Oncology Imaging Guidelines)
 - Traumatic vascular injuries

- Vascular malformations, vascular anatomic variants and fistulas (See **Pediatric Intracranial Arteriovenous Malformations (AVM) (PEDHD-10.2)**)
- Arterial, including carotid dissections
- Tumors of vascular origin or involving vascular structures
- Surgical and radiation therapy localization, planning and neuronavigation
- Evaluation for vascular intervention and follow-up including postsurgical/posttreatment vascular complications
- Intra-cranial pre-operative planning if there is concern of possible vascular involvement or risk for vascular complication from procedure
- Vasculitis and collagen vascular disease (See **CNS Vasculitis and Stroke (PEDHD-12.6)**)
- Sickle cell disease (See **Sickle Cell Disease (PEDHD-12.5)**)
- Moyamoya disease (See **Moyamoya Disease (PEDHD-12.4)**)
- MRA Head without contrast (CPT® 70544), MRA Head with contrast (CPT® 70545), **OR** MRA Head without and with contrast (CPT® 70546) **OR** CTA Head (CPT® 70496) for follow up of aneurysm clipping or coiling procedures (See **Intracranial Aneurysms (HD-12.1)** in the Head Imaging Guidelines)
- CT and MR Venography (CTV and MRV) are reported with the same codes as the CTA/MRA counterpart (there is no specific code for CT/MR venography):
 - If arterial and venous CT or MR studies are both performed in the same session, only one CPT® code should be used to report both procedures
- MRA without and with contrast with venous sinus thrombosis to differentiate total from subtotal occlusion
- NOTE: Evaluation of posterior circulation disease requires both neck and head MRA/CTA to visualize the entire vertebral-basilar system.
- Ultrasound
 - Cranial ultrasound (CPT® 76506) is a non-invasive means of evaluating for intracranial abnormalities in infants with an open anterior fontanelle.
 - Transcranial Doppler ultrasonography has some utility in select populations of older children with known or suspected intracranial vascular disease.
- Nuclear Medicine
 - Nuclear medicine studies other than metabolic PET imaging on the pediatric brain or head are rarely performed in an elective outpatient setting, but the following studies are supported for the following indications:
 - Brain Scintigraphy with or without vascular flow (any one of CPT® codes: CPT® 78600, CPT® 78601, CPT® 78605, or CPT® 78606)
 - Radiopharmaceutical Localization Imaging SPECT (CPT® 78803)
 - Immunocompromised individuals with mass lesion detected on CT or MRI for differentiation between lymphoma and infection.

- Radiopharmaceutical Localization Imaging SPECT (CPT® 78803) with vasodilating agent acetazolamide (Diamox) challenge when surgery or other vascular intervention is being considered (i.e. Moyamoya).
- Brain Imaging Vascular Flow (CPT® 78610)
 - Cerebral ischemia.
 - Establish brain death (rarely done in outpatient setting).
- CSF Leakage Detection (CPT® 78650)
 - Evaluation of CSF rhinorrhea or otorrhea, or refractory post-lumbar puncture headache.
- Radiopharmaceutical Dacryocystography (CPT® 78660)
 - Suspected obstruction of nasolacrimal duct due to excessive tearing.
- 3D Rendering
 - CPT® 76377 (3D rendering requiring image post-processing on an independent workstation) or CPT® 76376 (3D rendering not requiring image post-processing on an independent workstation) can be considered in the following clinical scenarios:
 - Bony conditions:
 - Evaluation of congenital skull abnormalities in newborns, infants, and toddler (usually for preoperative planning)
 - Complex joint fractures or pelvis fractures
 - Spine fractures (usually for preoperative planning)
 - Complex facial fractures
 - Preoperative planning for other complex surgical cases
 - Cerebral angiography
 - 3D Rendering (CPT® 76377 or CPT® 76376) may be used for surgical planning and surgical follow up after craniotomy when ordered by surgical specialist.
 - 3D Rendering indications in pediatric head imaging are identical to those in the general imaging guidelines. See **3D Rendering (Preface-4.1)** in the Preface Imaging Guidelines
- The guidelines listed in this section for certain specific indications are not intended to be all-inclusive; clinical judgment remains paramount and variance from these guidelines may be appropriate and warranted for specific clinical situations.

Background and Supporting Information

- “The U.S. Food and Drug Administration (FDA) is warning that repeated or lengthy use of general anesthetic and sedation drugs during surgeries or procedures in children younger than 3 years or in pregnant women during their third trimester may affect the development of children’s brains. ... Published studies in pregnant animals and young animals have shown the use of general anesthetic and sedation drugs for more than 3 hours caused widespread loss of nerve cells in the brain. ... All the studies in children had limitations, and it is unclear whether any negative effects seen in children’s learning or behavior were due to the drugs or to other

factors, such as the underlying medical condition that led to the need for the surgery or procedure.”²⁸

General Guidelines-Other Imaging Situations (PEDHD-1.4)

HDP.GG.0001.4.A

v1.0.2024

- MRI Brain without contrast (CPT® 70551) or MRI Brain with and without contrast (CPT® 70553) can be performed for nausea and vomiting, persistent, unexplained and a negative GI evaluation
- Screening for metallic fragments before MRI should be done initially with Plain x-ray.
 - The use of CT Orbital to rule out orbital metallic fragments prior to MRI is rarely necessary
 - Plain x-rays are generally sufficient; x-ray detects fragments of 0.12 mm or more, and CT detects those of 0.07 mm or more
 - Plain x-ray is generally sufficient to screen for aneurysm clips
- CPT® 76377 (3D rendering requiring image post-processing on an independent workstation) or CPT® 76376 (3D) can be considered when performed in conjunction with conventional angiography (i.e.: conventional 4 vessel cerebral angiography).
- MRI Brain with and without contrast (CPT® 70553) is appropriate in consideration of neurosarcoidosis
- CT or MRI Perfusion (See **CT or MRI Perfusion (HD-24.5)** in the Head Imaging Guidelines)
 - Performed as part of a CT Head or MRI Brain examination in the evaluation of individuals with very new strokes or brain tumors.
 - Category III 0042T - “cerebral perfusion analysis using CT”. The study is generally limited to evaluation of acute stroke (<24 hours), to help identify individuals with stroke-like symptoms most likely to benefit from thrombolysis or thrombectomy, to assist in planning and evaluating the effectiveness of therapy for cervical or intracranial arterial occlusive disease and/or chronic cerebral ischemia, identifying cerebral hyperperfusion syndrome following revascularization and following aneurysmal subarachnoid hemorrhage. Other indications are usually regarded as investigational and experimental. Individual health plan policies should be confirmed. (See **Moyamoya Disease (PEDHD-12.4)**)
 - There is no specific CPT® code for MRI Perfusion. Perfusion weighted images are not coded separately from a MRI Brain examination. If MRI Brain is planned, no additional CPT® codes are necessary or appropriate to perform MRI perfusion.
- MRI Perfusion may be obtained with MRI Brain (CPT® 70551 **OR** CPT® 70552 **OR** CPT® 70553), no additional CPT® codes are necessary or appropriate to perform MRI perfusion.³¹

References (HDP-1)

v1.0.2024

1. Siegel MJ. Brain. In: Pediatric sonography. 5th ed. Philadelphia, Wolters Kluwer. 2018. 40-111
2. Prabhu SP, Young-Poussaint T. Pediatric central nervous system emergencies. *Neuroimag Clin N Am*. 2010;20(4):663-683. doi:10.1016/j.nic.2010.07.008
3. Patra KP, Lancaster JD, Hogg J, et al. Pediatric MRI of the Brain: a primer. *Pediatr Rev*. 2014 Mar; 35 (3):106-113
4. Reighard C, Junaid S, Jackson WM, et al. Anesthetic Exposure During Childhood and Neurodevelopmental Outcomes. <*JAMA Netw Open*>. 2022;5(6):e2217427. doi:10.1001/jamanetworkopen.2022.174
5. Nakagawa TA, Ashwal S, Mathur M, Mysore M. the Committee for Determination of. Guidelines for the determination of brain death in infants and children: An Update of the 1987 Task Force Recommendations- Executive Summary. *Annals of Neurology*. 2012;71(4):573-585. doi:10.1002/ana.23552
6. Donohoe KJ, Agrawal G, Frey KA, et al. SNMPractice Guideline for Brain Death Scintigraphy 2.0 *Journal of Nuclear Medicine Technology*. 2012;40(3):198-203. doi:10.2967/jnmt.112.105130
7. MacDonald A, and Burrell S. Infrequently performed studies in nuclear medicine: Part 2. *J Nucl Med Technol*. 2009 Mar; 37: 1-13
8. Fraum TJ, Ludwig DR, Bashir MR, et al. Gadolinium-based contrast agents: a comprehensive risk assessment. *J Magn Reson Imaging*. 2017; 46:338–353
9. FDA Drug Safety Communication: FDA warns that gadolinium-based contrast agents (GBCAs) are retained in the body; requires new class warnings. 5-16-2018 Update <https://www.fda.gov/drugs/drug-safety-and-availability/fda-drug-safety-communication-fda-warns-gadolinium-based-contrast-agents-gbcas-are-retained-body>
10. ACR -AIUM -SPR -SRU Practice parameter for the performance of neurosonography in neonates and infants. *American College of Radiology*. Revised March, 2020 <https://onlinelibrary.wiley.com/doi/10.1002/jum.15264>
11. Sodhi K, Gupta P, Saxena A, Khandelwal N, Singhi P. Neonatal cranial sonography: A concise review for clinicians. *Journal of Pediatric Neurosciences*. 2016;11(1):7. doi:10.4103/1817-1745.181261
12. Gupta P, Sodhi KS, Saxena AK, Khandelwal N, Singhi P. Neonatal cranial sonography: A concise review for clinicians[AGM1].<*J Pediatr Neurosci*>. 2016;11(1):7-13. doi:10.4103/1817-1745.181261
13. ACR-ASNR-SPR Practice Parameter for the Performance of Computed Tomography (CT) of the Extracranial Head and Neck Revised 2021. (Resolution 5). <https://www.acr.org/-/media/ACR/Files/Practice-Parameters/CT-Head-Neck>
14. Stern BJ, Royal W, Gelfand JM, et al. Definition and Consensus Diagnostic Criteria for Neurosarcoidosis. *JAMA Neurology*. 2018;75(12):1546. doi:10.1001/jamaneurol.2018.2295
15. Shosha E, Dubey D, Palace J, et al. Area postrema syndrome. *Neurology*. 2018;91(17). doi:10.1212/wnl.00000000000006392
16. Hornby PJ. Central neurocircuitry associated with emesis. *The American Journal of Medicine*. 2001;111(8):106-112. doi:10.1016/s0002-9343(01)00849-x
17. ACR-ASNR- SPR Practice Parameters for the performance of Computed Tomography (CT) perfusion in neuroradiologic imaging. Revised 2017. (Resolution 18). <https://www.acr.org/-/media/ACR/Files/Practice-Parameters/CT-Perfusion.pdf>
18. Blumfield E, Swenson DW, Iyer RS, Stanescu AL. Gadolinium-based contrast agents — review of recent literature on magnetic resonance imaging signal intensity changes and tissue deposits, with emphasis on pediatric patients. *Pediatric Radiology*. 2019;49(4):448-457. doi:10.1007/s00247-018-4304-8
19. ACR ASNR SPR Practice Parameter for the Performance and Interpretation of Cervicocerebral Computed Tomography Angiography (CTA) Revised 2020. <https://www.acr.org/-/media/ACR/Files/Practice-Parameters/CervicoCerebralCTA.pdf?la=en>
20. ACR ASNR SPR Practice Parameter for the Performance and Interpretation of Magnetic Resonance Imaging (MRI) of the Brain. Revised 2019. <https://www.acr.org/-/media/ACR/Files/Practice-Parameters/MR-Brain.pdf>
21. ACR-ASNR-SNIS-SPR Practice Parameter for the Performance of Cervicocerebral Magnetic Resonance Angiography (MRA) Revised 2020 <https://www.acr.org/-/media/ACR/Files/Practice-Parameters/cervicocerebralmra.pdf?la=en>
22. Drug Safety Communication: FDA review results in new warnings about using general anesthetics and sedation drugs in young children and pregnant women. 12/14/2016. https://www.fda.gov/drugs/drug-safety-and-availability/fda-drug-safety-communication-fda-review-results-new-warnings-about-using-general-anesthetics-and?source=govdelivery&utm_medium=email&utm_source=govdelivery
23. Drug Safety Communication: FDA approves label changes for use of general anesthetic and sedation drugs in young children. 4-27-2017 Update. <https://www.fda.gov/drugs/drug-safety-and-availability/fda-drug-safety-communication-fda-approves-label-changes-use-general-anesthetic-and-sedation-drugs>

24. Response to the FDA Med Watch December 16, 2016. American Academy of Pediatrics. https://www.aap.org/en-us/_layouts/15/WopiFrame.aspx?sourcedoc=/en-us/Documents/Response_FDA_12-16_Statement.docx&action=default
25. Artunduaga M, Liu CA, Morin CE, et al. Safety challenges related to the use of sedation and general anesthesia in pediatric patients undergoing magnetic resonance imaging examinations. *Pediatr Radiol*. 2021;51(5):724-735. doi:10.1007/s00247-021-05044-5
26. ACR–AIUM–SPR–SRU PRACTICE PARAMETER FOR THE PERFORMANCE OF NEUROSONOGRAPHY IN NEONATES AND INFANTS <https://www.acr.org/-/media/ACR/Files/Practice-Parameters/Neurosonog.pdf>
27. ACR–ASNR–SPR PRACTICE PARAMETER FOR THE PERFORMANCE OF COMPUTED TOMOGRAPHY (CT) OF THE HEAD <https://www.acr.org/-/media/ACR/Files/Practice-Parameters/CT-Head.pdf>
28. History and Physicals - Understanding the Requirements at <https://www.jointcommission.org/standards/standard-faqs/critical-access-hospital/medical-staff-ms/000002272/?p=1>
29. Aylward SC, Reem RE. Pediatric Intracranial Hypertension. *Pediatr Neurol*. 2017 Jan;66:32-43. doi: 10.1016/j.pediatrneurol.2016.08.010
30. Implementation Guide: Medicaid State Plan Eligibility Eligibility Groups Mandatory Coverage Infants and Children under Age 19 Guidance Portal. <https://www.hhs.gov/guidance/document/implementation-guide-medicaid-state-plan-eligibility-eligibility-groups-aeu-mandatory-2>

Specialized Imaging Techniques (PEDHD-2)

Guideline

Magnetic Resonance Spectroscopy (MRS, CPT® 76390) (PEDHD-2.1)
Functional Magnetic Resonance Imaging (fMRI, CPT® 70554 and CPT®
70555) (PEDHD-2.2)
PET Brain Imaging (CPT® 78608) (PEDHD-2.3)
References (HDP-2)

Magnetic Resonance Spectroscopy (MRS, CPT[®] 76390) (PEDHD-2.1)

HDP.SI.0002.1.U

v1.0.2024

- Magnetic Resonance Spectroscopy involves the analysis of the levels of certain chemicals in pre-selected voxels (small regions) on an MRI scan done at the same time.
- Uses in pediatric neuro-oncology: See **Pediatric CNS Tumors (PEDONC-4)** in the Pediatric Oncology Imaging Guidelines.
- MRS is indicated in individuals with neonatal hypoxic ischemic encephalopathy to help estimate the age of the injury.
- Uses in Metabolic Disorders:
 - See **Neurometabolic and Neurogenetic Disorders (PEDHD-19.4)**
- MRS is considered investigational for all other pediatric indications at this time.

Functional Magnetic Resonance Imaging (fMRI, CPT[®] 70554 and CPT[®] 70555) (PEDHD-2.2)

HDP.SI.0002.2.A

v1.0.2024

- MRI is indicated to define eloquent areas of the brain as part of preoperative planning for epilepsy surgery or removal of a mass lesion.
 - The documentation should be clear that brain surgery is planned.
 - Can be performed concurrently with MRI Brain (CPT[®] 70551 or CPT[®] 70553) and/or PET Brain Metabolic (CPT[®] 78608 or CPT[®] 78609).
- fMRI is considered investigational for all other pediatric indications at this time.

PET Brain Imaging (CPT® 78608) (PEDHD-2.3)

HDP.SI.0002.3.A

v1.0.2024

- Uses in pediatric neuro-oncology: See **Pediatric CNS Tumors (PEDONC-4)** in the Pediatric Oncology Imaging Guidelines.
- Metabolic (FDG) PET Brain is indicated to define active areas of the brain as part of preoperative planning for epilepsy surgery. The documentation should be clear that brain surgery is planned.
 - Can be appropriate concurrently with MRI Brain (CPT® 70551 or CPT® 70553) and/or fMRI (CPT® 70554 or CPT® 70555).
- Metabolic (FDG) PET Brain/MRI is generally not supported for neurologic conditions due to lack of standardization in imaging technique and interpretation. However, it can be appropriate in certain pediatric individuals when ALL of the following criteria are met:
 - The individual meets guideline criteria for Metabolic (FDG) PET/CT Brain AND
 - Metabolic (FDG) PET/CT Brain is not available at the treating institution AND
 - The provider requests Metabolic (FDG) PET Brain/MRI in lieu of Metabolic (FDG) PET/CT Brain
- Metabolic (FDG) PET Brain/MRI, when the above criteria are met, are reported using the code combination of Metabolic (FDG) PET Brain (CPT® 78608) and MRI Brain (CPT® 70551 or CPT® 70553). All other methods of reporting Metabolic (FDG) PET Brain/MRI are inappropriate
 - When clinically appropriate, diagnostic MRI codes can be appropriate at the same time as the Metabolic (FDG) PET Brain/MRI code combination.
- Metabolic (FDG) PET Brain is considered investigational for all other pediatric indications at this time.

References (HDP-2)

v1.0.2024

1. Hertz-Pannier L, Noulhaine M, Rodrigo S, et al. Pretherapeutic functional magnetic resonance imaging in children. *Neuroimag Clin N Am*. 2014 Nov; 24 (4): 639-653
2. Patra KP, Lancaster JD, Hogg J, et al. Pediatric MRI of the brain: a primer. *Pediatr Rev*. 2014 Mar; 35 (3):106-111
3. Schneider JF. MR Spectroscopy in children: protocols and pitfalls in non-tumorous brain pathology. *Pediatr Radiol*. 2016 Jun; 46 (7): 963-982
4. Expert Panel on Pediatric Imaging, Trofimova A, Milla SS, et al. ACR Appropriateness Criteria® Seizures-Child. *J Am Coll Radiol*. 2021;18(5S):S199-S211. doi:10.1016/j.jacr.2021.02.020
5. Ramey WL, Martirosyan NL, Lieu CM, et al. Current management and surgical outcomes of medically intractable epilepsy. *Clin Neurol Neurosurg*. 2013 Dec; 115 (12): 2411-2418
6. Ghei SK, Zan E, Nathan JE, et al. MR Imaging of Hypoxic-Ischemic Injury in Term Neonates: Pearls and Pitfalls. *RadioGraphics*. 2014;34(4):1047-1061. doi:10.1148/rg.344130080
7. Schwartz ES, Barkovich AJ. Brain and spine injuries in infancy and childhood. In: Barkovich AJ, Raybaud C, eds. *Pediatric Neuroimaging*, 6th ed. Philadelphia PA. Wolters Kluwer. 2019; 263-404
8. Boerwinkle VL, Cediell EG, Mirea L, et al. Network-targeted approach and postoperative resting-state functional magnetic resonance imaging are associated with seizure outcome. *Annals of Neurology*. 2019;86(3):344-356. doi:10.1002/ana.25547
9. Yahyavi-Firouz-Abadi N, Pillai J, Lindquist M, et al. Presurgical Brain Mapping of the Ventral Somatomotor Network in Patients with Brain Tumors Using Resting-State fMRI. *American Journal of Neuroradiology*. 2017;38(5):1006-1012. doi:10.3174/ajnr.a5132
10. Szaflarski JP, Gloss D, Binder JR, et al. Practice guideline summary: Use of fMRI in the presurgical evaluation of patients with epilepsy. *Neurology*. 2017;88(4):395-402. doi:10.1212/wnl.0000000000003532

Pediatric Headache (PEDHD-3)

Guideline

Pediatric Headache (PEDHD-3.1)

References (HDP-3)

Pediatric Headache (PEDHD-3.1)

HDP.PH.0003.1.A

v1.0.2024

- Headache is a very common complaint in school aged children and adolescents. Many of these children have a family history of one of the primary headache disorders, such as migraine or tension headache.
- A pertinent clinical evaluation including a detailed history, physical examination with a thorough neurologic examination, since the onset or change in signs and/or symptoms, and appropriate laboratory studies should be performed prior to considering advanced imaging.
- Advanced imaging is not indicated for pediatric individuals with headache in the absence of red flag symptoms.
- Sensitivity and specificity of MRI are greater than that of CT for intracranial lesions.
- MRI Brain without contrast (CPT® 70551) **OR** MRI Brain without and with contrast (CPT® 70553) is indicated for children with headaches and at least ONE of the following red flags:
 - Age \leq 5 years.
 - Headaches awakening from sleep or always present in the morning.
 - Focal findings, and/or symptoms on neurologic examination including diplopia.
 - Clumsiness (common description of gait or coordination problems in young children).
 - Headaches associated with morning nausea/vomiting.
 - Seizures
 - Papilledema on physical exam.
 - Headache precipitated by coughing, sneezing, physical exertion¹² or Valsalva.
 - Thunderclap headache.
 - Progressive worsening in headache frequency and severity without period of temporary improvement.
 - Systemic symptoms such as persistent fever, weight loss, rash, or joint pain.
 - Immunocompromised individual.
 - Individual with hypercoagulable state or bleeding disorder.
 - Known history of cancer of any type.
 - Known autoimmune or rheumatologic disease.
 - Known genetic disorder with predisposition to intracranial mass lesions.
 - History of stable chronic headaches with recent significant change in frequency or severity.
 - Focal neurological complaints including dizziness, visual change, acute hypertension or altered mental status.

- MRI Brain without contrast (CPT® 70551) **OR** MRI Brain without and with contrast (CPT® 70553) is appropriate in the presence of neurological signs and/or symptoms, including headache, after COVID-19 infection
- If concern for CNS infection – See **CNS Infection (PEDHD-29)**
- CT Head poorly visualizes the posterior fossa in children and is generally insufficient to evaluate pediatric headaches with red flag symptoms. CT is not supported in lieu of MRI solely to avoid sedation.
- CT Head without contrast (CPT® 70450) is indicated for pediatric headache with one or more of the following:
 - Sudden severe headache including thunderclap headache
 - Acute setting of suspected intracranial infection prior to lumbar puncture (CT Head with contrast CPT® 70460 if intracranial spread of disease is suspected to detect suppurative fluid collections) (See **General Guidelines-Other Imaging Situations (PEDHD-1.4)**)
 - To exclude new hemorrhage, significant mass effect, or hydrocephalus in cases including rapid clinical deterioration.
 - Recent head trauma.
 - Suspected skull or other bony involvement.
 - If MRI is contraindicated
 - Ventriculoperitoneal shunt with suspected shunt malfunction. See **Macrocephaly, Microcephaly, and Hydrocephalus (PEDHD-7)** for additional imaging.
- MRI Brain without contrast (CPT® 70551) **OR** MRI Brain without and with contrast (CPT® 70553) is appropriate if a recent CT is inconclusive.
- MRI Brain without and with contrast (CPT® 70553) is appropriate if an abnormality is identified on a noncontrasted MRI performed greater than 2 weeks, otherwise a MRI Brain with contrast (CPT® 70552) is appropriate
- MRA Head or CTA Head are not generally medically necessary in the evaluation of headache in children unless a vascular lesion has been seen or suspected on a prior MRI Brain or CT Head.
 - Concurrent MRI and MRA is generally not indicated.
- MRV Head (CPT® 70544, CPT® 70545, or CPT® 70546) is indicated in pediatric individuals with papilledema and headache. See **Papilledema/Pseudotumor Cerebri (HD-17.1)** in the Head Imaging Guidelines

References (HDP-3)

v1.0.2024

1. Expert Panel on Pediatric Imaging., Hayes LL, Palasis S, et al. ACR Appropriateness Criteria® Headache-Child. *J Am Coll Radiol*. 2018;15(5S):S78-S90. doi:10.1016/j.jacr.2018.03.017
2. Expert Panel on Pediatric Imaging, Ryan ME, Pruthi S, et al. ACR Appropriateness Criteria® Head Trauma-Child. *J Am Coll Radiol*. 2020;17(5S):S125-S137. doi:10.1016/j.jacr.2020.01.026
3. Blume HK. Pediatric headache: a review. *Pediatr Rev*. 2012;33:562-574. doi:10.1542/pir.33-12-562
4. De Vries A, Young PC, Wall E, et al. CT scan utilization patterns in pediatric patients with recurrent headache. *Pediatrics*. 2013;132(1);e1-e8. doi:10.1542/peds.digest1321
5. Trofimova A, Vey BL, Mullins ME, Wolf DS, Kadom N. Imaging of Children With Nontraumatic Headaches. *AJR Am J Roentgenol*. 2018;210(1):8-17. doi:10.2214/AJR.17.18561
6. Dao JM, Qubty W. Headache Diagnosis in Children and Adolescents. *Curr Pain Headache Rep*. 2018;22(3). doi:10.1007/s11916-018-0675-7
7. Bear JJ, Gelfand AA, Goadsby PJ, Bass N. Occipital headaches and neuroimaging in children. *Neurology*. 2017;89(5):469-474. doi:10.1212/WNL.00000000000004186
8. Loder E, Weizenbaum E, Frishberg B, Silberstein S. Choosing Wisely in Headache Medicine: The American Headache Society's List of Five Things Physicians and Patients Should Question. *Headache*. 2013;53(10):1651-1659. doi:10.1111/head.12233
9. Gofshteyn JS, Stephenson DJ. Diagnosis and Management of Childhood Headache. *Curr Probl in Pediatr and Adolesc Health Care*. 2016;46(2):36-51. doi:10.1016/j.cppeds.2015.11.003
10. Dalvi N, Sivaswamy L. Life-Threatening Headaches in Children: Clinical Approach and Therapeutic Options. *Pediatric Annals*. 2018;47(2). doi:10.3928/19382359-20180129-04
11. Klein J, Koch T. Headache in Children. *Pediatr Rev*. 2020;41(4):159-171. doi:10.1542/pir.2017-0012.
12. Sarma A, Poussaint TY. Indications and Imaging Modality of Choice in Pediatric Headache. *Neuroimaging Clin N Am*. 2019;29(2):271-289. doi:10.1016/j.nic.2019.01.007
13. Kadom N. Imaging of Headaches: Appropriateness and Differential Diagnosis. *Pediatr Ann*. 2020;49(9):e389-e394. doi:10.3928/19382359-20200819-01

Pediatric Head and Face Trauma (PEDHD-4)

Guideline

Head Trauma (PEDHD-4.1)
Facial Trauma (PEDHD-4.2)
References (HDP-4)

Head Trauma (PEDHD-4.1)

HDP.PS.0004.1.A

v1.0.2024

- In individuals with recent head trauma, a history focused on the incident and careful examination of the head, neck, and neurological function should be performed since the onset or change in signs and/or symptoms prior to considering advanced imaging.
- Advanced imaging is indicated for children with head trauma with ANY of the following red flags:
 - Loss of consciousness
 - Altered mental status or abnormal behavior
 - Known or suspected skull fracture
 - Glasgow Coma Score <15
 - Age younger than 2 years
 - Vomiting
 - Severe mechanism of injury
 - Severe or worsening headache
 - Amnesia
 - Nonfrontal scalp hematoma
- CT Head without contrast (CPT® 70450) is the primary advanced imaging study in individuals with acute head trauma.
 - CT Maxillofacial without contrast (CPT® 70486), CT Orbits/Temporal Bone without contrast (CPT® 70480), **OR** CT Cervical Spine without contrast (CPT® 72125) is indicated if there has been associated injury to those structures.
- MRI Brain without contrast (CPT® 70551) **OR** MRI Brain without and with contrast (CPT® 70553) is indicated for the following:
 - Children with an abnormal neurological exam that is not explained by the CT findings.
 - Subacute (8 days to one month after initial traumatic event) or chronic blunt head trauma with new or worsening neurological signs or cognitive symptoms
 - Children suspected of being the victims of physical abuse. See **Suspected Physical Child Abuse (PEDMS-7)** in the Pediatric Musculoskeletal Imaging Guidelines.
- Following a head injury, a repeat CT Head without contrast (CPT® 70450) **OR** MRI Brain without contrast (CPT® 70551) is indicated if the child develops fixed or fluctuating diminished mental acuity or alertness, or new abnormalities on neurological examination.
- Follow-up of known or treated parenchymal subdural or epidural hematoma may require frequent imaging during the initial 8 weeks following injury, and these requests should generally appropriate.

Facial Trauma (PEDHD-4.2)

HDP.PS.0004.2.A

v1.0.2024

- CT Maxillofacial without contrast (CPT® 70486) is the preferred imaging study in facial trauma.

Coding of Facial Imaging

- Both CT Orbital/Facial/Temporal Bone without contrast (CPT® 70480) and CT Maxillofacial (CPT® 70486) cover the structures of the orbits, sinuses, and face. Unless there is a grounded suspicion of simultaneous involvement of more posterior lesions, especially of the region involving the middle or inner ear, one of these studies only should be sufficient.
- CT Maxillofacial without contrast (CPT® 70486) is the usual study (except in obvious orbital or temporal bone trauma), but either study is appropriate.

References (HDP-4)

v1.0.2024

1. Expert Panel on Pediatric Imaging, Ryan ME, Pruthi S, et al. ACR Appropriateness Criteria® Head Trauma-Child. *J Am Coll Radiol*. 2020;17(5S):S125-S137. doi:10.1016/j.jacr.2020.01.026
2. Osmond MH, Klassen TP, Wells GA, et al. CATCH: a clinical decision rule for the use of computed tomography in children with minor head injury. *CMAJ*. 2010 Mar 9; 182 (4): 341-348. doi:10.1503/cmaj.091421
3. Nigrovic LE, Stack AM, Mannix RC, et al. Quality improvement effort to reduce Cranial CTs for children with minor blunt head trauma. *Pediatrics*. 2015; 136 (1): e227-e233
4. Homme J(JL). Pediatric Minor Head Injury 2.0. *Emergency Medicine Clinics of North America*. 2018;36(2):287-304. doi:10.1542/peds.2014-3588
5. Lumba-Brown A, Yeates KO, Sarmiento K, et al. Centers for Disease Control and Prevention Guideline on the Diagnosis and Management of Mild Traumatic Brain Injury Among Children. *JAMA Pediatr*. 2018;172(11):e182853. doi:10.1001/jamapediatrics.2018.2853
6. Babl FE, Borland ML, Phillips N, et al. Accuracy of PECARN, CATCH, and CHALICE head injury decision rules in children: a prospective cohort study. *Lancet*. 2017;389(10087):2393-2402. doi:10.1016/S0140-6763(17)30555-X
7. O'Brien WT, Caré MM, Leach JL. Pediatric Emergencies: Imaging of Pediatric Head Trauma. *Semin Ultrasound CT MR*. 2018;39(5):495-514. doi:10.1053/j.sult.2018.01.007
8. Schachar JL, Zampolin RL, Miller TS, Farinhas JM, Freeman K, Taragin BH. External validation of the New Orleans Criteria (NOC), the Canadian CT Head Rule (CCHR) and the National Emergency X-Radiography Utilization Study II (NEXUS II) for CT scanning in pediatric patients with minor head injury in a non-trauma center. *Pediatr Radiol*. 2011;41(8):971-979. doi:10.1007/s00247-011-2032-4
9. Taylor CA, Bell JM, Breiding MJ, Xu L. Traumatic Brain Injury–Related Emergency Department Visits, Hospitalizations, and Deaths — United States, 2007 and 2013. *MMWR Surveill Summ*. 2017;66(9):1-16. doi:10.15585/mmwr.ss6609a1
10. Kuppermann N, Holmes JF, Dayan PS, et al. Identification of children at very low risk of clinically-important brain injuries after head trauma: a prospective cohort study. *Lancet*. 2009;374(9696):1160-1170. doi:10.1016/s0140-6736(09)61558-0
11. Kochanek PM and Bell MJ. Neurologic Emergencies and Stabilization. Nelson Textbook of Pediatrics, Chapter 85. eds Kliegman RM, St. Geme JW III, Blum NJ, Shah SS, Tasker RC, Wilson KM. 21st edition 2020, 21st edition. 2020, pp 557-563
12. Easter JS, Bakes K, Dhaliwal J, Miller M, Caruso E, Haukoos JS. Comparison of PECARN, CATCH, and CHALICE Rules for Children With Minor Head Injury: A Prospective Cohort Study. *Ann Emerg Med*. 2014;64(2). doi:10.1016/j.annemergmed.2014.01.030
13. Harmon KG, Clugston JR, Dec K, et al. American Medical Society for Sports Medicine position statement on concussion in sport. *Br J of Sports Med*. 2019;53(4):213-225. doi:10.1136/bjsports-2018-100338.
14. ACR-ASNR-SPR Practice Parameter for the Performance of Computed Tomography (CT) of the Extracranial Head and Neck Revised 2021. (Resolution 5). <https://www.acr.org/-/media/ACR/Files/Practice-Parameters/CT-Head-Neck>
15. Gelineau-Morel RN, Zinkus TP, Le Pichon JB. Pediatric Head Trauma: A Review and Update. *Pediatr Rev*. 2019;40(9):468-481. doi:10.1542/pir.2018-0257

Sinusitis and Allergic Rhinitis (PEDHD-5)

Guideline

Sinus And Facial Imaging General Considerations (PEDHD-5.1)

Imaging Indications in Sinusitis (PEDHD-5.2)

Stereotactic CT Localization (CPT® 77011) (PEDHD-5.3)

Requests for both Head and Sinus Imaging (PEDHD-5.4)

Allergic Rhinitis (PEDHD-5.5)

Other Indications for Sinus Imaging (PEDHD-5.6)

References (HDP-5)

Sinus And Facial Imaging General Considerations (PEDHD-5.1)

HDP.AR.0005.1.A

v1.0.2024

- Acute sinusitis is a clinical diagnosis, and imaging is not indicated to establish a diagnosis. Acute bacterial sinusitis can be presumptively diagnosed in a child with acute upper respiratory infection (URI) symptoms and any of the following:
 - Persistent symptoms lasting >10 days without improvement.
 - Worsening symptoms after initial period of improvement.
 - Severe symptoms including purulent nasal discharge and fever >102.2°F for at least 3 consecutive days.
 - Presumed bacterial infections should be treated empirically with appropriate antibiotics.
 - Imaging of any kind cannot distinguish bacterial from viral sinusitis.

Imaging Indications in Sinusitis (PEDHD-5.2)

HDP.AR.0005.2.A

v1.0.2024

- Mild mucosal thickening in the paranasal sinuses or mastoids is an extremely common incidental finding noted on head imaging studies done for other indications. If there are no other abnormalities of facial structures noted, this finding is not an indication for advanced imaging of the sinuses or temporal bone.
- CT Maxillofacial without contrast (CPT® 70486) is indicated if ANY of the following is present:
 - No improvement after 10 days of appropriate antibiotic treatment (generally this will be amoxicillin/clavulanate, amoxicillin, cefdinir, cefuroxime, cefpodoxime, or ceftriaxone)
 - Recurrence of a treated infection within 8 weeks of effective treatment
 - Chronic sinusitis (persistent residual URI symptoms, including nasal obstruction, facial pressure/pain or cough¹¹ for >90 days)
 - Known or suspected fungal sinusitis
 - MRI Orbit/Face/Neck without and with contrast (CPT® 70543) is appropriate if requested instead of CT Maxillofacial
 - Preoperative evaluation to assess surgical candidacy
- CT Maxillofacial with contrast (CPT® 70487) can be performed if ANY of the following is present:
 - Orbital or facial cellulitis
 - Proptosis.
 - Abnormal visual examination
 - Ophthalmoplegia
 - Immunocompromised individual
 - Fungal or vascular lesions visualized in nasal cavity
- CT Head with contrast (CPT® 70460) **OR** MRI Brain without and with contrast (CPT® 70553) **OR** MRI Orbit/Face/Neck with and without contrast (CPT® 70543) is indicated if ANY of the following are present:
 - Focal neurologic findings
 - Altered mental status
 - Seizures
 - Concern for orbital complications
 - Concern for invasive fungal sinusitis
 - MRA Head (CPT® 70544, CPT® 70545, or CPT® 70546) **OR** CTA Head (CPT® 70496) is appropriate with these findings as well if there is clinical concern for

associated vascular complications including but not limited to mycotic aneurysm or venous sinus thrombosis.

- Repeat sinus imaging is generally not indicated for individuals who have responded satisfactorily to treatment, but is appropriate with clear documentation of the need for updated CT results to direct acute patient care decisions.

Stereotactic CT Localization (CPT® 77011) (PEDHD-5.3)

HDP.AR.0005.3.A**v1.0.2024**

- Stereotactic CT localization is frequently obtained prior to sinus surgery. The dataset is then loaded into the navigational workstation in the operating room for use during the surgical procedure. The information provides exact positioning of surgical instruments with regard to the individual's 3D CT images. In most cases, the preoperative CT is a technical-only service that does not require interpretation by a radiologist.
- For treatment planning for sinus surgery CPT® 77011: A stereotactic CT localization scan is frequently obtained prior to sinus surgery. The dataset is then loaded into the navigational workstation in the operating room for use during the surgical procedure. The imaging facility should report CPT® 77011 when performing a scan not requiring interpretation by a radiologist.
- If a diagnostic scan is performed and interpreted by a radiologist, the appropriate diagnostic CT code (e.g. CPT® 70486) should be used.
- It is not appropriate to report both CPT® 70486 and CPT® 77011 for the same CT stereotactic localization imaging session.
- 3D Rendering (CPT® 76376 or CPT® 76377) should not be reported in conjunction with CPT® 77011 (or CPT® 70486 if used). The procedure inherently generates a 3D dataset.
- Such operative studies are indicated when ordered by the operating surgeon for this purpose.

Requests for both Head and Sinus Imaging (PEDHD-5.4)

HDP.AR.0005.4.A

v1.0.2024

- CT Head does not visualize all of the sinuses.
- MRI Brain provides excellent visualization of the sinuses sufficient to recognize sinusitis, and addition of sinus CT for this purpose is unnecessary.
- In individuals being evaluated for potential sinus surgery, separate CT Sinus is often appropriate even after a MRI Brain in order to visualize obstructions to spontaneous mucus flow. See **Stereotactic CT Localization (CPT® 77011) (PEDHD-5.3)**.
- Separate head imaging is not generally indicated in individuals with a normal neurological examination who have headaches associated with sinus symptoms.
- CT or MRI Sinus is not indicated for the evaluation of headaches or neurological complaints without a more specific indication pointing to a sinus etiology

Allergic Rhinitis (PEDHD-5.5)

HDP.AR.0005.5.A

v1.0.2024

- Advanced imaging is not indicated for diagnosis or management of individuals with uncomplicated allergic rhinitis.

Other Indications for Sinus Imaging (PEDHD-5.6)

HDP.AR.0005.6.A

v1.0.2024

- See **Facial Trauma (PEDHD-4.2)** for imaging guidelines in trauma.
- CT Maxillofacial without contrast (CPT® 70486) - Congenital anomalies of facial structures.
- Cleft lip and palate can be associated with brain malformations and abnormal brain development.
 - MRI Brain (CPT® 70551) is appropriate in cases of cleft lip and/or palate.
 - MRI Orbits/Face/Neck without contrast (CPT® 70540) or MRI Orbits/Face/Neck with and without contrast (CPT® 70543)¹⁹ is appropriate if requested by surgeon or any provider in consultation with the surgeon. See **Facial Anomalies (PEDHD-8.2)**
- 3D CT reconstructed images (CPT® 76377) **OR** CPT® 76376) in conjunction with routine CT should be an integral part of the examination in evaluating craniofacial abnormalities.
- CT Maxillofacial without and with contrast (CPT® 70488) **OR** MRI Orbits/Face/Neck without and with contrast (CPT® 70543) - Tumors or other disorders of facial structures.
- Obstructive sleep apnea See **Pediatric Sleep Disorders (PEDHD-24.1)** for imaging guidelines.
- See **Sinus and Facial Imaging (HD-29)** for conditions not addressed in **Sinus and Facial Imaging (PEDHD-5)**

References (HDP-5)

v1.0.2024

1. Wald ER, Applegate KE, Bordley C, et al. Clinical Practice Guideline for the Diagnosis and Management of Acute Bacterial Sinusitis in Children Aged 1 to 18 Years. *PEDIATRICS*. 2013;132(1):e262-e280. doi:10.1542/peds.2013-1071
2. Expert Panel on Pediatric Imaging.; Tekes A, Palasis S, et al. ACR Appropriateness Criteria® Sinusitis-Child. *J Am Coll Radiol*. 2018;15(11S):S403-S412. doi:10.1016/j.jacr.2018.09.029
3. Pappas DE, and Hendley JO. Sinusitis. Nelson Textbook of Pediatrics, Chapter 408. eds Kliegman RM, St. Geme JW III, Blum NJ, Shah SS, Tasker, RC, Wilson KM. 21st edition. 2020, pp 2188-2192
4. Magit A. Pediatric Rhinosinusitis. *Otolaryngol Clin of North Am*. 2014;47(5):733-746. doi:10.1016/j.otc.2014.06.003
5. Siedman MD, Gurgel RK, Lin SY, et al. Clinical Practice Guideline.allergic rhinitis executive summary *Otolaryngol Head Neck Surg*. 2015;152(2):197-206. doi:10.1177/0194599814562166
6. AAP Releases Guideline on Diagnosis and Management of Acute Bacterial Sinusitis in Children One to 18 Years of Age. *Am Fam Physician*. 2014 Apr 15;89:676-681
7. ACR-ASNR-SPR Practice Parameter for the Performance of Computed Tomography (CT) of the Extracranial Head and Neck Revised 2021. (Resolution 5). <https://www.acr.org/-/media/ACR/Files/Practice-Parameters/CT-Head-Neck>
8. Gallagher ER, Collett BR. Neurodevelopmental and Academic Outcomes in Children With Orofacial Clefts: A Systematic Review. *Pediatrics*. 2019;144(1):e20184027. doi:10.1542/peds.2018-4027
9. Ornoy, A. Craniofacial malformations and their association with brain development: the importance of a multidisciplinary approach for treatment. *Odontology*. 2019;108(1):1-15. doi:10.1007/s10266-019-00433-7
10. Kucukguven A, Calis M, Topaloglu H, Ozgur F. Assessment of Neurologic Disorders and Rare Intracranial Anomalies Associated With Cleft Lip and Palate. *J of Craniofac Surg*. 2018;29(8):2195-2197. doi:10.1097/scs.0000000000004848
11. Brietzke SE, Shin JJ, Choi S, et al. Clinical consensus statement: pediatric chronic rhinosinusitis. *Otolaryngol Head Neck Surg*. 2014;151(4):542-553. doi:10.1177/0194599814549302

Epilepsy and Other Seizure Disorders (PEDHD-6)

Guideline

Epilepsy and Other Seizure Disorders (PEDHD-6.0)

Initial Imaging of Non-Febrile Seizures (PEDHD-6.1)

Repeat imaging indications (PEDHD-6.2)

Special Imaging Studies in Evaluation for Epilepsy Surgery (PEDHD-6.3)

Febrile Seizures (PEDHD-6.4)

References (HDP-6)

Epilepsy and Other Seizure Disorders (PEDHD-6.0)

HDP.EP.0006.0.A

v1.0.2024

- A pertinent evaluation including a detailed history, physical examination with a thorough neurologic examination, since the onset or change in signs and/or symptoms, and appropriate laboratory studies should be performed prior to considering the use of an advanced imaging (CT, MRI, Nuclear Medicine) procedure. An exception can be made if the individual is undergoing guideline-supported, scheduled follow-up imaging evaluation or request is from or in consultation with a neurologist or neurosurgeon who has seen the individual since onset of symptoms. This clinical evaluation should also include family history and (whenever possible) the accounts of eyewitnesses to the event(s).

Initial Imaging of Non-Febrile Seizures (PEDHD-6.1)

HDP.EP.0006.1.A

v1.0.2024

- MRI Brain without contrast (CPT® 70551) **OR** MRI Brain without and with contrast (CPT® 70553) is indicated for the following:
 - First-time seizure in child that has no known cause and is not associated with fever
 - Partial seizures
 - New onset primary generalized epilepsy (e.g., absence epilepsy or juvenile myoclonic epilepsy)¹ in those who are neurologically abnormal (e.g. developmental delay)
 - Focal neurologic deficits
 - Inconclusive findings on recent cranial ultrasound or CT Head
 - If individual meets criteria for MRI imaging for initial imaging of non-febrile seizure, MRI is appropriate even with a recent negative CT.
 - MRI Brain with and without contrast (CPT® 70553) is appropriate if there are history or examination findings concerning for a mass lesion or demyelinating disease.
- CT Head without contrast (CPT® 70450) is indicated for the following:
 - First-time seizure in child associated with recent head trauma, barrier to obtaining a neuroimaging study in a timely manner and should not preclude MRI imaging when requested.(Late post traumatic seizures may be better evaluated by MRI Brain without contrast (CPT® 70551) See **Head Trauma (PEDHD-4.1)**)
 - Individual cannot safely undergo MRI (avoidance of sedation is not an indication) or in urgent situations.
 - Identification of blood and calcifications
- Cranial ultrasound (CPT® 76506) for the following:
 - First-time seizure in child <30 days of age that has no known cause and is not associated with fever if the infant has an open fontanelle.
 - Cranial ultrasound is not required before MRI Brain without (CPT® 70551) for hypoxic ischemic encephalopathy (HIE) and congenital malformations.
- The following imaging tests do not generally add valuable information initially and are not indicated for the initial evaluation of seizures in children:
 - CTA Head or Neck
 - MRA Head or Neck
 - MRI Cervical, Thoracic, or Lumbar Spine

Repeat imaging indications (PEDHD-6.2)

HDP.EP.0006.2.A

v1.0.2024

- Repeat MRI Brain without contrast (CPT® 70551) **OR** MRI Brain without and with contrast (CPT® 70553) is indicated for the following:
 - Need to perform MRI using Epilepsy Protocol (typically 3T magnet with thin section angled slices through hippocampus and temporal lobes, either without or without and with contrast)
 - New or worsening focal neurologic deficits
 - Refractory or drug resistant seizures (See **Background and Supporting Information** below)
 - Change in seizure type
 - Repeat imaging for persistent seizures as per specialist request or any provider in consultation with a specialist
 - MRI Brain with contrast (CPT® 70552) **OR** MRI Brain without and with contrast (CPT® 70553) to clarify an abnormality on noncontrast MRI or if considering infection or inflammation

Background and Supporting Information

- Drug Resistant synonyms may include “Refractory”, “Intractable” or “Pharmacoresistant”
- Drug Resistant requires only 2 trials of antiepileptic medications

Special Imaging Studies in Evaluation for Epilepsy Surgery (PEDHD-6.3)

HDP.EP.0006.3.U

v1.0.2024

- Individuals with a previous MRI Brain and documentation of intractable epilepsy for which surgical treatment or another interventional modality is under active consideration, below are examples of, but not all inclusive, include:
 - Focal Resection
 - Temporal Lobe Resection
 - Extratemporal Resection
 - Lesionectomy
 - Multiple Subpial Transections
 - Laser Interstitial Thermal Therapy
 - Anatomical or Functional Hemispherectomy and Hemispherotomy
 - Corpus Callosotomy
 - Stereotactic Radiosurgery
 - Neurostimulation Device Implantations including,
 - Vagus Nerve Stimulation (VNS)
 - Responsive Neurostimulation
 - Deep Brain Stimulation
- The following requests are appropriate for presurgical evaluation:
 - MRI Brain without contrast (CPT® 70551) **OR MRI Brain** with and without contrast 3T/7T (CPT® 70553)
 - Ictal SPECT (CPT® 78803)
 - Functional MRI (f-MRI) (CPT® 70555 or CPT® 70554) See **Functional MRI (fMRI) (HD-24.2)** in the Head Imaging Guidelines
 - Metabolic (FDG) PET Brain (CPT® 78608)
 - Metabolic (FDG) PET Brain/MRI is generally not supported for neurologic conditions due to lack of standardization in imaging technique and interpretation. However, it may be appropriate in certain pediatric individuals when ALL of the following criteria are met:
 - The individual meets guideline criteria for Metabolic (FDG) PET/CT Brain AND
 - Metabolic (FDG) PET/CT Brain is not available at the treating institution AND
 - The provider requests Metabolic (FDG) PET Brain/MRI in lieu of Metabolic (FDG) PET/CT Brain

- Metabolic (FDG) PET Brain (CPT® 78608) **AND**
- MRI Brain without contrast (CPT® 70551 **OR** MRI Brain without and with contrast (CPT® 70553). All other methods of reporting Metabolic (FDG) PET Brain/MRI are inappropriate.
- When clinically appropriate, diagnostic MRI codes may be appropriate at the same time as the Metabolic (FDG) PET Brain/MRI code combination.
- MR Spectroscopy (CPT® 76390).
- See **Primary Central Nervous System Tumors-General Considerations (ONC-2.1)** in the Oncology Imaging Guidelines for additional imaging requests for surgery and/or **Neurosurgical Imaging (HD-28)** in the Head Imaging Guidelines
- When noninvasive EEG monitoring is insufficient, intracranial monitoring with stereo-EEG or grids/strips and electrodes may be required with appropriate additional imaging for neuronavigation with one of each of the following after consulting the health plan direction for unlisted codes:
 - MRI Brain with and without contrast (CPT® 70553) **OR** MRI Brain without contrast (CPT® 70551)
 - CT Head, contrast as requested CPT
 - If previous head imaging is considered inadequate or additional sequences/protocols are required **OR** is greater than 6 months old, diagnostic head imaging may be appropriate.
- Due to variances with techniques currently available for neuronavigation, the following are appropriate:
 - CTA Head (CPT® 70496) **OR** MRA Head (CPT® 70544, CPT® 70545 or CPT® 70546)
 - Post-operative imaging including after intracranial (EEG) monitoring is appropriate per neurosurgeon's request.

Febrile Seizures (PEDHD-6.4)

HDP.EP.0006.4.A

v1.0.2024

- A typical febrile seizure is a generalized seizure occurring in the presence of fever ($T > 100.4^{\circ}\text{F}/38^{\circ}\text{C}$) and no central nervous system infection in a child between the age of 6 months and 5 years.
- Neuroimaging should not be performed in the routine evaluation of children with simple febrile seizures.
- MRI Brain without contrast (CPT[®] 70551) **OR** MRI Brain without and with contrast (CPT[®] 70553) is indicated for febrile seizures in the presence of one or more of the following:
 - Seizure lasting >15 minutes
 - Partial seizures
 - Focal neurologic deficits
 - Multiple seizures within 24 hours
 - Macrocephaly (Head circumference that is greater than the 95th percentile for age and sex, established by use of measurements and CDC growth charts. See **Macrocephaly (PEDHD-7.1)**)
 - Signs and symptoms of increased intracranial pressure
 - Developmental delay
 - If CT Head without contrast (CPT[®] 70450) was performed for an initial evaluation for new onset seizure, MRI (as described above) is indicated for additional evaluation
- CT of head without contrast (CPT[®] 70450) is indicated for:
 - Evaluation of structural findings in seizure etiologies that contain dystrophic calcifications, such as with oligodendrogliomas and tuberous sclerosis.
 - Acute setting of seizure evaluation.

References (HDP-6)

v1.0.2024

1. Expert Panel on Pediatric Imaging, Trofimova A, Milla SS, et al. ACR Appropriateness Criteria® Seizures-Child. *J Am Coll Radiol*. 2021;18(5S):S199-S211. doi:10.1016/j.jacr.2021.02.020
2. Mikati MA, and Tchapyjnikov, D. Seizures in Childhood. *Nelson Textbook of Pediatrics, Chapter 611*. eds Kliegman RM, St. Geme JW III, Blum NJ, Shah SS, Tasker, RC, Wilson KM. 21st edition. 2020, pp 3086-3120
3. Sidhu R, Velayudam K, and Barnes G. Pediatric seizures. *Pediatr Rev*. 2013 Aug; 34 (8):333-341
4. Ramey WL, Martirosyan NL, Lieu CM, et al. Current management and surgical outcomes of medically intractable epilepsy. *Clin Neurol Neurosurg*. 2013 Dec; 115 (12):2411-2418
5. Schuele SU. Evaluation of Seizure Etiology From Routine Testing to Genetic Evaluation. *CONTINUUM: Lifelong Learning in Neurology*. 2019;25(2):322-342. doi:10.1212/con.0000000000000723
6. Duffner PK, Berman PH, Baumann RJ, et al. Clinical practice guideline—febrile seizures: guideline for the neurodiagnostic evaluation of the child with a simple febrile seizure. *Pediatrics*. 2011 Feb; 127 (2): 389-394
7. Cendes F, Theodore WH, Brinkmann BH, et al. Neuroimaging of epilepsy. *Handb Clin Neurol*. 2016;136:985-1014. doi: 10.1016/B978-0-444-53486-6.00051-X
8. Biassoni L, Easty M. Paediatric nuclear medicine imaging. *British Medical Bulletin*. 2017;123(1):127-148. doi:10.1093/bmb/idx025
9. Coryell J, Gaillard WD, Shellhaas RA, et al. Neuroimaging of Early Life Epilepsy. *Pediatrics*. 2018;142(3). doi:10.1542/peds.2018-0672
10. Kwan P, Arzimanoglou A, Berg AT, et al. Definition of drug resistant epilepsy: consensus proposal by the ad hoc Task Force of the ILAE Commission on Therapeutic Strategies [published correction appears in *Epilepsia*. 2010 Sep;51(9):1922]. *Epilepsia*. 2010;51(6):1069-1077. doi:10.1111/j.1528-1167.2009.02397.x
11. Gaillard WD, Chiron C, Cross JH, et al. Guidelines for imaging infants and children with recent-onset epilepsy. *Epilepsia*. 2009;50(9):2147-2153. doi:10.1111/j.1528-1167.2009.02075.x
12. Szaflarski JP, Gloss D, Binder JR, et al. Practice guideline summary: Use of fMRI in the presurgical evaluation of patients with epilepsy. *Neurology*. 2017;88(4):395-402. doi:10.1212/wnl.0000000000003532
13. Duez L, Tankisi H, Hansen PO, et al. Electromagnetic source imaging in presurgical workup of patients with epilepsy. *Neurology*. 2019;92(6). doi:10.1212/wnl.0000000000006877
14. Qiu J, Cui Y, Qi B, Sun L, Zhu Z. The application of preoperative computed tomography angiogram for hemispherectomy. *Clinics and Practice*. 2017;7(4). doi:10.4081/cp.2017.992
15. Youngerman BE, Khan FA, Mckhann GM. Stereoelectroencephalography in epilepsy, cognitive neurophysiology, and psychiatric disease: safety, efficacy, and place in therapy. *Neuropsychiatric Disease and Treatment*. 2019;Volume 15:1701-1716. doi:10.2147/ndt.s177804/
16. Iida K, Otsubo H. Stereoelectroencephalography: Indication and Efficacy. *Neurologia medico-chirurgica*. 2017;57(8):375-385. doi:10.2176/nmc.ra.2017-0008
17. Yoo JY, Panov F. Identification and treatment of drug-resistant epilepsy. *CONTINUUM: Lifelong Learning in Neurology*. 2019 Apr 1;25(2):362-80. doi: 10.1212/CON.0000000000000710
18. Orringer DA, Golby A, Jolesz F. Neuronavigation in the surgical management of brain tumors: current and future trends. *Expert review of medical devices*. 2012 Sep 1;9(5):491-500

Macrocephaly, Microcephaly, and Hydrocephalus (PEDHD-7)

Guideline

Macrocephaly (PEDHD-7.1)

Microcephaly (PEDHD-7.2)

Hydrocephalus (PEDHD-7.3)

References (HDP-7)

Macrocephaly (PEDHD-7.1)

HDP.MC.0007.1.A

v1.0.2024

- Macrocephaly is defined as head circumference that is greater than the 95th percentile for age and sex, or head circumference increasing in percentiles over two visits established by use of measurements and CDC growth charts. An online calculator to determine head circumference percentile is available at: <http://www.infantchart.com/cdc0to3headforage.php>.
- Birth to age 6 months:
 - Ultrasound Head (CPT[®] 76506) is indicated initially in individuals with an open fontanelle.
 - CT Head without contrast (CPT[®] 70450) is indicated if hydrocephalus or hemorrhage is present on ultrasound.
 - MRI Brain without contrast (CPT[®] 70551) or without and with contrast (CPT[®] 70553) is indicated for any abnormality seen on ultrasound.
- Age 7 months and older, or with closed fontanelle:
 - MRI Brain without contrast (CPT[®] 70551) or without and with contrast (CPT[®] 70553) is indicated.
 - CT is generally not indicated in this age group since uncomplicated hydrocephalus is less likely after early infancy.

Microcephaly (PEDHD-7.2)

HDP.MC.0007.2.A

v1.0.2024

- Microcephaly is defined as head circumference that is less than the 5th percentile for age and sex, or head circumference decreasing in percentiles over two visits established by use of measurements and CDC growth charts. An online calculator to determine head circumference percentile is available at: <http://www.infantchart.com/cdc0to3headforage.php>.
- MRI Brain without and with contrast (CPT[®] 70553) is indicated for all individuals.
 - CT is generally not recommended as that modality lacks the sensitivity to detect the relevant anatomical abnormalities

Hydrocephalus (PEDHD-7.3)

HDP.MC.0007.3.A

v1.0.2024

- This is the most common identifiable cause of macrocephaly. Almost all hydrocephalus is obstructive, except hydrocephalus due to choroid plexus papillomas. See **Choroid Plexus Tumors (PEDONC-4.13)** in the Pediatric Oncology Imaging Guidelines for those lesions.
- Hydrocephalus is traditionally divided into non-communicating (the obstruction lies within the course of the brain's ventricular system) and communicating (the obstruction is distal to the ventricular system).
- Ventriculomegaly refers to enlarged ventricular spaces. It is often initially found on fetal ultrasound. It can be from an obstructive cause or can be relative secondary to small brain volume. It can remain stable and may be monitored with serial ultrasound (CPT® 76506) to assess stability or MRI Brain with and without contrast (CPT® 70553) if over age 6 months. If ventriculomegaly progresses to hydrocephalus, follow imaging timelines listed below for hydrocephalus.
- Benign external hydrocephalus (aka benign extra-axial fluid collection among other names) is defined as a rapid increase in head circumference in an infant with enlarged frontal subarachnoid spaces. It is a common cause of macrocephalus and is commonly secondary to a familial large head size. See **Macrocephaly (PEDHD-7.1)** for initial imaging guidelines. It typically requires no intervention. Once diagnosed and confirmed with MRI Brain with and without contrast (CPT® 70553) no additional imaging is required unless new neurological symptoms appear, worsen or persist beyond age 4 years. If developmental motor delay See **Developmental Motor Delay (PEDHD 19.3)**.
- For CSF flow imaging See **CSF Flow Imaging (HD-24.4)** in the Head Imaging Guidelines

Initial Imaging Indications

- Age 0-6 months:
 - Screening head ultrasound examination (CPT® 76506)
 - MRI Brain without and with contrast (CPT® 70553) is indicated if ultrasound shows hydrocephalus.
 - Serial US (CPT® 76506) can be used to monitor ventricular size to determine need and timing of placement of a ventricular catheter, or performance of an endoscopic third ventriculostomy (ETV).
- Greater than 6 months old:
 - MRI Brain without and with contrast (CPT® 70553) is indicated.

Spine Imaging Indication	Imaging Study
Including, but not limited to: <ul style="list-style-type: none"> • Chiari Malformation • Malignant infiltration of meninges 	MRI Cervical Spine without and with contrast (CPT® 72156) OR MRI Cervical Spine without contrast (CPT® 72141) AND/OR MRI Thoracic Spine without contrast (CPT® 72146) OR MRI Thoracic Spine without and with contrast (CPT® 72157) AND/OR MRI Lumbar Spine without and with contrast (CPT® 72158) OR MRI Lumbar Spine without contrast (CPT® 72148)
Dandy-Walker malformation	MRI Cervical Spine without and with contrast (CPT® 72156) OR MRI Cervical Spine without contrast (CPT® 72141)

Repeat Imaging Indications including CSF flow shunting and Ventriculostomy

- Rapid MRI Brain without contrast (CPT® 70551) **OR** CT Head without contrast (CPT® 70450) is indicated for any new signs or symptoms suggesting shunt malfunction or ETV malfunction, including (but not limited to) sepsis, decreased level of consciousness, protracted vomiting, visual or neurologic deterioration, decline of mentation after initial improvement, or new or changing pattern of seizures.
- Rapid MRI Brain without contrast (CPT® 70551) **OR** CT Head without contrast (CPT® 70450) is indicated after shunt setting adjustments or as ordered by a neurologist or neurosurgeon or any provider in consultation with a neurologist or neurosurgeon.
- Rapid MRI Brain without contrast (CPT® 70551) **OR** CT Head without contrast (CPT® 70450) is indicated in the postoperative period following shunt placement or ETV, with further follow-up imaging 6-12 months after the procedure and then every 12 months for individuals with stable clinical findings.
 - Rapid MRI provides more anatomical detail and does not involve radiation exposure, but many providers use CT Head as rapid MRI is not universally available.

- For routine follow up imaging with CT a low dose protocol should be used.
- Shunting into the peritoneum (VP shunts) can give rise to abdominal complications, but these are generally symptomatic, so surveillance imaging of the abdomen is not indicated.
 - Abdominal ultrasound (CPT® 76700) is appropriate for suspicion of CSF pseudocyst formation or distal shunt outlet obstruction.
- Familial screening is not indicated for hydrocephalus except in siblings of individuals with aqueductal stenosis, for whom a one-time CT Head without contrast (CPT® 70450) or Rapid MRI Brain without contrast (CPT® 70551) is indicated.

Additional Rarely Used Studies

- Cisternogram (CPT® 78630) is rarely done in children but can be appropriate for the following:
 - Known hydrocephalus with worsening symptoms.
 - Suspected obstructive hydrocephalus.
 - Suspected normal pressure hydrocephalus with gait disturbance and either dementia or urinary incontinence.
- Cerebrospinal Ventriculography (CPT® 78635) is rarely done in children but can be appropriate for the following:
 - Evaluation of internal shunt, porencephalic cyst, or posterior fossa cyst.
- Nuclear Medicine Shunt Evaluation (CPT® 78645) and CSF Flow SPECT (CPT® 78803) are rarely done in children but can be appropriate for the following:
 - Suspected malfunction of ventriculoperitoneal, ventriculopleural, or ventriculovenous shunts.

Background and Supporting Information

- Head ultrasound can be performed while the fontanelles are still open and has excellent spatial and anatomic resolution, particularly within the first 2 months of life. After 6 months, smaller acoustic windows due to closing sutures limit the sensitivity of the examination.
- Rapid MRI Brain without contrast (CPT® 70551) provides more anatomical detail and does not involve radiation exposure, but many providers use CT Head as rapid MRI is not universally available

References (HDP-7)

v1.0.2024

1. Ashwal S, Michelson D, Plawner L, et al. Practice parameter: evaluation of the child with microcephaly (an evidence-based review). *Neurology*. 2009 Sep; 73: 887-897
2. Kinsman SL, and Johnston MV. Hydrocephalus. Nelson Textbook of Pediatrics, Chapter 591.11. eds Kliegman RM, St. Geme JW III, Blum NJ, Shah SS, Tasker RC, Wilson KM. 20th edition. 2016, pp 2814-2817
3. Boyle TP, Paldino MJ, Kimia AA, et al. Comparison of Rapid Cranial MRI to CT for Ventricular Shunt Malfunction. *Pediatrics*. 2014 July; 134 (1): e47-e54
4. Orrù E, Calloni SF, Tekes A, Huisman TAGM, Soares BP. The Child With Macrocephaly: Differential Diagnosis and Neuroimaging Findings. *American Journal of Roentgenology*. 2018;210(4):848-859
5. Raybaud A. Hydrocephalus. In: Barkovich AJ, ed. Pediatric Neuroimaging, 6th ed. Philadelphia PA. Wolters Kluwer. 2019; 907-972
6. Feng Z, Li Q, Gu J, Shen W. Update on Endoscopic Third Ventriculostomy in Children. *Pediatric Neurosurgery*. 2018;53(6):367-370. doi:10.1159/000491638
7. Wright Z, Larrew TW, Eskandari R. Pediatric Hydrocephalus: Current State of Diagnosis and Treatment. *Pediatrics in Review*. 2016;37(11):478-490. doi:10.1542/pir.2015-0134
8. Sanyal S, Duraisamy S, Garga UC. Magnetic Resonance Imaging of Brain in Evaluation of Floppy Children: A Case Series. *Iran J Child Neurol*. 2015 Fall;9(4):65-74
9. Ali AS. Magnetic Resonance Imaging (MRI) Evaluation of Developmental Delay in Pediatric Patients. *Journal Of Clinical And Diagnostic Research*. 2015. doi:10.7860/jcdr/2015/11921.5478
10. Khalatbari H, Parisi MT. Complications of CSF Shunts in Pediatrics: Functional Assessment With CSF Shunt Scintigraphy—Performance and Interpretation. *American Journal of Roentgenology*. 2020;215(6):1474-1489. doi:10.2214/ajr.20.22899
11. Zahl SM, Egge A, Helseth E, Wester K. Benign external hydrocephalus: a review, with emphasis on management. *Neurosurgical Review*. 2011;34(4):417-432. doi:10.1007/s10143-011-0327-4
12. Zahl SM, Egge A, Helseth E, Wester K. Clinical, Radiological, and Demographic Details of Benign External Hydrocephalus: A Population-Based Study. *Pediatr Neurol*. 2019;96:53-57. doi:10.1016/j.pediatrneurol.2019.01.015
13. Kestle JRW, Riva-Cambrin J. Prospective multicenter studies in pediatric hydrocephalus. *Journal of Neurosurgery: Pediatrics*. 2019;23(2):135-141. doi:10.3171/2018.10.peds18328
14. Patel SK, Zamorano-Fernandez J, Nagaraj U, Bierbrauer KS, Mangano FT. Not all ventriculomegaly is created equal: diagnostic overview of fetal, neonatal and pediatric ventriculomegaly. *Child's Nervous System*. 2019;36(8):1681-1696. doi:10.1007/s00381-019-04384-w

Craniosynostosis (PEDHD-8)

Guideline

Craniosynostosis Imaging (PEDHD-8.1)

Facial Anomalies (PEDHD-8.2)

References (HDP-8)

Craniosynostosis Imaging (PEDHD-8.1)

HDP.CS.0008.1.A

v1.0.2024

- Craniosynostosis is the premature closure of one or more cranial sutures, usually during infancy. Craniosynostosis may be caused by a genetic condition, such as Apert, Pfeiffer or Crouzon syndrome to name a few.¹⁸ Abnormal head shape **is the common clinical feature**.
- Skull x-rays and/or ultrasound should be obtained prior to considering advanced imaging. In cases of very strong consideration of craniosynostosis with surgical planning in progress, x-rays and/or ultrasound are not required.
- CT Head without contrast (CPT® 70450) is indicated in the diagnosis of craniosynostosis, with reported sensitivity near 100%. CT also detects associated intracranial pathology.
- 3D rendering (CPT® 76376 or CPT® 76377) is indicated with the initial diagnostic CT to evaluate the extent of synostosis and determine surgical candidacy or for preoperative planning.
- CT Maxillofacial without contrast (CPT® 70486) **AND** CT Orbits/Temporal Bone without contrast (CPT® 70480) are generally not necessary to evaluate individuals with craniosynostosis but are indicated if the craniosynostosis is part of a larger congenital defect which also involves the bones of the face or orbit.
- CT Maxillofacial without contrast (CPT® 70486) **AND/OR** CT Orbits/Temporal Bone without contrast (CPT® 70480) is/are supported in certain types of craniosynostosis is/are supported be when ordered by surgical specialties or in consultation with surgical specialties during surgical evaluation and planning.
- Ultrasound Head (CPT® 76506) is supported as an alternative method of assessing sutural patency in neonates and infants when radiographs are indeterminate. If inconclusive or for pre-operative planning, CT with 3D rendering is supported as discussed previously in this section.
- CT Head without contrast (CPT® 70450) is supported postoperatively at the discretion of or in consultation with the surgical specialist coordinating the individual's care.
- Positional plagiocephaly typically does NOT require advanced imaging.^{13,15,16}

Facial Anomalies (PEDHD-8.2)

HDP.CS.0008.2.A
v1.0.2024

- Congenital anomalies of facial structures
 - CT Maxillofacial without contrast (CPT[®] 70486) **OR** MRI Orbits/Face/Neck without contrast (CPT[®] 70540) **OR** MRI Orbits/Face/Neck with and without CPT[®] 70543)¹⁹.
- Facial Anomalies (such as, cleft lip and palate) can be associated with brain malformations and abnormal brain development.
 - MRI Brain without contrast (CPT[®] 70551) is supported in individuals with cleft lip and/or palate.
 - MRI Orbits/Face/Neck without contrast (CPT[®] 70540) **OR** MRI Orbits/Face/Neck with and without contrast (CPT[®] 70543)¹⁹ is supported if requested by surgeon or any provider in consultation with the surgeon.

References (HDP-8)

v1.0.2024

1. Hall KM, Besachio DA, Moore MD, et al. Effectiveness of screening for craniosynostosis with ultrasound: a retrospective review. *Pediatr Radiol*. 2017;47: 606-612
2. Rozovsky K, Udjus K, Wilson N, Barrowman NJ, Simanovsky N, Miller E. Cranial Ultrasound as a First-Line Imaging Examination for Craniosynostosis. <*Pediatrics*>. 2016;137(2):e20152230. doi:10.1542/peds.2015-2230
3. Kinsman SL, and Johnston MV. Craniosynostosis. Nelson Textbook of Pediatrics, Chapter 609.12. eds Kliegman RM, St. Geme JW III, Blum NJ, Shah SS, Tasker RC, Wilson KM. I. 21st edition. 2020, pp 3080-3082
4. Fearon JA. Evidence-based medicine: craniosynostosis. *Plast Reconstr Surg*. 2014 May; 133 (5): 1261-1275
5. Khanna P, Thapa M, Iyer R, Prasad S. Pictorial essay: The many faces of craniosynostosis. *Indian Journal of Radiology and Imaging*. 2011;21(1):49. doi:10.4103/0971-3026.76055
6. Mathijssen IM. Guideline for Care of Patients With the Diagnoses of Craniosynostosis. *Journal of Craniofacial Surgery*. 2015;26(6):1735-1807. doi:10.1097/scs.0000000000002016
7. Kim HJ, Roh HG, Lee IW. Craniosynostosis : Updates in Radiologic Diagnosis. *Journal of Korean Neurosurgical Society*. 2016;59(3):219. doi:10.3340/jkns.2016.59.3.219
8. ACR-ASNR-SPR Practice Parameter for the Performance of Computed Tomography (CT) of the Extracranial Head and Neck Revised 2021. (Resolution 5). <https://www.acr.org/-/media/ACR/Files/Practice-Parameters/CT-Head-Neck.pdf>
9. AIUM Practice Parameter for the Performance of Neurosonography in Neonates and Infants. *J Ultrasound Med*. 2020;39(5):E57-E61. doi:10.1002/jum.15264
10. Gallagher ER and Collett BR. Neurodevelopmental and Academic Outcomes in Children With Orofacial Clefts: A Systematic Review. *Pediatrics*. 2019;144(1)
11. Massimi L, Bianchi F, Frassanito P, Calandrelli R, Tamburrini G, Caldarelli M. Imaging in craniosynostosis: when and what?. *Childs Nerv Syst*. 2019;35(11):2055-2069. doi:10.1007/s00381-019-04278-x
12. Flannery AM, Tamber MS, Mazzola C, et al. Congress of Neurological Surgeons Systematic Review and Evidence-Based Guidelines for the Management of Patients With Positional Plagiocephaly: Executive Summary. *Neurosurgery*. 2016;79(5):623-624. doi:10.1227/NEU.0000000000001426
13. Linz C, Collmann H, Meyer-Marcotty P, et al. Occipital plagiocephaly: unilateral lambdoid synostosis versus positional plagiocephaly. *Arch Dis Child*. 2015;100(2):152-157. doi:10.1136/archdischild-2014-305944
14. Linz C, Kunz F, Böhm H, Schweitzer T. Positional Skull Deformities. *Dtsch Arztebl Int*. 2017;114(31-32):535-542. doi:10.3238/arztebl.2017.0535
15. Mazzola C, Baird LC, Bauer DF, et al. Congress of Neurological Surgeons Systematic Review and Evidence-Based Guideline for the Diagnosis of Patients With Positional Plagiocephaly: The Role of Imaging. *Neurosurgery*. 2016;79(5):E625-E626. doi:10.1227/NEU.0000000000001427
16. Schweitzer T, Böhm H, Meyer-Marcotty P, Collmann H, Ernestus RI, Krauß J. Avoiding CT scans in children with single-suture craniosynostosis. *Childs Nerv Syst*. 2012;28(7):1077-1082. doi:10.1007/s00381-012-1721-0
17. Wenger T, Miller D, Evans K. FGFR Craniosynostosis Syndromes Overview. 1998 Oct 20 [Updated 2020 Apr 30]. In: Adam MP, Ardinger HH, Pagon RA, et al., editors. GeneReviews® [Internet]. Seattle (WA): University of Washington, Seattle; 1993-2022. https://www.ncbi.nlm.nih.gov/books/NBK1455/pdf/Bookshelf_NBK1455.pdf
18. Abramson ZR, Peacock ZS, Cohen HL, Choudhri AF. Radiology of Cleft Lip and Palate: Imaging for the Prenatal Period and throughout Life. *Radiographics*. 2015;35(7):2053-2063. doi:10.1148/rg.2015150050

Chiari and Skull Base Malformations (PEDHD-9)

Guideline

Chiari I Malformations (PEDHD-9.1)

Basilar Impression (PEDHD-9.4)

Platybasia (PEDHD-9.5)

References (HDP-9)

Chiari I Malformations (PEDHD-9.1)

HDP.CH.0009.1.A

v1.0.2024

- Ultrasound can be utilized for initial examination in infants to determine ventricular size and associated anomalies and to provide a baseline for follow up evaluation but is not required prior to MRI.

Indication	Imaging Study
<ul style="list-style-type: none">Initial evaluation for suspected or known Chiari malformations	<p>Any of the following sets of imaging:</p> <p>MRI Brain without contrast (CPT® 70551) OR</p> <p>MRI Brain without contrast (CPT® 70551) OR</p> <p>MRI Brain without and with contrast (CPT® 70553)</p> <p>AND/OR</p> <p>MRI Cervical Spine without contrast (CPT® 72141) OR</p> <p>MRI Cervical Spine without and with contrast (CPT® 72156)</p> <p>AND/OR</p> <p>MRI Thoracic Spine without contrast (CPT® 72146) OR</p> <p>MRI Thoracic Spine without and with contrast (CPT® 72157)</p> <p>AND/OR</p> <p>MRI Lumbar Spine without contrast (CPT® 72148) OR</p> <p>MRI Lumbar Spine without and with contrast (CPT® 72158)</p>

Indication	Imaging Study
<ul style="list-style-type: none"> Repeat imaging for any of the following: <ul style="list-style-type: none"> At the discretion of or in consultation with the neurologist and/or neurosurgeon coordinating the individual's care New or worsening signs or symptoms Surgical procedure is actively being considered 	<p>Any of the following sets of imaging:</p> <p>MRI Cervical Spine without contrast (CPT® 72141) OR</p> <p>MRI Cervical Spine without and with contrast (CPT® 72156)</p> <p>AND/OR</p> <p>MRI Thoracic Spine without contrast (CPT® 72146) OR</p> <p>MRI Thoracic Spine without and with contrast (CPT® 72157)</p> <p>AND/OR</p> <p>MRI Lumbar Spine without contrast (CPT® 72148) OR</p> <p>MRI Lumbar Spine without and with contrast (CPT® 72158)</p>

- Familial screening is not indicated for Chiari I Malformations
- For CSF flow imaging, see **CSF Flow Imaging (HD-24.4)** in the Head Imaging Guidelines

Background and Supporting Information

- Chiari I malformations involve caudal displacement or herniation of the cerebellar tonsils. Chiari I may be associated with syringomyelia, and rarely with hydrocephalus. Most cases are asymptomatic and discovered incidentally on a head scan performed for another indication. When symptoms are present, they are usually nonspecific but can include headache, lower cranial nerve palsies, or sleep apnea.
- Chiari II malformations are more severe than Chiari I malformations. These individuals usually present at birth. Myelomeningocele is always present, and syringomyelia and hydrocephalus are extremely common.
- Chiari III malformations include cerebellar herniation into a high cervical myelomeningocele. Chiari IV malformations refer to complete cerebellar agenesis. Both Chiari III and IV malformations are noted at birth, and are rarely compatible with life.

- Repeat brain and spine imaging in individuals with Chiari I malformations and known syringomyelia or hydromyelia is highly individualized.

Basilar Impression (PEDHD-9.4)

HDP.CH.0009.4.A

v1.0.2024

- Basilar impression involves malformation of the occipital bone in relation to C1-2 (cervical vertebrae 1 and 2). The top of the spinal cord is inside the posterior fossa and the foramen magnum is undersized. Over time, this can lead to brain stem and upper spinal cord compression. Basilar impression can also be associated with the Chiari malformation, producing very complex anatomical abnormalities.
- MRI Brain without contrast (CPT® 70551) **AND** Cervical Spine without contrast (CPT® 72141) are indicated.
- CT Head without contrast (CPT® 70450) **AND** Cervical Spine without contrast (CPT® 72125) are also indicated if surgery is being considered.
- Basilar impression appears to be genetic, and one-time screening of first-degree relatives with MRI Brain without contrast (CPT® 70551) can be appropriate.

Platybasia (PEDHD-9.5)

HDP.CH.0009.5.A

v1.0.2024

- Platybasia is a flattening malformation of the skull base, in which the clivus has a horizontal orientation.
- MRI Brain without contrast (CPT® 70551) **OR** CT Head without contrast (CPT® 70450) is indicated to establish a diagnosis when clinically suspected, individuals are usually asymptomatic

References (HDP-9)

v1.0.2024

1. Siegel MJ. Brain. In: pediatric sonography. 5th ed. Philadelphia. Wolters Kluwer. 2018 40-111
2. Mistovich, RJ and Spiegel, DA. Cervical Anomalies and Instabilities. Nelson Textbook of Pediatrics, Chapter 700.3. eds Kliegman RM, St. Geme JW III, Blum NJ, Shah SS, Tasker RC, Wilson KM. 21st edition. 2020, pp 3649-3650
3. Strahle J, Muraszko KM, Kapurch J, et al. Chiari malformation Type I and syrinx in children undergoing magnetic resonance imaging. *J Neurosurg Pediatr.* 2011 Aug; 8 (2): 205-213
4. Strahle J, Muraszko KM, Kapurch J, et al. Natural history of Chiari malformation Type I following decision for conservative treatment. *J Neurosurg Pediatr.* 2011 Aug; 8 (2): 214-221
5. Strahle J, Muraszko KM, Garton HJL, et al. Syrinx location and size according to etiology: identification of Chiari-associated syrinx. *J Neurosurg Pediatr.* 2015 July; 16 (1): 21-9 Epub 2015 Apr 3
6. Strahle J, Smith BW, Martinez M, et al. The association between Chiari malformation Type I, spinal syrinx, and scoliosis. *J Neurosurg Pediatr.* 2015 Jun; 15 (6): 607-611
7. Victorio MC, Khoury CK. Headache and Chiari I Malformation in Children and Adolescents. *Seminars in Pediatric Neurology.* 2016;23(1):35-39
8. Radic JAE, Cochrane DD. Choosing Wisely Canada: Pediatric Neurosurgery Recommendations. *Paediatrics & Child Health.* 2018;23(6):383-387. doi:10.1093/pch/pxy012
9. Smoker WRK and Khanna G. Imaging the craniocervical junction. *Childs Nerv Syst.* 2008 Oct; 24 (10): 1123-1145
10. Kinsman SL and Johnston MV. Congenital anomalies of the central nervous system. Nelson Textbook of Pediatrics, Chapter 609. eds Kliegman RM, St. Geme JW III, Blum NJ, Shah SS, Tasker RC, Wilson KM. 21st edition. 2020, pp 3063-3082
11. D'Arco F, Ganau M. Which neuroimaging techniques are really needed in Chiari I? A short guide for radiologists and clinicians. *Childs Nerv Syst.* 2019 Oct;35(10):1801-1808. doi: 10.1007/s00381-019-04210-3

Intracranial Aneurysms and AVM (PEDHD-10)

Guideline

Pediatric Intracranial Aneurysms (PEDHD-10.1)

Pediatric Intracranial Arteriovenous Malformations (AVM) (PEDHD-10.2)

References (HDP-10)

Pediatric Intracranial Aneurysms (PEDHD-10.1)

HDP.IA.0010.1.A

v1.0.2024

- A pertinent evaluation including a detailed history, physical examination with a thorough neurologic examination, and appropriate laboratory studies should be performed prior to considering advanced imaging, unless the individual is undergoing guideline-supported scheduled follow-up imaging evaluation or request is from a neurologist or neurosurgeon who has seen the individual since onset of symptoms
- Initial study for suspected subarachnoid hemorrhage:
 - CT Head without contrast (CPT® 70450) **AND OR**
 - MRI Brain without contrast (CPT® 70551) **OR**
 - MRI Brain without and with contrast (CPT® 70553)
- If subarachnoid hemorrhage is present on CT or MRI, or lumbar puncture findings suggest hemorrhage, then the following is/are supported
 - MRA Head (CPT® 70544, CPT® 70545, **OR** CPT® 70546) **OR**
 - CTA Head (CPT® 70496) **AND/OR**
 - CT Brain Perfusion (CPT® 0042T) or MRI Brain Perfusion (CPT® 70553)
 - See also: **Background and Supporting Information**
- If findings suspicious for intracranial aneurysm on MRI, then the following is supported
 - MRA Head (CPT® 70544, CPT® 70545, **OR** CPT® 70546) **OR**
 - CTA Head (CPT® 70496)
- Initial study for individuals presenting with headache, increased intracranial pressure, seizures, or focal neurologic findings:
 - CT Head without contrast (CPT® 70450) **AND/OR**
 - MRI Brain without contrast (CPT® 70551) **OR**
 - MRI Brain without and with contrast (CPT® 70553)
 - If findings suspicious for intracranial aneurysm on prior imaging, then the following is supported:
 - MRA head (CPT® 70544, CPT® 70545, **OR** CPT® 70546) **OR**
 - CTA Head (CPT® 70496)
- Imaging for individuals with known aneurysm presenting with headache, increased intracranial pressure, seizures, or focal neurologic findings:
 - MRI Brain without contrast (CPT® 70551) **OR**
 - MRI Brain without and with contrast (CPT® 70553) **AND/OR**
 - MRA Head (CPT® 70544, CPT® 70545 **OR** CPT® 70546) **OR**
 - CTA Head (CPT® 70496)

- CTA Head (CPT® 70496) for individuals with treated aneurysms is preferred.
- MRI Brain without contrast (CPT® 70551) **OR** MRI Brain without and with contrast (CPT® 70553) **AND/OR** MRA Head (CPT® 70544, CPT® 70545, **OR** CPT® 70546) is/ are indicated for individuals with any of the following conditions (including but not limited to the conditions below) and headache, increased intracranial pressure, seizures, or focal neurologic findings:
 - Polycystic kidney disease
 - Fibromuscular dysplasia
 - Ehlers-Danlos Syndrome
 - Klippel-Trenaunay-Weber Syndrome
 - Tuberous Sclerosis
 - Moyamoya Syndrome
 - Hereditary Hemorrhagic Telangiectasia (Osler-Weber-Rendu Syndrome)
 - Pseudoxanthoma elasticum
 - Neurofibromatosis type 1
 - Kawasaki disease
 - Coarctation of the aorta
 - Patent ductus arteriosus
 - Hyper-IgE syndrome
 - 4 forms of Loeys-Dietz syndrome
 - Klinefelter syndrome
 - Alpha-glucosidase deficiency
 - Noonan syndrome
 - Pheochromocytoma
 - Alpha-1-antitrypsin deficiency
 - Presence of an azygos anterior cerebral artery
 - Marfan Syndrome
 - Bicuspid aortic valve
 - Microcephalic osteodysplastic primordial dwarfism Type II
 - Multisystemic Smooth Muscle Syndrome (MSMS)/Smooth Muscle Dysfunction Syndrome (SMDS)/ACTA2 Mutations^(Regalado,Cuoco) (See PEDHD 12.8)
- MRI Perfusion may be obtained with MRI Brain (CPT® 70551 **OR** CPT® 70552 **OR** CPT® 70553)
 - No additional CPT® codes are necessary or appropriate to perform MRI perfusion.²²
- The timing of follow-up imaging for intracranial aneurysms in children is similar to that in adults. See **Intracranial Aneurysms (HD-12.1)** in the Head Imaging Guidelines.
- Screening MRI Brain or MRA Head for aneurysms is generally not supported in asymptomatic individuals under age 20 since only 0.6 % of ruptured aneurysms

occur in the pediatric age range. However, for Multisystemic Smooth Muscle Syndrome (MSMS)/Smooth Muscle Dysfunction Syndrome (SMDS)/ACTA2 Mutations see PEDHD 12.8)

- Screening MRI Brain or MRA Head for aneurysms is not supported in individuals with coarctation of the aorta repaired before age 3 since there is not an increased risk for intracranial aneurysm in this individual population.

Background and Supporting Information

- Prior CT Head (CPT® 70450) does not exclude indication for MRI Brain without and with contrast (CPT® 70553) **OR** MRI Brain without contrast (CPT® 70551)
- Unlike adults, the majority of pediatric aneurysms are caused by genetic or developmental defects rather than environmental or lifestyle factors.
- Pediatric aneurysms most commonly present with subarachnoid hemorrhage, headache, increased intracranial pressure, seizure activity, or focal neurologic findings.

Pediatric Intracranial Arteriovenous Malformations (AVM) (PEDHD-10.2)

HDP.IA.0010.2.A

v1.0.2024

- A pertinent evaluation including a detailed history, physical examination with a thorough neurologic examination, and appropriate laboratory studies should be performed prior to considering advanced imaging, unless the individual is undergoing guideline-supported scheduled follow-up imaging evaluation or request is from or in consultation with a neurologist or neurosurgeon who has seen the individual since onset of symptoms.
- Vascular malformations include arteriovenous, venous, cavernous, and capillary malformations and vein of Galen Malformations.

Disorders	Indications (any of the following)	Supported Imaging
<ul style="list-style-type: none"> • Any aneurysmal and/or AVM Disorder listed in this guideline 	<ul style="list-style-type: none"> • When MRI is contraindicated • Any emergency setting 	<ul style="list-style-type: none"> • CT Head without contrast (CPT® 70450) AND OR • CTA Head (CPT® 70496)AND OR • CTA Neck (CPT® 70498)
<ul style="list-style-type: none"> • Suspected Vein of Galen malformation in the neonate 	<ul style="list-style-type: none"> • Confirmation by Ultrasound Head (CPT® 76506) 	<ul style="list-style-type: none"> • MRI Brain without contrast (CPT® 70551)OR • MRI Brain without and with contrast (CPT® 70553OR • Catheter Angiography to precisely identify the feeding arteries and draining vein, especially if embolization is planned
<ul style="list-style-type: none"> • Low Flow Malformations 	<ul style="list-style-type: none"> • When requested by a neurologist or neurosurgeon or any provider in consultation with a neurologist or neurosurgeon 	<ul style="list-style-type: none"> • MRA Head (CPT® 70544, CPT® 70545, OR CPT® 70546)OR • CTA Head (CPT® 70496)

Disorders	Indications (any of the following)	Supported Imaging
<ul style="list-style-type: none"> Suspected AVM after the neonate period 	<ul style="list-style-type: none"> When requested by a neurologist or neurosurgeon or any provider in consultation with a neurologist or neurosurgeon 	<ul style="list-style-type: none"> MRI Brain without and with contrast (CPT® 70553)OR MRI Brain without contrast (CPT® 70551)
<ul style="list-style-type: none"> Known AVM 	<ul style="list-style-type: none"> When requested by a neurologist or neurosurgeon or any provider in consultation with a neurologist or neurosurgeon 	<ul style="list-style-type: none"> MRI Brain without contrast (CPT® 70551)OR MRI Brain without and with contrast (CPT® 70553)AND/OR MRA Head (CPT® 70544, CPT® 70545, OR CPT® 70546)OR CTA Head (CPT® 70496)
<ul style="list-style-type: none"> Hereditary Hemorrhagic Telangiectasia (HHT; Osler-Weber-Rendu Syndrome) 	<ul style="list-style-type: none"> Suspected based on Family History with at least one affected first-degree relative. (biological parent or sibling) At diagnosis, especially if confirmed by Genetic Testing Screening for confirmed HHT Clinical signs or symptoms concerning for disease progression When requested by a neurologist or neurosurgeon or any provider in consultation with a neurologist or neurosurgeon or geneticist 	<ul style="list-style-type: none"> MRI Brain without and with contrast (CPT® 70553)OR MRI Brain without contrast (CPT® 70551)AND/OR MRA Head (CPT® 70544, CPT® 70545 OR CPT® 70546)OR CTA Head (CPT® 70496)

Disorders	Indications (any of the following)	Supported Imaging
<ul style="list-style-type: none"> Capillary Malformation-Arteriovenous Malformation (CM-AVM) 	<ul style="list-style-type: none"> Suspected based on Family History with at least one affected first-degree relative (biological parent or sibling) At diagnosis, especially if confirmed by Genetic Testing Screening for confirmed CM-AVM Clinical signs or symptoms concerning for disease progression When requested by a neurologist or neurosurgeon or any provider in consultation with a neurologist or neurosurgeon or geneticist 	<ul style="list-style-type: none"> MRI Brain without and with contrast (CPT® 70553) OR MRI Brain without contrast (CPT® 70551) AND/OR MRA Head (CPT® 70544, CPT® 70545 OR CPT® 70546) OR CTA Head (CPT® 70496) AND/OR MRI Cervical Spine without and with contrast (CPT® 72156) OR MRI Cervical Spine without contrast (CPT® 72141) AND/OR MRI Thoracic Spine without and with contrast (CPT® 72157) OR MRI Thoracic Spine without contrast (CPT® 72146)^(Bayrak-Toydemir)

Disorders	Indications (any of the following)	Supported Imaging
<ul style="list-style-type: none"> Cerebral Cavernous Malformations (CCM) 	<ul style="list-style-type: none"> Suspected based on Family History with at least one affected first-degree relative (biological parent or sibling). At diagnosis, especially if confirmed by Genetic Testing Screening for confirmed CCM Clinical signs or symptoms concerning for disease progression When requested by a neurologist or neurosurgeon or geneticist or any provider in consultation with a neurologist or neurosurgeon or geneticist 	<ul style="list-style-type: none"> MRI Brain without and with contrast (CPT® 70553) OR MRI Brain without contrast (CPT® 70555)AND/OR MRA Head (CPT® 70544, CPT® 70545 OR CPT® 70546) OR CTA Head (CPT® 70496)AND/OR MRI Cervical Spine without and with contrast (CPT® 72156) OR MRI Cervical Spine without contrast (CPT® 72141)AND/OR MRI Thoracic Spine without and with contrast (CPT® 72157) OR MRI Thoracic Spine without contrast (CPT® 72146)

Disorders	Indications (any of the following)	Supported Imaging
<ul style="list-style-type: none"> Microcephalic Osteodysplastic Primordial Dwarfism, Type II (MOPDII)^(Bober) 	<ul style="list-style-type: none"> Suspected based on Family History with at least one affected first-degree relative (biological parent or sibling) At diagnosis, especially if confirmed by Genetic Testing Screening for confirmed MOPDII, repeated annually Clinical signs or symptoms concerning for disease progression When requested by a neurologist or neurosurgeon or any provider in consultation with a neurologist or neurosurgeon or geneticist 	<ul style="list-style-type: none"> MRI Brain without contrast (CPT[®] 70551) OR MRI Brain without and with contrast (CPT[®] 70553)AND/OR MRA Head (CPT[®] 70544, CPT[®] 70545, OR CPT[®] 70546) OR CTA Head (CPT[®] 70496)AND/OR MRA Neck without contrast (CPT[®] 70547, CPT[®] 70548 OR CPT[®] 70549) OR CTA Neck (CPT[®] 70498)
<ul style="list-style-type: none"> Sturge-Weber Syndrome 	<ul style="list-style-type: none"> At diagnosis Clinical signs or symptoms concerning for disease progression When requested by a neurologist or neurosurgeon or any provider in consultation with a neurologist or neurosurgeon 	<ul style="list-style-type: none"> MRI Brain without and with contrast (CPT[®] 70553) OR MRI Brain without contrast (CPT[®] 70551)AND/OR MRI Orbits/Face/Neck without and with contrast (CPT[®] 70543) OR MRI Orbits/Face/Neck without contrast (CPT[®] 70540)

Additional indications

- CT Head without contrast (CPT® 70450) may be indicated for:
 - Mass effect
 - Urgent/emergent settings due to availability and speed of CT
 - Trauma
 - Recent hemorrhage, whether traumatic or spontaneous
 - Prior to lumbar puncture in individuals with cranial complaints
 - Scenarios in which MRI is contraindicated (i.e. pacemakers, ICDs, cochlear implants, aneurysm clips, orbital metallic fragments, etc.)

Background and Supporting Information

- Prior CT Head (CPT® 70450) does not exclude indication for MRI Brain without and with contrast (CPT® 70553) **OR** MRI Brain without contrast (CPT® 70551)
- Most intracranial AVMs are congenital, vary widely in their location and type, and are discovered at birth due to associated clinical findings or incidentally later in life. Certain hereditary conditions are associated with an increased risk for AVM development.
- Vascular malformations include arteriovenous, venous, cavernous, and capillary malformations. The vein of Galen malformation is the most common arteriovenous malformation, presenting in neonates with signs of high output congestive heart failure or later in infancy of childhood with signs of hydrocephalus. Low flow venous, cavernous, and capillary malformations may be asymptomatic and discovered incidentally or they may present in childhood with seizures or neurologic findings secondary to intracranial hemorrhage.
- Hereditary AVMs usually have an autosomal dominant pattern of inheritance.^{5,6,13, 20}

References (HDP-10)

v1.0.2024

1. Montaser A, Smith ER. Intracranial Vascular Abnormalities in Children. *Pediatr Clin North Am*. 2021;68(4):825-843. doi:10.1016/j.pcl.2021.04.010
2. Beez T, Steiger H-J, and Hnggi D. Evolution of management of intracranial aneurysms in children: a systematic review of the modern literature. *J Child Neurol*. 2016; 31 (6): 773-783
3. Alvarez H, and Castillo M. Genetic markers and their influence on cerebrovascular malformations. *Neuroimag Clin N Am*. 2015 Feb; 25 (1): 69-82
4. Donti A, Spinardi L, Brighenti M, et al. Frequency of intracranial aneurysms determined by magnetic resonance angiography in children (mean age 16) having operative or endovascular treatment of coarctation of the aorta (mean age 13). *Am J Cardiol*. 2015 epub 2015 Aug; 116 (4):630-633
5. McDonald J, Stevenson DA. Hereditary Hemorrhagic Telangiectasia. In: Adam MP, Mirzaa GM, Pagon RA, et al., eds. <GeneReviews®>. Seattle (WA): University of Washington, Seattle; June 26, 2000. [Updated 2021 Nov 24
6. Morrison L, and Akers A. Cerebral cavernous malformation, familial. *GeneReviews™* [Internet] eds. Pagon RA, Adam MP, Bird TD et al. version August 4, 2016
7. Linscott LL, Leach JL, Jones BV, et al. Developmental venous anomalies of the brain in children—imaging spectrum and update. *Pediatr Radiol*. 2016 Mar; 46 (3): 394-406
8. Ghali MGZ, Srinivasan VM, Cherian J, et al. Pediatric Intracranial Aneurysms: Considerations and Recommendations for Follow-Up Imaging. *World Neurosurgery*. 2018;109:418-431
9. Bernstein, Daniel. Diseases of the Blood Vessels (Aneurysms and Fistulas). Nelson Textbook of Pediatrics, Chapter 471. eds eds Kliegman RM, St. Geme JW III, Blum NJ, Shah SS, Tasker RC, Wilson KM. 21st edition. 2020, pp 2487-2490
10. Derdeyn CP, Zipfel GJ, Albuquerque FC, et al. Management of Brain Arteriovenous Malformations: A Scientific Statement for Healthcare Professionals From the American Heart Association/American Stroke Association. *Stroke*. 2017;48(8). doi:10.1161/str.000000000000134
11. Martin KL. Vascular Disorders. Nelson Textbook of Pediatrics, Chapter 669. eds eds Kliegman RM, St. Geme JW III, Blum NJ, Shah SS, Tasker RC, Wilson KM. 21st edition. 2020, pp 3461-3469
12. Bober MB, Jackson AP. Microcephalic Osteodysplastic Primordial Dwarfism, Type II: a Clinical Review. *Current Osteoporosis Reports*. 2017;15(2):61-69. doi:10.1007/s11914-017-0348-1
13. Bober MB, Jackson AP. Erratum to: Microcephalic Osteodysplastic Primordial Dwarfism, Type II: a Clinical Review. *Curr Osteoporos Rep*. 2017;15(4):399. doi:10.1007/s11914-017-0389-5
14. Madhuban A, van den Heuvel F, van Stuijvenberg M. Vein of Galen Aneurysmal Malformation in Neonates Presenting With Congestive Heart Failure. *Child Neurol Open*. 2016;3:2329048X15624704. Published 2016 Apr 4. doi:10.1177/2329048X15624704
15. Siegel MJ. Brain. In: pediatric sonography. 5th ed. Philadelphia. Wolters Kluwer. 2018 40-111
16. Hoh BL, Ko NU, Amin-Hanjani S, et al. 2023 Guideline for the Management of Patients With Aneurysmal Subarachnoid Hemorrhage: A Guideline From the American Heart Association/American Stroke Association [published online ahead of print, 2023 May 22]. <Stroke>. 2023;10.1161/STR.0000000000000436. doi:10.1161/STR.0000000000000436
17. Faughnan ME, Mager JJ, Hets SW, et al. Second International Guidelines for the Diagnosis and Management of Hereditary Hemorrhagic Telangiectasia. <Ann Intern Med>. 2020;173(12):989-1001.doi:10.7326/M20-1443
18. Expert Panel on MR Safety, Kanal E, Barkovich AJ, et al. ACR guidance document on MR safe practices: 2013. <J Magn Reson Imaging>. 2013;37(3):501-530. doi:10.1002/jmri.24011
19. Sabeti S, Ball KL, Bhattacharya SK, et al. Consensus Statement for the Management and Treatment of Sturge-Weber Syndrome: Neurology, Neuroimaging, and Ophthalmology Recommendations. <Pediatr Neurol>. 2021;121:59-66. doi:10.1016/j.pediatrneurol.2021.04.013
20. Bayrak-Toydemir P, Stevenson DA. Capillary Malformation-Arteriovenous Malformation Syndrome. In: Adam MP, Mirzaa GM, Pagon RA, et al., eds. <GeneReviews®>. Seattle (WA): University of Washington, Seattle; February 22, 2011. Updated: September 12, 2019
21. Hammill AM, Wusik K, Kasthuri RS. Hereditary hemorrhagic telangiectasia (HHT): a practical guide to management. <Hematology Am Soc Hematol Educ Program>. 2021;2021(1):469-477. doi:10.1182/hematology.2021000281
22. ACR-ASNR-SPR PRACTICE PARAMETER FOR THE PERFORMANCE OF INTRACRANIAL MAGNETIC RESONANCE PERFUSION IMAGING. Revised 2022 (Resolution 24). <PRACTICE PARAMETER MR_Perfusion>. <https://www.acr.org/-/media/ACR/Files/Practice-Parameters/mr-perfusion.pdf?la=en>
23. Regalado ES, Mellor-Crummey L, De Backer J, et al. Clinical history and management recommendations of the smooth muscle dysfunction syndrome due to ACTA2 arginine 179 alterations. <Genet Med>. 2018;20(10):1206-1215. doi:10.1038/gim.2017.245

24. Cuoco JA, Busch CM, Klein BJ, et al. ACTA2 Cerebral Arteriopathy: Not Just a Puff of Smoke. <*Cerebrovasc Dis*>. 2018;46(3-4):161-171. doi:10.1159/000493863

Syncope (PEDHD-11)

Guideline

Syncope (PEDHD-11.1)

References (HDP-11)

Syncope (PEDHD-11.1)

HDP.SY.0011.1.A
v1.0.2024

- Syncope in children is almost always neurocardiogenic (vasovagal) in nature. Intracranial mass lesions do not cause isolated syncope. Syncope and seizure activity can often be challenging to distinguish for unwitnessed syncope.
- Advanced imaging of the brain is not indicated for individuals with isolated syncope without focal neurologic findings. See **Syncope (PEDCD-5)** in the Pediatric Cardiac Imaging Guidelines and **Epilepsy and Other Seizure Disorders (PEDHD-6)** for additional imaging considerations.
- There is no role for advanced neuroimaging for Postural Tachycardia Syndrome (POTS).

References (HDP-11)

v1.0.2024

1. Friedman KG, and Alexander ME. Chest pain and syncope in children: a practical approach to the diagnosis of cardiac disease. *J Pediatr.* 2013 Sep; 163 (3):896-901
2. Cannon B, and Wackel P. Syncope. *Pediatr Rev.* 2016 Apr; 37 (4):159-168
3. Fant C, Cohen A. Syncope In Pediatric Patients: A Practical Approach To Differential Diagnosis And Management In The Emergency Department. *Pediatric emergency medicine practice.* 2017 Apr;14(4):1-28
4. Dala AS and Van Hare GF. Syncope. Nelson Textbook of Pediatrics, Chapter 87. eds Kliegman RM, St. Geme JW III, Blum NJ, Shah SS, Tasker RC, Wilson KM. 21stth edition. 2020, pp 569-571

Pediatric Stroke (PEDHD-12)

Guideline

Pediatric Stroke General Considerations (PEDHD-12.1)

Pediatric Stroke Initial Imaging (PEDHD-12.2)

Pediatric Stroke Subsequent Imaging (PEDHD-12.3)

Moyamoya Syndrome/Disease (PEDHD-12.4)

Sickle Cell Disease (PEDHD-12.5)

CNS Vasculitis and Stroke (PEDHD-12.6)

COVID-19 and Multisystem Inflammatory Syndrome in Children (MIS-C)(PEDHD-12.7)

Multisystemic Smooth Muscle Syndrome (MSMS)/Smooth Muscle

Dysfunction Syndrome (SMDS)/ACTA2 Mutations (PEDHD-12.8)

References (HDP-12)

Pediatric Stroke General Considerations (PEDHD-12.1)

HDP.PS.0012.1.A

v1.0.2024

- Imaging indications are the same for neonates as for older children.

Pediatric Stroke Initial Imaging (PEDHD-12.2)

HDP.PS.0012.2.A

v1.0.2024

- Children may not present with typical stroke findings. MRI Brain without contrast (CPT® 70551) or MRI Brain without and with contrast (CPT® 70553) is appropriate in the presence of neurological signs and/or symptoms with concern for stroke.⁴
- ANY of the following studies are indicated for evaluation.
 - CT Head without contrast (CPT® 70450) **OR** MRI Brain without contrast (CPT® 70551)
 - MRA Head (CPT® 70544, CPT® 70545, **OR** CPT® 70546) **OR** CTA Head (CPT® 70496)
 - For suspected carotid dissection CTA Neck (CPT® 70498) **OR** MRA Neck (CPT® 70547, CPT® 70548 **OR** CPT® 70549)
 - Note: Both MRA **OR** CTA Head **AND** Neck are needed to visualize the posterior vertebrobasilar circulation for evaluation of the vertebrobasilar stroke/TIA (vertigo associated with diplopia, dysarthria, bifacial numbness or ataxia) or concern for arterial dissection (risks may include premature stroke [under age 50], head or neck trauma, fibromuscular dysplasia, Ehlers-Danlos syndrome, and chiropractic neck manipulation)
- In individuals with COVID-19, See **COVID-19 and Multisystem Inflammatory Syndrome in Children (MIS-C) (PEDHD-12.7)**

Pediatric Stroke Subsequent Imaging (PEDHD-12.3)

HDP.PS.0012.3.A

v1.0.2024

- MRI Brain without contrast (CPT® 70551) **OR** MRI Brain without and with contrast (CPT® 70553) is indicated for any new or worsening neurological findings or seizure activity.
- Repeat imaging for follow up and resolution of stroke or hemorrhage as determined by a neurology specialist or any provider in consultation with a neurology specialist.
 - MRI Brain without contrast (CPT® 70551) **OR** MRI Brain without and with contrast (CPT® 70553)
 - MRA Head/MRV Head (CPT® 70544, CPT® 70545 **OR** CPT® 70546) **OR** CTA Head/CTV Head (CPT® 70496) for follow-up of known cerebral artery stenosis or thrombosis^{4,7}
 - Other surveillance imaging indications after stroke are listed in the disease-specific sections.

Background and Supporting Information

- CT and MR Venography (CTV and MRV) are reported with the same codes as the CTA/MRA counterpart (there is no specific code for CT/MR venography):
 - If arterial and venous CT or MR studies are both performed in the same session, only **one** CPT® code is used to report both procedures
 - If an arterial CTA **OR** MRA study has been performed and subsequently a repeat study is needed to evaluate the venous anatomy, then this study is supported
 - If a venous CTV **OR** MRV study has been performed and subsequently a repeat study is needed to evaluate the arterial anatomy, then this study is supported
 - MRA without and with contrast with venous sinus thrombosis to differentiate total from subtotal occlusion

Moyamoya Syndrome/Disease (PEDHD-12.4)

HDP.PS.0012.4.A

v1.0.2024

Initial imaging

- Below are indicated for initial evaluation of Moyamoya Syndrome Disease:
 - MRI Brain without contrast (CPT® 70551) **OR**
 - MRI Brain without and with contrast (CPT® 70553) **AND/OR**
 - MRA Head (CPT® 70544, CPT® 70545, **OR** CPT® 70546) **AND/OR**
 - MRA Neck (CPT® 70547, CPT® 70548, **OR** CPT® 70549)
 - If MRA is contraindicated or not readily available, then CTA Head (CPT® 70496) **AND/OR** CTA Neck (CPT® 70498) are supported.
- MRI Perfusion may be obtained with MRI Brain (CPT® 70551 **OR** CPT® 70552 **OR** CPT® 70553), No additional CPT® codes are necessary or appropriate to perform MRI perfusion³³

Repeat imaging for Moyamoya Syndrome/Disease

- MRA Head (CPT® 70544, CPT® 70545, **OR** CPT® 70546) every 12 months.
 - CTA Head (CPT® 70496) can be appropriate if MRI/MRA is contraindicated or not readily available
- MRI Brain without contrast (CPT® 70551) **OR** MRI Brain without and with contrast (CPT® 70553) every 12 months
- Radiopharmaceutical Localization Imaging SPECT (CPT® 78803) with vasodilating agent acetazolamide (Diamox) challenge can be appropriate when surgery or other vascular intervention is being considered.
- CT Perfusion (CPT® 0042T) **OR** MRI Perfusion (CPT® 70551 **OR** CPT® 70552 **OR** CPT® 70553)³³ (see **Background and Supporting Information**) is indicated for the following:
 - Prior to change in treatment
 - Post-surgical
 - When requested by any provider coordinating care with a neurologist or neurosurgeon^(Choudri2014,ACR2017)
- CT or MRI Perfusion see **General Guidelines-Other Imaging Situations (PEDHD-1.4)**
- MRI Perfusion may be obtained with MRI Brain (CPT® 70551 **OR** CPT® 70552 **OR** CPT® 70553), No additional CPT® codes are necessary or appropriate to perform MRI perfusion.³³

Screening imaging for Moyamoya Disease^(HAN2014, KIM2016)

- Screening is **NOT** indicated for Moyamoya SYNDROME.
 - See **Background and Supporting Information** for Moyamoya DISEASE versus Moyamoya SYNDROME
- Screening with any of the following for Moyamoya Disease is indicated for first degree relatives (biological parent, full sibling, or biological child) of individuals with Moyamoya Disease:
 - MRA Head (CPT[®] 70544, CPT[®] 70545, **OR** CPT[®] 70546) **OR**
 - Transcranial Doppler (TCD) Ultrasound (CPT[®] 93886 or CPT[®] 93888)
 - See **Transcranial Doppler (CPT[®]93886) (HD-24.8)** in the Head Imaging Guideline
 - If MRA is contraindicated or not readily available, then CTA Head (CPT[®] 70496) is supported
 - See **General Guidelines-Other Imaging Situations (PEDHD-1.4)**
- MRI Perfusion may be obtained with MRI Brain (CPT[®] 70551 **OR** CPT[®] 70552 **OR** CPT[®] 70553), No additional CPT[®] codes are necessary or appropriate to perform MRI perfusion.³³

Background and supporting information

- Moyamoya disease (MMD) is a rare cerebrovascular disease characterized by progressive spontaneous bilateral occlusion of the intracranial internal carotid arteries (ICA) and their major branches (middle cerebral artery [MCA], and anterior cerebral artery [ACA]) with compensatory capillary collaterals as an expression of pathologically increased angiogenic activity resembling a "puff of smoke" (Japanese: Moyamoya) on cerebral angiography.²⁶ Moyamoya Disease is most prevalent in individuals with East Asian ancestry. Up to 15% of individuals with Moyamoya Disease may have a family history of Moyamoya Disease.^{23, 24}
- Moyamoya Disease is distinguished from Moyamoya Syndrome (MMS). MMD is a primary disease process. MMS is a secondary process that occurs in response to another underlying pathological process that causes stenosis of intracranial blood vessels.²⁵ There are two peaks of incidence with different clinical presentations, at around 10 years and 30-40 years. The peak appears to occur later in women than men. In children, ischemic symptoms, especially transient ischemic attacks, are predominant. Intellectual decline, seizures, and involuntary movements are also more common in this age group. In contrast, adult patients present with intracranial hemorrhage more often than pediatric patients.²⁴

Sickle Cell Disease (PEDHD-12.5)

HDP.PS.0012.5.A

v1.0.2024

- The following imaging is indicated for all sickle cell individuals with a severe phenotype (Hgb SS or Hgb S β^0)
 - Transcranial Doppler (TCD) Ultrasound (CPT[®] 93886 or CPT[®] 93888) annually for all individuals age 2 to 16:
 - A short interval repeat study is indicated for individuals with conditional (170-199 cm/sec) flow results, or with individuals undergoing transfusion therapy.
 - TCD for children aged 17 years old may be appropriate on a case-by-case basis.
 - See **Transcranial Doppler (CPT[®] 93886) (HD-24.8)** in the Head Imaging Guidelines for other indications for this modality and **Stroke/TIA (HD-21.1)** in the Head Imaging Guidelines
 - After 17 years old, for individuals with a history of abnormal TCDs, TCDs may be repeated every 3 months.
 - TCD is not indicated for individuals with other phenotypes (Hgb SC, Hgb S β^+).
 - See indications below for advanced imaging with MR or CT.
- MRI Brain without contrast (CPT[®] 70551) **OR** MRI Brain without and with contrast (CPT[®] 70553) is indicated for any of the following:
 - 2 non-imaging Transcranial Doppler (TCD) measurements of ≥ 200 cm/sec or a single measurement of >220 cm/sec or 2 assessment TCD measurements ≥ 185 cm/sec or a single measurement >205 cm/sec.
 - Persistently abnormal TCD velocities
 - For more regarding TCD, see **Background and Supporting Information**
 - Screening to detect silent cerebral infarcts
 - New symptoms or cognitive impairment occurs or a change in academic performance
 - After an infarct-like lesion is identified, repeat every 12-24 months to assess for cerebral infarct progression
 - Prior to any change in therapy²⁰⁻²⁵

Background and Supporting Information

- TCD is used to screen for overt and silent infarctions and monitor response to transfusion therapy
- Individuals with sickle cell disease are at significantly increased risk for stroke and silent infarction, beginning at a very young age. Recent advances allow physicians to identify individuals at high risk for stroke and begin a primary stroke prevention program.

- Identification of silent cerebral infarction is important because treatment with prophylactic red cell transfusions to maintain hemoglobin S levels at <30% of total hemoglobin may reduce recurrent stroke and extent of neurologic damage.

CNS Vasculitis and Stroke (PEDHD-12.6)

HDP.PS.0012.6.A

v1.0.2024

- MRI Brain without and with contrast (CPT® 70553) is the recommended initial study for all individuals with vasculitis and suspected CNS involvement, whether primary or secondary.
 - A normal MRI Brain almost always completely excludes intracranial vasculitis
 - MRA Head (CPT® 70544, CPT® 70545, or CPT® 70546) is indicated for inconclusive MRI findings suggesting medium or large vessel vasculitis.
 - Individuals with aggressive disease being treated with systemic therapy can have imaging for treatment response every 3 months during active treatment.
 - Annual surveillance imaging is appropriate to detect progressive vascular damage that may require intervention.

COVID-19 and Multisystem Inflammatory Syndrome in Children (MIS-C) (PEDHD-12.7)

HDP.PS.0012.7.A
v1.0.2024

- Symptoms of MIS-C may include some or all of the following:
 - Headache, irritability
 - Mucocutaneous changes similar to Kawasaki disease (i.e. strawberry tongue, red cracked lips, rash of hands and/or feet)
 - Polymorphous or vasculitic rash
 - Non-exudative conjunctivitis
 - Tachycardia, hypotension
 - Cough, shortness of breath
 - Abdominal pain, vomiting, diarrhea
 - Lymphadenopathy, joint pain, sore throat
- MRA is the preferred study in children however, CTA Head (CPT® 70496) and/or Neck (CPT® 70498) is appropriate if MRA is contraindicated

Indication	Imaging Study
<ul style="list-style-type: none"> • Imaging for neurological signs and/or symptoms, including headache, after known or presumed COVID-19 infection 	<ul style="list-style-type: none"> • Any or all of the following sets of imaging: <ul style="list-style-type: none"> • MRI Brain without contrast (CPT® 70551) OR • MRI Brain without and with contrast (CPT® 70553) • MRA Head (CPT® 70544, CPT®70545 OR CPT® 70546) OR • CTA Head (CPT® 70496) AND/OR • MRA Neck (CPT® 70547 OR CPT® 70548 OR CPT® 70549) OR • CTA Neck (CPT® 70498)

- If concern for CNS infection – See **CNS Infection (PEDHD-29.1)**
- See **Multisystem inflammatory syndrome in children (MIS-C) (PEDCD-12)** in the Pediatric Cardiac Imaging Guidelines

Background and Supporting Information

- COVID-19 infections in children are generally mild in comparison to that of adults, however a post viral syndrome in children has become increasingly noted.

Multisystem Inflammatory Syndrome in Children (MIS-C) can cause an inflammatory vasculopathy, prothrombotic state and/or post viral myocarditis in children who have had a COVID-19 infection caused by SARS-CoV-2. The child may have had minor symptoms or been asymptomatic at the time of COVID-19 infection but the virus can trigger endothelial injury and activation of the IL-1 pathway similar to that in Kawasaki disease and acute rheumatic fever.

Multisystemic Smooth Muscle Syndrome (MSMS)/Smooth Muscle Dysfunction Syndrome (SMDS)/ACTA2 Mutations (PEDHD-12.8)

HDP.PS.0012.8.A

v1.0.2024

Head/Neck Evaluations for MSMS/SMDS

Initial Evaluations

- Confirmed ACTA2 Mutation
 - MRI Brain without and with contrast (CPT® 70553) with **OR** without Perfusion **AND/OR**
 - MRA Head (CPT® 70544, CPT® 70545, or CPT® 70546) **AND/OR**
 - MRA Neck (CPT® 70547, CPT® 70548, or CPT® 70549)

As requested by neurologist and/or neurosurgeon and/or geneticist and/or provider coordinating care with a neurologist and/or neurosurgeon and/or geneticist

- MRI Brain without and with contrast (CPT® 70553) with **OR** without Perfusion **AND/OR**
 - MRA Head (CPT® 70544, CPT® 70545, **OR** CPT® 70546) **AND/OR**
 - MRA Neck (CPT® 70547, CPT® 70548, **OR** CPT® 70549)
-
- MRI Perfusion may be obtained with MRI Brain (CPT® 70551 **OR** CPT® 70552 **OR** CPT® 70553), No additional CPT® codes are necessary or appropriate to perform MRI perfusion.³³
 - Because radiation is a known risk factor for moyamoya disease. MRI/MRA Head is recommended instead of Computed Tomography (CT/CTA).²⁹
 - Conventional catheter angiogram should be reserved for patients with focal neurologic symptoms or evidence on MRA or transcranial Doppler (TCD) of critical or progressive narrowing of the cerebral arteries.³¹
 - See **Screening for Suspected Peripheral Artery Disease/Aneurysmal Disease (PVD-2)**.

Background and Supporting Information

- Smooth muscle dysfunction syndrome (SMDS)/Multisystemic Smooth Muscle Syndrome (MSMS) presents with a recognizable pattern of complications, including congenital mydriasis, patent ductus arteriosus (PDA), pulmonary arterial hypertension, aortic and other arterial aneurysms, moyamoya-like cerebrovascular disease, intestinal hypoperistalsis and malrotation, and hypotonic bladder.²⁹
- SMDS/MSMS is caused by heterozygous mutations of the ACTA2 altering arginine 179, most commonly p.Arg179His. With a single exception, all cases are due to de novo mutations.²⁹

References (HDP-12)

v1.0.2024

1. Naula S, Yeshokumar AK and Banwell BL. Central Nervous System Vasculitis. Nelson Textbook of Pediatrics, Chapter 620. eds Kliegman RM, St. Geme JW III, Blum NJ, Shah SS, Tasker RC, Wilson KM. 21st edition. 2020, pp 3219-3221
2. Robertson RL, et al. American College of Radiology ACR Appropriateness Criteria® Cerebrovascular Disease–Child. New 2019. 1-23
3. Ferriero DM, Fullerton HJ, Bernard TJ, et al. Management of Stroke in Neonates and Children: A Scientific Statement From the American Heart Association/American Stroke Association. *Stroke*. 2019;50(3). doi:10.1161/str.000000000000183
4. Mirsky DM, Beslow LA, Amlie-Lefond C, et al. Pathways for Neuroimaging of Childhood Stroke. *Pediatric Neurology*. 2017;69:11-23. doi:10.1016/j.pediatrneurol.2016.12.004
5. Soliman M, Laxer R, Manson D, et al. Imaging of systemic vasculitis in childhood. *Pediatr Radiol*. 2015 Aug; 45(8):1110-1125
6. Khalaf A, Iv M, Fullerton H, Wintermark M. Pediatric Stroke Imaging. *Pediatric Neurology*. 2018;86:5-18. doi:10.1016/j.pediatrneurol.2018.05.008
7. Zaza A, Auschwitz T, Klimo P, Mossa-Basha M, Choudhri A. Noninvasive vascular imaging of moyamoya: Diagnosis, followup, and surgical planning. *Journal of Pediatric Neuroradiology*. 2015;03(01):13-20. doi:https://doi.org/10.3233/pnr-14082
8. Dlamini Nomazulu and deVeber GA. Pediatric Stroke. Nelson Textbook of Pediatrics, Chapter 471. eds Kliegman RM, St. Geme JW III, Blum NJ, Shah SS, Tasker RC, Wilson KM. 21st edition. 2020, pp 3209-3212
9. Smith-Whitley K. Sick Cell Disease. Nelson Textbook of Pediatrics, Chapter 489.1. eds Kliegman RM, St. Geme JW III, Blum NJ, Shah SS, Tasker RC, Wilson KM. 21st edition. 2020, pp 2541-2550
10. ACR-ASNR- SPR Practice Parameters for the performance of Computed Tomography (CT) perfusion in neuroradiologic imaging. Revised 2017. Resolution 18. <https://www.acr.org/-/media/ACR/Files/Practice-Parameters/CT-Perfusion.pdf>
11. Debaun MR, Jordan LC, King AA, et al. American Society of Hematology 2020 guidelines for sickle cell disease: prevention, diagnosis, and treatment of cerebrovascular disease in children and adults. *Blood Advances*. 2020;4(8):1554-1588. doi:10.1182/bloodadvances.2019001142
12. McMurray JC, May JW, Cunningham MW, Jones OY. Multisystem Inflammatory Syndrome in Children (MIS-C), a Post-viral Myocarditis and Systemic Vasculitis-A Critical Review of Its Pathogenesis and Treatment. *Frontiers in Pediatrics*. 2020;8:626182. doi:https://doi.org/10.3389/fped.2020.626182
13. Jiang Li, et al. COVID-19 and multisystem inflammatory syndrome in children and adolescents. *Lancet Infect Dis* 2020;20:e276–88
14. Panda PK, Sharawat IK, Panda P, Natarajan V, Bhakat R, Dawman L. Neurological Complications of SARS-CoV-2 Infection in Children: A Systematic Review and Meta-Analysis [published online ahead of print, 2020 Sep 10]. *J Trop Pediatr*. 2020;fmaa070. doi:10.1093/tropej/fmaa070
15. Lin JE, Asfour A, Sewell TB, et al. Neurological issues in children with COVID-19. *Neurosci Lett*. 2021;743:135567. doi:10.1016/j.neulet.2020.135567
16. Bernaudin F, Verlhac S, Arnaud C, et al. Long-term treatment follow-up of children with sickle cell disease monitored with abnormal transcranial Doppler velocities. *Blood*. 2016;127(14):1814-1822. doi:10.1182/blood-2015-10-675231
17. Nickel RS, Kamani NR. Ethical Challenges in Hematopoietic Cell Transplantation for Sickle Cell Disease. *Biol Blood Marrow Transplant*. 2018;24(2):219-227. doi:10.1016/j.bbmt.2017.08.034
18. Krishnamurti L. Hematopoietic Cell Transplantation for Sickle Cell Disease. *Frontiers in Pediatrics*. 2021;8. doi:10.3389/fped.2020.551170
19. King AA, McKinstry RC, Wu J, et al. Functional and Radiologic Assessment of the Brain after Reduced-Intensity Unrelated Donor Transplantation for Severe Sickle Cell Disease: Blood and Marrow Transplant Clinical Trials Network Study 0601. *Biol Blood Marrow Transplant*. 2019;25(5):e174-e178. doi:10.106/j.bbmt.2019.01.008
20. Kanter J, Liem RI, Bernaudin F, et al. American Society of Hematology 2021 guidelines for sickle cell disease: stem cell transplantation. *Blood Adv*. 2021;5(18):3668-3689. doi:10.1182/bloodadvances.2021004394C
21. Jordan LC, Kassim AA, Wilkerson KL, Lee CA, Waddle SL, Donahue MJ. Using novel magnetic resonance imaging methods to predict stroke risk in individuals with sickle cell anemia. *Hematol Oncol Stem Cell Ther*. 2020;13(2):76-84. doi:10.1016/j.hemonc.2019.12.009
22. Hirtz D, Kirkham FJ. Sickle Cell Disease and Stroke. *Pediatr Neurol*. 2019;95:34-41. doi:10.1016/j.pediatrneurol.2019.02.018
23. Han C, Feng H, Han YQ, et al. Prospective screening of family members with moyamoya disease patients. *PLoS One*. 2014;9(2):e88765. Published 2014 Feb 19. doi:10.1371/journal.pone.0088765

24. Kim JS. Moyamoya Disease: Epidemiology, Clinical Features, and Diagnosis. <J Stroke>. 2016;18(1):2-11. doi:10.5853/jos.2015.01627
25. Berry JA, Cortez V, Toor H, Saini H, Siddiqi J. Moyamoya: An Update and Review. <Cureus>. 2020;12(10):e10994. Published 2020 Oct 16. doi:10.7759/cureus.10994
26. Mertens R, Graupera M, Gerhardt H, et al. The Genetic Basis of Moyamoya Disease. <Transl Stroke Res>. 2022;13(1):25-45. doi:10.1007/s12975-021-00940-2
27. Moyamoya disease: MedlinePlus Genetics. medlineplus.gov. <https://medlineplus.gov/genetics/condition/moyamoya-disease/>
28. Scott RM, Smith ER. Moyamoya disease and moyamoya syndrome. <N Engl J Med>. 2009;360(12):1226-1237. doi:10.1056/
29. Regalado ES, Mellor-Crummey L, De Backer J, et al. Clinical history and management recommendations of the smooth muscle dysfunction syndrome due to ACTA2 arginine 179 alterations. <Genet Med>. 2018;20(10):1206-1215. doi:10.1038/gim.2017.245
30. Cuoco JA, Busch CM, Klein BJ, et al. ACTA2 Cerebral Arteriopathy: Not Just a Puff of Smoke. <Cerebrovasc Dis>. 2018;46(3-4):161-171. doi:10.1159/000493863
31. Du L, Jiang H, Li J, Duan T, Zhou C, Yan F. Imaging methods for surgical revascularization in patients with moyamoya disease: an updated review. <Neurosurg Rev>. 2022;45(1):343-356. doi:10.1007/s10143-021-01596-0
32. Li J, Jin M, Sun X, et al. Imaging of Moyamoya Disease and Moyamoya Syndrome: Current Status. J Comput Assist Tomogr. 2019;43(2):257-263. doi:10.1097/RCT.0000000000000834
33. ACR–ASNR–SPR PRACTICE PARAMETER FOR THE PERFORMANCE OF INTRACRANIAL MAGNETIC RESONANCE PERFUSION IMAGING. Revised 2022 (Resolution 24). PRACTICE PARAMETER MR_Perfusion. <https://www.acr.org/-/media/ACR/Files/Practice-Parameters/mr-perfusion.pdf? la=en>.

Benign Brain Lesions (PEDHD-13)

Guideline

Arachnoid Cysts (PEDHD-13.1)

Pineal/Colloid Cysts (PEDHD-13.2)

Acoustic Neuromas (PEDHD-13.3)

References (HDP-13)

Arachnoid Cysts (PEDHD-13.1)

HDP.BL.0013.1.A

v1.0.2024

- Arachnoid cysts arise in the middle or posterior fossa, and the majority of lesions are discovered incidentally and do not require surgical intervention.
- MRI Brain without contrast (CPT® 70551) **OR** MRI Brain without and with contrast (CPT® 70553) is indicated for initial evaluation of arachnoid cysts if not already completed.
- Repeat MRI Brain is not indicated for most individuals with arachnoid cysts, but is appropriate for the following:
 - Annual MRI Brain without contrast (CPT® 70551) **OR** MRI Brain without and with contrast (CPT® 70553) until age 4 if diagnosed at a younger age
 - New or worsening headache or focal neurologic deficits suggesting progression of cyst
 - Preoperative planning
 - When requested by a specialist or any provider in consultation with a specialist

Pineal/Colloid Cysts (PEDHD-13.2)

HDP.BL.0013.2.A

v1.0.2024

- Pineal cysts are generally discovered incidentally and do not require surgical intervention.
- MRI Brain without contrast (CPT® 70551) **OR** MRI Brain without and with contrast (CPT® 70553) is indicated for initial evaluation of pineal cysts if not already completed.
- Repeat MRI Brain is not indicated for most individuals with pineal cysts, but MRI Brain without contrast (CPT® 70551) **OR** MRI Brain without and with contrast (CPT® 70553) is appropriate for the following:
 - New or worsening headache or focal neurologic deficits suggesting progression of cyst
 - Preoperative planning
- Repeat MRI Brain without contrast (CPT® 70551) **OR** MRI Brain without and with contrast (CPT® 70553) is appropriate for colloid cysts for the following:
 - In the presence of symptoms including syncope
 - Evaluation of CSF flow (CPT® 70551)
 - When requested by a specialist or any provider in consultation with a specialist

Acoustic Neuromas (PEDHD-13.3)

HDP.BL.0013.3.A

v1.0.2024

- See **Neurofibromatosis 2 (PEDPND-2.2)** in the Pediatric Peripheral Nerve Disorders Imaging Guidelines

References (HDP-13)

v1.0.2024

1. Hervey-Jumper SL, Cohen-Gadol AA, and Maher CO. Neurosurgical management of congenital malformations of the brain. *Neuroimag Clin N Am*. 2011 Aug; 21 (3): 705-717
2. Jussila M-P, Olsén P, Salokorpi N, Suo-Palosaari M. Follow-up of pineal cysts in children: is it necessary? *Neuroradiology*. 2017;59(12):1265-1273
3. Bulas D. Prenatal Imaging. *Caffey's Pediatric Diagnostic Imaging*, Chapter 621. Coley BR, et al. 13th edition. 2019, pp 245-250
4. Koral Korgun. Neoplasia. *Caffey's Pediatric Diagnostic Imaging*, Chapter 12. Coley BR, et al. 13th edition. 2019, pp 93-96
5. Lagman C, Rai K, Chung LK, et al. Fatal Colloid Cysts: A Systematic Review. *World Neurosurgery*. 2017;107:409-415. doi:10.1016/j.wneu.2017.07.183
6. Goldbrunner R, Weller M, Regis J, et al. EANO guideline on the diagnosis and treatment of vestibular schwannoma. *Neuro-Oncology*. 2019;22(1):31-45. doi:10.1093/neuonc/noz153
7. Muhlestein WE, Maher CO. Incidental Intracranial Cysts in Children. *Pediatr Clin North Am*. 2021;68(4):775-782. doi:10.1016/j.pcl.2021.04.005

Pediatric Demyelinating Diseases (PEDHD-14)

Guideline

Pediatric Demyelinating Disease General Considerations (PEDHD-14.1)

Multiple Sclerosis (MS) (PEDHD-14.2)

Acute Disseminated Encephalomyelitis (ADEM) and Other Pediatric Demyelinating Disorders (PEDHD-14.3)

Transverse Myelitis (PEDHD-14.4)

References (HDP-14)

Pediatric Demyelinating Disease General Considerations (PEDHD-14.1)

HDP.DD.0014.1.A

v1.0.2024

- MRI Brain without and with contrast (CPT® 70553) is the preferred imaging study for evaluation of pediatric demyelinating disease.
 - MRI Cervical Spine without and with contrast (CPT® 72156 **AND** MRI Thoracic Spine without and with contrast CPT® 72157) is also indicated for evaluation of pediatric demyelinating disease.
 - MRI Lumbar Spine without and with contrast (CPT® 72158) is not indicated unless the individual has a tethered cord or other anatomic abnormality causing caudal displacement of the filum terminalis.
- CT imaging is generally not indicated in the evaluation of demyelinating disease.
- Metabolic (FDG) PET Brain (CPT® 78608) and MR Spectroscopy (CPT® 76390) are considered investigational for evaluation of pediatric demyelinating diseases.
- See **Neurometabolic and Neurogenetic Disorders (PEDHD-19.4)**

Multiple Sclerosis (MS) (PEDHD-14.2)

HDP.DD.0014.2.A

v1.0.2024

- Multiple sclerosis is less common in children. About 4% of MS cases are diagnosed before age 18, and only ~0.7% of all MS cases begin before age 10.
- Ataxia, optic neuritis, diplopia, and transverse myelitis are common presentations. MS can present as an acute encephalitis-like illness, especially in childhood.
- Among children with suspected demyelinating diseases, the principal differential diagnosis is often between MS and acute disseminated encephalomyelitis.
- MRI Brain without and with contrast (CPT® 70553) **AND** Cervical Spine (CPT® 72156 **AND** Thoracic Spine without and with contrast (CPT® 72157) is indicated for initial diagnosis in individuals with clinical signs and/or symptoms suggestive of MS.
 - MRI Brain (CPT® 70551) and Spinal Cord (CPT® 72141 and CPT® 72146) without contrast is appropriate if there is a contraindication to gadolinium administration.
- MRI Brain without contrast (CPT® 70551), which is preferred, OR MRI Brain without and with contrast (CPT® 70553) is indicated every 6 months for disease monitoring whether or not receiving treatment.¹⁹
 - MRI Cervical Spine without and with contrast (CPT® 72156) **AND/OR** MRI Thoracic Spine without and with contrast (CPT® 72157) **OR** Cervical Spine without contrast (CPT® 72141) **AND/OR** CPT® 72146) is (are) indicated every 12 months or for new signs or symptoms.¹⁹
 - MRI Orbits/Face/Neck without and with contrast (CPT® 70543) may be considered if optic neuritis is suspected, in addition to the above scenario
 - Symptoms suggestive of Progressive Multifocal Leukoencephalopathy (PML) during Tysabri therapy (or other medications with similar risk).
 - Screening for individuals on natalizumab (Tysabri) or other drugs with risk of PML (Progressive Multifocal Leukoencephalopathy)
 - MRI Brain without and with contrast (CPT® 70553) **OR** MRI Brain without contrast (CPT® 70551) every 6 months while on treatment
 - MRI Brain without and with contrast (CPT® 70553) **OR** MRI Brain without contrast (CPT® 70551) every 3-6 months for high risk individuals positive for serum JC virus antibody and >18 months natalizumab exposure
- If a non-contrast study shows incidental evidence of possible demyelinating disease, repeat with MRI Brain with contrast (CPT® 70552) is appropriate within 2 weeks of previous non-contrast study as the presence of enhancing lesions may be helpful in confirming the diagnosis. If non-contrast study was performed more than 2 weeks prior to the performance of the repeat imaging, an MRI Brain with and without contrast (CPT® 70553) is appropriate.

Background and Supporting Information

- Medications with similar risks of PML as Tysabri include: Dimethyl fumarate (Tecfidera), Fingolimod (Gilenya), Ocrelizumab (Ocrevus), Mavenclad (cladribine),

Vumerity (diroximel fumarate), Soliris (eculizaumab), Zeposia (ozanimod), Lemtrada (alemtuzumab), Bafiertam (monomethyl fumarate), Rituxan (rituximab).

- 3D imaging in the evaluation of Multiple Sclerosis is not supported as a separate code as most scanners are capable of 3D acquisitions or other imaging sequences may be done.

Acute Disseminated Encephalomyelitis (ADEM) and Other Pediatric Demyelinating Disorders (PEDHD-14.3)

HDP.DD.0014.3.A

v1.0.2024

- ADEM has an acute onset, and is more common among younger children than MS, but the signs and symptoms overlap significantly, and distinguishing between MS and ADEM can be challenging based on clinical examination alone.
- MRI Brain (CPT® 70553) and Spinal Cord (CPT® 72156 and CPT® 72157) without and with contrast is indicated for initial diagnosis in individuals with clinical signs and/or symptoms suggestive of ADEM.
 - MRI Brain (CPT® 70551) and Spinal Cord (CPT® 72141 and CPT® 72146) without contrast is indicated if there is a contraindication to gadolinium.
- MRI Brain without and with contrast (CPT® 70553) **AND** MRI Cervical Spine (CPT® 72156 **AND** MRI Thoracic Spine without contrast (CPT® 72157) is/are indicated every 3 months for 1 year following diagnosis or if ordered out of sequence or beyond one year by a neurologist or any provider in consultation with a neurologist.
 - MRI Brain without contrast (CPT® 70551) **AND** Cervical Spine (CPT® 72141) **AND** MRI Thoracic Spine without contrast (CPT® 72146) is/are indicated if there is a contraindication to gadolinium.
 - Most individuals will have complete clinical recovery by 12 months, while stable MRI abnormalities (gliosis) may persist. These findings do not require additional imaging unless the individual develops new neurologic symptoms. Prolonged symptoms or return of symptoms may represent a different demyelinating disorder.
- There are other pediatric demyelinating disorders that are less common but have clinical overlap with multiple sclerosis and ADEM such as (but not limited to):
 - Neuromyelitis optica (NMO) spectrum disorders (See **Neuromyelitis Optica and NMO Spectrum Disorders (HD 16.2)**)
 - Anti-MOG syndromes (anti-myelin oligodendrocyte glycoprotein) (See **Anti-MOG Syndromes (HD 16.3)**)
 - Demyelination secondary to infectious or inflammatory disorders (e.g. transverse myelitis) (See **General Guidelines – Other Imaging Situations (HD 1.7)**)
- These conditions may require a different treatment regimen than multiple sclerosis and may require repeat imaging to monitor treatment response as the diagnosis becomes more clear. Repeat imaging with MRI Brain and/or MRI Cervical Spine and MRI Thoracic Spine as requested by neurology or infectious disease is supported.

- See **Neurometabolic and Neurogenetic Disorders (PEDHD-19.4)**

Transverse Myelitis (PEDHD-14.4)

HDP.DD.0014.4.A

v1.0.2024

- Transverse myelitis is an inflammatory disorder of the spine and can be:
 - Idiopathic
 - Associated with autoimmune central nervous system inflammatory diseases
 - First event of multiple sclerosis (MS)
 - Neuromyelitis optica (NMO)
 - MOG (Myelin Oligodendrocyte Glycoprotein) antibody disorder
 - Associated with connective tissue autoimmune disease
 - Systemic Lupus Erythematosus (SLE)
 - Systemic Sclerosis
 - Rheumatoid Arthritis (RA)
 - Sjogren's Syndrome (SS)
 - Neuro-Sarcoidosis (NS)
 - Post-infectious or post-vaccine neurological syndrome
- See **Multiple Sclerosis (MS) and Related Conditions (HD-16)**

References (HDP-14)

v1.0.2024

1. Hemingway C. Demyelinating disorders of the central nervous system. *Nelson Textbook of Pediatrics, Chapter 618*. eds Kliegman RM, St. Geme JW III, Blum NJ, Shah SS, Tasker RC, Wilson KM. 21st edition. 2020, pp 3197-3209
2. Weygandt M, Hummel H-M, Schregel K, et al. MRI-based diagnostic biomarkers for early onset pediatric multiple sclerosis. *NeuroImage: Clinical*. 2015;7:400-408. doi:10.1016/j.nicl.2014.06.015
3. Tenenbaum SN. Pediatric multiple sclerosis. Distinguishing clinical and MR imaging features. *Neuroimag Clin*. 2017; 27:229-250
4. Van Haren K, Waubant E. Therapeutic Advances in Pediatric Multiple Sclerosis. *The Journal of Pediatrics*. 2013;163(3):631-637. doi:https://doi.org/10.1016/j.jpeds.2013.04.028
5. Ketelslegers IA, Neuteboom RF, Boon M, Catsman-Berrepoets CE, Hintzen RQ. A comparison of MRI criteria for diagnosing pediatric ADEM and MS. *Neurology*. 2010;74(18):1412-1415. doi:https://doi.org/10.1212/WNL.0b013e3181dc138b
6. Banwell B, Arnold DL, Tillema J-M, et al. MRI in the evaluation of pediatric multiple sclerosis. *Neurology*. 2016;87(9 Supplement 2). doi:10.1212/WNL.0000000000002787
7. Marin SE, Callen DJA. The Magnetic Resonance Imaging Appearance of Monophasic Acute Disseminated Encephalomyelitis. *Neuroimaging Clinics of North America*. 2013;23(2):245-266. doi:https://doi.org/10.1016/j.nic.2012.12.005
8. Neuteboom R, Wilbur C, Pelt DV, Rodriguez M, Yeh A. The Spectrum of Inflammatory Acquired Demyelinating Syndromes in Children. *Seminars in Pediatric Neurology*. 2017;24(3):189-200
9. Ruet A. Update on pediatric-onset multiple sclerosis. *Revue Neurologique*. 2018;174(6):398-407. doi:10.1016/j.neurol.2018.04.003
10. Troxell RM, Christy A. Atypical Pediatric Demyelinating Diseases of the Central Nervous System. *Current Neurology and Neuroscience Reports*. 2019;19(12). doi:10.1007/s11910-019-1015-y
11. Thompson AJ, Banwell BL, Barkhof F, et al. Diagnosis of multiple sclerosis: 2017 revisions of the McDonald criteria. *The Lancet Neurology*. 2018;17(2):162-173. doi:10.1016/S1474-4422(17)30470-2
12. Expert Panel on Neurologic Imaging:, Kennedy TA, Corey AS, et al. ACR Appropriateness Criteria® Orbits Vision and Visual Loss. *J Am Coll Radiol*. 2018;15(5S):S116-S131. doi:10.1016/j.jacr.2018.03.023
13. Wingerchuk DM et al. International consensus diagnostic criteria for neuromyelitis optica spectrum disorders. *Neurology*. 2015;85(2):177-89. doi:10.1212/WNL.0000000000001729
14. Major EO. Progressive Multifocal Leukoencephalopathy Lesions and JC Virus. *JAMA Neurology*. 2018;75(7):789. doi:10.1001/jamaneurol.2018.0004
15. Vukusic S, Rollot F, Casey R, et al. Progressive Multifocal Leukoencephalopathy Incidence and Risk Stratification Among Natalizumab Users in France. *JAMA Neurology*. 2020;77(1):94. doi:10.1001/jamaneurol.2019.2670
16. Rae-Grant A, et al. Practice guideline: Disease-modifying therapies for adults with multiple sclerosis. Report of the Guideline Development, Dissemination, and Implementation Subcommittee of the American Academy of Neurology
17. Wattjes MP, Barkhof F. Diagnosis of natalizumab-associated progressive multifocal leukoencephalopathy using MRI. *Current Opinion in Neurology*. 2014;27(3):260-270. doi:10.1097/WCO.0000000000000099
18. Barraza G, Deiva K, Husson B, Adamsbaum C. Imaging in pediatric multiple sclerosis. *Clinical Neuroradiology* 2021;31:61-71
19. Wattjes MP, Ciccarelli O, Reich DS, et al. 2021 MAGNIMS-CMSC-NAIMS consensus recommendations on the use of MRI in patients with multiple sclerosis. *The Lancet Neurology*. 2021;20(8):653-670. doi:10.1016/S1474-4422(21)00095-8

Pituitary Dysfunction (PEDHD-15)

Guideline

Pituitary Dysfunction General Considerations (PEDHD-15.1)

Panhypopituitarism (PEDHD-15.2)

Isolated Growth Hormone Deficiency (PEDHD-15.3)

Diabetes Insipidus (DI) and Other Disorders of Anti-Diuretic Hormone (PEDHD-15.4)

Precocious Puberty (PEDHD-15.5)

Benign Pituitary Tumors (PEDHD-15.6)

Pituitary Malignancies (PEDHD-15.7)

References (HDP-15)

Pituitary Dysfunction General Considerations (PEDHD-15.1)

HDP.PD.0015.1.A

v1.0.2024

- The initial step in the evaluation of all potential pituitary masses is a detailed history, recent physical examination, and thorough neurological exam, including evaluation of the visual fields.
- Endocrine laboratory studies should be performed prior to considering initial advanced imaging.
- MRI Brain without and with contrast (CPT® 70553) or MRI Brain without contrast (CPT® 70551) when pituitary imaging is indicated.
 - Pituitary Gland: one study (either MRI Brain without and with contrast [CPT® 70553] **OR** MRI Orbits/Face/Neck [CPT® 70543]) is adequate to report the imaging of the pituitary. The reporting of two CPT® codes, to image the pituitary, is not indicated.
- If a previous MRI Brain was reported to show a possible pituitary tumor with supporting evidence of pituitary disease or is inconclusive, a repeat MRI with dedicated pituitary protocol may be performed. If a prior MRI Brain was without contrast a follow up scan either MRI Brain with contrast (CPT® 70552) **OR** MRI Brain with and without contrast (CPT® 70553) is appropriate
- For association between pituitary dysfunction and optic nerve issues see **Eye Disorders and Visual Loss (HD- 32.1)** in the Head Imaging Guidelines
- For repeat imaging, See **Pituitary (HD-19.1)** in the Head Imaging Guidelines

Panhypopituitarism (PEDHD-15.2)

HDP.PD.0015.2.A

v1.0.2024

- Endocrine testing should be performed initially.
- MRI Brain without and with contrast (CPT® 70553) **OR** MRI Brain without contrast (CPT® 70551) with special attention to the pituitary is indicated for newly diagnosed Panhypopituitarism.
- Individuals with a normal pituitary on initial MRI do not need routine follow up imaging.
- Individuals with mass lesions should have follow up imaging according to the guidelines for the specific diagnosis

Isolated Growth Hormone Deficiency (PEDHD-15.3)

HDP.PD.0015.3.A

v1.0.2024

- Clinical features include: height below the normal range (<3rd percentile), subnormal growth velocity or the child's height is below the range expected based on parental height.
- Risk factors include: a history of brain tumor, cranial irradiation or other congenital/organic hypothalamic-pituitary abnormality as well as an incidental finding of a hypothalamic-pituitary abnormality on MRI.
- Endocrine testing should be performed initially.
- MRI Brain without and with contrast (CPT® 70553) **OR** MRI Brain without contrast (CPT® 70551) with special attention to the pituitary is indicated for any of the following:
 - Both IGF1 and IGFBP3 are below the laboratory reference range for age/sex or Tanner stage.
 - 2 measurements of growth hormone stimulation with different stimulation agents (glucagon, clonidine, arginine, insulin, levodopa) performed on the same day or separate days produce maximal GH levels <10ng/mL See **Background and Supporting Information**
- Individuals with a normal pituitary on initial MRI do not need routine follow up imaging.
- Individuals with mass lesions should have follow up imaging according to the guidelines for the specific diagnosis.

Background and Supporting Information

- Growth hormone stimulation testing is limited by poor specificity and requires failure on 2 tests to diagnose growth hormone deficiency.
- Controversy exists as to the cutoff level which differentiates a normal response from a deficient response on provocative testing. Some experts support GH <7 ng/mL however many pediatric endocrinologists consider a peak GH level <10 ng/mL to be indicative of growth hormone deficiency and may identify children with partial GHD.

Diabetes Insipidus (DI) and Other Disorders of Anti-Diuretic Hormone (PEDHD-15.4)

HDP.PD.0015.4.A

v1.0.2024

- Laboratory testing should be performed initially. Diabetes insipidus is characterized by serum osmolality >300mOsm/kg and urine osmolality <300 mOsm/kg.
- Central diabetes insipidus (CDI) is caused by diminished synthesis or secretion of vasopressin in the hypothalamus and nephrogenic diabetes insipidus (NDI) is caused by renal resistance to vasopressin.

Central Diabetes Insipidus (DI)

- MRI Brain without and with contrast (CPT® 70553) **OR** MRI Brain without contrast (CPT® 70551) is indicated for newly diagnosed central DI
- Individuals with a normal pituitary on initial MRI can have repeat MRI Brain without and with contrast (CPT® 70553) every 3-6 months for the first 2 years as germinomas may cause central DI while still too small to detect on imaging.
 - Serial measurement of β -hCG is also indicated for these individuals, and MRI should be repeated if a significant rise in β -hCG is detected on screening.
- Individuals with mass lesions should have follow up imaging according to the guidelines for the specific diagnosis.

Nephrogenic DI

- Once this diagnosis is firmly established, further advanced imaging is usually not indicated.

Syndrome of Inappropriate Antidiuretic Hormone Secretion (SIADH)

- Laboratory studies should be obtained prior to considering advanced imaging—urine osmolality should be high and serum osmolality low.
- MRI Brain without and with contrast (CPT® 70553) **OR** MRI Brain without contrast (CPT® 70551) is indicated for initial evaluation of unexplained central (hypothalamic pituitary) SIADH.
- Individuals with a normal pituitary on initial MRI do not need routine follow up imaging.
- Individuals with mass lesions should have follow up imaging according to the guidelines for the specific diagnosis.

Background and Supporting Information

- See **Small Cell Lung Cancer-Suspected/Diagnosis (ONC-7.1)** and **Paraneoplastic Syndromes (ONC-30.3)** in the Oncology Imaging Guidelines.
- Pulmonary diseases including infection (tuberculosis, viral/bacterial pneumonia), acute respiratory infections, mechanical ventilation and others can cause SIADH although the mechanism is unclear. Individuals with lung disease should have chest imaging according to the guidelines for the specific diagnosis.

Precocious Puberty (PEDHD-15.5)

HDP.PD.0015.5.A

v1.0.2024

- Defined as the appearance of secondary sexual characteristics before age 8 in females and before age 9 in males. The diagnosis is made clinically using Tanner staging and often will include a bone age assessment (hand/wrist radiographs) and/or abdominal and/or pelvic ultrasound (See Peripheral Precocious Puberty below).
- Endocrine laboratory studies (baseline LH, FSH and either estradiol or testosterone) are used to determine if the etiology of precocious puberty is central (gonadotropin dependent) or peripheral (gonadotropin independent). Estradiol and testosterone levels will often be elevated to a pubertal range.

Central Precocious Puberty (CPP)

- An LH >0.3 U/L on a random blood sample is the most reliable screening test for central precocious puberty. If LH <0.3 U/L and CPP is suspected, a stimulation test with a GnRH analog is the gold standard.
- Neuroimaging should always follow hormonal studies that suggest a central origin of precocious puberty.
- MRI Brain without and with contrast (CPT® 70553, preferred study) **OR** MRI Brain without contrast (CPT® 70551) is indicated for evaluation of any child with documented central precocious puberty.
- MRI is appropriate irrespective of age and gender in individuals with precocious puberty and concurrent CNS symptoms of severe headache, visual changes or seizures.
- Individuals with a normal pituitary on initial MRI do not need routine follow up imaging.
- Individuals with mass lesions should have follow up imaging according to the guidelines for the specific diagnosis. (**Benign Pituitary Tumors (PEDHD-15.6)** and **Pituitary Malignancies (PEDHD-15.7)**)

Peripheral Precocious Puberty

- The differential diagnosis of peripheral precocious puberty (LH suppressed or in the pre-pubertal range with elevated estradiol, testosterone and/or adrenal androgens) is broad and may include ovarian, testicular, adrenal and other sources of excessive hormonal production
- Ultrasound Abdomen (CPT® 76700) in both genders and Ultrasound Pelvis (CPT® 76856) in females and Scrotal ultrasound (CPT 76870) in males depending on the suspected source of hormonal excess for initial imaging.
- See **CNS Germinomas and Non-Germinomatous Germ Cell Tumors (PEDONC-4.7)** in the Pediatric Oncology Imaging Guidelines for evaluation of HCG secreting CNS tumors
- See **Hepatoblastoma (PEDONC-11.2)** in the Pediatric Oncology Imaging Guidelines for evaluation of HCG secreting hepatic tumors

- See **Pediatric Germ Cell Tumors (PEDONC-10)** in the Pediatric Oncology Imaging Guidelines and **Testicular, Ovarian and Extragonadal Germ Cell Tumors (ONC-20)** in the Oncology Imaging Guidelines for evaluation of Leydig Cell tumors.
- See **Adrenal Cortical Lesions (AB-16.1)** in the Abdomen Imaging Guidelines for evaluation of adrenal virilizing tumors

Benign Pituitary Tumors (PEDHD-15.6)

HDP.PD.0015.6.A

v1.0.2024

- Benign pituitary tumor indications in pediatric individuals are identical to those for adult individuals. See **Pituitary (HD-19)** in the Head Imaging Guidelines.

Pituitary Malignancies (PEDHD-15.7)

HDP.PD.0015.7.A

v1.0.2024

- See **Craniopharyngioma and Other Hypothalamic/Pituitary Region Tumors (PEDONC-4.10)** or **Histiocytic Disorders (PEDONC-18)** in the Pediatric Oncology Imaging Guidelines

References (HDP-15)

v1.0.2024

1. Expert Panel on Neurologic Imaging; Burns J, Policeni B, et al. ACR Appropriateness Criteria® Neuroendocrine Imaging. *J Am Coll Radiol*. 2019;16(5S):S161-S173. doi:10.1016/j.jacr.2019.02.017
2. Patterson BC and Felner EI. Hypopituitarism. *Nelson Textbook of Pediatrics, Chapter 573*. eds Kliegman RM, St. Geme JW III, Blum NJ, Shah SS, Tasker RC, Wilson KM. 21st edition. 2020, pp 2887-2889
3. Breault DT and Majzoub JA. Diabetes Insipidus. *Nelson Textbook of Pediatrics, Chapter 573*. eds Kliegman RM, St. Geme JW III, Blum NJ, Shah SS, Tasker RC, Wilson KM. 21st edition. 2020, pp 2887-2889
4. Garibaldi LR and Chemaitilly W. Physiology of Puberty, *Nelson Textbook of Pediatrics, Chapter 577*. eds Kliegman RM, St. Geme JW III, Blum NJ, Shah SS, Tasker RC, Wilson KM. 21st edition. 2020, pp 2899-2907
5. Zaky W, Ater JL and Khatua S. Brain Tumors in Childhood. *Nelson Textbook of Pediatrics, Chapter 524*. eds Kliegman RM, St. Geme JW III, Blum NJ, Shah SS, Tasker RC, Wilson KM. 21st edition. 2020, pp 2666-2678
6. Kaplowitz P, Bloch C. Evaluation and Referral of Children With Signs of Early Puberty. *Pediatrics*. 2015;137(1). doi:10.1542/peds.2015-3732
7. Grimberg A, Divall SA, Polychronakos C, et al. Guidelines for Growth Hormone and Insulin-Like Growth Factor-I Treatment in Children and Adolescents: Growth Hormone Deficiency, Idiopathic Short Stature, and Primary Insulin-Like Growth Factor-I Deficiency. *Hormone Research in Paediatrics*. 2016;86(6):361-397. doi:10.1159/000452150
8. Thompson CJ et al. Posterior Pituitary. *Textbook of Endocrinology*. Chapter 10, eds. Melmed S, et al, 14th edition. 2019. pp 303-330
9. Cooke DW et al. Normal and Aberrant Growth in Children. *Textbook of Endocrinology*. Chapter 25, eds. Melmed S, et al, 14th edition. 2019. pp 937-1022
10. Styne DM et al. Physiology and Disorders of Puberty. *Textbook of Endocrinology*. Chapter 26, eds. Melmed S, et al, 14th edition. 2019. pp 1023-1164
11. IGFB3 - Clinical: Insulin-Like Growth Factor-Binding Protein 3, Serum. www.mayocliniclabs.com. <https://www.mayocliniclabs.com/test-catalog/Clinical+and+Interpretive/83300>
12. IGFMS - Clinical: Insulin-Like Growth Factor-1, LC-MS, Serum. www.mayocliniclabs.com. <https://www.mayocliniclabs.com/test-catalog/Clinical+and+Interpretive/62750>

Pediatric Ear Disorders (PEDHD-16)

Guideline

- Hearing Loss (PEDHD-16.1)
- Ear Pain (PEDHD-16.2)
- Cholesteatoma (PEDHD-16.3)
- Vertigo (PEDHD-16.4)
- Tinnitus (PEDHD-16.5)
- References (HDP-16)

Hearing Loss (PEDHD-16.1)

HDP.ED.0016.1.A

v1.0.2024

- A pertinent evaluation including a detailed history, physical examination (including otoscopic examination), and age-appropriate audiology testing should be performed on any child with known or suspected hearing loss prior to considering advanced imaging. The selection of imaging testing will depend on the age of the child and type of hearing loss.
- CT Orbits/Temporal Bone without contrast (CPT® 70480) is indicated for the following:
 - Conductive hearing loss of any cause.
 - Preoperative planning for resection of mass lesion or cochlear implant placement.
 - Sensorineural hearing loss in individuals who cannot safely undergo MRI.
 - Mixed conductive and sensorineural hearing loss.
 - Congenital hearing loss.
 - Total deafness.
- MRI Brain without and with contrast (CPT® 70553) with attention to internal auditory canals (included in CPT® 70553 and does not require a separate CPT code) is indicated for the following:
 - Conductive hearing loss secondary to known or suspected mass lesion.
 - Preoperative planning for resection of mass lesion or cochlear implant placement.
 - Sensorineural hearing loss of any cause.
 - Mixed conductive and sensorineural hearing loss.
 - Congenital hearing loss.
 - Total deafness.
 - Hearing loss associated with tinnitus see **Tinnitus (PEDHD-16.5)**
- Both modalities (CT and MRI) are supported simultaneously for evaluation and surgical planning if ordered by or in consultation with an ENT or Neurosurgical specialist
- Limited MRI Brain with attention to internal auditory canals (CPT® 70540, CPT® 70542, or CPT® 70543) is supported when requested by the provider in place of a complete MRI Brain. Note: Limited MRI codes should not be used in addition to MRI Brain codes; IAC views are performed as additional sequences as part of the brain study. (See **General Guidelines – Anatomic Issues (HD-1.1)** in the Head Imaging Guidelines)

Ear Pain (PEDHD-16.2)

HDP.ED.0016.2.A

v1.0.2024

- A pertinent evaluation including a detailed history, physical examination (including otoscopic examination), should be performed on any child with ear pain prior to considering advanced imaging. Common causes of ear pain include external and middle ear infections, dental problems, sinus infection, neck problems, and referred pain from the oral pharynx, tonsillitis, and pharyngitis.
- Advanced imaging is not indicated in the overwhelming majority of pediatric individuals with ear pain.

Indications	Imaging Study
<ul style="list-style-type: none">• Any of the following<ul style="list-style-type: none">• Persistent ear pain without obvious cause• Clinical suspicion for complicated or invasive infection such as mastoiditis• Clinical suspicion of mass lesion causing ear pain• Significant trauma with concern for hematoma formation• Preoperative planning	<ul style="list-style-type: none">• ONE of the following:<ul style="list-style-type: none">• CT Orbits/Temporal Bone without contrast (CPT® 70480) OR• CT Orbits/Temporal Bone without and with contrast (CPT® 70482) OR• MRI Brain without and with contrast with attention to internal auditory canals (CPT® 70553) OR• MRI Orbits/Face/Neck without and with contrast (CPT® 70543)

Cholesteatoma (PEDHD-16.3)

HDP.ED.0016.3.A

v1.0.2024

- One of the following study is indicated for preoperative evaluation in children with cholesteatoma:
 - CT Orbits/Temporal Bone without contrast (CPT® 70480) **OR**
 - CT Orbits/Temporal Bone without and with contrast (CPT® 70482) **OR**
 - MRI Brain without and with contrast with attention to internal auditory canals (CPT® 70553), **OR**
 - MRI Orbits/Face/Neck without and with contrast (CPT® 70543)
- ONE of the following study is indicated one time post-operatively to exclude residual or regrown cholesteatoma to avoid the need for a second-look surgery:
 - CT Orbits/Temporal Bone without contrast (CPT® 70480) **OR**
 - CT Orbits/Temporal without and with contrast (CPT® 70482) **OR**
 - MRI Brain without and with contrast with attention to internal auditory canals (CPT® 70553) **OR**
 - MRI Orbits/Face/Neck without and with contrast (CPT® 70543)

Background and Supporting Information

- Cholesteatomas are expansive cysts of the middle ear filled with cellular debris. They can be congenital or arise from recurrent middle ear infections or trauma to the tympanic membrane. Hearing loss is usually conductive, although if the lesion is large enough combined conductive and sensorineural hearing loss may be present. Otoscopic exam findings and symptoms may include a white mass in the middle ear cleft, painless drainage from the ear or chronic/recurrent ear infections. Advanced imaging for the diagnosis and management of suspected cholestatoma, in particular, should be reserved for the otolaryngologist or provider in consultation with the otolaryngologist.

Vertigo (PEDHD-16.4)

HDP.ED.0016.4.A

v1.0.2024

- Isolated vertigo is an uncommon complaint during childhood. Middle ear/Eustachian tube problems are the most common cause of isolated vertigo in children.
- A pertinent evaluation including a detailed history, physical examination (including otoscopic examination), should be performed on any child with vertigo prior to considering advanced imaging.
- If physical examination is otherwise normal and the vertigo responds to treatment, advanced imaging is not indicated.
- MRI Brain without and with contrast with attention to internal auditory canals (CPT® 70553) is indicated for the following:
 - Vertigo with associated headache or ataxia.
 - Vertigo associated with tinnitus.
 - Vertigo that does not respond to vestibular treatment.

Tinnitus (PEDHD-16.5)

HDP.ED.0016.5.A

v1.0.2024

- Tinnitus without hearing loss is a less common complaint during childhood.
- Children with hearing loss and tinnitus should be imaged according to **Hearing Loss (PEDHD-16.1)**. A pertinent evaluation including a detailed history, physical examination (including otoscopic examination), and age-appropriate audiology testing should be performed on any child with known or suspected tinnitus prior to considering advanced imaging.
- Advanced imaging is not indicated in the overwhelming majority of pediatric individuals with isolated tinnitus and normal hearing.

Indications	Imaging Study
<ul style="list-style-type: none"> • ANY of the following <ul style="list-style-type: none"> • Clinical suspicion of mass lesion causing tinnitus • Persistent tinnitus after recent significant trauma 	<ul style="list-style-type: none"> • ONE of the following <ul style="list-style-type: none"> • CT Orbits/Temporal Bone without contrast (CPT® 70480) OR • CT Orbits/Temporal Bone without and with contrast (CPT® 70482), OR • MRI Brain without and with contrast with attention to internal auditory canals (CPT® 70553) OR • MRI Brain without contrast with attention to internal auditory canals (CPT® 70553) OR • MRI Orbits/Face/Neck without and with contrast (CPT® 70543)
<ul style="list-style-type: none"> • ANY of the following: <ul style="list-style-type: none"> • Pulsatile tinnitus • Suspicion for vascular lesions 	<ul style="list-style-type: none"> • MRA Head (CPT® 70544, CPT® 70545 OR CPT® 70546) OR • CTA Head (CPT® 70496) <p>AND/OR</p> <ul style="list-style-type: none"> • MRA Neck (CPT® 70547, CPT® 70548 OR CPT® 70549) OR • CTA Neck (CPT® 70498)

References (HDP-16)

v1.0.2024

1. Haddad J, and Dodhia SN. The ear. *Nelson Textbook of Pediatrics, Chapter 654*. eds Kliegman RM, St. Geme JW III, Blum NJ, Shah SS, Tasker RC, Wilson KM. 21st edition. 2020, pp 3398-3400
2. Expert Panel on Neurologic Imaging:, Sharma A, Kirsch CFE, et al. ACR Appropriateness Criteria® Hearing Loss and/or Vertigo. *J Am Coll Radiol*. 2018;15(11S):S321-S331. doi:10.1016/j.jacr.2018.09.020
3. Minovi A, and Dazert S. Diseases of the middle ear in childhood. *GMS Curr Top Otorhinolaryngol Head Neck Surg*. 2014 Dec; 13:1-29
4. Kerr R, Kang E, Hopkins B, Anne S. Pediatric tinnitus: Incidence of imaging anomalies and the impact of hearing loss. *International Journal of Pediatric Otorhinolaryngology*. 2017;103:147-149
5. Jahn K. Vertigo and dizziness in children. *Handbook of Clinical Neurology Neuro-Otology*. 2016:353-363. doi:10.1016/b978-0-444-63437-5.00025-x
6. Shekdar KV, Bilaniuk LT. Imaging of Pediatric Hearing Loss. *Neuroimaging Clinics of North America*. 2019;29(1):103-115. doi:10.1016/j.nic.2018.09.011
7. ACR-ASNR-SPR Practice Parameter for the Performance of Computed Tomography (CT) of the Extracranial Head and Neck Revised 2021. (Resolution 5). <https://www.acr.org/-/media/ACR/Files/Practice-Parameters/CT-Head-Neck>
8. Rosenfeld RM, Shin JJ, Schwartz SR, et al. Clinical Practice Guideline: Otitis Media with Effusion (Update). *Otolaryngology–Head and Neck Surgery*. 2016;154(1_suppl). doi:10.1177/0194599815623467
9. Rosenfeld RM, Schwartz SR, Cannon CR, et al. Clinical Practice Guideline. *Otolaryngology–Head and Neck Surgery*. 2014;150(1_suppl). doi:10.1177/0194599813517083
10. Rosenfeld RM, Schwartz SR, Pynnonen MA, et al. Clinical practice guideline: Tympanostomy tubes in children. *Otolaryngol Head Neck Surg*. 2013;149(1 Suppl):S1-S35. doi:10.1177/0194599813487302
11. Expert Panel on Neurologic Imaging:, Kessler MM, Moussa M, et al. ACR Appropriateness Criteria® Tinnitus. *J Am Coll Radiol*. 2017;14(11S):S584-S591. doi:10.1016/j.jacr.2017.08.052
12. Lieu JEC, Kenna M, Anne S, Davidson L. Hearing Loss in Children: A Review. *JAMA*. 2020 Dec 1;324(21):2195-2205. doi: 10.1001/jama.2020.17647
13. Aylward SC, Reem RE. Pediatric Intracranial Hypertension. *Pediatr Neurol*. 2017 Jan;66:32-43. doi: 10.1016/j.pediatrneurol.2016.08.010
14. Ropers FG, Pham ENB, Kant SG, et al. Assessment of the Clinical Benefit of Imaging in Children With Unilateral Sensorineural Hearing Loss: A Systematic Review and Meta-analysis. *JAMA Otolaryngol Head Neck Surg*. 2019;145(5):431-443. doi:10.1001/jamaoto.2019.0121
15. Campion T, Taranath A, Pinelli L, et al. Imaging of temporal bone inflammations in children: a pictorial review. *Neuroradiology*. 2019;61(9):959-970. doi:10.1007/s00234-019-02258-1

Autism Spectrum Disorders (PEDHD-17)

Guideline

Autism Spectrum Disorders (PEDHD-17.1)

References (HDP-17)

Autism Spectrum Disorders (PEDHD-17.1)

HDP.AS.0017.1.A

v1.0.2024

- The group of diagnoses, including Asperger syndrome, are classified as pervasive development disorders (PDD). These diagnoses are established on clinical criteria, and no imaging study can confirm the diagnosis.
- Comprehensive evaluation for autism might include history, physical exam, audiology evaluation, speech, language, and communication assessment, cognitive and behavioral assessments, and academic assessment.
- MRI Brain without and with contrast (CPT® 70553) **OR** MRI Brain without contrast (CPT® 70551) is indicated for new or worsening focal neurologic findings documented on a pertinent physical. Consider advanced imaging if there is loss of developmental milestones and/or regression in two or more areas of development.
- PET imaging is considered investigational in the evaluation of individuals with autism spectrum disorders.

References (HDP-17)

v1.0.2024

1. Bridgemohan CF. Autism spectrum disorder. Nelson Textbook of Pediatrics, Chapter 54. eds Kliegman RM, St. Geme JW III, Blum NJ, Shah SS, Tasker RC, Wilson KM. 21st edition. 2020, pp 294-302
2. Baker E, and Jeste SS. Diagnosis and Management of Autism Spectrum Disorder in the Era of Genomics. *Pediatric Clinics of North America*. 2015;62(3):607-618. doi:10.1016/j.pcl.2015.03.003
3. Zürcher NR, Bhanot A, McDougle CJ, Hooker JM. A systematic review of molecular imaging (PET and SPECT) in autism spectrum disorder: Current state and future research opportunities. *Neuroscience & Biobehavioral Reviews*. 2015;52:56-73. doi:10.1016/j.neubiorev.2015.02.002

Behavioral and Psychiatric Disorders (PEDHD-18)

Guideline

Behavioral and Psychiatric Disorders (PEDHD-18.1)
Reference (HDP-18)

Behavioral and Psychiatric Disorders (PEDHD-18.1)

HDP.BD.0018.1.A

v1.0.2024

- Behavioral and psychiatric disorders of childhood or adolescence, to include Attention Deficit Hyperactivity Disorder (ADHD), generally require no advanced imaging for diagnosis or management.²
 - MRI Brain without and with contrast (CPT® 70553) **OR** MRI Brain without contrast (CPT® 70551) **OR** CT Head without contrast (CPT® 70450) is indicated for:
 - Acute onset mental status change
 - New or worsening focal neurologic findings
 - Presentation of acute psychiatric symptoms with comorbid serious medical illness
 - Non-auditory hallucinations (e.g., visual, tactile, olfactory) with no known etiology
 - Nonresponse to adequate medication trials
 - Symptoms of an organic brain disorder (e.g., focal deficits, severe headache, or seizures)
 - Prior to Electro-Convulsive Therapy (ECT) to screen for intracranial disease
See **HD 4.2: Mental Health Related Disorders**
- For concerns of PANS (Pediatric acute-onset neuropsychiatric syndrome) and PANDAS (Pediatric autoimmune neuropsychiatric disorder associated with streptococcal infection) see **Movement Disorders including Tourette's Syndrome (PEDHD-26)**

Reference (HDP-18)

v1.0.2024

1. Behavioral and Psychiatric Disorders. *Nelson Textbook of Pediatrics, Part III, Behavioral and Psychiatric Disorders. Chapters 32-47.* eds Kliegman RM, St. Geme JW III, Blum NJ, Shah SS, Tasker RC, Wilson KM. 21st edition. 2020, pp 124-191
2. Pereira-Sanchez V, Castellanos FX. Neuroimaging in attention-deficit/hyperactivity disorder. *Curr Opin Psychiatry.* 2021;34(2):105-111. doi:10.1097/YCO.0000000000000669

Developmental Disorders (PEDHD-19)

Guideline

Intellectual Disability (PEDHD-19.1)

Cerebral Palsy (PEDHD-19.2)

Developmental Motor Delay (PEDHD-19.3)

Neurometabolic and Neurogenetic Disorders (PEDHD-19.4)

References (HDP-19)

Intellectual Disability (PEDHD-19.1)

HDP.ID.0019.1.A
v1.0.2024

- Intellectual disability may be primary or secondary to a variety of heterogeneous disorders. See **Background and Supporting Information**.
- MRI Brain without and with contrast (CPT® 70553) **OR** MRI Brain without contrast (CPT® 70551) is indicated for new or worsening focal neurologic findings and/or new or worsening cognitive decline.⁹

Background and Supporting Information

- Intellectual disability is a condition characterized by significant limitations in both intellectual functioning and adaptive behavior that originates before the age of 22.¹³ One way to measure intellectual functioning is an IQ test. Generally, an IQ test score of around 70 or as high as 75 indicates a significant limitation in intellectual functioning.¹³

Cerebral Palsy (PEDHD-19.2)

HDP.ID.0019.2.A

v1.0.2024

- MRI Brain without and with contrast (CPT® 70553) **OR** MRI Brain without contrast (CPT® 70551) is indicated for:
 - Initial evaluation of newly diagnosed cerebral palsy.
 - New or worsening focal neurologic findings documented on a physical examination, including the presence of developmental delay.
 - Re-evaluation after 24 months of age due to rapid myelination during the first 2 years of life.
- For spinal imaging requests See **Myelopathy (SP-7.1)** in the Spine Imaging Guidelines

Background and Supporting Information

- Many individuals with intellectual disability also have cerebral palsy, but not all individuals with cerebral palsy have intellectual disability
- Cerebral palsy is a static motor encephalopathy caused by a variety of entities spanning developmental, metabolic, genetic, infectious, ischemic, and other acquired etiologies

Developmental Motor Delay (PEDHD-19.3)

HDP.ID.0019.3.A

v1.0.2024

- There are many causes for developmental motor delay. Individuals with motor delay can have decreased, normal, or increased muscular tone. Individuals with normal tone do not require imaging unless they have focal neurologic findings.
- MRI Brain without contrast (CPT® 70553) **OR** MRI Brain without and with contrast (CPT® 70553) is indicated for:
 - Initial evaluation of newly diagnosed developmental motor delay with abnormal muscle tone.
 - Toe walking, when associated with upper motor neuron signs including hyperreflexia, abnormal tone (spasticity/hypotonia), or positive Babinski sign.
 - New or worsening focal neurologic findings.
 - Re-evaluation after 24 months of age due to rapid myelination during the first 2 years of life.
- For spinal imaging requests See **Myelopathy (SP-7.1)** in the Spine Imaging Guidelines and **Tethered Cord (PEDSP-5)** in the Pediatric Spine Imaging Guidelines.

Neurometabolic and Neurogenetic Disorders (PEDHD-19.4)

HDP.ID.0019.4.A

v1.0.2024

Imaging Supported	Indications	Suspected or known Neurometabolic and/or neurogenetic disorders, but not limited to
<p>MRI Brain without and with contrast (CPT® 70553)</p> <p>OR</p> <p>MRI Brain without contrast (CPT® 70551)</p> <p>AND/OR</p> <p>Magnetic Resonance Spectroscopy (MRS, CPT® 76390)</p>	<p>Requested by a neurologist or geneticist, or any provider in consultation with a neurologist or geneticist, for:</p> <ul style="list-style-type: none"> • Initial evaluation <p>AND/OR</p> <ul style="list-style-type: none"> • Disease monitoring <p>AND/OR</p> <ul style="list-style-type: none"> • New or worsening symptoms <p>AND/OR</p> <ul style="list-style-type: none"> • Change in therapy is being considered 	<ul style="list-style-type: none"> • X-linked adrenoleukodystrophy (X-ALD, CALD) • Canavan disease • Creatine deficiency • Nonketotic hyperglycinemia • Maple Syrup Urine disease • Metachromatic Leukodystrophy (MCL) • Pelizaeus-Merzbacher disease (PMD) • Hypomyelination and Congenital Cataract • Globoid Cell Leukodystrophy (Krabbe disease) • Mitochondrial disorders (such as, but not limited to Leigh’s syndrome, Kearns-Sayre syndrome, Mitochondrial Encephalopathy with Lactic Acidosis and Stroke-Like Episodes (MELAS)) • Alexander disease (ALX, AXD, dysmyelinogenic leukodystrophy) • Megalencephalic leukoencephalopathy with subcortical cysts • Vanishing White Matter (VWM) disease (Leukoencephalopathy with VWM, Childhood Ataxia with CNS Hypomyelination (CACH) syndrome)

References (HDP-19)

v1.0.2024

1. Shapiro BK, and O'Neil ME. Intellectual Disability. Nelson Textbook of Pediatrics, Chapter 53. eds Kliegman RM, St. Geme JW III, Blum NJ, Shah SS, Tasker RC, Wilson KM. 21st edition. 2020, pp 283-294
2. Johnston MV. Encephalopathies. Nelson Textbook of Pediatrics, Chapter 616.1. eds Kliegman RM, St. Geme JW III, Blum NJ, Shah SS, Tasker RC, Wilson KM. 21st edition. 2020, pp 3186-3173
3. Noritz GH, and Murphy NA. Motor delays: early identification and evaluation. *Pediatrics*. 2013;131(6)
4. Murias K, Moir A, Myers KA, Liu I, Wei X-C. Systematic review of MRI findings in children with developmental delay or cognitive impairment. *Brain and Development*. 2017;39(8):644-655
5. Haynes KB, Wimberly RL, Vanpelt JM, Jo C-H, Riccio AI, Delgado MR. Toe Walking. *Journal of Pediatric Orthopaedics*. 2018;38(3):152-156
6. Sanyal S, et.al. Magnetic Resonance Imaging of Brain in Evaluation of Floppy Children: A Case Series. *Iran J Child Neurol*. 2015 Autumn; 9(4):65-74. PMID: 26664445
7. Ali AS, et al. Magnetic Resonance Imaging (MRI) Evaluation of Developmental Delay in Pediatric Patients. *J Clin Diagn Res*. 2015 Jan; 9(1): TC21-TC24. doi: 10.7860/JCDR/2015/11921.5478
8. Barkovich AJ. Magnetic resonance techniques in the assessment of myelin and myelination. *Journal of Inherited Metabolic Disease*. 2005;28(3):311-343. doi:10.1007/s10545-005-5952-z
9. Bonkowsky JL, Keller S; AAP Section on Neurology, Council on Genetics. Leukodystrophies in Children: Diagnosis, Care, and Treatment. *Pediatrics*. 2021;148(3):e2021053126. doi:10.1542/peds.2021-053126
10. Mankad K, Talenti G, Tan AP, et al. Neurometabolic Disorders of the Newborn. *Top Magn Reson Imaging*. 2018;27(4):179-196. doi:10.1097/RMR.000000000000176
11. Whitehead MT, Lai LM, Blüml S. Clinical ¹H MRS in childhood neurometabolic diseases - part 2: MRS signatures. *Neuroradiology*. 2022;64(6):1111-1126. doi:10.1007/s00234-022-02918-9
12. Aida N. ¹H-MR Spectroscopy of the Early Developmental Brain, Neonatal Encephalopathies, and Neurometabolic Disorders. *Magn Reson Med Sci*. 2022;21(1):9-28. doi:10.2463/mrms.rev.2021-0055
13. American Association on Intellectual and Developmental Disabilities. Defining Criteria for Intellectual Disability. Aaidd.org. Published 2019. <https://www.aaidd.org/intellectual-disability/definition>

Ataxia (PEDHD-20)

Guideline

Ataxia (PEDHD-20.1)

References (HDP-20)

Ataxia (PEDHD-20.1)

HDP.AT.0020.1.A

v1.0.2024

- Ataxia refers to an abnormally ill-coordinated or unsteady gait for age. “Limb ataxia” refers to impaired coordination (for age) of limbs, especially arms. Developmental failure to acquire the ability to walk is a form of developmental delay, not ataxia.
- See also **Developmental Disorders (PEDHD-19)**
- A pertinent evaluation including a detailed history and physical examination with a thorough neurologic examination, should be performed prior to considering advanced imaging, unless the individual is undergoing guideline-supported scheduled follow-up imaging evaluation or request is from or in consultation with a neurologist or neurosurgeon who has seen the individual since onset of symptoms.
- If spinal etiology of ataxia is suspected the following may be indicated
 - MRI Cervical Spine (CPT® 72141 or CPT® 72156) and/or
 - MRI Thoracic Spine (CPT® 72146 or CPT® 72157) and/or
 - MRI Lumbar Spine (CPT® 72148 or CPT® 72158)

Indications	Imaging Studies
<ul style="list-style-type: none"> • ANY of the following: <ul style="list-style-type: none"> • Ataxia • Hereditary Ataxia • Slowly progressive ataxia 	<ul style="list-style-type: none"> • ONE of the following: <ul style="list-style-type: none"> • MRI Brain without and with contrast (CPT® 70553) OR • MRI Brain without contrast (CPT® 70551)
<ul style="list-style-type: none"> • Suspected Spinal Etiology 	<ul style="list-style-type: none"> • MRI Cervical Spine without contrast (CPT® 72141) OR • MRI Cervical Spine without and with contrast (CPT® 72156)AND/OR • MRI Thoracic Spine without contrast (CPT® 72146) OR • MRI Thoracic Spine without and with contrast (CPT® 72157)AND/OR • MRI Lumbar Spine without contrast (CPT® 72148) OR • MRI Lumbar Spine without and with contrast (CPT® 72158)

Indications	Imaging Studies
<ul style="list-style-type: none"> Acute ataxia following significant head trauma 	<ul style="list-style-type: none"> ONE of the following: <ul style="list-style-type: none"> CT Head without contrast (CPT® 70450) OR CT Head without and with contrast (CPT® 70470) OR MRI Brain without contrast (CPT® 70551) OR MRI Brain without and with contrast (CPT® 70553)
<ul style="list-style-type: none"> Contraindication to MRI 	<ul style="list-style-type: none"> ONE of the following: <ul style="list-style-type: none"> CT Head without and with contrast (CPT® 70470) OR CT Head with contrast (CPT® 70460)
<ul style="list-style-type: none"> BOTH of the following: <ul style="list-style-type: none"> Contraindication to MRI AND Suspected Spinal Etiology 	<ul style="list-style-type: none"> CT Cervical Spine without contrast (CPT® 72125) OR CT Cervical Spine without and with contrast (CPT® 72127) AND/OR CT Thoracic Spine without contrast (CPT® 72128) OR CT Thoracic Spine without and with contrast (CPT® 72130) AND/OR CT Lumbar Spine without contrast (CPT® 72131) OR AND/OR CT Cervical Spine without and with contrast (CPT® 72133)

- CT should not be used in place of MRI solely to avoid sedation in young children because MRI is superior for imaging the posterior fossa.
- If there is a contraindication to contrast and a spinal etiology is suspected the following may be indicated:
 - CT Cervical Spine (CPT® 72125 or CPT® 72127) **AND/OR**
 - CT Thoracic Spine (CPT® 72128 or CPT® 72130) **AND/OR**
 - CT Lumbar Spine (CPT® 72131 or CPT® 72133)
- Repeat imaging may be appropriate no more frequently than every 12 months when requested by a neurologist and/or neurosurgeon or any provider in consultation with a neurologist and/or neurosurgeon unless there are new signs or symptoms.

References (HDP-20)

v1.0.2024

1. Expert Panel on Pediatric Imaging, Radhakrishnan R, Shea LAG, et al. ACR Appropriateness Criteria® Ataxia-child. *J Am Coll Radiol*. 2022;19(11S):S240-S255.doi:10.1016/j.jacr.2022.09.010
2. Salman MS, Chodirker BN, Bunge M. Neuroimaging Findings and Repeat Neuroimaging Value in Pediatric Chronic Ataxia. *Canadian Journal of Neurological Sciences / Journal Canadien des Sciences Neurologiques*. 2016;43(06):824-832
3. Vedolin L, Gonzalez G, Souza C, Lourenço C, Barkovich A. Inherited Cerebellar Ataxia in Childhood: A Pattern-Recognition Approach Using Brain MRI. *American Journal of Neuroradiology*. 2012;34(5):925-934. doi:10.3174/ajnr.a3055
4. Alves CAPF, Fragoso DC, Gonçalves FG, Marussi VH, Amaral LLFD. Cerebellar Ataxia in Children. *Topics in Magnetic Resonance Imaging*. 2018;27(4):275-302. doi:10.1097/rmr.000000000000175
5. Morrison PE and Mink JW. Ataxias. Nelson Textbook of Pediatrics, Chapter 615.1 eds Kliegman RM, St. Geme JW III, Blum NJ, Shah SS, Tasker RC, Wilson KM. 21st edition. 2020, pp 3151-3155

Epistaxis (PEDHD-21)

Guideline

Epistaxis Imaging (PEDHD-21.1)

References (HDP-21)

Epistaxis Imaging (PEDHD-21.1)

HDP.ET.0021.1.A

v1.0.2024

- Initial evaluation of epistaxis (nosebleed), including recurrent epistaxis that is refractory to medical management is by direct or endoscopic visualization of the relevant portions of the upper airway.
- If a mass lesion is detected on direct visualization, any ONE of the following imaging studies is indicated:
 - CT Maxillofacial without contrast (CPT® 70486) **OR** CT Maxillofacial without and with contrast (CPT® 70488)
 - MRI Orbits/Face/Neck without and with contrast (CPT® 70543)

References (HDP-21)

v1.0.2024

1. Haddad J, and Keesecker S. Acquired disorders of the nose. *Nelson Textbook of Pediatrics, Chapter 405.2*. eds Kliegman RM, St. Geme JW III, Blum NJ, Shah SS, Tasker RC, Wilson KM. 21st edition. 2020, pp 2183-2084
2. Tunkel DE, Anne S, Payne SC, et al. Clinical Practice Guideline: Nosebleed (Epistaxis). *Otolaryngology–Head and Neck Surgery*. 2020;162(1_suppl). doi:10.1177/0194599819890327
3. ACR-ASNR-SPR Practice Parameter for the Performance of Computed Tomography (CT) of the Extracranial Head and Neck Revised 2021. (Resolution 5). <https://www.acr.org/-/media/ACR/Files/Practice-Parameters/CT-Head-Neck>

Pseudotumor Cerebri (PEDHD-22)

Guideline

Pseudotumor Cerebri (PEDHD-22.1)

Pseudotumor Cerebri (PEDHD-22.1)

HDP.PC.0022.1.A

v1.0.2024

- Pseudotumor cerebri indications in pediatric individuals are identical to those for adult individuals. See [Papilledema/Pseudotumor Cerebri \(HD-17.1\)](#) in the Head Imaging Guidelines.

Cranial Neuropathies (PEDHD-23)

Guideline

Cranial Neuropathies (PEDHD-23.1)

References (HDP-23)

Cranial Neuropathies (PEDHD-23.1)

HDP.CN.0023.1.A

v1.0.2024

- MRI Brain without and with contrast (CPT® 70553) **OR** MRI Brain without contrast (CPT® 70551) is indicated for all individuals with new or worsening specific cranial nerve abnormalities.
- MRI ORbits/Face/Neck without and with contrast (CPT® 70543) **OR** MRI Orbits/Face/Neck without contrast (CPT® 70540) is also indicated for individuals with abnormalities in cranial nerves IX, X, XI, or XII.

References (HDP-23)

v1.0.2024

1. Expert Panel on Neurological Imaging, Rath TJ, Policeni B, et al. ACR Appropriateness Criteria® Cranial Neuropathy: 2022 Update. <*J Am Coll Radiol*>. 2022;19(11S):S266-S303. doi:10.1016/j.jacr.2022.09.021
2. Rubin M. Overview of neuro-ophthalmologic and cranial nerve disorders. Merck Manual. Last Modified September 2020. <https://www.merckmanuals.com/professional/neurologic-disorders/neuro-ophthalmologic-and-cranial-nerve-disorders/overview-of-neuro-ophthalmologic-and-cranial-nerve-disorders>
3. Janowski AB and Hunstad DA. Central Nervous System Infections. Nelson Textbook of Pediatrics, Chapter 621. eds Kliegman RM, St. Geme JW III, Blum NJ, Shah SS, Tasker RC, Wilson KM. 21st edition. 2020, pp 3223-3234

Pediatric Sleep Disorders (PEDHD-24)

Guideline

Pediatric Sleep Disorders (PEDHD-24.1)

References (HDP-24)

Pediatric Sleep Disorders (PEDHD-24.1)

HDP.SD.0024.1.A

v1.0.2024

- See **Pediatric Sleep Guidelines (SL-3)** in the Sleep Apnea and Treatment Clinical Guidelines
- For over 18 years of age OR regarding Oral Appliance OR Hypersomnolence
 - See **Sleep-Related Imaging Guidelines (HD-37)**
- For Obstructive Sleep Apnea:
 - There is NO indication for imaging prior to tonsillectomy (with or without adenoidectomy) for obstructive sleep apnea
 - Initially, endoscopic examination of the upper airway should be performed.
 - CT Maxillofacial without contrast (CPT® 70486) is supported for evaluation of obstructive anatomy if operative intervention, other than a tonsillectomy (with or without adenoidectomy), is being considered.
- For suspected Central Sleep Apnea, the following is supported:
 - MRI Brain without contrast (CPT® 70551) OR
 - MRI Brain without and with contrast (CPT® 70553)
- Advanced imaging is NOT indicated for the following:
 - Confusional arousals
 - Sleep terrors
 - Nightmare disorder
 - Sleep walking (Somnambulism)
 - Bed wetting (Enuresis)
 - Insomnia
 - Narcolepsy (without or with cataplexy)
 - Restless Leg Syndrome/Periodic Limb Movement Disorder
- For suspected sleep-related seizures, see **Epilepsy and Other Seizure Disorders (PEDHD-6)**

References (HDP-24)

v1.0.2024

1. Owens JA. Sleep medicine. *Nelson Textbook of Pediatrics, Chapter 31*. eds Kliegman RM, St. Geme JW III, Blum NJ, Shah SS, Tasker RC, Wilson KM. 21st edition. 2020, pp 172-184
2. Mitchell RB, Archer SM, Ishman SL, et al. Clinical Practice Guideline: Tonsillectomy in Children (Update). *Otolaryngology–Head and Neck Surgery*. 2019;160(1_suppl). doi:10.1177/0194599818801757

Temporomandibular Joint (TMJ)/Dental/Maxillofaci al Imaging in Children (PEDHD-25)

Guideline

Temporomandibular Joint Imaging (PEDHD-25.1)

Dental/Periodontal/Maxillofacial Imaging (PEDHD-25.2)

References (HDP-25)

Temporomandibular Joint Imaging (PEDHD-25.1)

HDP.TJ.0025.1.A

v1.0.2024

- Temporomandibular Joint (TMJ) Imaging in Children indications in pediatric individuals are very similar to those for adult individuals. See **Temporomandibular Joint Disease (TMJ) (HD-30.1)** in the Head Imaging Guidelines.
- Pediatric-specific imaging considerations include the following:
 - There is a paucity of clinical symptoms and poor sensitivity of conventional x-rays in diagnosing TMJ arthritis in pediatric individuals with arthritis
- MRI TMJ (CPT® 70336) is indicated annually for detecting silent TMJ arthritis in children with juvenile idiopathic arthritis (JIA) as requested by a rheumatologist and/or oral/maxillofacial surgeon (OMS) and/or any provider in consultation with a rheumatologist or OMS
- Repeat imaging with MRI TMJ (CPT® 70336) in patients with JIA is indicated for any of the following:
 - Change in signs or symptoms suggesting progression of disease
 - To monitor the effects of treatment⁸
- Bone Scintigraphy/Bone Scan 3 Phase Study (CPT® 78315) in individuals over 12 years of age⁷ is appropriate in anticipation or consideration of surgery⁷
- Unilateral condylar hyperplasia is manifested by slow growth in areas of the mandible causing facial asymmetry. It is usually a self-limiting condition seen predominantly in 12–30 year olds.

Dental/Periodontal/Maxillofacial Imaging (PEDHD-25.2)

HDP.TJ.0025.2.A

v1.0.2024

- See [Dental/Periodontal/Maxillofacial Imaging \(HD 30.2\)](#)

References (HDP-25)

v1.0.2024

1. Zwir LM, Terreri MT, Sousa SA, et al. Are temporomandibular joint signs and symptoms associated with magnetic resonance imaging findings in juvenile idiopathic arthritis patients? A longitudinal study. *Clin Rheumatol*. 2015 Dec; 34 (12) 057-2063
2. Navallas M, Inarejos EJ, Iglesias E, Lee GYC, Rodríguez N, Antón J. MR Imaging of the Temporomandibular Joint in Juvenile Idiopathic Arthritis: Technique and Findings. *RadioGraphics*. 2017;37(2):595-612. doi:10.1148/rg.2017160078
3. Stoll ML, Kau CH, Waite PD, Cron RQ. Temporomandibular joint arthritis in juvenile idiopathic arthritis, now what? *Pediatric Rheumatology*. 2018;16(1)
4. Miller E, Clemente EJI, Tzaribachev N, et al. Imaging of temporomandibular joint abnormalities in juvenile idiopathic arthritis with a focus on developing a magnetic resonance imaging protocol. *Pediatric Radiology*. 2018;48(6):792-800. doi:10.1007/s00247-017-4005-8
5. Hammer MR, Kanaan Y. Imaging of the Pediatric Temporomandibular Joint. *Oral and Maxillofacial Surgery Clinics of North America*. 2018;30(1):25-34. doi:10.1016/j.coms.2017.08.008
6. Wu EY and Rabinovich CE. Juvenile Idiopathic Arthritis. Nelson Textbook of Pediatrics, Chapter 180. eds Kliegman RM, St. Geme JW III, Blum NJ, Shah SS, Tasker RC, Wilson KM. 21st edition. 2020, pp 1260-1268
7. Lee YH, Hong IK, Chun YH. Prediction of painful temporomandibular joint osteoarthritis in juvenile patients using bone scintigraphy. *Clin Exp Dent Res*. 2019;5(3):225-235. doi:10.1002/cre2.175
8. Schmidt C, Ertel T, Arbogast M, et al. The Diagnosis and Treatment of Rheumatoid and Juvenile Idiopathic Arthritis of the Temporomandibular Joint. *Dtsch Arztebl Int*. 2022;119(4):47-54. doi:10.3238/arztebl.m2021.0388

Movement Disorders including Tourette's Syndrome (PEDHD-26)

Guideline

Tourette's Syndrome (PEDHD-26.1)

Movement Disorders (PEDHD-26.2)

References (HDP-26)

Tourette's Syndrome (PEDHD-26.1)

HDP.MD.0026.1.A

v1.0.2024

- The diagnosis of Tourette's syndrome is made clinically and advanced neuroimaging is not indicated for either diagnosis or management.

Movement Disorders (PEDHD-26.2)

HDP.MD.0026.2.A

v1.0.2024

- Movement disorders are hyperkinetic and hypokinetic movements that are involuntary. The majority are diagnosed based on a clinical diagnosis and do not require imaging.
- Typically Benign Movement disorders include:
 - Stereotypies, repetitive rhythmic movements
 - Tics that are vocal or motor with typical onset and course
 - Tourette Syndrome
 - Essential Tremor or tremors of anxiety or weakness
 - Restless Leg Syndrome
- MRI Brain without contrast (CPT® 70551), **OR** MRI Brain without and with contrast (CPT® 70553) is considered in the following clinical scenarios:
 - Atypical clinical features for example, movements that persist in sleep, onset outside of typical age at onset (4-6 years for tics), rapid progression, incomplete or uncertain medication responsiveness, or clinical diagnostic uncertainty, limbic encephalitis
 - Dystonia, intermittent involuntary muscle contractions
 - Chorea, continual irregular movements
 - Ballism, involuntary high amplitude movements
 - Athetosis, slow writhing continuous movements
 - Myoclonus, involuntary muscle jerks (not sleep myoclonus)
- MRI Brain without contrast (CPT® 70551) **OR** MRI Brain without and with contrast (CPT® 70553) is supported for concerns of:
 - PANS (Pediatric acute-onset neuropsychiatric syndrome) and/or
 - PANDAS (Pediatric autoimmune neuropsychiatric disorder associated with streptococcal infection)
 - Only after a complete medical workup including labs, acute infection, and other comorbid psychiatric disorders (examples, such as Obsessive Compulsive Disorder (OCD), Attention Deficit Hyperactivity Disorder (ADHD) and Autism Spectrum Disorder (ASD) have been investigated.
 - Routine brain imaging is not routinely recommended for OCD, ADHD or ASD.
- See **Movement Disorders (HD-15.1)** in the Head Imaging Guidelines for the following
 - Suspected Huntington Disease
 - Evaluation for surgical treatment of Essential Tremor or Parkinson's disease, including Deep Brain Stimulator (DBS) placement

- Post-op imaging is supported when ordered by a neurologist or neurosurgeon or any provider in consultation with a neurologist or neurosurgeon for either procedure.

Background and Supporting Information

- There is little evidence to support the use of MRA/CTA and PET in the evaluation of movement disorders.
- Tourette syndrome (TS) is a neurological disorder characterized by repetitive, stereotyped, involuntary movements and vocalizations called tics. The first symptoms of TS are almost always noticed in childhood. Some of the more common tics include eye blinking and other vision irregularities, facial grimacing, shoulder shrugging, and head or shoulder jerking. Perhaps the most dramatic and disabling tics are those that result in self-harm such as punching oneself in the face, or vocal tics including coprolalia (uttering swear words) or echolalia (repeating the words or phrases of others). Many with TS experience additional neurobehavioral problems including inattention, hyperactivity and impulsivity, and obsessive-compulsive symptoms such as intrusive thoughts/worries and repetitive behaviors

Reference: <https://www.ninds.nih.gov/Disorders/All-Disorders/Tourette-Syndrome-Information-Page>

References (HDP-26)

v1.0.2024

1. Serajee FJ, Mahbulul Huq AH. Advances in Tourette syndrome: diagnoses and treatment. *Pediatr Clin North Am.* 2015;62(3):687-701. doi:10.1016/j.pcl.2015.03.007
2. Zinner SH, Mink JW. Movement Disorders I: Tics and Stereotypies. *Pediatrics in Review.* 2010;31(6):223-233. doi:10.1542/pir.31-6-223
3. Jonathon W. Mink, Movement Disorders. Nelson Textbook of Pediatrics, Chapter 615. eds Kliegman RM, St. Geme JW III, Blum NJ, Shah SS, Tasker RC, Wilson KM. 21st edition 2020, pp 143-144
4. Colleen Ryan, Heather Walter, David DeMaso, Tic Disorders. Nelson Textbook of Pediatrics, Chapter 37.1. eds Kliegman RM, St. Geme JW III, Blum NJ, Shah SS, Tasker RC, Wilson KM. 21st edition 2020, pp 206-208
5. Frankovich J, Swedo S, Murphy T, et al. Clinical Management of Pediatric Acute-Onset Neuropsychiatric Syndrome: Part II—Use of Immunomodulatory Therapies. *Journal of Child and Adolescent Psychopharmacology.* 2017;27(7):574-593. doi:10.1089/cap.2016.0148
6. Cooperstock MS, Swedo SE, Pasternack MS, Murphy TK, Consortium FTP. Clinical Management of Pediatric Acute-Onset Neuropsychiatric Syndrome: Part III—Treatment and Prevention of Infections. *Journal of Child and Adolescent Psychopharmacology.* 2017;27(7):594-606. doi:10.1089/cap.2016.0151
7. Thienemann M, Murphy T, Leckman J, et.al. Clinical Management of Pediatric Acute-Onset Neuropsychiatric Syndrome: Part 1-Psychiatric and Behavioral Interventions. *Journal of Child and Adolescent Psychopharmacology.* 2017;27(7):556-573. doi:10.1089/cap.2016.0145

Tuberous Sclerosis (PEDHD-27)

Guideline

Tuberous Sclerosis (PEDHD-27.1)

Tuberous Sclerosis (PEDHD-27.1)

HDP.TS.0027.1.A

v1.0.2024

- See **Tuberous Sclerosis Complex (TSC) (PEDONC-2.9)** in the Pediatric Oncology Imaging Guidelines

Von Hippel-Lindau Syndrome (VHL) (PEDHD-28)

Guideline

Von Hippel-Lindau Syndrome (VHL) (PEDHD-28.1)

Von Hippel-Lindau Syndrome (VHL) (PEDHD-28.1)

HDP.VL.0028.1.A

v1.0.2024

- See **Von Hippel-Lindau Syndrome (VHL) (PEDONC-2.10)** in the Pediatric Oncology Imaging Guidelines

CNS Infection (PEDHD-29)

Guideline

CNS Infection (PEDHD-29.1)

References (HDP-29)

CNS Infection (PEDHD-29.1)

HDP.CI.0029.1.A

v1.0.2024

- CNS infection imaging indications in pediatric individuals are similar to those for adult individuals. See **CNS and Head Infection/Neuro-COVID-19 (HD-14)** in the Head Imaging Guidelines.
- CT Head (as per **General Guidelines – CT Head (HD-1.4)** in the Head Imaging Guidelines) may be considered in Pediatric CNS Infection.
- The following studies are supported for suspected intracranial infection if any signs of CNS infection are present:
 - MRI Brain without and with contrast (CPT® 70553) (preferred) **OR** MRI Brain without contrast (CPT® 70551)
 - CT Head (CPT® 70450, CPT® 70460, **OR** CPT® 70470) in cases where MRI is contraindicated or urgently required prior to lumbar puncture to evaluate for meningitis.
- Repeat imaging is supported if requested by infectious disease specialist, neurologist, ophthalmologist, neuro-ophthalmologist or neurosurgeon or any provider coordinating care with an infectious disease specialist, neurologist, ophthalmologist, neuro-ophthalmologist or neurosurgeon.
- Pediatric-specific imaging considerations include suspected congenital brain infection and neonatal meningitis. The common causes of prenatal infections of the central nervous system are cytomegalovirus, *Toxoplasma gondii*, herpes simplex type 2 virus and most recently zika virus. The findings suggesting prenatal brain infection include microcephaly, microphthalmia, chorioretinitis, cataracts, hypotonia, and seizures. The following are performed for congenital brain infections:
 - The following imaging is considered for newborn infants with suspected prenatal brain infection regardless of inciting organism. (For additional information see CDC's Areas with risk of Zika site: <https://wwwnc.cdc.gov/travel/page/zika-information>)
- Ultrasound Head (CPT® 76506) is supported as an initial imaging study
 - MRI Brain without and with contrast (CPT® 70553) is indicated if the ultrasound is abnormal.
 - Newborn infants with microcephaly should be evaluated as discussed in **Macrocephaly, Microcephaly, and Hydrocephalus (PEDHD-7)**
- The following imaging is considered for newborns or older infants with an open fontanelle and suspected meningitis:
 - Ultrasound Head (CPT® 76506) as an initial imaging study, but is not required
 - MRI Brain without and with contrast (CPT® 70553)² is indicated if the ultrasound is abnormal
- A wide spectrum of neurological diseases have been observed in children with COVID-19 infection in children including, but not limited to, Multisystem Inflammatory Syndrome.^{10,11}

- MRI Brain without and with contrast (CPT® 70553) **AND/OR**
- MRA Head (CPT® 70544, CPT®70545 **OR** CPT® 70546) **OR** CTA Head (CPT® 70496) **AND/OR**
- MRA Neck (CPT® 70547 **OR** CPT® 70548 **OR** CPT® 70549) **OR** CTA Neck (CPT® 70498) **AND/OR**
 - If Acute Necrotizing Myelitis is suspected, the following are indicated:
 - MRI Cervical Spine without and with contrast (CPT® 72156) **AND/OR**
 - MRI Thoracic Spine without and with contrast (CPT® 72157) **AND/OR**
 - MRI Lumbar Spine without and with contrast (CPT® 72158)
- Metabolic (FDG) Brain PET (CPT® 78608) is appropriate to evaluate individuals suspected of having encephalitis, including autoimmune encephalitis, if diagnosis remains unclear after evaluation with MRI Brain, CSF analysis, and lab testing including serology.¹²

Background and Supporting Information

- Neonatal meningitis most often is caused by bacterial pathogens and usually occurs as a complication of sepsis in the first week of life. In older infants and children, meningeal inoculation occurs secondary to hematogenous spread or penetrating trauma.

References (HDP-29)

v1.0.2024

1. De Vries LS, and Volpe JJ. Viral, protozoan, and related intracranial infections. In: Volpe JJ, ed. *Volpe's Neurology of the Newborn*. 6th ed. Philadelphia: Elsevier. 2018;973-1049
2. Melo AS, Aguiar RS, Amorim MM, et al. Congenital Zika Virus Infection: Beyond Neonatal Microcephaly. *JAMA Neurol*. 2016;73(12):1407-1416. doi:10.1001/jamaneurol.2016.3720
3. Levine D, Jani JC, Castro-Aragon I, et al. How does imaging of congenital Zika compare with imaging of other TORCH infections? *Radiology*. 2017;285:744-761
4. De Oliveria Melo AS, Aquiar RS, Amorim MM, et al. Congenital Zika virus infection: beyond neonatal microcephaly. *JAMA Neurol*. 2016 Dec 1;73:1407-1416
5. Rabe I, Meaney-Delman D, and Moore CA. "Zika Virus – What Clinicians Need to Know." clinician outreach and communication activity call. Centers for Disease Control and Prevention. 26 Jan. 2016. Available at: http://coursewareobjects.elsevier.com/objects/elr/ExpertConsult/Kliegman/nelson20e/updates/CDC_presentation_01262016.pdf
6. Janowski AB and Hunstad DA. Central Nervous System Infections. Nelson Textbook of Pediatrics, Chapter 621. eds Kliegman RM, St. Geme JW III, Blum NJ, Shah SS, Tasker RC, Wilson KM. 21st edition. 2020, pp 3223-3234
7. ACR-ASNR-SPR Practice Parameter for the Performance of Computed Tomography (CT) of the Extracranial Head and Neck Revised 2021. (Resolution 5). <https://www.acr.org/-/media/ACR/Files/Practice-Parameters/CT-Head-Neck>
8. Wong A, Toh CH. Spectrum of neuroimaging mimics in children with COVID-19 infection [published online ahead of print, 2021 Nov 15]. *Biomed J*. 2021;S2319-4170(21)00151-7. doi:10.1016/j.bj.2021.11.005
9. Lindan CE, Mankad K, Ram D, et al. Neuroimaging manifestations in children with SARS-CoV-2 infection: a multinational, multicentre collaborative study. *Lancet Child Adolesc Health*. 2021;5(3):167-177 doi:10.1016/S2352-4642(20)30362-X
10. Probasco JC, Solnes L, Nalluri A, et al. Abnormal brain metabolism on FDG-PET/CT is a common early finding in autoimmune encephalitis. *Neurology - Neuroimmunology Neuroinflammation*. 2017;4(4). doi:10.1212/nxi.0000000000000352
11. Mullins E, Perry A, Banerjee J, et al. Pregnancy and neonatal outcomes of COVID-19: The PAN-COVID study. *Eur J Obstet Gynecol Reprod Biol*. 2022;276:161-167. doi:10.1016/j.ejogrb.2022.07.010
12. Hwee TP, Koh Cheng T. Imaging of Congenital/Childhood Central Nervous System Infections. *Neuroimaging Clin N Am*. 2023;33(1):207-224. doi:10.1016/j.nic.2022.07.017

Scalp and Skull Lesions (PEDHD-30)

Guideline

Scalp and Skull Lesions (PEDHD-30.1)

References (HDP-30)

Scalp and Skull Lesions (PEDHD-30.1)

HDP.SL.0030.1.A

v1.0.2024

- Scalp and skull lesion imaging indications in pediatric individuals are identical to those for adult individuals with the exception of neonates. See **Scalp and Skull Lesions (HD-20.1)** in the Head Imaging Guidelines.
 - In neonates and young infants, scalp masses include:
 - Congenital lesions (cephalocele-discussed above, dermoid cysts, epidermoid cyst)
 - Vascular lesions (hemangioma, sinus pericranii)
 - Extracranial hemorrhage related to birth trauma (caput succedaneum, cephalohematoma, subgaleal hematoma)
 - After the first year of life, malignant tumors, such as Langerhans cell histiocytosis metastases from neuroblastoma and rhabdomyosarcoma are an additional cause of a scalp mass.
 - The following imaging is considered for newborns with palpable scalp and skull lesions.
 - Ultrasound Head (CPT® 76506) is supported as an initial imaging study.
 - MRI Brain without and with contrast (CPT® 70553) (preferred) or CT Head without and with contrast (CPT® 70470) is indicated if the ultrasound is abnormal and associated anomalies are suspected
 - The following imaging is indicated for children and adults with Pott Puffy Tumor:
 - MRI Brain without and with contrast (CPT® 70553) OR CT Head without and with contrast (CPT® 70470)⁸
 - Repeat imaging is supported if requested by neurologist, neurosurgeon, otolaryngologist (ENT) and/or oral maxillofacial surgery (OMS) or any provider coordinating care with a neurologist, neurosurgeon, otolaryngologist (ENT) and/or oral maxillofacial surgery (OMS).

Background and Supporting Information

- Pott Puffy Tumor is an abscess involving the frontal bone with adjacent osteomyelitis as the result of a frontal sinus infection that spreads contiguously through the wall of the sinus or through hematogenous spread via the veins that drain sinus mucosa.⁸

References (HDP-30)

v1.0.2024

1. Siegel MJ. Brain. In: *Pediatric sonography*. 5th ed. Philadelphia. Wolters Kluwer. 2018 40-111
2. Bansal AG, Oudsema R, Masseaux JA, Rosenberg HK. US of Pediatric Superficial Masses of the Head and Neck. *RadioGraphics*. 2018;38(4):1239-1263. doi:10.1148/rg.2018170165
3. Carratalá RM, Cabezuelo MEC, Herrera IH, et al. Nontraumatic Lesions of the Scalp: Practical Approach to Imaging Diagnosis: Neurologic/Head and Neck Imaging. *RadioGraphics*. 2017;37(3):999-1000. doi:10.1148/rg.2017160112
4. Kollipara R, Dinneen L, Rentas KE, et al. Current Classification and Terminology of Pediatric Vascular Anomalies. *American Journal of Roentgenology*. 2013;201(5):1124-1135. doi:10.2214/ajr.12.10517
5. Landisch S. Hemophagocytic Lymphohistiocytosis. Nelson Textbook of Pediatrics, Chapter 534.2. eds Kliegman RM, St. Geme JW III, Blum NJ, Shah SS, Tasker RC, Wilson KM. 21st edition. 2020, pp 2712-2713
6. Robinson AJ, Blaser S and Fink AM. Prenatal Imaging. Caffey's Pediatric Diagnostic Imaging, Chapter 19. Coley BR, et al. 13th edition. 2019, pp 158-161
7. Tobler JF, Slovis, TL and Rozzelle AA. Selected Craniofacial Syndromes, and Other Abnormalities of the Skull. Caffey's Pediatric Diagnostic Imaging, Chapter 20. Coley BR, et al. 13th edition. 2019, pp 162-180
8. Barnett RR, Piazza MG, Elton SW. Pediatric Neurosurgery in Primary Care: Masses of the Scalp and Skull in Children. *Pediatr Clin North Am*. 2021;68(4):743-757. doi:10.1016/j.pcl.2021.04.003

Eye Disorders (PEDHD-31)

Guideline

Eye Disorders (PEDHD-31.1)

References (HDP-31)

Eye Disorders (PEDHD-31.1)

HDP.EY.0031.1.A

v1.0.2024

- Eye disorder imaging indications in pediatric individuals are close to identical to those for adult individuals. See **Eye Disorders and Visual Loss (HD-32.1)** in the Head Imaging Guidelines

Indication	Imaging Studies
<ul style="list-style-type: none"> • Imaging is supported in the evaluation for congenital disorders or disorders that begin early in life, such as, but not limited to <ul style="list-style-type: none"> • Optic Nerve Hypoplasia • Septo-Optic Dysplasia • Infantile Nystagmus Syndrome⁴ 	<ul style="list-style-type: none"> • MRI Orbits/Face/Neck without contrast (CPT® 70540) OR • MRI Orbits/Face/Neck without and with contrast (CPT® 70543) OR • CT Orbits/Temporal Bone with contrast (CPT® 70481) OR • CT Orbits/Temporal Bone without contrast (CPT® 70480)AND/OR • MRI Brain without contrast (CPT® 70551) OR • MRI Brain with and without contrast (CPT® 70553)²

- Repeat imaging is supported if requested by a neurologist, ophthalmologist, neuro-ophthalmologist or neurosurgeon or any provider coordinating care with a neurologist, ophthalmologist, neuro-ophthalmologist or neurosurgeon.
- For traumatic retinal hemorrhages as seen in suspected shaken baby syndrome (See **(PEDHD-4.1)**)

References (HDP-31)

v1.0.2024

1. Dumitrescu AV, Scruggs BA, Drack AV. Clinical Guidelines: Childhood Nystagmus Workup. American Academy of Ophthalmology. <https://www.aao.org/disease-review/clinical-guidelines-childhood-nystagmus-workup>. Published February 13, 2020
2. Ganau M, Huet S, Syrmos N, Meloni M, Jayamohan J. Neuro-Ophthalmological Manifestations Of Septo-Optic Dysplasia: Current Perspectives Eye and Brain. 2019;Volume 11:37-47. doi:10.2147/eb.s186307
3. Costello F, Scott JN. Imaging in Neuro-ophthalmology. *CONTINUUM (MINNEAP MINN)*. 2019;25(5, NEURO-OPHTHALMOLOGY):1438–1490
4. Bhat R, Al-Samarraie M, Nada A, Leiva-Salinas C, Whitehead M, Mahdi E. Spotlight on the pediatric eye: a pictorial review of orbital anatomy and congenital orbital pathologies. *Neuroradiol J*. 2021;34(1):21-32. doi: 10.1177/1971400920949232

Table of Contents

Guideline

- General Guidelines (PEDMS-1.0)
- Fracture and Dislocation (PEDMS-2)
- Soft Tissue and Bone Masses (PEDMS-3)
- Limping Child (PEDMS-4)
- Developmental Dysplasia of the Hip (PEDMS-5)
- Avascular Necrosis (AVN) / Legg-Calvé-Perthes Disease / Idiopathic Osteonecrosis (PEDMS-6)
- Suspected Physical Child Abuse (PEDMS-7)
- Infection/Osteomyelitis (PEDMS-8)
- Foreign Body (PEDMS-9)
- Inflammatory Musculoskeletal Disease (PEDMS-10)
- Muscle/Tendon Unit Injuries (PEDMS-11)
- Osgood-Schlatter Disease (PEDMS-12)
- Popliteal (Baker) Cyst (PEDMS-13)
- Slipped Capital Femoral Epiphysis (SCFE) (PEDMS-14)
- Limb Length Discrepancy (PEDMS-15)
- Congenital Anomalies of the Foot and Lower Extremity (PEDMS-16)

General Guidelines (PEDMS-1.0)

Guideline

Procedure Codes Associated with Musculoskeletal Imaging (PEDMS)

General Guidelines (PEDMS-1.0)

Age Considerations (PEDMS-1.1)

Appropriate Clinical Evaluation and Conservative Treatment (PEDMS-1.2)

Modality General Considerations (PEDMS-1.3)

References (PEDMS-1)

Procedure Codes Associated with Musculoskeletal Imaging (PEDMS)

MSP.GG.ProcedureCodes.A
v1.0.2024

MRI	CPT®
MRI Upper Extremity non-joint without contrast	73218
MRI Upper Extremity non-joint with contrast (rarely used)	73219
MRI Upper Extremity non-joint without and with contrast	73220
MRI Upper Extremity joint without contrast	73221
MRI Upper Extremity joint with contrast (rarely used)	73222
MRI Upper Extremity joint without and with contrast	73223
MRI Lower Extremity non-joint without contrast	73718
MRI Lower Extremity non-joint with contrast (rarely used)	73719
MRI Lower Extremity non-joint without and with contrast	73720
MRI Lower Extremity joint without contrast	73721
MRI Lower Extremity joint with contrast (rarely used)	73722
MRI Lower Extremity joint without and with contrast	73723
Unlisted MRI procedure (for radiation planning or surgical software)	76498

MRA	CPT®
MRA Upper Extremity	73225
MRA Lower Extremity	73725

CT	CPT®
CT Upper Extremity without contrast	73200
CT Upper Extremity with contrast	73201
CT Upper Extremity without and with contrast	73202
CT Lower Extremity without contrast	73700
CT Lower Extremity with contrast	73701
CT Lower Extremity without and with contrast	73702
CT Chest without contrast	71250
CT Chest with contrast	71260
CT Abdomen with contrast	74160

CT	CPT®
CT Pelvis with contrast	72193
CT Abdomen and Pelvis with contrast	74177
Bone Mineral Density CT, one or more sites, axial skeleton	77078
CT Guidance for Placement of Radiation Therapy Fields	77014
Unlisted CT procedure (for radiation planning or surgical software)	76497

CTA	CPT®
CTA Upper Extremity	73206
CTA Lower Extremity	73706

Nuclear Medicine	CPT®
PET Imaging; limited area (this code not used in pediatrics)	78811
PET Imaging: skull base to mid-thigh (this code not used in pediatrics)	78812
PET Imaging: whole body (this code not used in pediatrics)	78813
PET with concurrently acquired CT; limited area (this code rarely used in pediatrics)	78814
PET with concurrently acquired CT; skull base to mid-thigh	78815
PET with concurrently acquired CT; whole body	78816
Bone Marrow Imaging Limited Areas	78102
Bone Marrow Imaging Multiple Areas	78103
Bone Marrow Imaging Whole Body	78104
Nuclear Bone Scan Limited	78300
Nuclear Bone Scan Multiple Areas	78305
Nuclear Bone Scan Whole Body	78306
Bone Scan Three Phase	78315
DEXA Bone Densitometry, axial skeleton	77080
DEXA Bone Densitometry, peripheral skeleton	77081
Radiopharmaceutical localization of tumor, inflammatory process or distribution of radiopharmaceutical agent(s) (includes vascular flow and blood pool imaging, when performed); planar, single area (eg, head, neck, chest, pelvis), single day imaging	78800

Nuclear Medicine	CPT®
Radiopharmaceutical localization of tumor, inflammatory process or distribution of radiopharmaceutical agent(s) (includes vascular flow and blood pool imaging, when performed); planar, 2 or more areas (eg, abdomen and pelvis, head and chest), 1 or more days imaging or single area imaging over 2 or more days	78801
Radiopharmaceutical localization of tumor, inflammatory process or distribution of radiopharmaceutical agent(s) (includes vascular flow and blood pool imaging, when performed); planar, whole body, single day imaging	78802
Radiopharmaceutical localization of tumor, inflammatory process or distribution of radiopharmaceutical agent(s) (includes vascular flow and blood pool imaging, when performed); tomographic (SPECT), single area (eg, head, neck, chest, pelvis), single day imaging	78803
Radiopharmaceutical localization of tumor, inflammatory process or distribution of radiopharmaceutical agent(s) (includes vascular flow and blood pool imaging, when performed); tomographic (SPECT) with concurrently acquired computed tomography (CT) transmission scan for anatomical review, localization and determination/detection of pathology, single area (eg, head, neck, chest, pelvis), single day imaging	78830
Radiopharmaceutical localization of tumor, inflammatory process or distribution of radiopharmaceutical agent(s) (includes vascular flow and blood pool imaging, when performed); tomographic (SPECT), minimum 2 areas (eg, pelvis and knees, abdomen and pelvis), single day imaging, or single area imaging over 2 or more days	78831
Radiopharmaceutical localization of tumor, inflammatory process or distribution of radiopharmaceutical agent(s) (includes vascular flow and blood pool imaging, when performed); tomographic (SPECT) with concurrently acquired computed tomography (CT) transmission scan for anatomical review, localization and determination/detection of pathology, minimum 2 areas (eg, pelvis and knees, abdomen and pelvis), single day imaging, or single area imaging over 2 or more days	78832

Ultrasound	CPT®
Ultrasound, extremity, nonvascular; complete joint	76881
Ultrasound, extremity, nonvascular; limited, anatomic specific for focal abnormality	76882
Ultrasound, infant hips; dynamic (requiring physician manipulation)	76885
Ultrasound, infant hips; limited, static (not requiring physician manipulation)	76886
Ultrasound, axilla	76882
Ultrasound, upper back	76604

Ultrasound	CPT®
Ultrasound, lower back	76705
Ultrasound, other soft tissue areas not otherwise specified	76999
Limited bilateral noninvasive physiologic studies of upper or lower extremity arteries	93922
Complete bilateral noninvasive physiologic studies of upper or lower extremity arteries	93923
Duplex scan of upper extremity arteries or arterial bypass grafts; complete bilateral	93930
Duplex scan of upper extremity arteries or arterial bypass grafts; unilateral or limited	93931
Duplex scan of extremity veins including responses to compression and other maneuvers; complete bilateral study	93970
Duplex scan of extremity veins including responses to compression and other maneuvers; unilateral or limited study	93971
Duplex scan of hemodialysis access (including arterial inflow, body of access and venous outflow)	93990

General Guidelines (PEDMS-1.0)

MSP.GG.0001.0.A

v1.0.2024

- A pertinent clinical evaluation including a detailed history, physical examination, appropriate laboratory studies and basic imaging such as plain radiography or ultrasound should be performed prior to considering advanced imaging (CT, MR, Nuclear Medicine), unless the individual is undergoing guideline-supported scheduled imaging evaluation. A meaningful technological contact (telehealth visit, telephone call, electronic mail or messaging) can serve as a pertinent clinical evaluation.
- Plain x-ray should be done prior to advanced imaging. The results of plain x-rays performed after the current episode of symptoms started or changed need to be available to the requesting provider of the advanced imaging study. X-ray can rule out those situations that do not require advanced imaging, such as acute/healing fracture, osteomyelitis, and tumors of bone amenable to biopsy or radiation therapy (in known metastatic disease), etc.
 - Even in soft tissue masses, plain x-rays are helpful in evaluating for calcium/bony deposits, e.g. myositis ossificans and invasion of bone.
- Unless otherwise stated in a specific guideline section, repeat imaging studies of the same body area are not necessary unless there is evidence for progression of disease, new onset of disease, and/or documentation of how repeat imaging will affect individual management or treatment decisions.
- Provider-directed conservative care may include any or all of the following: R.I.C.E (rest, ice, compression, and elevation), NSAIDs (non-steroidal anti-inflammatory drugs), narcotic and non-narcotic analgesic medications, oral or injectable corticosteroids, viscosupplementation injections, a provider-directed home exercise program, cross-training, physical medicine, or immobilization by splinting/casting/bracing.
- These guidelines are based upon using advanced imaging to answer specific clinical questions that will affect patient management. Imaging is not indicated if the results will not affect individual management decisions. Standard medical practice would dictate continuing conservative therapy prior to advanced imaging in individuals who are improving on current treatment programs.

Age Considerations (PEDMS-1.1)

MSP.GG.0001.1.A

v1.0.2024

- Many conditions affecting the musculoskeletal system in the pediatric population are different diagnoses than those occurring in the adult population. For those diseases which occur in both pediatric and adult populations, differences may exist in management due to individual age, comorbidities, and differences in disease natural history between children and adults.
- Individuals who are ≤ 18 years old should be imaged according to the Pediatric Musculoskeletal Imaging Guidelines if discussed. Any conditions not specifically discussed in the Pediatric Musculoskeletal Imaging Guidelines should be imaged according to the General Musculoskeletal Imaging Guidelines. Individuals who are > 18 years old should be imaged according to the General Musculoskeletal Imaging Guidelines except where directed otherwise by a specific guideline section.

Appropriate Clinical Evaluation and Conservative Treatment (PEDMS-1.2)

MSP.GG.0001.2.A
v1.0.2024

- See: [General Guidelines \(PEDMS-1.0\)](#)

Modality General Considerations (PEDMS-1.3)

MSP.GG.0001.3.A

v1.0.2024

- MRI
 - MRI without contrast is the preferred modality for pediatric musculoskeletal imaging unless otherwise stated in a specific guideline section, as it is superior in imaging the soft tissues and can also define physiological processes in some instances, e.g. edema, loss of circulation (AVN), and increased vascularity (tumors).
 - MRI without and with contrast is frequently recommended for evaluation of tumors, infection, post-operative evaluation, arthrography, and juvenile idiopathic arthritis, as described in the disease-specific guideline sections.
 - Due to the length of time required for MRI acquisition and the need to minimize patient movement, anesthesia is usually required for almost all infants (except neonates) and young children (age <7 years), as well as older children with delays in development or maturity. This anesthesia may be administered via oral or intravenous route. In this individual population, MRI sessions should be planned with a goal of minimizing anesthesia exposure by adhering to the following considerations:
 - MRI procedures can be performed without and/or with contrast as supported by these condition-based guidelines. If intravenous access will already be present for anesthesia administration and there is no contraindication for using contrast, imaging without and with contrast may be appropriate if requested. By doing so, the requesting provider may avoid repetitive anesthesia administration to perform an MRI with contrast if the initial study without contrast is inconclusive.
 - Recent evidence-based literature demonstrates the potential for gadolinium deposition in various organs including the brain, after the use of MRI contrast.
 - The U.S. Food and Drug Administration (FDA) has noted that there is currently no evidence to suggest that gadolinium retention in the brain is harmful and restricting gadolinium-based contrast agents (GBCAs) use is not warranted at this time. It has been recommended that GBCA use should be limited to circumstances in which additional information provided by the contrast agent is necessary and the necessity of repetitive MRIs with GBCAs should be assessed.
 - If multiple body areas are supported by eviCore guidelines for the clinical condition being evaluated, MRI of all necessary body areas should be obtained concurrently in the same imaging session.
 - The presence of surgical hardware or implanted devices may preclude MRI, as magnetic field distortion may limit detail in adjacent structures. CT may be the procedure of choice in these cases.

- The selection of best examination may require coordination between the provider and the imaging service.
- CT
 - CT without contrast is generally superior to MRI for imaging bone and joint anatomy; thus it is useful for studying complex fractures (particularly of the joints, dislocations, and assessing delayed union or non-union of fractures, integration of bone graft material, if plain x-rays are equivocal).
 - CT should not be used to replace MRI in an attempt to avoid sedation unless listed as a recommended study in a specific guideline section.
 - CT beam attenuation can result in streak artifact which can obscure adjacent details. This can occur with radiopaque material such as metal objects or dense bones.
 - The selection of best examination may require coordination between the requesting provider and the rendering imaging facility.
- Ultrasound
 - Ultrasound is frequently used to evaluate infants for hip dysplasia, to detect and/or aspirate joint effusion, and as an initial evaluation of extremity soft tissue masses.
 - CPT® codes vary by body area and the use of Doppler imaging. These CPT® codes are included in the table at the beginning of this guideline.
- Nuclear Medicine
 - Nuclear medicine studies are commonly used in evaluation of the peripheral musculoskeletal system, and other rare indications exist as well:
 - Bone scan (CPT® 78315), Distribution of Radiopharmaceutical Agent SPECT (CPT® 78803, or 78831), or SPECT/CT (CPT® 78830) is indicated for evaluation of suspected loosening of orthopedic prostheses when recent plain x-ray is nondiagnostic.
 - Nuclear medicine bone marrow imaging (CPT® codes: CPT® 78102, CPT® 78103, or CPT® 78104), SPECT (CPT® code: 78803), or SPECT/CT (CPT® 78830) is indicated for detection of ischemic or infarcted regions in sickle cell disease.
 - Triple phase bone scan (CPT® 78315) is indicated for evaluation of complex regional pain syndrome or reflex sympathetic dystrophy.
- 3D Rendering
 - 3D Rendering indications in pediatric musculoskeletal imaging are identical to those in the general imaging guidelines. See: **3D Rendering (MS-3)** for imaging guidelines.
- Bilateral Imaging
 - Coding for bilateral imaging may vary from health care plan to health care plan. Not all coding options may be available for all health care plans.

The guidelines listed in this section for certain specific indications are not intended to be all-inclusive; clinical judgment remains paramount and variance from these guidelines may be appropriate and warranted for specific clinical situations.

References (PEDMS-1)

v1.0.2024

1. ACR–ASER–SCBT–MR–SPR Practice Parameter for the performance of pediatric computed tomography (CT). Revised 2019 (Resolution 6). <https://www.acr.org/-/media/ACR/Files/Practice-Parameters/CT-Ped.pdf?la=en>
2. ACR–SPR–SSR Practice Parameter for the performance of radiography of the extremities. Revised 2018 (Resolution 6). <https://www.acr.org/-/media/ACR/Files/Practice-Parameters/Rad-Extremity.pdf?la=en>
3. ACR Practice Parameter for performing and interpreting magnetic resonance imaging (MRI). Revised 2022 (Resolution 8). <https://www.acr.org/-/media/ACR/Files/Practice-Parameters/MR-Perf-Interpret.pdf>.
4. Biassoni L, Easty M. Paediatric nuclear medicine imaging. *Br Med Bull*. 2017;123(1):127-148. doi:10.1093/bmb/ldx025.
5. Ing C, DiMaggio C, Whitehouse A, et al. Long-term differences in language and cognitive function after childhood exposure to anesthesia. *Pediatrics*. 2012;130(3):e476-e485. doi:10.1542/peds.2011-3822d.
6. Monteleone M, Khandji A, Cappell J, et al. Anesthesia in children: perspectives from nonsurgical pediatric specialists. *J Neurosurg Anesthesiol*. 2014;26(4):396-398. doi:10.1097/ana.000000000000124.
7. DiMaggio C, Sun LS, Li G. Early Childhood exposure to anesthesia and risk of developmental and behavioral disorders in a sibling birth cohort. *Anesth Analg*. 2011;113(5):1143-1151. doi:10.1213/ane.0b013e3182147f42.
8. Hindorf C, Glatting G, Chiesa C, et al. EANM Dosimetry committee guidelines for bone marrow and whole body dosimetry. *Eur J Nucl Med Mol Imaging*. 2010;37(6):1238-1250. doi:10.1007/s00259-010-1422-4.
9. Hryhorczuk AL, Restropo R. Pediatric musculoskeletal ultrasound: practical imaging approach. *AJR*. 2016;206:W62-W72. doi:10.2214/AJR.15.15858.
10. Fraum TJ, Ludwig DR, Bashir MR, et al. Gadolinium-based contrast agents: a comprehensive risk assessment. *J Magn. Reson. Imaging*. 2017;46(2):338–353. doi:10.1002/jmri.25625.
11. FDA Medical Imaging Drug Advisory Committee meeting 9/8/17 Minutes available at: <https://www.fda.gov/downloads/AdvisoryCommittees/CommitteesMeetingMaterials/Drugs/MedicalImagingDrugsAdvisoryCommittee/UCM574746.pdf>.
12. Siegel MJ. Musculoskeletal system and vascular imaging. In: Zinner S, Fischer A, eds. *Pediatric sonography*. 5th ed. Philadelphia, PA: Wolters Kluwer; 2018:601-11.
13. Fotenos, A. *Update on FDA approach to safety issue of gadolinium retention after administration of gadolinium-based contrast agents*. FDA. <https://www.fda.gov/media/116492/download>. Accessed April 22, 2020.
14. Blumfield E, Swenson DW, Iyer RS, Stanescu AL. Gadolinium-based contrast agents – review of recent literature on magnetic resonance imaging signal intensity changes and tissue deposits, with emphasis on pediatric patients. *Pediatric Radiology*. 2019;49(4):448-457. doi:10.1007/s00247-018-4304-8.

Fracture and Dislocation (PEDMS-2)

Guideline

Fracture and Dislocation (PEDMS-2)

Acute Fracture (PEDMS-2.1)

Joint-Adjacent Fracture (PEDMS-2.2)

Growth Plate Injuries (Salter-Harris Fractures) (PEDMS-2.3)

Osteochondral or Chondral Fractures, Including Osteochondritis Dissecans (PEDMS-2.4)

Stress/Occult Fracture (PEDMS-2.5)

Compartment Syndrome (PEDMS-2.6)

Physical Child Abuse (PEDMS-2.7)

References (PEDMS-2)

Fracture and Dislocation (PEDMS-2)

MSP.FX.0002.0.A

v1.0.2024

- A pertinent clinical evaluation including a detailed history, physical examination, and plain radiography should be performed prior to considering advanced imaging.

Acute Fracture (PEDMS-2.1)

MSP.FX.0002.1.A

v1.0.2024

- Plain x-rays should be performed initially in any obvious or suspected acute fracture or dislocation.
 - If plain x-rays are positive, no further imaging is generally indicated except in complex (comminuted or displaced) joint fractures where MRI or CT without contrast can be approved for preoperative planning.
 - 3D Rendering may sometimes be indicated for complex fracture repairs. See: **3D Rendering (MS-3)** in the Musculoskeletal Imaging Guidelines.
- Ultrasound (CPT® 76881 or CPT® 76882) may be approved for evaluation of fracture, but is not required to allow for other advanced imaging¹², especially in infants¹³.
- CT or MRI without contrast is indicated if plain x-rays are negative or equivocal for fracture, and fracture or bone marrow edema is still clinically suspected, and if the results will determine immediate treatment decisions as documented by the treating physician.¹²
- Bone scan may be approved for evaluation of suspected fracture when two x-rays are negative at least 10 days apart, using any of the following CPT® code combinations:
 - CPT® 78300, CPT® 78305, or CPT® 78306 as a single study
 - See: **Stress/Occult Fracture (PEDMS-2.5)** for bone scan indications

Joint-Adjacent Fracture (PEDMS-2.2)

MSP.FX.0002.2.A

v1.0.2024

- CT without contrast can be approved in complex (comminuted or displaced) fractures seen on plain x-ray involving a joint for preoperative planning.
- CT without contrast can be approved when there is clinical concern for delayed union or non-union of fracture or joint fusions on follow-up plain x-ray.

Growth Plate Injuries (Salter-Harris Fractures) (PEDMS-2.3)

MSP.FX.0002.3.A

v1.0.2024

- These fractures can generally be diagnosed and managed adequately with plain x-ray.
- In case of severe injury with displacement of bone fractures seen on plain x-ray, CT without contrast may be indicated prior to surgical intervention.
- If there is concern for delayed union or non-union of the bone seen on plain x-ray, CT without contrast is indicated.
- MRI without contrast is indicated for the evaluation of a suspected physeal bar in a healing fracture or other complication of a fracture involving the growth plate seen on plain x-ray, which may result in abnormal growth.
- Compressive injuries of the growth plate (Salter-Harris V) injuries may be difficult to identify on plain films, and MRI without contrast is indicated for confirmation.

Osteochondral or Chondral Fractures, Including Osteochondritis Dissecans (PEDMS-2.4)

MSP.FX.0002.4.A

v1.0.2024

An osteochondral fracture is a tear of the cartilage which covers the end of a bone, within a joint. It is also known as Osteochondritis Dissecans. In both disorders, loose bone fragments may form in a joint.

- If x-rays are negative and an osteochondral fracture is still suspected, or if x-ray or clinical exam suggests an unstable osteochondral injury, either MRI without contrast, MR arthrogram, or CT arthrogram of the involved joint is indicated.
- If plain x-rays show a non-displaced osteochondral fragment, follow up imaging should be with plain x-rays. Advanced imaging is not necessary.
- MRI without contrast or CT without contrast is indicated when healing cannot be adequately assessed on follow up plain x-rays.¹¹

Stress/Occult Fracture (PEDMS-2.5)

MSP.FX.0002.5.A

v1.0.2024

- These fractures can usually be adequately evaluated by history, physical exam, and x-ray. Advanced imaging may be appropriate as discussed below if the initial evaluation of history, physical exam, and plain x-ray fails to establish a definitive diagnosis.
- Plain x-rays should be performed before advanced imaging. Plain x-rays are often negative initially, but may become positive after 14 days.
- If stress or occult fracture is suspected involving the pelvis, sacrum, hip, femur, tibia, tarsal navicular, proximal 5th metatarsal, or scaphoid, and initial plain x-ray fails to establish a definitive diagnosis:
 - MRI or CT without contrast is indicated, without conservative care or follow-up plain x-rays OR
 - Bone scan (CPT[®] 78315, 78306, or 78300), SPECT/CT (CPT[®] 78830), or Distribution Of Radiopharmaceutical Agent SPECT (CPT[®] 78803) may be approved in place of MRI or CT if provider requests
- For all other suspected stress or occult fractures, if follow-up plain x-rays are negative after 10 days of conservative care, or initial non-diagnostic x-ray is obtained a minimum of 14 days after the onset of symptoms:
 - MRI or CT without contrast is indicated OR
 - Bone scan (CPT[®] 78315, 78306, or 78300), SPECT/CT (CPT[®] 78830), or Distribution Of Radiopharmaceutical Agent SPECT (CPT[®] 78803) may be approved in place of MRI or CT if provider requests
- Periodic follow-up plain x-rays will usually show progressive healing.
 - CT without contrast is indicated when there is clinical concern for non-union.

Compartment Syndrome (PEDMS-2.6)

MSP.FX.0002.6.A

v1.0.2024

- Acute compartment syndrome is a clinical diagnosis made by direct measurement of compartment pressure and is a surgical emergency. Advanced imaging is not indicated.
- See: **Chronic Exertional Compartment Syndrome (MS-11.3)** for imaging guidelines.

Physical Child Abuse (PEDMS-2.7)

MSP.FX.0002.7.A

v1.0.2024

- See: **Suspected Physical Child Abuse (PEDMS-7)** for imaging guidelines

References (PEDMS-2)

v1.0.2024

1. Mintz DN, Roberts CC, Bencardino JT, et al. ACR Appropriateness Criteria®. Chronic hip pain. Date of origin: 1985. Last review date: 2022. <https://acsearch.acr.org/docs/69425/Narrative>.
2. Bruno MA, Weissman BN, Kransdorf MJ, et al. ACR Appropriateness Criteria®. Acute hand and wrist trauma. Date of origin: 1998. Last review date: 2018. <https://acsearch.acr.org/docs/69418/Narrative/>
3. Luchs JS, Flug JA, Weissman BN, et al. ACR Appropriateness Criteria®. Chronic ankle pain. Date of origin: 1998. Last review date: 2017. <https://acsearch.acr.org/docs/69422/Narrative>.
4. Taljanovic MS, Chang EY, Ha AS, et al. ACR Appropriateness Criteria®. Acute Trauma to the Knee. Last review date: 2019. <https://acsearch.acr.org/docs/69419/Narrative/>.
5. Bencardino JT, Stone TJ, Roberts CC, et al. ACR Appropriateness Criteria®. Stress (fatigue/insufficiency) fracture, including sacrum, excluding other vertebrae. Last review date: 2016. <https://acsearch.acr.org/docs/69435/Narrative/>.
6. Borsa JJ, Peterson HA, Ehman RL. MR imaging of physeal bars. *Radiology*. 1996;199(3):683-687. doi:10.1148/radiology.199.3.8637987.
7. Rodrigo RM, Vilanova JC, Martel J. Sports injuries in children and adolescents: a case-based approach. New York, NY: Springer; 2014.
8. Wootton-Gorges SL, Soares BP, Alazraki AL, et al. ACR Appropriateness Criteria®. Suspected physical abuse—child. Last review date: 2016. <https://acsearch.acr.org/docs/69443/Narrative/>.
9. Christian CW, Crawford-Jakubiak JE, Flaherty EG, et al. AAP Clinical Practice Guideline: The evaluation of suspected physical child abuse. *Pediatrics*. 2015;135(5):e1337-e1354. doi:10.1542/peds.2015-0356 .
10. Nguyen JC, Markhardt BK, Merrow AC, Dwek JR. Imaging of pediatric growth plate disturbances. *RadioGraphics*. 2017;37(6):1791-812.
11. Ecklund K. Sports-related injuries of the pediatric musculoskeleton: lower extremity. 2021. In: Hodler J, Kubik-Huch RA, von Schulthess GK, eds. Musculoskeletal Diseases 2021-2024: Diagnostic Imaging [Internet]. Cham (CH): Springer; 2021. Chapter 19. PMID: 33950618.
12. Kraus R, Dresing K. Rational usage of fracture imaging in children and adolescents. *<Diagnostics (Basel)>*. 2023;13(3):538. doi:10.3390/diagnostics13030538.
13. Chauvin NA, Khwaja A. Musculoskeletal imaging in neonates: use of ultrasound. *<Pediatr Radiol>*. 2022;52(4):765-776. doi:10.1007/s00247-021-05152-2.

Soft Tissue and Bone Masses (PEDMS-3)

Guideline

Soft Tissue and Bone Masses – General Considerations (PEDMS-3.1)

Soft Tissue Mass with Negative X-ray and Abnormal Ultrasound (PEDMS-3.2)

Soft Tissue Mass with Calcification/Ossification on X-ray (PEDMS-3.3)

Mass Involving Bone (Including Suspected Lytic and Blastic Metastatic Disease) (PEDMS-3.4)

References (PEDMS-3)

Soft Tissue and Bone Masses – General Considerations (PEDMS-3.1)

MSP.ST.0003.1.A

v1.0.2024

- A pertinent clinical evaluation including a detailed history, physical examination, with detailed information on the mass (including location, size, duration, solid vs. cystic, fixed vs. not fixed to bone) should be performed prior to considering advanced imaging.
- Evaluation by a surgical specialist or oncologist is strongly recommended to help determine the most helpful advanced imaging studies for an individual.
- Plain x-rays should be performed as initial imaging. This is true even for soft tissue masses that are clearly not directly associated with osseous structures. Details such as soft tissue calcification, presence or absence of phleboliths, radiographic density, and any effect on adjacent bone are all potentially significant plain film findings that may help better identify the etiology of the mass and determine the optimal modality and contrast level when advanced imaging is indicated.
- Ultrasound (CPT® 76881 or CPT® 76882) if initial plain x-ray is negative to evaluate:
 - Ill-defined masses or areas of swelling
 - Hematomas
 - Subcutaneous lipomas with inconclusive clinical examination
 - Lipomas in other locations
 - Masses that have been present and stable for ≥ 1 year
 - Vascular malformations (see: **Vascular Anomalies (PEDPVD-2)** in the Pediatric Peripheral Vascular Disease Imaging Guidelines)
- Advanced imaging is not indicated for the following entities:
 - Ganglion cysts
 - Sebaceous cysts
 - Hematomas
 - Subcutaneous lipomas
 - MRI without or without and with contrast can be performed if surgery is planned.
- MRI without and with contrast, or ultrasound (CPT® 76881 or CPT® 76882) is indicated for lipomas in other locations (not subcutaneous).

Soft Tissue Mass with Negative X-ray and Abnormal Ultrasound (PEDMS-3.2)

MSP.ST.0003.2.A

v1.0.2024

- MRI without and with contrast is indicated when plain x-ray is negative and ultrasound is abnormal.
 - CT without or with contrast is indicated if MRI is contraindicated.

Soft Tissue Mass with Calcification/Ossification on X-ray (PEDMS-3.3)

MSP.ST.0003.3.A

v1.0.2024

- MRI without and with contrast is indicated when calcification/ossification is noted on plain x-ray.
 - CT without or with contrast is indicated if MRI is contraindicated.

Mass Involving Bone (Including Suspected Lytic and Blastic Metastatic Disease) (PEDMS-3.4)

MSP.ST.0003.4.A

v1.0.2024

- Complete radiograph of the entire bone containing the lesion of bone is required prior to consideration of advanced imaging. Many benign bone tumors have a characteristic appearance on plain x-ray and advanced imaging is not necessary unless one of the following applies:
 - MRI without and with contrast and/or CT without may be indicated for preoperative planning.
 - MRI without and with contrast when the diagnosis is uncertain based on plain x-ray appearance.
 - CT without or with contrast can be approved if MRI is contraindicated.
- Surveillance of benign bony lesions is with plain x-ray¹¹
 - MRI without and with contrast may be approved for new findings on x-ray, or new or worsening clinical symptoms not explained by recent x-ray.
- Osteochondroma, osteoid osteoma, osteogenic sarcoma, and Ewing sarcoma family of tumors should be imaged according to **Bone Tumors (PEDONC-9)** in the Pediatric Oncology Imaging Guidelines.
- If there is concern for metastatic disease in an individual with a known malignancy, refer to the appropriate Pediatric Oncology Imaging Guideline.

References (PEDMS-3)

v1.0.2024

1. ACR–SPR–SSR Practice parameter for the performance and interpretation of magnetic resonance imaging (MRI) of bone and soft tissue tumors. Revised 2020 (Resolution 30) <https://www.acr.org/-/media/ACR/Files/Practice-Parameters/MR-SoftTissue-Tumors.pdf?la=en>.
2. Arndt CAS. Soft Tissue Sarcomas. In: Kliegman RM, St. Geme JW III, Blum NJ, et. al., eds. *Nelson Textbook of Pediatrics*. 21st edition. Philadelphia, PA: Elsevier; 2020:2685-2688.
3. Arndt CAS. Neoplasms of bone. In: Kliegman RM, St. Geme JW III, Blum NJ, et. al., eds. *Nelson Textbook of Pediatrics*. 21st edition. Philadelphia, PA: Elsevier; 2020:2689-2697.
4. Eutsler EP, Siegel MJ. Musculoskeletal system and vascular imaging. In: Zinner S, Fischer A, eds. *Pediatric sonography*. 5th ed. Philadelphia, PA: Wolters Kluwer; 2018:601-11.
5. Johnson CM, Navarro OM. Clinical and sonographic features of pediatric soft-tissue vascular anomalies part I: classification, sonographic approach and vascular tumors. *Pediatr Radiol*. 2017;47(9):1184-95. doi:10.1007/s00247-017-3885-y.
6. Johnson CM, Navarro OM. Clinical and sonographic features of pediatric soft-tissue vascular anomalies part 2: vascular malformations. *Pediatr Radiol*. 2017;47(9):1196-1208. doi:10.1007/s00247-017-3906-x.
7. Morrison WB, Weissman BN, Kransdorf MJ, et al. *ACR Appropriateness Criteria*®. Primary bone tumors. Date of origin: 1995. Last review date: 2019. <https://acsearch.acr.org/docs/69421/Narrative/>.
8. Mintz DN, Roberts CC, Bencardino JT, et al. *ACR Appropriateness Criteria*®. Chronic hip pain. Last review 2022. <https://acsearch.acr.org/docs/69425/Narrative/>.
9. Sargar KM, Sheybani EF, Shenoy A, Aranake-Chrisinger J, Khanna G. Pediatric fibroblastic and myofibroblastic tumors: a pictorial review. *RadioGraphics*. 2016;36:1195-1214. doi:10.1148/rg.2016150191.
10. Sheybani EF, Eutsler EP, Navarro OM. Fat-containing soft-tissue masses in children. *Pediatr radiol*. 2016;46(13):1760-73. doi:10.1007/s00247-016-3690-z.
11. Collier CD, Nelson GB, Conry KT, Kosmas C, Getty PJ, Liu RW. The natural history of benign bone tumors of the extremities in asymptomatic children: A longitudinal radiographic study. *J Bone Joint Surg Am*. 2021;103(7):575-580. doi:10.2106/JBJS.20.00999. PMID: 33646982.

Limping Child (PEDMS-4)

Guideline

General Evaluation of the Limping Child (PEDMS-4.1)

Limping Child with Suspected Trauma (PEDMS-4.2)

Limping Child with Suspected Infection (PEDMS-4.3)

Limping Child with No Evidence of Trauma or Infection (PEDMS-4.4)

References (PEDMS-4)

General Evaluation of the Limping Child (PEDMS-4.1)

MSP.LC.0004.1.A

v1.0.2024

- This guideline primarily applies to children under the age of 6 years. It may also be applied to older children with pre-existing conditions who may not be able to communicate, such as a child with severe intellectual disability. Many of these cases will be urgent, because of the risk of adverse outcomes in delay of diagnosis.
- A pertinent clinical evaluation, including a detailed history and physical examination, should be performed, which will help determine any indication for advanced imaging. Based on this clinical evaluation, the most likely etiology should be determined, usually trauma, infection, or neither trauma nor infection.
- X-ray should be obtained if there are no localized findings on physical examination.⁵

Limping Child with Suspected Trauma (PEDMS-4.2)

MSP.LC.0004.2.A

v1.0.2024

- Plain radiographs are indicated for detection of fractures, destructive lesions, and avascular necrosis. For children under age 4 this may require x-rays of the entire leg from hip to foot. If clinical suspicion is high for “toddler fracture” imaging may start with tibia/fibula radiographs, and if a fracture is demonstrated, additional imaging may not be required.
- If initial radiographs are negative, but limping symptoms or avoidance of weight-bearing persist, follow-up radiographs in 7 to 10 days are indicated.
 - If plain films are negative and suspicion remains high for stress fractures or soft tissue injury:
 - MRI without contrast of the affected body area OR
 - Radionuclide bone scan (CPT® 78300, CPT® 78305, CPT® 78306, or CPT® 78315), SPECT/CT (CPT® 78830), or SPECT (CPT® 78803) may be approved if implanted hardware or devices precluding MRI are present.
- CT use is limited in the evaluation of the limping child with suspected trauma.

Limping Child with Suspected Infection (PEDMS-4.3)

MSP.LC.0004.3.A
v1.0.2024

- Pain localized to hip:
 - It is essential to exclude septic arthritis. Ultrasound of the hip (CPT® 76881 or 76882) is used to exclude hip joint effusion.
 - Hip joint fluid aspiration to distinguish infection from non-infectious etiologies if hip joint effusion is demonstrated.
 - Plain radiographs should be obtained if no hip joint effusion is demonstrated.
 - MRI without contrast (CPT® 73721) or without and with contrast (CPT® 73723) is indicated if plain films are not diagnostic.
- Pain localized distal to hip:
 - MRI without contrast or without and with contrast of the affected body part if plain radiographs are not diagnostic.
- Nonlocalized pain:
 - Plain radiographs of the spine, pelvis, and lower extremities may be necessary to localize the abnormality.
 - If plain radiography is not diagnostic and suspicion for infection remains high:
 - Whole-body bone scan (CPT® 78306) OR
 - SPECT (CPT® 78803) OR
 - SPECT/CT (CPT® 78830) OR
 - MRI without contrast or without and with contrast of the affected body area

Limping Child with No Evidence of Trauma or Infection (PEDMS-4.4)

MSP.LC.0004.4.A

v1.0.2024

- This differential diagnosis is quite broad.
 - Transient (or toxic) synovitis of the hip:
 - Ultrasound of the hip (CPT® 76881 or CPT® 76882) is the preferred initial exam.
 - Plain radiographs if no hip effusion is demonstrated.
 - Hip joint fluid aspiration is indicated if a hip joint effusion is demonstrated. This is usually performed with US guidance, though fluoroscopic guidance or blind aspiration may be required.
 - Avascular Necrosis, see: **Avascular Necrosis (AVN)/ Legg-Calvé-Perthes Disease (PEDMS-6)**
 - Juvenile Idiopathic Arthritis, see: **Juvenile Idiopathic Arthritis (PEDMS-10.1)**
 - Histiocytic Disorders, see: **Histiocytic Disorders (PEDONC-18)** in the Pediatric Oncology Imaging Guidelines
 - Neoplasm, see: **General Guidelines (PEDONC-1), Pediatric Leukemias (PEDONC-3), Neuroblastoma (PEDONC-6), Pediatric Soft Tissue Sarcomas (PEDONC-8), or Bone Tumors (PEDONC-9)** in the Pediatric Oncology Imaging Guidelines
 - Child abuse, see: **Suspected Physical Child Abuse (PEDMS-7)**

References (PEDMS-4)

v1.0.2024

1. Sadfar NM, Rigsby CK, Iyer RS, et al. *ACR Appropriateness Criteria*®. Limping child—Ages 0-5 Years. Date of origin: 1995. Last review date: 2018. <https://acsearch.acr.org/docs/69361/Narrative/>
2. Herman MJ, Martinek M. The limping child. *Pediatr Rev*. 2015;36(5):184-197. doi:10.1542/pir.36-5-184.
3. Chaturvedi A, Rupasov A. The acutely limping preschool and school-age child: an imaging perspective. *Semin Musculoskelet Radiol*. 2018;22(1):46-56. doi:10.1055/s-0037-1608001.
4. Thapa M, Vo JN, Shiels WE. Ultrasound-guided musculoskeletal procedures in children. *Pediatr Radiol*. 2013;43:55-60. doi:10.1007/s00247-012-2599-4.
5. Karout L, Naffaa L. Pediatric hip disorders: imaging guidelines and recommendations. *Radiol Clin North Am*. 2022;60(1):149-163. doi:10.1016/j.rcl.2021.08.007.

Developmental Dysplasia of the Hip (PEDMS-5)

Guideline

Developmental Dysplasia of the Hip (PEDMS-5)

References (PEDMS-5)

Developmental Dysplasia of the Hip (PEDMS-5)

MSP.DZ.0005.A

v1.0.2024

Developmental dysplasia of the hip (DDH) was formerly known as congenital dislocation of the hip. DDH includes a spectrum of abnormalities including abnormal acetabular shape (dysplasia) and malposition of the femoral head ranging from mild subluxation, dislocatable hip to fixed dislocation. 60 to 80% of abnormalities are identified by physical exam, and more than 90% are identified by ultrasound. Treatment may involve placement in a Pavlik harness, casting, or surgery in extreme or refractory cases.

Screening studies

- The routine use of ultrasound in screening neonates and infants without risk factors for DDH is not recommended by the American Academy of Pediatrics and the American Academy of Orthopedic Surgeons.
- There are two sonographic methods of evaluating the hip: the dynamic stress (Harcke) technique and the static (Graf) technique
- Screening ultrasound (CPT® 76885 or CPT® 76886) is recommended for infants between 4 weeks⁸ of age and 4 months of age with one or more of the following risk factors:
 - Breech presentation
 - Family history of DDH
 - Abnormal hip exam (e.g. positive Ortolani or Barlow maneuvers, asymmetric thigh folds, shortening of the thigh observed on the dislocated side, limitation of hip abduction).
- For children between 4 and 6 months of age plain x-ray is the preferred imaging modality as femoral head ossification is often seen on x-ray in normal patients
 - If x-ray is inconclusive, ultrasound (CPT® 76885 or CPT® 76886) may be indicated
- Indications for follow-up hip ultrasound (CPT® 76885 or CPT® 76886):
 - Type IIA hip was diagnosed on a previous hip ultrasound using the Graf method and follow-up hip ultrasound is requested to confirm normal development.
 - Graf type IIA hip has an alpha angle (bony angle) between 50 to 59 degrees in a child less than 3 months of age.
 - The overwhelming majority of these hips mature spontaneously, but follow-up may be required to ensure that maturation has occurred.
 - Full description of the Graf classification can be found at: <http://radiopaedia.org/articles/ultrasound-classification-of-developmental-dysplasia-of-the-hip-1>.
 - Subluxation or dislocation was diagnosed on previous hip ultrasound using the dynamic Harcke imaging method.

- Prior ultrasound demonstrates abnormal hip and treatment has been applied, such as a Pavlik harness or other device. Follow-up ultrasound is indicated to document effectiveness of treatment, to ensure the femoral head remains located in the acetabulum or to identify treatment failure. The usual interval for follow-up sonography is monthly, but earlier imaging is indicated for clinical suspicion of treatment failure, subluxation or dislocation of the hip.
- MRI without contrast (CPT® 73721) or CT without contrast (CPT® 73700) is indicated to evaluate alignment following reduction. Children in casts or following surgery may require repeated advanced imaging to ensure the reduction remains satisfactory, or to assess incorporation of bone graft material.
- Hip ultrasound is NOT indicated for the following:
 - Infants less than 2 weeks of age, since hip laxity is normal after birth and usually resolves spontaneously.
 - Infants older than 6 months of age as plain x-ray of the hips become more reliable due to femoral head ossification and should be used in infants over 6 months of age.
 - Type I, IIB, IIC, IID, and III hips diagnosed on a previous hip ultrasound using the Graf method. Type I hip is normal, and Type IIB, IIC, IID, and III require referral for treatment rather than follow-up imaging.
 - Plain x-ray of the hips should be performed rather than ultrasound if there is a clinical suspicion for teratogenic dysplasia.

References (PEDMS-5)

v1.0.2024

1. Nguyen JC, Dorfman SR, Rigsby CK, et al. ACR appropriateness criteria: Developmental dysplasia of the hip—child. 2018, American College of Radiology. Reston, VA. [http://www.jacr.org/article/S1546-1440\(09\)00189-6/fulltext](http://www.jacr.org/article/S1546-1440(09)00189-6/fulltext).
2. Mulpuri K, Song KM, Gross RH, et al. The American Academy of Orthopaedic Surgeons Evidence-Based Guideline on detection and nonoperative management of pediatric developmental dysplasia of the hip in infants up to six months of age. *J Bone Joint Surg Am*. 2015;97(20):1717-1718. doi:10.2106/JBJS.O.00500.
3. Sankar WN, Horn BD, Winell JJ, Wells L. Developmental dysplasia of the hip. In: Kliegman RM, St. Geme JW III, Blum NJ, et al., eds. *Nelson Textbook of Pediatrics*. 21st edition. Philadelphia, PA: Elsevier; 2020:3623-3628.
4. Chin MS, Betz BW, Halanski MA. Comparison of hip reduction using magnetic resonance imaging or computed tomography in hip dysplasia. *J Pediatr Orthop*. 2011;31(5):525-529. doi:10.1097/BPO.0b013e31821f905b.
5. Shaw BA, Segal LS. Evaluation and referral for developmental dysplasia of the hip in infants. *Pediatrics*. 2016;138(6):e20163107. doi:10.1542/peds.2016-3107.
6. Wright J, James K. Developmental dysplasia of the hip. In: Aresti NA, Ramachandran M, Paterson M, Barry M, eds. *Paediatric Orthopedics in Clinical Practice*. London: Springer; 2016:69-90.
7. Ortiz-Neira CL, Paolucci EO, Donnon T. A meta-analysis of common risk factors associated with the diagnosis of developmental dysplasia of the hip in newborns. *Euro J Radiol*. 2012;8:e344-e351. doi:10.1016/j.ejrad.2011.11.003.
8. Karout L, Naffaa L. Pediatric hip disorders: imaging guidelines and recommendations. *Radiol Clin North Am*. 2022;60(1):149-163. doi:10.1016/j.rcl.2021.08.007.

Avascular Necrosis (AVN) / Legg-Calvé- Perthes Disease / Idiopathic Osteonecrosis (PEDMS-6)

Guideline

Avascular Necrosis and Legg-Calvé-Perthes Disease (PEDMS-6.1)
Osteonecrosis (PEDMS-6.2)
References (PEDMS-6)

Avascular Necrosis and Legg-Calvé-Perthes Disease (PEDMS-6.1)

MSP.AN.0006.1.A

v1.0.2024

- Plain x-ray is the initial imaging study and may be all that is necessary for follow-up¹¹.
- MRI Hip either without contrast (CPT[®] 73721) or without and with contrast (CPT[®] 73723) is indicated if the diagnosis is uncertain on plain x-ray¹⁰.
 - If MRI is contraindicated or unavailable, any one of the following studies may be approved in lieu of MRI:
 - CT scan without contrast, OR
 - Nuclear bone scan (CPT[®] codes: 78300, 78305, 78306, or 78803) OR
 - SPECT/CT (CPT[®] 78830)

Osteonecrosis (PEDMS-6.2)

MSP.AN.0006.2.A

v1.0.2024

- Osteonecrosis can occur in a number of conditions, including during treatment for developmental dysplasia of the hip.
- Individuals with acute lymphoblastic leukemia, lymphoblastic lymphoma, or other conditions with recurrent exposure to high dose corticosteroids and known or suspected osteonecrosis should be imaged according to guidelines in: **Acute Lymphoblastic Leukemia (ALL) (PEDONC-3.2)** in the Pediatric Oncology Imaging Guidelines.
- Known or suspected osteonecrosis in long-term cancer survivors should be imaged according to guidelines in: **Osteonecrosis in Long Term Cancer Survivors (PEDONC-19.4)** in the Pediatric Oncology Imaging Guidelines.
- X-ray is indicated as initial imaging study¹⁰
- MRI either without contrast or without and with contrast in other individuals with concern for osteonecrosis and inconclusive recent x-ray, if imaging results will change current individual management.
 - CT scan without contrast may be appropriate for surgical planning⁸

References (PEDMS-6)

v1.0.2024

1. Boutault JR, Baunin C, Bérard E, et al. Diffusion MRI of the neck of the femur in Legg-Calvé-Perthes disease: a preliminary study. *Diagn Interv Imaging*. 2013; 94(1):78-83. doi:10.1016/j.diii.2012.10.003.
2. Dillman JR, Hernandez RJ. MRI of Legg-Calvé-Perthes Disease. *AJR Am J Roentgenol*. 2009;193(5):1394-1407. doi:10.2214/AJR.09.2444.
3. Divi SN, Bielski RJ. Legg-Calvé-Perthes Disease. *Pediatric annals*. 2016 Apr 14;45(4):e144-9.
4. Gough-Palmer A, McHugh K. Investigating hip pain in a well child. *BMJ*. 2007;334:1216-1217. doi:10.1136/bmj.39188.515741.47.
5. Hindorf C, Glatting G, Chiesa C, et al. EANM Dosimetry Committee guidelines for bone marrow and whole body dosimetry. *Eur J Nucl Med Mol Imaging*. 2010;37(6):1238-1250. doi:10.1007/s00259-010-1422-4.
6. Kaste SC, Karimova EJ, Neel MD. Osteonecrosis in children after therapy for malignancy. *AJR Am J Roentgenol*. 2011;196(5):1011-18. doi:10.2214/AJR.10.6073.
7. Laine J, Martin BD, Novotny SA, et al. Role of advanced imaging in the diagnosis and management of active Legg-Calvé-Perthes Disease. *J Am Acad Orthop Surg*. 2018;26:526-36. doi:10.5435/JAAOS-D-16-00856.
8. Murphey MD, Foreman KL, Klassen-Fischer MK, Fox MG, Chung EM, Kransdorf MJ. From the radiologic pathology archives imaging of osteonecrosis: radiologic-pathologic correlation. *Radiographics*. 2014;34:1003-1028. doi:10.1148/rg.344140019.
9. Sankar WN, Winell JJ, Horn DB, Wells L. Legg-Calve-Perthes Disease. In: Kliegman RM, St. Geme JW III, Blum NJ, et al., eds. *Nelson Textbook of Pediatrics*. 21st edition. Philadelphia, PA: Elsevier; 2020:3628-3631.
10. Ha AS, Chang EY, Bartolotta RJ, et. al. ACR Appropriateness Criteria® Osteonecrosis: 2022 Update. *J Am Coll Radiol*. 2022;19(11S):S409-S416. doi: 10.1016/j.jacr.2022.09.009.
11. Divi SN, Bielski RJ. Legg-Calvé-Perthes Disease. *Pediatr Ann*. 2016;45(4):e144-9. doi:10.3928/00904481-20160310-03.

Suspected Physical Child Abuse (PEDMS-7)

Guideline

Suspected Physical Child Abuse (PEDMS-7)

References (PEDMS-7)

Suspected Physical Child Abuse (PEDMS-7)

MSP.AB.0007.A

v1.0.2024

The suspicion of physical abuse of a child often requires imaging, both for clinical management and for forensic purposes. Every effort should be made to support reasonable requests for imaging in these children.

Child abuse injuries may affect any organ or system. Fractures are common, but injuries may also involve solid and hollow visceral organs, and/or superficial and deep soft tissue injuries. Some fracture patterns are highly correlated with non-accidental mechanisms, such as the “classic metaphyseal lesion,” also known as a corner fracture or bucket handle fracture, but fractures may occur in any bone. Unsuspected fractures, multiple fractures at various stages of healing, or fractures of a configuration or distribution inconsistent with the history provided, may raise the suspicion for physical abuse.

Skeletal Injury

- The radiographic skeletal survey is the primary imaging procedure for detecting fractures, especially in children age 24 months or younger. In older children, skeletal survey may be indicated, but more tailored radiographic evaluation based on history and physical examination may be preferable to skeletal survey.
- When skeletal survey is negative, but clinical suspicion remains high:
 - Bone scan (CPT® codes: CPT® 78300, 78305, 78306, 78315, or 78830) OR
 - Distribution of Radiopharmaceutical Agent SPECT (CPT® 78803)
- Suspected injury to the spine should usually first be evaluated with plain radiographs. CT without contrast and/or MRI without contrast or without and with contrast may be required for complete evaluation of osseous and soft tissue spine injuries. If requested for suspected or known physical abuse, both CT without contrast and/or MRI without contrast or without and with contrast of suspected sites should be approved.
- CT Chest without contrast (CPT® 71250) is indicated in patients with a negative skeletal survey and a high clinical suspicion for rib fracture associated with child abuse.⁸
- A repeat skeletal survey performed approximately 2 weeks after the initial examination can provide additional information on the presence and age of child abuse fractures and should be performed when abnormal or equivocal findings are found on the initial study and when abuse is suspected on clinical grounds

Head Injury

- CT Head without contrast (CPT® 70450) is indicated when there is clinical evidence of head injury or when skull fracture of any age is detected on survey skull x-ray.⁷

- CT Head without contrast (CPT® 70450) is also indicated when known or suspected cervical trauma is present in a pediatric individual.
- CT Head without contrast (CPT® 70450) is indicated in individuals less than 1 year of age, even if no neurologic symptoms are detected due to the great potential morbidity of abuse head trauma. MRI Brain without contrast (CPT® 70551) may also be approved.¹
- MRI Spine without contrast (CPT® 72141, 72146, 72148) or without and with contrast (CPT® 72156, 72157, 72158) may be approved when there is clinical evidence of head injury or when skull fracture of any age is detected on survey skull x-ray. CT Spine (CPT® 72125, CPT® 72128, CPT® 72131) may be approved if MRI is not readily available.⁹
- MRI Brain without contrast (CPT® 70551) or without and with contrast (CPT® 70553) is indicated to further evaluate brain parenchymal injury, or in a child where the clinical signs of brain injury are not sufficiently explained by CT findings.

Other Body Area Injuries

- CT should be performed with contrast unless an absolute contraindication exists.
- ANY of the following imaging studies are indicated for suspected injury to the abdomen or pelvis^{6,7}:
 - Abdominal ultrasound (CPT® 76700)
 - Pelvic ultrasound (CPT® 76856)
 - CT Abdomen with contrast (CPT® 74160)
 - CT Pelvis with contrast (CPT® 72193)
 - CT Abdomen and Pelvis with contrast (CPT® 74177)
- ANY of the following imaging studies are indicated for suspected injury to the chest:
 - CT Chest without contrast (CPT® 71250)
 - CT Chest with contrast (CPT® 71260)

Screening of other children

- Contacts are defined as the asymptomatic siblings, cohabiting children, or children under the same care as an index child with suspected child physical abuse. All contact children should undergo a thorough physical examination and a history elicited prior to imaging. Contact children younger than 12 months should have neuroimaging, and skeletal survey. CT Head without contrast (CPT® 70450) or MRI Brain without contrast (CPT® 70551) may be approved. Contact children aged 12 to 24 months should undergo skeletal survey. No routine imaging is indicated in asymptomatic children older than 24 months.¹⁰

References (PEDMS-7)

v1.0.2024

1. Wooten-Gorges SL, Soares BP, Alazarki AL, et al. *ACR Appropriateness Criteria*®. Suspected Physical Abuse—Child. Date of origin: 1984. Last review: 2016.
2. Campbell KA, Olson LM, and Keenan HT. Critical elements in the medical evaluation of suspected physical child abuse. *Pediatrics*. 2015;136(1):35-43. doi:10.1542/peds.2014-4192.
3. Christian CW, Crawford-Jakubiak JE, Flaherty EG et al. AAP Clinical Practice Guideline: the evaluation of suspected physical child abuse. *Pediatrics*. 2015;135(5):e1337-e1354. doi:10.1542/peds.2015-0356.
4. Henry MK, Wood JN. Advanced cervical spine imaging in abusive head trauma: an update on recent literature and future directions. *Acad pediatr*. 2018;18(7):733-735. doi:10.1016/j.acap.2018/05.008.
5. Society and College of Radiographers and The Royal College of Radiologists. *The radiological investigation of suspected physical abuse in children*. Revised 1st edition. London: The Royal College of Radiologists; 2018. https://www.rcr.ac.uk/system/files/publication/field_publication_files/bfcr174_suspected_physical_abuse.pdf.
6. Henry MK, Bennett CE, Wood JN, Servaes S. Evaluation of the abdomen in the setting of suspected child abuse. *Pediatric radiology*. 2021;23:1-7.
7. Bennett CE, Christian CW. Clinical evaluation and management of children with suspected physical abuse. *Pediatric radiology*. 2021;51(6):853-60.
8. Karmazyn B, Marine MB, Wanner MR, et. al. Chest CT in the evaluation of child abuse - when is it useful? *Child Abuse Negl*. 2022;133:105823. doi:10.1016/j.chiabu.2022.105823.
9. Karmazyn B, Reher TA, Supakul N, et. al. Whole-spine MRI in children with suspected abusive head trauma. *AJR Am J Roentgenol*. 2022;218(6):1074-1087. doi:10.2214/AJR.21.26674.
10. Mankad K, Sidpra J, Mirsky DM, et. al. International consensus statement on the radiological screening of contact children in the context of suspected child physical abuse. *JAMA Pediatr*. 2023;177(5):526-533. doi:10.1001/jamapediatrics.2022.6184.

Infection/Osteomyelitis (PEDMS-8)

Guideline

Infection/Osteomyelitis (PEDMS-8)

References (PEDMS-8)

Infection/Osteomyelitis (PEDMS-8)

MSP.OI.0008.A

v1.0.2024

- Infection and osteomyelitis imaging indications in pediatric individuals are similar to those for adult individuals other than the limping child.
 - See: **Infection/Osteomyelitis (MS-9)** in the Musculoskeletal Imaging Guidelines other than in the limping child.
 - See: **Limping Child with Suspected Infection (PEDMS-4.3)** for imaging guidelines when limping is present.
 - See: **Inflammatory Musculoskeletal Disease (PEDMS-10)** for imaging guidelines for chronic recurrent multifocal osteomyelitis (CRMO, which is an autoimmune disease).
- Ultrasound of the involved extremity (CPT® 76881 or CPT® 76882) is indicated to evaluate for effusion or soft tissue fluid collection⁶
 - Ultrasound is not a prerequisite for other advanced imaging studies
- Bone scan (CPT® 78300, 78305, 78306, or 78315), SPECT/CT (CPT® 78830, or 78832), or SPECT (CPT® 78803, or 78831) is indicated for evaluation of suspected bone infection if MRI cannot be done and when infection is multifocal, or when the infection is associated with orthopedic hardware or chronic bone alterations from trauma or surgery. Combining bone scintigraphy with a labeled leukocyte scan enhances sensitivity. A labeled leukocyte scan (radiopharmaceutical localization of tumor, inflammatory process, or distribution of radiopharmaceutical agent(s) imaging) - one of the following CPT® codes: CPT® 78800, CPT® 78801, 78802, or CPT® 78803 in concert with Tc-99m sulfur colloid marrow imaging (one of CPT® codes: CPT® 78102, CPT® 78103, or CPT® 78104) or SPECT/CT (CPT® 78830) is particularly useful in cases with altered bone marrow distribution, such as joint prosthesis.

References (PEDMS-8)

v1.0.2024

1. Tuson CE, Hoffman EB, and Mann MD. Isotope bone scanning for acute osteomyelitis and septic arthritis in children. *J Bone Joint Surg.* 1994;76(2):306-310.
2. Lazzarini L, Mader JT, Calhoun JH. Osteomyelitis in long bones. *J Bone Joint Surg.* 2004;86-A(10):2305-2318. doi:10.2106/00004623-200410000-00028.
3. Robinette E, Shah SS. Osteomyelitis. In: Kliegman RM, St. Geme JW III, Blum NJ, et. al., eds. *Nelson Textbook of Pediatrics*, Chapter 684. eds Kliegman RM, Stanton BF, St. Geme JW III, et al. 21st edition. Philadelphia, PA: Elsevier; 2020:3670-3676.
4. Funk SS, Copley LA. Acute hematogenous osteomyelitis in children: pathogenesis, diagnosis, and treatment. *Orthopedic Clinics.* 2017;48(2):199-208. doi:10.1016/j.ocl.2016.12.007.
5. Palestro CJ. Radionuclide imaging of osteomyelitis. *Semin Nucl Med.* 2015;45(1):32-46. doi:10.1053/j.semnuclmed.2014.07.005.
6. Shet NS, Iyer RS, et. al. *ACR Appropriateness Criteria*®. Osteomyelitis or Septic Arthritis-Child (Excluding Axial Skeleton). Date of origin: 2021. <https://acsearch.acr.org/docs/3158175/Narrative/>

Foreign Body (PEDMS-9)

Guideline

Foreign Body (PEDMS-9)

Reference (PEDMS-9)

Foreign Body (PEDMS-9)

MSP.FB.0009.A

v1.0.2024

- Foreign body imaging indications in pediatric individuals are similar to those for adult individuals. See: **Foreign Body – General (MS-6.1)** for imaging guidelines.
- The common soft tissue foreign bodies in children are wood, glass, and metal slivers. The latter two elements are radiopaque and visible to some degree on plain radiographs, whereas wood is usually radiolucent and nearly always imperceptible on radiographs. When a radiolucent foreign body is suspected, ultrasound (CPT® 76881 or 76882) can be used to identify the foreign body.

Reference (PEDMS-9)

v1.0.2024

1. Nung RCH, Lee AWH. Ultrasonographic findings of suspected retained foreign body in soft tissue following penetrating injury. *Hong Kong J Radiol.* 2017;20:76-83. doi:10.12809/hkjr1715382.

Inflammatory Musculoskeletal Disease (PEDMS-10)

Guideline

Inflammatory Musculoskeletal Disease (PEDMS-10.0)

Juvenile Idiopathic Arthritis (PEDMS-10.1)

Chronic Recurrent Multifocal Osteomyelitis (PEDMS-10.2)

Inflammatory Muscle Diseases (PEDMS-10.3)

References (PEDMS-10)

Inflammatory Musculoskeletal Disease (PEDMS-10.0)

MSP.MD.0010.0.A

v1.0.2024

- A pertinent clinical evaluation including a detailed history, physical examination, and plain radiography should be performed prior to considering advanced imaging.
- Inflammatory arthritis imaging indications in pediatric patients are very similar to those for adult individuals. See: **Rheumatoid Arthritis (RA) and Inflammatory Arthritis (MS-15)** in the Musculoskeletal Imaging Guidelines. Specific pediatric considerations are included below.

Juvenile Idiopathic Arthritis (PEDMS-10.1)

MSP.MD.0010.1.A

v1.0.2024

- Ultrasound (CPT® 76881 or 76882) is indicated for assessment of: size and characteristics of joint effusions, extent of synovial hypertrophy, which is the hallmark of juvenile idiopathic arthritis, and involvement of tendinous structures.
 - Repeat imaging for monitoring treatment or with planned treatment change may be approved
 - MRI of the most symptomatic joint without contrast or without and with contrast may be considered if ultrasound is inconclusive and MRI findings would alter individual management
- Distribution of Radiopharmaceutical Agent SPECT (CPT® 78802, or 78803), or SPECT/CT (CPT® 78830), is indicated for evaluation of facet arthropathy in patients with ankylosing spondylitis, osteoarthritis, or rheumatoid arthritis.
- MRI TMJ (CPT® 70336) is indicated annually for detecting silent TMJ arthritis in children with juvenile idiopathic arthritis (JIA).
- MRI without or without and with of the most involved joint may be approved to evaluate involved or symptomatic joints in the following situations:¹⁵
 - When diagnosis is uncertain prior to initiation of drug therapy
 - To study the effects of treatment with disease modifying anti-rheumatic drug (DMARD) therapy
 - To determine a change in treatment
- MRI (with the exception of the annual screening MRI of the TMJ discussed above) should NOT be considered for routine follow-up of treatment.

Chronic Recurrent Multifocal Osteomyelitis (PEDMS-10.2)

MSP.MD.0010.2.A

v1.0.2024

Chronic recurrent multifocal osteomyelitis (CRMO) is a rare autoimmune disease affecting multiple bones, arising most commonly during the second decade of life. Treatment consists of anti-inflammatory and immunomodulatory therapies, and is directed predominantly by status of clinical symptoms (most commonly pain).

- Individuals with CRMO can have the following imaging approved for evaluation of new or worsening pain, or response to treatment in patients without complete clinical resolution of pain symptoms, when plain x-rays are non-diagnostic:
 - Bone scan (CPT® codes: 78300, 78305, 78306, 78315) OR
 - SPECT (CPT® codes: 78803, or 78831), OR
 - Nuclear Bone Marrow imaging (CPT® codes: 78102, 78103, or 78104), OR
 - Radiopharmaceutical localization of tumor, inflammatory process, or distribution of radiopharmaceutical agent imaging (CPT® codes: 78800, 78801, 78802, or 78803), OR
 - SPECT/CT (CPT® codes: 78830, or 78832)
 - MRI without contrast of specific painful body areas when plain x-ray and bone scan are insufficient to direct acute individual care decisions.
- Literature¹⁴ suggests MRI may have greater sensitivity for clinically occult lesions than bone scan. Whole-body MRI (CPT® 76498) can be approved for CRMO in the following situations.
 - WBMRI may be approved in an individual suspected of having CRMO if characteristic MR findings of CRMO would preclude the need for a biopsy.
 - Characteristic finding include multiple lesions most commonly involving the juxtaphyseal/peri-physeal portions of the tibia and femur, the clavicle and thoracolumbar spine.
 - WBMRI may be approved every 6-12 months in individuals with an established diagnosis of CRMO to monitor treatment or to evaluate for clinically occult, but radiographically active lesions.
 - See: **Whole Body MR Imaging (Preface-5.2)** for additional details.

Inflammatory Muscle Diseases (PEDMS-10.3)

MSP.MD.0010.3.A

v1.0.2024

- A pertinent clinical face-to-face evaluation including a detailed history, physical examination, and plain radiography should be performed prior to considering advanced imaging.

Inflammatory Muscle Diseases:

These include but are not limited to dermatomyositis, polymyositis, and sporadic inclusion body myositis. MRI without contrast of a single site is indicated in these disorders for the following purposes:

- Selection of biopsy site
- Clinical concern for progression
- Treatment monitoring
- Detection of occult malignancy

Juvenile Dermatomyositis:

- MRI without contrast can frequently confirm the diagnosis and thus avoid a biopsy.
- CT without contrast (CPT® 73700) is indicated to follow progressive calcification in muscles, but MRI (CPT® 73718) is often used instead since it permits assessment of the primary muscle disease as well.
 - Both CT and MRI are rarely indicated concurrently.
- Contrary to adult dermatomyositis, juvenile dermatomyositis is very rarely paraneoplastic in nature, and routine screening for occult neoplasm is not indicated.
 - CT Chest (CPT® 71260) and Abdomen and Pelvis (CPT® 74177) with contrast are indicated for individuals with palpable lymphadenopathy or hepatosplenomegaly.

References (PEDMS-10)

v1.0.2024

1. Chauvin NA, Doria AS. Ultrasound imaging of synovial inflammation in juvenile idiopathic arthritis *Pediatr Radiol*. 2017;47(9):1160-1170. doi:10.1007/s00247-017-3934-6.
2. Voit AM, Arnoldi AP, Douis H, et al. Whole-body magnetic resonance imaging in chronic recurrent multifocal osteomyelitis: clinical longterm assessment may underestimate activity. *J Rheumatol*. 2015;42:1357-1537. doi:10.3899/jrheum.141026.
3. Restrepo R, Lee EY, Babyn PS. Juvenile idiopathic arthritis current practical imaging assessment with emphasis on magnetic resonance imaging. *Radiol Clin N Am*. 2013;51(4):703-719. doi:10.1016/j.rcl.2013.03.003.
4. Wu EY, Rabinovich CE. Juvenile idiopathic arthritis. In: Kliegman RM, St. Geme JW III, Blum NJ, et. al., eds. *Nelson Textbook of Pediatrics*. 21st edition. Philadelphia, PA: Elsevier; 2020:1260-1268.
5. Robinson AB, Reed AM. Juvenile dermatomyositis. In: Kliegman RM, St. Geme JW III, Blum NJ, et. al., eds. *Nelson Textbook of Pediatrics*. 21st edition. Philadelphia, PA: Elsevier; 2020:1280-1284.
6. Ackigoz G, Averill LW. Chronic recurrent multifocal osteomyelitis: typical patterns of bone involvement in whole-body bone scintigraphy. *Nucl Med Commun*. 2014;35(8):797-807. doi:10.1097/MNM.000000000000126.
7. Stern SM, Ferguson PJ. Autoinflammatory Bone Diseases. *Rheum Dis Clin N Am*. 2013;39(4):735-749. doi:10.1016/j.rdc.2013.05.002.
8. Hedrich CM, Hofmann SR, Pablik J, et al. Autoinflammatory bone disorders with special focus on chronic recurrent multifocal osteomyelitis. *Pediatr Rheumatol Online J*. 2013;11:47. doi:10.1186/1546-0096-11-47.
9. Borzutzky A, Stern S, Reiff A et al. Pediatric chronic nonbacterial osteomyelitis. *Pediatrics*. 2012;130(5):e1190-e1197 doi: 10.1542/peds.2011-3788.
10. Khanna G, Sato TSP, Ferguson P. Imaging of chronic recurrent multifocal osteomyelitis. *RadioGraphics*, 2009;29(4):1159-1177. doi:10.1148/rg.294085244.
11. Feldman BM, Rider LG, Reed AM, et al. Juvenile dermatomyositis and other idiopathic inflammatory myopathies of childhood. *The Lancet*. 2008;371(9631):2201-12. doi:10.1016/S0140-6736(08)60955-1.
12. Morris P, Dare J. Juvenile dermatomyositis as a paraneoplastic phenomenon: an update. *J Pediatr Hematol Oncol*. 2010;32(3):189-191. doi:10.1097/MPH.0b013e3181bf29a2.
13. Colebatch-Bourn AN, Edwards CJ, Collado P, et. al. EULAR-PRReS points to consider for the use of imaging in the diagnosis and management of juvenile idiopathic arthritis in clinical practice. *Annals of the rheumatic diseases*. 2015;74(11):1946-1957. doi:10.1136/annrheumdis-2015-207892.
14. Nico MAC, Araújo FF, Guimarães JB, et. al. Chronic nonbacterial osteomyelitis: the role of whole-body MRI. *Insights Imaging*. 2022;13(1):149. doi: 10.1186/s13244-022-01288-3.
15. Sudot-Szopińska I, Herregods N, Doria AS, et. al. Advances in musculoskeletal imaging in juvenile idiopathic arthritis. *Biomedicines*. 2022;10(10):2417. doi:10.3390/biomedicines10102417.
16. Basra HA, Humphries PD. Juvenile idiopathic arthritis: what is the utility of ultrasound? *Br J Radiol*. 2017;90(1073):20160920. doi:10.1259/bjr.20160920.
17. Arnoldi AP, Schlett CL, Douis H, et. al. Whole-body MRI in patients with non-bacterial osteitis: radiological findings and correlation with clinical data. *Eur Radiol*. 2017;27(6):2391-9. doi:10.1007/s00330-016-4586-x.
18. Roderick MR, Sen ES, Ramanan AV. Chronic recurrent multifocal osteomyelitis in children and adults: current understanding and areas for development. *Rheumatology (Oxford)*. 2018;57(1):41-48. doi:10.1093/rheumatology/kex066.
19. Villani M, de Horatio LT, Garganese M, et. al. Whole-body MRI versus bone scintigraphy: which is the best diagnostic tool in patients with chronic recurrent multifocal osteomyelitis (CRMO)? *Pediatr Rheumatol*. 2015;13:P58. doi:10.1186/1546-0096-13-S1-P58.
20. Huber AM. Juvenile idiopathic inflammatory myopathies. *Pediatr Clin North Am*. 2018;65(4):739-56. doi:10.1016/j.pcl.2018.04.006.
21. Zhao Y, Ferguson PJ. Chronic nonbacterial osteomyelitis and chronic recurrent multifocal osteomyelitis in children. *Pediatric Clinics*. 2018;65(4):783-800. doi:10.1016/j.pcl.2018.04.003.
22. Rosendahl K, Maas M. Update on imaging in juvenile idiopathic arthritis. *Pediatr radiol*. 2018;48(6):783-784. doi:10.1007/s00247-017-4039-y.
23. Andronikou S, Kraft JK, Offiah AC, et. al. Whole-body MRI in the diagnosis of paediatric CNO/CRMO. *Rheumatology*. 2020;59(10):2671-80. doi: 10.1093/rheumatology/keaa303.
24. Roderick MR, Shah R, Rogers V, Finn A, Ramanan AV. Chronic recurrent multifocal osteomyelitis (CRMO)–advancing the diagnosis. *Pediatric Rheumatology*. 2016;14(1):1-5. doi:10.1186/s12969-016-0109-1.
25. Malattia C, Tzaribachev N, van den Berg JM, Magni-Manzoni S. Juvenile idiopathic arthritis-the role of imaging from a rheumatologist's perspective. *Pediatric radiology*. 2018;48(6):785-91. doi:10.1007/s00247-017-4014-7.

26. Malattia C, Tolend M, Mazzone M, et. al. Current status of MR imaging of juvenile idiopathic arthritis. *Best Practice & Research Clinical Rheumatology*. 2020;3:101629. doi:10.1016/j.berh.2020.101629.

Muscle/Tendon Unit Injuries (PEDMS-11)

Guideline

Muscle/Tendon Unit Injuries (PEDMS-11)

Muscle/Tendon Unit Injuries (PEDMS-11)

MSP.MI.0011.A

v1.0.2024

- Muscle and tendon unit injury imaging indications in pediatric individuals are identical to those in the general imaging guidelines. See: **Muscle/Tendon Unit Injuries/Diseases (MS-11)** in the Musculoskeletal Imaging Guidelines.

Osgood-Schlatter Disease (PEDMS-12)

Guideline

Osgood-Schlatter Disease (PEDMS-12)

References (PEDMS-12)

Osgood-Schlatter Disease (PEDMS-12)

MSP.OD.0012.A

v1.0.2024

- Osgood-Schlatter Disease is defined as traction apophysitis of the tibial tubercle in skeletally immature individuals. Diagnosis is by clinical examination and x-ray, and treatment is conservative.
- Advanced imaging is not indicated in this disorder.

References (PEDMS-12)

v1.0.2024

1. Alessi S, Depaoli R, Canepari M, et al. Baker's cysts in pediatric patients: ultrasonographic characteristics. *J Ultrasound*. 2012;15:76-81. doi:10.1016/j.jus.2011.06.007.
2. Sarkissian EJ, Lawrence JTR. Osgood-Schlatter Disease and Sinding-Larsen-Johansson Syndrome. In: Kliegman RM, St. Geme JW III, Blum NJ, et. al., eds. *Nelson Textbook of Pediatrics*. 21st edition. Philadelphia, PA: Elsevier; 2020:3620-3621.
3. Griffin LY. *Essentials of Musculoskeletal Care*. 3rd edition. Rosemont, IL: American Academy of Orthopaedic Surgeons; 2005:713-714.
4. Kaneshiro NK. Osgood-Schlatter disease. Medline Plus. 10/11/2018. <http://www.nlm.nih.gov/medlineplus/ency/article/001258.htm>

Popliteal (Baker) Cyst (PEDMS-13)

Guideline

Popliteal (Baker) Cyst (PEDMS-13)

References (PEDMS-13)

Popliteal (Baker) Cyst (PEDMS-13)

MSP.PC.0013.A

v1.0.2024

Popliteal or Baker cyst in children is a different clinical entity than in adults and is almost never due to intra-articular pathology. These lesions are usually treated conservatively and rarely require surgery.

- Ultrasound (CPT® 76881 or 76882) is the appropriate initial imaging study.
- MRI without contrast (CPT® 73721) is indicated for preoperative planning or if ultrasound is non-diagnostic.

References (PEDMS-13)

v1.0.2024

1. Lawrence JTR. Popliteal cysts (baker cysts). In: Kliegman RM, St. Geme JW III, Blum NJ, et. al., eds. *Nelson Textbook of Pediatrics*. 21st edition. Philadelphia, PA: Elsevier; 2020:3618-3619.
2. Wheeless CR. Baker's cyst/popliteal cysts. Wheeless' Textbook of Orthopaedics. http://www.wheelessonline.com/ortho/bakers_cyst_popliteal_cysts.

Slipped Capital Femoral Epiphysis (SCFE) (PEDMS-14)

Guideline

Slipped Capital Femoral Epiphysis (SCFE) (PEDMS-14)
References (PEDMS-14)

Slipped Capital Femoral Epiphysis (SCFE) (PEDMS-14)

MSP.FE.0014.A

v1.0.2024

Slipped capital femoral epiphysis (SCFE) should be considered in young adolescents or preadolescents with groin, anterior thigh, or atraumatic knee pain. Symptoms often include a history of intermittent limp and pain for several weeks or months that are often poorly localized to the thigh, groin, or knee. Any obese adolescent or preadolescent presenting with a history of a limp and thigh, knee, or groin pain for several weeks to one month should be presumed to have a slipped capital femoral epiphysis (SCFE).

Imaging studies:

- Anteroposterior and lateral x-rays (frog leg or cross table lateral) of both hips will confirm or exclude the diagnosis.⁸
 - If clinical suspicion remains after negative plain films, MRI without contrast (CPT[®] 73721) or without and with contrast (CPT[®] 73723) is indicated to detect widening of the physis before the femoral head is displaced (pre-slip).
- Because a significant percentage of SCFE is bilateral at presentation, it is reasonable to evaluate the contralateral hip if requested, as some surgeons advocate surgical treatment of pre-slip.
- If MRI was not completed for diagnosis, MRI without contrast (CPT[®] 73721) is indicated for preoperative planning.

References (PEDMS-14)

v1.0.2024

1. Sankar WN, Winell JJ, Horn BD, Wells L. Slipped capital femoral epiphysis. In: Kliegman RM, St. Geme JW III, Blum NJ, et. al., eds. *Nelson Textbook of Pediatrics*. 21st edition. Philadelphia, PA: Elsevier; 2020:3631-3632.
2. Kim YJ, Sierra RJ. Report of breakout session: slipped capital femoral epiphysis management 2011. *Clin Orthop Relat Res*. 2012;470(12):3464-3466. doi:10.1007/s11999-012-2587-x.
3. Gough-Palmer A, McHugh K. Investigating hip pain in a well child. *BMJ*. 2007;334:1216-1217. doi:10.1136/bmj.39188.515741.47.
4. Hesper T, Zilkens C, Bittersohl B, Krauspe R. Imaging modalities in patients with slipped capital femoral epiphysis. *J Child Orthop*. 2017;11:99-106. doi:10.1302/1863-2548-11-160276.
5. Jarrett DY, Matheney T, Kleinman PK. Imaging SCFE: diagnosis, treatment and complications. 2013. *Pediatr Radiol*. 2013;43:S71-S82. doi:10.1007/s00247-012-2577-x.
6. Peck D. Slipped capital femoral epiphysis: diagnosis and management. *Am Fam Physician*. 2017;95(12):779-84.
7. Sucato DJ. Approach to the Hip for SCFE: the North American perspective. *J Pediatr Orthop*. 2018;38:S5-12. doi:10.1097/BPO.0000000000001183.
8. Karout L, Naffaa L. Pediatric hip disorders: imaging guidelines and recommendations. *Radiol Clin North Am*. 2022;60(1):149-163. doi:10.1016/j.rcl.2021.08.007.

Limb Length Discrepancy (PEDMS-15)

Guideline

Limb Length Discrepancy (PEDMS-15)

Limb Length Discrepancy (PEDMS-15)

MSP.LL.0015.A

v1.0.2024

- Limb length discrepancy imaging indications in pediatric individuals are identical to those in the general imaging guidelines. See: **Limb Length Discrepancy (MS-17.1)** in the Musculoskeletal Imaging Guidelines.

Congenital Anomalies of the Foot and Lower Extremity (PEDMS-16)

Guideline

Tarsal Coalition (Calcaneonavicular Bar/Rigid Flat Foot) (PEDMS-16.1)

Club Foot (PEDMS-16.2)

Vertical Talus (PEDMS-16.3)

Femoral Anteversion and Tibial Torsion (PEDMS-16.4)

References (PEDMS-16)

Tarsal Coalition (Calcaneonavicular Bar/Rigid Flat Foot) (PEDMS-16.1)

MPS.CD.0016.1.A

v1.0.2024

- Plain x-rays should be performed initially since the calcaneonavicular bar is readily visible in older children and adults.
 - Talocalcaneal coalition is more difficult to evaluate on plain x-rays.
- CT without contrast (CPT® 73700) or MRI without contrast (CPT® 73718) is indicated if tarsal coalition is suspected (because of restricted hindfoot motion on physical exam), and plain x-rays are inconclusive.

Club Foot (PEDMS-16.2)

MSP.CD.0016.2.A

v1.0.2024

Club Foot is a congenital foot contracture with foot in equinus (plantar flexion) and heel and forefoot in varus/adduction (turned in). Immediate diagnosis and specialty evaluation in the first week of life provide the best chance for successful correction.

- Plain x-rays should be performed initially since the anomaly is readily visible in older children and adults.
- Ultrasound (CPT® 76881 or 76882) can be used to characterize the cartilaginous tarsal bones and demonstrate tarsal bone alignment in infants with non-ossified tarsal bones.
- MRI is not currently used to image clubfoot, and limited experiences are published in the literature. MRI (CPT® 73718) or CT (CPT® 73700) can be approved to determine residual deficits following repair.
 - Ultrasound is not required prior to MRI or CT if those studies are appropriate.

Vertical Talus (PEDMS-16.3)

MSP.CD.0016.3.A

v1.0.2024

- Congenital vertical talus (also known as congenital rocker-bottom foot) is a fixed foot deformity characterized by irreducible talonavicular dislocation. The talus is plantar flexed and does not articulate with the navicular bone.
- Plain x-rays should be performed initially since the anomaly is readily visible in older children and adults.
- MRI (CPT® 73718) or CT (CPT® 73700) to determine residual deficits following repair.

Femoral Anteversion and Tibial Torsion (PEDMS-16.4)

MSP.CD.0016.4.A

v1.0.2024

- Femoral anteversion is a rotational deformity of the femur which may lead to an in-toeing gait.
- Tibial torsion is a rotational deformity of the tibia that may lead to in-toeing or out-toeing gait, and can be associated with the foot deformities already discussed in **Tarsal Coalition (Calcaneonavicular Bar/Rigid Flat Foot) (PEDMS-16.1)**, **Club Foot (PEDMS-16.2)**, and **Vertical Talus (PEDMS-16.3)**.
- Both deformities are typically diagnosed on clinical examination, but CT Lower Extremity without contrast (CPT® 73700) can be approved for preoperative evaluation⁹.

References (PEDMS-16)

v1.0.2024

1. Miron M-C, Grimard G. Ultrasound evaluation of foot deformities in infants. *Pediatr Radiol*. 2016;46:193-209. doi:10.1007/s00247-015-3460-3.
2. Griffin LY. *Essentials of Musculoskeletal Care*. 3rd edition. Rosemont, IL: American Academy of Orthopaedic Surgeons; 2005:728-730.
3. Wise JN, Weissman BN, Appel M, et al. *ACR Appropriateness Criteria*®. Chronic foot pain. Date of origin: 1998. Last review date: 2020. <https://acsearch.acr.org/docs/69424/Narrative>.
4. Winell JJ, Davidson RS. Tarsal Coalition. In: Kliegman RM, St. Geme JW III, Blum NJ, et. al., eds. *Nelson Textbook of Pediatrics*. 21st edition. Philadelphia, PA: Elsevier; 2020:3601-3602,
5. Denning JR. Tarsal coalition in children. *Pediatric annals*. 2016;45(4):e139-43.
6. Winell JJ, Davidson RS. Talipes equinovarus (clubfoot). In: Kliegman RM, St. Geme JW III, Blum NJ, et. al., eds. *Nelson Textbook of Pediatrics*. 21st edition. Philadelphia, PA: Elsevier; 2020:3598-3599.
7. Machida J, Inaba Y, Nakamura N. Management of foot deformity in children. *J Orthop Sci*. 2017;22(2):175-83. doi:10.1016/j.jos.2016.12.009.
8. Hammer MR, Kanaan Y, Strouse PJ. Alignment disorders. In: Coley B, ed. *Caffey's Pediatric Diagnostic Imaging*. 13th edition. Philadelphia, PA: Elsevier Saunders; 2019:1296-1308.
9. Waelti S, Fischer T, Griessinger J, et. al. Ultra-low-dose computed tomography for torsion measurements of the lower extremities in children and adolescents. *Insights Imaging*. 2022;13(1):118. doi:10.1186/s13244-022-01257-w.

Table of Contents

Guideline

- General Guidelines (PEDNECK-1)
- Neck Masses (Pediatric) (PEDNECK-2)
- Cervical Lymphadenopathy (PEDNECK-3)
- Dystonia/Torticollis (PEDNECK-4)
- Dysphagia (PEDNECK-5)
- Thyroid and Parathyroid (PEDNECK-6)
- Esophagus (PEDNECK-7)
- Trachea (PEDNECK-8)

General Guidelines (PEDNECK-1)

Guideline

Procedure Codes Associated with Neck Imaging

General Guidelines (PEDNECK-1.0)

Age Considerations (PEDNECK-1.1)

Modality General Considerations (PEDNECK-1.3)

References (PEDNECK-1)

Procedure Codes Associated with Neck Imaging

NKP.GG.ProcedureCodes.A
v1.0.2024

MRI	CPT®
MRI Orbit, Face, Neck without contrast	70540
MRI Orbit, Face, Neck with contrast (rarely used)	70542
MRI Orbit, Face, Neck without and with contrast	70543
MRI Temporomandibular Joint (TMJ)	70336
Unlisted MRI procedure (for radiation planning or surgical software)	76498

MRA	CPT®
MRA Neck without contrast	70547
MRA Neck with contrast	70548
MRA Neck without and with contrast	70549

CT	CPT®
CT Maxillofacial without contrast (includes sinuses, jaw, and mandible)	70486
CT Maxillofacial with contrast (includes sinuses, jaw, and mandible)	70487
CT Maxillofacial without and with contrast (includes sinuses, jaw, and mandible)	70488
CT Neck without contrast (includes jaw, and mandible)	70490
CT Neck with contrast (includes jaw, and mandible)	70491
CT Neck without and with contrast (includes jaw, and mandible)	70492
CT Guidance for Placement of Radiation Therapy Fields	77014
Unlisted CT procedure (for radiation planning or surgical software)	76497

CTA	CPT®
CTA Neck	70498

Nuclear Medicine	CPT®
PET Imaging; limited area (this code not used in pediatrics)	78811
PET Imaging: skull base to mid-thigh (this code not used in pediatrics)	78812
PET Imaging: whole body (this code not used in pediatrics)	78813

Nuclear Medicine	CPT®
PET with concurrently acquired CT; limited area (this code rarely used in pediatrics)	78814
PET with concurrently acquired CT; skull base to mid-thigh	78815
PET with concurrently acquired CT; whole body	78816
Thyroid Uptake, Single or Multiple Quantitative Measurement(s) (Including Stimulation, Suppression, or Discharge, When Performed)	78012
Thyroid Imaging (Including Vascular Flow, When Performed)	78013
Thyroid Imaging (Including Vascular Flow, When Performed); with Single or Multiple Uptake(s) Quantitative Measurement(s) (Including Stimulation, Suppression, or Discharge, When Performed)	78014
Thyroid Carcinoma Metastases Imaging Limited Area	78015
Thyroid Carcinoma Metastases Imaging with Additional Studies	78016
Thyroid Carcinoma Metastases Imaging Whole Body	78018
Thyroid Carcinoma Metastases Uptake (Add-on Code)	78020
Parathyroid Planar Imaging (Including Subtraction, When Performed)	78070
Parathyroid Planar Imaging (Including Subtraction, When Performed); with Tomographic (SPECT)	78071
Parathyroid Planar Imaging (Including Subtraction, When Performed); with Tomographic (SPECT), and Concurrently Acquired Computed Tomography (CT) for Anatomical Localization	78072
Salivary Gland Nuclear Imaging	78230
Salivary Gland Nuclear Imaging with Serial Imaging	78231
Salivary Gland Function Study	78232
Esophageal Motility Study	78258
Radiopharmaceutical Localization Imaging Limited area	78800
Radiopharmaceutical Localization Imaging Whole Body	78802
Radiopharmaceutical Localization Imaging SPECT	78803

Ultrasound	CPT®
Soft tissues of head and neck Ultrasound (thyroid, parathyroid, parotid, etc.)	76536
Duplex scan of extracranial arteries; complete bilateral study	93880
Duplex scan of extracranial arteries; unilateral or limited study	93882
Non-invasive physiologic studies of extracranial arteries, complete bilateral study	93875

Ultrasound	CPT [®]
Ultrasound guidance for needle placement	76942

General Guidelines (PEDNECK-1.0)

NKP.GG.0001.0.A

v1.0.2024

- A pertinent clinical evaluation including a detailed history, physical examination, since the onset or change in symptoms, and appropriate laboratory studies should be performed prior to considering advanced imaging (CT, MRI, Nuclear Medicine), unless the individual is undergoing guideline-supported scheduled follow-up imaging evaluation. A meaningful technological contact (telehealth visit, telephone call, electronic mail or messaging) since the onset or change in symptoms can serve as a pertinent clinical evaluation.
- Unless otherwise stated in a specific guideline section, the use of advanced imaging to screen asymptomatic individuals for disorders involving the neck is not supported. Advanced imaging of the neck is only supported in individuals who have documented active clinical signs or symptoms of disease involving the neck.
- Unless otherwise stated in a specific guideline section, repeat imaging studies of the neck are not necessary unless there is evidence for progression of disease, new onset of disease, and/or documentation of how repeat imaging will affect individual management or treatment decisions.

Age Considerations (PEDNECK-1.1)

NKP.GG.0001.1.A

v1.0.2024

- Many conditions affecting the neck in the pediatric population are different diagnoses than those occurring in the adult population. For those diseases which occur in both pediatric and adult populations, minor differences may exist in management due to individual age, comorbidities, and differences in disease natural history between children and adults.
- Individuals who are 18 years old or younger¹¹ should be imaged according to the Pediatric Neck Imaging Guidelines. Any conditions not specifically discussed in the Pediatric Neck Imaging Guidelines should be imaged according to the General Neck Imaging Guidelines. Individuals who are >18 years old should be imaged according to the General Neck Imaging Guidelines, except where directed otherwise by a specific guideline section.

Modality General Considerations (PEDNECK-1.3)

NKP.GG.0001.3.A
v1.0.2024

- MRI
 - MRI Orbit/Face/Neck is generally performed without and with contrast (CPT® 70543) unless the individual has a documented contraindication to gadolinium or otherwise stated in a specific guideline section.
 - Due to the length of time required for MRI acquisition and the need to minimize individual movement, sedation is usually required for almost all infants (except neonates) and young children (age <7 years) as well as older children with developmental delays. Sedation may be administered by oral, intravenous, and/or inhalational routes. In order to limit sedation time in this subdivision of pediatric individuals, the following should be considered:
 - MRI procedures can be performed without and/or with contrast use as supported by these condition-based guidelines. If intravenous access is indicated for sedation and there is no contraindication for using contrast, imaging without and with contrast may avoid repeating a study with sedation to perform an MRI with contrast if the initial study without contrast is inconclusive.
 - Recent evidence-based literature demonstrates the potential for gadolinium deposition in various organs including the brain, after the use of MRI contrast.
 - The U.S. Food and Drug Administration (FDA) has noted that there is currently no evidence to suggest that gadolinium retention in the brain is harmful and restricting gadolinium-based contrast agents (GBCAs) use is not warranted at this time. It has been recommended that GBCA use should be limited to circumstances in which additional information provided by the contrast agent is necessary and the necessity of repetitive MRIs with GBCAs should be assessed.
 - If studies of multiple body areas are supported by eviCore guidelines for the clinical condition being evaluated, MRI studies of all necessary body areas should be obtained concurrently in the same sedation session.
 - The presence of surgical hardware or implanted devices may preclude the use of MRI.
 - Coordination between provider and the imaging service can result in providing the best choice of radiologic studies for the pediatric individual.
- CT
 - CT Neck typically extends from the base of the skull to the upper thorax.
 - A separate CPT® code for head imaging in order to visualize the skull base is not necessary.

- In some cases, especially in follow-up of a known finding, it may be appropriate to limit the exam to the region of concern to reduce radiation exposure.
- CT Neck is generally performed with contrast (CPT® 70491) unless the individual has a documented contraindication to CT contrast or otherwise stated in a specific guideline section.
- CT Neck may be indicated for further evaluation of abnormalities suggested on prior US or MRI Procedures.
- In general, CT Neck is appropriate when evaluating trauma, malignancy, and for preoperative planning.
- CTA Neck (CPT® 70498) is indicated for evaluation of the vessels of the neck, especially with concern for dissection.
- CT should not be used to replace MRI in an attempt to avoid sedation unless listed as a recommended study in a specific guideline section.
- Coordination between the provider and the imaging service can result in the best choice of radiologic studies for the pediatric individual.
- Ultrasound
 - Ultrasound soft tissues of the neck (CPT® 76536) is indicated as an initial study for evaluating thyroid, parathyroid, parotid and other salivary gland lesions. Ultrasound is also used to further characterize adenopathy, palpable superficial masses, or swelling.
 - For those individuals who do require additional advanced imaging after ultrasound; ultrasound can be very beneficial in selecting the proper modality, body area, image sequences, and contrast level that will provide the most definitive information for the pediatric individual.
- Nuclear Medicine
 - Nuclear medicine studies of the neck in pediatric individuals are most commonly used to evaluate neck masses, or thyroid and parathyroid disease following initial studies with anatomic imaging, such as ultrasound, CT, or MRI. See **Neck Masses (Pediatric) (PEDNECK-2.1)** and **Thyroid and Parathyroid (PEDNECK-6)** for imaging guidelines.
 - Evaluation of salivary gland function in individuals with dry mouth (xerostomia) and **ONE** of the following:
 - Sjögren syndrome **OR**
 - Sialadenitis **OR**
 - History of head or neck radiation therapy, one of the following is supported:
 - Salivary Gland Nuclear Imaging (CPT® 78230) **OR**
 - Salivary Gland Nuclear Imaging with Serial Imaging (CPT® 78231) **OR**
 - Salivary Gland Function Study (CPT® 78232)
- 3D Rendering
 - 3D Rendering indications in pediatric neck imaging are identical to those in the general imaging guidelines. See **3D Rendering (Preface-4.1)** in the Preface Imaging Guidelines.

The guidelines listed in this section for certain specific indications are not intended to be all-inclusive; clinical judgment remains paramount and variance from these guidelines may be appropriate and warranted for specific clinical situations.

References (PEDNECK-1)

v1.0.2024

1. Siegel MJ. Neck sonography. In: *Pediatric Sonography*. 5th ed. Wolters Kluwer/Lippincott Williams & Wilkins; 2018:112-155.
2. Meier JD, and Grimmer JF. Evaluation and management of neck masses in children. *Am Fam Physician*. 2014; 89:353-358
3. Biassoni L, Easty M. Paediatric nuclear medicine imaging. *British Medical Bulletin*. 2017;123(1):127-148. doi:10.1093/bmb/ldx025
4. Bridges MD, Berland LL, Friedberg EB, et al. ACR Practice parameter for performing and interpreting magnetic resonance imaging (MRI). *American College of Radiology*. Revised 2017 (Resolution 10)
5. Karmazyn BK, John SD, Siegel MJ, et al. ACR-ASER-SCBT-MR-SPR Practice parameter for the performance of pediatric computed tomography (CT). American College of Radiology. Revised 2019 (Resolution 6)
6. Reighard C, Junaid S, Jackson WM, et al. Anesthetic Exposure During Childhood and Neurodevelopmental Outcomes: A Systematic Review and Meta-analysis. *JAMA Netw Open*. 2022;5(6):e2217427. Published 2022 Jun 1. doi:10.1001/jamanetworkopen.2022.17427
7. MacDonald A, Burrell S. Infrequently Performed Studies in Nuclear Medicine: Part 2. *Journal of Nuclear Medicine Technology*. 2009;37(1):1-13. doi:10.2967/jnmt.108.057851
8. Fraum TJ, Ludwig DR, Bashir MR, Fowler KJ. Gadolinium-based contrast agents: A comprehensive risk assessment. *Journal of Magnetic Resonance Imaging*. 2017;46(2):338-353. doi:10.1002/jmri.25625
9. Update on FDA approach to safety issue of gadolinium retention after administration of gadolinium-based contrast agents available at <https://www.fda.gov/media/116492/download>
10. Blumfield E, Swenson DW, Iyer RS, Stanescu AL. Gadolinium-based contrast agents — review of recent literature on magnetic resonance imaging signal intensity changes and tissue deposits, with emphasis on pediatric patients. *Pediatric Radiology*. 2019;49(4):448-457. doi:10.1007/s00247-018-4304-8
11. Implementation Guide: Medicaid State Plan Eligibility Eligibility Groups Mandatory Coverage Infants and Children under Age 19 Guidance Portal. <https://www.hhs.gov/guidance/document/implementation-guide-medicaid-state-plan-eligibility-eligibility-groups-aeu-mandatory-2>
12. Ho ML. Pediatric Neck Masses: Imaging Guidelines and Recommendations. *Radiol Clin North Am*. 2022;60(1):1-14. doi:10.1016/j.rcl.2021.08.001

Neck Masses (Pediatric) (PEDNECK-2)

Guideline

Neck Masses (Pediatric) (PEDNECK-2.1)

References (PEDNECK-2)

Neck Masses (Pediatric) (PEDNECK-2.1)

NKP.NM.0002.1.A

v1.0.2024

- Evaluation of neck masses in pediatric individuals involves careful consideration of clinical history and accurate physical examination. The individual's age and knowledge of the anatomy and common lesions of the neck are very important in narrowing the differential diagnosis.
- Initial imaging of choice:
 - Ultrasound Neck (CPT® 76536)
 - Color Doppler ultrasound bilateral study of carotid arteries (CPT® 93880) **OR** Duplex unilateral study (CPT® 93882) is supported to evaluate the vasculature.
- For inconclusive ultrasound or to further delineate abnormalities on ultrasound:
 - MRI Orbit/Face/Neck without contrast (CPT® 70540) **OR**
 - MRI Orbit/Face/Neck without and with contrast (CPT® 70543) **OR**
 - CT Neck with contrast (CPT® 70491)
- Lymphadenopathy persisting for more than 4-weeks of treatment **OR** suspicion of complications such as abscess formation:
 - Ultrasound Neck (CPT® 76536) is indicated. See **Cervical Lymphadenopathy (PEDNECK-3.1)**.
- Congenital cervical cysts:
 - Ultrasound Neck (CPT® 76536) is supported for suspected cystic neck mass.
- Congenital cervical sinus, fistula, or cyst for preoperative planning:
 - MRI Orbit/Face/Neck without and with contrast (CPT® 70543) **OR**
 - CT Neck with contrast (CPT® 70491)
 - For fourth branchial cleft cyst/sinus/fistula- barium swallow is supported in addition to the above conventional imaging.
- Salivary gland nuclear imaging: **ONE** of the following is indicated for evaluation of parotid masses to allow preoperative diagnosis of Warthin's tumor:
 - Salivary Gland Nuclear Imaging (CPT® 78230) **OR**
 - Salivary Gland Nuclear Imaging with Serial Imaging (CPT® 78231) **OR**
 - Salivary Gland Function Study (CPT® 78232)
- Ranula (a cystic structure on the floor of the mouth):
 - CT Neck with contrast (CPT® 70491) **OR**
 - MRI Orbit/Face/Neck without and with contrast (CPT® 70543) is supported, especially when there is concern for a "plunging" ranula (lesion extending into the submandibular space).¹¹

Background and Supporting Information

Cervical lymphadenitis is common in children and follows most viral or bacterial infections of the ears, nose, and throat. No advanced imaging is necessary with uncomplicated lymph node enlargement.

Congenital cervical cysts frequently present in children and include thyroglossal duct cyst (55% of cases), cystic hygroma (25%), branchial cleft cysts (16%), bronchogenic cyst (0.91%), and thymic cyst (0.3%).

The most common malignant ENT tumors in children are lymphoma and rhabdomyosarcoma.

Differential Diagnosis of Neck Lesions by Anatomic Region:

- Subcutaneous tissues:
 - Teratoma (includes dermoid cysts)
 - Cervical teratomas are typically large bulky masses discovered at birth or in the first year of life.
 - Large lesions may cause stridor, dyspnea, or dysphagia.
 - Most teratomas arise in the anterior suprahyoid neck and may be midline or off midline in location and adjacent to or within a thyroid lobe.
 - Vascular malformations
 - Lipoma
 - Cellulitis
 - Plexiform neurofibromas
 - Keloid
 - Scar
 - Pilomatrixoma
 - Subcutaneous fat fibrosis (in neonates)
- Retropharyngeal space:
 - Abscess, cellulitis, adenitis
 - Usually involves children under age 6.
 - Individuals have history of upper respiratory tract infection followed by high fever, dysphagia, and neck pain.
 - Lymphadenopathy
 - Extension of goiter
 - Extension of pharyngeal tumor
- Retrovisceral space (posterior to the cervical esophagus):
 - Gastrointestinal duplication cysts (usually are diagnosed in first year of life).
- Pretracheal space (contains trachea, larynx, cervical esophagus, recurrent laryngeal nerves, and thyroid and parathyroid glands):
 - Thyroglossal duct cyst

- Thyroglossal duct cyst most commonly presents before the age of 20; 75% present as a midline mass and 43% of individuals present with an infected mass.
- Usually presents as an enlarging, painless midline mass.
- Thyroid carcinoma occurs in 1% of thyroglossal duct cysts.
- Goiter
- Laryngocele
- Lymphadenopathy
- Teratoma
- Abscess
- Ectopic thymus or cervical extension of normal thymus
- Danger space (closed space lying between the skull base and the posterior mediastinum and between the alar and prevertebral fasciae in a sagittal plane):
 - Cellulitis
 - Abscess
- Prevertebral space:
 - Neurenteric cyst
 - Cellulitis
 - Abscess
 - Spondylodiskitis
 - Lymphadenopathy
 - Paraganglioma
- Carotid sheath space:
 - Jugular vein thrombosis or phlebitis
 - Lymphadenopathy
 - Cellulitis
 - Abscess
 - Paraganglioma
- Parotid gland space:
 - Parotid lymphadenopathy
 - Retromandibular vein thrombosis
 - Parotiditis
 - Sialodochitis (inflammation of the salivary gland duct)
 - Salivary duct stone
 - Abscess
- Submandibular and sublingual spaces:
 - Cellulitis
 - Abscess
 - Sialadenitis

- Thyroglossal duct cyst
- Branchial cleft cyst
 - 90% of branchial abnormalities arise from the second branchial apparatus.
 - Second branchial cleft cysts are the most common branchial cleft cyst and usually present in individuals between 10 and 40 years as painless fluctuant masses.
 - They typically present as slowly growing, non-tender masses in the upper neck
 - Most second branchial cleft cysts are located in the submandibular space, at the anteromedial border of the sternocleidomastoid muscle, lateral to the carotid space, or posterior to the submandibular gland.
 - Ranula – typically cystic masses in the floor of the mouth.
- Masticator space (includes masseter and pterygoid muscles):
 - Venous or lymphatic malformation
 - Cellulitis
 - Abscess
 - Rhabdomyosarcoma
- Parapharyngeal space:
 - Cellulitis
 - Abscess
 - Neurogenic tumors (CN V, IX, XI and XII)
 - Paragangliomas
 - Neurofibromas
 - Lymphoma
 - Rhabdomyosarcoma
- Paravertebral space:
 - Cervical dermal sinus (epithelium lined dural tubes that connect the skin with the central nervous system or its covering)
 - Meningocele
 - Rhabdomyosarcoma
 - Lymphoma
 - Neuroblastoma
 - Neurofibroma
- Posterior cervical space:
 - Lymphadenopathy
 - Lymphatic malformation

Congenital Neck Masses:^{2,13}

- Anterior neck masses
 - Branchial anomalies

- Sinus: with either an internal (to the pharynx) or external (to the skin) opening
- Fistula: with both an internal and external opening
- Cyst: closed sac with no openings
- First branchial anomalies
 - Typically sinus or cyst
 - Located anywhere from the external auditory canal to the region of the parotid gland, down to the level of the hyoid; may communicate with the preauricular soft tissue/parotid, parapharyngeal space or anterior triangle of the neck
 - Type I tract parallels the external auditory meatus
 - Type II tract courses over the angle of mandible through the parotid ending near/within the external auditory canal bony cartilaginous junction
- Second branchial anomalies
 - The most common
 - Located from anterior neck in the region of the middle to lower two thirds of the sternocleidomastoid and the great vessels to the pharyngeal mucosa (tonsil)- a tract and/or cyst may occur anywhere along this path
- Third branchial anomalies
 - Typically located from the low anterior neck to the base of the pyriform sinus
- Fourth branchial anomalies
 - Potential tract from the low anterior neck to the thyroid gland or mediastinum
- Cervical thymus
 - Ectopic thymic remnants can be found in the anterior neck (left more commonly than right) and extend deep (near the carotid sheath)- can connect to mediastinum or have cystic components
- Midline
 - Ectopic Thyroid/Thyroglossal Duct Cysts
 - Anywhere from the tongue base to the mediastinum (a result of the normal embryologic pathway of the thyroid that fails to obliterate or reach its normal location in the lower neck)
- Just off the midline
 - Laryngocele
 - An an abnormal dilation of the saccule of the larynx
 - Internal: within the thyroid cartilage
 - External: beyond the thyrohyoid membrane into the neck
- Anywhere within the neck
 - Teratomas
 - Tissue form all three germ cell layers (ectodermal, mesodermal and endodermal components) typically present as a firm mass, can have calcifications seen on imaging

- Dermoid cysts
 - Cysts with ectodermal and mesodermal structures (Commonly lined by epidermis and containing epidermal appendages) typically in the midline/submental region, but can be anywhere in the head and neck including orbit
- Epidermoid cysts
 - Cysts with only ectodermal components (with squamous material)
- Pilomatixoma
 - Lesion derived from hair matrix/follicles
- Vascular anomalies
 - Hemangiomas (most common)
 - Congenital: present at birth typically involute
 - Infantile: noted to have a rapid/proliferative phase followed by involution
 - High flow
 - Arteriovenous malformations (AVM) and arteriovenous fistulas (AVF) tangle of vessels
 - Low flow
 - Venous lymphatic and capillary malformations
- Lymphatic malformations (lymphangiomas)
 - Result from a failure of lymph spaces to connect to the rest of the lymphatic system
 - Macrocytic: comprised of large cysts
 - Microcystic: comprised of smaller cysts typically more infiltrative, leading to difficult excision

References (PEDNECK-2)

v1.0.2024

1. Siegel MJ. Neck sonography. In: *Pediatric Sonography*. 5th ed. Wolters Kluwer/Lippincott Williams & Wilkins; 2018:112-155
2. Geddes G, Butterly MM, Patel SM, Marra S. Pediatric Neck Masses. *Pediatrics in Review*. 2013;34(3):115-125. doi:10.1542/pir.34-3-115
3. Ludwig BJ, Wang J, Nadgir RN, Saito N, Castro-Aragon I, Sakai O. Imaging of Cervical Lymphadenopathy in Children and Young Adults. *American Journal of Roentgenology*. 2012;199(5):1105-1113. doi:10.2214/ajr.12.8629
4. Rizzi MD, Wetmore RF, Potsic WP. Differential diagnosis of neck masses. In: Lesperance MM, Flint PW, eds. *Cummings Pediatric Otolaryngology*, Philadelphia: Saunders Company, 2015:245-254
5. Bansal AG, Oudsema R, Masseaux JA, Rosenberg HK. US of Pediatric Superficial Masses of the Head and Neck. *RadioGraphics*. 2018;38(4):1239-1263. doi:10.1148/rg.2018170165
6. Kelly TG, Faulkes SV, Pierre SK, et al. Imaging submandibular pathology in the paediatric patient. *Clinical Radiology*. 2015;70(7):774-786. doi:10.1016/j.crad.2015.03.003
7. Collins B, Stoner JA, Digoy GP. Benefits of ultrasound vs. computed tomography in the diagnosis of pediatric lateral neck abscesses. *International Journal of Pediatric Otorhinolaryngology*. 2014;78(3):423-426. doi:10.1016/j.ijporl.2013.11.034
8. MacDonald A, Burrell S. Infrequently Performed Studies in Nuclear Medicine: Part 2. *Journal of Nuclear Medicine Technology*. 2009;37(1):1-13. doi:10.2967/jnmt.108.057851
9. Stern JS, Ginat DT, Nicholas JL, Ryan ME. Imaging of Pediatric Head and Neck Masses. *Otolaryngologic Clinics of North America*. 2015;48(1):225-246. doi:10.1016/j.otc.2014.09.015
10. Expert Panel on Neurologic Imaging:, Aulino JM, Kirsch CFE, et al. ACR Appropriateness Criteria® Neck Mass-Adenopathy. *J Am Coll Radiol*. 2019;16(5S):S150-S160. doi:10.1016/j.jacr.2019.02.025
11. Brown RE, Harave S. Diagnostic imaging of benign and malignant neck masses in children—a pictorial review. *Quantitative Imaging in Medicine and Surgery*. 2016;6(5):591-604. doi:10.21037/qims.2016.10.10
12. Riva G, Sensini M, Peradotto F, Scolfaro C, Rosa GD, Tavormina P. Pediatric neck masses: how clinical and radiological features can drive diagnosis. *European Journal of Pediatrics*. 2019;178(4):463-471. doi:10.1007/s00431-018-3305-9
13. Ho ML. Pediatric Neck Masses: Imaging Guidelines and Recommendations. *Radiol Clin North Am*. 2022;60(1):1-14. doi:10.1016/j.rcl.2021.08.001

Cervical Lymphadenopathy (PEDNECK-3)

Guideline

Imaging (PEDNECK-3.1)

References (PEDNECK-3)

Imaging (PEDNECK-3.1)

NKP.CL.0003.1.A

v1.0.2024

- Painful acute lymphadenopathy and other painful neck masses (including neck “swelling”) should be treated with a trial of conservative therapy for at least 4-weeks, including antibiotics if appropriate.
 - If there is improvement with conservative treatment, advanced imaging is not indicated.
 - Ultrasound (CPT® 76536) is indicated for any of the following:
 - Initial evaluation of persistent lymphadenopathy following 4-weeks of treatment/observation **OR**
 - Unexplained fever (temperature $\geq 100.4^{\circ}\text{F}$) and there is clinical concern for suppurative lymphadenopathy/neck abscess
- For inconclusive ultrasound/to further characterize abnormalities found on ultrasound:
 - MRI Orbit/Face/Neck without contrast (CPT® 70540) **OR**
 - MRI Orbit/Face/Neck without and with contrast (CPT® 70543) **OR**
 - CT Neck with contrast (CPT® 70491)
- If systemic symptoms or other clinical findings suggest malignancy, see **Pediatric Lymphomas (PEDONC-5)** in the Pediatric Oncology Imaging Guidelines.

Background and Supporting Information

Both MRI and CT are superior to ultrasound for defining the relationship of an abscess to adjacent structures, particularly the airway; and detecting posterior cervical, mediastinal and intracranial extension.

Inflammatory lymph nodes from acute lymphadenitis are usually painful, tender and mobile, frequently associated with upper respiratory infection, pharyngitis or dental infection.

Occasionally, sarcoidosis or toxoplasmosis and Human immunodeficiency virus (HIV) can cause inflammatory lymphadenopathy as well.

References (PEDNECK-3)

v1.0.2024

1. Ludwig BJ, Wang J, Nadgir RN, et al. Imaging of cervical lymphadenopathy in children and young adults. *Am J Roentgenol*. 2012 Nov; 199 (5):1105-1113
2. Nolder AR. Paediatric cervical lymphadenopathy. *Current Opinion in Otolaryngology & Head and Neck Surgery*. Published online December 2013:567-570. doi:10.1097/moo.0000000000000003
3. Chadha M, Yang Z, Ellika S. Imaging in Nontraumatic Pediatric Head and Neck Emergencies. *Journal of Pediatric Neurology*. 2017;15(05):263-293. doi:10.1055/s-0037-1604238
4. Rosenberg TL, Nolder AR. Pediatric Cervical Lymphadenopathy. *Otolaryngologic Clinics of North America*. 2014;47(5):721-731. doi:10.1016/j.otc.2014.06.012
5. Weinstock MS, Patel NA, Smith LP. Pediatric Cervical Lymphadenopathy. *Pediatrics in Review*. 2018;39(9):433-443. doi:10.1542/pir.2017-0249
6. Expert Panel on Neurologic Imaging; Aulino JM, Kirsch CFE, et al. ACR Appropriateness Criteria® Neck Mass-Adenopathy. *J Am Coll Radiol*. 2019;16(5S):S150-S160. doi:10.1016/j.jacr.2019.02.025
7. Ho ML. Pediatric Neck Masses: Imaging Guidelines and Recommendations. *Radiol Clin North Am*. 2022;60(1):1-14. doi:10.1016/j.rcl.2021.08.001

Dystonia/Torticollis (PEDNECK-4)

Guideline

Dystonia/Torticollis (PEDNECK-4.1)

References (PEDNECK-4)

Dystonia/Torticollis (PEDNECK-4.1)

NKP.TO.0004.1.A

v1.0.2024

Infants under 12 Months of Age (Congenital Muscular Torticollis/Fibromatosis Colli)

- Ultrasound Neck (CPT® 76536) is indicated as the initial study.
 - If Ultrasound is Positive→ No further imaging is needed since diagnosis is defined.
 - If Ultrasound is Negative or to further evaluate for other structural causes:
 - CT Neck with contrast (CPT® 70491) **OR**
 - MRI Orbit/Face/Neck without contrast (CPT® 70540) **OR**
 - MRI Orbit/Face/Neck without and with contrast (CPT® 70543)

Background and Supporting Information

- Individuals usually present by 2-weeks of life with an anterior neck mass, which is commonly right sided (75% of cases). A history of a traumatic breech or forceps delivery is common.

Children and Adults (Acquired Torticollis)

- Initial evaluation with recent trauma, and low suspicion of injury:
 - Plain radiographs of the cervical spine
 - To identify fracture or malalignment if plain radiographs are inconclusive or in individuals with a high-risk mechanism of cervical spine injury within the last 3 months (see below**):
 - CT Neck with contrast (CPT® 70491) **AND/OR**
 - CT Cervical Spine without contrast (CPT® 72125) is supported
- In the clinical setting of cervical spine trauma with an associated neurologic deficit:
 - MRI Cervical Spine without contrast (CPT® 72141) is supported
- In the absence of trauma, to identify underlying abscess, bony, muscular, vascular, or neurologic causes, ONE of the following is supported:
 - CT Neck with contrast (CPT® 70491), **OR**
 - CT Cervical Spine without contrast (CPT® 72125), **OR**
 - MRI Cervical Spine without contrast (CPT® 72141), **OR**
 - MRI Orbit/Face/Neck without and with contrast (CPT® 70543), **OR**
 - MRA Neck without and with contrast (CPT® 70549)
 - Positive→ Further advanced imaging is not required if a local cause has been identified
 - Negative→ MRI Brain without and with contrast (CPT® 70553) is supported to exclude CNS cause

****High-risk mechanisms of cervical spine injury may include:**

- Head trauma and/or maxillofacial trauma
- Pedestrian in a motor vehicle accident
- Fall from above standing height
- Diving accident
- Head-on motor vehicle collision without/with airbag deployment
- Rollover motor vehicle collision
- Ejection from the vehicle in a motor vehicle collision
- High speed of the vehicle at the time of collision
- Not wearing a seatbelt/shoulder harness in a motor vehicle collision
- Individuals with ankylosing spondylitis are at high-risk of cervical spine fractures even with minor direct/indirect trauma to the cervical spine which can result in quadriparesis/quadriplegia

Background and Supporting Information

- Injury or inflammation involving the sternocleidomastoid or trapezius muscles is the most common cause of acquired torticollis in children.
- Torticollis or cervical dystonia is an abnormal twisting of the neck in which the head is rotated or twisted. Acute causes are most common. Children with deep space neck infections present with torticollis approximately 50% of the time.⁵ Other causes are variable and may be congenital, acquired (caused by trauma, juvenile idiopathic arthritis, or neoplasm), or idiopathic.

References (PEDNECK-4)

v1.0.2024

1. Dudkiewicz I, Ganel A, Blankstein A. Congenital Muscular Torticollis in Infants: Ultrasound-Assisted Diagnosis and Evaluation. *Journal of Pediatric Orthopaedics*. 2005;25(6):812-814. doi:10.1097/01.bpo.0000184648.81109.75
2. Suhr MC, Oledzka M. Considerations and intervention in congenital muscular torticollis. *Current opinion in pediatrics*. 2015;27(1):75-81. doi:10.1097/MOP.0000000000000175
3. Haque S, Bilal Shafi BB, Kaleem M. Imaging of Torticollis in Children. *RadioGraphics*. 2012;32(2):557-571. doi:10.1148/rg.322105143
4. Expert Panel on Pediatric Imaging:, Kadom N, Palasis S, et al. ACR Appropriateness Criteria® Suspected Spine Trauma-Child. *J Am Coll Radiol*. 2019;16(5S):S286-S299. doi:10.1016/j.jacr.2019.02.003
5. Demongeot N, Akkari M, Blanchet C, et al. Pediatric deep neck infections: Clinical description and analysis of therapeutic management. *Arch Pediatr*. 2022;29(2):128-132. doi:10.1016/j.arcped.2021.11.011

Dysphagia (PEDNECK-5)

Guideline

Dysphagia (PEDNECK-5.1)

References (PEDNECK-5)

Dysphagia (PEDNECK-5.1)

NKP.DY.0005.1.A

v1.0.2024

- Dysphagia imaging indications in pediatric individuals are very similar to those for adult individuals. See **Dysphagia and Esophageal Disorders (Neck-3.1)** in the Neck Imaging Guidelines.
- Concern for foreign body ingestion as the etiology of dysphagia initial imaging:
 - X-rays of the neck and chest are supported⁶
- Dysphagia associated with chest pain and difficulty swallowing both solids and liquids or Gastroesophageal reflux:
 - Esophageal motility study (CPT[®] 78258) is indicated
- For a suspected anatomical variant such as a vascular ring, right sided aortic arch, or double arch noted on chest radiography (which can be associated with dysphagia):
 - CTA Chest (CPT[®] 71275) **OR**
 - MRA Chest (CPT[®] 71555) is supported

References (PEDNECK-5)

v1.0.2024

1. Kakodkar K, Schroeder JW. Pediatric Dysphagia. *Pediatric Clinics of North America*. 2013;60(4):969-977. doi:10.1016/j.pcl.2013.04.010
2. Stagnaro N, Rizzo F, Torre M, Cittadini G, Magnano G. Multimodality imaging of pediatric airways disease: indication and technique. *La radiologia medica*. 2017;122(6):419-429. doi:10.1007/s11547-017-0737-7
3. Dodrill P, Gosa MM. Pediatric Dysphagia: Physiology, Assessment, and Management. *Annals of Nutrition and Metabolism*. 2015;66(5):24-31. doi:10.1159/000381372
4. Sommburg O, Helling-Bakki A, Alrajab A, et al. Assessment of Suspected Vascular Rings and Slings and/or Airway Pathologies Using Magnetic Resonance Imaging Rather Than Computed Tomography. *Respiration*. 2018;97(2):108-118. doi:10.1159/000492080.
5. Lawlor CM, Choi S. Diagnosis and Management of Pediatric Dysphagia: A Review. *JAMA Otolaryngol Head Neck Surg*. 2020;146(2):183-191. doi:10.1001/jamaoto.2019.3622
6. Leinwand K, Brumbaugh DE, Kramer RE. Button Battery Ingestion in Children: A Paradigm for Management of Severe Pediatric Foreign Body Ingestions. *Gastrointest Endosc Clin N Am*. 2016;26(1):99-118. doi:10.1016/j.giec.2015.08.003

Thyroid and Parathyroid (PEDNECK-6)

Guideline

Thyroid Masses or Nodules (PEDNECK-6.1)

Hyperthyroidism (PEDNECK-6.2)

Hypothyroidism (PEDNECK-6.3)

Parathyroid Imaging (PEDNECK-6.4)

References (PEDNECK-6)

Thyroid Masses or Nodules (PEDNECK-6.1)

NKP.PT.0006.1.A

v1.0.2024

- Initial study for evaluation of thyroid masses, diffuse thyroid enlargement, or nodules in pediatric individuals:
 - Ultrasound Neck (CPT® 76536) is indicated
- **For a normal or elevated TSH** with any solitary or suspicious thyroid nodule noted on imaging or physical exam:
 - Fine needle aspiration (FNA) under ultrasound guidance (CPT® 76942) is indicated
- **For a low TSH:**
 - Nuclear thyroid scintigraphy (either CPT® 78013 or CPT® 78014) is indicated
 - Hyperfunctioning nodules should be treated surgically but may also undergo FNA under ultrasound guidance (CPT® 76942) if suspicious in appearance and not being treated surgically.
 - Hypofunctioning nodules should undergo FNA under ultrasound guidance (CPT® 76942).
- For lymph node assessment if cervical lymph node imaging was not performed at the time of the initial diagnostic thyroid ultrasound:
 - Repeat imaging with Ultrasound Neck (CPT® 76536) is supported.
- For preoperative planning in individuals with large or fixed masses, vocal cord paralysis, or bulky cervical or supraclavicular adenopathy:
 - CT Neck without contrast (CPT® 70490) **OR**
 - CT Neck with contrast (CPT® 70491) **OR**
 - MRI Orbit/Face/Neck without contrast (CPT® 70540) **OR**
 - MRI Orbit/Face/Neck without and with contrast (CPT® 70543) is supported
 - In addition, individuals with substernal extension of the thyroid, pulmonary symptoms or abnormalities on recent chest x-ray:²¹
 - CT Chest without contrast (CPT® 71250) **OR**
 - CT Chest with contrast (CPT® 71260) is supported
- If any biopsy reveals thyroid carcinoma, See **Thyroid Cancer (ONC-6)** in the Oncology Imaging Guidelines.
- Repeat ultrasound (CPT® 76536) and/or FNA under ultrasound guidance (CPT® 76942) is indicated 3-6 months following initial biopsy if the initial biopsy shows inadequate, or non-diagnostic findings.
 - Repeat ultrasound (CPT® 76536) is indicated in 6-12 months if the nodule is stable and/or FNA is benign.
 - The nodule should be treated surgically if growing or the FNA is not benign.

- Repeat ultrasound (CPT® 76536) is indicated 6-12 months following initial biopsy if the initial biopsy shows benign findings.
 - Repeat ultrasound (CPT® 76536) is indicated every 1-2 years if the nodule is stable.
 - Repeat FNA under ultrasound guidance (CPT® 76942) or be treated surgically if the nodule is growing or concerning new findings are present.
 - Benign nodules that have been surgically resected do not require routine imaging follow up in the absence of clinical or laboratory changes suggesting recurrence.
- If the initial biopsy shows indeterminate or suspicious findings, surgery is recommended.

Hyperthyroidism (PEDNECK-6.2)

NKP.PT.0006.2.A

v1.0.2024

- Initial study for evaluation of hyperthyroidism:
 - Ultrasound Neck (CPT® 76536) is supported
 - If a nodule or mass is discovered on ultrasound, the individual should be imaged according to **Thyroid Masses or Nodules (PEDNECK-6.1)**
- For all other individuals with documented hyperthyroidism:
 - Thyroid uptake nuclear imaging (either CPT® 78012 or CPT® 78014) is supported

Background and Supporting Information

- Common causes are Graves' disease and autoimmune disorders (lupus, rheumatoid arthritis, and Sjögren syndrome).

Hypothyroidism (PEDNECK-6.3)

NKP.PT.0006.3.A

v1.0.2024

- Initial study for evaluation of hypothyroidism:
 - Ultrasound Neck (CPT® 76536) is supported
 - If a nodule or mass is discovered on ultrasound, the individual should be imaged according to **Thyroid Masses or Nodules (PEDNECK-6.1)**
- For individuals with documented congenital hypothyroidism, thyroid uptake nuclear imaging (either CPT® 78012 or CPT® 78014) is indicated.

Background and Supporting Information

- Causes of pediatric hypothyroidism include thyroid congenital dysgenesis, dyshormonogenesis autoimmune thyroiditis, Hashimoto thyroiditis, subacute thyroiditis, and abnormality in the pituitary gland or hypothalamus. Congenital hypothyroidism is usually diagnosed in the neonate on a routine perinatal screening examination.

Parathyroid Imaging (PEDNECK-6.4)

NKP.PT.0006.4.A

v1.0.2024

- Parathyroid imaging indications in pediatric individuals are the same as those for adult individuals. See **Parathyroid Imaging (Neck-8.3)** in the Neck Imaging Guidelines

References (PEDNECK-6)

v1.0.2024

1. Waguespack SG, Huh WW, and Bauer AJ. Endocrine tumors. In: Pizzo PA, Poplack DG, eds. *Principles and Practices of Pediatric Oncology*. 7th ed. Wolters Kluwer. Philadelphia, PA. 2016:919-945
2. Wassner AJ, Smith JR. Hypothyroidism. In: Kliegman RM, St. Geme JW III, Blum NJ, Shah SS, Tasker RC, Wilson KM, eds. *Nelson Textbook of Pediatrics*, 21st ed. 2020:2914-2922
3. Smith JR, Wassner AJ. Thyroid nodule. In: Kliegman RM, St. Geme JW III, Blum NJ, Shah SS, Tasker RC, Wilson KM, eds. *Nelson Textbook of Pediatrics*, 21st ed. 2020:2936-2937
4. Wassner AJ, Smith JR. Thyroiditis. In: Kliegman RM, St. Geme JW III, Blum NJ, Shah SS, Tasker RC, Wilson KM, eds. *Nelson Textbook of Pediatrics*, 21st ed. 2020:2923-2925
5. Smith JR, Wassner AJ. Thyrotoxicosis. In: Kliegman RM, St. Geme JW III, Blum NJ, Shah SS, Tasker RC, Wilson KM, eds. *Nelson Textbook of Pediatrics*, 21st ed. 2020:2928-2934
6. Doyle DA. Hypoparathyroidism. In: Kliegman RM, St. Geme JW III, Blum NJ, Shah SS, Tasker RC, Wilson KM, eds. *Nelson Textbook of Pediatrics*, 21st ed. 2020:2945-2948
7. Doyle DA. Hyperparathyroidism. In: Kliegman RM, St. Geme JW III, Blum NJ, Shah SS, Tasker RC, Wilson KM, eds. *Nelson Textbook of Pediatrics*, 21st ed. 2020:2950-2953
8. Francis GL, Waguespack SG, Bauer AJ, et al. Management Guidelines for Children with Thyroid Nodules and Differentiated Thyroid Cancer. *Thyroid*. 2015;25(7):716-759. doi:10.1089/thy.2014.0460
9. Essenmacher AC, Joyce PH, Kao SC, et al. Sonographic Evaluation of Pediatric Thyroid Nodules. *RadioGraphics*. 2017;37(6):1731-1752. doi:10.1148/rg.2017170059
10. Williams JL, Paul DL, Bisset G. Thyroid disease in children: part 1. *Pediatric Radiology*. 2013;43(10):1244-1253. doi:10.1007/s00247-013-2735-9
11. Williams JL, Paul D, Bisset G. Thyroid disease in children: part 2. *Pediatric Radiology*. 2013;43(10):1254-1264. doi:10.1007/s00247-013-2707-0
12. Papendieck P, Gruñeiro-Papendieck L, Venara M, et al. Differentiated Thyroid Cancer in Children: Prevalence and Predictors in a Large Cohort with Thyroid Nodules Followed Prospectively. *The Journal of Pediatrics*. 2015;167(1):199-201. doi:10.1016/j.jpeds.2015.04.041
13. Ross DS, Burch HB, Cooper DS, et al. 2016 American Thyroid Association Guidelines for Diagnosis and Management of Hyperthyroidism and Other Causes of Thyrotoxicosis. *Thyroid*. 2016;26(10):1343-1421. doi:10.1089/thy.2016.0229
14. Donangelo I, and Braunstein GD. Update on subclinical hyperthyroidism. *Am Fam Physician*. 2011; 83(8):933-938.
15. Gharib H, Papini E, Garber JR, et al. American Association Of Clinical Endocrinologists, American College Of Endocrinology, And Associazione Medici Endocrinologi medical guidelines for clinical practice for the diagnosis and management of thyroid nodules-2016 update. *Endocrine Practice*. 2016;22(Supplement 1):1-60. doi:10.4158/ep161208.gl
16. Bilezikian JP, Brandi ML, Eastell R, et al. Guidelines for the Management of Asymptomatic Primary Hyperparathyroidism: Summary Statement from the Fourth International Workshop. *The Journal of Clinical Endocrinology & Metabolism*. 2014;99(10):3561-3569. doi:10.1210/jc.2014-1413
17. Greenspan BS, Dillehay G, Intenzo C, et al. SNM Practice Guideline for Parathyroid Scintigraphy 4.0. *Journal of Nuclear Medicine Technology*. 2012;40(2):111-118. doi:10.2967/jnmt.112.105122
18. Sung, Jin Yong. "Parathyroid Ultrasonography: The Evolving Role of the Radiologist." *Ultrasonography* 34, no. 4 (2015): 268-74. doi:10.14366/usg.14071
19. ACR–SPR PRACTICE PARAMETER FOR THE PERFORMANCE OF PARATHYROID SCINTIGRAPHY—White paper, revised 2019. <https://www.acr.org/-/media/ACR/Files/Practice-Parameters/parathyroidscint.pdf>
20. ACR Appropriateness Criteria Parathyroid Adenoma, published April 2021. <https://acsearch.acr.org/docs/3158171/Narrative/>
21. Hanson MA, Shaha AR, Wu JX. Surgical approach to the substernal goiter. *Best Pract Res Clin Endocrinol Metab*. 2019;33(4):101312. doi:10.1016/j.beem.2019.101312

Esophagus (PEDNECK-7)

Guideline

Esophagus (PEDNECK-7.1)

References (PEDNECK-7)

Esophagus (PEDNECK-7.1)

NKP.ES.0007.1.A

v1.0.2024

- Esophagus imaging indications in pediatric individuals are very similar to those for adult individuals. See **Dysphagia and Esophageal Disorders (Neck-3.1)** in the Neck Imaging Guidelines.
- Pediatric-specific imaging considerations include the following:
 - Suspected foreign body ingestion or impaction:
 - Plain x-rays initial imaging⁵
 - Ultrasound Neck (CPT[®] 76536) can be approved for evaluation of upper esophageal foreign bodies.
 - See **Dysphagia and Esophageal Disorders (Neck-3.1)**
 - For evaluating congenital atresia with associated tracheoesophageal fistula:
 - Esophagram is supported
 - For evaluation of suspected congenital malformations with inconclusive x-rays or esophagram:
 - CT Neck with contrast (CPT[®] 70491) **AND/OR**
 - CT Chest with contrast (CPT[®] 71260)
 - 3D rendering (CPT[®] 76376 or CPT[®] 76377) is supported for preoperative planning in complex cases.
 - Plain radiographs alone usually suffice for the diagnosis of other types of esophageal atresia and a contrast examination of the esophagus is not warranted but may be indicated for post-operative evaluation.

References (PEDNECK-7)

v1.0.2024

1. Hryhorczuk AL, Lee EY, Eisenberg RL. Esophageal Abnormalities in Pediatric Patients. *American Journal of Roentgenology*. 2013;201(4):W519-W532. doi:10.2214/ajr.12.9291
2. Seekins JM, et al. Esophagus congenital and neonatal abnormalities. In: Coley B, Saunders E, eds. *Caffey's Pediatric Diagnostic Imaging*. Philadelphia, PA. 2013:12
3. Ellis WE. Esophagus: Congenital and Neonatal Abnormalities. In: Coley B, ed. *Caffey's Pediatric Diagnostic Imaging*, 13th Edition. Philadelphia, PA. 2018:901-910
4. Mori T, Nomura O, Hagiwara Y. Another Useful Application of Point-of-Care Ultrasound. *Pediatric Emergency Care*. 2019;35(2):154-156. doi:10.1097/pec.0000000000001729
5. Leinwand K, Brumbaugh DE, Kramer RE. Button Battery Ingestion in Children: A Paradigm for Management of Severe Pediatric Foreign Body Ingestions. *Gastrointest Endosc Clin N Am*. 2016;26(1):99-118. doi:10.1016/j.giec.2015.08.003

Trachea (PEDNECK-8)

Guideline

Trachea (PEDNECK-8.1)

References (PEDNECK-8)

Trachea (PEDNECK-8.1)

NKP.TR.0008.1.A

v1.0.2024

- Trachea imaging indications in pediatric individuals are similar to those for adult individuals. See **Trachea and Bronchus (Neck-9.1)** in the Neck Imaging Guidelines.
- Pediatric-specific imaging considerations include the following:
 - For evaluation of suspected congenital malformations if x-rays are inconclusive:
 - CT Neck with contrast (CPT® 70491) **AND/OR**
 - CT Chest with contrast (CPT® 71260) are supported
 - 3D rendering (CPT® 76376 or CPT® 76377) is supported for preoperative planning in complex cases.
 - CT is not routinely performed to evaluate foreign body aspiration, but it may be considered in complicated cases.

References (PEDNECK-8)

v1.0.2024

1. Pugmire BS, Lim R, Avery LL. Review of Ingested and Aspirated Foreign Bodies in Children and Their Clinical Significance for Radiologists. *RadioGraphics*. 2015;35(5):1528-1538. doi:10.1148/rg.2015140287
2. Lee EY, Restrepo R, Dillman JR, Ridge CA, Hammer MR, Boiselle PM. Imaging Evaluation of Pediatric Trachea and Bronchi: Systematic Review and Updates. *Seminars in Roentgenology*. 2012;47(2):182-196. doi:10.1053/j.ro.2011.12.002
3. Lee EY. Lower large airway disease. In: Coley B, ed. *Caffey's Pediatric Diagnostic Imaging*. Philadelphia, PA. 2018;486-494.
4. Semple T, Calder A, Owens CM, Padley S. Current and future approaches to large airways imaging in adults and children. *Clinical Radiology*. 2017;72(5):356-374. doi:10.1016/j.crad.2017.01.012
5. Stagnaro N, Rizzo F, Torre M, Cittadini G, Magnano G. Multimodality imaging of pediatric airways disease: indication and technique. *La radiologia medica*. 2017;122(6):419-429. doi:10.1007/s11547-017-0737-7

Table of Contents

Guideline

- General Guidelines (PEDONC-1)
- Screening Imaging in Cancer Predisposition Syndromes (PEDONC-2)
- Pediatric Leukemias (PEDONC-3)
- CNS Tumors (PEDONC-4)
- Pediatric Lymphomas (PEDONC-5)
- Neuroblastoma (PEDONC-6)
- Pediatric Renal Tumors (PEDONC-7)
- Pediatric Soft Tissue Sarcomas (PEDONC-8)
- Bone Tumors (PEDONC-9)
- Pediatric Germ Cell Tumors (PEDONC-10)
- Pediatric Liver and Pancreatic Tumors (PEDONC-11)
- Retinoblastoma (PEDONC-12)
- Pediatric Nasopharyngeal Carcinoma (PEDONC-13)
- Pediatric Adrenocortical Carcinoma (PEDONC-14)
- Pediatric Melanoma and Other Skin Cancers (PEDONC-15)
- Pediatric Salivary Gland Tumors and Thyroid Tumors (PEDONC-16)
- Pediatric Breast Masses (PEDONC-17)
- Histiocytic Disorders (PEDONC-18)
- Long Term Pediatric Cancer Survivors (PEDONC-19)
- Hematopoietic Stem Cell Transplantation (HSCT) (PEDONC-20)

General Guidelines (PEDONC-1)

Guideline

Abbreviations for Pediatric and Special Populations Oncology Imaging Guidelines

General Guidelines (PEDONC-1.0)

Age Considerations (PEDONC-1.1)

Appropriate Clinical Evaluations (PEDONC-1.2)

Modality General Considerations (PEDONC-1.3)

PET Imaging in Pediatric Oncology (PEDONC-1.4)

Diagnostic Radiation Exposure in Pediatric Oncology (PEDONC-1.5)

References (PEDONC-1)

Abbreviations for Pediatric and Special Populations Oncology Imaging Guidelines

ONCP.GG.Abbreviations.A
v2.0.2024

Abbreviations for Pediatric and Special Populations Oncology Imaging Guidelines	
AFP	Alpha-fetoprotein (tumor marker)
ALCL	Anaplastic large cell lymphoma
ALL	Acute lymphoblastic leukemia
AML	Acute myelogenous leukemia
β-hCG	Human chorionic gonadotropin beta-subunit (tumor marker)
BKL	Burkitt's lymphoma
BWT	Bilateral Wilms tumor
CCSK	Clear cell sarcoma of the kidney
CNS	Central nervous system
COG	Children's Oncology group
CPT®	Current procedural terminology; trademark of the American Medical Association
CSF	Cerebrospinal fluid
CT	Computed tomography
CXR	Chest x-ray
DAWT	Diffuse anaplasia Wilms tumor
ESFT	Ewing sarcoma family of tumors
FAWT	Focal anaplasia Wilms tumor
FHWT	Favorable histology Wilms tumor
HL	Hodgkin lymphoma
HSCT	Hematopoietic stem cell transplant (bone marrow or peripheral blood)
HVA	Homovanillic acid
LL	Lymphoblastic lymphoma

Pediatric and Special Populations Oncology

Abbreviations for Pediatric and Special Populations Oncology Imaging Guidelines

MIBG	Metaiodobenzylguanidine (nuclear scan using ¹²³ I or ¹³¹ I)
MPNST	Malignant peripheral nerve sheath tumor
MRI	Magnetic resonance imaging
NBL	Neuroblastoma
NED	No evidence of disease
NHL	Non-hodgkin lymphoma
NPC	Nasopharyngeal carcinoma
NRSTS	Nonrhabdomyosarcomatous soft tissue sarcomas
OS	Osteosarcoma
PET	Positron emission tomography
PMBCL	Primary mediastinal b-cell lymphoma
PNET	Primitive neuroectodermal tumor
RCC	Renal cell carcinoma
RMS	Rhabdomyosarcoma
US	Ultrasound
VMA	Vannilylmandelic acid
WBC	White blood cell count
XRT	Radiation therapy

General Guidelines (PEDONC-1.0)

ONCP.GG.0001.0.A

v2.0.2024

- A recent clinical evaluation (within 60 days) or meaningful contact (telephone call, electronic mail or messaging) should be performed prior to considering advanced imaging, unless the individual is undergoing guideline-supported scheduled off therapy surveillance evaluation or cancer screening. The clinical evaluation may include a relevant history and physical examination, including biopsy, appropriate laboratory studies, and results of non-advanced or advanced imaging modalities.
 - Because of the relatively small number of childhood cancer treatment centers, it is common to combine off-therapy visits with imaging and other subspecialist visits to accommodate families traveling long distances for their child's care.
- Unless otherwise stated in the disease-specific guideline, a histological confirmation of malignancy (or recurrence) and the stage of disease is required to perform a medical necessity review of the requested imaging.
- Unless otherwise stated in the disease-specific guideline, advanced imaging of asymptomatic individuals is not routinely supported without signs or symptoms of systemic involvement of cancer.
- Conventional imaging performed prior to diagnosis should not be repeated unless there is a delay of at least 6 weeks since previous imaging and treatment initiation or there are new or significantly worsening clinical signs or symptoms
- Generally, the studies listed in the disease-specific sections reflect the studies supported by current literature and research for that condition. If a study is not listed, then it is not supported.
- Routine imaging of brain, spine, neck, chest, abdomen, pelvis, bones, or other body areas is not indicated except where explicitly stated in a diagnosis-specific guideline section, or if one of the following applies:
 - Known prior disease involving the requested body area
 - New or worsening symptoms or physical exam findings involving the requested body area (including non-specific findings such as ascites or pleural effusion)
 - New finding on basic imaging study such as plain x-ray or ultrasound
 - New finding on adjacent body area CT/MRI study (i.e., pleural effusion observed on CT abdomen)
 - Unless otherwise stated in the disease-specific guideline, advanced imaging of asymptomatic individuals is not routinely supported without signs or symptoms of systemic involvement of cancer.
 - Repeat imaging studies are not generally necessary unless there is evidence of disease progression, recurrence of disease, and/or the repeat imaging will affect an individual's clinical management.
- Unless otherwise stated in the diagnosis-specific guidelines, imaging for treatment response can be approved after every 2 cycles, which is usually ~6 weeks of therapy for solid tumors and usually ~8 to 12 weeks for CNS tumors

- Unless otherwise specified for a specific cancer type, once PET has been documented to be negative for a given individual's cancer or all PET-avid disease has been surgically resected, PET should not be used for continued disease monitoring or surveillance unless one of the following applies:
 - Conventional imaging (CT, MRI, US, plain film) reveals findings that are inconclusive or suspicious for recurrence
 - Residual mass that has not changed in size since the last conventional imaging does not justify PET imaging
 - PET avidity in a residual mass at the end of planned therapy is not an indication for PET imaging during surveillance

Clarification of phases of therapy

Phases of Oncology Imaging	Definition
Screening	<ul style="list-style-type: none"> • Imaging requested for individuals at increased risk for a particular cancer in the absence of known clinical signs or symptoms • Screening using advancing imaging is only supported for conditions listed in <u>Screening Imaging in Cancer Predisposition Syndromes (PEDONC-2)</u>
Suspected/Initial Staging	<ul style="list-style-type: none"> • All imaging studies requested from the time cancer is first clinically suspected until the initiation of specific treatment <ul style="list-style-type: none"> • CT Chest prior to anesthesia for biopsy or resection of solid tumors and CTs of other involved body areas are generally indicated and should be performed concurrently • Metastatic CNS imaging and nuclear medicine imaging are generally deferred until after a histologic diagnosis is made, unless otherwise indicated by diagnosis-specific guideline
Treatment Response	<ul style="list-style-type: none"> • Imaging performed during any type of active treatment (chemotherapy or other medications, radiation therapy, or surgery), including evaluation at the end of planned active treatment <ul style="list-style-type: none"> • Unless otherwise stated in the diagnosis-specific guidelines, imaging for treatment response can be approved after every 2 cycles, which is usually ~6 weeks of therapy for solid tumors and usually ~8 to 12 weeks for CNS tumors

Phases of Oncology Imaging	Definition
Surveillance	<ul style="list-style-type: none"> Imaging performed in individuals who are asymptomatic or have chronic stable symptoms and not receiving any active treatment, even if residual imaging abnormalities are present <ul style="list-style-type: none"> PET imaging is not supported for surveillance imaging unless specifically stated in elsewhere in the diagnosis-specific guideline sections
Recurrence	<ul style="list-style-type: none"> All imaging studies completed at the time a recurrence or progression of a known cancer is strongly suspected or documented based on clinical signs or symptoms, laboratory findings, or results of basic imaging studies such as plain radiography or ultrasound Following documented recurrence of childhood cancer, any studies recommended for initial staging of that cancer type in the diagnosis-specific imaging guideline section should be approved <ul style="list-style-type: none"> During active treatment for recurrent pediatric cancer, conventional imaging evaluation (CT or MRI, should use the same modality for ongoing monitoring as much as possible) of previously involved areas should be approved according to the treatment response imaging in the diagnosis-specific guideline section <ul style="list-style-type: none"> Always refer to the diagnosis specific guideline for PET indications in recurrence.

- Brain imaging is performed for signs or symptoms of brain disease
 - MRI Brain without and with contrast (CPT® 70553) is the recommended study for evaluation of suspected or known brain metastases. If a non-contrast CT head shows suspicious lesion, MRI Brain may be obtained to further characterize the lesion
 - CT without and with contrast (CPT® 70470) can be approved when MRI is contraindicated or not available, or if there is skull bone involvement
 - Certain malignancies including, but not limited to melanoma, lung cancer and renal cell cancer have indications for brain imaging for asymptomatic individuals
 - If stage IV disease is demonstrated elsewhere or if systemic disease progression is noted, refer to disease specific guidelines
 - Initiation of angiogenesis therapy is not an indication for advanced imaging of the brain in asymptomatic individuals (Avastin/Bevacizumab; <3% risk of bleeding and <1% risk of serious bleeding)

- Bone Scan:
 - Primarily used for evaluation of bone metastases in individuals with solid malignancies.
 - Indications for bone scan in individuals with history of malignancy include – bone pain, rising tumor markers, elevated alkaline phosphatase or in individuals with primary bone tumor.
 - For evaluation of suspected or known bony metastases, CPT® 78306 (Nuclear bone scan whole-body), may be approved.
 - Radiopharmaceutical Localization scan SPECT (CPT® 78803 or CPT® 78831) or SPECT/CT (CPT® 78830 or CPT® 78832) may be approved as an add-on test for further evaluation of a specific area of interest.
 - CPT® codes 78300 (Nuclear bone scan limited), 78305 (Nuclear bone scan multiple areas) or 78315 do not have any indications in oncology nuclear medicine imaging.
- Bone scan supplemented by plain x-rays are the initial imaging modalities for suspected malignant bone pain. For specific imaging indications, see also:
 - **Nuclear Medicine (NM) Imaging in Oncology (ONC-1.3)**
 - **Bone (including Vertebral) Metastases (ONC-31.5)**
 - **Spinal Cord Compression (ONC-31.6)**
 - **Carcinoma of Unknown Primary Site (ONC-31.7)**
- Delay PET/CT for at least 12 weeks after completion of radiation treatment, unless required sooner for imminent surgical resection.
- PET/CT may be considered prior to biopsy in order to determine a more favorable site for biopsy when a prior biopsy was nondiagnostic or a relatively inaccessible site is contemplated which would require invasive surgical intervention for biopsy attempt.
- PET/CT may be indicated if:
 - Conventional imaging (CT, MRI or bone scan) reveals findings that are inconclusive or negative, with continued suspicion for recurrence
- **Unless specified in diagnosis-specific guideline section PET/CT Imaging is NOT indicated for:**
 - Infection, inflammation, trauma, post-operative healing, granulomatous disease, rheumatological conditions
 - Concomitantly with separate diagnostic CT studies
 - Conclusive evidence of distant or diffuse metastatic disease on recent conventional imaging studies
 - Metastatic disease in the central nervous system (CNS)
 - Lesions less than 8 mm in size
 - Follow up after localized therapy (i.e. radiofrequency ablation, embolization, stereotactic radiation, etc.)

- Rare malignancies, due to lack of available evidence regarding the diagnostic accuracy of PET in rare cancers
- Surveillance
 - Serial monitoring of individuals who are not currently receiving anti-tumor treatment or are receiving maintenance treatment
 - Serial monitoring of FDG avidity until resolution.
 - PET/CT avidity in a residual mass at the end of planned therapy is not an indication for PET/CT imaging during surveillance.
 - Residual mass that has not changed in size since the last conventional imaging does not justify PET imaging
- Please refer to general guidelines section **PET Imaging in Oncology (ONC-1.4)** and **PET Imaging in Pediatric Oncology (PEDONC-1.4)** for further guidance regarding PET. Those guidelines should be applied with regard to radiotracer coverage.
- Please refer to general guidelines in **Unlisted Procedure Codes in Oncology (ONC-1.5)** for unlisted procedures in pediatric oncology.

Clinical Trials

- Similar to investigational and experimental studies, clinical trial imaging requests will be considered to determine whether they meet Health Plan coverage and eviCore's evidence-based guidelines.
- Imaging studies which are inconsistent with established clinical standards, or are requested for data collection and not used in direct clinical management are not supported.

Age Considerations (PEDONC-1.1)

ONCP.GG.0001.1.A

v2.0.2024

- The majority of malignancies occurring in the pediatric population are different diagnoses than those occurring in the adult population.
- For those diseases which occur in both pediatric and adult populations, minor differences may exist in management between pediatric and adult medical oncologists due to the following:
 - Age of the individual
 - Comorbidities
 - Differences in disease natural history between children and adults

AGE APPROPRIATE GUIDELINES	
Age of Individual	Appropriate Imaging Guidelines
≥18 years old at initial diagnosis	<ul style="list-style-type: none"> • General Oncology Imaging Guidelines, except where directed otherwise by a specific guideline section
<18 years old at initial diagnosis	<ul style="list-style-type: none"> • Pediatric Oncology Imaging Guidelines, except where directed otherwise by a specific guideline section
15 to 39 years old at initial diagnosis (defined as Adolescent and Young Adult (AYA) oncology individuals)	<ul style="list-style-type: none"> • When unique guidelines for a specific cancer type exist only in either Oncology or Pediatric Oncology, AYA individuals should be imaged according to the guideline section for their specific cancer type, regardless of the individual's age • When unique guidelines for a specific cancer type exist in both Oncology and Pediatric Oncology, AYA individuals should be imaged according to the age rule in the previous bullet

Appropriate Clinical Evaluations (PEDONC-1.2)

ONCP.GG.0001.2.A

v2.0.2024

- The majority of pediatric oncology imaging indications are listed in the diagnosis-specific guideline sections
 - Rare malignancies and other circumstances not specifically addressed elsewhere in the Pediatric Oncology guidelines, the following general principles apply:
 - Routine imaging of brain, spine, neck, chest, abdomen, pelvis, bones, or other body areas is not indicated in the absence of:
 - Localizing symptoms or
 - Abnormalities on plain radiography or ultrasound
- The overwhelming majority of pediatric oncology individuals treated in the United States will be enrolled on or treated according to recent Children’s Oncology Group (COG) protocols
 - COG is a National Cancer Institute (NCI) supported clinical trials group
 - These imaging guidelines are generally consistent with evaluations recommended by COG protocols commonly used for direct individual care (whether formally enrolled on study or not)
 - Requests for exception to guidelines based on COG protocol should be accompanied by the COG road map or COG details in the medical record for case-by-case consideration.
 - For individuals enrolled on a COG study, imaging recommended by COG protocols should generally be approved unless the imaging is being performed solely to address a study objective and would not be indicated in usual clinical care.
 - Requests for exception to guidelines based on COG protocol should be accompanied by the COG road map or COG details in the medical record for case-by-case consideration.

Phases of Pediatric Oncology Imaging:

- Pediatric malignancies, in general, behave more aggressively than adult cancers, and the time from initial suspicion of cancer to specific therapy initiation can be measured in hours to days for most pediatric cancers
- It is recommended that children with pediatric solid tumors undergo CT evaluation of the chest prior to general anesthesia for biopsy or resection due to the risk of post-operative atelectasis mimicking pulmonary metastasis resulting in inaccurate staging and/or delay in therapy initiation
- Unlike adult cancers, in most pediatric cancers surveillance does not begin until all planned multimodal therapy is completed

- Pediatric cancers where surgical resection is considered curative are listed in the diagnosis-specific guideline sections
- Certain tumor types do not require surveillance with advanced imaging as individual outcomes following relapse are not improved by surveillance imaging. See diagnosis-specific guideline sections for details
- Imaging may be indicated more frequently than recommended by guidelines with clinical documentation that the imaging results are likely to result in a treatment change for the individual, including a change from active treatment to surveillance

Phases of Oncology Imaging	Definition
Screening	<ul style="list-style-type: none"> • Imaging requested for individuals at increased risk for a particular cancer in the absence of known clinical signs or symptoms • Screening using advancing imaging is only supported for conditions listed in <u>Screening Imaging in Cancer Predisposition Syndromes (PEDONC-2)</u>
Suspected/Initial Staging	<ul style="list-style-type: none"> • All imaging studies requested from the time cancer is first clinically suspected until the initiation of specific treatment <ul style="list-style-type: none"> • CT Chest prior to anesthesia for biopsy or resection of solid tumors and CTs of other involved body areas are generally indicated and should be performed concurrently • Metastatic CNS imaging and nuclear medicine imaging are generally deferred until after a histologic diagnosis is made, unless otherwise indicated by diagnosis-specific guideline
Treatment Response	<ul style="list-style-type: none"> • Imaging performed during any type of active treatment (chemotherapy or other medications, radiation therapy, or surgery), including evaluation at the end of planned active treatment <ul style="list-style-type: none"> • Unless otherwise stated in the diagnosis-specific guidelines, imaging for treatment response can be approved after every 2 cycles, which is usually ~6 weeks of therapy for solid tumors and usually ~8 to 12 weeks for CNS tumors
Surveillance	<ul style="list-style-type: none"> • Imaging performed in individuals who are asymptomatic or have chronic stable symptoms and not receiving any active treatment, even if residual imaging abnormalities are present <ul style="list-style-type: none"> • PET imaging is not supported for surveillance imaging unless specifically stated in elsewhere in the diagnosis-specific guideline sections

Phases of Oncology Imaging	Definition
Recurrence	<ul style="list-style-type: none"> All imaging studies completed at the time a recurrence or progression of a known cancer is strongly suspected or documented based on clinical signs or symptoms, laboratory findings, or results of basic imaging studies such as plain radiography or ultrasound Following documented recurrence of childhood cancer, any studies recommended for initial staging of that cancer type in the diagnosis-specific imaging guideline section should be approved During active treatment for recurrent pediatric cancer, conventional imaging evaluation (CT or MRI, should use the same modality for ongoing monitoring as much as possible) of previously involved areas should be approved according to the treatment response imaging in the diagnosis-specific guideline section <ul style="list-style-type: none"> Always refer to the diagnosis specific guideline for PET indications in recurrence.

Radiation Treatment Planning In Pediatric Oncology

- Imaging performed in support of radiation therapy treatment planning should follow guidelines outlined in **Unlisted Procedure Codes in Oncology (ONC-1.5)**.

Cardiac Function Assessment in Pediatric Oncology During Active Treatment:

Indication	Imaging Study
<ul style="list-style-type: none"> Evaluation of cardiac function prior to cardiotoxic chemotherapy, and for monitoring while on active therapy or at end of therapy at the discretion of the treating pediatric oncologist based on: <ul style="list-style-type: none"> Cumulative cardiotoxic therapy received to date Individual's age and gender Most recent echocardiogram results New or worsening cardiac symptoms 	<ul style="list-style-type: none"> Echocardiography (CPT® 93306, CPT® 93307, or CPT® 93308)

Indication	Imaging Study
<ul style="list-style-type: none"> • For either of the following: <ul style="list-style-type: none"> • Echocardiography yielded a borderline shortening fraction (<30%) and additional left ventricular function data are necessary to make a chemotherapy decision OR • Echocardiography windowing is suboptimal due to body habitus or tumor location 	<ul style="list-style-type: none"> • Multi-gated acquisition (MUGA, CPT® 78472) blood pool nuclear medicine scanning

Background and Supporting Information

Immunosuppression During Pediatric Cancer Therapy and Imaging

Ramifications:

- Individuals may be severely immunocompromised during active chemotherapy treatment and any conventional imaging request to evaluate for infectious complications during this time frame should be approved immediately
 - Imaging requests for infectious disease concerns for all individuals with absolute neutrophil count (ANC) <500 **or**
 - Inconclusive findings on chest x-ray or US at any ANC during active treatment should be approved as requested
 - Individuals may have therapy-induced hypogammaglobulinemia which requires supplemental intravenous immune globulin (IVIG) during maintenance therapy. These individuals receiving supplemental IVIG should be treated similarly to individuals with ANC <500 with regards to imaging for infectious disease
- Some individuals are treated with very intensive chemotherapy regimens (including autologous stem cell transplantation) and spend the majority of their chemotherapy treatment phase in the hospital. See: **Hematopoietic Stem Cell Transplantation (ONC-29)**.
- Due to the high risk of invasive infections, frequent CT may be indicated to evaluate known sites of invasive fungal infection, and in general these should be approved as requested
 - Surveillance imaging of asymptomatic individuals to detect invasive fungal infection has not been shown to impact individual outcomes
 - Imaging requests are indicated when acute clinical decisions will be made based on the imaging

Hematopoietic Stem Cell Transplant (HSCT) in Pediatric Oncology:

- Transplantation of hematopoietic stem cells from bone marrow, peripheral blood, or cord blood is commonly used in the following clinical situations:

- High-risk or recurrent leukemia (allogeneic)
- Recurrent lymphoma (allogeneic or autologous)
- Hemophagocytic lymphohistiocytosis (allogeneic)
- High-risk sickle cell disease (allogeneic)
- High-risk neuroblastoma (autologous)
- High-risk CNS tumors (autologous)
- Recurrent Ewing sarcoma family of tumors (autologous, rarely allogeneic)
- Imaging considerations for HSCT should follow guidelines in: **Hematopoietic Stem Cell Transplantation (ONC-29)**.

Modality General Considerations (PEDONC-1.3)

ONCP.GG.0001.3.A

v2.0.2024

- Plain radiography
 - Chest x-ray (CXR) can provide a prompt means to evaluate primary intrathoracic tumors and continues to be the initial imaging study recommended to detect complications, such as suspected infection, in symptomatic individuals undergoing treatment.
 - CXR continues to be the initial imaging study recommended for pulmonary surveillance for some pediatric cancers. See diagnosis-specific guideline sections for details.
 - Plain radiography continues to be the initial imaging study recommended for evaluation of lesions involving the appendicular skeleton, both during and after completion of treatment. See diagnosis-specific guideline sections for details.
 - Plain abdominal radiographs have largely been replaced by ultrasound, CT, or MRI.
- Ultrasound
 - Ultrasound is not widely used in pediatric oncology for staging but is frequently used for surveillance in individuals who have successfully treated (primarily abdominal or pelvic) tumors with little or no residual disease.
 - See diagnosis-specific guideline sections for details.
- CT
 - CT with contrast is the imaging study of choice in pediatric individuals with lymphomas or solid tumors of the neck, thorax, abdomen, and/or pelvis
 - If CT contrast use is contraindicated due to allergy or impaired renal function, either CT without contrast or MRI without and with contrast may be substituted at the discretion of the ordering physician
- MRI
 - MRI without and with contrast is the study of choice for CNS tumors and musculoskeletal tumors
 - If MRI contrast use is contraindicated due to allergy or impaired renal function, MRI without contrast may be substituted at the discretion of the ordering physician
 - Due to the length of time for image acquisition and the need for stillness, anesthesia is required for almost all infants and young children (age <7 years), as well as older children with delays in development or maturity. In this population, MRI imaging sessions should be planned with a goal of avoiding a short-interval repeat anesthesia exposure due to insufficient information using the following considerations:

- MRI should generally be performed without and with contrast unless there is a specific contraindication to gadolinium use since the individual already has intravenous access for anesthesia
 - Recent evidence-based literature demonstrates the potential for gadolinium deposition in various organs including the brain, after the use of MRI contrast
 - The U.S. Food and Drug Administration (FDA) has noted that there is currently no evidence to suggest that gadolinium retention in the brain is harmful and restricting gadolinium-based contrast agents (GBCAS) use is not warranted at this time
 - It has been recommended that GBCA use should be limited to circumstances in which additional information provided by the contrast agent is necessary and the necessity of repetitive MRIs with GBCAS should be assessed
 - If requesting clinicians indicate that a non-contrast study is being requested due to concerns regarding the use of gadolinium, the exam can be approved
- In some instances, to reduce time under anesthesia for MRI in pediatric individuals, surveillance or restaging studies may be requested with contrast only when it is determined that repeat non-contrast imaging does not add to an individual clinical case. These may be approved on a case-by-case basis.
 - If multiple body areas are supported by eviCore guidelines for the clinical condition being evaluated, MRI of all necessary body areas should be obtained concurrently in the same anesthesia session
- Nuclear medicine
 - General PET imaging consideration can be found in **PET Imaging in Pediatric Oncology (PEDONC-1.4)**.
 - Bone scan is frequently used for evaluation of bone metastases in pediatric oncology during initial treatment, treatment response, and surveillance
 - CPT® 78315 has no specific indications for evaluation of malignant disease
 - ¹²³I-metaiodobenzylguanidine (MIBG) scintigraphy is the preferred metabolic imaging for neuroblastoma and is positive in 90% to 95% of neuroblastomas. MIBG is also used for evaluation of pheochromocytomas, paragangliomas, ganglioneuromas, and ganglioneuroblastomas, PET/CT indications are provided in the relevant sections.

Study Type	Coding
Bone Scan	<ul style="list-style-type: none"> • ANY of the following codes can be approved: <ul style="list-style-type: none"> • CPT® 78300 • CPT® 78305 • CPT® 78306 • CPT® 78803, 78830, or 78832 <ul style="list-style-type: none"> • May be approved alone or in combination with: <ul style="list-style-type: none"> • CPT® 78305 • CPT® 78306
¹²³ I- metaiodobenzylguanidine (MIBG) scintigraphy	<ul style="list-style-type: none"> • ANY one of the following codes can be approved: <ul style="list-style-type: none"> • CPT® 78801 • CPT® 78802 • CPT® 78804 • ANY one of the following codes may also be approved, individual or in combination with CPT® 78801,78802 or 78804: <ul style="list-style-type: none"> • CPT® 78803 • CPT® 78830 • CPT® 78831 • CPT® 78832 • CPT® 78800 may be approved for KNOWN neuroblastoma when only a single site follow up is desired but is not sufficient for the initial workup of suspected disease
Octreotide scan	Same coding as MIBG
Gallium scan	Same coding as MIBG

PET Imaging in Pediatric Oncology (PEDONC-1.4)

ONCP.GG.0001.4.A

v2.0.2024

Throughout these guidelines, the term “PET” refers specifically to ¹⁸F-FDG-PET imaging and also applies to PET/CT fusion studies.

- PET imaging in pediatric oncology should use PET/CT fusion imaging (CPT® 78815 or CPT® 78816)
- The decision whether to use skull base to mid-femur (“eyes to thighs”) procedure code for PET (CPT® 78815) or whole-body PET (CPT® 78816) is addressed in the diagnosis-specific guideline sections.
- PET imaging in oncology should use PET/CT fusion imaging (CPT® 78815 or CPT® 78816)
- PET/MRI is generally not supported by eviCore for a vast majority of oncologic conditions due to lack of standardization in imaging technique and interpretation. **However, it may be approved in certain oncologic conditions when all of the following criteria are met:**
 - PET/MRI is supported in the condition-specific guideline criteria **OR**
 - The individual meets guideline criteria for PET/CT **AND**
 - The individual is a pediatric patient or the patient is an adult whose condition is reviewed under pediatric eviCore Radiology Guidelines (examples include histiocytic disorders, osteosarcoma, Ewing sarcoma, and some lymphomas) **AND**
 - PET/CT is **not** available at the treating institution **AND**
 - The provider requests PET/MRI in lieu of PET/CT
 - When the above criteria are met, PET/MRI may be approved using the code combination of PET Whole-Body (CPT® 78813) and MRI Unlisted (CPT® 76498). All other methods of reporting PET/MRI are inappropriate.
 - When clinically appropriate, diagnostic MRI codes may be approved at the same time as the PET/MRI code combination.
- Unbundling PET/CT imaging into separate PET (such as CPT® 78812 or CPT® 78813) and diagnostic CT codes is otherwise not supported.
- PET imaging is not reliable for the detection of anatomic lesions smaller than 8 mm in size.
- Delay PET/CT for at least 12 weeks after completion of radiation treatment, unless required sooner for imminent surgical resection.
- PET imaging using isotopes other than ¹⁸F-FDG, ⁶⁸Ga-DOTATATE, or ⁶⁸Ga-DOTATOC is considered investigational at this time.
- PET has not been shown to be diagnostically useful in all forms of childhood cancer. PET is supported for pediatric malignancies with significant published

evidence regarding its diagnostic accuracy and importance in accurately directing individual care decisions. See diagnosis-specific guideline sections for details.

- PET imaging is not specific to cancer, and has a high rate of false positivity. Inflammation, infection (especially granulomatous), trauma, and post-operative healing may show high levels of FDG uptake and be false-positive for malignant lesions.
- PET for rare malignancies not specifically addressed by eviCore guidelines is generally not indicated, due to lack of available evidence regarding diagnostic accuracy of PET in the majority of rare cancers. Conventional imaging studies should be used for initial staging and treatment response for these diagnoses.
- PET can be approved if **all** of the following apply:
 - Conventional imaging (CT, MRI, US, plain film) reveals findings that are equivocal or suspicious
 - No other specific metabolic imaging (MIBG, octreotide, technetium, etc.) is appropriate for the cancer type
 - The submitted clinical information describes a specific decision regarding the individual's care that will be made based on the PET results
- PET imaging for surveillance imaging **only** when specifically stated elsewhere in the diagnosis-specific guideline sections
- Unless otherwise specified for a specific cancer type, once PET has been documented to be negative for a given individual's cancer or all PET-avid disease has been surgically resected, PET should not be used for continued disease monitoring or surveillance unless **one** of the following applies:
 - Conventional imaging (CT, MRI, US, plain film) reveals findings that are inconclusive or suspicious for recurrence
 - Residual mass that has not changed in size since the last conventional imaging does **not** justify PET imaging
 - PET avidity in a residual mass at the end of planned therapy is **not** an indication for PET imaging during surveillance.
 - Very rare circumstances where tumor markers or obvious clinical symptoms show strong evidence suggesting recurrence and PET would replace conventional imaging modalities
 - The individual is undergoing salvage treatment for a recurrent solid tumor with residual measurable disease on conventional imaging and confirmed repeat negative PET imaging will allow the individual to transition from active treatment to surveillance

Diagnostic Radiation Exposure in Pediatric Oncology (PEDONC-1.5)

ONCP.GG.0001.5.A

v2.0.2024

- Young children are presumed to be at increased risk for malignancy from diagnostic radiation exposure, most commonly from CT and nuclear medicine imaging. They are more sensitive to radiation than adults and generally live longer after receiving radiation doses from medical procedures, resulting in a larger number of years during which to manifest a cancer.
- Because of this presumed increased risk in young children, requests to substitute MRI without and with contrast for CT with contrast to avoid radiation exposure can be approved if ALL of the following criteria apply:
 - The individual is presently a young child and the ordering physician has documented the reason for MRI, rather than CT, is to avoid radiation exposure.
 - The disease-specific guidelines do not list CT as superior to MRI for the current disease and time point, meaning the MRI will provide equivalent or superior information relative to CT.
 - The request is for a body area other than Chest as MRI is substantially inferior to CT for detection of small pulmonary metastases.
- The guidelines listed in this section for certain specific indications are not intended to be all-inclusive; clinical judgment remains paramount and variance from these guidelines may be appropriate and warranted for specific clinical situations.

References (PEDONC-1)

v2.0.2024

1. Krishnamurthy R, Daldrup-Link HE, Jones JY, et al. Imaging studies in the diagnosis and management of pediatric malignancies. In: Pizzo PA, Poplack DG, eds. *Principles and Practice of Pediatric Oncology*. 7th ed. Philadelphia, PA: Wolters Kluwer; 2016:185-238.
2. Allen-Rhoades W, Steuber CP. Clinical assessment and differential diagnosis of the child with suspected cancer. In: Pizzo PA, Poplack DG, eds. *Principles and Practice of Pediatric Oncology*. 7th ed. Philadelphia, PA: Wolters Kluwer; 2016:101-112.
3. Gottschalk S, Naik S, Hegde M, et al. Hematopoietic stem cell transplantation in pediatric oncology. In: Pizzo PA, Poplack DG, eds. *Principles and Practice of Pediatric Oncology*. 7th ed. Philadelphia, PA: Wolters Kluwer; 2016:419-440.
4. Freedman JL, Rheingold SR, and Fisher MJ. Oncologic emergencies. In: Pizzo PA, Poplack DG, eds. *Principles and Practice of Pediatric Oncology*. 7th ed. Philadelphia, PA: Wolters Kluwer; 2016:967-991.
5. Andrews J, Galel SA, Wong W, et al. Hematologic supportive care for children with cancer. In: Pizzo PA, Poplack DG, eds. *Principles and Practice of Pediatric Oncology*. 7th ed. Philadelphia, PA: Wolters Kluwer; 2016:992-1009.
6. Ardura MI, Koh AY. Infectious complications in pediatric cancer patients. In: Pizzo PA, Poplack DG, eds. *Principles and Practice of Pediatric Oncology*. 7th ed. Philadelphia, PA: Wolters Kluwer; 2016:1010-1057.
7. Shaikh R, Prabhu SP, Voss SD. Imaging in the evaluation and management of childhood cancer. In: Orkin SH, Fisher DE, Ginsburg D, Look AT, Lux SE, Nathan DG, eds. *Nathan and Oski's Hematology and Oncology of Infancy and Childhood*. 8th ed. Philadelphia, PA: Elsevier Saunders; 2015:2146-2254.
8. Sung L, Fisher BT, Koh AY. Infectious Disease in the pediatric cancer patient. In: Orkin SH, Fisher DE, Ginsburg D, Look AT, Lux SE, Nathan DG, eds. *Nathan and Oski's Hematology and Oncology of Infancy and Childhood*. 8th ed. Philadelphia, PA: Elsevier Saunders; 2015:2257-2266.
9. Mullen EA, Gratiias E. Oncologic emergencies. In: Orkin SH, Fisher DE, Ginsburg D, Look AT, Lux SE, Nathan DG, eds. *Nathan and Oski's Hematology and Oncology of Infancy and Childhood*. 8th ed. Philadelphia, PA: Elsevier Saunders; 2015:2267-2291.
10. Weiser DA, Kaste SC, Siegel MJ, et al. Imaging in childhood cancer: A society for Pediatric Radiology and Children's Oncology Group joint task force report. *Pediatr Blood Cancer*. 2013;60(8):1253-1260. doi:10.1002/pbc.24533.
11. American College of Radiology. ACR-ASER-SCBT-MR-SPR Practice Parameter for the Performance of Pediatric Computed Tomography (CT). 2014. <https://www.acr.org/-/media/ACR/Files/Practice-Parameters/CT-Ped.pdf>.
12. ACR-SPR Practice Parameter for the Performance and Interpretation of Pediatric Magnetic Resonance Imaging (MRI), Revised 2015 (Resolution 11). <https://www.acr.org/-/media/CB384A65345F402083639E6756CE513F.pdf>.
13. Smith EA, Dillman JR. Current role of body MRI in pediatric oncology. *Pediatr Radiol*. 2016;46(6):873-880. doi:10.1007/s00247-016-3560-8.
14. The Center for Drug Evaluation and Research. Meeting of the Medical Imaging Drugs Advisory Committee, presented September 8, 2017. <https://www.fda.gov/downloads/AdvisoryCommittees/CommitteesMeetingMaterials/Drugs/MedicalImagingDrugsAdvisoryCommittee/UCM574746.pdf>.
15. Uslu L, Doing J, Link M, et al. Value of 18F-FDG PET and PET/CT for evaluation of pediatric malignancies. *J Nucl Med*. 2015;56(2):274-286. doi:10.2967/jnumed.114.146290.
16. McCarville MB. PET-CT imaging in pediatric oncology. *Cancer Imaging*. 2009(1);9:35-43. doi:10.1102/1470-7330.2009.0008.
17. Matthews JD, Forsythe AV, Brady Z, et al. Cancer risk in 680 000 people exposed to computed tomography scans in childhood or adolescence: data linkage study of 11 million Australians. *BMJ*. 2013;346:f2360. doi:10.1136/bmj.f2360.
18. Erdi YE. Limits of tumor detectability in nuclear medicine and PET. *Mol Imaging Radio Nucl Ther*. 2012;21(1):23-28. doi:10.4274/Mirt.138.
19. Brody AS, Guillerman RP. Don't let radiation scare trump patient care: 10 ways you can harm your patients by fear of radiation-induced cancer from diagnostic imaging. *Thorax*. 2014;69(8):782-784. doi:10.1136/thoraxjnl-2014-205499.
20. Meulepas JM, Ronckers CM, Smets AMJB, et al. Radiation exposure from pediatric CT scans and subsequent cancer risk in the Netherlands, *JNCI J Natl Cancer Inst*. 2019;111:256-2634. doi: 10.1093/jnci/djy104.
21. Bhatia S, Pappo AS, Acquazzino M, et al. National Comprehensive Cancer Network (NCCN) Guidelines Version 2.2024—July 7, 2023, Adolescent and Young Adult (AYA) Oncology, available at: <https://www.nccn.org>.

nccn.org/professionals/physician_gls/pdf/aya.pdf, referenced with permission from the NCCN Clinical Practice Guidelines in Oncology (NCCN Guidelines™) for Adolescent and Young Adult (AYA) Oncology V2.2024 07/07/2023. ©2023 National Comprehensive Cancer Network, Inc. All rights reserved. The NCCN Guidelines™ and illustrations herein may not be reproduced in any form for any purpose without the express written permission of the NCCN. To view the most recent and complete version of the NCCN Guidelines™, go online to NCCN.org.

22. States LJ, Reid JR. Whole-Body PET/MRI applications in pediatric oncology. *AJR Am J Roentgenol*. 2020;215(3):713-725. doi:10.2214/AJR.19.22677.
23. Mayerhoefer ME, Archibald SJ, Messiou C, Staudenherz A, Berzaczy D, Schöder H. MRI and PET/MRI in hematologic malignancies. *J Magn Reson Imaging*. 2020;51(5):1325-1335. doi:10.1002/jmri.26848.
24. Sher AC, Seghers V, Paldino MJ, et. al. Assessment of sequential PET/MRI in comparison with PET/CT of pediatric lymphoma: a prospective study. *AJR Am J Roentgenol*. 2016;206(3):623-31. doi:10.2214/AJR.15.15083.
25. Reighard C, Junaid S, Jackson WM, Arif A, Waddington H, Whitehouse AJO, Ing C. Anesthetic exposure during childhood and neurodevelopmental outcomes: a systematic review and meta-analysis. *JAMA Netw Open*. 2022;5(6):e2217427. doi:10.1001/jamanetworkopen.2022.17427.

Screening Imaging in Cancer Predisposition Syndromes (PEDONC-2)

Guideline

Screening Imaging in Cancer Predisposition Syndromes – General Considerations (PEDONC-2.1)

Li-Fraumeni Syndrome (LFS) (PEDONC-2.2)

Neurofibromatosis 1 and 2 (NF1 and NF2) (PEDONC-2.3)

Beckwith-Wiedemann Syndrome (BWS) (PEDONC-2.4)

Denys-Drash Syndrome (DDS) (PEDONC-2.5)

Wilms Tumor-Aniridia-Growth Retardation (WAGR) (PEDONC-2.6)

Familial Adenomatous Polyposis (FAP) and Related Conditions (PEDONC-2.7)

Multiple Endocrine Neoplasias (MEN) (PEDONC-2.8)

Tuberous Sclerosis Complex (TSC) (PEDONC-2.9)

Von Hippel-Lindau Syndrome (VHL) (PEDONC-2.10)

Rhabdoid Tumor Predisposition Syndrome (PEDONC-2.11)

Familial Retinoblastoma Syndrome (PEDONC-2.12)

Hereditary Paraganglioma-Pheochromocytoma (HPP) Syndromes (PEDONC-2.13)

Costello Syndrome (PEDONC-2.14)

Constitutional Mismatch Repair Deficiency (CMMRD or Turcot Syndrome) (PEDONC-2.15)

Hereditary Leiomyomatosis and Renal Cell Cancer (HLRCC) (PEDONC-2.16)

Other Renal Cell Cancer Predisposition Syndromes (PEDONC-2.17)

Infantile Myofibromatosis (PEDONC-2.18)

Bloom Syndrome (PEDONC-2.19)

References (PEDONC-2)

Screening Imaging in Cancer Predisposition Syndromes – General Considerations (PEDONC-2.1)

ONCP.SC.0002.1.A
v2.0.2024

- This section is intended to give guidance for screening imaging prior to diagnosis with a specific malignancy. Once an individual with a cancer predisposition syndrome has been diagnosed with a malignant disease, future imaging decisions should be guided by the appropriate disease-specific guidelines except as explicitly stated elsewhere in this section.
- This section's guidelines are limited to cancer predisposition syndromes with screening imaging considerations. Syndromes requiring only clinical or laboratory screening are not discussed here.
- In general, a recent (within 60 days) detailed history and physical examination and appropriate laboratory studies should be performed prior to considering advanced imaging, unless the individual is undergoing guideline-supported scheduled screening evaluation identified in this section.
- Where MRI is indicated in these guidelines, CT may be approved only if MRI is contraindicated, given the risk of radiation exposure in these syndromes.
- Many of these cancer predisposition syndromes also affect adults as survival continues to improve for these individuals.
 - Adults with syndromes covered in this section may follow these imaging guidelines except where contradicted by specific statements in the general imaging guidelines.
- Documentation of genetic or molecular confirmation of the appropriate syndrome with increased cancer risk is preferred for any individual to qualify for screening imaging. There are a number of complex ethical, social, and financial issues involved in the decision to complete genetic testing in a pediatric individual.
 - From the 2013 AAP Policy Statement, "Predictive genetic testing for adult-onset conditions generally should be deferred unless an intervention initiated in childhood may reduce morbidity or mortality." **Imaging surveillance is one such intervention and should not be performed without justifiable cause.**
 - Genetic testing should be performed in conjunction with genetic counseling for appropriate communication of risks identified by testing.
 - When genetic testing is not possible or not supported by health plan coverage policies, formal diagnosis after evaluation by a physician with significant training and/or experience in cancer predisposition syndromes (most commonly a geneticist or oncologist) is generally sufficient to confirm eligibility for screening imaging.
- Due to the length of time for image acquisition and the need for stillness, anesthesia is required for almost all infants and young children (age < 7 years), as

well as older children with delays in development or maturity. In this individual population, MRI imaging sessions should be planned with a goal of avoiding a short-interval repeat anesthesia exposure due to insufficient information using the following considerations:

- MRI should always be performed without and with contrast unless there is a specific contraindication to gadolinium use, since the individual already has intravenous access for anesthesia.
 - Recent evidence-based literature demonstrates the potential for gadolinium deposition in various organs including the brain, after the use of MRI contrast.
 - The U.S. food and drug administration (FDA) has noted that there is currently no evidence to suggest that gadolinium retention in the brain is harmful and restricting gadolinium-based contrast agents (GBCAS) use is not warranted at this time. It has been recommended that GBCA use should be limited to circumstances in which additional information provided by the contrast agent is necessary and the necessity of repetitive MRIs with GBCAS should be assessed.
 - If requesting clinicians indicate that a non-contrast study is being requested due to concerns regarding the use of gadolinium, the exam can be approved.
 - In some instances, to reduce time under anesthesia for MRI in pediatric individuals, surveillance or restaging studies may be requested with contrast only when it is determined that repeat non-contrast imaging does not add to an individual clinical case. These may be approved on a case-by-case basis.
- If multiple body areas are supported by eviCore guidelines for the clinical condition being evaluated, MRI of all necessary body areas should be obtained concurrently in the same anesthesia session

Li-Fraumeni Syndrome (LFS) (PEDONC-2.2)

ONCP.SC.0002.2.A

v2.0.2024

The following imaging studies should be considered appropriate in individuals with LFS:

Indication	Imaging Study
All individuals	<ul style="list-style-type: none"> • BOTH of the following, annually: <ul style="list-style-type: none"> • MRI Brain without and with contrast (CPT® 70553) • Whole-body MRI (WBMRI, CPT® 76498) <ul style="list-style-type: none"> • CPT® 76498 is the only approvable code for whole-body MRI at this time. • Every 3 months from birth to age 18: <ul style="list-style-type: none"> • Abdominal (CPT® 76700) and pelvic (CPT® 76856) ultrasound • Beginning at age 20: <ul style="list-style-type: none"> • Annual Breast MRI (CPT® 77049), alternating every 6 months with breast ultrasound, in addition to the previously noted annual MRI studies.
Documented signs or symptoms suggestive of possible malignancy	<ul style="list-style-type: none"> • Targeted MRI without and with contrast of the involved body area(s)

Background and Supporting Information

- LFS - syndrome inherited in an autosomal dominant manner (50% risk to offspring) associated with germline mutations in *TP53* resulted in an increased susceptibility to a variety of cancers.
 - Eighty percent of individuals will have germline *TP53* mutation:
 - Tumor-specific *TP53* mutations are much more common than germline *TP53* mutations and are not associated with an increased risk for subsequent cancers
 - If *TP53*-negative, formal diagnosis of LFS should be assigned by a physician with significant training and/or experience in LFS (most commonly a geneticist or oncologist) based on specified clinical criteria prior to beginning a screening imaging program

- *TP53* mutations may be present in 50% to 80% of pediatric adrenocortical carcinoma, 10% of pediatric rhabdomyosarcoma, and 10% of pediatric osteosarcoma
- Individuals with LFS have an increased sensitivity to ionizing radiation, so screening strategies resulting in significant radiation exposure are not appropriate (CT and nuclear medicine).
- When a specific malignancy is suspected, the individual should be imaged according to the eviCore imaging guideline specific to the suspected cancer type
- Annual complete detailed physical examinations, complete blood counts, and urinalyses form the backbone of LFS cancer screening.

Neurofibromatosis 1 and 2 (NF1 and NF2) (PEDONC-2.3)

ONCP.SC.0002.3.A

v2.0.2024

The following imaging studies should be considered appropriate in individuals with NF1:

Indication	Imaging Study
<ul style="list-style-type: none"> Clarification of the diagnosis of NF1 if evaluation by a physician with significant training and/or experience in neurofibromatosis is inconclusive <ul style="list-style-type: none"> Most commonly a neurologist, geneticist, ophthalmologist, or oncologist 	<ul style="list-style-type: none"> One-time MRI Brain (CPT® 70553) and Orbits (CPT® 70543) without and with contrast
<ul style="list-style-type: none"> New or worsening neurological or visual symptoms 	<ul style="list-style-type: none"> MRI Brain (CPT® 70553) and Orbits (CPT® 70543) without and with contrast
<ul style="list-style-type: none"> Clinical symptoms suggestive of change in a known plexiform neurofibroma <ul style="list-style-type: none"> Examples include: pain, rapid growth, and neurologic dysfunction 	<ul style="list-style-type: none"> MRI without and with contrast
<ul style="list-style-type: none"> <u>Clinical symptoms concerning for malignant transformation of a known plexiform neurofibroma, and ALL of the following are met:</u> <ul style="list-style-type: none"> Recent MRI is inconclusive regarding transformation or progression Negative PET will result in a decision to avoid biopsy in a difficult or morbid location 	<ul style="list-style-type: none"> PET/CT (CPT® 78815 or 78816)
<ul style="list-style-type: none"> Baseline tumor burden at age 16 or older (one-time imaging) 	<ul style="list-style-type: none"> WBMBRI (CPT® 76498)

Indication	Imaging Study
<ul style="list-style-type: none"> New soft tissue mass(es) 	<ul style="list-style-type: none"> See: <u>Soft Tissue Mass (MS 10.1)</u> in the Musculoskeletal Imaging Guidelines or <u>Soft Tissue and Bone Masses – General Considerations (PEDMS 3.1)</u> in the Pediatric Musculoskeletal Imaging Guidelines depending on the individual’s age at the time the mass is discovered. Plain x-ray or ultrasound is not required prior to advanced imaging in these individuals.
<ul style="list-style-type: none"> New bone mass(es) 	<ul style="list-style-type: none"> See: <u>Bone Tumors - General Considerations (PEDONC-9.1)</u>
<ul style="list-style-type: none"> Documented optic pathway gliomas 	<ul style="list-style-type: none"> See: <u>Intracranial Low Grade Gliomas (PEDONC-4.2)</u>
<ul style="list-style-type: none"> Known plexiform neurofibromas 	<ul style="list-style-type: none"> MRI without and with contrast of a known body area containing a neurofibroma is indicated for any of the following: <ul style="list-style-type: none"> Every 3 months for treatment response in individuals receiving active treatment New or worsening clinical symptoms suggesting progression Preoperative planning
<ul style="list-style-type: none"> Biopsy-proven MPNST in individuals with known NF-1 or NF-2 	<ul style="list-style-type: none"> See: <u>Non-Rhabdomyosarcoma Soft Tissue Sarcomas (NRSTS) (PEDONC-8.3)</u>

Background and Supporting Information

NF1:

- Common syndrome inherited in an autosomal dominant manner (50% risk to offspring) affecting 1 in 2500 people. The diagnosis is commonly made based on established clinical criteria including café-au-lait spots, lisch nodules of the iris, axillary freckling, family history, and the presence of NF-associated tumors.
- Genetic testing is encouraged for children with possible NF1 and no family history prior to assigning a diagnosis, but will not identify a mutation for all individuals with NF1.
- The majority of tumors are benign in nature, but malignant degeneration can occur.

- NF1-affected persons have increased sensitivity to ionizing radiation, so CT and nuclear medicine imaging are not appropriate screening or surveillance studies for these individuals.
- CT and/or nuclear medicine studies may be indicated for acute clinical situations and should be judged on a case-by-case basis.
- Annual ophthalmology evaluation is strongly recommended beginning at the time of diagnosis of NF1 to evaluate for optic pathway abnormalities:
 - Screening MRIs Brain (CPT® 70553) and Orbits (CPT® 70543) for asymptomatic individuals are **not** generally recommended due to the ~60% rate of unidentified bright objects (UBOs, T2-weighted signal abnormalities) which mostly disappear by age 30
 - Routine follow up imaging of UBOs is not warranted in the absence of acute symptoms suggesting new or worsening intracranial disease
- Individuals with NF1 are at increased risk for plexiform neurofibromas (PN) and malignant peripheral nerve sheath tumors (MPNST— a high grade sarcoma)
 - Screening imaging of asymptomatic individuals for these tumors is not supported by evidence. PET imaging is not supported for PN surveillance in asymptomatic individuals at this time as the positive predictive value is only 60% to 65% even in symptomatic individuals.
- Although PET imaging has a positive predictive value of only 61% to 63% in NF1 with suspected transformation to MPNST, the negative predictive value is high (96% to 99%)
 - Considerations for PET/CT coding and indications/coding for PET/MRI are found in **PET Imaging in Pediatric Oncology (PEDONC-1.4)**
 - Inconclusive PET findings should lead to biopsy of the concerning lesion
 - Repeat PET studies are not indicated due to the poor positive predictive value in this setting
- 2017 AACR recommendations support a single baseline Whole-Body MRI to assess tumor burden in late adolescence or young adulthood. Further imaging should be based on focused MRI for symptomatic changes or pre-operative planning, and further surveillance WBMRI are not supported.

The following imaging studies should be considered appropriate in individuals with NF2:

Indication	Imaging Study
<ul style="list-style-type: none"> • All individuals, beginning at age 10 years 	<ul style="list-style-type: none"> • Annual MRI Brain without and with contrast (CPT® 70553)
<ul style="list-style-type: none"> • All individuals without a history of spinal tumors, beginning at age 10 years 	<ul style="list-style-type: none"> • MRI Spine without and with contrast (Cervical-CPT® 72156, Thoracic-CPT® 72157, Lumbar-CPT® 72158) every 3 years

Indication	Imaging Study
<ul style="list-style-type: none"> All individuals with a history of spinal tumors 	<ul style="list-style-type: none"> Annual MRI Spine without and with contrast (Cervical-CPT® 72156, Thoracic-CPT® 72157, Lumbar-CPT® 72158)
<ul style="list-style-type: none"> Clinical symptoms of intracranial mass or vestibular disease 	<ul style="list-style-type: none"> MRI Brain without and with contrast (CPT® 70553)
<ul style="list-style-type: none"> <u>Any of the following:</u> <ul style="list-style-type: none"> Clinical symptoms suggestive of new or progressive spinal or paraspinal tumors, including uncomplicated back pain or radiculopathy Recent diagnosis with a meningioma or vestibular schwannoma 	<ul style="list-style-type: none"> MRI Spine without and with contrast (Cervical-CPT® 72156, Thoracic-CPT® 72157, Lumbar-CPT® 72158)
<ul style="list-style-type: none"> Surveillance for progression of unresected tumors in individuals with known vestibular schwannoma 	<ul style="list-style-type: none"> Annual MRI Brain without and with contrast (CPT® 70553)
<ul style="list-style-type: none"> <u>Known vestibular schwannomas and any of the following:</u> <ul style="list-style-type: none"> New or worsening clinical symptoms including hearing loss Preoperative planning 	<ul style="list-style-type: none"> MRI Brain without and with contrast (CPT® 70553)
<ul style="list-style-type: none"> Known meningioma 	<ul style="list-style-type: none"> See: Meningiomas (ONC-2.8) in the Oncology Imaging Guidelines
<ul style="list-style-type: none"> Known ependymoma 	<ul style="list-style-type: none"> See: Ependymoma (PEDONC-4.8)

Background and Supporting Information

NF2:

- NF2 is substantially less common than NF1. It is inherited in an autosomal dominant manner (50% risk to offspring) affecting ~1 in 25000 people. NF2 is associated with increased risk for meningiomas (50% of affected individuals), vestibular schwannomas, and spinal tumors (75% of affected individuals).

Beckwith-Wiedemann Syndrome (BWS) (PEDONC-2.4)

ONCP.SC.0002.4.A

v2.0.2024

The following imaging studies should be considered appropriate in individuals with BWS:

Indication	Imaging Study
<ul style="list-style-type: none"> All individuals, from birth to the 8th birthday 	<ul style="list-style-type: none"> Abdominal ultrasound (CPT® 76700) every 3 months
<ul style="list-style-type: none"> Purely cystic adrenal mass found on screening ultrasound 	<ul style="list-style-type: none"> Continue screening ultrasound (CPT® 76700 or 76705) every 3 months without additional imaging (i.e. advanced imaging is not supported for a purely cystic adrenal mass)
<ul style="list-style-type: none"> <u>Solid or mixed adrenal mass found on screening ultrasound AND:</u> <ul style="list-style-type: none"> Individual age 0 to 5 months, and Mass 0 to 3 cm in diameter 	<ul style="list-style-type: none"> MIBG imaging (See: PEDONC-1.3 for coding) and either CT or MRI Abdomen (contrast as requested)
<ul style="list-style-type: none"> <u>Solid or mixed adrenal mass found on screening ultrasound AND:</u> <ul style="list-style-type: none"> Individual age 0 to 5 months, and Mass > 3 cm in diameter 	<ul style="list-style-type: none"> MIBG imaging (See: PEDONC-1.3 for coding) and MRI Abdomen (contrast as requested)
<ul style="list-style-type: none"> <u>Solid or mixed adrenal masses on screening ultrasound AND:</u> <ul style="list-style-type: none"> Individual age 6 months or greater 	<ul style="list-style-type: none"> MIBG imaging (See: PEDONC-1.3 for coding) prior to biopsy or resection <ul style="list-style-type: none"> If no evidence of malignancy on biopsy or resection, resume screening abdominal ultrasound every 3 months
<ul style="list-style-type: none"> <u>Solid or mixed adrenal masses on screening ultrasound AND:</u> <ul style="list-style-type: none"> No evidence of malignancy based on MIBG, CT or MRI, Urine HVA/VMA, and serum ACTH 	<ul style="list-style-type: none"> Repeat abdominal ultrasound (CPT® 76700 or 76705) every 6 weeks for 2 years
<ul style="list-style-type: none"> Known renal tumors 	<ul style="list-style-type: none"> See: <u>Pediatric Renal Tumors (PEDONC-7)</u>

Indication	Imaging Study
• Known hepatoblastoma	• See: <u>Hepatoblastoma (PEDONC-11.2)</u>
• Known neuroblastoma	• See: <u>Neuroblastoma (PEDONC-6)</u>
• Known adrenocortical carcinoma	• See: <u>Pediatric Adrenocortical Carcinoma (PEDONC-14)</u>
• Known pheochromocytoma	• See: <u>Neuroendocrine Cancers and Adrenal Tumors (ONC-15)</u> in the Oncology Imaging Guidelines

Background and Supporting Information

- Inherited syndrome characterized by macroglossia, hemihypertrophy, macrosomia, organomegaly, and neonatal hypoglycemia. Individuals with isolated hemihypertrophy are also imaged according to this guideline.
- Caused by mutation at chromosome 11p15, affected children are predisposed to Wilms tumor, hepatoblastoma, rhabdomyosarcoma, and adrenal tumors.

Denys-Drash Syndrome (DDS) (PEDONC-2.5)

ONCP.SC.0002.5.A

v2.0.2024

The following imaging studies should be considered appropriate in individuals with DDS:

Indication	Imaging Study
<ul style="list-style-type: none">All individuals, from birth to the 8th birthday	<ul style="list-style-type: none">Abdominal ultrasound (CPT® 76700) every 3 months
<ul style="list-style-type: none">Known renal tumors	<ul style="list-style-type: none">See: <u>Pediatric Renal Tumors (PEDONC-7)</u>

Background and Supporting Information

- Characterized by pseudohermaphroditism, early renal failure, and >90% risk of Wilms tumor development in each kidney. Associated with mutations at 11p13, risk of renal failure after detection of symptomatic Wilms tumor is 62%, so early detection may allow for renal-sparing surgical approaches.

Wilms Tumor-Aniridia-Growth Retardation (WAGR) (PEDONC-2.6)

ONCP.SC.0002.6.A

v2.0.2024

The following imaging studies should be considered appropriate in individuals with WAGR:

Indication	Imaging Study
<ul style="list-style-type: none">All individuals, from birth to the 8th birthday	<ul style="list-style-type: none">Abdominal ultrasound (CPT® 76700) every 3 months
<ul style="list-style-type: none">Known renal tumors	<ul style="list-style-type: none">See: <u>Pediatric Renal Tumors (PEDONC-7)</u>

Background and Supporting Information

- Named for the components of the disorder, it is associated with mutations at 11p13. As the name suggests, individuals are predisposed to Wilms tumor, with 57% of individuals in one cohort developing Wilms tumor. Risk of renal failure after detection of symptomatic Wilms tumor is 38%, so early detection may allow for renal-sparing surgical approaches

Familial Adenomatous Polyposis (FAP) and Related Conditions (PEDONC-2.7)

ONCP.SC.0002.7.A

v2.0.2024

- Individuals with Lynch, Gardner, and Turcot syndromes should also be imaged according to these guidelines.

The following imaging studies should be considered appropriate in individuals with FAP and related conditions:

- For colonoscopy and endoscopy guidance for those with FAP and related conditions, See: **EGD-1.16**, **CAPEND-5**, or **COLON-17: Genetic Syndromes** for the endoscopic management of polyposis syndromes.

Indication	Imaging Study
<ul style="list-style-type: none"> • All individuals, from birth to the 6th birthday 	<ul style="list-style-type: none"> • Abdominal ultrasound (CPT® 76700) every 3 months
<ul style="list-style-type: none"> • All individuals, beginning at age 12 years 	<ul style="list-style-type: none"> • Annual thyroid ultrasound (CPT® 76536)
<ul style="list-style-type: none"> • All individuals, beginning at age 30 years 	<ul style="list-style-type: none"> • Annual pelvic ultrasound (CPT® 76856)
<ul style="list-style-type: none"> • Family history of desmoid tumors 	<ul style="list-style-type: none"> • Abdominal ultrasound (CPT® 76700) annually for life after age 6
<ul style="list-style-type: none"> • Individuals with Spigelman Stage III or IV or if duodenectomy is being planned • See: <u>Genetic Syndromes (EGD-1.16)</u> for additional information regarding Spigelman staging. 	<ul style="list-style-type: none"> • MR Enterography (MRI Abdomen without and with contrast, CPT® 74183 and MRI Pelvis without and with contrast, CPT® 72197)
<ul style="list-style-type: none"> • Known colorectal tumors 	<ul style="list-style-type: none"> • See: <u>Colorectal Cancer (ONC-16)</u> in the Oncology Imaging Guidelines
<ul style="list-style-type: none"> • Known desmoid tumors 	<ul style="list-style-type: none"> • See: <u>Non-Rhabdomyosarcoma Soft Tissue Sarcomas (NRSTS) (PEDONC-8.3)</u>

Background and Supporting Information

- Inherited in an autosomal dominant manner (50% risk to offspring), it is also known as Adenomatous Polyposis Coli (APC). It is associated with the development of thousands of colonic polyps by age 20 and >90% risk of colorectal carcinoma. Prophylactic total colectomy is recommended by age 20 for most individuals. FAP is also associated with hepatoblastoma, tumors of the pancreas and small bowel, medulloblastoma, and thyroid cancer.

Multiple Endocrine Neoplasias (MEN) (PEDONC-2.8)

ONCP.SC.0002.8.A

v2.0.2024

The following imaging studies should be considered appropriate in individuals with MEN1:

Indication	Imaging Study
All individuals, beginning at age 5 years	<ul style="list-style-type: none"> Annual MRI Brain without and with contrast (CPT® 70553) Annual MRI Abdomen without and with contrast (CPT® 74183), CT Abdomen with contrast (CPT® 74160), or ultrasound (CPT® 76700) Annual Octreotide study (see: PEDONC-1.3 for coding)
All individuals, beginning at age 15 years	<ul style="list-style-type: none"> Annual MRI Chest without and with contrast (CPT® 71552) or CT Chest with contrast (CPT® 71260)
Known thyroid cancer	<ul style="list-style-type: none"> See: Thyroid Cancer (ONC-6) in the Oncology Imaging Guidelines
Known pheochromocytoma	<ul style="list-style-type: none"> See: Neuroendocrine Cancers and Adrenal Tumors (ONC-15) in the Oncology Imaging Guidelines

The following imaging studies should be considered appropriate in individuals with MEN2a and MEN2b:

Indication	Imaging Study
All individuals, beginning at age 5 years	<ul style="list-style-type: none"> MRI Abdomen without and with contrast (CPT® 74183) can be approved every 3 years
<ul style="list-style-type: none"> One of the following: <ul style="list-style-type: none"> Elevated catecholamines Inconclusive adrenal mass on MRI 	<ul style="list-style-type: none"> ONE of the following: <ul style="list-style-type: none"> Octreotide study (see: PEDONC-1.3 for coding) Adrenal Nuclear Imaging (CPT® 78075)
<ul style="list-style-type: none"> Known pheochromocytoma 	<ul style="list-style-type: none"> See: Neuroendocrine Cancers and Adrenal Tumors (ONC-15)

Background and Supporting Information

- Inherited in an autosomal dominant manner (50% risk to offspring)
- MEN1 is characterized by parathyroid, pancreatic islet cell, and pituitary gland tumors (3 P's), as well as carcinoid tumors in the chest and abdomen, and 28% of individuals will develop at least one tumor by age 15.
- MEN2a is characterized by medullary thyroid carcinoma, parathyroid adenomas, and pheochromocytomas.
- MEN2b is characterized by ganglioneuromas of the GI tract and skeletal abnormalities presenting in infancy.
- Recommended cancer screening includes:
 - Individuals with MEN2a and MEN2b receive annual measurement of catecholamines for pheochromocytoma screening

Tuberous Sclerosis Complex (TSC) (PEDONC-2.9)

ONCP.SC.0002.9.A

v2.0.2024

- Abdominal MRI (CPT® 74183) may be approved for women of childbearing age planning pregnancy.

The following imaging studies should be considered appropriate in individuals with TSC:

Indication	Imaging Study
<ul style="list-style-type: none"> All individuals, at the time of suspected diagnosis until age 25 years 	<ul style="list-style-type: none"> Annual Brain MRI without and with contrast (CPT® 70553)
<ul style="list-style-type: none"> All individuals at diagnosis 	<ul style="list-style-type: none"> Single baseline MRI Abdomen without and with contrast (CPT® 74183)
<ul style="list-style-type: none"> If no renal lesions seen on baseline MRI Abdomen 	<ul style="list-style-type: none"> From diagnosis through age 11: <ul style="list-style-type: none"> Annual Renal US (CPT® 76770) Age 12 (or 10 years earlier than the youngest family member with renal cell carcinoma, whichever comes earlier): <ul style="list-style-type: none"> MRI Abdomen without and with contrast (CPT® 74183) every 3 years in lieu of ultrasound
<ul style="list-style-type: none"> For documented renal lesions on baseline MRI Abdomen or any ultrasound 	<ul style="list-style-type: none"> MRI Abdomen without and with contrast (CPT® 74183) annually
<ul style="list-style-type: none"> All individuals, beginning at age 18 years 	<ul style="list-style-type: none"> CT Chest without contrast (CPT® 71250) every 5 years
<ul style="list-style-type: none"> All individuals, for cardiac screening or follow up of known cardiac disease 	<ul style="list-style-type: none"> See: <u>Initial Transthoracic Echocardiography (TTE) Indications (PEDCD-8.2)</u> and <u>Repeat Transthoracic Echocardiography Indications (PEDCD-8.3)</u> in the Pediatric Cardiology Imaging Guidelines
<ul style="list-style-type: none"> Individuals with documented abnormalities on baseline CT Chest 	<ul style="list-style-type: none"> Additional CT Chest without contrast or with contrast (CPT® 71250 or 71260) may be approved every 1 year

Indication	Imaging Study
<ul style="list-style-type: none"> • Any of the following: <ul style="list-style-type: none"> • New pulmonary symptoms • Worsening pulmonary function testing 	<ul style="list-style-type: none"> • CT Chest without contrast (CPT® 71250)
<ul style="list-style-type: none"> • Known SEGA tumors 	<ul style="list-style-type: none"> • See: <u>Intracranial Low Grade Gliomas (LGG) (PEDONC-4.2)</u>
<ul style="list-style-type: none"> • Known renal cell carcinoma 	<ul style="list-style-type: none"> • See: <u>Pediatric Renal Cell Carcinoma (RCC) (PEDONC-7.4)</u>

Background and Supporting Information

- Inherited in an autosomal dominant manner (50% risk to offspring), affecting ~1 in 6000 individuals, it is associated with benign tumors, hypopigmented skin macules (ash leaf spots), developmental delay, and epilepsy.
- Malignancies associated with this syndrome include:
 - Subependymal giant cell astrocytomas (SEGA tumors)
 - Historically, early surgery was important to reduce morbidity related to these tumors
 - More recently, everolimus has been successfully used to treat these tumors without surgery, and early detection remains an important feature for success
 - Renal cell carcinoma
 - Cardiac rhabdomyosarcoma
 - Pulmonary lymphangiomyomatosis
- Recommended cancer screening includes:
 - Ophthalmologic and dermatologic evaluation annually

Von Hippel-Lindau Syndrome (VHL) (PEDONC-2.10)

ONCP.SC.0002.10.A

v2.0.2024

The following imaging studies should be considered appropriate in individuals with VHL:

Indication	Imaging Study
<ul style="list-style-type: none"> All individuals, beginning at age 11 years 	<ul style="list-style-type: none"> MRI Brain without and with contrast (CPT® 70553) and MRI Spine without and with contrast (Cervical-CPT® 72156), Thoracic-CPT® 72157, and Lumbar-CPT® 72158) every 2 years
<ul style="list-style-type: none"> Individuals with frequent ear infections, prior to age 8 	<ul style="list-style-type: none"> One-time MRI Brain without and with contrast (CPT® 70553)
<ul style="list-style-type: none"> All individuals, beginning at age 5 years 	<ul style="list-style-type: none"> Annual Abdominal US (CPT® 76700)
<ul style="list-style-type: none"> All individuals, beginning at age 15 years 	<ul style="list-style-type: none"> MRI Abdomen without and with contrast (CPT® 74183) every 2 years
<ul style="list-style-type: none"> <u>ONE of the following:</u> <ul style="list-style-type: none"> Elevated catecholamines Inconclusive adrenal mass on MRI 	<ul style="list-style-type: none"> Octreotide study (CPT® 78800, CPT® 78801, CPT® 78802, CPT® 78803, or CPT® 78804) or Adrenal Nuclear imaging (CPT® 78075)
<ul style="list-style-type: none"> Individuals with known hemangioblastoma anywhere in the body (based on imaging) that has not been resected 	<ul style="list-style-type: none"> <u>Both of the following, every 1 year:</u> <ul style="list-style-type: none"> MRI Brain without and with contrast (CPT® 70553) MRI Spine without and with contrast (Cervical-CPT® 72156), Thoracic-CPT® 72157, and Lumbar-CPT® 72158)
<ul style="list-style-type: none"> Known hemangioblastoma that has not been resected and new or worsening symptoms 	<ul style="list-style-type: none"> MRI Brain without and with contrast (CPT® 70553) MRI Spine without and with contrast (Cervical-CPT® 72156), Thoracic-CPT® 72157, and Lumbar-CPT® 72158)
<ul style="list-style-type: none"> Known (based on imaging) CNS hemangioblastoma 	<ul style="list-style-type: none"> See: <u>Intracranial Low Grade Gliomas (LGG) (PEDONC-4.2)</u>
<ul style="list-style-type: none"> Known renal cell carcinoma 	<ul style="list-style-type: none"> See: <u>Pediatric Renal Cell Carcinoma (RCC) (PEDONC-7.4)</u>

Indication	Imaging Study
<ul style="list-style-type: none">Known pheochromocytoma or other neuroendocrine tumor	<ul style="list-style-type: none">See: <u>Neuroendocrine Cancers And Adrenal Tumors (ONC-15)</u> in the Oncology Imaging Guidelines

Background and Supporting Information

- Inherited in an autosomal dominant manner (50% risk to offspring), it is associated with CNS hemangioblastomas, retinal angiomas, endolymphatic sac tumors (ELST), gastrointestinal stromal tumor (GIST), renal cell carcinoma (RCC), and pheochromocytomas and other neuroendocrine tumors (NETs). Pediatric individuals are at risk of developing hemangioblastomas and pheochromocytomas that can remain clinically occult until symptoms become severe. Historically, substantial mortality was attributable to RCC, pancreatic NET, and CNS hemangioblastoma.
- Recommended cancer screening includes:
 - Annual ophthalmologic evaluation beginning at birth
 - Annual measurement of catecholamines beginning at age 2
 - Audiology assessment every 2 years beginning at age 5

Rhabdoid Tumor Predisposition Syndrome (PEDONC-2.11)

ONCP.SC.0002.11.A

v2.0.2024

The following imaging studies should be considered appropriate in individuals with Rhabdoid Tumor Predisposition Syndrome:

Indication	Imaging Study
<ul style="list-style-type: none"> All individuals, at diagnosis, as early as birth if requested 	<ul style="list-style-type: none"> Whole-body MRI (WBMRI) (CPT® 76498)
<ul style="list-style-type: none"> All individuals, from birth to 6 months of age 	<ul style="list-style-type: none"> <u>ALL of the following, monthly:</u> <ul style="list-style-type: none"> US Head (CPT® 76506) US Abdomen (CPT® 76700) US Pelvis (CPT® 76856) US Neck (CPT® 76536) MRI with and without contrast of areas of concern found on baseline WBMRI
<ul style="list-style-type: none"> All individuals, from age 7 months to 5 years 	<ul style="list-style-type: none"> <u>ALL of the following, every 3 months:</u> <ul style="list-style-type: none"> US Abdomen (CPT® 76700) US Pelvis (CPT® 76856) US Neck (CPT® 76536) MRI Brain (CPT® 70553) MRI Spine (CPT® 72156, CPT® 72157, and CPT® 72158) without and with contrast MRI with and without contrast of areas of concern found on baseline WBMRI
<ul style="list-style-type: none"> All individuals, after age 5 years 	<ul style="list-style-type: none"> Annual WBMRI (CPT® 76498)
<ul style="list-style-type: none"> Clinical symptoms or WBMRI findings suggesting malignancy 	<ul style="list-style-type: none"> Targeted advanced imaging of the suspected disease site (CT with or without contrast, or MRI without and with contrast)
<ul style="list-style-type: none"> Inconclusive findings on ultrasound 	<ul style="list-style-type: none"> MRI with and without contrast of the inconclusive US site <ul style="list-style-type: none"> MRI should be used in place of ultrasound for remainder of planned screening

Background and Supporting Information

- Inherited in an autosomal dominant manner (50% risk to offspring), it is associated with malignant rhabdoid tumors of the kidney and extrarenal locations, and atypical teratoid/rhabdoid tumors (ATRT) of the CNS. It is caused by a germline mutation in *INI1* or *SMARCB1*, and is associated with a more variable prognosis than de novo rhabdoid tumors.

Familial Retinoblastoma Syndrome (PEDONC-2.12)

ONCP.SC.0002.12.A

v2.0.2024

- Regular physical and ophthalmologic evaluations under anesthesia (EUA) are the hallmark of surveillance strategies for these individuals, and asymptomatic screening imaging does not have a defined role at this time.

The following imaging studies should be considered appropriate in individuals with Familial Retinoblastoma Syndrome:

Indication	Imaging Study
<ul style="list-style-type: none">• Individuals with retinomas (pre-malignant retinal lesions)	<ul style="list-style-type: none">• Annual MRI Orbits (CPT® 70543)
<ul style="list-style-type: none">• Either of the following:<ul style="list-style-type: none">• Inconclusive EUA findings• New symptoms	<ul style="list-style-type: none">• US Orbits (CPT® 76512, 76510, or 76511) or MRI Orbits (CPT® 70543)<ul style="list-style-type: none">• These studies should be used if at all possible in lieu of CT or nuclear imaging to avoid radiation exposure

Background and Supporting Information

- This syndrome is inherited in an autosomal dominant manner (50% risk to offspring). As the name suggests, it is associated with retinoblastoma, as well as osteosarcoma, pediatric melanoma, and a significantly increased risk for radiation-related malignancies.

Hereditary Paraganglioma-Pheochromocytoma (HPP) Syndromes (PEDONC-2.13)

ONCP.SC.0002.13.A
v2.0.2024

The following imaging studies should be considered appropriate in individuals with HPP Syndromes:

Indication	Imaging Study
<ul style="list-style-type: none"> All individuals with SDHx, MAX, TMEM127 mutations, beginning at age 6 	<ul style="list-style-type: none"> Every 2 years, ONE of the following sets of imaging: <ul style="list-style-type: none"> Whole-body MRI (CPT® 76498) <ul style="list-style-type: none"> CPT® 76498 is the only approvable code for whole-body MRI at this time OR MRI Neck without and with contrast (CPT® 70543), MRI Chest without and with contrast (CPT® 71552), MRI Abdomen without and with contrast (CPT® 74183), and MRI Pelvis without and with contrast (CPT® 72197) <ul style="list-style-type: none"> If MRI cannot be performed: CT Neck with contrast (CPT® 70491), CT Chest with contrast (CPT® 71260), and CT Abdomen and Pelvis with contrast (CPT® 74177) MRI Neck imaging should include skull base, thus separate MRI Brain (CPT® 70553) is not routinely supported, but may be approved if there are CNS specific symptoms.
<ul style="list-style-type: none"> Initial screening for individuals diagnosed at age 18 or older 	<ul style="list-style-type: none"> One-time PET/CT (CPT® 78815 or 78816)
<ul style="list-style-type: none"> Known pheochromocytoma or other neuroendocrine tumors 	<ul style="list-style-type: none"> See: <u>Neuroendocrine Cancers and Adrenal Tumors (ONC-15)</u> in the Oncology Imaging Guidelines

Background and Supporting Information

- Caused by mutations in *SDHx* and related genes, this syndrome is inherited in an autosomal dominant manner (50% risk to offspring), and is associated with pheochromocytomas and paragangliomas.

- Individuals with multiple endocrine neoplasias should not use this guideline and should be imaged according to **Multiple Endocrine Neoplasias (MEN) (PEDONC-2.8)**.
- MRI is preferred to CT to minimize radiation exposure given these individuals' lifelong need for screening
- All individuals with HPP receive annual measurement of catecholamines

Costello Syndrome (PEDONC-2.14)

ONCP.SC.0002.14.A
v2.0.2024

The following imaging studies should be considered appropriate in individuals with Costello Syndrome:

Indication	Imaging Study
<ul style="list-style-type: none"> Following confirmation of gene mutation 	<ul style="list-style-type: none"> <u>ANY or ALL of the following:</u> <ul style="list-style-type: none"> Echocardiogram <ul style="list-style-type: none"> CPT® 93306 or CPT® 93308 with 93321 and 93325 MRI Brain (CPT® 70553) without and with contrast MRI Cervical (CPT® 72156) and Thoracic Spine (CPT® 72157) without and with contrast
<ul style="list-style-type: none"> All individuals, from birth to 10th birthday 	<ul style="list-style-type: none"> <u>Every 3 months:</u> <ul style="list-style-type: none"> US Abdomen (CPT® 76700) and Pelvis (CPT® 76856)
<ul style="list-style-type: none"> Known cardiac disease 	<ul style="list-style-type: none"> See: <u>Initial Transthoracic Echocardiography (TTE) Indications (PEDCD-8.2)</u> and <u>Repeat Transthoracic Echocardiography Indications (PEDCD-8.3)</u> in the Pediatric Cardiology Guidelines
<ul style="list-style-type: none"> Known rhabdomyosarcoma 	<ul style="list-style-type: none"> See: <u>Rhabdomyosarcoma (RMS) (PEDONC-8.2)</u>
<ul style="list-style-type: none"> Known neuroblastoma 	<ul style="list-style-type: none"> See: <u>Neuroblastoma (PEDONC-6)</u>

Background and Supporting Information

- Caused by mutations in *HRAS* genes, this syndrome is inherited in an autosomal dominant manner (50% risk to offspring), and is associated with rhabdomyosarcoma and neuroblastoma in early childhood, and transitional cell cancer of the bladder in older children and adults.

Constitutional Mismatch Repair Deficiency (CMMRD or Turcot Syndrome) (PEDONC-2.15)

ONCP.SC.0002.15.A
v2.0.2024

The following imaging studies should be considered appropriate in individuals with CMMRD/Turcot Syndrome:

Indication	Imaging Study
<ul style="list-style-type: none">All individuals, after CMMRD diagnosis is confirmed by genetic mutation	<ul style="list-style-type: none">MRI Brain without and with contrast (CPT® 70553) every 6 months
<ul style="list-style-type: none">All individuals, beginning at age 4 years	<ul style="list-style-type: none">Annual esophagogastroduodenoscopy and colonoscopy
<ul style="list-style-type: none">All individuals, beginning at age 6 years	<ul style="list-style-type: none">Annual whole-body MRI (CPT® 76498)<ul style="list-style-type: none">76498 is the only approvable code for whole-body MRI at this time

Background and Supporting Information

- A highly penetrant and aggressive cancer predisposing syndrome resulting from autosomal recessive inheritance of biallelic mutations in mismatch repair genes, CMMRD syndrome leads to substantial risk for several commonly fatal childhood malignancies - high-grade CNS tumors (glioma, PNET, medulloblastoma) and hematologic malignancies (non-Hodgkin lymphoma, acute lymphoblastic leukemia). Individuals with CMMRD are also at increased risk for gastrointestinal tumors.

Hereditary Leiomyomatosis and Renal Cell Cancer (HLRCC) (PEDONC-2.16)

ONCP.SC.0002.16.A

v2.0.2024

The following imaging studies should be considered appropriate in individuals with HLRCC:

Indication	Imaging Study
<ul style="list-style-type: none"> • Beginning at age 8 years, individuals with at least ONE of the following: <ul style="list-style-type: none"> • Documented fumarate hydratase (FH) gene mutation/variant consistent with HLRCC • Histologically confirmed multiple cutaneous piloleiomyomas • At least TWO of the following manifestations: <ul style="list-style-type: none"> • Surgical treatment for symptomatic uterine leiomyomas before age 40 • Type 2 papillary renal cell carcinoma or collecting duct renal carcinoma before age 40 • A first-degree family member with either of the two above criteria 	<ul style="list-style-type: none"> • MRI Abdomen with and without contrast (CPT® 74183), annually

Background and Supporting Information

- Hereditary leiomyomatosis and renal cell cancer (HLRCC) is a disorder in which affected individuals tend to develop benign tumors containing smooth muscle tissue (leiomyomas) in the skin and, in females, the uterus. Approximately 20 percent of people with HLRCC develop renal cell cancer. People with HLRCC are commonly diagnosed with kidney cancer in their forties but cases have been reported in individuals as young as 11.
- In 2019, Forde et. al. published the first large, prospective study of screening for HLRCC and showed that most symptomatic individuals present with stage 3 or 4 RCC with a high risk of death and one life is saved for every 5 individuals on an MRI screening protocol.

Other Renal Cell Cancer Predisposition Syndromes (PEDONC- 2.17)

ONCP.SC.0002.17.A
v2.0.2024

Birt-Hogg-Dube Syndrome (BHDS)

The following imaging studies should be considered appropriate in individuals with BHDS:

Indication	Imaging Study
<ul style="list-style-type: none"> All individuals, beginning at age 20 years 	<ul style="list-style-type: none"> Abdominal MRI with and without contrast (CPT® 74183) every 3 years

Background and Supporting Information

- Birt-Hogg-Dube Syndrome (BHDS) is an autosomal dominant disorder with a heterozygous pathogenic variant in FLCN gene.
- These individuals have, or may have:
 - Cutaneous manifestations (fibrofolliculomas, acrochordons, angiofibromas, oral papules, cutaneous collagenomas, and epidermal cysts)
 - Pulmonary cysts/history of pneumothorax
 - A seven-fold increase in renal tumors
 - The most common renal tumors are oncocytoma, chromophobe, and a hybrid of these two.
 - Renal tumors may be multifocal and bilateral.
 - Median age of renal tumor diagnosis is 48 years.
- Recommended cancer screening includes:
 - Screening colonoscopy starting at age 40
 - Earlier colonoscopy may be considered for those with a family history of colorectal cancer earlier than age 40.

BAP1 Tumor Predisposition Syndrome

The following imaging studies should be considered appropriate in individuals with BAP1:

Indication	Imaging Study
<ul style="list-style-type: none"> All individuals, beginning at age 30 years 	<ul style="list-style-type: none"> Abdominal MRI with and without contrast (CPT® 74183) every 2 years

Background and Supporting Information

BAP1 tumor predisposition syndrome (TPDS) is an autosomal dominant condition with a predisposition to melanoma (ocular and cutaneous), mesothelioma, clear cell renal cancer, and chromophobe renal cancer.

Hereditary Papillary Renal Carcinoma (HPRC)

The following imaging studies should be considered appropriate in individuals with HPRC:

Indication	Imaging Study
<ul style="list-style-type: none"> All individuals, beginning at age 30 years 	<ul style="list-style-type: none"> Abdominal MRI with and without contrast (CPT® 74183) every 2 years

Background and Supporting Information

- Hereditary papillary renal carcinoma (HPRC) is an autosomal dominant condition involving the MET gene and predisposes individuals to multifocal, bilateral renal tumors.

DICER1

The following imaging studies should be considered appropriate in individuals with DICER1:

Indication	Imaging Study
<ul style="list-style-type: none"> DICER1 mutation asymptomatic lung surveillance 	<ul style="list-style-type: none"> Once at age 3-6 months of age and again at 2.5-3 years of age: <ul style="list-style-type: none"> CT Chest (contrast as requested) In addition, chest x-ray at birth and every 6 months until 8 years of age and annually until age 12
<ul style="list-style-type: none"> DICER1 mutation asymptomatic abdominal and pelvic surveillance 	<ul style="list-style-type: none"> Every 3 months, from birth to the 8th birthday, then every 12 months until 12 years of age: <ul style="list-style-type: none"> Abdominal US (CPT® 76700) After age 12, females with DICER1 mutation may continue abdominal and pelvic ultrasounds (CPT® 76700 and CPT® 76856 or CPT® 76857) annually until age 40
<ul style="list-style-type: none"> DICER1 mutation thyroid surveillance 	<ul style="list-style-type: none"> Baseline thyroid US (CPT® 76536) by 8 years of age then every 3 years

Indication	Imaging Study
<ul style="list-style-type: none"> Individuals with DICER1 mutation and new CNS symptoms 	<ul style="list-style-type: none"> MRI Brain without and with contrast (CPT® 70553)

Other Renal Predisposition Syndromes

The following imaging studies should be considered appropriate in individuals with other renal predisposition syndromes:

Indication	Imaging Study
<ul style="list-style-type: none"> Individuals with <u>any of the following genetic variants or syndromes:</u> <ul style="list-style-type: none"> REST, TRIM28, FBXW7, NYNRIN, KDM3B, XPO5, CHECK2, PALB2, CTNNB1, DROSHA, WT1 and 2, WTX, DGCR8, SIC1 and 2, BCORL1, MLLT1, MYCN Bloom Syndrome/BLM mutations Frasier Syndrome Trisomy 18 Perlman Syndrome Bohring-Opitz Syndrome (ASXL1) MULIBREY and Nanism Syndrome Congenital anomalies associated with Wilms Tumor <ul style="list-style-type: none"> Horseshoe kidney Renal ectopia, hypoplasia or renal/ureteral duplication Congenital mesoblastic nephroma 	<ul style="list-style-type: none"> Every 3 months, from birth to the 8th birthday: <ul style="list-style-type: none"> Abdominal US (CPT® 76700)

Background and Supporting Information

- The list of syndromes and congenital anomalies associated with Wilms Tumor specifically is ever growing. The following genetic variants and syndromes, not otherwise listed in **PEDONC-2** for more specific imaging, may have imaging as shown above.

Infantile Myofibromatosis (PEDONC-2.18)

ONCP.SC.0002.18.A

v2.0.2024

The following imaging studies should be considered appropriate in individuals with Infantile Myofibromatosis:

Indication	Imaging Study
<ul style="list-style-type: none"> Assess for the presence of multifocal disease in children under two years of age 	<ul style="list-style-type: none"> WBMRI (CPT® 76498) once within 6 months of diagnosis
<ul style="list-style-type: none"> Pre-operative planning or Signs or symptoms suggesting progression that may require treatment with surgery or chemotherapy 	<ul style="list-style-type: none"> Imaging of cutaneous/muscular sites with MRI with and without contrast of symptomatic sites or sites requiring treatment.
<ul style="list-style-type: none"> Unresected, known visceral sites of disease 	<ul style="list-style-type: none"> MRI with and without contrast of unresected visceral involved sites, every 6 months until the age of two years
<ul style="list-style-type: none"> <u>Post-operative evaluation and both of the following:</u> <ul style="list-style-type: none"> Adequacy of resection is unclear and Re-excision is being considered 	<ul style="list-style-type: none"> One-time MRI with and without contrast
<ul style="list-style-type: none"> Surveillance for emergence of visceral disease 	<ul style="list-style-type: none"> <u>Every 6 months, until the age of two years:</u> <ul style="list-style-type: none"> CT Chest with contrast (CPT® 71260) or without contrast (CPT® 71250) CT Abdomen and Pelvis (CPT® 74177) CT should not duplicate simultaneous MRI imaging of involved sites
<ul style="list-style-type: none"> Individuals requiring chemotherapy 	<ul style="list-style-type: none"> See: PEDONC-8.3

Background and Supporting Information

- Infantile myofibromatosis is a benign condition characterized by soft tissue tumors, 90% of which present in the first 2 years of life. 75% of cases present as solitary lesions affecting the skin and/or muscles of the head, neck and trunk. Other patterns of inheritance include congenital multicentric disease limited to skin and muscle, congenital multicentric with a single visceral site, and congenital with multiple visceral site involvement.
- The condition is most commonly sporadic, though familial cases associated with *PDGFRB* and *NOTCH3* have been described
- The majority of cases with skin or muscle only involvement regress spontaneously.
- Visceral cases are lethal in the absence of therapy in 75% of cases due to organ compression, particularly with cardiopulmonary involvement.
- If vital structures are involved or significant symptoms occur, treatment is generally radical resection. Chemotherapy is sometimes utilized for progressive or multifocal life threatening lesions.
- Infants may present with a single lesion and develop further lesions in the first two years of life. This scenario, along with the inability of infants to readily express symptoms, impacts the imaging studies that may be approved.
- Routine surveillance of cutaneous/muscular sites is not supported as spontaneous regression is common.
- Surveillance beyond the age of two years is not supported.

Bloom Syndrome (PEDONC-2.19)

ONCP.SC.0002.19.A
v2.0.2024

The following imaging studies should be considered appropriate in individuals with Bloom Syndrome:

Indication	Imaging Study
Malignancy screening particularly lymphomas	<ul style="list-style-type: none">Every 2 years, starting at age 13:<ul style="list-style-type: none">Whole-Body MRI (CPT® 76498)
Wilms tumor screening	<ul style="list-style-type: none">See: <u>Other Renal Cell Cancer Predisposition Syndromes (PEDONC-2.17)</u>
Gastrointestinal tumor screening	<ul style="list-style-type: none">There is no strong data to support endoscopic screening
Breast cancer screening	<ul style="list-style-type: none">There is no strong data to support Breast MRI. See: <u>Breast MRI Indications (BR-5.1)</u> for any updates to supported imaging

References (PEDONC-2)

v2.0.2024

1. Plon SE, Malkin D. Childhood Cancer and Heredity. In: Pizzo PA, Poplack DG, eds. Principles and Practice of Pediatric Oncology. 7th ed. Philadelphia, PA: Wolters Kluwer; 2016:13-31.
2. Aplan PD, Shern JF, Khan J. Molecular and genetic basis of childhood cancer. In: Pizzo PA, Poplack DG, eds. Principles and Practice of Pediatric Oncology. 7th ed. Philadelphia, PA: Wolters Kluwer; 2016:32-62.
3. Zelle K, Lindell RB, Schiffman JD, et al. Genetic predisposition to cancer. In: Orkin SH, Fisher DE, Ginsburg D, Look AT, Lux SE, Nathan DG, eds. Nathan and Oski's Hematology and Oncology of Infancy and Childhood. 8th ed. Philadelphia, PA: Elsevier Saunders; 2015:1270-1293.
4. Garber JE, Offit K. Hereditary cancer predisposition syndromes. *J Clin Oncol*. 2005;23(2):276-292. doi:10.1200/JCO.2005.10.042.
5. Holman JD, Dyer JA. Genodermatoses with malignant potential. *Current Opin Pediatr*. 2007;19(4):446-454. doi:10.1097/MOP.0b013e3282495939.
6. Foulkes WD. Inherited susceptibility to common cancers. *N Engl J Med*. 2008;359:2143-2153. doi:10.1056/NEJMra0802968.
7. Schiffman JD, Geller JI, Mundt E, et al. Update on pediatric cancer predisposition syndromes. *Pediatr Blood Cancer*. 2013;60(8):1247-1252. doi:10.1002/pbc.24555.
8. American Academy of Pediatrics. Ethical and policy issues in genetic testing and screening of children. *Pediatrics*. 2013;131(3):620-622. doi:10.1542/peds.2012-3680.
9. Monsalve J, Kapur J, Malkin D, Babyn PS. Imaging of cancer predisposition syndromes in children. *Radiographics*. 2011;31(1):263-280. doi:10.1148/rg.311105099.
10. D'Orazio JA. Inherited cancer syndromes in children and young adults. *J Pediatr Hematol Oncol*. 2010;32(3):195-228. doi:10.1097/MPH.0b013e3181ced34c.
11. Lu KH, Wodd ME, Daniels M, et al. American Society of Clinical Oncology Expert Statement: collection and use of a cancer family history for oncology providers. *J Clin Oncol*. 2014;32(8):833-841. doi:10.1200/JCO.2013.50.9257.
12. Farid M, Ngeow J. Sarcomas associated with genetic cancer predisposition syndromes: a review. *Oncologist*. 2016;21(8):1002-1013. doi:10.1634/theoncologist.2016-0079.
13. Tiwari R, Singh AK, Somwaru AS, et al. Radiologist's primer on imaging of common hereditary cancer syndromes. *RadioGraphics*. 2019;39:759-778. doi:10.1148/rg.2019180171.
14. Schneider K, Zelle K, Nichols KE, Garber J. Li-Fraumeni Syndrome. In: Adam MP, Ardinger HH, Pagon RA, et al., ed. GeneReviews® [Internet]. Seattle, WA: University of Washington, Seattle; 1993-2019. <https://www.ncbi.nlm.nih.gov/books/NBK1311/>.
15. Villani A, Tabori U, Schiffman J, et al. Biochemical and imaging surveillance in germline TP53 mutation carriers with Li-Fraumeni syndrome: a prospective observational study. *Lancet Oncol*. 2011;12(6):559-567. doi:10.1016/S1470-2045(11)70119-X.
16. Villani A, Shore A, Wasserman JD, et al. Biochemical and imaging surveillance in germline TP53 mutation carriers with Li-Fraumeni syndrome: 11 year follow-up of a prospective observational study. *Lancet Oncol*. 2016;17(9):1295-1305. doi:10.1016/S1470-2045(16)30249-2.
17. Ballinger ML, Best A, Mai PL, et al. Baseline surveillance in Li-Fraumeni Syndrome using whole-body magnetic resonance imaging a meta analysis. *JAMA Oncol*. 2017;3(12):1634-1639. doi:10.1001/jamaoncol.2017.1968.
18. Ruijs MWG, Loo CE, van Buchem CAJM, et al. Surveillance of Dutch patients with Li-Fraumeni Syndrome: the life-guard study. *JAMA Oncol*. 2017;3(12):1733-1734. doi:10.1001/jamaoncol.2017.1346.
19. Mai PL, Khincha PP, Loud JT, et al. Prevalence of Cancer at Baseline screening in the National Cancer Institute Li-Fraumeni Syndrome Cohort. *JAMA Oncol*. 2017;3(12):1640-1645. doi:10.1001/jamaoncol.2017.1350.
20. Kratz CP, Achatz MI, Brugières L, et al. Cancer screening recommendations for individuals with Li-Fraumeni Syndrome. *Clin Cancer Res*. 2017;23(11):e38-e45. doi:10.1158/1078-0432.CCR-17-0408.
21. Greer MC, Voss SD, States LJ. Pediatric cancer predisposition imaging: focus on whole-body MRI. *Clin Cancer Res*. 2017;23(11):e6-e13. doi:10.1158/1078-0432.CCR-17-0515.
22. Asdahl PH, Ojha RP, Hasle H. Cancer screening in Li-Fraumeni Syndrome. *JAMA Oncol*. 2017;3(12):1645-1646. doi:10.1001/jamaoncol.2017.2459.
23. Eutsler EP, Khanna G. Whole-body magnetic resonance imaging in children: technique and clinical applications. *Pediatr Radiol*. 2016;46(6):858-872. doi: 10.1007/s00247-016-3586-y.
24. Gottumukkalla RV, Gee MS, Hampilos PJ, Greer MC. Current and emerging roles of whole-body MRI in evaluation of pediatric cancer patients. *RadioGraphics*. 2019;39:516-534. doi:10.1148/rg.2019180130.
25. Daly MB, Pilarski R, Berry MP, et al. National Comprehensive Cancer Network (NCCN) Guidelines Version 3.2023—February 13, 2023. Genetic/Familial High-Risk Assessment: Breast and Ovarian, available at: <http://www.nccn.org>

- s://www.nccn.org/professionals/physician_gls/pdf/genetics_screening.pdf, Referenced with permission from the NCCN Clinical Practice Guidelines in Oncology (NCCN Guidelines™) for Genetic/Familial High-Risk Assessment: Breast and Ovarian V3.2023 2/13/2023 ©2023 National Comprehensive Cancer Network, Inc. All rights reserved. The NCCN Guidelines™ and illustrations herein may not be reproduced in any form for any purpose without the express written permission of the NCCN. To view the most recent and complete version of the NCCN Guidelines™, go online to NCCN.org.
26. Miller DT, Freedenberg D, Schorry E, et al. Health supervision for children with neurofibromatosis type 1. *Pediatrics*. 2019;143:e20190660. doi:10.1541/peds.2019-0660.
 27. Sahin M. Neurocutaneous syndromes. In: Kliegman RM, Stanton BF, St. Geme JW, Schor NF, Behrman RE, eds. *Nelson Textbook of Pediatrics*. Philadelphia, PA: Elsevier Saunders; 2011:2046-2048.
 28. Ullrich NJ. Neurocutaneous syndromes and brain tumors. *J Child Neurol*. 2016;31(12):1399-1411. doi:10.1177/0883073815604220.
 29. Korf BR and Bebin EM. Neurocutaneous disorders in Children. *Pediatr Rev*. 2017; 38(3):119-127. doi:10.1542/pir.2015-0118.
 30. Campian J, Gutmann DH. CNS tumors in neurofibromatosis. *J Clin Oncol*. 2017; 35(21):2378-2385. doi:10.1200/JCO.2016.71.7199.
 31. Friedman JM. Neurofibromatosis 1. In: Pagon RA, Adam MP, Ardinger HH et al., eds. *GeneReviews™ [Internet]*. Seattle, WA: University of Washington, Seattle;1998-2017. Version June 6, 2019. <https://www.ncbi.nlm.nih.gov/books/NBK1109/>.
 32. Karajannis MA, Ferner RE. Neurofibromatosis-related tumors: emerging biology and therapies. *Curr Opin Pediatr*. 2015;27(1):26-33. doi:10.1097/MOP.000000000000169.
 33. Meany H, Dombi E, Reynolds J, et al. 18-Fluorodeoxyglucose-Positron Emission Tomography (FDG-PET) evaluation of nodular lesions in patients with neurofibromatosis Type 1 and Plexiform Neurofibromas (PN) or Malignant Peripheral Nerve Sheath Tumors (MPNST). *Pediatr Blood Cancer*. 2013;60(1):59-64. doi:10.1002/pbc.24212.
 34. Tsai LL, Druback L, Fahey F, et al. [18F]-Fluorodeoxyglucose positron emission tomography in children with neurofibromatosis type 1 and plexiform neurofibromas: correlation with malignant transformation. *J Neuro Oncol*. 2012;108(3):469-475. doi:10.1007/s11060-012-0840-5.
 35. Corbemale P, Valeyrie-Allanore L, Giammarile F, et al. Utility of 18F-FDG PET with a semi-quantitative index in the detection of sarcomatous transformation in patients with neurofibromatosis Type 1. *PLoS ONE*. 2014;9(2):e85954. doi:10.1371/journal.pone.0085954.
 36. Chirindel A, Chaudhry M, Blakeley JO, Wahl R. 18F-FDG PET/CT Qualitative and quantitative evaluation in neurofibromatosis Type 1 Patients for detection of malignant transformation: comparison of early to delayed imaging with and without liver activity normalization. *J Nucl Med*. 2015;56(3):379-385. doi:10.2967/jnumed.114.142372.
 37. Prada CE, Hufnagel RB, Hummel TR, et al. The use of magnetic resonance imaging screening for optic pathway gliomas in children with neurofibromatosis Type 1. *J Pediatr*. 2015;167(4):851-856. doi:10.1016/j.jpeds.2015.07.001.
 38. Blakeley JO, Evans DG, Adler J, et al. Consensus recommendations for current treatments and accelerating clinical trials for patients with neurofibromatosis Type 2. *Am J Med Genet A*. 2012;158A(1):24-41. doi:10.1002/ajmg.a.34359.
 39. Evans DG. Neurofibromatosis 2. In: Pagon RA, Adam MP, Bird TD et al., eds. *GeneReviews™ [Internet]*. Seattle, WA: University of Washington, Seattle; 2011. Version March 15, 2018. <https://www.ncbi.nlm.nih.gov/books/NBK1201/>.
 40. Evans DG. Neurofibromatosis type 2 (NF2): a clinical and molecular review. *Orphanet J Rare Dis*. 2009;4:16. doi:10.1186/1750-1172-4-16.
 41. Ardern-Holmes S, Fisher G, North K. Neurofibromatosis Type 2: presentation, major complications, and management, with a focus on the pediatric age group. *J Child Neurol*. 2016;32(1):9-22. doi:10.1177/0883073816666736.
 42. Shuman C, Beckwith JB, Weksberg R. Beckwith-Wiedemann syndrome. In: Pagon RA, Adam MP, Bird TD et al., eds. *GeneReviews™ [Internet]*. Seattle, WA: University of Washington, Seattle; 2016. Version August 11, 2016. <https://www.ncbi.nlm.nih.gov/pubmed/20301568>.
 43. Choyke PL, Siegel MJ, Craft AW, Green DM, DeBaun MR. Screening for Wilms Tumor in children with Beckwith-Wiedemann syndrome or idiopathic hemihypertrophy. *Med Pediatr Oncol*. 1999;32(3):196-200. doi:10.1002/(SICI)1096-911X(199903)32:3<196::AID-MPO6>3.0.CO;2-9.
 44. Mussa A, Molinatto C, Baldassare G, et al. Cancer risk in Beckwith-Wiedemann syndrome: A systematic review and meta-analysis outlining a novel (epi)genotype specific histotype targeted screening protocol. *J Pediatr*. 2016;176:142-149. doi:10.1016/j.jpeds.2016.05.038.
 45. MacFarland SP, Mostoufi-Moab S, Zelle K, et al. Management of adrenal masses in patients with Beckwith-Wiedemann syndrome. *Pediatr Blood Cancer*. 2017;64(8):e26432. doi:10.1002/pbc.26432.
 46. Dome JS and Huff V. Wilms tumor predisposition. In: Pagon RA, Adam MP, Bird TD et al., eds. *GeneReviews™ [Internet]*. Seattle, WA: University of Washington, Seattle; 2016. <https://www.ncbi.nlm.nih.gov/pubmed/20301471> Accessed January 3, 2018

47. Fischbach BV, Trout KL, Lewis J, Luis CA, Sika M. WAGR Syndrome: A Clinical Review of 54 Cases. *Pediatrics*. 2005;116(4):984-988. doi:10.1542/peds.2004-0467.
48. Provenzale D, Gupta S, Ahnen DJ, et al. National Comprehensive Cancer Network (NCCN) Guidelines Version 1.2023—May 30, 2023, Genetic/Familial High-Risk Assessment: Colorectal, available at: https://www.nccn.org/professionals/physician_gls/pdf/genetics_colon.pdf, Referenced with permission from the NCCN Clinical Practice Guidelines in Oncology (NCCN Guidelines™) for Genetic/Familial High-Risk Assessment: Colorectal V1.2023 5/20/2023. ©2023 National Comprehensive Cancer Network, Inc. All rights reserved. The NCCN Guidelines™ and illustrations herein may not be reproduced in any form for any purpose without the express written permission of the NCCN. To view the most recent and complete version of the NCCN Guidelines™, go online to NCCN.org.
49. Kennedy RD, Potter DD, Moir CR, Mounif E. The natural history of familial adenomatous polyposis syndrome: A 24 year review of a single center experience in screening, diagnosis, and outcomes, *J Pediatr Surg*. 2014;49(1):82-86. doi:10.1016/j.jpedsurg.2013.09.033.
50. Jasperson KW, Patel SG, Ahnen DJ. APC-Associated Polyposis Conditions. In: Pagon RA, Adam MP, Bird TD, et al., ed. *GeneReviews™ [Internet]*. Seattle, WA: University of Washington, Seattle; 2017. Version February 2, 2017. <https://www.ncbi.nlm.nih.gov/books/NBK1345/>.
51. Stoffel EM, Mangu PB, Gruber SB, et al. Hereditary colorectal cancer syndromes: American Society of Clinical Oncology clinical practice guideline endorsement of the familial risk-colorectal cancer: European Society for Medical Oncology clinical practice guidelines. *J Clin Oncol*. 2015;33(2):209-217. doi:10.1200/JCO.2014.58.1322.
52. Giusti F, Marini F, Brandi ML. Multiple endocrine neoplasia Type 1. In: Pagon RA, Adam MP, Ardinger HH et al, ed. *GeneReviews™ [Internet]*. Seattle, WA: University of Washington, Seattle; 1993-2019. Version December 14, 2017. <https://www.ncbi.nlm.nih.gov/books/NBK1538/>.
53. Thakker RV, Newey PJ, Walls GV, et al. Clinical Practice guidelines for multiple endocrine neoplasia type 1 (MEN1). *J Clin Endocrinol Metab*. 2012;97(9):2990-3011. doi:10.1210/jc.2012-1230
54. Giri D, McKay V, Weber A, Blair JC. Multiple endocrine neoplasia syndromes 1 and 2: manifestations and management in childhood and adolescence. *Arch Dis Child*. 2015;100(10):994-999. doi:10.1136/archdischild-2014-307028.
55. Eng C. Multiple endocrine neoplasia Type 2. In: Pagon RA, Adam MP, Ardinger HH et al, eds. *GeneReviews™ [Internet]*. Seattle, WA: University of Washington, Seattle; 1999-2019. Version August 15, 2019. <https://www.ncbi.nlm.nih.gov/books/NBK1257/>.
56. Northrup H, Koenig MK, Pearson DA, Au KS. Tuberous Sclerosis Complex. In: Pagon RA, Adam MP, Ardinger HH et al, eds. *GeneReviews™ [Internet]*. Seattle, WA: University of Washington, Seattle; Version September 3, 2015. <https://www.ncbi.nlm.nih.gov/pubmed/20301399>.
57. Northrup H, Koenig MK, Pearson DA, Au KS. Tuberous sclerosis complex. In: Pagon RA, Adam MP, Ardinger HH et al, eds. *GeneReviews™ [Internet]*. Seattle, WA: University of Washington, Seattle; 1993-2019. Version July 12, 2018. <https://www.ncbi.nlm.nih.gov/books/NBK1220/>.
58. Krueger DA, Care MM, Agricola K, Tudor C, Mays M, Franz DN. Everolimus long-term safety and efficacy in subependymal giant cell astrocytoma. *Neurology*. 2013;80(6):574-580. doi:10.1212/WNL.0b013e3182815428.
59. Wheless JW, Klimo P. Subependymal giant cell astrocytomas in patients with tuberous sclerosis complex: considerations for surgical or pharmacotherapeutic intervention. *J Child Neurol*. 2014;29(11):1562-1571. doi:10.1177/0883073813501870.
60. van Leeuwen RS, Ahmad S, Links TP, Giles RH. Von Hippel-Lindau Syndrome. In: Pagon RA, Adam MP, Ardinger HH et al, eds. *GeneReviews™ [Internet]*. Seattle, WA: University of Washington, Seattle; 1993-2019. Version September 6, 2018. <https://www.ncbi.nlm.nih.gov/books/NBK1463/>.
61. Nielsen SM, Rhodes L, Blanco I, et al. Von Hippel-Lindau Disease: genetics and role of genetic counseling in a Multiple Neoplasia Syndrome. *J Clin Oncol*. 2016;34(18):2172-2181.
62. Rednam SP, Erez A, Druker H, et al. Von Hippel-Lindau and hereditary pheochromocytoma/paraganglioma syndromes: clinical features, genetics, and surveillance recommendations in childhood. *Clin Cancer Res*. 2017;23:e68-e75. doi: 10.1158/1078-0432.CCR-17-0547.
63. Kordes U, Bartelheim K, Modena P, et al. Favorable outcome of patients affected by rhabdoid tumors due to Rhabdoid Tumor Predisposition Syndrome (RTPS). *Pediatr Blood Cancer*. 2014;61(5):919-921. doi:10.1002/pbc.24793.
64. Sredni ST, Tomita T. Rhabdoid Tumor Predisposition Syndrome. *Pediatr Dev Pathol*. 2015;18(1):49-58. doi:10.2350/14-07-1531-MISC.1.
65. Nemes K, Bens S, Bourdeaut F, et al. Rhabdoid tumor predisposition syndrome. In: Pagon RA, Adam MP, Ardinger HH et al, eds. *GeneReviews™ [Internet]*. Seattle, WA: University of Washington, Seattle; 1993-2019. Version December 7, 2017. <https://www.ncbi.nlm.nih.gov/books/NBK469816/>.
66. Lohmann DR, Gallie BL. Retinoblastoma. In: Pagon RA, Adam MP, Ardinger HH et al, eds. *GeneReviews™ [Internet]*. Seattle, WA: University of Washington, Seattle; 1993-2019. Version November 21, 2018. <https://www.ncbi.nlm.nih.gov/books/NBK1452/>.

67. Else T, Greenberg S, Fishbein L. Hereditary Paraganglioma-Pheochromocytoma Syndromes. 2008 May 21 [updated 2018 Oct 4]. In: Adam MP, Everman DB, Mirzaa GM, Pagon RA, Wallace SE, Bean LJH, Gripp KW, Amemiya A, editors. GeneReviews® [Internet]. Seattle (WA): University of Washington, Seattle; 1993–2022. PMID: 20301715. Version April 1, 2021. <https://www.ncbi.nlm.nih.gov/pubmed/20301715>.
68. Gripp KW, Lin AE. Costello Syndrome. In: Pagon RA, Adam MP, Ardinger HH et al, eds. *GeneReviews™ [Internet]*. Seattle, WA: University of Washington, Seattle; 1999-2019. Version January 12, 2012. <https://www.ncbi.nlm.nih.gov/books/NBK1507/>.
69. Tabori U, Hansford JR, Achatz MI, et al. Clinical management and tumor surveillance recommendations of inherited mismatch repair deficiency in childhood. *Clin Cancer Res*. 2017;23:e32-e37. doi: 10.1158/1078-0432.CCR-17-0574.
70. Krueger DA, Northrup H. Tuberous sclerosis complex surveillance and management: recommendations of the 2012 International Tuberous Sclerosis Complex Consensus Conference. *Pediatr Neurol*. 2013;49(4):255–265. doi:10.1016/j.pediatrneurol.2013.08.002.
71. Campen CJ, Gutmann DH. Optic pathway gliomas in neurofibromatosis type 1. *J Child Neurol*. 2018;33(1):73–81. doi:10.1177/0883073817739509.
72. Rosser T. Neurocutaneous disorders. *CONTINUUM*. 2018;24(1, Child Neurology):96-129. doi:10.1212/CON000000000000562.
73. Motzer RJ, Jonasch E, Agarwal N, et al. National Comprehensive Cancer Network (NCCN) Guidelines Version 1.2024 – June 21, 2023. Kidney Cancer, available at: https://www.nccn.org/professionals/physician_gls/pdf/kidney.pdf, Referenced with permission from the NCCN Clinical Practice Guidelines in Oncology (NCCN Guidelines™) for Kidney Cancer V1.2024 – 6/21/2023. ©2023 National Comprehensive Cancer Network, Inc. All rights reserved. The NCCN Guidelines™ and illustrations herein may not be reproduced in any form for any purpose without the express written permission of the NCCN. To view the most recent and complete version of the NCCN Guidelines™, go online to NCCN.org.
74. Tuberous Sclerosis Alliance. Diagnosis, surveillance, and management of individuals with tuberous sclerosis complex. Silver Spring, MD. *Tuberous Sclerosis Alliance*; 2014. <https://www.tsalliance.org/healthcare-professionals/diagnosis/>.
75. Lam H, Siroky BJ, Henske EP. Renal disease in tuberous sclerosis complex: pathogenesis and therapy. *Nat Rev Nephrol*. 2018;14(11):704-706. doi:10.1038/s41581-018-0059-6.
76. Sattler EC, Ortud KS. Birt-Hogg-Dube Syndrome. In: Pagon RA, Adam MP, Ardinger HH et al, eds. *GeneReviews™ [Internet]*. Seattle, WA: University of Washington, Seattle;1993-2020. Version January 30, 2020. <https://www.ncbi.nlm.nih.gov/books/NBK1522/>.
77. Pilarski R, Rai K, Cebulla C, et al. BAP1 Tumor Predisposition Syndrome. In: Pagon RA, Adam MP, Ardinger HH et al, eds. *GeneReviews™ [Internet]*. Seattle, WA: University of Washington, Seattle;1993-2020. Version January 30, 2020. <https://www.ncbi.nlm.nih.gov/books/NBK390611/>.
78. Gläsker S, Vergauwen E, Koch CA, Kutikov A, Vortmeyer AO. Von Hippel-Lindau disease: current challenges and future prospects. *Onco Targets Ther*. 2020;13;5669-5690. doi:10.2147/OTT.S190753.
79. VHL Alliance. VHLA suggested active surveillance guidelines. Boston, MA. VHL Alliance; 2020. <https://www.vhl.org/wp-content/uploads/2020/07/Active-Surveillance-Guidelines-2020-2.pdf>.
80. Balis F, Green DM, Anderson C, et. al. National Comprehensive Cancer Network (NCCN) Guidelines Version 2.2023 – March 14, 2023. Wilms Tumor (Nephroblastoma), available at: https://www.nccn.org/professionals/physician_gls/pdf/wilms_tumor.pdf, Referenced with permission from the NCCN Clinical Practice Guidelines in Oncology (NCCN Guidelines™) for Wilms Tumor (Nephroblastoma) V1.2023 – 3/14/2023. ©2023 National Comprehensive Cancer Network, Inc. All rights reserved. The NCCN Guidelines™ and illustrations herein may not be reproduced in any form for any purpose without the express written permission of the NCCN. To view the most recent and complete version of the NCCN Guidelines™, go online to NCCN.org.
81. Todd K, Kim HK, Szabo S, et. al. Solitary myofibroma preceding the development of multicentric myofibromatosis: A report of two cases with surveillance recommendations. *Pediatr Blood Cancer*. 2020;67(10):e28266. doi:10.1002/pbc.28266.
82. Orbach, D, Bodemer C. Infantile myofibromatosis. *Orphanet*. 2019. https://www.orpha.net/consor/cgi-bin/OC_Exp.php?Lng=GB&Expert=2591
83. National Cancer Institute. *Infantile myofibromatosis*. 2020. <https://www.cancer.gov/pediatric-adult-rare-tumor/rare-tumors/rare-soft-tissue-tumors/infantile-myofibromatosis>.
84. Tang ER, Khalatbari H, Parisi MT. Utility of 18F-FDG PET/CT in infantile myofibromatosis. *Clin Nucl Med*. 2019;44:676-679. doi:10.1097/RLU.0000000000002627.
85. Evans DGR, Salvador H, Chang VY, et al. Cancer and Central Nervous System Tumor Surveillance in Pediatric Neurofibromatosis 1. *Clin Cancer Res*. 2017;23(12):e46-e53. doi: 10.1158/1078-0432.CCR-17-0589.
86. Gottumukkala RV, Gee MS, Hampilos PJ, et al. Current and Emerging Roles of Whole-Body MRI in Evaluation of Pediatric Cancer Patients. *Radiographics*. 2019;39(2):516-534. doi:10.1148/rg.2019180130.

87. Al-Sarhani H, Gottumukkala RV, Grasparil ADS 2nd, Tung EL, Gee MS, Greer MC. Screening of cancer predisposition syndromes. *Pediatr Radiol*. 2021. doi:10.1007/s00247-021-05023-w.
88. Grasparil AD 2nd, Gottumukkala RV, Greer MC, Gee MS. Whole-Body MRI surveillance of cancer predisposition syndromes: current best practice guidelines for use, performance, and interpretation. *AJR Am J Roentgenol*. 2020;215(4):1002-1011. doi:10.2214/AJR.19.22399.
89. Yang J, Gurudu SR, Koptiuch C, et al. American Society for Gastrointestinal Endoscopy guideline on the role of endoscopy in familial adenomatous polyposis syndromes. *Gastrointestinal Endoscopy*. 2020;91(5):963-82. doi:10.1016/j.gie.2020.01.028.
90. PDQ® Cancer Genetics Editorial Board. PDQ Birt-Hogg-Dubé Syndrome. Bethesda, MD: National Cancer Institute. Updated 04/13/2022. Available at: <https://www.cancer.gov/types/kidney/hp/renal-cell-carcinoma-genetics/bhd-syndrome>.
91. Frühwald MC, Nemes K, Boztug H, et al. Current recommendations for clinical surveillance and genetic testing in rhabdoid tumor predisposition: a report from the SIOPE Host Genome Working Group. *Fam Cancer*. 2021;20(4):305-316. doi:10.1007/s10689-021-00229-1.
92. Wolters WPG, Dreijerink KMA, Giles RH, et al. Multidisciplinary integrated care pathway for von Hippel-Lindau disease. *Cancer*. 2022;128(15):2871-2879. doi:10.1002/cncr.34265.
93. Schultz KAP, Williams GM, Kamihara J, et al. DICER1 and Associated conditions: identification of at-risk individuals and recommended surveillance strategies. *Clin Cancer Res*. 2018;24(10):2251-2261. doi:10.1158/1078-0432.CCR-17-3089.
94. Flanagan M, Cunniff CM. Bloom Syndrome. 2006 Mar 22 [updated 2019 Feb 14]. In: Adam MP, Mirzaa GM, Pagon RA, Wallace SE, Bean LJH, Gripp KW, Amemiya A, editors. GeneReviews®[Internet]. Seattle (WA): University of Washington, Seattle; 1993–2023. PMID: 20301572.
95. Cunniff C, Djavid AR, Carrubba S, et al. Health supervision for people with Bloom syndrome. *Am J Med Genet A*. 2018;176(9):1872-1881. doi:10.1002/ajmg.a.40374.
96. Taieb D, Jha A, Treglia G, Pacak K. Molecular imaging and radionuclide therapy of pheochromocytoma and paraganglioma in the era of genomic characterization of disease subgroups. *Endocr Relat Cancer*. 2019;26(11):R627-R652. doi:10.1530/ERC-19-0165.
97. Amar L, Pacak K, Steichen O, et al. International consensus on initial screening and follow-up of asymptomatic SDHx mutation carriers. *Nature Reviews Endocrinology*. 2021;17:435-445. doi:10.1038/s41574-021-00492-3.

Pediatric Leukemias (PEDONC-3)

Guideline

Pediatric Leukemia General Considerations (PEDONC-3.1)

Acute Lymphoblastic Leukemia (ALL) (PEDONC-3.2)

Acute Myeloid Leukemia (AML) (PEDONC-3.3)

References (PEDONC-3)

Pediatric Leukemia General Considerations (PEDONC-3.1)

ONCP.LE.0003.1.A

v2.0.2024

- MRI Brain without and with contrast (CPT® 70553) in individuals exhibiting CNS symptoms
 - Imaging due to CSF tumor burden has not been shown to improve the detection of CNS involvement compared with CSF alone
- See: **Hematopoietic Stem Cell Transplantation (ONC-29)** for imaging guidelines related to transplant

Background and Supporting Information

- The overwhelming majority of leukemias occurring in children are acute. Chronic myelogenous leukemia (CML) is rare in children, and the occurrence of chronic lymphocytic leukemia (CLL) appears to have only been reported once in pediatric individuals to date
- Routine advanced imaging is not indicated in the evaluation and management of chronic myeloid leukemia in the absence of specific localizing clinical symptoms or clearance for hematopoietic stem cell transplantation

Acute Lymphoblastic Leukemia (ALL) (PEDONC-3.2)

ONCPL.E.0003.2.A

v2.0.2024

- Individuals with B-precursor or T-cell lymphoblastic lymphoma without bone marrow involvement are treated similarly to leukemia individuals of the same cell type and should be imaged according to this guideline section
- This section does not apply to individuals with mature B-cell histology (primarily Burkitt's in children). Please refer to **Pediatric Aggressive Mature B-Cell Non-Hodgkin Lymphomas (NHL) (PEDONC-5.3)** for guidelines for these individuals
- Scrotal Ultrasound CPT® 76870 and/or doppler ultrasound of the scrotum CPT® 93975 or 93976 may be approved for suspected testicular involvement.
- Chest x-ray should be performed to evaluate for mediastinal mass in suspected cases or upon initial diagnosis.
 - CT Chest with contrast (CPT® 71260) immediately to evaluate for airway compression and anesthesia safety prior to attempting histologic diagnosis if mediastinal widening is seen on chest x-ray
 - Individuals with known or strongly suspected T-cell histology or other suspected lymphoblastic lymphoma involvement EITHER of the following for initial staging purposes:
 - CT Neck (CPT® 70491), CT Chest (CPT® 71260) and CT Abdomen and Pelvis (CPT® 74177) with contrast OR
 - PET/CT (CPT® 78816)
 - Indications and coding for rare circumstances where PET/MRI may be approved are found in **PET Imaging in Pediatric Oncology (PEDONC-1.4)**
- MRI Brain without and with contrast (CPT® 70553) for individuals exhibiting CNS symptoms.
 - Imaging due to CSF tumor burden has not been shown to improve the detection of CNS involvement compared with CSF alone.

Additional imaging in lymphoblastic lymphoma/lymphomatous extramedullary disease:

- CT to assess response to therapy **only** for individuals with known bulky nodal disease (usually with T-cell histology) at the end of induction (4 to 6 weeks). Individuals with residual masses can be evaluated with every new therapy phase (Consolidation, Interim maintenance, etc., generally every 8 to 12 weeks) until disease resolution is seen
- PET/CT (CPT® 78815) when residual mass ≥ 8 mm in diameter is present on recent CT imaging **and** immediate radiation or chemotherapy plan will be based on results.
 - Residual mass of any size with no PET-avidity is considered a complete response at the extranodal/lymphomatous site.

- Chest x-ray or Abdominal ultrasound (CPT® 76700) **only**, as indicated by site(s) of bulky disease present at diagnosis, for further surveillance, once CT imaging shows no evidence of disease.
- CT of all involved bulky nodal areas individuals with persistent residual masses performed as part of an end of therapy evaluation

Immunosuppression during ALL therapy:

- CT or MRI requests for infectious disease concerns for individuals with ALL with:
 - Absolute neutrophil count (ANC) <500 or
 - Inconclusive findings on chest x-ray **or** ultrasound at any ANC during active treatment
- Individuals with ALL are severely immunocompromised during the first 4 to 6 weeks of treatment (induction) and any conventional imaging request to evaluate for infectious complications during this time frame should be approved immediately
- MRA/MRV of the head (CPT® 70544, 70545, or 70546)
 - To rule out bleeding associated with sinus venous thrombosis in individuals treated with asparaginase

Imaging during therapy for relapsed ALL:

- Frequent CT or MRI imaging may be indicated to evaluate known or suspected new sites of invasive fungal or other aggressive infections
- Surveillance imaging of asymptomatic individuals to detect invasive fungal infection **only** when acute clinical decisions will be made based on the imaging

Imaging of known or suspected osteonecrosis in ALL:

- MRI without contrast or without and with contrast of the affected joint(s) with symptoms suggesting osteonecrosis
 - CT without contrast can be approved when MRI is contraindicated or unavailable, or for diagnosis of suspected subchondral fracture
- MRI Bilateral Hips (CPT® 73721 or CPT® 73723 with modifier -50) once at 6 to 9 months after diagnosis for individuals age ≥11 years
- Repeat MRI without contrast of the affected joint(s) every 2 cycles of maintenance (every 6 months) if reintroduction of corticosteroids is being considered in individuals whose symptoms have resolved and are still receiving active treatment
- MRI without contrast of the affected joint(s) for preoperative planning for individuals undergoing core decompression
- See: **Osteonecrosis In Long Term Cancer Survivors (PEDONC-19.4)** for information on osteonecrosis in ALL individuals who have completed therapy

Background and Supporting Information

- The majority of individuals with ALL have B-precursor ALL and routine advanced imaging is not necessary.
- Individuals with ALL who relapse are treated with very intensive chemotherapy regimens and most spend the majority of their chemotherapy treatment phase in the hospital
- Individuals may have therapy-induced hypogammaglobulinemia which requires supplemental intravenous immune globulin (IVIG) during maintenance therapy. Those receiving supplemental IVIG should be treated similarly to individuals with ANC <500 with regards to imaging for infectious disease
- Osteonecrosis (ON) in individuals with ALL is a relatively common complication of ALL and its treatment, primary corticosteroids. Approximately 3% of younger children and 12 to 15% of adolescents are affected by ON at some point during therapy. The peak incidence occurs approximately one year from the time of diagnosis
- Screening MRI of asymptomatic individuals age ≤10 years to detect osteonecrosis has not been shown to impact individual outcomes, and it is not standard to alter treatment based on imaging findings alone without symptoms
- If osteonecrosis is detected on initial MRI, corticosteroids are often withheld during maintenance chemotherapy (but continued in earlier phases of therapy).

Acute Myeloid Leukemia (AML) (PEDONC-3.3)

ONCP.LE.0003.3.A

v2.0.2024

- Frequent CT or MRI imaging may be indicated to evaluate known sites of invasive fungal infection
- Surveillance imaging of asymptomatic individuals to detect invasive fungal infection **only** when acute clinical decisions will be made based on the imaging
- Advanced imaging may be approved on a case-by-case basis for rare individuals with bulky tumor masses (commonly referred to as chloromas, leukemic sarcomas, or myeloid sarcomas) noted on physical examination or other imaging such as plain film or ultrasound

Background and Supporting Information

- The majority of AML individuals do not have any bulky disease and routine advanced imaging is not necessary
- AML individuals are treated with very intensive chemotherapy regimens and spend the majority of their chemotherapy treatment phase in the hospital

References (PEDONC-3)

v2.0.2024

1. Rabin KR, Gramatges MM, Margolin JF, et al. Acute Lymphoblastic Leukemia. In: Pizzo PA, Poplack DG, eds. Principles and Practice of Pediatric Oncology. 7th ed. Philadelphia, PA: Wolters Kluwer; 2016:463-497.
2. Arceci RJ, Meshinchi S. Acute Myeloid Leukemia and Myelodysplastic disorders. In: Pizzo PA, Poplack DG, eds. Principles and Practice of Pediatric Oncology. 7th ed. Philadelphia, PA: Wolters Kluwer; 2016:498-544.
3. Rau R, Loh ML. Myeloproliferative neoplasms of childhood. In: Pizzo PA, Poplack DG, eds. Principles and Practice of Pediatric Oncology. 7th ed. Philadelphia, PA: Wolters Kluwer; 2016:545-567.
4. Gutierrez A, Silverman LB. Acute Lymphoblastic Leukemia. In: Orkin SH, Fisher DE, Ginsburg D, Look AT, Lux SE, Nathan DG, eds. Nathan and Oski's Hematology and Oncology of Infancy and Childhood. 8th ed. Philadelphia, PA: Elsevier Saunders; 2015:1527-1554.
5. Berman JN, Look AT. Pediatric Myeloid Leukemia, Myelodysplasia, and Myeloproliferative Disease. In: Orkin SH, Fisher DE, Ginsburg D, Look AT, Lux SE, Nathan DG, eds. Nathan and Oski's Hematology and Oncology of Infancy and Childhood. 8th ed. Philadelphia, PA: Elsevier Saunders; 2015:1555-1613.
6. Kobos R, Shukla N, and Armstrong SA. Infant Leukemias. In: Orkin SH, Fisher DE, Ginsburg D, Look AT, Lux SE, Nathan DG, eds. Nathan and Oski's Hematology and Oncology of Infancy and Childhood. 8th ed. Philadelphia, PA: Elsevier Saunders; 2015:1614-1625.
7. Kaplan JA. Leukemia in children. *Pediatr Rev*. 2019;40:319-331. doi: 10.1542/pir.2018-0192.
8. Inaba H, Teachey D, Annesley C, et al. National Comprehensive Cancer Network (NCCN) Guidelines Version 2.2023—March 10, 2023, Pediatric Acute Lymphoblastic Leukemia, available at: https://www.nccn.org/professionals/physician_gls/pdf/ped_all.pdf, Referenced with permission from the NCCN Clinical Practice Guidelines in Oncology (NCCN Guidelines™) for Pediatric Acute Lymphoblastic Leukemia V2.2023 03/10/2023. ©2023 National Comprehensive Cancer Network, Inc. All rights reserved. The NCCN Guidelines™ and illustrations herein may not be reproduced in any form for any purpose without the express written permission of the NCCN. To view the most recent and complete version of the NCCN Guidelines™, go online to NCCN.org.
9. Ranta S, Palomäki M, Levinsen M, et al. Role of neuroimaging in children with Acute Lymphoblastic Leukemia and central nervous system involvement at diagnosis. *Pediatr Blood Cancer*. 2016;64:64-70. doi:10.1002/pbc.26182/epdf.
10. Agrawal AK, Saini N, Gildengorin G et al. Is routine computed tomographic scanning justified in the first week of persistent febrile neutropenia in children with malignancies? *Pediatr Blood Cancer*. 2011;57(4):620-624. doi:10.1002/pbc.22974/epdf.
11. Pui C-H, Yang JJ, Hunger SP, et al. Childhood Acute Lymphoblastic Leukemia: progress through collaboration. *J Clin Oncol*. 2015;33(27):2938-2948. doi: 10.1200/JCO.2014.59.1636.
12. Kawedia JD, Kaste SC, Pei D, et al. Pharmacokinetic, pharmacodynamic, and pharmacogenetic determinants of osteonecrosis in children with acute lymphoblastic leukemia. *Blood Journal*. 2011;117(8):2340-2347. doi:10.1182/blood-2010-10-311969.
13. Marcucci G, Beltrami G, Tamburini A, et al. Bone health in childhood cancer: review of the literature and recommendations for the management of bone health in childhood cancer survivors. *Ann Oncol*. 2019;30:908-920. doi:10.1093/annonc/mdz120.
14. Vora A. Management of osteonecrosis in children and young adults with acute lymphoblastic leukaemia. *Br J Haematol*. 2011;155(5):549-560. doi:10.1111/j.1365-2141.2011.08871.x.
15. Kaste SC, Pei D, Cheng C, et al. Utility of early screening magnetic resonance imaging for extensive hip osteonecrosis in pediatric patients treated with glucocorticoids. *J Clin Oncol*. 2015;33(6):610-615. doi:10.1200/JCO.2014.57.5480.
16. Niinimäki T, Harila-Saari A, Niinimäki R. The diagnosis and classification of osteonecrosis in patients with childhood Leukemia. *Pediatr Blood Cancer*. 2015;62(2):198-203. doi:10.1002/pbc.25295.
17. Murphey MD, Roberts CC, Bencardino JT, et al. Osteonecrosis of the hip. ACR Appropriateness Criteria® 2015;1-12. <https://acsearch.acr.org/docs/69420/Narrative/>.
18. Karol SE, Mattano LA, Yang W, et al. Genetic risk factors for the development of osteonecrosis in children under age 10 treated for acute lymphoblastic leukemia. *Blood Journal*. 2016;127(5):558-564. doi:10.1182/blood-2015-10-673848.
19. Chavhan GB, Babyn PS, Nathan PC, et al. Imaging of acute and subacute toxicities of cancer therapy in children. *Pediatr Radiol*. 2016;46(1):9-20. doi:10.1007/s00247-015-3454-1.
20. Lauer M, Kernen E, Schwabe D, Lehrnbecher T, Porto L. The role of magnetic resonance imaging in the diagnosis of central nervous system involvement in children with acute lymphoblastic leukemia. *Pediatr Blood Cancer*. 2020;e28294. doi:10.1002/pbc.28294.

CNS Tumors (PEDONC-4)

Guideline

- CNS Tumors General Considerations (PEDONC-4.1)
- CNS Low Grade Gliomas (LGG) (PEDONC-4.2)
- CNS High Grade Gliomas (HGG) (PEDONC-4.3)
- Medulloblastoma (MDB), Other CNS Embryonal Tumors, and Pineoblastoma (PEDONC-4.4)
- Atypical Teratoid/Rhabdoid Tumors (ATRT) (PEDONC-4.5)
- Pineocytomas and Pineal Parenchymal Tumors (PEDONC-4.6)
- CNS Germinomas and Non-Germinomatous Germ Cell Tumors (NGGCT) (PEDONC-4.7)
- Ependymal Tumors (Ependymoma) (PEDONC-4.8)
- Malignant Tumors of the Spinal Cord (PEDONC-4.9)
- Craniopharyngioma and Other Tumors of the Sellar Region (PEDONC-4.10)
- Primary CNS Lymphoma (PEDONC-4.11)
- Meningiomas (PEDONC-4.12)
- Choroid Plexus Tumors (PEDONC-4.13)
- References (PEDONC-4)

CNS Tumors General Considerations (PEDONC-4.1)

ONCP.CT.0004.1.A

v2.0.2024

- The classification of pediatric central nervous tumors has recently been revised to incorporate molecular biomarkers in addition to histology, immunohistochemical results and ultrastructure characteristics. The changes in nomenclature are incorporated in these guidelines⁵⁰.
- Central nervous system tumors are the second most common form of childhood cancer, accounting for ~20% of all pediatric malignancies

Red Flag Symptoms Raising Suspicion for CNS Tumors Include:

Any headache complaint from a child age ≤5 years
Headaches awakening from sleep
Focal findings on neurologic exam
Clumsiness (common description of gait or coordination problems in young children)
Headaches associated with morning nausea/vomiting
New onset of seizure activity with focal features
Papilledema on physical exam
Loss of developmental milestones (infants and young children)

MRI Considerations

- MRI is the preferred imaging modality for all pediatric CNS tumors
 - MRI Brain without and with contrast (CPT® 70553) is the primary imaging study for pediatric brain tumors
 - MRI Brain without contrast (CPT® 70551) if requested for initial evaluation of suspected CNS tumor for children able to undergo MRI without sedation
 - Initial MRI should be performed without and with contrast in order to avoid a second anesthesia exposure in younger children requiring sedation for MRI
- MRI Spine with contrast only (Cervical-CPT® 72142, Thoracic-CPT® 72147, Lumbar-CPT® 72149) can be substituted where MRI Spine without and with contrast is indicated, if being performed immediately following a contrast-enhanced MRI Brain
- Functional MRI (CPT® 70555 or CPT® 70554) is indicated to depict spatial relationships between eloquent cortex and neoplasms for preoperative planning and to promote safe resections (following baseline MRI Brain).
- MRI Orbits without and with contrast (CPT® 70543) is indicated in individuals who present with papilledema, altered vision, strabismus, nystagmus, anisocoria, proptosis, ocular cranial nerve palsies, coloboma, or leukocoria.

CT Considerations

- CT for evaluation of ventriculomegaly or other operative considerations, or for children who cannot undergo MRI safely
 - CT for evaluation of headaches related to head trauma or evaluation of skull or facial bone abnormalities
 - Post-contrast CT is generally not indicated
- CT is not a recommended study for evaluation of pediatric headache when brain tumor is clinically suspected because of its limited diagnostic accuracy in this area. MRI should be used as first line imaging in these cases
- CT should not be used in place of MRI to avoid sedation in young children when red flag symptoms for CNS tumors are present

MRA/CTA and Perfusion Studies

- MRA or CTA **only** for preoperative planning or to clarify inconclusive findings on MRI or CT
- CT and MRI Perfusion
 - See: **CT or MRI Perfusion (HD-24.5)** in the Head Imaging guidelines

MR Spectroscopy (MRS, CPT® 76390)

- MRS is **only** supported for use in brain tumors of specified histologies where diagnostic accuracy has been established in peer-reviewed literature
 - See diagnosis-specific guidelines for MRS indications
- MRS is considered investigational/experimental for all other histologies and indications not listed in a diagnosis-specific guideline section
- MR spectroscopy is not indicated for routine surveillance

PET Brain Imaging (CPT® 78608 and CPT® 78609)

- PET Brain Metabolic imaging (CPT® 78608) is **only** supported for use in brain tumors of specified histologies where diagnostic accuracy has been established in peer-reviewed literature
 - See diagnosis-specific guidelines for PET indications
- PET Brain Metabolic is not indicated for routine surveillance
- PET Brain Metabolic imaging is considered investigational/experimental for all other histologies and indications not listed in a diagnosis-specific guideline section
- PET Brain Perfusion imaging (CPT® 78609) is not indicated in the evaluation or management of primary CNS tumors
- Fusion PET/CT studies (CPT® 78814, CPT® 78815, or CPT® 78816) are not indicated in the evaluation or management of primary CNS tumors

Timing and Frequency of Imaging

- Definitive imaging should be completed prior to considering biopsy given the high degree of morbidity associated with operating on the CNS
 - Occasionally biopsy is not necessary because the imaging findings provide a definitive diagnosis
 - Examples include diffuse intrinsic pontine glioma and optic pathway gliomas in an individual with known neurofibromatosis
- Perioperative imaging frequency
 - Children may undergo very frequent imaging in the immediate perioperative period around resection or debulking of a CNS tumor due to the small anatomic spaces involved
 - Requests for imaging during this time period to specifically evaluate postoperative course or ventriculoperitoneal shunt functioning should, in general, be approved as requested
 - MRI Brain without and with contrast (CPT® 70553) one time in the immediate preoperative period (even if another study has already been completed) to gain additional information which can be important in optimizing individual outcomes, such as:
 - Completion of additional specialized MRI sequences such as diffusion-tensor imaging
 - Perfusion imaging
 - Tractography
 - Other sequences not reported under a separate CPT® code but not part of a routine MRI Brain series
 - Repeat MRI Brain that is being requested solely for loading into operative navigation software should not be requested as a diagnostic code but can be approved under a treatment planning code (CPT® 76498).
 - Clinical note: for all pediatric CNS tumors, cerebrospinal fluid pathology positive for malignancy is considered leptomeningeal/spinal disease.

CNS Low Grade Gliomas (LGG) (PEDONC-4.2)

ONCP.CT.0004.2.A

v2.0.2024

- MR Spectroscopy and PET Brain Metabolic are not indicated for routine surveillance
- MRI is generally superior to CT for staging and restaging CNS malignancies, but CT may be approved in accordance with these guidelines where MRI is contraindicated.

Indication	Imaging Study
Initial staging of all LGG	<ul style="list-style-type: none"> • MRI Brain without and with contrast (CPT® 70553) • MRI Spine without and with contrast (Cervical-CPT® 72156, Thoracic-CPT® 72157, Lumbar-CPT® 72158) • MRI Orbits without and with contrast (CPT® 70543) is indicated in addition to the above studies for individuals presenting with visual signs or symptoms as listed in PEDONC-4.1
<ul style="list-style-type: none"> • <u>At any time, for ANY of the following:</u> <ul style="list-style-type: none"> • For rapid assessment in the acute setting • Evaluation of acute intracranial hemorrhage • Evaluation of ventriculomegaly • Evaluation of shunt-related issues 	<ul style="list-style-type: none"> • CT Head without contrast (CPT® 70450)
<ul style="list-style-type: none"> • <u>ANY of the following:</u> <ul style="list-style-type: none"> • Determining the need for biopsy when transformation to high grade glioma is suspected based on clinical symptoms or recent MRI findings • Evaluation of a brain lesion of indeterminate nature when the PET findings will be used to determine whether biopsy/resection can be safely postponed 	<ul style="list-style-type: none"> • PET Brain Metabolic imaging (CPT® 78608)

Indication	Imaging Study
<ul style="list-style-type: none"> • <u>ANY of the following:</u> <ul style="list-style-type: none"> • Distinguish low grade from high grade gliomas • Evaluate a brain lesion of indeterminate nature when the MRS findings will be used to determine whether biopsy/resection can be safely postponed • Distinguish radiation-induced tumor necrosis from progressive disease within 18 months of completing radiotherapy 	<ul style="list-style-type: none"> • MR Spectroscopy (MRS, CPT® 76390)
<p>Baseline imaging after resection, to assess degree of resection</p>	<ul style="list-style-type: none"> • MRI Brain without and with contrast (CPT® 70553) • MRI with and without contrast at level of resected spinal site • If orbital resection, MRI Orbits without and with contrast (CPT® 70543)
<p>Treatment response at the completion of radiotherapy</p>	<ul style="list-style-type: none"> • MRI Brain without and with contrast (CPT® 70553) • MRI with and without contrast at level of irradiated spinal site • If prior orbital involvement, MRI Orbits without and with contrast (CPT® 70543)
<p>Treatment response on chemotherapy</p>	<ul style="list-style-type: none"> • MRI Brain without and with contrast (CPT® 70553) approved every 2 cycles during active treatment and at the end of planned chemotherapy • If prior orbital involvement, MRI Orbits without and with contrast (CPT® 70543)
<p>Additional treatment response imaging during induction chemotherapy for individuals with measurable spinal cord disease on MRI</p>	<ul style="list-style-type: none"> • MRI Spine without and with contrast (Cervical-CPT® 72156, Thoracic-CPT® 72157, Lumbar-CPT® 72158) every 2 cycles

Indication	Imaging Study
Surveillance	<ul style="list-style-type: none"> • <u>For individuals with intracranial primary:</u> <ul style="list-style-type: none"> • MRI Brain without and with contrast (CPT® 70553) every 3 months for 2 years, then every 6 months for 3 years, then annually thereafter. • If prior orbital involvement, MRI Orbits without and with contrast (CPT® 70543) • MRI Spine is not indicated during surveillance in individuals without prior history of spinal involvement except to evaluate symptoms suspicious for spinal cord recurrence • <u>For individuals with a history of spine primary tumor or metastatic spinal involvement:</u> <ul style="list-style-type: none"> • MRI Spine without and with contrast (Cervical-CPT® 72156, Thoracic-CPT® 72157, Lumbar-CPT® 72158) every 3 months for 2 years, then every 6 months for 3 years, then annually thereafter
Surveillance imaging for individuals with optic pathway glioma and a history of NF1	<ul style="list-style-type: none"> • <u>Every 3 months for 2 years, then every 6 months for 3 years, then annually thereafter:</u> <ul style="list-style-type: none"> • MRI Brain without and with contrast (CPT® 70553) and • MRI Orbits without and with contrast (CPT® 70543)
Suspected intracranial or intraspinal recurrence	<ul style="list-style-type: none"> • All imaging supported in initial staging criteria may be repeated

Background and Supporting Information

Includes the following tumors:

- Pediatric-type diffuse low-grade gliomas
 - Diffuse astrocytoma, MYB- or MYBL1-altered
 - Angiocentric glioma
 - Polymorphous low-grade neuroepithelial tumor of the young
 - Diffuse low-grade glioma, MAPK pathway-altered
- Circumscribed astrocytic gliomas
 - Pilocytic astrocytoma
 - High-grade astrocytoma with piloid features
 - Pleomorphic xanthoastrocytoma
 - Subependymal giant cell astrocytoma (SEGA)
 - Choroid glioma
 - Astroblastoma, MN
- Glioneuronal and neuronal tumors
 - Ganglioglioma
 - Desmoplastic infantile ganglioglioma/desmoplastic infantile astrocytoma
 - Dysembryoplastic neuroepithelial tumor
 - Diffuse glioneuronal tumor with oligodendroglioma-like features and nuclear clusters
 - Papillary glioneuronal tumor
 - Rosette-forming glioneuronal tumor
 - Myxoid glioneuronal tumor
 - Diffuse leptomeningeal glioneuronal tumor
 - Gangliocytoma
 - Multinodular and vacuolating neuronal tumor
 - Dysplastic cerebellar gangliocytoma (Lhermitte-Duclos disease)
 - Central neurocytoma
 - Extraventricular neurocytoma
 - Cerebellar liponeurocytoma
- Any other glial tumor with a WHO grade I or II classification

General Considerations:

- Account for 40 to 60% of pediatric CNS tumors.
- These tumors are defined as having a WHO grade of I or II (out of IV), can occur anywhere in the CNS

Treatment Considerations:

- Children with neurofibromatosis and small optic pathway tumors may not undergo biopsy or resection and will proceed directly to treatment or surveillance

- Children on observation without specific treatment should be imaged according to surveillance guidelines for LGG
- Individuals who undergo complete resection should be imaged according to surveillance guidelines after post-resection imaging
- Individuals age >10 years with incompletely resected tumors usually receive adjuvant radiation therapy
- Individuals age ≤10 years with incompletely resected tumors are commonly treated with chemotherapy

CNS High Grade Gliomas (HGG) (PEDONC-4.3)

ONCP.CT.0004.3.A

v2.0.2024

Indication	Imaging Study
Initial staging of all HGG	<ul style="list-style-type: none"> • MRI Brain without and with contrast (CPT® 70553) • MRI Spine without and with contrast (Cervical-CPT® 72156, Thoracic-CPT® 72157, Lumbar-CPT® 72158) • 3D rendering may be approved as requested for initial staging
<ul style="list-style-type: none"> • <u>At any time, for ANY of the following:</u> <ul style="list-style-type: none"> • For rapid assessment in the acute setting • Evaluation of acute intracranial hemorrhage • Evaluation of ventriculomegaly • Evaluation of shunt-related issues 	<ul style="list-style-type: none"> • CT Head without contrast (CPT® 70450)
<ul style="list-style-type: none"> • <u>ANY of the following:</u> <ul style="list-style-type: none"> • Distinguishing radiation-induced tumor necrosis from progressive disease within 18 months of completing radiotherapy • Evaluating inconclusive MRI findings when the PET findings will be used to determine need for biopsy or change in therapy, including a change from active therapy to surveillance • Evaluation of a brain lesion of indeterminate nature when the PET findings will be used to determine whether biopsy/resection can be safely postponed 	<ul style="list-style-type: none"> • PET Brain Metabolic Imaging (CPT® 78608)

Indication	Imaging Study
<ul style="list-style-type: none"> • <u>ANY of the following:</u> <ul style="list-style-type: none"> • To distinguish low grade from high grade gliomas • To evaluate a brain lesion of indeterminate nature when the MRS findings will be used to determine whether biopsy/resection can be safely postponed • To distinguish radiation-induced tumor necrosis from progressive disease within 18 months of completing radiotherapy 	<ul style="list-style-type: none"> • MR Spectroscopy (MRS, CPT® 76390)
<p>Baseline imaging following resection, to assess degree of resection</p>	<ul style="list-style-type: none"> • MRI Brain without and with contrast (CPT® 70553) • MRI with and without contrast at level of resected spinal site
<p>Treatment response at the completion of radiotherapy</p>	<ul style="list-style-type: none"> • MRI Brain without and with contrast (CPT® 70553) • MRI with and without contrast at level of irradiated spinal site
<p>Treatment response on chemotherapy</p>	<ul style="list-style-type: none"> • MRI Brain without and with contrast (CPT® 70553) every 2 cycles during active treatment and at the end of planned chemotherapy
<p>Additional treatment response imaging during induction chemotherapy for individuals with measurable spinal cord disease on MRI</p>	<ul style="list-style-type: none"> • MRI Spine without and with contrast (Cervical-CPT® 72156, Thoracic-CPT® 72157, Lumbar-CPT® 72158) every 2 cycles
<p>Signs or symptoms of recurrence or progression</p>	<ul style="list-style-type: none"> • MRI Brain without and with contrast (CPT® 70553) • MRI Spine without and with contrast (Cervical-CPT® 72156, Thoracic-CPT® 72157, Lumbar-CPT® 72158)

Indication	Imaging Study
Surveillance	<ul style="list-style-type: none"> • <u>For individuals with intracranial primary:</u> <ul style="list-style-type: none"> • MRI Brain without and with contrast (CPT® 70553) every 3 months for 3 years, then every 6 months thereafter • MRI Spine is not indicated during surveillance in individuals without prior history of spinal involvement except to evaluate symptoms suspicious for spinal cord recurrence • <u>For individuals with a history of spine primary tumor or metastatic spinal involvement:</u> <ul style="list-style-type: none"> • MRI Spine without and with contrast (Cervical-CPT® 72156, Thoracic-CPT® 72157, Lumbar-CPT® 72158) every 3 months for 3 years, then every 6 months thereafter
Suspected intracranial or intraspinal recurrence	<ul style="list-style-type: none"> • All imaging supported for initial staging may be repeated
Suspected spinal cord recurrence	<ul style="list-style-type: none"> • MRI Spine without and with contrast (Cervical-CPT® 72156, Thoracic-CPT® 72157, Lumbar-CPT® 72158)

Background and Supporting Information

Includes the following tumors:

- Diffuse midline glioma, H3 K27-altered
- Diffuse hemispheric glioma, H3 G34-mutant
- Diffuse pediatric-type high-grade glioma, H3-wildtype and IDH-wildtype
- Infant-type hemispheric glioma
- Any other glial tumor with a WHO grade of III or IV classification

General Considerations:

- Rare in children compared with the adult population, but represent 10% to 20% of pediatric CNS tumors
- Prognosis is very poor, and survival significantly beyond 3 years from diagnosis is rare, even with complete surgical resection at initial diagnosis
- These tumors are defined as having a WHO histologic grade of III or IV (out of IV) can occur anywhere in the CNS (though the majority occur in the brain)

Treatment Considerations:

- Individuals who undergo complete resection should be imaged according to surveillance guidelines after post-resection imaging
- Individuals with incompletely resected tumors are commonly treated with chemotherapy

Medulloblastoma (MDB), Other CNS Embryonal Tumors, and Pineoblastoma (PEDONC-4.4)

ONCP.CT.0004.4.A
v2.0.2024

- MR Spectroscopy and PET Brain Metabolic are not indicated for routine surveillance

Indication	Imaging Study
Initial staging for all individuals, preoperatively	<ul style="list-style-type: none"> MRI Brain without and with contrast (CPT® 70553) MRI spine without and with contrast (Cervical-CPT® 72156, Thoracic-CPT® 72157, Lumbar-CPT® 72158)
<ul style="list-style-type: none"> <u>At any time, for ANY of the following:</u> <ul style="list-style-type: none"> For rapid assessment in the acute setting Evaluation of acute intracranial hemorrhage Evaluation of ventriculomegaly Evaluation of shunt-related issues 	<ul style="list-style-type: none"> CT Head without contrast (CPT® 70450)
<ul style="list-style-type: none"> <u>ANY of the following:</u> <ul style="list-style-type: none"> To distinguish radiation-induced tumor necrosis from progressive disease within 18 months of completing radiotherapy To evaluate inconclusive MRI findings when the PET findings will be used to determine need for biopsy or change in therapy, including a change from active therapy to surveillance To evaluate a brain lesion of indeterminate nature when the PET findings will be used to determine whether biopsy/resection can be safely postponed 	<ul style="list-style-type: none"> PET Brain Metabolic Imaging (CPT® 78608)

Indication	Imaging Study
<ul style="list-style-type: none"> • <u>ANY of the following:</u> <ul style="list-style-type: none"> • To evaluate a brain lesion of indeterminate nature when the MRS findings will be used to determine whether biopsy/resection can be safely postponed 	<ul style="list-style-type: none"> • MR Spectroscopy (CPT® 76390)
<p>Postoperative (preferably within 48 hours of surgery) to quantify residual tumor volume</p>	<ul style="list-style-type: none"> • MRI Brain without and with contrast (CPT® 70553)
<p>Within 28 days post-op, if spinal imaging was not performed preoperatively</p>	<ul style="list-style-type: none"> • MRI Spine without and with contrast (Cervical-CPT® 72156, Thoracic-CPT® 72157, Lumbar-CPT® 72158)
<p>Treatment response</p>	<ul style="list-style-type: none"> • At the start of adjuvant chemotherapy and every 2 cycles until therapy is completed: <ul style="list-style-type: none"> • MRI Brain without and with contrast (CPT® 70553) • MRI Spine without and with contrast (Cervical-CPT® 72156, Thoracic CPT® 72157, Lumbar-CPT® 72158)
<p>Children age <3 years treated with multiple cycles of high dose chemotherapy with autologous stem cell rescue in lieu of radiotherapy</p>	<ul style="list-style-type: none"> • Disease evaluations (imaging per treatment response guidelines) may occur prior to each cycle (every 4 to 6 weeks) if needed for response determination.
<p>End of treatment evaluation</p>	<ul style="list-style-type: none"> • MRI Brain without and with contrast (CPT® 70553) • MRI Spine with contrast (Cervical-CPT® 72142, Thoracic-CPT® 72147, Lumbar-CPT® 72149) or MRI Spine without and with contrast (Cervical-CPT® 72156, Thoracic-CPT® 72157, Lumbar-CPT® 72158)
<p>Signs or symptoms of recurrence or progression</p>	<ul style="list-style-type: none"> • MRI Brain without and with contrast (CPT® 70553) • MRI Spine without and with contrast (Cervical-CPT® 72156, Thoracic-CPT® 72157, Lumbar-CPT® 72158)

Indication	Imaging Study
Surveillance	<ul style="list-style-type: none"> • Every 3 months for 3 years, then every 6 months for 2 years, then annually for 10 years: <ul style="list-style-type: none"> • MRI Brain without and with contrast (CPT® 70553) • MRI Spine without and with contrast (Cervical-CPT® 72156, Thoracic-CPT® 72157, Lumbar-CPT® 72158) • For additional imaging guidelines for individuals in long term follow up after CNS tumor treatment that included radiation therapy, see: <u>Second Malignant Neoplasms (SMN) (PEDONC-19.3)</u>

Background and Supporting Information

Includes the Following Tumors:

- Medulloblastoma
 - Molecularly-defined Medulloblastoma
 - WNT-activated Medulloblastoma
 - SHH-activated and TP53-wildtype Medulloblastoma
 - SHH-activated and TP53-mutant Medulloblastoma
 - Non-WNT/Non-SHH
 - Medulloblastoma, histologically defined
- Other CNS Embryonal Tumors (previously supratentorial primitive neuroectodermal tumors)
 - CNS embryonal tumor
 - Cribriform neuroepithelial tumor
 - Embryonal tumor with multilayered rosettes
 - CNS neuroblastoma
 - FOXR2-activated CNS tumor with BCOR internal tandem duplication
- Pineoblastoma

Risk Assessment is Important in Determining Optimal Treatment

High-Risk Features Include the Following:

- Spinal metastasis (including cytology positive only)
- Multifocal intracranial tumors
- Anaplastic histology
- All other CNS embryonal tumors and pineoblastomas
- > 1.5 cm² residual tumor area on postoperative MRI and age <3 years

Individuals without any high-risk features are considered “Average Risk”

General Considerations:

- Account for 15% to 25% of pediatric CNS tumors
- Prognosis is generally favorable
- Leptomeningeal spread is common and can occur after initial diagnosis

Treatment Considerations:

- Individuals generally proceed to chemoradiotherapy within 31 days of surgical resection
 - All individuals receive adjuvant chemotherapy lasting 6 to 12 months that begins ~6 weeks after completion of chemoradiotherapy

Atypical Teratoid/Rhabdoid Tumors (ATRT) (PEDONC-4.5)

ONCP.CT.0004.5.A

v2.0.2024

- PET Brain Metabolic does not have a defined role in the evaluation of ATRT at this time
- MR Spectroscopy is not indicated for routine surveillance

Indication	Imaging Study
Initial staging for all individuals, preoperatively	<ul style="list-style-type: none"> • MRI Brain without and with contrast (CPT® 70553) • MRI Spine without and with contrast (Cervical-CPT® 72156, Thoracic-CPT® 72157, Lumbar-CPT® 72158) • Renal US (CPT® 76770) <ul style="list-style-type: none"> • If renal US is abnormal, refer to: <u>Malignant Rhabdoid Tumor of the Kidney (MRT) and Other Extracranial Sites (PEDONC-7.6)</u>
<ul style="list-style-type: none"> • <u>At any time, for ANY of the following:</u> <ul style="list-style-type: none"> • For rapid assessment in the acute setting • Evaluation of acute intracranial hemorrhage • Evaluation of ventriculomegaly • Evaluation of shunt-related issues 	<ul style="list-style-type: none"> • CT Head without contrast (CPT® 70450)
Evaluation of a brain lesion of indeterminate nature when the MRS findings will be used to determine whether biopsy/resection can be safely postponed	<ul style="list-style-type: none"> • MR Spectroscopy (CPT® 76390)
Postoperative (preferably within 48 hours of surgery) to quantify residual tumor volume	<ul style="list-style-type: none"> • MRI Brain without and with contrast (CPT® 70553)
Within 28 days post-op, if spinal imaging was not performed preoperatively	<ul style="list-style-type: none"> • MRI Spine without and with contrast (Cervical-CPT® 72156, Thoracic-CPT® 72157, Lumbar-CPT® 72158)

Indication	Imaging Study
Treatment response to induction chemotherapy	<ul style="list-style-type: none"> • <u>After every 2 cycles:</u> <ul style="list-style-type: none"> • MRI Brain without and with contrast (CPT® 70553) • MRI Spine without and with contrast (Cervical-CPT® 72156, Thoracic-CPT® 72157, Lumbar-CPT® 72158)
Individuals treated with consolidation chemotherapy and autologous stem cell rescue	<ul style="list-style-type: none"> • Disease evaluation is indicated following the end of the planned stem cell rescues but may occur prior to each cycle (every 4 to 6 weeks) if needed for response determination
End of treatment evaluation	<ul style="list-style-type: none"> • MRI Brain without and with contrast (CPT® 70553) • MRI Spine without and with contrast (Cervical-CPT® 72156, Thoracic-CPT® 72157, Lumbar-CPT® 72158)
Signs or symptoms of recurrence or progression	<ul style="list-style-type: none"> • MRI Brain without and with contrast (CPT® 70553) • MRI Spine without and with contrast (Cervical-CPT® 72156, Thoracic-CPT® 72157, Lumbar-CPT® 72158)
Surveillance	<ul style="list-style-type: none"> • <u>Every 3 months for 2 years, then every 6 months for 3 years, then annually for 10 years:</u> <ul style="list-style-type: none"> • MRI Brain without and with contrast (CPT® 70553) • MRI Spine without and with contrast (Cervical-CPT® 72156, Thoracic-CPT® 72157, Lumbar-CPT® 72158) • For additional imaging guidelines for individuals in long term follow up after CNS tumor treatment that included radiation therapy, see: <u>Second Malignant Neoplasms (SMN) (PEDONC-19.3)</u>

Background and Supporting Information

General Considerations:

- Highly aggressive tumor occurring primarily in very young children that has a clinical presentation very similar to medulloblastoma with a much higher rate of leptomeningeal spread.
- Metastases can occur outside the CNS, and associated tumors can also arise in the kidneys (Malignant Rhabdoid Tumor of the Kidney, MRT).
 - Rhabdoid malignancies occurring outside the CNS should be imaged according to **Malignant Rhabdoid Tumor of the Kidney (MRT) and Other Extracranial Sites (PEDONC-7.6)**.
- Overall prognosis is poor, with <20% of individuals surviving beyond 2 years from diagnosis.
- Individuals generally proceed to induction chemotherapy shortly following surgical resection or biopsy.
- Following completion of chemotherapy some individuals will proceed to radiotherapy.
 - MRI performed at the end of consolidation therapy should serve as the diagnostic MRI prior to radiotherapy.

Pineocytomas and Pineal Parenchymal Tumors (PEDONC-4.6)

ONCP.CT.0004.6.A

v2.0.2024

- PET Brain Metabolic imaging and MR Spectroscopy do not have a defined role in the evaluation of pineocytoma

Indication	Imaging Study
Initial staging for all individuals	<ul style="list-style-type: none"> • MRI Brain without and with contrast (CPT® 70553)
<ul style="list-style-type: none"> • Additional initial staging imaging for individuals with: <ul style="list-style-type: none"> • Multicentric tumors • Atypical histology including pineoblastoma-like elements (grade 2 or 3 pineal parenchymal tumor which have not been considered a pineoblastoma) • Clinical signs or symptoms suggesting spinal cord involvement 	<ul style="list-style-type: none"> • MRI Spine without and with contrast (Cervical-CPT® 72156, Thoracic-CPT® 72157, Lumbar-CPT® 72158)
Baseline imaging following resection	<ul style="list-style-type: none"> • MRI Brain without and with contrast (CPT® 70553)
End of radiotherapy	<ul style="list-style-type: none"> • MRI Brain without and with contrast (CPT® 70553)
Additional imaging at end of radiotherapy for individuals with measurable spinal cord disease on MRI	<ul style="list-style-type: none"> • MRI Spine without and with contrast (Cervical-CPT® 72156, Thoracic-CPT® 72157, Lumbar-CPT® 72158)
Surveillance	<ul style="list-style-type: none"> • MRI Brain without and with contrast (CPT® 70553) every 3 months for 1 year, then every 4 months for 1 year, then every 6 months for 1 year, then annually thereafter
Additional surveillance imaging for individuals with cord involvement at diagnosis	<ul style="list-style-type: none"> • MRI Spine without and with contrast (Cervical-CPT® 72156, Thoracic-CPT® 72157, Lumbar-CPT® 72158) after completion of therapy every 3 months for 1 year, then every 4 months for 1 year, then every 6 months for 1 year, then annually thereafter

Indication	Imaging Study
Signs or symptoms of recurrence or progression	<ul style="list-style-type: none">MRI Brain without and with contrast (CPT® 70553)
Suspected spinal cord recurrence or progression	<ul style="list-style-type: none">MRI Spine without and with contrast (Cervical-CPT® 72156, Thoracic-CPT® 72157, Lumbar-CPT® 72158)

Background and Supporting Information

General Considerations:

- Low grade malignancy that is similar in presentation to low grade glioma (LGG)
- Surgical resection is curative for most individuals
 - Individuals with a complete resection should then be imaged according to surveillance guidelines
- Individuals with incompletely resected tumors may receive adjuvant radiation therapy
 - After end of radiotherapy imaging, these individuals should be imaged according to surveillance guidelines

CNS Germinomas and Non-Germinomatous Germ Cell Tumors (NGGCT) (PEDONC-4.7)

ONCP.CT.0004.7.A

v2.0.2024

- PET Metabolic Brain imaging does not have a defined role in the evaluation of CNS GCT

Indication	Imaging Study
Initial staging for all individuals	<ul style="list-style-type: none"> • MRI Brain without and with contrast (CPT® 70553) • MRI Spine without and with contrast (Cervical-CPT® 72156, Thoracic-CPT® 72157, Lumbar-CPT® 72158)
<ul style="list-style-type: none"> • <u>At any time, for ANY of the following:</u> <ul style="list-style-type: none"> • For rapid assessment in the acute setting • Evaluation of acute intracranial hemorrhage • Evaluation of ventriculomegaly • Evaluation of shunt-related issues 	<ul style="list-style-type: none"> • CT Head without contrast (CPT® 70450)
Evaluation of a brain lesion of indeterminate nature when the MRS findings will be used to determine whether biopsy/resection can be safely postponed	<ul style="list-style-type: none"> • MR Spectroscopy (CPT® 76390)
Treatment response to induction chemotherapy	<ul style="list-style-type: none"> • MRI Brain without and with contrast (CPT® 70553) every 2 cycles
Additional treatment response to induction chemotherapy for individuals with measurable spinal cord disease on MRI	<ul style="list-style-type: none"> • MRI Spine without and with contrast (Cervical-CPT® 72156, Thoracic-CPT® 72157, Lumbar-CPT® 72158) every 2 cycles
End of induction chemotherapy for individuals with localized intracranial tumors	<ul style="list-style-type: none"> • MRI Spine without and with contrast (Cervical-CPT® 72156, Thoracic-CPT® 72157, Lumbar-CPT® 72158)
Prior to second-look surgery	<ul style="list-style-type: none"> • MRI of all known sites of measurable disease

Indication	Imaging Study
Prior to radiotherapy	<ul style="list-style-type: none"> MRI of all known sites of measurable disease
At the end of all planned therapy	<ul style="list-style-type: none"> MRI Brain without and with contrast (CPT® 70553) MRI Spine (with or without and with contrast)
Signs or symptoms of recurrence or progression	<ul style="list-style-type: none"> MRI Brain without and with contrast (CPT® 70553) MRI Spine without and with contrast (Cervical-CPT® 72156, Thoracic-CPT® 72157, Lumbar-CPT® 72158)
Surveillance	<ul style="list-style-type: none"> <u>Every 3 months for 1 year, then every 4 months for 1 year, then every 6 months for 1 year, then annually until 5 years after completion of therapy:</u> <ul style="list-style-type: none"> MRI Brain without and with contrast (CPT® 70553) MRI Spine without and with contrast (Cervical-CPT® 72156, Thoracic-CPT® 72157, Lumbar-CPT® 72158) For additional imaging guidelines for individuals in long term follow up after CNS tumor treatment that included radiation therapy, see: <u>Second Malignant Neoplasms (SMN) (PEDONC-19.3)</u>
Suspected recurrence - new or worsening neurologic symptoms (including worsening of diabetes insipidus)	<ul style="list-style-type: none"> MRI Brain without and with contrast (CPT® 70553) MRI Spine without and with contrast (Cervical-CPT® 72156, Thoracic-CPT® 72157, Lumbar-CPT® 72158)

Background and Supporting Information

Includes the following tumors:

- CNS Germinoma
- Non-Germinomatous Germ Cell Tumors (NGGCT)
 - Embryonal carcinoma
 - Yolk sac tumor
 - Choriocarcinoma
 - Immature Teratoma
 - Mature Teratoma
 - Mixed germ cell tumor

General Considerations:

- More common in older school age children and younger adolescents, but can occur throughout the pediatric age range
- Although leptomeningeal spread is common, prognosis is excellent due to high sensitivity to chemotherapy and radiotherapy
- Individuals generally proceed to chemotherapy shortly following surgical resection or biopsy and will usually receive 2 to 4 cycles
- Following completion of chemotherapy, individuals with residual disease will proceed to second-look surgery and/or radiotherapy

Ependymal Tumors (Ependymoma) (PEDONC-4.8)

ONCP.CT.0004.8.A

v2.0.2024

- PET Brain Metabolic imaging does not have a defined role in the evaluation of ependymal tumors
- MR Spectroscopy is not indicated for routine surveillance

Indication	Imaging Study
Initial staging for all individuals	<ul style="list-style-type: none"> • MRI Brain without and with contrast (CPT® 70553) • MRI Spine without and with contrast (Cervical-CPT® 72156, Thoracic-CPT® 72157, Lumbar-CPT® 72158)
Evaluation of a brain lesion of indeterminate nature when the MRS findings will be used to determine whether biopsy/resection can be safely postponed	<ul style="list-style-type: none"> • MR Spectroscopy (CPT® 76390)
Baseline imaging following resection	<ul style="list-style-type: none"> • MRI Brain without and with contrast (CPT® 70553) or MRI without and with contrast of involved spinal level(s)
Completion of radiotherapy	<ul style="list-style-type: none"> • MRI Brain without and with contrast (CPT® 70553) or MRI without and with contrast of involved spinal level(s)
Prior to radiotherapy	<ul style="list-style-type: none"> • MRI of all known sites of measurable disease
Treatment response to induction chemotherapy	<ul style="list-style-type: none"> • MRI Brain without and with contrast (CPT® 70553) or MRI without and with contrast of involved spinal level(s) every 2 cycles
End of induction chemotherapy and again at end of all therapy	<ul style="list-style-type: none"> • MRI Brain without and with contrast (CPT® 70553) • MRI Spine without and with contrast (Cervical-CPT® 72156, Thoracic-CPT® 72157, Lumbar-CPT® 72158)
Prior to second-look surgery	<ul style="list-style-type: none"> • MRI of all known sites of measurable disease

Indication	Imaging Study
Signs or symptoms of recurrence or progression	<ul style="list-style-type: none"> • MRI Brain without and with contrast (CPT® 70553) • MRI Spine without and with contrast (Cervical-CPT® 72156, Thoracic-CPT® 72157, Lumbar-CPT® 72158)
Surveillance, primary intracranial ependymal tumor and NO history of spinal cord involvement	<ul style="list-style-type: none"> • MRI Brain without and with contrast (CPT® 70553) every 3 months for 2 years, then every 4 months for 1 year, then every 6 months in years 4 and 5, then annually to 10 years post treatment • For additional imaging guidelines for individuals in long term follow up after CNS tumor treatment that included radiation therapy, see: <u>Second Malignant Neoplasms (SMN) (PEDONC-19.3)</u> • MRI Spine without and with contrast (Cervical-CPT® 72156, Thoracic-CPT® 72157, Lumbar-CPT® 72158) can be approved annually for 2 years
Surveillance, primary intracranial ependymal tumor AND metastatic cord involvement at diagnosis	<ul style="list-style-type: none"> • MRI Brain without and with contrast (CPT® 70553) every 3 months for 2 years, then every 4 months for 1 year, then every 6 months in years 4 and 5, then annually to 10 years post treatment • For additional imaging guidelines for individuals in long term follow up after CNS tumor treatment that included radiation therapy, see: <u>Second Malignant Neoplasms (SMN) (PEDONC-19.3)</u> • MRI Spine without and with contrast (Cervical-CPT® 72156, Thoracic-CPT® 72157, Lumbar-CPT® 72158) every 3 months for 2 years, then every 4 months for 1 year, then every 6 months in years 4 and 5, then annually to 10 years post treatment

Indication	Imaging Study
Surveillance, primary <u>intra</u> spinal ependymal tumor and NO history of intracranial involvement	<ul style="list-style-type: none"> • MRI without and with contrast of the involved spinal level(s) every 3 months for 2 years, then every 4 months for 1 year, then every 6 months in years 4 and 5, then annually to 10 years post treatment
Surveillance, primary <u>intra</u> spinal ependymal tumor AND metastatic intracranial involvement at diagnosis	<ul style="list-style-type: none"> • MRI of the involved spinal level(s) without and with contrast every 3 months for 2 years, then every 4 months for 1 year, then every 6 months in years 4 and 5, then annually to 10 years post treatment • MRI Brain without and with contrast (CPT® 70553) every 3 months for 2 years, then every 4 months for 1 year, then every 6 months in years 4 and 5, then annually to 10 years post treatment

Background and Supporting Information

Includes the following tumors:

- Ependymal tumors
 - Supratentorial ependymoma
 - ZFTA fusion-positive Supratentorial ependymoma
 - YAP1 fusion-positive Posterior fossa ependymoma
 - Posterior fossa ependymoma, group
 - PFA Posterior fossa ependymoma, group PFB

General Considerations:

- Occur primarily intracranially, roughly 2/3 in the posterior fossa
- Overall prognosis is very good, with supratentorial tumors faring better
- Primary spinal tumors can also occur, and are more common in adult individuals than pediatric individuals.
- Surgery is the primary treatment modality
- Individuals with a complete resection should then be imaged according to surveillance guidelines
- Radiotherapy +/- chemotherapy is used for:
 - Incompletely resected tumors
 - Anaplastic histology

- Infratentorial location
 - Individuals with incomplete resection or high-risk histology that receive adjuvant radiation therapy should then be imaged according to surveillance guidelines after end of radiotherapy imaging.
- Individuals with gain of chromosome 1q have worse progression-free survival and overall survival outcomes
- RELA-fusion supratentorial ependymoma did not portend worse overall survival outcomes in recent Clinical Oncology Group studies, and is generally not considered an indication for more frequent surveillance imaging

Malignant Tumors of the Spinal Cord (PEDONC-4.9)

ONCP.CT.0004.9.A

v2.0.2024

- If a disease-specific guideline exists, image according to the guidance found in that disease-specific guideline section.
- Common histologies of primary spinal cord tumor in children include:
 - Low Grade Glioma, see: **CNS Low Grade Glioma (LGG) (PEDONC-4.2)** for guidelines
 - High Grade Glioma, see: **CNS High-Grade Glioma (HGG) (PEDONC-4.3)** for guidelines
 - Ependymoma, see: **Ependymal Tumors (Ependymoma) (PEDONC-4.8)** for guidelines
 - NF 1 or 2, see **Neurofibromatosis 1 and 2 (NF1 and NF2) (PEDONC-2.3)** for guidelines
 - Any type of malignant spinal cord tumor can occur, but other histologies are rare.

For rare histologies that do not have a disease-specific guideline section, follow the imaging outlined in the table below

Indication	Imaging Study
Initial staging for all individuals	<ul style="list-style-type: none"> • MRI Brain without and with contrast (CPT® 70553) • MRI Spine without and with contrast (Cervical-CPT® 72156, Thoracic-CPT® 72157, Lumbar-CPT® 72158)
Treatment response, every 2 cycles	<ul style="list-style-type: none"> • MRI Spine without and with contrast (Cervical-CPT® 72156, Thoracic-CPT® 72157, Lumbar-CPT® 72158) • Additionally, MRI Brain without and with contrast (CPT® 70553) for known intracranial disease
Signs or symptoms of recurrence or progression	<ul style="list-style-type: none"> • MRI Spine without and with contrast (Cervical-CPT® 72156, Thoracic-CPT® 72157, Lumbar-CPT® 72158) • Additionally, MRI Brain without and with contrast (CPT® 70553) for known intracranial disease

Indication	Imaging Study
<p>Surveillance of rare histologies is highly individualized.</p> <p>Surveillance imaging after recent evaluation by a physician with significant training and/or experience in pediatric spinal cord tumors (most commonly a pediatric neurosurgeon or pediatric oncologist) may be indicated in these rare individuals.</p>	<ul style="list-style-type: none">• MRI Brain and/or MRI Spine may be considered

Background and Supporting Information

- Treatment principles are the same as tumors of the brain, and should follow imaging guidelines according to the specific histologic type
- Multiple spinal cord tumors should raise suspicion for neurofibromatosis
- Asymptomatic surveillance imaging should generally end at the time point appropriate for the specific tumor type

Craniopharyngioma and Other Tumors of the Sellar Region (PEDONC-4.10)

ONCP.CT.0004.10.A

v2.0.2024

- Individuals of all ages should be imaged according to these guidelines.
- PET Brain Metabolic Imaging and MR Spectroscopy do not have a defined role in the evaluation of craniopharyngioma

Indication	Imaging Study
Initial staging for all individuals	<ul style="list-style-type: none"> • MRI Brain without and with contrast (CPT® 70553) <ul style="list-style-type: none"> • Concurrent CT Head without contrast (CPT® 70450) can be approved in addition to MRI if craniopharyngioma is suspected
<ul style="list-style-type: none"> • <u>Additional initial staging for individuals with:</u> <ul style="list-style-type: none"> • Multicentric tumors • Clinical signs or symptoms suggesting spinal cord involvement 	<ul style="list-style-type: none"> • MRI Spine without and with contrast (Cervical-CPT® 72156, Thoracic-CPT® 72157, Lumbar-CPT® 72158)
Operative planning or image guidance	<ul style="list-style-type: none"> • MRA Head (CPT® 70544, 70545, or 70546) OR • CTA Head (CPT® 70496)
Baseline imaging following resection	<ul style="list-style-type: none"> • MRI Brain without and with contrast (CPT® 70553)
Completion of radiotherapy	<ul style="list-style-type: none"> • MRI Brain without and with contrast (CPT® 70553)
Treatment response to chemotherapy	<ul style="list-style-type: none"> • MRI Brain without and with contrast (CPT® 70553) approved every 2 cycles during active treatment and at the end of planned chemotherapy
Additional treatment response imaging during induction chemotherapy for individuals with measurable spinal cord disease on MRI	<ul style="list-style-type: none"> • MRI Spine without and with contrast (Cervical-CPT® 72156, Thoracic-CPT® 72157, Lumbar-CPT® 72158) every 2 cycle

Indication	Imaging Study
Signs or symptoms of recurrence or progression	<ul style="list-style-type: none"> • MRI Brain without and with contrast (CPT® 70553) <ul style="list-style-type: none"> • Concurrent CT Head without contrast (CPT® 70450) can be approved in addition to MRI if craniopharyngioma • MRI Spine without and with contrast (Cervical-CPT® 72156, Thoracic-CPT® 72157, Lumbar-CPT® 72158) for signs or symptoms suggesting spinal cord involvement
Surveillance	<ul style="list-style-type: none"> • MRI Brain without and with contrast (CPT® 70553) can be approved every 3 months for 1 year, then every 4 months for 1 year, then every 6 months for 1 year, then annually until 10 years after completion of therapy as late progressions can occur <ul style="list-style-type: none"> • For additional imaging guidelines for individuals in long term follow up after CNS tumor treatment that included radiation therapy, see: <u>Second Malignant Neoplasms (SMN) (PEDONC-19.3)</u>
Suspected spinal cord recurrence	<ul style="list-style-type: none"> • MRI Spine without and with contrast (Cervical-CPT® 72156, Thoracic-CPT® 72157, Lumbar-CPT® 72158)

Background and Supporting Information

Includes the following tumors:

- Adamantinomatous craniopharyngioma
- Papillary craniopharyngioma
- Pituicytoma, granular cell tumor of the sellar region, and spindle cell oncocytoma
- Pituitary adenoma/PitNET
- Pituitary blastoma

General Considerations:

- Imaging guidelines and treatment approaches for pediatric pituitary tumors other than craniopharyngioma are consistent with those used for adults with pituitary tumors

- For these tumors follow guidelines in **Pituitary (HD-19)** in the Head Imaging Guidelines
- Craniopharyngiomas are less common, accounting for 6% to 8% of pediatric CNS tumors.
- Most commonly affects children in the preadolescent ages
- Several key imaging findings can be used to differentiate the tumors in this region including the presence of calcifications, cysts, and T1/T2 enhancement patterns in craniopharyngiomas
 - These are best evaluated using a COMBINATION of both MRI and CT modalities. Preoperative prediction is much more successful when BOTH modalities are obtained prior to biopsy.
- Other less common tumors in the optic chiasm, sella, and suprasella region may include Germ Cell Tumors (GCT, see: **PEDONC-4.7**) and Langerhans Cell Histiocytosis (LCH, see: **PEDONC-18**)

Treatment Considerations:

- Surgical resection is curative for many individuals
 - Those with a complete resection should then be imaged according to surveillance guidelines after post-resection imaging is completed
- Individuals with incomplete resection and receiving adjuvant radiation therapy can have a single MRI Brain (CPT® 70553) approved at completion of radiotherapy and should then be imaged according to surveillance guidelines

Primary CNS Lymphoma (PEDONC-4.11)

ONCP.CT.0004.11.A

v2.0.2024

- Primary CNS lymphoma imaging indications in pediatric individuals are identical to those in the general imaging guidelines. See: **CNS Lymphoma (ONC-2.7)** in the Oncology Imaging Guidelines
- CNS lymphomas also involving bone marrow and/or lymph nodes should be imaged according to: **Pediatric Aggressive Mature B-Cell Non-Hodgkin Lymphomas (NHL) (PEDONC-5.3)**

Background and Supporting Information

- Primary CNS lymphoma is a solitary or multifocal mass occurring in the brain without evidence of systemic (bone marrow or lymph node) involvement
- Usually associated with immunodeficiency, this is a very rare entity in pediatrics accounting for <0.1% of pediatric malignancies, so age-specific guidelines have not been established

Meningiomas (PEDONC-4.12)

ONCP.CT.0004.12.A
v2.0.2024

- Meningioma imaging indications in pediatric individuals are identical to those in the general imaging guidelines
 - See: **Meningiomas (Intracranial and Intraspinal) (ONC-2.8)** in the Oncology Imaging Guidelines

Background and Supporting Information

- Account for 1% to 3% of pediatric CNS tumors
- Usually associated with neurofibromatosis type 2 (NF-2) or prior therapeutic radiation exposure to the brain
 - Lifetime risk may be as high as 20% for young children receiving whole brain radiotherapy, most commonly occurring 15 to 20 years after radiation exposure

Choroid Plexus Tumors (PEDONC-4.13)

ONCP.CT.0004.13.A

v2.0.2024

- PET Metabolic Brain imaging does not have a defined role in the evaluation of choroid plexus tumors

Choroid Plexus Papilloma:

Indication	Imaging Study
Suspected/Diagnosis	<ul style="list-style-type: none"> • MRI Brain without and with contrast (CPT® 70553)
Evaluation of a brain lesion of indeterminate nature when the MRS findings will be used to determine whether biopsy/resection can be safely postponed	<ul style="list-style-type: none"> • MR Spectroscopy (CPT® 76390)
Suspected return of hydrocephalus, or return of hydrocephalus seen on CT imaging	<ul style="list-style-type: none"> • MRI Brain without and with contrast (CPT® 70553)

Choroid Plexus Adenoma or Atypical Choroid Plexus Papilloma:

Indication	Imaging Study
Suspected/Diagnosis	<ul style="list-style-type: none"> • MRI Brain without and with contrast (CPT® 70553) • MRI Spine without and with contrast (Cervical-CPT® 72156, Thoracic-CPT® 72157, Lumbar-CPT® 72158)
Evaluation of a brain lesion of indeterminate nature when the MRS findings will be used to determine whether biopsy/resection can be safely postponed	<ul style="list-style-type: none"> • MR Spectroscopy (CPT® 76390)
Suspected return of hydrocephalus, or return of hydrocephalus seen on CT imaging	<ul style="list-style-type: none"> • MRI Brain without and with contrast (CPT® 70553)

Choroid Plexus Carcinoma:

Indication	Imaging Study
Initial staging of all individuals	<ul style="list-style-type: none"> • MRI Brain without and with contrast (CPT® 70553) • MRI Spine without and with contrast (Cervical-CPT® 72156, Thoracic-CPT® 72157, Lumbar-CPT® 72158)
Evaluation of a brain lesion of indeterminate nature when the MRS findings will be used to determine whether biopsy/resection can be safely postponed	<ul style="list-style-type: none"> • MR Spectroscopy (CPT® 76390)
Baseline imaging following resection	<ul style="list-style-type: none"> • MRI Brain without and with contrast (CPT® 70553)
Prior to radiotherapy	<ul style="list-style-type: none"> • MRI Brain without and with contrast (CPT® 70553) and MRI with and without contrast of all known sites with measurable disease prior to radiotherapy.
Completion of radiotherapy	<ul style="list-style-type: none"> • MRI Brain without and with contrast (CPT® 70553)
Treatment response to chemotherapy	<ul style="list-style-type: none"> • MRI Brain without and with contrast (CPT® 70553) every 2 cycles during active treatment
Additional treatment response to chemotherapy for individuals with measurable spinal cord disease on MRI	<ul style="list-style-type: none"> • MRI Spine without and with contrast (Cervical-CPT® 72156, Thoracic-CPT® 72157, Lumbar-CPT® 72158) every 2 cycles during active treatment
Prior to second-look surgery	<ul style="list-style-type: none"> • MRI of all known sites of measurable disease
End of all planned therapy	<ul style="list-style-type: none"> • MRI Brain without and with contrast (CPT® 70553) • MRI Spine without and with contrast (Cervical-CPT® 72156, Thoracic-CPT® 72157, Lumbar-CPT® 72158)
Signs or symptoms of recurrence or progression	<ul style="list-style-type: none"> • MRI Brain without and with contrast (CPT® 70553) • MRI Spine without and with contrast (Cervical-CPT® 72156, Thoracic-CPT® 72157, Lumbar-CPT® 72158)

Indication	Imaging Study
Surveillance, no history of spinal cord involvement	<ul style="list-style-type: none"> • MRI Brain without and with contrast (CPT® 70553) every 4 months for 3 years, then every 6 months for 2 years after completion of therapy, then annually to 10 years after treatment <ul style="list-style-type: none"> • For additional imaging guidelines for individuals in long term follow up after CNS tumor treatment that included radiation therapy, see: Second Malignant Neoplasms (SMN) (PEDONC-19.3) • MRI Spine without and with contrast (Cervical-CPT® 72156, Thoracic-CPT® 72157, Lumbar-CPT® 72158) at 12 and 24 months after completion of therapy
Surveillance, individuals with cord involvement at diagnosis	<ul style="list-style-type: none"> • MRI Brain without and with contrast (CPT® 70553) every 4 months for 3 years, then every 6 months for 2 years after completion of therapy, then annually to 10 years after treatment <ul style="list-style-type: none"> • For additional imaging guidelines for individuals in long term follow up after CNS tumor treatment that included radiation therapy, see: Second Malignant Neoplasms (SMN) (PEDONC-19.3) • MRI Spine without and with contrast (Cervical-CPT® 72156, Thoracic-CPT® 72157, Lumbar-CPT® 72158) every 4 months for 3 years, then every 6 months for 2 years after completion of therapy, then annually to 10 years after treatment

Background and Supporting Information

- As a group these account for 1% to 4% of pediatric CNS tumors, and 70% of choroid plexus tumors present within the first 2 years of life
- Includes the following tumors:
 - Choroid plexus papilloma
 - Choroid plexus adenoma, or atypical choroid plexus papilloma
 - Choroid plexus carcinoma
- Choroid plexus papillomas

- Choroid plexus papillomas outnumber other choroid plexus tumors by 4 to 5 times.
- These ventricular tumors commonly present with hydrocephalus caused by increased CSF production, resulting in signs of increased intracranial pressure.
- Appearance on MRI is typical, and they are usually treated by excision.
- Regrowth is rare
- Choroid Plexus Adenoma or Atypical Choroid Plexus Papilloma
 - These are extremely rare tumors with features midway in the malignant spectrum between papillomas and carcinomas
 - They are more prone to local invasion but rarely to metastasis
 - Presenting symptoms are similar to papillomas
 - Appearance on MRI is typical, and they are usually treated by excision
 - Spinal imaging may be approved if requested at initial diagnosis
 - Regrowth is rare
- Choroid Plexus Carcinoma
 - This is a very aggressive malignancy, with high rates of metastasis to other parts of the CNS
 - Overall incidence of metastases in choroid plexus carcinoma is 12%–50%, which is associated with a worse outcome
 - Prognosis is significantly less favorable than for papillomas with overall survival rates of 35% to 40%
 - *TP53* mutations and alternative lengthening telomeres (ALT) are common in individuals with choroid plexus carcinoma
 - Surgical gross total resection is curative for many individuals
 - Individuals with confirmed gross total resection should then be imaged according to surveillance guidelines
 - Individuals with incomplete resection who receive adjuvant radiation therapy should be imaged according to surveillance guidelines after end of radiotherapy imaging
 - MR Spectroscopy is not indicated for routine surveillance

References (PEDONC-4)

v2.0.2024

1. Parsons DW, Pollack IF, Hass-Kogan DA, et al. Gliomas, ependymomas, and other nonembryonal tumors of the central nervous system. In: Pizzo PA, Poplack DG, eds. Principles and Practice of Pediatric Oncology. 7th ed. Philadelphia, PA: Wolters Kluwer; 2016:628-670.
2. Chintagumpala MM, Paulino A, Panigraphy A, et al. Embryonal and pineal region tumors. In: Pizzo PA, Poplack DG, eds. Principles and Practice of Pediatric Oncology. 7th ed. Philadelphia, PA: Wolters Kluwer; 2016:671-699.
3. Kieran MW, Chi SN, Manley PE, et al. Tumors of the Brain and Spinal Cord. In: Orkin SH, Fisher DE, Ginsburg D, Look AT, Lux SE, Nathan DG, eds. Nathan and Oski's Hematology and Oncology of Infancy and Childhood. 8th ed. Philadelphia, PA: Elsevier Saunders; 2015:1779-1885.
4. Nabors LB, Portnow J, Baehring J, et al. National Comprehensive Cancer Network (NCCN) Guidelines Version 1.2023—March 24, 2023. Central Nervous System Cancers, available at: https://www.nccn.org/professionals/physician_gls/pdf/cns.pdf, referenced with permission from the NCCN Clinical Practice Guidelines in Oncology (NCCN Guidelines™) for Central Nervous System Cancers V1.2023 3/24/2023. ©2023 National Comprehensive Cancer Network, Inc. All rights reserved. The NCCN Guidelines™ and illustrations herein may not be reproduced in any form for any purpose without the express written permission of the NCCN. To view the most recent and complete version of the NCCN Guidelines™, go online to NCCN.org.
5. Menashe SJ, Iyer RS. Pediatric Spinal neoplasia: a practical imaging overview of intramedullary, intradural, and osseous tumors. *Curr Probl Diagn Radiol*. 2013;42(6):249-265. doi:10.1067/j.cpradiol.2013.05.003.
6. Warmuth-Metz M. Imaging guidelines for pediatric brain tumor patients. In: Warmuth-Metz M, ed. Imaging and Diagnosis in Pediatric Brain Tumor Studies. Switzerland; Springer, Cham:2017:55-67. https://doi.org/10.1007/978-3-319-42503-0_4
7. Warren KW, Poussaint TY, Vezina G, et al. Challenges with defining response to antitumor agents in pediatric neuro-oncology: a report from the response assessment in pediatric neuro-oncology (RAPNO) working group. *Pediatr Blood Cancer*. 2013;60(9):1397-1401. doi:10.1002/pbc.24562.
8. Zukotynski K, Fahey F, Kocak M, et al. 18F-FDG PET and MR Imaging associations across a spectrum of pediatric brain tumors: a report from the Pediatric Brain Tumor Consortium. *J Nucl Med*. 2014;55(9):1473-1480. doi:10.2967/jnumed.114.139626.
9. Gajjar A, Bowers DC, Karajannis MA, Leary S, Witt H, Gottardo NG. Pediatric brain tumors: innovative genomic information is transforming the diagnostic and clinical landscape. *J Clin Oncol*. 2015;33(27):2986-2998. doi:10.1200/JCO.2014.59.9217.
10. Brandão LA, Poussaint TY. Pediatric brain tumors. *Neuroimag Clin N Am*. 2013 August;23(3):499-525. Accessed January 3, 2018. [http://www.neuroimaging.theclinics.com/article/S1052-5149\(13\)00017-8/abstract](http://www.neuroimaging.theclinics.com/article/S1052-5149(13)00017-8/abstract). <https://www.ncbi.nlm.nih.gov/pubmed/23928202>
11. Brandão LA and Castillo M. Adult brain tumors: clinical applications of magnetic resonance spectroscopy. *Neuroimag Clin N Am*. 2013;23(3):527-555. doi:10.1016/j.nic.2013.03.003
12. Zarifi M, Tzika AA. Proton MRS imaging in pediatric brain tumors. *Pediatr Radiol*. 2016;46(7):952-962. doi:10.1007/s00247-016-3547-5. <https://doi.org/10.1007/s00247-016-3547-5>
13. Uslu L, Doing J, Link M, Rosenberg J, Quon A, Daldrup-Link HE. Value of 18F-FDG-PET and PET/CT for evaluation of pediatric malignancies. *J Nucl Med*. 2015;56(2):274-286. doi:10.2967/jnumed.114.146290.
14. Soffietti R, Baumert BG, Bello L, et al. Guidelines on management of low-grade gliomas: report of an EFSN-EANO* Task Force. *Eur J Neurol*. 2010;17(9):1124-1133. doi:10.1111/j.1468-1331.2010.03151.x.
15. Kruer MC, Kaplan AM, Etzl MM Jr, et al. The value of positron emission tomography and proliferation index in predicting progression in low-grade astrocytomas of childhood. *J Neurooncol*. 2009;95(2):239-245. doi:10.1007/s11060-009-9922-4.
16. Chamdine O, Broniscer A, Wu S, Gajjar A, Qaddoumi I. Metastatic low-grade gliomas in children: 20 years' experience at St. Jude Children's Research Hospital. *Pediatr Blood Cancer*. 2016;63(1):62-70. doi:10.1002/pbc.25731. <https://doi.org/10.1007/s11060-009-9922-4>
17. Chalil A, Ramaswamy V. Low grade gliomas in children. *J Child Neurol*. 2016;31(4):517-522. doi:10.1177/0883073815599259.
18. Krishnatry R, Zhukova N, Stucklin ASG, et al. Clinical and treatment factors determining long-term outcomes for adult survivors of childhood low-grade glioma: a population-based study. *Cancer*. 2016;122(8):1261-1269. doi:10.1002/cncr.29907.
19. Ullrich NJ. Neurocutaneous Syndromes and brain tumors. *J Child Neurol*. 2016;31(12):1399-1411. doi:10.1177/0883073815604220.
20. Campian J, Gutmann DH. CNS tumors in neurofibromatosis. *J Clin Oncol*. 2017; 35(21):2378-2385. doi:10.1200/JCO.2016.71.7199.

21. Morris EB, Gajjar A, Okuma JO, et al. Survival and late mortality in long-term survivors of pediatric CNS tumors. *J Clin Oncol*. 2007;25(12):1532-1538. doi:10.1200/JCO.2006.09.8194.
22. Karthigeyan M, Gupta K, Salunke P. Pediatric central neurocytoma: a short series with literature review. *J Child Neurol*. 2016;32(1):53-59. Accessed January 3, 2018 doi:10.1177/0883073816668994.
23. Tisnado J, Young R, Peck KK, et al. Conventional and advanced imaging of diffuse intrinsic pontine glioma. *J Child Neurol*. 2016;31(12):1386-1393. doi:10.1177/0883073816634855.
24. Greenfield JP, Heredia AC, George E, Keiran MW, Morales La Madrid A. Gliomatosis cerebri: a consensus summary report from the First International Gliomatosis cerebri Group Meeting, March 26-27, 2015, Paris, France. *Pediatr Blood Cancer*. 2016;63(12):2072-2077. doi:10.1002/pbc.26169.
25. Zaky W, Dhall G, Ji L, et al. Intensive induction chemotherapy followed by myeloablative chemotherapy with autologous hematopoietic progenitor cell rescue for young children newly-diagnosed with central nervous system atypical teratoid/rhabdoid tumors: the head start III experience. *Pediatr Blood Cancer*. 2014;61(1):95-101. doi:10.1002/pbc.24648.
26. Gururangan S, Hwang E, Herndon JE II, et al. [18F]Fluorodeoxyglucose-Positron Emission Tomography in patients with medulloblastoma. *Neurosurgery*. 2004;55(6):1280-1289. doi:10.1227/01.NEU.0000143027.41632.2B.
27. Millard NE and DeBraganca KC. Medulloblastoma. *J Child Neurol*. 2016;31(12):1341-1353. doi:10.1177/0883073815600866.
28. Koschmann C, Bloom K, Upadhyaya S, Geyer JR. Survival after relapse of medulloblastoma. *J Pediatr Hematol. Oncol*. 2016;38(4):269-273. doi:10.1097/MPH.0000000000000547.
29. Martinex S, Khakoo Y, Giheeney S, et al. Marker (+) CNS germ cell tumors in remission: are surveillance MRI scans necessary? *Pediatr Blood Cancer*. 2014;61(5):853-854. Accessed January 3, 2018. doi:10.1002/pbc.24888.
30. Goldman S, Bouffet E, Fisher PG, et al. Phase II trial assessing the ability of neoadjuvant chemotherapy with or without second-look surgery to eliminate measurable disease for nongerminomatous germ cell tumors: a children's oncology group study. *J Clin Oncol*. 2015;33(22):2464-2471. doi:10.1200/JCO.2014.59.5132.
31. Abu Arja MH, Bouffet E, Finlay JL, AbdelBaki MS. Critical review of the management of primary central nervous system germ cell tumors. *Pediatr Blood Cancer*. 2019;66:e27658. doi:10.1002/pbc.27658.
32. Vitanza NA, Partap S. Pediatric Ependymoma. *J Child Neurol*. 2016;31(12):1354-1366. doi:10.1177/0883073815610428
33. Norris GA, Garcia J, Hankinson TC, et al. Diagnostic accuracy of neuroimaging in pediatric optic chiasm/suprasellar tumors. *Pediatr Blood Cancer*. 2019;66:e27860. doi:10.1002/pbc.27680.
34. McCrea HJ, George E, Settler A, et al. Pediatric suprasellar tumors. *J Child Neurol*. 2016;31(12):1367-1376. doi:10.1177/0883073815620671.
35. Grommes C, DeAngelis LM. Primary CNS lymphoma. *J Clin Oncol*. 2017;35(21):2410-2418. doi:10.1200/JCO.2017.72.7602.
36. Larrew T, Eskandari R. Pediatric intraparenchymal meningioma, case report and comparative review. *Pediatr Neurosurg*. 2016;51(2):83-86. doi:10.1159/000441008.
37. Li Z, Li H, Wang S, et al. Pediatric skull base meningiomas: clinical features and surgical outcomes. *J Child Neurol*. 2016;31(14):1523-1527. doi:10.1177/0883073816664669.
38. Horská A, Barker PB. Imaging of brain tumors: MR Spectroscopy and metabolic imaging. *Neuroimaging Clin N Am*. 2010;20(3):293-310. doi:10.1016/j.nic.2010.04.003.
39. Sundgren PC. MR Spectroscopy in radiation injury. *AJNR Am J Neuroradiol*. 2009;30(8):1469-1476. doi:10.3174/ajnr.A1580.
40. Zaky W, Dhall G, Khatua S, et al. Choroid plexus carcinoma in children: the head start experience. *Pediatr Blood Cancer*. 2015;62(5):784-789. doi:10.1002/pbc.25436.
41. Zaky W, Finlay JL. Pediatric choroid plexus carcinoma: Biologically and clinically in need of new perspectives. *Pediatr Blood Cancer*. 2018;65:e27031. doi:10.1002/pbc.27031.
42. Kramer K. Rare primary central nervous system tumors encountered in pediatrics. *J Child Neurol*. 2016;31(12):1394-1398. doi:10.1177/0883073815627878.
43. Merchant TE, Bendel AE, Sabin ND, et al. Conformal radiation therapy for pediatric ependymoma, chemotherapy for incompletely resected ependymoma, and observation for completely resected, supratentorial ependymoma. *J Clin Oncol*. 2019;37(12):974-983. doi:10.1200/JCO.18.01765.
44. PDQ® Pediatric Treatment Editorial Board. PDQ Childhood Medulloblastoma and Other Central Nervous System Embryonal Tumors Treatment. Bethesda, MD: National Cancer Institute. Updated 4/12/2023. Available at: <https://www.cancer.gov/types/brain/hp/child-cns-embryonal-treatment-pdq>. [PMID: 26389418].
45. Burns J, Policeni B, Bykowski J, et al. ACR Appropriateness Criteria® Neuroendocrine Imaging. Available at <https://acsearch.acr.org/docs/69485/Narrative/>. American College of Radiology. Accessed 7/21/2020.
46. Klawinski D, Indelicato DJ, Hossain J, Sandler E. Surveillance imaging in pediatric ependymoma. *Pediatr Blood Cancer*. 2020;67(11):e28622. doi:10.1002/pbc.28622.

47. Massimino M, Barretta F, Modena P, et al. Pediatric intracranial ependymoma: correlating signs and symptoms at recurrence with outcome in the second prospective AIEOP protocol follow-up. *J Neurooncol.* 2018;140(2):457-465. doi:10.1007/s11060-018-2974-6.
48. Gajjar A, Mahajan A, Abdelbaki M, et al. National Comprehensive Cancer Network (NCCN) Guidelines Version 2.2023—October 31,2022. Pediatric Central Nervous System Cancers, available at: https://www.nccn.org/professionals/physician_gls/pdf/ped_cns.pdf, referenced with permission from the NCCN Clinical Practice Guidelines in Oncology (NCCN Guidelines™) for Central Nervous System Cancers V2.2023 10/31/2022. ©2022 National Comprehensive Cancer Network, Inc. All rights reserved. The NCCN Guidelines™ and illustrations herein may not be reproduced in any form for any purpose without the express written permission of the NCCN. To view the most recent and complete version of the NCCN Guidelines™, go online to NCCN.org.
49. Jaju A, Li Y, Dahmouh H, et. al. Imaging of pediatric brain tumors: A COG Diagnostic Imaging Committee/SPR Oncology Committee/ASPNR white paper. *Pediatr Blood Cancer.* 2023;70 Suppl 4:e30147. doi:10.1002/pbc.30147.
50. Louis DN, Perry A, Wesseling P. et al. The 2021 WHO classification of tumors of the central nervous system: a summary. *Neuro-Oncology.* 2021;23(8):1231–1251.doi:10.1093/neuonc/noab106.
51. Rootman MS, Dotan G, Konen O. Neuroimaging in children with ophthalmological complaints: a review. *J Neuroimaging.* 2021;31(3):446-458. doi:10.1111/jon.12842.
52. Hande PC, Talwar I. Multimodality imaging of the orbit. *Indian J Radiol Imaging.* 2012;(3):227-39. doi:10.4103/0971-3026.107184.

Pediatric Lymphomas (PEDONC-5)

Guideline

Pediatric Lymphoma – General Considerations (PEDONC-5.1)

Pediatric Hodgkin Lymphoma (HL) (PEDONC-5.2)

Pediatric Aggressive Mature B-Cell Non-Hodgkin Lymphomas (NHL)
(PEDONC-5.3)

Anaplastic Large Cell Lymphoma (ALCL) (PEDONC-5.4)

References (PEDONC-5)

Pediatric Lymphoma – General Considerations (PEDONC-5.1)

ONCP.HL.0005.1.A

v2.0.2024

- Lymphoma mostly commonly involves the lymph nodes (LNs). However, lymphoma can also arise from primary lymphoid tissues (bone marrow or thymus) or various secondary lymphoid tissues (spleen, mucosa-associated lymphoid tissue) or non-lymphoid organs (skin, bone, brain, lungs, liver, salivary glands, etc.).
- Pediatric lymphomas are generally Hodgkin Lymphomas, Aggressive B-Cell Non-Hodgkin Lymphomas, Lymphoblastic Lymphomas, or Anaplastic Large Cell Lymphomas
- Individuals with Lymphoblastic Lymphoma (even those with bulky nodal disease) are treated using the leukemia treatment plan appropriate to the cell type (B or T cell).
 - These individuals should be imaged using guidelines in **Acute Lymphoblastic Leukemia (ALL) (PEDONC-3.2)**
- Other histologies are rare in pediatric individuals, and should be imaged according to the following guidelines:
 - Follicular lymphoma: **Follicular Lymphoma (ONC-27.3)** in the Oncology Imaging Guidelines
 - Marginal zone or MALT lymphomas: **Marginal Zone Lymphomas (ONC-27.4)** in the Oncology Imaging Guidelines
 - Mantle cell lymphomas: **Mantle Cell Lymphoma (ONC-27.5)** in the Oncology Imaging Guidelines
 - Cutaneous lymphomas: **Cutaneous Lymphomas and T Cell Lymphomas (ONC-27.8)** in the Oncology Imaging Guidelines
 - **Exception:** Cutaneous B-Lymphoblastic Lymphoma should be imaged using guidelines in **Acute Lymphoblastic Leukemia (ALL) (PEDONC-3.2)**
 - Castleman's Disease: **Castleman's Disease (Unicentric and Multicentric) (ONC-31.11)** in the Oncology Imaging Guidelines
- All CT imaging recommended in this section refers to CT with contrast only.
 - Noncontrast CT imaging has not been shown to be beneficial in the management of pediatric lymphomas
 - Given the limited utility of noncontrast CT imaging in pediatric lymphomas, MRI without or without and with contrast is recommended in place of CT for individuals who cannot tolerate CT contrast due to allergy or impaired renal function
- MRI without and with contrast of symptomatic or previously involved bony areas can be approved in known lymphoma individuals without prior plain x-ray or bone scan evaluation

- Bone scan is inferior to MRI for evaluation of known or suspected bone metastases in lymphoma
- MRI Brain without and with contrast (CPT® 70553) is the preferred study for evaluation of suspected brain metastases in pediatric lymphoma
 - CT Head with (CPT® 70460) or without and with contrast (CPT® 70470) can be approved when MRI is contraindicated

Pediatric Hodgkin Lymphoma (HL) (PEDONC-5.2)

ONCP.HL.0005.2.A

v2.0.2024

Indication	Imaging Study
Initial staging	<p><u>ANY or ALL of the following may be approved:</u></p> <ul style="list-style-type: none"> • CT Neck with contrast (CPT® 70491) <ul style="list-style-type: none"> • MRI Neck without and with contrast (CPT® 70543) may be substituted for CT to limit radiation exposure if requested • CT Chest with contrast (CPT® 71260) <ul style="list-style-type: none"> • MRI is not an acceptable substitution for CT Chest • CT Abdomen and Pelvis with contrast (CPT® 74177) <ul style="list-style-type: none"> • MRI Abdomen with and without contrast (CPT® 74183) and MRI Pelvis (CPT® 72197) may be substituted for CT to limit radiation exposure if requested • MRI Brain with and without contrast (CPT® 70553) for known CNS involvement or new signs or symptoms suggesting intracranial disease • PET/CT (CPT® 78815 or CPT® 78816) or PET/MRI (only using combination of CPT® 78813 and CPT® 76498) <ul style="list-style-type: none"> • Can be performed prior to biopsy if necessary for individual scheduling • CT or MRI of other body areas may be indicated for rare individuals based on physical findings or PET/CT results

Indication	Imaging Study
Restaging	<ul style="list-style-type: none"> • ALL of the following, as often as every 2 cycles of chemotherapy: <ul style="list-style-type: none"> • CT of previously involved visceral areas <ul style="list-style-type: none"> • In individuals on treatment for recurrent or refractory Hodgkin Lymphoma, the following are indicated: <ul style="list-style-type: none"> • CT Neck with contrast (CPT® 70491) • CT Chest with contrast (CPT® 71260) • CT Abdomen and Pelvis with contrast (CPT® 74177) • MRI Brain with and without contrast (CPT® 70553) for known CNS involvement <p>AND</p> <ul style="list-style-type: none"> • After cycles 2 and 4 of chemotherapy* and at end of therapy: <ul style="list-style-type: none"> • PET/CT (CPT® 78815 or CPT® 78816) or PET/MRI (only using combination of CPT® 78813 and 76498) <ul style="list-style-type: none"> • This restaging PET/CT may instead be performed after cycles 1 and 3 for individuals with low risk stage IA or IIA mixed cellularity Hodgkin lymphoma • Diagnostic CT or MRI of previously involved areas may be combined with PET at end of therapy. • In addition to the above studies: <ul style="list-style-type: none"> • A single follow-up PET/CT (CPT® 78815 or CPT® 78816) or PET/MRI is indicated >12 weeks after radiation therapy, if end of therapy PET/CT report documents Deauville 3, 4, or 5 FDG avidity, to confirm complete response
Surveillance for individuals with no history of recurrent HL	<ul style="list-style-type: none"> • Imaging studies are only recommended when relapse is clinically suspected, because most individuals will clinically declare themselves and there is no survival advantage in pre-emptive imaging. • Routine surveillance imaging is not supported in individuals without a prior history of recurrent disease
Surveillance, individuals with recurrent HL and no evidence of disease following successful treatment	<ul style="list-style-type: none"> • ALL of the following, every 3 months for 1 year after completing therapy for recurrence: <ul style="list-style-type: none"> • CT Neck with contrast (CPT® 70491) • CT Chest with contrast (CPT® 71260) • CT Abdomen and Pelvis with contrast (CPT® 74177)

Indication	Imaging Study
<p>Clarify inconclusive findings on conventional imaging suspicious for recurrence AND considering biopsy to establish recurrence</p>	<ul style="list-style-type: none"> PET/CT (CPT® 78815 or CPT® 78816) or PET/MRI (only using combination of CPT® 78813 and CPT® 76498)
<p>Clinical symptoms suggesting recurrence</p>	<ul style="list-style-type: none"> MRI Brain with and without contrast (CPT® 70553) for known CNS involvement or new signs or symptoms suggesting intracranial disease <p><u>AND either of the following sets of imaging:</u></p> <ul style="list-style-type: none"> Conventional imaging: <ul style="list-style-type: none"> CT Neck with contrast (CPT® 70491) OR MRI Neck with and without (CPT® 70491) AND CT Chest with contrast (CPT® 71260) AND CT Abdomen and Pelvis with contrast (CPT® 74177) OR MRI Abdomen and Pelvis with and without contrast (CPT® 74183 and CPT® 72197) AND CT of other previously involved visceral areas or currently symptomatic areas <p>OR</p> <ul style="list-style-type: none"> PET/CT (CPT® 78815 or 78816) or PET/MRI (only using combination of CPT® 78813 and CPT® 76498)

Background and Supporting Information

- Most individuals experiencing recurrence are detected based on physical findings, and frequent CT surveillance imaging of Hodgkin Lymphoma after completion of therapy does not improve post-recurrence overall survival. The primary determinant of survival at recurrence is time to relapse, regardless of whether relapse is detected clinically or via imaging. NCCN pediatric HL guidelines recommend no pre-emptive surveillance imaging.
- Pediatric individuals have a high rate of neck involvement with Hodgkin Lymphoma
- Early treatment response evaluations involve both PET and CT as decisions about chemotherapy drug selection and radiation treatment are frequently made based on both anatomic (CT-based) and metabolic (PET/CT-based) responses.
- Indications and coding for rare circumstances where PET/MRI may be approved are found in **PET imaging in Pediatric Oncology (PEDONC-1.4)**

Pediatric Aggressive Mature B-Cell Non-Hodgkin Lymphomas (NHL) (PEDONC-5.3)

ONCP.HL.0005.3.A
v2.0.2024

Indication	Imaging Study
Initial staging	<p>ANY or ALL of the following may be approved:</p> <ul style="list-style-type: none"> • CT Neck with contrast (CPT® 70491) <ul style="list-style-type: none"> • May substitute MRI Neck with and without contrast (CPT® 70543) if requested • CT Chest with contrast (CPT® 71260) • CT Abdomen and Pelvis with contrast (CPT® 74177) <ul style="list-style-type: none"> • May substitute MRI Abdomen without and with contrast (CPT® 74183) and MRI Pelvis without and with contrast (CPT® 72197) in place of CT Abdomen and Pelvis, if requested. • Abdominal ultrasound (CPT® 76700 or 76705) may be approved at initial presentation if CT/MRI not available. • CT with contrast or MRI without and with contrast any other symptomatic body area • PET/CT (CPT® 78815 or CPT® 78816) or PET/MRI (only using combination of CPT® 78813 and CPT® 76498 [may be approved in addition to diagnostic CTs])
Additional initial staging if symptoms or extent of disease suggest intracranial extension or metastasis	<ul style="list-style-type: none"> • MRI Brain without and with contrast (CPT® 70553)
Additional initial staging if symptoms or extent of disease suggest intraspinal extension or metastasis (back pain)	<ul style="list-style-type: none"> • MRI of suspected spinal level involvement without and with contrast

Indication	Imaging Study
Restaging for treatment response (following initial response evaluation)	<ul style="list-style-type: none"> • ANY OR ALL of the following, as often as every cycle of chemotherapy (~every 3 weeks): <ul style="list-style-type: none"> • CT with contrast or MRI without and with contrast (should be same modality as initial diagnosis if possible) of previously involved areas • PET/CT (CPT® 78815 or CPT® 78816) or PET/MRI (only using combination of CPT® 78813 and CPT® 76498) until a negative PET is obtained <ul style="list-style-type: none"> • Whole-body PET/CT (CPT® 78816) may be approved if there is clinical suspicion of, or known, skull or distal lower extremity involvement. • PET/CT may be approved in conjunction with diagnostic CTs/MRIs, PET/CT should not replace imaging with contrast-enhanced diagnostic-quality CT or MRI.
Restaging for all subsequent treatment response, including end of therapy evaluation, after negative PET/CT (either Deauville or Lugano 1, 2 or 3 as reported in formal radiology interpretation)	<ul style="list-style-type: none"> • CT with contrast or MRI without and with contrast (should be same modality as initial diagnosis if possible) of previously involved areas, as often as every 2 cycles of chemotherapy, and at the end of therapy
Assessment of disease activity in inconclusive residual masses seen on conventional imaging	<ul style="list-style-type: none"> • PET/CT (CPT® 78815 or CPT® 78816) or PET/MRI (only using combination of CPT® 78813 and CPT® 76498)
Individuals being treated with Rituximab who present with abdominal pain, due to risk of bowel perforation and obstruction	<ul style="list-style-type: none"> • CT Abdomen and Pelvis with contrast (CPT® 74177) <ul style="list-style-type: none"> • US, x-ray, or other red flags are not required prior to CT
Surveillance of asymptomatic individuals with residual masses in the chest or abdomen and pelvis	<ul style="list-style-type: none"> • Chest x-ray and Abdominal (CPT® 76700) and Pelvic (CPT® 76856) ultrasound 3 months after completion of therapy. If stable, no further imaging is indicated.

Indication	Imaging Study
Clinical symptoms or laboratory findings suggesting recurrence	<ul style="list-style-type: none"> • MRI Brain with and without contrast (CPT® 70553) for history of CNS involvement or new signs or symptoms suggesting intracranial disease <p><u>And:</u></p> <ul style="list-style-type: none"> • CT Neck with contrast (CPT® 70491) and CT Chest with contrast (CPT® 71260) and CT Abdomen and Pelvis with contrast (CPT® 74177) and CT with contrast of other previously involved visceral areas or currently symptomatic areas (MRI with and without contrast may be substituted for CT for all areas other than the chest if requested) • PET/CT (CPT® 78815 or CPT® 78816) or PET/MRI (only using combination of CPT® 78813 and CPT® 76498) may be approved if relapse is suspected based on CT scan findings
Suspected PTLD recurrence with documentation of new palpable nodes, rising LDH, or rising quantitative EBV PCR	<ul style="list-style-type: none"> • PET/CT (CPT® 78815 or CPT® 78816) or PET/MRI (only using combination of CPT® 78813 and CPT® 76498)
Clarify inconclusive findings on conventional imaging to evaluate the need for biopsy to establish recurrence	<ul style="list-style-type: none"> • PET/CT (CPT® 78815 or CPT® 78816) or PET/MRI (only using combination of CPT® 78813 and CPT® 76498)

Background and Supporting Information

- Aggressive mature B-Cell NHL includes all of the following diagnoses, all of which should be imaged according to this section:
 - Burkitt’s lymphoma/leukemia (BL)
 - Diffuse Large B-Cell Lymphoma (DLBCL)
 - Primary Mediastinal Large B-Cell Lymphoma (PMBCL)
 - Post-transplant Lymphoproliferative Disorder (PTLD)
 - Most commonly occurs following solid organ or stem cell transplantation
 - Viral-associated lymphoproliferative disorders
 - Most commonly occurs following hematopoietic stem cell transplantation or in individuals with primary immunodeficiency
- Initial treatment is usually 7 days of low intensity therapy, with early response evaluation determining next steps in therapy using CT with contrast or MRI without and with contrast of previously involved areas performed around day 6

- Individuals are customarily still inpatient for this evaluation so outpatient requests should be rare for this time point
- Routine asymptomatic surveillance with advanced imaging has not been found to impact individual outcomes as the majority of these individuals present clinically at relapse due to the highly aggressive nature of these lymphomas
- Indications and coding for rare circumstances where PET/MRI may be approved are found in **PET Imaging in Pediatric Oncology (PEDONC-1.4)**

Anaplastic Large Cell Lymphoma (ALCL) (PEDONC-5.4)

ONCP.HL.0005.4.A

v2.0.2024

Indication	Imaging Study
Initial staging	<ul style="list-style-type: none"> • ANY OR ALL of the following may be approved: <ul style="list-style-type: none"> • CT Neck with contrast (CPT[®] 70491), CT Chest with contrast (CPT[®] 71260), and CT Abdomen and Pelvis (CPT[®] 74177) • MRI without and with contrast of affected area <ul style="list-style-type: none"> • May be substituted for CT in cases of paraspinal or soft tissue extremity primary tumors • CT with contrast or MRI without and with contrast any other symptomatic body area • PET/CT (CPT[®] 78815 or CPT[®] 78816) or PET/MRI (only using combination of CPT[®] 78813 and 76498)
Additional initial staging for individuals with bony primary tumors or metastatic disease	<ul style="list-style-type: none"> • Bone scan (See: <u>Modality General Considerations (PEDONC-1.3)</u>)
Restaging at the end of induction chemotherapy (commonly 4 to 6 weeks)	<ul style="list-style-type: none"> • CT with contrast or MRI without and with contrast of previously involved areas (should be same modality as initial diagnosis if possible)

Indication	Imaging Study
Treatment response in individuals treated with cytotoxic chemotherapy	<ul style="list-style-type: none"> • <u>Every 2 cycles:</u> <ul style="list-style-type: none"> • CT of previously involved areas <ul style="list-style-type: none"> • If CT is performed for primary treatment response, PET/CT (CPT® 78815 or CPT® 78816) can be approved to clarify inconclusive findings detected on conventional imaging OR <ul style="list-style-type: none"> • PET/CT or PET/MRI (only using combination of CPT® 78813 and CPT® 76498) until a negative PET is obtained <ul style="list-style-type: none"> • If PET/CT (CPT® 78815 or CPT® 78816) is performed for primary treatment response, CT or MRI can be approved to clarify inconclusive findings detected on PET imaging
Restaging after negative PET/CT (either Deauville or Lugano 1, 2 or 3 as reported in formal radiology interpretation)	<ul style="list-style-type: none"> • CT with contrast of previously involved areas
Surveillance	<ul style="list-style-type: none"> • CT with contrast or MRI without and with contrast of all previously involved areas is indicated every 6 months for 2 years after completion of therapy.
Additional surveillance for individuals with bony primary tumors or metastatic disease	<ul style="list-style-type: none"> • Bone scan (See: Modality General Considerations (PEDONC-1.3) for coding) is indicated at 3, 6, 12, and 18 months after therapy is completed
Clinical symptoms suggesting recurrence	<ul style="list-style-type: none"> • CT Neck (CPT® 70491), CT Chest (CPT® 71260), Abdomen and Pelvis (CPT® 74177), and other previously involved or currently symptomatic areas
Clarify inconclusive findings on conventional imaging to evaluate the need for biopsy to establish recurrence	<ul style="list-style-type: none"> • PET/CT (CPT® 78815 or CPT® 78816) or PET/MRI (only using combination of CPT® 78813 and CPT® 76498)

Background and Supporting Information

- Similar in presentation to Hodgkin Lymphoma, and may be indistinguishable until immunocytology and molecular studies are complete.
- Indications and coding for rare circumstances where PET/MRI may be approved are found in **PET Imaging in Pediatric Oncology (PEDONC-1.4)**

References (PEDONC-5)

v2.0.2024

1. Davies K, Barth M, Armenian S, et al. National Comprehensive Cancer Network (NCCN) Guidelines Version 1.2023—April 4, 2023, Pediatric Aggressive Mature B-Cell Lymphomas, available at: https://www.nccn.org/professionals/physician_gls/pdf/ped_b-cell.pdf, Referenced with permission from the NCCN Clinical Practice Guidelines in Oncology (NCCN Guidelines™) for Pediatric Aggressive Mature B-Cell Lymphomas V1.2023 4/4/2023. ©2023 National Comprehensive Cancer Network, Inc. All rights reserved. The NCCN Guidelines™ and illustrations herein may not be reproduced in any form for any purpose without the express written permission of the NCCN. To view the most recent and complete version of the NCCN Guidelines™, go online to NCCN.org.
2. Metzger ML, Krasin MJ, Choi JK, et al. Hodgkin lymphoma. In: Pizzo PA, Poplack DG, eds. Principles and Practice of Pediatric Oncology. 7th ed. Philadelphia, PA: Wolters Kluwer; 2016:568-586.
3. Allen CE, Kamdar KY, Bollard CM, et al. Malignant Non-Hodgkin lymphomas in Children. In: Pizzo PA, Poplack DG, eds. Principles and Practice of Pediatric Oncology. 7th ed. Philadelphia, PA: Wolters Kluwer; 2016:587-603.
4. Hayashi RJ, Wistinghausen B, Shiramizu B. Lymphoproliferative Disorders and Malignancies Related To Immunodeficiencies. In: Pizzo PA, Poplack DG, eds. Principles and Practice of Pediatric Oncology. 7th ed. Philadelphia, PA: Wolters Kluwer; 2016:604-616.
5. Alexander S, Ferrando AA. Pediatric lymphoma. In: Orkin SH, Fisher DE, Ginsburg D, Look AT, Lux SE, Nathan DG, eds. Nathan and Oski's Hematology and Oncology of Infancy and Childhood. 8th ed. Philadelphia, PA: Elsevier Saunders; 2015:1626-1671.
6. Lee Chong A, Grant RM, Ahmed BA, Thomas KE, Connolly BL, Greenberg M. Imaging in pediatric patients: time to think again about surveillance. *Pediatr Blood Cancer*. 2010;55(3):407-413. doi:10.1002/pbc.22575.
7. Uslu L, Doing J, Link M, Rosenberg J, Quon A, Daldrop-Link H. Value of 18F-FDG-PET and PET/CT for evaluation of pediatric malignancies. *J Nucl Med*. 2015;56(2):274-286. doi:10.2967/jnumed.114.146290.
8. Ceppi F, Pope E, Ngan B, Abla O. Primary cutaneous lymphomas in children and adolescents. *Pediatr Blood Cancer*. 2016;63(11):1886-1894. doi:10.1002/pbc.26076.
9. Flerlage JE, Kelly KM, Beishuizen A, et al. Staging evaluation and response criteria harmonization (SEARCH) for childhood, adolescent, and young adult Hodgkin Lymphoma (CAYAHL): Methodology statement. *Pediatr Blood Cancer*. 2017;64(7):e26421. doi:10.1002/pbc.26421.
10. Friedman DL, Chen L, Wolden S, et al. Dose-intensive response-based chemotherapy and radiation therapy for children and adolescents with newly diagnosed intermediate-risk Hodgkin lymphoma: a report from the Children's Oncology Group Study AHOD0031. *J Clin Oncol*. 2014;32(32):3651-3658. doi:10.1200/JCO.2013.52.5410.
11. Schwartz CL, Chen L, McCarten K, et al. Childhood Hodgkin International Prognostic Score (CHIPS) predicts event-free survival in Hodgkin lymphoma: a report from the Children's Oncology Group. *Pediatr Blood Cancer*. 2017;64(4):e26278. doi:10.1002/pbc.26278.
12. Friedmann AM, Wolfson JA, Hudson MM, et al. Relapse after treatment of Hodgkin lymphoma: outcome and role of surveillance after therapy. *Pediatr Blood Cancer*. 2013;60(9):1458-1463. doi:10.1002/pbc.24568.
13. Mauz-Körholz C, Metzger ML, Kelly KM, et al. Pediatric Hodgkin lymphoma. *J Clin Oncol*. 2015;33(27):2975-2985. doi:10.1200/JCO.2014.59.4853.
14. Voss SD, Chen L, Constine LS, et al. Surveillance computed tomography imaging and detection of relapse in intermediate- and advanced-stage pediatric Hodgkin's lymphoma: A report from the Children's Oncology Group. *J Clin Oncol*. 2012;30(21):2635-2640. doi:10.1200/JCO.2011.40.7841.
15. Voss SD. Surveillance Imaging in Pediatric Hodgkin Lymphoma. *Curr Hematol Malig Rep*. 2013;8(3):218-225. doi:10.1007/s11899-013-0168-z.
16. Appel BE, Chen L, Buxton AB, et al. Minimal treatment of low-risk, pediatric lymphocyte-predominant Hodgkin lymphoma: a report from the Children's Oncology Group. *J Clin Oncol*. 2016;34(20):2372-2379. doi:10.1200/JCO.2015.65.3469.
17. Rosolen A, Perkins SL, Pinkerton CR, et al. Revised international pediatric non-Hodgkin lymphoma staging system. *J Clin Oncol*. 2015;33:2112-2118. doi:10.1200/JCO.2014.59.7203.
18. Sandlund JT, Guilleman RP, Perkins SL, et al. International pediatric Non-Hodgkin lymphoma response criteria. *J Clin Oncol*. 2015;33(18):2106-2111. doi:10.1200/JCO.2014.59.0745.
19. Eissa HM, Allen CE, Kamdar K, et al. Pediatric Burkitt's lymphoma and Diffuse B-cell lymphoma: are surveillance scans required? *Pediatr Hematol Oncol*. 2014;31(3):253-257. doi:10.3109/08880018.2013.834400.

20. Minard-Colin V, Brugieres L, Reiter A, et al. Non-Hodgkin lymphoma in children and adolescents: progress through effective collaboration, current knowledge, and challenges ahead. *J Clin Oncol*. 2015;33(27):2963-2974. doi:10.1200/JCO.2014.59.5827.
21. Dierickx D, Tousseym T, and Gheysens O. How I treat posttransplant lymphoproliferative disorders. *Blood*. 2015;126(20):2274-2283. doi:10.1182/blood-2015-05-615872.
22. Vali R, Punnett A, Bajno L, Moineddin R, Shamma A. The value of 18F-FDG PET in pediatric patients with post-transplant lymphoproliferative disorder at initial diagnosis. *Pediatr Transplant*. 2015;19(8):932-939. doi:10.1111/ptr.12611.
23. Hapgood G and Savage KJ. The biology and management of systemic anaplastic large cell lymphoma. *Blood*. 2015;126(1):17-25. doi:10.1182/blood-2014-10-567461.
24. Kempf W, Kazakov DV, Belousova IE, Mitteldorf C, Kerl K. Pediatric cutaneous lymphomas: a review and comparison with adult counterparts. *J Eur Acad Dermatol Venereol*. 2015;29(9):1696-1709. doi:10.1111/jdv.13044.
25. Hochberg J, Flower A, Brugieres L, Cairo MS. NHL in adolescents and young adults: a unique population. *Pediatr Blood Cancer*. 2018;65:e27073. doi.org/10.1002/pbc.27073.
26. Buhtoiarov IN. Pediatric lymphoma. *Pediatr In Rev*. 2017;38(9):410-423. doi:10.1542/pir.2016-0152.
27. Hoppe, RT, Advani RH, Ambinder RF, et al. National Comprehensive Cancer Network (NCCN) Guidelines Version 2.2023, November 8 2022. Pediatric Hodgkin Lymphoma, available at: https://www.nccn.org/professionals/physician_gls/pdf/ped_hodgkin.pdf, Referenced with permission from the NCCN Clinical Practice Guidelines in Oncology (NCCN Guidelines™) for Pediatric Hodgkin Lymphoma V2.2023, 11/8/2022. ©2022 National Comprehensive Cancer Network, Inc. All rights reserved. The NCCN Guidelines™ and illustrations herein may not be reproduced in any form for any purpose without the express written permission of the NCCN. To view the most recent and complete version of the NCCN Guidelines™, go online to NCCN.org.
28. Kaste SC. Imaging of pediatric cutaneous melanoma. *Pediatric Radiology*. 2019;49:1476-1487. doi:10.1007/s00247-019-04374-9.
29. Mhlanga J, Alazraki A, Cho SY, et. al. Imaging recommendations in pediatric lymphoma: A COG Diagnostic Imaging Committee/SPR Oncology Committee white paper. *Pediatr Blood Cancer*. 2022:e29968. doi:10.1002/pbc.2996.

Neuroblastoma (PEDONC-6)

Guideline

- Neuroblastoma – General Considerations (PEDONC-6.1)
- Staging and Risk Grouping – Neuroblastoma (PEDONC-6.2)
- Neuroblastoma – Initial Staging (PEDONC-6.3)
- Neuroblastoma – Treatment Response Imaging (Risk Group Dependent) (PEDONC-6.4)
- Neuroblastoma – Surveillance Imaging (Risk Group Dependent) (PEDONC-6.5)
- References (PEDONC-6)

Neuroblastoma – General Considerations (PEDONC-6.1)

ONCP.NP.0006.1.U

v2.0.2024

- **PEDONC-6** should be used to review neuroblastoma in individuals of all ages, with the exception of esthesioneuroblastoma in individuals of all ages, which should be reviewed using **ONC-3**.
- Neuroblastoma is divided into very low, low, intermediate, and high-risk disease based on International Neuroblastoma Risk Group (INRG) Staging System (see: **Staging and Risk Grouping – Neuroblastoma (PEDONC-6.2)**). The treatment approaches for each risk group vary widely and have distinct imaging strategies. The risk group for a given individual should be provided by the ordering provider in the clinical information provided for review.
- For metabolic imaging in individuals who are MIBG positive at diagnosis and then become MIBG negative in response to treatment:
 - Continue to use MIBG (see: table below and **PEDONC-1.3** for coding)

Study Type	Coding
Bone scan	<ul style="list-style-type: none"> • Any of the following codes can be approved: <ul style="list-style-type: none"> • CPT® 78300 • CPT® 78305 • CPT® 78306 • CPT® 78803, 78830, or 78832 <ul style="list-style-type: none"> • May be approved alone or in combination with: <ul style="list-style-type: none"> • CPT® 78305 • CPT® 78306

Study Type	Coding
¹²³ I-metaiodobenzylguanidine (MIBG) scintigraphy	<ul style="list-style-type: none"> Any one of the following codes can be approved: <ul style="list-style-type: none"> CPT® 78801 CPT® 78802 CPT® 78804 Any one of the following codes may also be approved, individual or in combination with CPT® 78801, 78802 or 78804 <ul style="list-style-type: none"> CPT® 78803 CPT® 78830 CPT® 78831 CPT® 78832 CPT® 78800 may be approved for KNOWN neuroblastoma when only a single site follow up is desired, but is not sufficient for the initial workup of suspected disease.
Octreotide scan	<ul style="list-style-type: none"> Same coding as MIBG
Gallium scan	<ul style="list-style-type: none"> Same coding as MIBG

- MIBG remains the standard of care metabolic imaging in neuroblastoma, 18F-FDG-PET-CT is not supported unless one of the exceptions below is present. All other radiotracers are considered investigational at this time:

Indication	Imaging Study
<ul style="list-style-type: none"> Any of the following: <ul style="list-style-type: none"> Individuals with MIBG-negativity documented at initial diagnosis At major decision points (such as hematopoietic stem cell transplant or surgery), if MIBG and CT/MRI findings are inconclusive 	<ul style="list-style-type: none"> Whole body 18F-FDGPET/CT (CPT® 78816) In scenarios where PET/CT is supported, it does not preclude the other diagnostic imaging studies supported throughout PEDONC 6 . PET/CT is viewed as replacing MIBG in these scenarios. Indications and coding for rare circumstances where PET/MRI may be approved are found in <u>PET Imaging in Pediatric Oncology (PEDONC-1.4)</u>

Indication	Imaging Study
<ul style="list-style-type: none"> • Individuals currently receiving medications that may interfere with MIBG uptake that cannot be safely discontinued prior to imaging, including: <ul style="list-style-type: none"> • Tricyclic antidepressants (amitriptyline, imipramine, etc.) • Selective serotonin reuptake inhibitors (SSRI's, sertraline, paroxetine, escitalopram, etc.) • Neuroleptics (risperidone, haloperidol, etc.) • Antihypertensive drugs (alpha or beta blockers, calcium channel blockers) • Decongestants (phenylephrine, ephedrine, pseudoephedrine) • Stimulants (methylphenidate, dextroamphetamine, etc.) 	<ul style="list-style-type: none"> • PET/CT (CPT® 78816) should only be approved for this indication when specific documentation of the medication interaction is included with the current PET imaging request. • Indications and coding for rare circumstances where PET/MRI may be approved are found in <u>PET Imaging in Pediatric Oncology (PEDONC-1.4)</u>

Background and Supporting Information

- Neuroblastoma is the most common extracranial solid tumor of childhood, and generally arises from the adrenal gland or along the sympathetic chain. Neuroblastoma staging has recently changed to better incorporate the prognostic impact of biological and genetic characteristics, particularly segmental chromosome aberrations (SCA) as an additional genomic marker. SCAs of 1p or 11g are poor prognostic indicators.
- 90% to 95% of neuroblastomas secrete homovanillic acid (HVA) and vanillylmandelic acid (VMA) in the urine, and urine HVA/VMA should be performed at every disease evaluation for individuals with positive HVA or VMA at diagnosis
- 99mTc-MDP bone scan does not identify foci of disease that affect staging or clinical management and provides no advantage over MIBG scintigraphy and is not used for evaluation of most individuals with neuroblastoma

Staging and Risk Grouping – Neuroblastoma (PEDONC-6.2)

ONCP.NP.0006.2.A

v2.0.2024

- Most recent treatment protocols are using the updated International Neuroblastoma Risk Group (INRG) staging system
 - L1: Localized tumor not involving vital structures as defined by the list of image-defined risk factors and confined to one body compartment
 - Image-defined risk factors include a list of specific imaging findings defining individuals less likely to be candidates for complete surgical resection
 - These risk factors involve the encasement of major blood vessels, airway, skull base, costovertebral junction, brachial plexus, spinal canal, or major organs or structures
 - L2: Locoregional tumor with presence of one or more image-defined risk factors
 - M: Distant metastatic disease (except stage MS)
 - MS: Metastatic disease in children younger than 18 months with metastases confined to skin, liver, and/or bone marrow with <10% involvement (MIBG must be negative in bone and bone marrow)
- The tables for risk grouping are provided below for reference. The risk group for any given individual should be provided or documented by the requesting provider.

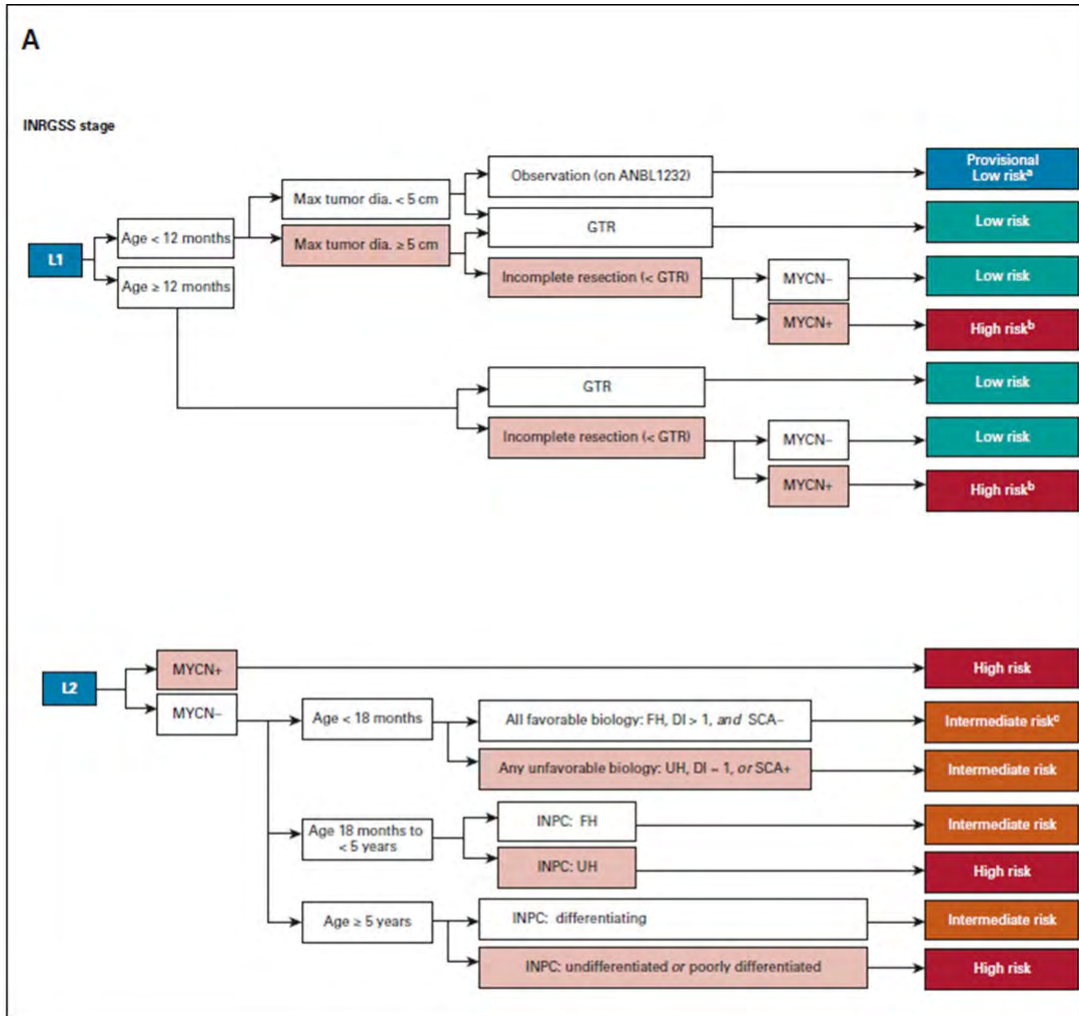


FIG 1. Risk classifier v2 algorithm for patients with (A) locoregional and (B) metastatic tumors. (A) Patients with locoregional tumors with neuroblastoma and ganglioneuroblastoma (nodular) are classified based on INRG stage (L1 and L2), age, resection, biomarkers (*MYCN*, ploidy, and SCAs), and INPC. Select patients with all favorable features are eligible for surveillance on the current non-high-risk COG ANBL1232 protocol. L1 or L2 tumors with histopathology diagnostic category of ganglioneuroma or ganglioneuroblastoma-intermixed will be classified as low-risk regardless of biomarkers (and thus are not included in the figure). Ages are broken down by < 18 months, 18 months to < 5 years, and ≥ 5 years based on age categories used by INPC. ^aIf tumor progresses during observation, biopsy or resect and reclassify with biomarkers (as in COG ANBL1232). ^bConsider complete resection if feasible. ^cIf no tumor burden symptoms, consider observation (as in COG ANBL1232). (B) Patients with metastatic tumors are classified by stage (M and MS), age, INPC, and biomarkers. For MS patients, presence or absence of symptoms may influence therapy independent of biomarker status. In previous risk classifiers, missing data were considered as unfavorable. In COG v2, missing data for SCA will not be considered as unfavorable based on the low incidence of SCA in otherwise favorable subsets. (continued on following page).

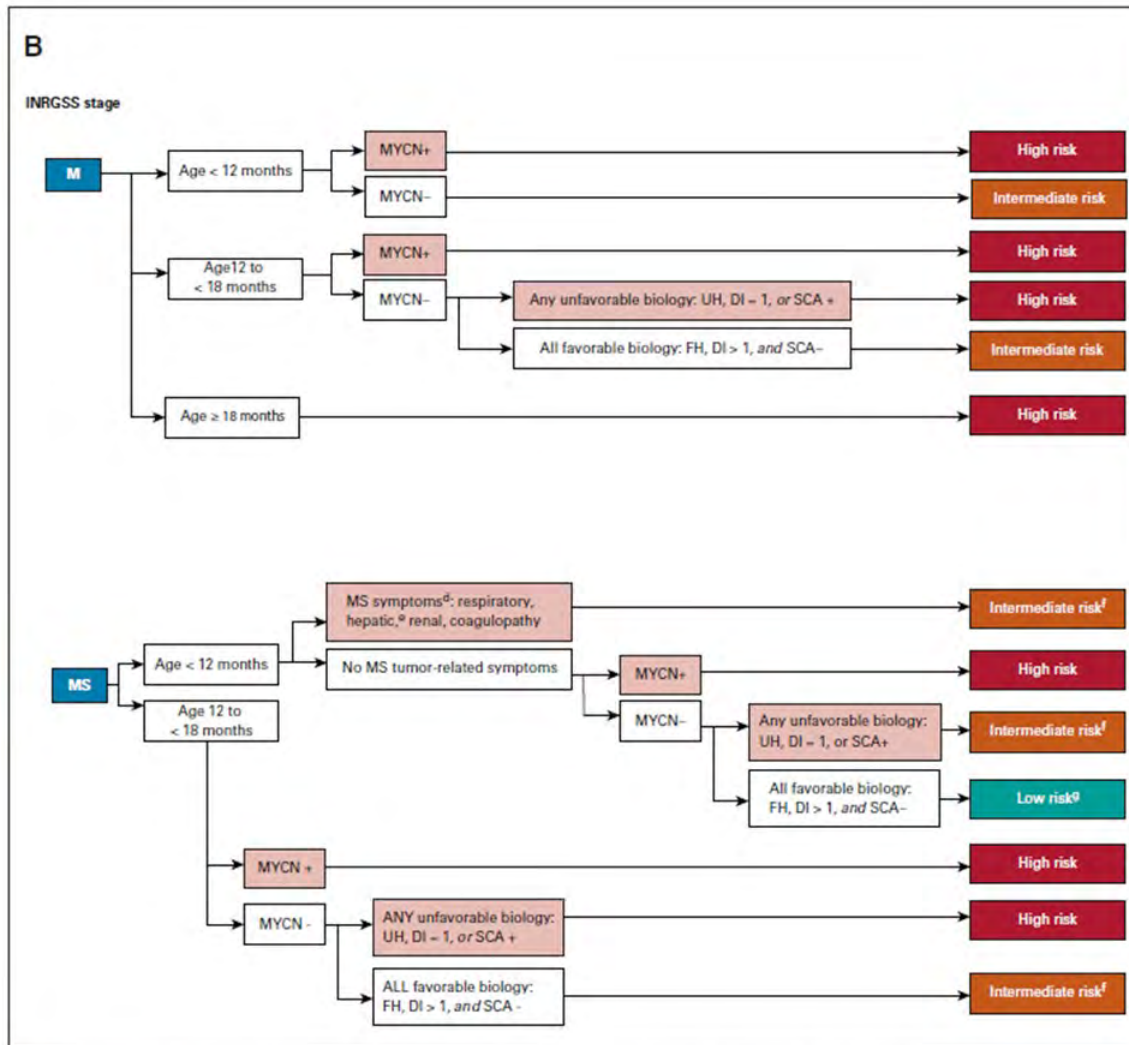


FIG 1. (Continued). ^aBiopsy contraindicated, defer biopsy until stable (note: biomarker results may modify Risk Class). ^bHepatomegaly alone is an MS symptom in patients age < 3 months of age (see COG ANBL1232). ^cResponse-based therapy (as in COG ANBL1232). ^dMS score-based therapy (as in COG ANBL1232). COG, Children's Oncology Group; DI, DNA index; dia., diameter; FH, favorable histology; GTR, gross-total resection; INPC, International Neuroblastoma Pathology Classifier; INRG, International Neuroblastoma Risk Group; MYCN+, *MYCN* amplified; MYCN-, *MYCN* not amplified; SCA, segmental chromosomal aberration; UH, unfavorable histology; v1, version 1; v2, version 2.

Neuroblastoma – Initial Staging (PEDONC-6.3)

ONCP.NP.0006.3.A

v2.0.2024

The following imaging studies should be considered appropriate in the initial staging of individuals with Neuroblastoma:

Indication	Imaging Study
Initial staging for all individuals	<ul style="list-style-type: none"> • ¹²³I-metaiodobenzylguanidine (see table in Neuroblastoma – General Considerations (PEDONC-6.1) for MIBG coding details) scintigraphy <p style="text-align: center;">AND</p> <ul style="list-style-type: none"> • <u>ONE</u> of the following sets of imaging: <ul style="list-style-type: none"> • CT Neck with contrast (CPT[®] 70491), CT Chest with contrast (CPT[®] 71260), and CT Abdomen and Pelvis with contrast (CPT[®] 74177) <p style="text-align: center;">OR</p> <ul style="list-style-type: none"> • MRI Neck without and with contrast (CPT[®] 70543), MRI Chest without and with contrast (CPT[®] 71552), and MRI Abdomen and Pelvis without and with contrast (CPT[®] 74183 and CPT[®] 72197)
Evaluation of paraspinal tumors where cord compression is a possibility	<ul style="list-style-type: none"> • MRI without and with contrast of the appropriate spinal level
Evaluation of suspected adrenal neuroblastoma, ganglioneuroblastoma, or ganglioneuroma when CT or MRI is inconclusive for an adrenal lesion.	<ul style="list-style-type: none"> • Adrenal nuclear imaging (CPT[®] 78075)
Clinical signs/symptoms suggest brain involvement	<ul style="list-style-type: none"> • MRI Brain without and with contrast (CPT[®] 70553)

- PET should not be used unless one of the exceptions stated in section **Neuroblastoma – General Considerations (PEDONC-6.1)** is present

Background and Supporting Information

- MIBG provides superior sensitivity and sensitivity for detecting viable osseous disease compared with bone scintigraphy so technetium bone scan is not necessary when MIBG is utilized. MIBG is positive in 90% to 95% of neuroblastomas.
 - Most MIBG imaging studies are SPECT/CT studies using CT for localization only. Separate diagnostic CT codes should not be approved for this purpose
 - Occasionally MIBG cannot be performed prior to initiation of therapy. In this circumstance, MIBG should be completed within 3 weeks of therapy initiation as the reduction in MIBG avidity in response to chemotherapy is not immediate. Inability to complete MIBG before starting therapy is not an indication to approve PET imaging
- MRI Brain of asymptomatic individuals with no history of brain metastases is not indicated for neuroblastoma but may be approved for signs and symptoms of brain involvement.

Neuroblastoma – Treatment Response Imaging (Risk Group Dependent) (PEDONC-6.4)

ONCP.NP.0006.4.A
v2.0.2024

- Risk Grouping will not be known at the time of initial staging, but is critical for all imaging decisions after initial staging is complete. **The treating oncologist should always know the individual's risk grouping.** It is not possible to establish the appropriate imaging plan for a neuroblastoma individual without knowing his/her risk group.

All Very Low Risk and Low Risk Neuroblastoma Not Receiving Chemotherapy:

Indication	Imaging Study
All individuals, 6 to 8 weeks after diagnosis to determine if additional treatment is necessary	<ul style="list-style-type: none">• CT with contrast or MRI without and with contrast of the primary tumor site. If primary tumor site is abdomen or pelvis, imaging of both sites is indicated.• Ultrasound may be used in place of CT or MRI to avoid radiation and/or anesthesia exposure in low risk individuals

Background and Supporting Information

- Many individuals will be treated with surgical resection only without adjuvant therapy, and these individuals enter immediately into surveillance.

All Intermediate Risk Neuroblastoma and Very Low Risk or Low Risk Neuroblastoma Receiving Chemotherapy:

Indication	Imaging Study
Prior to surgical resection	<ul style="list-style-type: none"> Restaging imaging (MIBG and CT or MRI, as performed at initial diagnosis)
Treatment response, as often as every 2 cycles of chemotherapy (~every 6 weeks and at the end of planned treatment)	<ul style="list-style-type: none"> CT Chest with contrast (CPT® 71260) and CT Abdomen and Pelvis with contrast (CPT® 74177) <p>OR</p> <ul style="list-style-type: none"> MRI Neck (CPT® 70543) without and with contrast, MRI Chest without and with contrast (CPT® 71552), and MRI Abdomen and Pelvis without and with contrast (CPT® 74183 and CPT® 72197) <p>AND</p> <ul style="list-style-type: none"> CT or MRI of other sites with prior measurable disease
In addition to treatment response listed above, every 4 cycles, and at the end of planned chemotherapy treatment	<ul style="list-style-type: none"> MIBG scan (see table in <u>Neuroblastoma - General Considerations (PEDONC-6.1)</u> for MIBG coding details)

Background and Supporting Information

- Individuals generally receive 2 to 12 cycles of moderate-intensity chemotherapy depending on response to treatment.
- Surgical resection may occur prior to or following chemotherapy depending on disease stage. Restaging prior to surgery is appropriate.

High-Risk Neuroblastoma:

Indication	Imaging Study
<ul style="list-style-type: none"> • ANY of the following: <ul style="list-style-type: none"> • Treatment response <ul style="list-style-type: none"> • As often as every 2 cycles of chemotherapy, mAb, or biologic therapy (~every 6 weeks) • Change in modality <ul style="list-style-type: none"> • Prior to surgery, HSCT, XRT, or mAb therapy • End of therapy 	<ul style="list-style-type: none"> • CT Chest with contrast (CPT® 71260) and CT Abdomen and Pelvis with contrast (CPT® 74177) OR • MRI Neck (CPT® 70543) without and with contrast, MRI Chest without and with contrast (CPT® 71552), and MRI Abdomen and Pelvis without and with contrast (CPT® 74183 and CPT® 72197) AND • CT or MRI of other sites with prior measurable disease • MIBG scan (see table in Neuroblastoma - General consideration (PEDONC-6.1) for MIBG coding details)
<p>At completion of ¹³¹I-MIBG therapy</p>	<ul style="list-style-type: none"> • ¹²³I-MIBG scan <ul style="list-style-type: none"> • FDG-PET cannot be used after ¹³¹I-MIBG therapy
<p>Preoperative planning</p>	<ul style="list-style-type: none"> • More frequent imaging with any of the above modalities can be approved around the time of surgery if needed

Background and Supporting Information

- This group of individuals receives highly aggressive therapy using sequential chemotherapy, surgery, high dose chemotherapy with stem cell rescue, radiotherapy, monoclonal antibody (mAb) immunotherapy, and biologic therapy.

Neuroblastoma – Surveillance Imaging (Risk Group Dependent) (PEDONC-6.5)

ONCP.NP.0006.5.A

v2.0.2024

Very Low Risk and Low Risk Neuroblastoma:

Indication	Imaging Study
All individuals	<ul style="list-style-type: none"> • Every 2 months for 1 year and annually for 3 years to complete 4 years surveillance: <ul style="list-style-type: none"> • Ultrasound of involved areas OR • 3, 6, 9, 12, 24, and 36 months after surgery or to clarify unclear findings on ultrasound: <ul style="list-style-type: none"> • CT with contrast or MRI without and with contrast of the primary tumor site • Ultrasound may be approved at 48 months after surgery to complete 4 years surveillance
Clarification of findings on CT or MRI suspicious for disease recurrence	<ul style="list-style-type: none"> • MIBG (see table in Neuroblastoma - General Considerations (PEDONC-6.1) for MIBG coding details)

Intermediate Risk Neuroblastoma:

Indication	Imaging Study
Favorable biology	<ul style="list-style-type: none"> • Every 3 months for 1 year, then every 4 months for 1 year, and then annually to complete 5 years surveillance <ul style="list-style-type: none"> • Ultrasound of involved areas <p>OR</p> <ul style="list-style-type: none"> • Every 3 months for 1 year, then every 6 months for 1 year, and then at 36 months after surgery or to clarify unclear findings on ultrasound: <ul style="list-style-type: none"> • CT with contrast or MRI without and with contrast of the primary tumor • Ultrasound may be approved at 48 and 60 months after surgery to complete 5 years surveillance • If primary site is abdomen or pelvis, both body sites may be approved (CPT® 74177 or the combination of CPT® 71297 and CPT® 74183) • If negative at 36 months, no further advanced imaging is necessary.
Unfavorable biology or risk for epidural extension	<ul style="list-style-type: none"> • Every 3 months for 1 year, every 6 months for 1 year, and then annually for 3 years to complete 5 years surveillance: <ul style="list-style-type: none"> • CT with contrast or MRI without and with contrast of the primary tumor site AND • MIBG scan (see table in Neuroblastoma – General Considerations (PEDONC-6.1) for coding details) • If primary site is abdomen or pelvis, both body sites may be approved (CPT® 74177 or the combination of CPT® 71297 and CPT® 74183)
<ul style="list-style-type: none"> • <u>BOTH of the following:</u> <ul style="list-style-type: none"> • Individuals with stage 4, or M disease, or 4S, or MS disease AND • Positive MIBG at completion of therapy 	<ul style="list-style-type: none"> • At 3, 6, 9, 12, 24, and 36 months after completion of therapy: <ul style="list-style-type: none"> • MIBG scan (see table in Neuroblastoma – General Considerations (PEDONC-6.1) for MIBG coding details) • If negative at 36 months, no further MIBG imaging is necessary. • MIBG (or PET, if MIBG-negative at initial diagnosis) not indicated for all other intermediate risk individuals

High Risk Neuroblastoma:

Indication	Imaging Study
All individuals	<ul style="list-style-type: none"> • Every 3 months for 2 years, then every 4 months for 1 year, and then annually to complete 6 years surveillance: <ul style="list-style-type: none"> • CT with contrast or MRI without and with contrast of the primary tumor site AND • MIBG scan (see table in Neuroblastoma – General Considerations (PEDONC-6.1) for MIBG coding details) • If primary site is abdomen or pelvis, both body sites may be approved (CPT® 74177 or the combination of CPT® 71297 and CPT® 74183) • If negative at 6 years, no further advanced imaging is necessary.
Suspected recurrence	<ul style="list-style-type: none"> • CT Chest/Abdomen/Pelvis with contrast (CPT® 71260, and CPT® 74177) or MRI without and with contrast, (CPT® 71552, CPT® 74183, and CPT® 72197) and other sites of prior measurable disease or current symptoms • MRI Brain with and without contrast (CPT® 70553) may be approved if signs or symptoms of brain involvement • MIBG scan (see table in Neuroblastoma - General Considerations (PEDONC-6.1) for MIBG coding details)

Background and Supporting Information

- Very Low Risk and Low Risk Neuroblastoma:
 - Urine HVA/VMA (if positive at diagnosis) at 1, 2, 3, 6, 9, 12, 18, 24, 36, 48, and 60 months after surgery
 - CT Chest is not indicated in asymptomatic surveillance imaging of any stages of neuroblastoma individuals with no prior history of thoracic disease
- Intermediate Risk Neuroblastoma:
 - Urine HVA/VMA (if positive at diagnosis) every month until 12 months after completion of therapy, then at 14, 16, 18, 21, 24, 30, and 36 months after completion of therapy, then annually until 10 years after completion of therapy
- High-Risk Neuroblastoma:
 - Early detection of recurrence with ¹²³I-MIBG has been shown to improve post-relapse outcomes in high-risk neuroblastoma
 - Urine HVA/VMA (if positive at diagnosis) at 3, 6, 9, 12, 18, 24, 30, 36, 42, 48, 54, and 60 months after completion of therapy, then annually until 10 years after completion of therapy, and for suspected recurrence.

References (PEDONC-6)

v2.0.2024

1. Brodeur GM, Hogarty MD, Bagatell R, et al. Neuroblastoma. In: Pizzo PA, Poplack DG, eds. Principles and Practice of Pediatric Oncology. 7th ed. Philadelphia, PA: Wolters Kluwer; 2016:772-797.
2. Shusterman S and George RE. Neuroblastoma. In: Orkin SH, Fisher DE, Ginsburg D, Look AT, Lux SE, Nathan DG, eds. Nathan and Oski's Hematology and Oncology of Infancy and Childhood. 8th ed. Philadelphia, PA: Elsevier Saunders; 2015:1675-1713.
3. Sharp SE, Gelfand MJ, Shulkin BL. Pediatrics: diagnosis of neuroblastoma. *Semin Nucl Med*. 2011;41(5):345-353. doi:10.1053/j.semnucmed.2011.05.001.
4. Kushner BH, Kramer K, Modak S, et al. Sensitivity of surveillance studies for detecting asymptomatic and unsuspected relapse of high-risk neuroblastoma. *J Clin Oncol*. 2009;27(7):1041-1046. doi:10.1200/JCO.2008.17.6107.
5. Uslu L, Doing J, Link M, Rosenberg J, Quon A, Daldrup-Link HE. Value of 18F-FDG PET and PET/CT for evaluation of pediatric malignancies. *J Nucl Med*. 2015;56(2):274-286. doi:10.2967/jnumed.114.146290.
6. Nuchtern JG, London WB, Barnewolt CE, et al. A prospective study of expectant observation as primary therapy for neuroblastoma in young infants: A Children's Oncology Group Study. *Ann Surg*. 2012;256(4):573-580. doi:10.1097/SLA.0b013e31826cbbbd.
7. Brisse HJ, McCarville MB, Granata C, et al. Guidelines for imaging and staging of neuroblastic tumors: Consensus report from the International Neuroblastoma Risk Group Project. *Radiology*. 2011;261(1):243-257. doi:10.1148/radiol.11101352.
8. Monclair T, Brodeur GM, Ambros PF, et al. The International Neuroblastoma Risk Group (INRG) staging system: an INRG task force report. *J Clin Oncol*. 2009;27(2):298-303. doi:10.1200/JCO.2008.16.6876.
9. Cohn SL, Pearson ADJ, London WB, et al. The International Neuroblastoma Risk Group (INRG) classification system: an INRG Task Force Report. *J Clin Oncol*. 2009;27(2):289-297. doi:10.1200/JCO.2008.16.6785.
10. GE Healthcare. AdreView™ Iobenguane I 123 Injection prescribing information. Revised September 2008. https://www.accessdata.fda.gov/drugsatfda_docs/label/2008/222901bl.pdf
11. Bombardieri E, Giammarile F, Aktolun C, et al. 131I/123I-Metaiodobenzylguanidine (MIBG) scintigraphy: procedure guidelines for tumor imaging. *Eur J Nucl Med Mol Imaging*. 2010;37(12):2436-2446. http://snmmi.files.cms-plus.com/docs/hpra/2010_published_OC_131I_123I_Metaiodobenzylguanidine_Scintigraphy.pdf.
12. Mueller WP, Copenrath E, Pfluger T. Nuclear medicine and multimodality imaging of pediatric neuroblastoma. *Pediatr Radiol*. 2013;43(4):418-427. doi:10.1007/s00247-012-2512-1.
13. Sharp SE, Gelfand MJ, Shulkin BL. Pediatrics: Diagnosis of neuroblastoma. *Semin Nucl Med*. 2011;41(5):345-353. doi:10.1053/j.semnucmed.2011.05.001.
14. McCarville MB. What MRI can tell us about neurogenic tumors and rhabdomyosarcoma. *Pediatr Radiol*. 2016;46(6):881-890. doi:10.1007/s00247-016-3572-4.
15. Pinto NR, Applebaum MA, Volchenboum SL, et al. Advances in risk classification and treatment strategies for neuroblastoma. *J Clin Oncol*. 2015;33(27):3008-3017. doi:10.1200/JCO.2014.59.4648.
16. Park JR, Bagatell R, Cohn SL, et al. Revisions to the International Neuroblastoma Response Criteria: A consensus statement from the National Cancer Institute clinical trials planning meeting. *J Clin Oncol*. 2017;35(22):2580-2587. doi:10.1200/JCO.2016.72.0177.
17. Federico SM, Brady SL, Pappo A, et al. The role of chest computed tomography (CT) as a surveillance tool in children with high risk neuroblastoma. *Pediatr Blood Cancer*. 2015;62(6):976-981. doi:10.1002/pbc.25400.
18. Gauguet J-M, Pace-Emerson T, Grant FD, et al. Evaluation of the utility of 99mTC-MDP bone scintigraphy versus MIBG scintigraphy and cross-sectional imaging for staging patients with neuroblastoma. *Pediatr Blood Cancer*. 2017;64:e26601. doi:10.1002/pbc.26601.
19. Venkatramani R, Pan H, Furman WL, et al. Multimodality treatment of pediatric esthesioneuroblastoma. *Pediatr Blood Cancer*. 2016;63(3):465-470. doi:10.1002/pbc.25817.
20. Owens C, Li BK, Thomas KE, et al. Surveillance imaging and radiation exposure, in the detection of relapsed neuroblastoma. *Pediatr Blood Cancer*. 2016;63(10):1786-1793. doi:10.1002/pbc.26099.
21. Allen-Rhoades W, Whittle SB, Rainusso N. Pediatric solid tumors of infancy: an overview. *Pediatr In Rev*. 2018;39(2):57-67. doi:10.1542/pir.2017-0057.
22. Park JR, Kreissman SG, London WB. Effect of tandem autologous stem cell transplant vs single transplant on event-free survival in patients with high-risk neuroblastoma. *JAMA*. doi:10.1001/jama.2019.11642.
23. Irwin MS, Naranjo A, Zhang FF, et al. Revised neuroblastoma risk classification system: a report from the Children's Oncology Group. *J Clin Oncol*. 2021;39(29):3229-3241. doi:10.1200/JCO.21.00278.

24. Maaz AUR, O'Doherty J, Djekidel M. 68Ga-DOTATATE PET/CT for neuroblastoma staging: utility for clinical use. *J Nucl Med Technol*. 2021;49(3):265-268. doi:10.2967/jnmt.120.258939.
25. Bar-Sever Z, Biassoni L, Shulkin B, et. al. Guidelines on nuclear medicine imaging in neuroblastoma. *Eur J Nucl Med Mol Imaging*. 2018;45(11):2009-2024. doi:10.1007/s00259-018-4070-8.
26. Bleeker G, Tytgat GAM, Adam JA, et. al. 123I-MIBG and 18F-FDGPET imaging for diagnosing neuroblastoma. *Cochrane Database of Systematic Reviews*. 2015;9. doi:10.1002/14651858.CD009263.pub2.
27. Lai HA, Sharp SE, Bhatia A, et. al. Imaging of pediatric neuroblastoma: A COG Diagnostic Imaging Committee/SPR Oncology Committee white paper. *Pediatr Blood Cancer*. 2022;e29974. doi:10.1002/psc.29974.
28. Vo KT, DuBois SG, Neuhaus J, et. al. Pattern and predictors of sites of relapse in neuroblastoma: A report from the International Neuroblastoma Risk Group (INRG) project. *Pediatr Blood Cancer*. 2022;69(9):e29616. doi:10.1002/psc.29616.

Pediatric Renal Tumors (PEDONC-7)

Guideline

- Pediatric Renal Tumors – General Considerations (PEDONC-7.1)
- Unilateral Wilms Tumor (UWT) (PEDONC-7.2)
- Bilateral Wilms Tumor (BWT) (PEDONC-7.3)
- Pediatric Renal Cell Carcinoma (RCC) (PEDONC-7.4)
- Clear Cell Sarcoma of the Kidney (CCSK) (PEDONC-7.5)
- Malignant Rhabdoid Tumor of the Kidney (MRT) and Other Extracranial Sites (PEDONC-7.6)
- Congenital Mesoblastic Nephroma (CMN) (PEDONC-7.7)
- References (PEDONC-7)

Pediatric Renal Tumors – General Considerations (PEDONC-7.1)

ONCP.RC.0007.1.U

v2.0.2024

- Ultrasound is considered first-line imaging for suspected pediatric renal mass, given the lack of radiation exposure and need for sedation. Advanced imaging for suspected Wilms Tumor should be done after initial assessment with ultrasound, which has often been completed prior to diagnosis.
- A variety of tumors can occur in the pediatric kidney, and include the following:
 - Wilms Tumor
 - Favorable Histology (FHWT)
 - Focal Anaplasia (FAWT)
 - Diffuse Anaplasia (DAWT)
 - Bilateral Wilms Tumor (BWT)
 - Renal Cell Carcinoma (RCC)
 - Clear Cell Sarcoma of the Kidney (CCSK)
 - Malignant Rhabdoid Tumor of the Kidney (MRT)
 - Congenital Mesoblastic Nephroma (CMN)
 - Other cancers occurring in the kidney:
 - Neuroblastoma
 - Primitive Neuroectodermal Tumor
 - Rhabdomyosarcoma
 - Non-Rhabdomyosarcoma Soft Tissue Sarcomas
 - These and other rare tumors have been reported occurring primarily in the kidney and should be imaged according to the guidelines for the specific histologic diagnosis.
- For suspected renal tumor, cell type unknown, image according to **Pediatric Renal Cell Carcinoma (RCC) (PEDONC-7.4)**
- PET is not **routinely** supported for initial staging, treatment response or surveillance of any pediatric renal tumor-rare circumstances where an exception to routine may be considered are listed in the relevant guideline sections

Unilateral Wilms Tumor (UWT) (PEDONC-7.2)

ONCP.RC.0007.2.A

v2.0.2024

Indication	Imaging Study
Initial Staging	<ul style="list-style-type: none"> CT Abdomen with contrast (CPT® 74160) <ul style="list-style-type: none"> CT Abdomen and Pelvis with contrast (CPT® 74177) may be approved in lieu of CPT® 74160 included if mass is presumed to extend into the pelvis. <ul style="list-style-type: none"> Doppler ultrasound to evaluate for tumor thrombus is not necessary unless CT findings are inconclusive CT Chest with (CPT® 71260) or without contrast (CPT® 71250) <ul style="list-style-type: none"> Should be completed prior to anesthesia exposure if possible PET is not routinely indicated in the initial staging of any pediatric renal tumor
Bilateral renal lesions noted on ultrasound or CT	<ul style="list-style-type: none"> MRI Abdomen (CPT® 74183) and Pelvis (CPT® 72197) without and with contrast
Additional initial staging imaging for any individual with neurologic signs or symptoms raising suspicion of CNS metastases	<ul style="list-style-type: none"> MRI Brain without and with contrast (CPT® 70553)
Additional initial staging imaging for any individual with signs or symptoms raising suspicion of bony metastases	<ul style="list-style-type: none"> Bone scan (see: PEDONC-1.3 for coding)
Treatment response ~every 2 cycles during treatment and at the end of planned therapy	<ul style="list-style-type: none"> CT Chest with (CPT® 71260) or without contrast (CPT® 71250) CT Abdomen with contrast (CPT® 74160) or CT Abdomen and Pelvis with contrast (CPT® 74177) or MRI Abdomen (CPT® 74183) and Pelvis (CPT® 72197) without and with contrast

Indication	Imaging Study
Rare circumstances to establish the presence of active disease only when a major therapeutic decision depends on PET avidity	<ul style="list-style-type: none"> PET/CT (CPT® 78815)
Surveillance	<ul style="list-style-type: none"> CT Chest with contrast (CPT® 71260) or CT Chest without contrast (CPT® 71250), or chest x-ray AND CT with contrast (CPT® 74160) or Abdominal US (CPT® 76700) <ul style="list-style-type: none"> Every 3 months for 2 years, then every 6 months for 2 additional years, to complete 4 years surveillance Pelvic imaging (CT or ultrasound) may be added for individuals treated with nephrectomy only or individuals with a history of tumor rupture, known pelvic involvement, or a history of disease recurrence
<ul style="list-style-type: none"> There are no data to support the use of PET imaging for routine surveillance in any individual with Wilms tumor. 	

Background and Supporting Information

- Many individuals will present with an asymptomatic abdominal mass, and will undergo ultrasound as a primary evaluation.
- Only ~0.5% of individuals with Wilms tumor will ever develop brain metastases
- A very low risk subset of stage I FHWT will be observed after nephrectomy, and enter directly into surveillance.
- The majority of individuals will receive chemotherapy with or without XRT, beginning within 14 days of initial surgery.

Bilateral Wilms Tumor (BWT) (PEDONC-7.3)

ONCP.RC.0007.3.A

v2.0.2024

Indication	Imaging Study
Initial Staging	<ul style="list-style-type: none"> • MRI Abdomen and Pelvis without and with contrast (CPT® 74183 and CPT® 72197) <ul style="list-style-type: none"> • CT Abdomen and Pelvis with contrast (CPT® 74177) may be approved in lieu of MRI per provider request. • CT Abdomen and Pelvis with contrast (CPT® 74177) is often performed prior to discovery of bilateral lesions and should not prevent MRI from being approved if requested <ul style="list-style-type: none"> • Doppler ultrasound to evaluate for tumor thrombus is not necessary unless CT findings are inconclusive • CT Chest with (CPT® 71260) or without contrast (CPT® 71250) <ul style="list-style-type: none"> • Should be completed prior to anesthesia exposure if possible • PET is not indicated in the initial staging of any pediatric renal tumor
Additional initial staging imaging for any individual with neurologic signs or symptoms raising suspicion of CNS metastases	<ul style="list-style-type: none"> • MRI Brain without and with contrast (CPT® 70553)
Additional initial staging imaging for any individual with signs or symptoms raising suspicion of bony metastases	<ul style="list-style-type: none"> • Bone scan (see: PEDONC-1.3 for coding)
Treatment response ~every 2 cycles during treatment and at the end of planned therapy	<ul style="list-style-type: none"> • MRI Abdomen and Pelvis without and with contrast (CPT® 74183 and CPT® 72197) <ul style="list-style-type: none"> • CT Abdomen and Pelvis with contrast (CPT® 74177) may be used for individuals with a contraindication to MRI • CT Chest with (CPT® 71260) or without contrast (CPT® 71250)

Indication	Imaging Study
Rare circumstances to establish the presence of active disease only when a major therapeutic decision depends on PET avidity	<ul style="list-style-type: none"> • PET/CT (CPT® 78815)
Surveillance	<ul style="list-style-type: none"> • Every 3 months for 2 years, then every 6 months for 2 additional years, to complete 4 years surveillance: <ul style="list-style-type: none"> • CT Chest with contrast (CPT® 71260) or CT Chest without contrast (CPT® 71250) or chest x-ray AND • CT Abdomen with contrast (CPT® 74160) or Abdominal US (CPT® 76700) • Pelvic imaging (CT or ultrasound) may be added for individuals treated with nephrectomy only or individuals with a history of tumor rupture, known pelvic involvement, or a history of disease recurrence
<ul style="list-style-type: none"> • PET is not routinely utilized to assess treatment response or for surveillance in Wilms tumor. 	

Background and Supporting Information

- Many individuals will present with an asymptomatic abdominal mass, and will undergo ultrasound as a primary evaluation.
- Individuals with bilateral Wilms Tumor may begin therapy without a histologic diagnosis to preserve a localized disease stage and attempt to shrink the tumors to allow for renal-sparing surgical approaches.
- Only ~0.5% of Wilms tumor individuals will ever develop brain metastases
- If treating with chemotherapy without a biopsy, disease evaluation is indicated at week 6. If either tumor has not shrunk 50%, then open biopsy is indicated to confirm favorable histology.
- If partial nephrectomy still not feasible at week 6, the next disease evaluation is at week 12. Surgical resection should occur no later than week 12.

Pediatric Renal Cell Carcinoma (RCC) (PEDONC-7.4)

ONCP.RC.0007.4.A

v2.0.2024

Indication	Imaging Study
Initial Staging	<ul style="list-style-type: none"> CT Abdomen and Pelvis with contrast (CPT® 74177) <ul style="list-style-type: none"> If bilateral renal lesions are noted on ultrasound or CT, MRI Abdomen and Pelvis without and with contrast (CPT® 74183 and CPT® 72197) should be strongly considered CT Chest with (CPT® 71260) <i>or</i> without contrast (CPT® 71250) <ul style="list-style-type: none"> Should be completed prior to anesthesia exposure if possible PET scan is not indicated in the initial staging of any pediatric renal tumor
Additional initial staging for any individual with neurologic signs or symptoms raising suspicion of CNS metastases	<ul style="list-style-type: none"> MRI Brain without and with contrast (CPT® 70553)
Additional initial staging for any individual with signs or symptoms raising suspicion of bony metastases	<ul style="list-style-type: none"> Bone scan (See: PEDONC-1.3 for coding)
Treatment response in individuals with residual measurable disease after initial surgery and receiving adjuvant medical therapy	<ul style="list-style-type: none"> Every 2 cycles during active treatment: <ul style="list-style-type: none"> CT Chest with (CPT® 71260) <i>or</i> without contrast (CPT® 71250) and CT Abdomen with contrast (CPT® 74160) <ul style="list-style-type: none"> Pelvic imaging is not indicated unless prior pelvic involvement has been documented
Rare circumstances to establish the presence of active disease only when a major therapeutic decision depends on PET avidity	<ul style="list-style-type: none"> PET/CT (CPT® 78815) Indications and coding for rare circumstances where PET/MRI may be approved are found in PET Imaging in Pediatric Oncology (PEDONC-1.4)

Indication	Imaging Study
Surveillance in individuals with documented CNS metastases	<ul style="list-style-type: none"> • Every 6 months for 2 years after completion of all therapy: <ul style="list-style-type: none"> • MRI Brain without and with contrast (CPT® 70553)
Surveillance in individuals with TFE3 or TFEB subtype	<ul style="list-style-type: none"> • Every 3 months for 2 years, then every 6 months for 2 years after completion of all therapy: <ul style="list-style-type: none"> • CT Chest with (CPT® 71260) or without contrast (CPT® 71250) • CT Abdomen with contrast (CPT® 74160) or MRI Abdomen without and with contrast (CPT® 74183) <ul style="list-style-type: none"> • Pelvic imaging is not indicated for surveillance unless prior pelvic involvement has been documented
Surveillance in all other histologies	<ul style="list-style-type: none"> • See: <u>Renal Cell Cancer (RCC) – Surveillance (ONC-17.4)</u>
New signs/symptoms suggestive of CNS recurrence	<ul style="list-style-type: none"> • MRI Brain without and with contrast (CPT® 70553)
<ul style="list-style-type: none"> • PET is not routinely utilized to assess treatment response in pediatric RCC. 	

Background and Supporting Information

- A majority of pediatric cases have a novel subtype involving TFE3 or TFEB translocations, which have a different natural history than “adult type” RCC
- Individuals of any age with TFE3 or TFEB translocated RCC should be imaged according to this guideline section.
- 40% to 45% of pediatric RCC cases have similar histologies to adult RCC (clear cell, papillary, chromophobe, etc.) and imaging decisions will be similar to general oncology guidelines.
- Individuals with all other subtypes of RCC should be imaged according to **Renal Cell Cancer (RCC) (ONC-17)** in the Oncology Imaging Guidelines
- Many individuals will present with an asymptomatic abdominal mass, and will undergo ultrasound as a primary evaluation. Doppler ultrasound to evaluate for tumor thrombus is no longer necessary unless CT findings are inconclusive, and should not be performed if CT is already completed.
- Other staging imaging than what is stated in the above table should be deferred until a histologic diagnosis is made, by complete nephrectomy for most unilateral renal tumors and biopsy for bilateral renal tumors or inoperable unilateral tumors
- Most individuals will have surgical resection of all disease at the time of diagnosis and will enter directly into surveillance

Clear Cell Sarcoma of the Kidney (CCSK) (PEDONC-7.5)

ONCP.RC.0007.5.A

v2.0.2024

Be careful not to confuse the diagnosis with clear cell RCC. See: Renal Cell Cancer (RCC) (ONC-17) for imaging guidelines.

Indication	Imaging Study
Initial Staging	<ul style="list-style-type: none"> CT Abdomen and Pelvis with contrast (CPT® 74177) <ul style="list-style-type: none"> Doppler ultrasound to evaluate for tumor thrombus is not necessary unless CT findings are inconclusive CT Chest with (CPT® 71260) or without contrast (CPT® 71250) <ul style="list-style-type: none"> Should be completed prior to anesthesia exposure if possible Bone scan (see: PEDONC-1.3 for coding) MRI Brain without and with contrast (CPT® 70553) PET is not indicated in the initial staging of any pediatric renal tumor
Bilateral renal lesions are noted on ultrasound or CT in initial staging	<ul style="list-style-type: none"> MRI Abdomen and Pelvis without and with contrast (CPT® 74183 and CPT® 72197)
Treatment response ~every 2 cycles during treatment and at the end of planned therapy	<ul style="list-style-type: none"> CT Chest with (CPT® 71260) or without contrast (CPT® 71250) CT Abdomen and Pelvis with contrast (CPT® 74177) or MRI Abdomen and Pelvis without and with contrast (CPT® 74183 and CPT® 72197) Additionally, for individuals with CNS metastases at initial staging: <ul style="list-style-type: none"> MRI Brain without and with contrast (CPT® 70553) Bone scan (see: Modality General Considerations (PEDONC-1.3) for coding) at the end of planned therapy
Rare circumstances to establish the presence of active disease only when a major therapeutic decision depends on PET avidity	<ul style="list-style-type: none"> PET/CT (CPT® 78815) Indications and coding for rare circumstances where PET/MRI may be approved are found in PET Imaging in Pediatric Oncology (PEDONC-1.4)

Indication	Imaging Study
Surveillance	<ul style="list-style-type: none"> • Every 3 months for 2 years after completion of all therapy: <ul style="list-style-type: none"> • CT Chest with (CPT® 71260) <i>or</i> without contrast (CPT® 71250) • CT Abdomen and Pelvis with contrast (CPT® 74177) or MRI Abdomen and Pelvis without and with contrast (CPT® 74183 and CPT® 72197) • Every 6 months for 3 years after completion of all therapy: <ul style="list-style-type: none"> • MRI Brain without and with contrast (CPT® 70553) • Every 3 months for 1 year, then every 6 months for 2 years after completion of all therapy: <ul style="list-style-type: none"> • Bone scan (see: Modality General Considerations (PEDONC-1.3) for coding) • If negative at 36 months, no further advanced imaging is necessary. • Other surveillance imaging should be by Abdominal US (CPT® 76700) and chest x-ray

Background and Supporting Information

- Many individuals will present with an asymptomatic abdominal mass, and will undergo ultrasound as a primary evaluation.
- Other staging imaging should be deferred until a histologic diagnosis is made, by complete nephrectomy for most unilateral renal tumors and biopsy for bilateral renal tumors or inoperable unilateral tumors

Malignant Rhabdoid Tumor of the Kidney (MRT) and Other Extracranial Sites (PEDONC-7.6)

ONCP.RC.0007.6.A
v2.0.2024

Be careful not to confuse the diagnosis with rhabdomyosarcoma. See: Rhabdomyosarcoma (RMS) (PEDONC-8.2) for Imaging Guidelines

Indication	Imaging Study
Initial Staging	<ul style="list-style-type: none"> • CT Abdomen and Pelvis with contrast (CPT® 74177) <ul style="list-style-type: none"> • Doppler ultrasound to evaluate for tumor thrombus is not necessary unless CT findings are inconclusive • CT Chest with (CPT® 71260) or without contrast (CPT® 71250) <ul style="list-style-type: none"> • Should be completed prior to anesthesia exposure if possible • Bone scan (see: PEDONC-1.3 for coding) • MRI Brain without and with contrast (CPT® 70553) • PET is not indicated in the initial staging of any pediatric renal tumor
Bilateral renal lesions are noted on ultrasound or CT in initial staging	<ul style="list-style-type: none"> • MRI Abdomen and Pelvis without and with contrast
Treatment response ~every 2 cycles during treatment and at the end of planned therapy	<ul style="list-style-type: none"> • CT Chest with (CPT® 71260) or without contrast (CPT® 71250) • CT Abdomen and Pelvis with contrast (CPT® 74177) or MRI Abdomen and Pelvis without and with contrast (CPT® 74183 and CPT® 72197) <ul style="list-style-type: none"> • If primary site other than kidney, perform CT with contrast or MRI without and with contrast of primary site in place of abdominal and pelvic imaging • MRI Brain without and with contrast (CPT® 70553) can be performed: <ul style="list-style-type: none"> • Every 2 cycles during treatment for individuals with CNS metastases at initial staging • At the end of planned therapy for all individuals • Bone scan (see: PEDONC-1.3 for coding) at the end of planned therapy only if positive at initial diagnosis

Indication	Imaging Study
Rare circumstances to establish the presence of active disease only when a major therapeutic decision depends on PET avidity	<ul style="list-style-type: none"> • PET/CT (CPT® 78815) • Indications and coding for rare circumstances where PET/MRI may be approved are found in <u>PET Imaging in Pediatric Oncology (PEDONC-1.4)</u>
Surveillance	<ul style="list-style-type: none"> • Every 3 months for 2 years after completion of all therapy: <ul style="list-style-type: none"> • CT Chest with (CPT® 71260) or without contrast (CPT® 71250) • Every 3 months for 3 years after completion of all therapy: <ul style="list-style-type: none"> • CT Abdomen and Pelvis with contrast (CPT® 74177) or MRI Abdomen and Pelvis without and with contrast (CPT® 74183 and CPT® 72197) <ul style="list-style-type: none"> • If primary site other than kidney, perform CT with contrast or MRI without and with contrast of primary site in place of abdominal imaging • Every 3 months for 1 year, then every 6 months for 1 year after completion of all therapy: <ul style="list-style-type: none"> • MRI Brain without and with contrast (CPT® 70553) • If bone scan positive at initial diagnosis: <ul style="list-style-type: none"> • Every 3 months for 1 year, then every 6 months for 2 years: <ul style="list-style-type: none"> • Bone scan (see: <u>PEDONC-1.3</u> for coding) • If negative at 36 months, no further advanced imaging is necessary • The role of surveillance imaging beyond these timeframes is unclear. Abdominal US (CPT® 76700) and chest x-ray may be considered
Continued Surveillance of individuals with Rhabdoid Tumor predisposition Syndrome	<ul style="list-style-type: none"> • See: <u>Rhabdoid Tumor Predisposition Syndrome (PEDONC-2.11)</u>

Background and Supporting Information

- MRT is a highly aggressive histologic variant that can also occur in other locations and all non-CNS sites should follow these guidelines.
- Primary CNS rhabdoid malignancies should be imaged according to **Atypical Teratoid/Rhabdoid Tumors (ATRT) PEDONC-4.5**
- Many individuals will present with an asymptomatic abdominal mass, and will undergo ultrasound as a primary evaluation.
- Other staging imaging should be deferred until a histologic diagnosis is made, by complete nephrectomy for most unilateral renal tumors and biopsy for bilateral renal tumors or inoperable unilateral tumors

Congenital Mesoblastic Nephroma (CMN) (PEDONC-7.7)

ONCP.RC.0007.7.A

v2.0.2024

Congenital Mesoblastic Nephroma Initial Staging

- CT Abdomen and Pelvis with contrast (CPT® 74177) is indicated in all individuals
- CT Chest with (CPT® 71260) can be approved to evaluate inconclusive findings on chest x-ray

Congenital Mesoblastic Nephroma Treatment Response

- CT Abdomen and Pelvis with contrast (CPT® 74177) once following resection to establish baseline imaging, and those with a complete resection should then be imaged according to surveillance guidelines
- CT Abdomen and Pelvis with contrast (CPT® 74177) for individuals receiving preoperative chemotherapy every 2 cycles of therapy until surgery and then should be imaged according to surveillance guidelines after their postoperative baseline imaging study

Congenital Mesoblastic Nephroma Surveillance Imaging

- Ultrasound is the preferred surveillance imaging modality to avoid radiation and anesthesia exposures
- CT Abdomen and Pelvis with contrast (CPT® 74177) **or** MRI Abdomen and Pelvis without and with contrast (CPT® 74183 and CPT® 72197) for residual abnormalities present on post-operative imaging or inconclusive findings on ultrasound every 3 months for 1 year after completion of all therapy

Background and Supporting Information

- This is the most common primary renal tumor occurring in young infants, and the overall prognosis is very good
- Complete surgical removal is curative in most cases, and histologically confirmed metastatic disease or bilateral disease has never been reported
- Many individuals will present with an asymptomatic abdominal mass at the time of birth or abnormal prenatal ultrasound, and will undergo ultrasound as a primary evaluation.
- PET is not indicated in the initial staging of any pediatric renal tumor
- Recurrences are rare but most occur within 12 months of diagnosis

References (PEDONC-7)

v2.0.2024

1. Fernandez C, Geller JI, Ehrlich PF, et al. Renal tumors. In: Pizzo PA, Poplack DG, eds. Principles and Practice of Pediatric Oncology. 7th ed. Philadelphia, PA: Wolters Kluwer; 2016:753-771.
2. Dome JS, Mullen EA, and Argani P. Pediatric renal tumors. In: Orkin SH, Fisher DE, Ginsburg D, Look AT, Lux SE, Nathan DG, eds. Nathan and Oski's Hematology and Oncology of Infancy and Childhood. 8th ed. Philadelphia, PA: Elsevier Saunders; 2015:1714-1746.
3. Kaste SC, Brady SL, Yee B, et al. Is routine pelvic surveillance imaging necessary in patients with Wilms tumor? *Cancer*. 2013;119(1):182-188. doi:10.1002/cncr.27687.
4. Malkan AD, Loh A, Bahrami A, et al. An approach to renal masses in pediatrics. *Pediatrics*. 2015;135(1):142-158. doi:10.1542/peds.2014-1011.
5. Khanna G, Rosen N, Anderson JR, et al. Evaluation of diagnostic performance of CT for detection of tumor thrombus in children with Wilms tumor: a report from the Children's Oncology Group. *Pediatr Blood Cancer*. 2012;58(4):551-555. doi:10.1002/pbc.23222.
6. Kieran K and Ehrlich PF. Current surgical standards of care in Wilms tumor. *Urol Oncol*. 2016;34(1):13-23. doi:10.1016/j.urolonc.2015.05.029.
7. Moinul Hossain AK, Shulkin BL, Gelfand MJ, et al. FDG positron emission tomography/computed tomography studies of Wilms' tumor. *Eur J Nucl Med Mol Imaging*. 2010;37(7):1300-1308. doi:10.1007/s00259-010-1396-2.
8. Misch D, Steffen IG, Schönberger S, et al. Use of positron emission tomography for staging, preoperative response assessment and post therapeutic evaluation in children with Wilms tumor. *Eur J Nucl Med Mol Imaging*. 2008;35(9):1642-1650. doi:10.1007/s00259-008-0819-9.
9. Servaes S, Khanna G, Naranjo A, et al. Comparison of diagnostic performance of CT and MRI for abdominal staging of pediatric renal tumors: a report from the Children's Oncology Group. *Pediatr Radiol*. 2015;45(2):166-172. doi:10.1007/s00247-014-3138-2.
10. Servaes SE, Hoffer FA, Smith EA, Khanna G. Imaging of Wilms tumor: an update. *Pediatr Radiol*. 2019;49(11):1441-1452. doi:10.1007/s00247-019-04423-3.
11. Uslu L, Doing J, Link M, Rosenburg J, Quon A, Daldrup-Link HE. Value of 18F-FDG PET and PET/CT for Evaluation of Pediatric Malignancies. *J Nucl Med*. 2015;56(2):274-286. doi:10.2967/jnumed.114.146290.
12. Dome JS, Graf N, Geller JI, et al. Advances in Wilms tumor treatment and biology: progress through international collaboration. *J Clin Oncol*. 2015;33(27):2999-3007. doi:10.1200/JCO.2015.62.1888.
13. Venkatramani R, Chi Y-Y, Coppes MJ, et al. Outcome of patients with intracranial relapse enrolled on National Wilms Tumor Study Group clinical trials. *Pediatr Blood Cancer*. 2017;64(7):e26406. doi:10.1002/pbc.26406.
14. Mullen EA, Chi Y-Y, Hibbitts E, et al. Impact of surveillance imaging modality on survival after recurrence in patients with favorable-histology Wilms tumor: a report from the Children's Oncology Group. *J Clin Oncol*. 2018;36:3396-3403. doi:10.1200/JCO.18.00076.
15. Ehrlich P, Chi Y-Y, Chintagumpala MM, et al. Results of the first prospective multi-institutional treatment study in children with bilateral Wilms tumor (AREN0534): a report from the Children's Oncology Group. *Ann Surg*. 2017;266(3):470-478. doi:10.1097/SLA.0000000000002356.
16. Geller JI, Ehrlich PF, Cost NG, et al. Characterization of adolescent and pediatric renal cell carcinoma: a report from the Children's Oncology Group study AREN03B2. *Cancer*. 2015 July; 121(14):2457-2464. doi:10.1002/cncr.29368.
17. Rialon KL, Gulack BC, Englum BR, Routh JC, Rice HE. Factors impacting survival in children with renal cell carcinoma. *J Pediatr Surg*. 2015;50(6):1014-1018. doi:10.1016/j.jpedsurg.2015.03.027.
18. Young EE, Brown CTG, Merguerian PA, Akhavan A. Pediatric and adolescent renal cell carcinoma. *Urol Oncol*. 2016;34(1):42-49. doi:10.1016/j.urolonc.2015.06.009.
19. Gooskens SL, Houwing ME, Vujanic GM, et al. Congenital mesoblastic nephroma 50 years after its recognition: a narrative review. *Pediatr Blood Cancer*. 2017; 64(7):e26437. doi:10.1002/pbc.26437.
20. Seibel NL, Chi YY, et al. Impact of cyclophosphamide and etoposide on outcome of clear cell sarcoma of the kidney treated on the National Wilms Tumor Study-5 (NWTS-5). *Pediatr Blood Cancer*. 2019;66(1):e27450. doi:10.1002/pbc.27450.
21. Balis F, Green DM, Anderson C, et al. National Comprehensive Cancer Network (NCCN) Guidelines Version 1.2023 – March 14, 2023. Wilms Tumor (Nephroblastoma), available at: https://www.nccn.org/professionals/physician_gls/pdf/wilms_tumor.pdf, Referenced with permission from the NCCN Clinical Practice Guidelines in Oncology (NCCN Guidelines™) for Wilms Tumor (Nephroblastoma) V1.2023 – 3/14/2023. ©2023 National Comprehensive Cancer Network, Inc. All rights reserved. The NCCN Guidelines™ and illustrations herein may not be reproduced in any form for any

purpose without the express written permission of the NCCN. To view the most recent and complete version of the NCCN Guidelines™, go online to NCCN.org.

22. Servaes SE, Hoffer FA, Smith EA, Khanna G. Imaging of Wilms tumor: an update. *Pediatric Radiol.* 2019;49(11):1441–1452. doi:10.1007/s00247-019-04423-3.
23. Dix DB, Seibel NL, Chi Y, et. al. Treatment of stage IV favorable histology Wilms tumor with lung metastases: a report from the Children's Oncology Group AREN0533 study. *J Clin Oncol.* 2018;36(16):1564-1570. doi:10.1200/JCO.2017.77.1931.

Pediatric Soft Tissue Sarcomas (PEDONC-8)

Guideline

Pediatric Soft Tissue Sarcomas – General Considerations (PEDONC-8.1)

Rhabdomyosarcoma (RMS) (PEDONC-8.2)

Non-Rhabdomyosarcoma Soft Tissue Sarcomas (NRSTS) (PEDONC-8.3)

References (PEDONC-8)

Pediatric Soft Tissue Sarcomas – General Considerations (PEDONC-8.1)

ONCP.SS.0008.1.U

v2.0.2024

- Unless specified below, individuals age <18 years old should be imaged according to this guideline section. Exceptions include:
 - Rhabdomyosarcoma in individuals (except uterine rhabdomyosarcoma) of all ages should be imaged according to guidelines in **Rhabdomyosarcoma (RMS) (PEDONC-8.2)**
 - Uterine rhabdomyosarcoma individuals of all ages should be imaged according to guidelines in Uterine Cancer (ONC-22). See: **Uterine Cancer – General Considerations (ONC-22.0)** in the Oncology Imaging Guidelines
 - Kaposi's sarcoma in individuals of all ages should be imaged according to guidelines in **Kaposi's Sarcoma (ONC-31.10)** in the Oncology Imaging Guidelines
- Evaluation of soft tissue masses of uncertain nature prior to biopsy should follow general imaging guidelines:
 - Individuals age 0 to 17 years, see: **Soft Tissue and Bone Masses (PEDMS-3)** in the Pediatric Musculoskeletal Imaging Guidelines
 - Individuals age ≥18 years, see: **Soft Tissue Mass or Lesion of Bone (MS-10)** in the Musculoskeletal Imaging Guidelines
- Where there are indications for PET/CT in these guidelines, note that indications and coding for rare circumstances where PET/MRI may be approved are found in **PET Imaging in Pediatric Oncology (PEDONC-1.4)**

Rhabdomyosarcoma (RMS) (PEDONC-8.2)

ONCP.SS.0008.2.A

v2.0.2024

- Individuals of all ages are imaged according to this guideline, with exception of uterine rhabdomyosarcoma, which is imaged according to Uterine Cancer (ONC-22). See: **Uterine Cancer – General Considerations (ONC-22.0)** in the Oncology Imaging Guidelines.

Indication	Imaging Study
Initial staging for all individuals	<p><u>ALL of the following:</u></p> <ul style="list-style-type: none"> MRI without and with contrast of primary site <ul style="list-style-type: none"> CT with contrast is supported if MRI is contraindicated CT Chest with contrast or CT Chest without contrast <ul style="list-style-type: none"> Should be completed prior to anesthesia exposure if possible Whole-Body PET/CT (CPT® 78816) <ul style="list-style-type: none"> Bone scan may be substituted for PET, if PET not available
<p><u>Additional initial staging for ANY of the following:</u></p> <ul style="list-style-type: none"> Evaluation of inconclusive PET findings in the abdomen or pelvis Primary site of abdomen or pelvis Lower extremity primary site 	<ul style="list-style-type: none"> CT Abdomen and Pelvis with contrast (CPT 74177)
<p><u>Additional initial staging for ANY of the following:</u></p> <ul style="list-style-type: none"> Primary site involving the paraspinal or paravertebral region PET or bone scan-avid lesions in skull, neck, vertebrae Neurologic signs or symptoms raising suspicion of CNS metastases 	<p><u>ALL of the following:</u></p> <ul style="list-style-type: none"> MRI Brain (CPT® 70553) MRI Spine without and with contrast (Cervical-CPT® 72156, Thoracic-CPT® 72157, Lumbar-CPT® 72158)

Indication	Imaging Study
<p>Treatment response, every 2 cycles during treatment, prior to local control surgery, and at the end of planned therapy</p>	<p><u>ALL of the following:</u></p> <ul style="list-style-type: none"> • CT Chest with (CPT® 71260) contrast or CT Chest without contrast (CPT® 71250) • MRI without and with contrast of primary site <ul style="list-style-type: none"> • CT may be used if used at initial imaging for MRI contraindication • CT with contrast or MRI without and with contrast of all known metastatic sites using the same conventional imaging modality as per initial staging
<p><u>ANY of the following:</u></p> <ul style="list-style-type: none"> • Response assessment prior to local control surgery or radiation therapy • Evaluation of residual mass visible on conventional imaging as part of end of therapy evaluation • Response assessment of disease visible on PET but not conventional imaging • PET results are likely to result in a treatment change for the individual, including a change from active treatment to surveillance. 	<ul style="list-style-type: none"> • Whole-body PET/CT (CPT® 78816) <ul style="list-style-type: none"> • Once PET has been documented to be negative for a given individual's cancer or all PET-avid disease has been surgically resected, PET should not be used for continued disease monitoring or surveillance unless one of the exceptions in section General Guidelines (PEDONC-1.0) applies.
<p>Restaging following local control surgery</p>	<p><u>ALL of the following:</u></p> <ul style="list-style-type: none"> • MRI without and with contrast of primary site <ul style="list-style-type: none"> • CT may be used if used at initial imaging for MRI contraindication • CT with contrast or MRI without and with contrast of all known metastatic sites using the same conventional imaging modality as per initial staging

Indication	Imaging Study
Surveillance, localized RMS	<p><u>ALL of the following, every 3 months for 1 year, then every 4 months for 2 years, then every 6 months for 1 year after completion of all therapy:</u></p> <ul style="list-style-type: none"> • MRI without or without and with contrast of primary tumor site <ul style="list-style-type: none"> • CT may be substituted if MRI contraindicated • Chest x-ray <ul style="list-style-type: none"> • CT Chest with (CPT® 71260) or CT Chest without contrast (CPT® 71250) is indicated for new or worsening clinical symptoms of chest disease or new findings on chest x-ray
Surveillance, metastatic RMS	<p><u>ALL of the following, every 3 months for 1 year, then every 4 months for 2 years, then every 6 months for 1 year after completion of all therapy:</u></p> <ul style="list-style-type: none"> • MRI without or without and with contrast of primary tumor site • CT may be substituted if contraindication to MRI • CT Chest with (CPT® 71260) or without contrast (CPT® 71250) • CT with or without contrast of all known metastatic sites • Nuclear bone scan (see: PEDONC-1.3 for coding) for surveillance of known bony metastases
Suspected recurrence	<ul style="list-style-type: none"> • Repeat conventional imaging as per initial staging for all individuals

Indication	Imaging Study
<p>ONE of the following:</p> <ul style="list-style-type: none"> • Biopsy-proven recurrence • Conventional imaging (CT, MRI, US, plain film) reveals findings that are inconclusive or suspicious for recurrence, and PET avidity will determine whether biopsy or continued observation is appropriate • Rare circumstances where obvious clinical symptoms show strong evidence suggesting recurrence, and PET would replace conventional imaging modalities. 	<ul style="list-style-type: none"> • Whole-body PET/CT (CPT® 78816)

Background and Supporting Information

- Soft tissue sarcomas occur in both adult and pediatric individuals, but some are more common in one age group than the other.
- Pediatric soft tissue sarcomas are divided into **two** groups:
 - Rhabdomyosarcoma (RMS) accounts for ~60% of soft tissue sarcomas in young individuals, but only ~25% of soft tissue sarcomas in adolescents
 - Nonrhabdomyosarcoma soft tissue sarcomas (NRSTS) which encompasses all other histologic subtypes
- Because RMS can arise from any muscle tissue, the presenting symptoms and primary tumor sites vary widely and strongly influence the appropriate imaging decisions
- CT with contrast is the preferred primary site imaging modality for RMS arising in the thoracic cavity (not the chest wall)
- MRI without and with contrast is the preferred primary site imaging modality for RMS occurring in all other anatomic locations, including the chest wall.
- PET/CT is superior to conventional imaging for detection of nodal and bony metastases in pediatric RMS and is indicated in the initial staging of all individuals after histologic diagnosis is established
- CT Abdomen and Pelvis with contrast (CPT® 74177) is not routinely indicated in the initial metastatic staging of pediatric RMS
- PET is not routinely utilized to assess treatment response in RMS
- PET is generally not indicated during active treatment for recurrent pediatric cancer

- Residual mass that has not changed in size since the last conventional imaging does not justify PET imaging during surveillance
- PET avidity in a residual mass at the end of planned therapy is not an indication for PET imaging during surveillance

Non-Rhabdomyosarcoma Soft Tissue Sarcomas (NRSTS) (PEDONC-8.3)

ONcp.ss.0008.3.A

v2.0.2024

Indication	Imaging Study
Initial staging of all individuals	<p><u>ALL</u> of the following:</p> <ul style="list-style-type: none"> • MRI without and with contrast of primary site <ul style="list-style-type: none"> • CT with contrast may be substituted if contraindication to MRI • CT Chest with contrast or without contrast <ul style="list-style-type: none"> • Should be completed prior to anesthesia if possible • For primary tumor of the chest wall, both MRI Chest wall without and with contrast (CPT® 71552) and CT Chest with contrast (CPT® 71260) or without contrast to assess for pulmonary metastatic disease (indicated simultaneously) • PET/CT (CPT® 78815) <ul style="list-style-type: none"> • Whole-body PET/CT (CPT® 78816) if there is clinical suspicion of skull or distal lower extremity involvement • Nuclear bone scan (see: PEDONC-1.3 for coding) if PET is not available
<p><u>ANY</u> of the following:</p> <ul style="list-style-type: none"> • Additional initial staging for individuals with disease in the abdomen, pelvis, or lower extremities • Inconclusive findings in the abdomen on PET/CT 	<ul style="list-style-type: none"> • CT Abdomen and Pelvis with contrast (CPT® 74177) if not already performed
Additional staging for individuals with primary site arising in the paraspinal or paravertebral region	<ul style="list-style-type: none"> • MRI Brain (CPT® 70553) and Spine (Cervical-CPT® 72156, Thoracic-CPT® 72157, Lumbar-CPT® 72158) without and with contrast

Indication	Imaging Study
<p>Further evaluation of ANY of the following:</p> <ul style="list-style-type: none"> • PET or nuclear bone scan-avid lesions in skull, neck, or vertebrae seen on initial imaging • Neurologic signs or symptoms raising suspicion of CNS metastases 	<p><u>ALL of the following:</u></p> <ul style="list-style-type: none"> • MRI Brain (CPT® 70553) • MRI Spine (Cervical-CPT® 72156, Thoracic-CPT® 72157, Lumbar-CPT® 72158)
<p>Treatment response, every 2 cycles of treatment, prior to local control, and at the end of planned therapy</p>	<p><u>Either of the following:</u></p> <ul style="list-style-type: none"> • CT Chest with (CPT® 71260) or CT Chest without contrast (CPT® 71250), and • MRI without and with contrast of primary site <ul style="list-style-type: none"> • CT may be substituted if contraindication to MRI and • Imaging of all known metastatic sites using the same conventional imaging modality as per initial staging <p>OR</p> <ul style="list-style-type: none"> • PET/CT (CPT® 78815) if disease visible on initial staging PET but not on conventional imaging <ul style="list-style-type: none"> • Whole-body PET/CT (CPT® 78816) if there is clinical suspicion of skull or distal lower extremity involvement

Indication	Imaging Study
<p>ANY of the following, if PET positive at initial diagnosis:</p> <ul style="list-style-type: none"> • Assessment prior to local control surgery or radiation therapy • Evaluation of residual mass visible on conventional imaging as part of end of therapy evaluation • Rare circumstances when PET results are likely to result in a treatment change for the individual, including a change from active treatment to surveillance 	<ul style="list-style-type: none"> • PET/CT (CPT® 78815) <ul style="list-style-type: none"> • Whole-body PET/CT (CPT® 78816) if there is clinical suspicion of skull or distal lower extremity involvement • Once PET has been documented to be negative for a given individual's cancer or all PET-avid disease has been surgically resected, PET should not be used for continued disease monitoring or surveillance unless one of the exceptions in section General Guidelines (PEDONC-1.0) applies.
<p>Restaging following local control surgery</p>	<p>ALL of the following:</p> <ul style="list-style-type: none"> • MRI without and with contrast of the primary site <ul style="list-style-type: none"> • CT may be substituted if contraindication to MRI • Imaging of all known metastatic sites using the same conventional imaging modality as per initial staging
<p>Surveillance, localized NRSTS treated with resection (with or without radiation) or chemotherapy</p>	<p><u>Every 3 months for the first 12 months, then every 4 months in years 2 and 3, and every 6 months in years 4 and 5 to complete 5 years surveillance after completion of therapy:</u></p> <ul style="list-style-type: none"> • MRI without and with contrast of the primary site • CT may be substituted if MRI contraindicated <p>AND</p> <p><u>Every 6 months for 3 years after completion of all therapy</u></p> <ul style="list-style-type: none"> • CT Chest with (CPT® 71260) or CT Chest without contrast (CPT® 71250) <ul style="list-style-type: none"> • CT Chest only supported for new symptoms or new findings on chest x-ray thereafter.

Indication	Imaging Study
<p>Surveillance of metastatic NRSTS, and no prior history of disease in the chest</p>	<p><u>Every 3 months for the first 12 months, then every 4 months in years 2 and 3, and every 6 months in years 4 and 5 to complete 5 years surveillance after completion of therapy:</u></p> <ul style="list-style-type: none"> • MRI without and with contrast of the primary site <ul style="list-style-type: none"> • CT may be substituted if MRI contraindicated • Nuclear bone scan (see: PEDONC-1.3 for coding) for surveillance of known bony metastases <p>AND</p> <p><u>Every 6 months for 3 years:</u></p> <ul style="list-style-type: none"> • CT Chest with (CPT® 71260) or CT Chest without contrast (CPT® 71250)
<p>Surveillance of metastatic NRSTS, and known prior history of metastatic disease in the chest</p>	<p><u>Every 3 months for the first 12 months, then every 4 months in years 2 and 3, and every 6 months in years 4 and 5 to complete 5 years surveillance after completion of therapy:</u></p> <ul style="list-style-type: none"> • MRI without and with contrast of the primary site <ul style="list-style-type: none"> • CT may be substituted if MRI contraindicated • CT Chest with contrast (CPT® 71260) or CT Chest without contrast (CPT® 71250) • Nuclear bone scan (see: PEDONC-1.3 for coding) for surveillance of known bony metastases
<p>Surveillance, recurrent NRSTS</p>	<p><u>ALL of the following after successful treatment for recurrent disease, every 3 months for 1 year:</u></p> <ul style="list-style-type: none"> • CT Chest (CPT® 71260) with contrast • CT with contrast or MRI without and with contrast of the primary site • Surveillance in years 2 through 5 after completing therapy for recurrence should follow the standard timing listed in the appropriate surveillance section

Indication	Imaging Study
<p>ANY of the following:</p> <ul style="list-style-type: none"> Conventional imaging (CT, MRI, US, plain film) during surveillance reveals findings that are inconclusive or suspicious for recurrence, and PET avidity will determine whether biopsy or continued observation is appropriate Obvious clinical symptoms show strong evidence suggesting recurrent and PET would replace conventional imaging modalities 	<ul style="list-style-type: none"> PET/CT (CPT® 78815) <ul style="list-style-type: none"> Whole-body PET/CT (CPT® 78816) if there is clinical suspicion of skull or distal lower extremity involvement

Background and Supporting Information

- All soft tissue sarcomas other than RMS fall into this category
- Because soft tissue sarcomas can arise from any soft tissue, the presenting symptoms and primary tumor sites vary widely and strongly influence the appropriate imaging decisions
- CT Abdomen and Pelvis with contrast (CPT® 74177) is not routinely indicated in the initial metastatic staging of pediatric NRSTS
- Many individuals with NRSTS will be treated with surgical resection alone, and these individuals enter immediately into surveillance
- PET imaging is not routinely utilized to assess treatment response in NRSTS
- PET imaging is generally not indicated during active treatment for recurrent pediatric cancer.
- Residual mass that has not changed in size since the last conventional imaging does not justify PET
- PET avidity in a residual mass at the end of planned therapy is not an indication for PET imaging during surveillance

References (PEDONC-8)

v2.0.2024

1. Wexler LH, Skapek SX, Helman LJ. Rhabdomyosarcoma. In: Pizzo PA, Poplack DG, eds. Principles and Practice of Pediatric Oncology. 7th edition. Philadelphia, PA: Wolters Kluwer; 2016:798-826.
2. Spunt SL, Million L, and Coffin C. The Nonrhabdomyosarcoma soft tissue sarcomas. In: Pizzo PA, Poplack DG, eds. Principles and Practice of Pediatric Oncology. 7th edition. Philadelphia, PA: Wolters Kluwer; 2016:827-854.
3. Womer RB, Barr FG, Linardic CM. Rhabdomyosarcoma. In: Orkin SH, Fisher DE, Ginsburg D, Look AT, Lux SE, Nathan DG, eds. Nathan and Oski's Hematology and Oncology of Infancy and Childhood. 8th edition. Philadelphia, PA: Elsevier Saunders; 2015:1906-1945.
4. Davis IJ, Perez-Atayde AR, Fisher DE. Nonrhabdomyosarcoma soft tissue sarcomas and other soft tissue tumors. In: Orkin SH, Fisher DE, Ginsburg D, Look AT, Lux SE, Nathan DG, eds. Nathan and Oski's Hematology and Oncology of Infancy and Childhood. 8th edition. Philadelphia, PA: Elsevier Saunders; 2015:1946-1982.
5. McCarville MB. What MRI can tell us about neurogenic tumors and rhabdomyosarcoma. *Pediatr Radiol*. 2016;46(6):881-890. doi:10.1007/s00247-016-3572-4.
6. Federico SM, Spunt SL, Krasin MJ, et al. Comparison of PET-CT and Conventional Imaging in staging pediatric rhabdomyosarcoma. *Pediatr Blood Cancer*. 2013;60(7):1128-1134. doi:10.1002/pbc.24430.
7. Dharmarajan KV, Wexler LH, Gavane S, et al. Positron Emission Tomography (PET) evaluation after initial chemotherapy and radiation therapy predicts local control in rhabdomyosarcoma. *Int J Radiat Biol Oncol Phys*. 2012;84(4):996-1002. doi:10.1016/j.ijrobp.2012.01.077.
8. Arnold MA, Anderson JA, Gastier-Foster JM, et al. Histology, fusion status, and outcome in alveolar rhabdomyosarcoma with low-risk clinical features: a report from the Children's Oncology Group. *Pediatr Blood Cancer*. 2016;63(4):634-639. doi:10.1002/pbc.25862.
9. Völker T, Denecke T, Steffen I, et al. Positron Emission Tomography for staging of pediatric sarcoma patients: results of a prospective multicenter trial. *J Clin Oncol*. 2007; 25(34):5435-5441. doi:10.1200/JCO.2007.12.2473.
10. Ostermeier A, McCarville MB, Navid F, et al. FDG PET/CT imaging of desmoplastic small round cell tumor: findings at staging, during treatment and at follow-up. *Pediatr Radiol*. 2015;45(9):1308-1315. doi:10.1007/s00247-015-3315-y.
11. Uslu L, Doing J, Link M, Rosenberg J, Quon A, Daldrup-Link HE. Value of 18F-FDG PET and PET/CT for evaluation of pediatric malignancies. *J Nucl Med*. 2015;56(2):274-286. doi:10.2967/jnumed.114.146290.
12. Roberts CC, Kransdorf MJ, Beaman FD, et al. Follow-Up of malignant or aggressive musculoskeletal tumors. ACR Appropriateness Criteria® 2015:1-15. <https://acsearch.acr.org/docs/69428/Narrative/>.
13. Ferrari A, Chi Y-Y, De Salvo GL, et al. Surgery alone is sufficient therapy for children and adolescents with low-risk synovial sarcoma: a joint analysis from the European paediatric soft tissue sarcoma Study Group and the Children's Oncology Group. *Eur J Cancer*. 2017;78:1-6. doi:10.1016/j.ejca.2017.03.003.
14. Spunt SL, Million L, Chi YY, et al. A risk-based treatment strategy for non-rhabdomyosarcoma soft-tissue sarcomas in patients younger than 30 years (ARST0332): a Children's Oncology Group prospective study. *Lancet Oncol*. 2020;21(1):145-161. doi:10.1016/S1470-2045(19)30672-2.
15. Acord MR, Pace E, El-Ali A, et al. Imaging of pediatric extremity soft tissue tumors: A COG Diagnostic Imaging Committee/SPR Oncology Committee white paper. *Pediatr Blood Cancer*. 2022:e29944. doi:10.1002/pbc.29944.
16. Abramson ZR, Nagaraj UD, Lai LM, et al. Imaging of pediatric head and neck tumors: A COG Diagnostic Imaging Committee/SPR Oncology Committee/ASPNR white paper. *Pediatr Blood Cancer*. 2023;70 Suppl 4:e30151. doi:10.1002/pbc.30151.

Bone Tumors (PEDONC-9)

Guideline

Bone Tumors – General Considerations (PEDONC-9.1)

Benign Bone Tumors (PEDONC-9.2)

Osteogenic Sarcoma (OS) (PEDONC-9.3)

Ewing Sarcoma Family of Tumors (ESFT), Including Primitive Neuroectodermal Tumors (PNET) (PEDONC-9.4)

References (PEDONC-9)

Bone Tumors – General Considerations (PEDONC-9.1)

ONCP.BT.0009.1.A

v2.0.2024

These guidelines include both benign and malignant lesions.

- Unless specified below, individuals who are <18 years old should be imaged according to this guideline section. Exceptions include:
 - Osteogenic sarcoma individuals of all ages should be imaged according to guidelines in **Osteogenic Sarcoma (OS) (PEDONC-9.3)**
 - Ewing Sarcoma and Primitive Neuroectodermal Tumor individuals of all ages should be imaged according to guidelines in **Ewing Sarcoma and Primitive Neuroectodermal Tumors (ESFT) (PEDONC-9.4)**
 - Chondrosarcoma individuals of all ages should be imaged according to guidelines in **Bone Sarcomas – Initial Work-up/Staging (ONC-12.6)**
 - Chordoma individuals of all ages should be imaged according to guidelines in **Bone Sarcomas – Initial Work-up/Staging (ONC-12.6)**
 - Giant cell tumor of bone and enchondroma individuals of all ages should be imaged according to guidelines in **Benign Bone Tumors – General Considerations (ONC-12.9)**
 - Other benign bone tumor individuals of all ages should be imaged according to guidelines in **Benign Bone Tumors (PEDONC-9.2)**
- Prosthetic devices for children after surgery for bony tumors are nearly all customized.
 - CT, contrast as requested in alignment with prosthetic manufacturer specifications, is appropriate when requested by the operating surgeon for planning for customized-to-individual joint replacement or prosthetic surgery
- All bone tumors should be evaluated by plain x-ray prior to any advanced imaging
- PET does not reliably distinguish between benign and malignant bone tumors and should not be performed prior to biopsy.
- Where indications for PET/CT are noted, please note that indications and coding for rare circumstances where PET/MRI may be approved are found in **PET Imaging in Pediatric Oncology (PEDONC-1.4)**
- CT Chest is superior to PET/CT for the detection of pulmonary metastases, and is indicated in the initial workup of all suspected malignant bone tumors.
 - CT Chest should be completed prior to anesthesia exposure, if possible.

Benign Bone Tumors (PEDONC-9.2)

ONCP.BT.0009.2.A
v2.0.2024

- Osteochondroma

Indication	Imaging Study
Preoperative planning	<ul style="list-style-type: none"> MRI without and with contrast can be approved after evaluation by the operating surgeon See: General Considerations (PEDONC-9.1) for requests related to prosthetic planning
<ul style="list-style-type: none"> ANY of the following: <ul style="list-style-type: none"> Concern for malignant transformation New or worsening pain/symptoms Change on a recent plain x-ray 	<ul style="list-style-type: none"> MRI without contrast or without and with contrast

- Osteoid osteoma

Indication	Imaging Study
Suspected, based on clinical history and plain film findings	<ul style="list-style-type: none"> CT without contrast
<ul style="list-style-type: none"> ANY of the following: <ul style="list-style-type: none"> CTs are not characteristic for diagnosis Individual has bone pain not localized to the area of findings on CT or x-ray 	<ul style="list-style-type: none"> ONE of the following: <ul style="list-style-type: none"> Triple phase bone scan (CPT® 78315) SPECT (CPT® 78803) Hybrid SPECT/CT (CPT® 78830)
<ul style="list-style-type: none"> Individuals with new pain who have been previously treated with radiofrequency ablation or curettage 	<ul style="list-style-type: none"> Bone scan (CPT® code 78830, 78315, or 78803 – as requested)

- Other benign tumors
 - Refer to **Mass Involving Bone (Including suspected Lytic and Blastic Metastatic Disease) (PEDMS-3.4)**

Background and Supporting Information

- Plain x-ray appearance is diagnostic for many benign bone tumors, and advanced imaging is generally unnecessary except for preoperative planning
- Plain x-ray appearance is diagnostic for osteochondroma for the majority of individuals and advanced imaging is generally unnecessary

Osteogenic Sarcoma (OS) (PEDONC-9.3)

ONCP.BT.0009.3.A

v2.0.2024

Indication	Imaging Study
Suspected or Biopsy Proven Diagnosis	<ul style="list-style-type: none"> • MRI without and with contrast of the primary site OR • CT, contrast as request, of the primary site if there is a contraindication to MRI <p>AND</p> <ul style="list-style-type: none"> • CT Chest with (CPT® 71260) or without contrast (CPT® 71250) <ul style="list-style-type: none"> • CT Chest is indicated in initial workup of all suspected malignant bone tumors in children and should be completed prior to anesthesia exposure if possible • These studies may be approved even when PET/CT has already been authorized or performed
Initial Staging of Biopsy Proven Disease	<ul style="list-style-type: none"> • PET/CT whole-body (CPT® 78816) <ul style="list-style-type: none"> • Nuclear bone scan (see: (PEDONC-1.3) for coding) may be substituted if PET not available • PET/CT may be approved in addition to the conventional imaging listed in the suspected/diagnosis sections • CT Abdomen and Pelvis with contrast (CPT® 74177) is not routinely indicated in the initial metastatic staging of pediatric OS but can be approved in the following situations: <ul style="list-style-type: none"> • Evaluation of inconclusive PET findings • Primary site of abdomen or pelvis
Suspected bony metastatic sites noted on PET or bone scan	<ul style="list-style-type: none"> • MRI without and with contrast of the suspected metastatic site OR • CT with contrast of the suspected metastatic site
Restaging after 10 to 12 weeks of neoadjuvant chemotherapy prior to local control surgery	<ul style="list-style-type: none"> • MRI without and with contrast of primary site • CT Chest with (CPT® 71260) or without contrast (CPT® 71250) • PET/CT whole-body (CPT® 78816) or bone scan (see: (PEDONC-1.3) for coding)

Indication	Imaging Study
Individuals with metastatic disease undergoing current chemotherapy	<ul style="list-style-type: none"> • CT Chest with (CPT®) or without contrast (CPT® 71250) can be performed every 2 cycles during treatment and at the end of planned chemotherapy • MRI without and with contrast of primary site can be performed every 2 cycles during treatment and at the end of planned chemotherapy • If previously positive for bony metastases, PET/CT whole body (CPT® 78816) or bone scan (see: (PEDONC-1.3) for coding) every 2 cycles during treatment and at the end of planned chemotherapy • Imaging may be indicated more frequently around the time of surgical resection of primary or metastatic lesions to assess for resectability
Preoperative planning for local control surgery	<ul style="list-style-type: none"> • CT, contrast as requested • MRA and/or CTA may rarely be indicated for complicated surgical resections, and can be approved after evaluation by the operating surgeon to clarify inconclusive MRI findings for preoperative planning • See: General Considerations (PEDONC-9.1) for advancing imaging requests related to prosthetic planning
Following local control surgery, until the end of planned adjuvant chemotherapy	<ul style="list-style-type: none"> • MRI without and with contrast of primary site ~6 weeks after surgical procedure, and at the end of planned chemotherapy • Plain x-rays of the primary site and chest immediately after local control and then every 2 months between the supported, listed advanced imaging studies. • CT Chest with (CPT® 71260) or without contrast (CPT® 71250): <ul style="list-style-type: none"> • Measurable pulmonary metastases: every 6 weeks, and at the end of planned chemotherapy • No measurable pulmonary metastases: every 4 months, and at the end of planned chemotherapy • Bone scan (see: (PEDONC-1.3) for coding) every 4 months, and at the end of planned chemotherapy <ul style="list-style-type: none"> • PET/CT whole-body (CPT® 78816) can be used in place of bone scan, if positive for distant bone metastases at initial diagnosis

Indication	Imaging Study
<p>Recurrent metastatic or recurrent unresectable disease on treatment</p>	<ul style="list-style-type: none"> • The following may be approved every 2 cycles of treatment, and at the end of planned chemotherapy: <ul style="list-style-type: none"> • CT Chest with (CPT® 71260) or without contrast (CPT® 71250) • MRI without and with contrast of primary site can be performed every 2 cycles during treatment and at the end of planned chemotherapy • PET is generally not indicated during active treatment for recurrent pediatric cancer. In rare circumstances, PET/CT imaging with CPT® 78816 may be appropriate when results are likely to result in a treatment change for the patient, including a change from active treatment to surveillance.
<p>Surveillance (all individuals regardless of primary site)</p>	<ul style="list-style-type: none"> • Any or all of the following every 3 months for year 1 and 2, then every 4 months in year 3, then every 6 months in year 4 and 5 after completion of all therapy <ul style="list-style-type: none"> • CT or MRI of primary site as performed during suspected or initial disease workup (provided the individual does not have an endoprosthesis that will cause MRI or CT artifact): <ul style="list-style-type: none"> • CT Chest with (CPT® 71260) or without contrast (CPT® 71250) • Bone scan (see: (PEDONC-1.3) for coding) every 3 months for 1 year, then every 4 months for 1 year, then every 6 months for 1 year, then annually for 2 years after completion of all therapy

Indication	Imaging Study
<p>Suspected recurrence</p>	<ul style="list-style-type: none"> • MRI without and with contrast of the primary site and /or site of suspected recurrence based on symptoms or other imaging OR • CT, contrast as request, of the primary site and /or site of suspected recurrence based on symptoms or other imaging if there is a contraindication to MRI AND • CT Chest with (CPT® 71260) or without contrast (CPT® 71250) <ul style="list-style-type: none"> • CT Chest is indicated in initial workup of all suspected malignant bone tumors in children and should be completed prior to anesthesia exposure if possible • CT Abdomen and Pelvis with contrast (CPT® 74177) is not routinely indicated in the metastatic staging of pediatric OS, but can be approved in the following situations: <ul style="list-style-type: none"> • Evaluation of inconclusive PET findings • Primary site of abdomen or pelvis • These studies may be approved even when PET/CT has already been authorized or performed
<ul style="list-style-type: none"> • For suspected recurrence, ANY of the following: <ul style="list-style-type: none"> • Conventional imaging reveals findings that are inconclusive or suspicious for recurrence and PET avidity will determine whether biopsy or continued observation is appropriate • Rare circumstances where obvious clinical symptoms show strong evidence suggesting recurrence and PET would replace conventional imaging modalities 	<ul style="list-style-type: none"> • PET/CT <ul style="list-style-type: none"> • If PET is approved in osteosarcoma, it should be whole-body PET/CT (CPT® 78816)

Indication	Imaging Study
<ul style="list-style-type: none">Biopsy proven recurrence	<ul style="list-style-type: none">PET/CT whole-body (CPT[®] 78816) may be approved for biopsy proven recurrence<ul style="list-style-type: none">If disease is considered potentially resectable, follow osteosarcoma treatment response as previous

Ewing Sarcoma Family of Tumors (ESFT), Including Primitive Neuroectodermal Tumors (PNET) (PEDONC-9.4)

ONCP.BT.0009.4.A

v2.0.2024

Indication	Imaging Study
Suspected/Diagnosis – ill-defined or non-discrete soft tissue mass without bony involvement	<ul style="list-style-type: none"> • US (CPT® 76881 or 76882) in addition to plain x-ray
Suspected or Biopsy Proven Diagnosis – Primary site	<ul style="list-style-type: none"> • MRI without and with contrast <ul style="list-style-type: none"> • CT, contrast as requested, if there is a contraindication to MRI • MRA and/or CTA may rarely be indicated for complicated surgical resections, and can be approved after evaluation by the operating surgeon to clarify inconclusive MRI findings for preoperative planning • CT Chest with (CPT® 71260) or without contrast (CPT® 71250) <ul style="list-style-type: none"> • CT Chest is indicated in initial workup of all suspected or confirmed malignant bone tumors in children and should be completed prior to anesthesia exposure if possible • These studies may be approved even when PET/CT has already been authorized or performed
Suspected or Biopsy Proven Diagnosis – Chest wall primary	<ul style="list-style-type: none"> • MRI Chest without and with contrast AND • CT Chest with (CPT® 71260) or without contrast (CPT® 71250) <ul style="list-style-type: none"> • CT Chest is indicated in initial workup of all suspected or confirmed malignant bone tumors in children and should be completed prior to anesthesia exposure if possible • These studies may be approved even when PET/CT has already been authorized or performed

Indication	Imaging Study
<p>Initial Staging (additional imaging after biopsy confirmed disease)</p>	<ul style="list-style-type: none"> • PET/CT whole-body (CPT® 78816) <ul style="list-style-type: none"> • Bone scan (see: (PEDONC-1.3) for coding) may be substituted for PET imaging if PET not available • PET/CT may be approved in addition to the conventional imaging listed in the suspected/diagnosis sections
<ul style="list-style-type: none"> • For ANY of the following: <ul style="list-style-type: none"> • Evaluation of inconclusive PET findings • Primary site involving the abdomen or pelvis 	<ul style="list-style-type: none"> • CT Abdomen and Pelvis with contrast (CPT® 74177)
<p>Restaging after 10 to 12 weeks of neoadjuvant chemotherapy prior to local control surgery</p>	<p>Imaging modality should be the same as used for initial staging, any or all from the list below as described:</p> <ul style="list-style-type: none"> • MRI without and with contrast of the primary site • CT (contrast as requested) may be approved if requested per valuation by the operating surgeon for pre-operative planning <ul style="list-style-type: none"> • See: General Considerations (PEDONC-9.1) for imaging requests related to prosthetic planning • CT Chest with (CPT® 71260) or without contrast (CPT® 71250) • ONE of the following: <ul style="list-style-type: none"> • PET/CT whole-body (CPT® 78816) • Whole-body bone scan (see: PEDONC-1.3 for coding) • MRI bone marrow blood supply/diffusion-weighted MRI with ADC (CPT® 77084)

Indication	Imaging Study
<p>Treatment response following local control surgery</p>	<ul style="list-style-type: none"> • MRI without and with contrast of primary site 3 months after surgical procedure and at the end of planned chemotherapy • Plain x-rays of the primary site and chest immediately after local control then every 3 months • CT Chest with (CPT® 71260) or without contrast (CPT® 71250): <ul style="list-style-type: none"> • Measurable pulmonary metastases: every 6 weeks and at the end of planned chemotherapy • No measurable pulmonary metastases: every 3 months and at the end of planned chemotherapy • Whole-body bone scan (see: PEDONC-1.3 for coding) at the end of planned chemotherapy • PET/CT whole-body (CPT® 78816) is supported for clinical or imaging findings suggestive of local recurrence
<p>Individuals with metastatic disease undergoing current chemotherapy</p>	<ul style="list-style-type: none"> • CT Chest with (CPT® 71260) or without contrast (CPT® 71250) can be performed every 2 cycles during treatment and at the end of planned chemotherapy • MRI without and with contrast of primary site can be performed every 2 cycles during treatment and at the end of planned chemotherapy • If previously positive for bony metastases, PET/CT whole-body (CPT® 78816) or bone scan (see: (PEDONC-1.3) for coding) every 2 cycles during treatment and at the end of planned chemotherapy • Imaging may be indicated more frequently around the time of surgical resection of primary or metastatic lesions to assess for resectability

Indication	Imaging Study
<p>Recurrent metastatic or recurrent unresectable disease on treatment</p>	<ul style="list-style-type: none"> • The following may be approved every 2 cycles of treatment, and at the end of planned chemotherapy: <ul style="list-style-type: none"> • CT Chest with (CPT® 71260) or without contrast (CPT® 71250) • MRI without and with contrast of primary site can be performed every 2 cycles during treatment and at the end of planned chemotherapy • PET is generally not indicated during active treatment for recurrent pediatric cancer. In rare circumstances, PET imaging may be appropriate when results are likely to result in a treatment change for the individual, including a change from active treatment to surveillance.
<p>Surveillance for all disease other than low grade, stage I disease</p>	<ul style="list-style-type: none"> • Every 3 months for year 1 and 2, then every 4 months in year 3, then every 6 months in year 4 and 5, and annually for 5 years after completion of all therapy to complete 10 years of surveillance: <ul style="list-style-type: none"> • CT or MRI of primary site as performed during suspected or initial disease workup (provided the individual does not have an endoprosthesis that will cause MRI or CT artifact): • Bone scan (see: (PEDONC-1.3) for coding) • Every 3 months for year 1 and 2, then every 4 months in year 3, then every 6 months in year 4 and 5: <ul style="list-style-type: none"> • CT Chest with (CPT® 71260) or without contrast (CPT® 71250) • After year 5, CXR should be used for surveillance

Indication	Imaging Study
<p>Surveillance for low grade stage I disease only</p>	<ul style="list-style-type: none"> • Every 3 months for year 1 and 2, then every 4 months in year 3, then every 6 months in year 4 and 5, and annually for 5 years after completion of all therapy to complete 10 years of surveillance: <ul style="list-style-type: none"> • CT or MRI of primary site as performed during suspected or initial disease workup (provided the individual does not have an endoprosthesis that will cause MRI or CT artifact) • Bone scan (see: PEDONC-1.3 for coding) • Every 3 months for year 1 and 2 <ul style="list-style-type: none"> • CT Chest with (CPT® 71260) or without contrast (CPT® 71250) • After 24 months off therapy, CXR should be used for surveillance with CT supported for new or inconclusive findings on CXR
<p>Suspected Recurrence</p>	<ul style="list-style-type: none"> • MRI without and with contrast of the primary site and/or site of suspected recurrence based on symptoms or other imaging, OR • CT, contrast as request, of the primary site and/or site of suspected recurrence based on symptoms or other imaging if there is a contraindication to MRI AND • CT Chest with (CPT® 71260) or without contrast (CPT® 71250) <ul style="list-style-type: none"> • CT Chest is indicated in initial workup of all suspected malignant bone tumors in children and should be completed prior to anesthesia exposure if possible • CT Abdomen and Pelvis with contrast (CPT® 74177) is not routinely indicated in the metastatic staging of pediatric EWS but can be approved in the following situations: <ul style="list-style-type: none"> • Evaluation of inconclusive PET findings • Primary site of abdomen or pelvis • These studies may be approved even when PET/CT has already been authorized or performed

Indication	Imaging Study
<ul style="list-style-type: none"> • For suspected recurrence, any of the following: <ul style="list-style-type: none"> • Conventional imaging reveals findings that are inconclusive or suspicious for recurrence and PET avidity will determine whether biopsy or continued observation is appropriate • Rare circumstances where obvious clinical symptoms show strong evidence suggesting recurrence and PET would replace conventional imaging modalities 	PET/CT whole-body (CPT® 78816)
<ul style="list-style-type: none"> • Biopsy proven recurrence 	<ul style="list-style-type: none"> • Refer to ESFT initial imaging for studies for suspected recurrence. • PET/CT whole-body (CPT® 78816) • If disease is considered potentially resectable, follow ESFT treatment response as previously noted

Background and Supporting Information

- Bone and bone marrow metastases can occur in ESFT, and cause a significant change in treatment approach.
- PET/CT can replace bone scan and bone marrow biopsy in ESFT individuals and is indicated in the initial staging of all ESFT individuals after histologic diagnosis is established

References (PEDONC-9)

v2.0.2024

1. Hawkins DS, Brennan BMD, Bölling T, et al. Ewing Sarcoma. In: Pizzo PA, Poplack DG, eds. Principles and Practice of Pediatric Oncology. 7th edition. Philadelphia, PA: Wolters Kluwer; 2016:855-876.
2. Gorlick R, Janeway K, and Marina N. Osteosarcoma. In: Pizzo PA, Poplack DG, eds. Principles and Practice of Pediatric Oncology. 7th edition. Philadelphia, PA: Wolters Kluwer; 2016:877-898.
3. DuBois SG, Grier HE, and Lessnick SL. Ewing Sarcoma. In: Orkin SH, Fisher DE, Ginsburg D, Look AT, Lux SE, Nathan DG, eds. Nathan and Oski's Hematology and Oncology of Infancy and Childhood. 8th edition. Philadelphia, PA: Elsevier Saunders; 2015:1983-2017.
4. Janeway KA. Osteosarcoma. In: Orkin SH, Fisher DE, Ginsburg D, Look AT, Lux SE, Nathan DG, eds. Nathan and Oski's Hematology and Oncology of Infancy and Childhood. 8th edition. Philadelphia, PA: Elsevier Saunders; 2015:2018-2055.
5. Azouz EM. Magnetic resonance imaging of benign bone lesions: cysts and tumors. *Top Magn Reson Imaging*. 2002 August;13(4):219-230.
6. Wolf M. Knee pain in children, part III: stress injuries, benign bone tumors, growing pains. *Pediatr Rev*. 2016;37(3):114-119. doi:10.1542/pir.2015-0042.
7. Uslu L, Doing J, Link M, Rosenberg J, Quon A, Daldrup-Link HE. Value of 18F-FDG PET and PET/CT for Evaluation of Pediatric Malignancies. *J Nucl Med*. 2015;56(2):274-286. doi:10.2967/jnumed.114.146290.
8. Reed DR, Hayashi M, Wagner L, et al. Treatment pathway of bone sarcoma in children, adolescents, and young adults. *Cancer*. 2017 March;123(12):2206-2218.
9. Hurley C, McCarville MB, Shulkin BL, et al. Comparison of 18F-FDG-PET-CT and Bone Scintigraphy for evaluation of osseous metastases in newly diagnosed and recurrent osteosarcoma. *Pediatr Blood Cancer*. 2016;63(8):1381-1386. Accessed January 4, 2018. doi:10.1002/pbc.26014.
10. Byun BH, Kong CB, Lim I, et al. Comparison of (18)F-FDG PET/CT and (99m)TC-MDP bone scintigraphy for detection of bone metastasis in osteosarcoma. *Skeletal Radiol*. 2013;42(12):1673-1681.
11. Quartuccio N, Treglia G, Saisano M, et al. The role of Fluorine-18-Fluorodeoxyglucose positron emission tomography in staging and restaging of patients with osteosarcoma. *Radiol Oncol*. 2013;47(2):97-102. doi:10.2478/raon-2013-0017.
12. Isakoff MS, Bielack SS, Meltzer P, Gorlick R. Osteosarcoma: current treatment and a collaborative pathway to success. *J Clin Oncol*. 2015;33(27):3029-3035. doi:10.1200/JCO.2014.59.4895.
13. Newman EN, Jones RL, Hawkins DS. An evaluation of [F-18]-Fluorodeoxy-D-Glucose positron emission tomography, bone scan, and bone marrow aspiration/biopsy as staging investigations in Ewing sarcoma. *Pediatr Blood Cancer*. 2013;60(7):1113-1117. doi:10.1002/pbc.24406.
14. Roberts CC, Kransdorf MJ, Beaman FD, et al. Follow-up of malignant or aggressive musculoskeletal tumors. ACR Appropriateness Criteria® 2015:1-15. <https://acsearch.acr.org/docs/69428/Narrative/>.
15. Meyer JS, Nadel HR, Marina N, et al. Imaging guidelines for children with Ewing sarcoma and osteosarcoma: a report from the Children's Oncology Group Bone Tumor Committee. *Pediatr Blood Cancer*. 2008;51(2):163-170. doi:10.1002/pbc.21596.
16. Gaspar N, Hawkins DS, Dirksen U, et al. Ewing sarcoma: current management and future approaches through collaboration. *J Clin Oncol*. 2015;33(27):3036-3046. doi:10.1200/JCO.2014.59.5256.
17. Mascarenhas L, Felgenhauer JL, Bond MC, et al. Pilot study of adding vincristine, topotecan, and cyclophosphamide to interval-compressed chemotherapy in newly diagnosed patients with localized Ewing sarcoma: a report from the Children's Oncology Group. *Pediatr Blood Cancer*. 2016;63(3):493-498. doi:10.1002/pbc.25837.
18. Weiser DA, Kaste SC, Siegel MJ, et al. Imaging in childhood cancer: a society for pediatric radiology and children's oncology group joint task force report. *Pediatr Blood Cancer*. 2013;60(8):1253-1260. doi:10.1002/pbc.24533.
19. Dimitrakopoulou-Strauss A, Strauss LG, Heichel T, et al. The role of quantitative 18F-FDG PET studies for the differentiation of malignant and benign bone lesions. *J Nucl Med*. 2002;43(4):510-518.
20. Bestic JM, Wessell DE, Beaman FD, et al. Primary bone tumors. ACR Appropriateness Criteria®, 2019;1-13. Date of origin: 1995 Last review date: 2019 <https://acsearch.acr.org/docs/69421/Narrative/>.
21. Biermann JS, Chow W, Adkins DR, et al. National Comprehensive Cancer Network (NCCN) Guidelines Version 1.2023 – April 4, 2023. Bone cancer, available at: https://www.nccn.org/professionals/physician_gls/pdf/bone.pdf. Referenced with permission from the NCCN Clinical Practice Guidelines in Oncology (NCCN Guidelines™) for Bone Cancer V1.2023– 4/4/2023. ©2023 National Comprehensive Cancer Network, Inc. All rights reserved. The NCCN Guidelines™ and illustrations herein may not be reproduced in any form for any purpose without the express written permission of the NCCN. To view the most recent and complete version of the NCCN Guidelines™, go online to NCCN.org.

22. Jeys L, Abudu A, Grimer R. Expandable prostheses. In: Wiesel SW, ed. *Operative Techniques in Orthopaedic Surgical Oncology*. Philadelphia, PA: Lippincott Williams & Wilkins; 2015:1-9.
23. PDQ® Pediatric Treatment Editorial Board. PDQ Osteosarcoma and Malignant Fibrous Histiocytoma of Bone Treatment. Bethesda, MD: National Cancer Institute. Updated 1/29/2021. Available at: <https://www.cancer.gov/types/bone/hp/osteosarcoma-treatment-pdq>. Accessed 03/01/2021. [PMID: 26389179].
24. Demertzis JL, Wessell DE, Lenchik L, et. al. ACR Appropriateness Criteria® malignant or aggressive primary musculoskeletal tumor-staging and surveillance: 2022 update. *J Am Coll Radiol*. 2022;19(11S):S374-S389. doi:10.1016/j.jacr.2022.09.015.
25. Cederberg KB, Iyer RS, Chaturvedi A, et. al. Imaging of pediatric bone tumors: A COG Diagnostic Imaging Committee/SPR Oncology Committee white paper. *Pediatr Blood Cancer*. 2023;70 Suppl 4:e30000. doi:10.1002/pbc.30000.

Pediatric Germ Cell Tumors (PEDONC-10)

Guideline

Pediatric Germ Cell Tumors (PEDONC-10)

References (PEDONC-10)

Pediatric Germ Cell Tumors (PEDONC-10)

ONCP.GC.0010.A
v2.0.2024

Indication	Imaging Study
Initial staging	<ul style="list-style-type: none"> CT Abdomen/Pelvis with contrast (CPT® 74177) <ul style="list-style-type: none"> Testicular primary tumors can defer abdominal imaging until after histologic confirmation at the discretion of the operating surgeon MRI Abdomen and Pelvis without and with contrast (CPT® 74183 and CPT® 72197) is indicated in lieu of CT Abdomen/Pelvis with contrast when a proven or highly suspected ovarian neoplasm was already imaged with ultrasound, or for initial imaging of immature sacrococcygeal teratoma suspected on other imaging CT Chest with contrast (CPT® 71260) <ul style="list-style-type: none"> Should be completed prior to anesthesia exposure if possible
<ul style="list-style-type: none"> Ovarian masses that are <10 cm in size, have minimal or no visible solid component on ultrasound, and have normal tumor markers <ul style="list-style-type: none"> These are almost universally benign teratomas or functional cysts 	<ul style="list-style-type: none"> Advanced imaging is not indicated
Clarify inconclusive initial staging CT findings or for a known contraindication to CT contrast	<ul style="list-style-type: none"> MRI Abdomen and Pelvis without and with contrast (CPT® 74183 and CPT® 72197)

Indication	Imaging Study
<ul style="list-style-type: none"> • Additional initial evaluation for individuals with ANY of the following: <ul style="list-style-type: none"> • Symptoms suggesting CNS metastases • Choriocarcinoma syndrome (hemorrhagic metastatic disease to lung with extremely elevated HCG) HCG >10,000miU/ml 	<ul style="list-style-type: none"> • MRI Brain without and with contrast (CPT® 70553)
<p>Additional initial evaluation for individuals with systemic symptoms or bone pain</p>	<ul style="list-style-type: none"> • Nuclear bone scan (See: PEDONC-1.3 for coding)
<p>Restaging in individuals with disease not completely resected at initial diagnosis</p>	<ul style="list-style-type: none"> • Every 2 cycles (~every 6 weeks) and at the end of planned therapy: <ul style="list-style-type: none"> • CT Chest/Abdomen/Pelvis (CPT® 71260 and CPT® 74177) with contrast <ul style="list-style-type: none"> • CT imaging may be indicated more frequently to assess for surgical resectability in individuals who have received more than 4 cycles of chemotherapy • MRI Abdomen and Pelvis without and with contrast (CPT® 74183 and CPT® 72197) may be approved in lieu of CT abdomen and pelvis for ovarian neoplasms if this modality was used for initial staging • Imaging of any metastatic sites with the same modality used during initial staging
<ul style="list-style-type: none"> • Suspicious lesion seen on CT and both of the following: <ul style="list-style-type: none"> • Relapse risk is determined to be low by the treating physician • Biopsy would cause unnecessary morbidity for the individual 	<ul style="list-style-type: none"> • Short-interval CT study of the involved area can be approved

Indication	Imaging Study
<p>Stage I individuals age 0-10 years treated with surgery only</p>	<ul style="list-style-type: none"> • Chest x-ray should be completed every 3 months for 1 year, then every 6 months in year two, to complete two years surveillance after completion of all therapy • For those with primary mediastinal tumors at diagnosis, CT Chest with contrast (CPT® 71260) should be approved in lieu of CXR according to the above schedule. • Every 3 months for 1 year, then every 6 months in year two, to complete two years surveillance after completion of all therapy: <ul style="list-style-type: none"> • CT Abdomen/Pelvis with contrast (CPT® 74177) • MRI Abdomen and Pelvis without and with contrast (CPT® 74183 and CPT® 72197) may be substituted for surveillance for ovarian neoplasm if this modality was used for initial staging
<p>Stage I individuals ages 11+ years treated with surgery only</p>	<ul style="list-style-type: none"> • Every 4 months for 2 years, then every 6 months for 1 year, then every 12 months for 2 years to complete 5 years surveillance imaging after completion of all therapy: <ul style="list-style-type: none"> • Chest x-ray • For individuals with primary mediastinal tumors at diagnosis, CT Chest with contrast (CPT® 71260) should be approved in lieu of chest x-ray on the above schedule. • Every 4 months for 2 years, then every 6 months for 1 year, then every 12 months for two years to complete 5 years surveillance <ul style="list-style-type: none"> • CT Abdomen and Pelvis with contrast (CPT® 74177) • MRI Abdomen and Pelvis without and with contrast (CPT® 74183 and CPT® 72197) may be substituted for surveillance for ovarian neoplasm if this modality was used for initial staging

Indication	Imaging Study
<p>Stage II-IV individuals</p>	<ul style="list-style-type: none"> • Chest x-ray should be completed every 3 months for 1 year, then every 6 months in year 2, then annually in years 3-5 after completion of all therapy. • For individuals with primary mediastinal tumors at diagnosis, CT Chest with contrast (CPT® 71260) should be approved in lieu of chest x-ray on the above schedule. • CT Abdomen and Pelvis with contrast (CPT® 74177) every 3 months for 1 year then every 6 months in year 2, then annually in years 3-5 year after completion of all therapy. • MRI Abdomen and Pelvis without and with contrast (CPT® 74183 and CPT® 72197) may be substituted for surveillance for ovarian neoplasm if this modality was used for initial staging • Individuals with brain or bone metastases should have surveillance imaging of those areas on the same schedule as the primary site imaging with the same modality used during initial staging
<ul style="list-style-type: none"> • Suspected Recurrence: <ul style="list-style-type: none"> • Any clinically significant rise in tumor markers • Symptoms suggesting recurrent disease • Abnormal chest x-ray 	<ul style="list-style-type: none"> • CT Chest with contrast (CPT® 71260) and CT Abdomen and Pelvis with contrast (CPT® 74177) • MRI Abdomen and Pelvis without and with contrast (CPT® 74183 and CPT® 72197) may be approved in lieu of CT for suspected recurrence of immature sacrococcygeal tumor or ovarian neoplasm • Whole-body bone scan (CPT® 78306) for individuals with a history of bone involvement or with bone pain

Background and Supporting Information

General Considerations:

- Malignant pediatric germ cell tumors commonly include one of four histologic subtypes:
 - Yolk sac tumor
 - Choriocarcinoma
 - Embryonal carcinoma
 - Mixed histology (including immature sacrococcygeal teratoma)
- Tumors can occur in testicular, ovarian or extragonadal primary locations
- Sex cord stromal tumors (granulosa cell, theca, sertoli, and leydig tumors) are rare in pediatrics and should be imaged according to general guidelines in: **Testicular, Ovarian and Extragonadal Germ Cell Tumors (ONC-20)** in the Oncology Imaging Guidelines
- This section applies to primary germ cell tumors occurring outside the central nervous system in children who are ≤ 15 years old at the time of initial diagnosis.
 - For individuals who are > 15 years old at diagnosis, the overall prognosis is inferior and these individuals should be imaged according to general guidelines in: **Testicular, Ovarian and Extragonadal Germ Cell Tumors (ONC-20)** in the Oncology Imaging Guidelines.
- For CNS germ cell tumors, use the imaging guidelines in: **CNS Germinomas and Non-Germinomatous Germ Cell Tumors (NGGCT) (PEDONC-4.7)**.

Treatment Considerations:

- Overall treatment strategies are similar for all malignant germ cell tumors.
- Individuals with localized GCT are often cured with surgery alone and do not receive adjuvant therapy.
 - These individuals should be imaged using surveillance guidelines after surgery is completed.
- Individuals receiving adjuvant chemotherapy are usually treated with 4 to 6 cycles of combination chemotherapy.

Imaging Modality Considerations:

- Initial evaluation of: Ovarian, testicular, and abdominal extragonadal suspected GCT should be completed by ultrasound and tumor markers (AFP, β -hCG)
 - Once a primary mass suspected to be GCT is discovered, initial staging is indicated prior to histologic confirmation

- The degree of abdominal exploration and node sampling necessary for adequate staging is determined in part by imaging findings and is required for preoperative planning
- The primary method of response assessment is by tumor marker decrease
- The primary method of surveillance in pediatric GCT is frequent assessment of serum tumor markers, unless tumor markers were not elevated at diagnosis
- Surveillance imaging of the chest in disease stages I-IV should generally be performed using chest x-ray
 - See surveillance indications for specific imaging recommendations
- There has been no published evidence to date supporting the routine use of PET/CT in the evaluation of pediatric GCT
 - Additionally, PET has been found to have similar efficacy to CT imaging in initial staging of adults with non-seminomatous GCT (the majority of pediatric GCT are non-seminomatous)
- PET as a marker of treatment response has been shown not to be predictive of individual outcomes in GCT and should not be approved
 - Suspicious lesions seen on conventional imaging should be biopsied to confirm active disease

References (PEDONC-10)

v2.0.2024

1. Frazier AL, Olson TA, Schneider DT, et al. Germ cell tumors. In: Pizzo PA, Poplack DG, eds. Principles and Practice of Pediatric Oncology. 7th edition. Philadelphia, PA: Wolters Kluwer; 2016:899-918.
2. Frazier AL, Billmire D, Amatruda J. Pediatric germ cell tumors. In: Orkin SH, Fisher DE, Ginsburg D, Look AT, Lux SE, Nathan DG, eds. Nathan and Oski's Hematology and Oncology of Infancy and Childhood. 8th edition. Philadelphia, PA: Elsevier Saunders; 2015:2056-2099.
3. Gilligan T, Lin DW, Aggarwal R, et al. National Comprehensive Cancer Network (NCCN) Guidelines Version 1.2023—January 26, 2023, Testicular Cancer, available at: https://www.nccn.org/professionals/physician_gls/pdf/testicular.pdf, Referenced with permission from the NCCN Clinical Practice Guidelines in Oncology (NCCN Guidelines™) for Testicular Cancer V1.2023 6/02/2023. ©2023 National Comprehensive Cancer Network, Inc. All rights reserved. The NCCN Guidelines™ and illustrations herein may not be reproduced in any form for any purpose without the express written permission of the NCCN. To view the most recent and complete version of the NCCN Guidelines™, go online to NCCN.org
4. Armstrong DK, Plaxe SC, Alvarez RD, et al. National Comprehensive Cancer Network (NCCN) Guidelines Version 2.2023—June 2, 2023 Ovarian Cancer, available at: https://www.nccn.org/professionals/physician_gls/pdf/ovarian.pdf, Referenced with permission from the NCCN Clinical Practice Guidelines in Oncology (NCCN Guidelines™) for Ovarian Cancer V2.2023 6/2/2023. ©2023 National Comprehensive Cancer Network, Inc. All rights reserved. The NCCN Guidelines™ and illustrations herein may not be reproduced in any form for any purpose without the express written permission of the NCCN. To view the most recent and complete version of the NCCN Guidelines™, go online to NCCN.org.
5. de Wit M, Brenner W, Hartmann M, et al. [18F]-FDG-PET in clinical stage I/II non-seminomatous germ cell tumors: results of the German multicentre trial. *Ann Oncol.* 2008;19(9):1619-1623. doi:10.1093/annonc/mdn170.
6. Huddart RA, O'Doherty MJ, Padhani A, et al. 18Fluorodeoxyglucose positron emission tomography in the prediction of relapse in patients with high-risk, clinical stage I nonseminomatous germ cell tumors: preliminary report of MRC trial TE22--the NCRI testis tumor clinical study group. *J Clin Oncol.* 2007;25(21):3090-3095. doi:10.1200/JCO.2006.09.3831.
7. Papis JC, Finnell MA, Slaven JE, et al. Predictors of ovarian malignancy in children: overcoming clinical barriers of ovarian preservation. *J Pediatr Surg.* 2014;49(1):144-148. doi:10.1016/j.jpedsurg.2013.09.068.
8. Olson TA, Murray MJ, Rodriguez-Galindo C, et al. Pediatric and adolescent extracranial germ cell tumors: the road to collaboration. *J Clin Oncol.* 2015;33(27):3018-3028. doi:10.1200/JCO.2014.60.5337.
9. Fresneau B, Orbach D, Faure-Contier C, et al. Sex-cord stromal tumors in children and teenagers: results of the TGM-95 study. *Pediatr Blood Cancer.* 2015;62(12):2114-2119. doi:10.1002/pbc.25614.
10. Fonseca A, Xia C, Lorenzo AJ et al, Detection of Relapse by Tumor Markers Versus Imaging in Children and Adolescents With Nongerminomatous Malignant Germ Cell Tumors: A Report From the Children's Oncology Group. *J Clin Oncol.* 2019;37:396-402. doi:10.1200/JCO.18.00790.
11. Behr GG, Morani AC, Artunduaga M, et. al. Imaging of pediatric ovarian tumors: A COG Diagnostic Imaging Committee/SPR Oncology Committee white paper. *Pediatr Blood Cancer.* 2022:e29995. doi:10.1002/pbc.29995.
12. Behr GG, Morani AC, Artunduaga M, et. al. Imaging of pediatric testicular tumors: A COG Diagnostic Imaging Committee/SPR Oncology Committee white paper. *Pediatr Blood Cancer.* 2022:e29988. doi:10.1002/pbc.29988.
13. Keenan C, Ramirez N, Elijevich L, et. al. A rare manifestation of choriocarcinoma syndrome in a child with primary intracranial germ cell tumor and extracranial metastases: A case report and review of the literature. *Pediatr Blood Cancer.* 2021;68(6):e29000. doi:10.1002/pbc.29000.
14. Pace E, Johnson TS, Kao SC, et. al. Imaging of pediatric extragonadal pelvic soft tissue tumors: A COG Diagnostic Imaging Committee/SPR Oncology Committee white paper. *Pediatr Blood Cancer.* 2023;70 Suppl 4:e29966. doi:10.1002/pbc.29966.

Pediatric Liver and Pancreatic Tumors (PEDONC-11)

Guideline

- Pediatric Liver Tumors – General Considerations (PEDONC-11.1)
- Hepatoblastoma (PEDONC-11.2)
- Pediatric Hepatocellular Carcinoma (HCC) (PEDONC-11.3)
- Pediatric Pancreatic Carcinoma (PEDONC-11.4)
- References (PEDONC-11)

Pediatric Liver Tumors – General Considerations (PEDONC-11.1)

ONCP.LT.0011.1.U
v2.0.2024

- Primary hepatic germ cell tumors should follow imaging guidelines in: **Pediatric Germ Cell Tumors (PEDONC-10)**.
- Primary hepatic sarcomas should follow imaging guidelines in: **Non-Rhabdomyosarcoma Soft Tissue Sarcomas (NRSTS) (PEDONC-8.3)**.
- Imaging requests relating to liver transplant surgery and surveillance should follow guidelines in section **Transplant (AB-42)** in the Abdomen Imaging Guidelines.

Hepatoblastoma (PEDONC-11.2)

ONCP.LT.0011.2.A
v2.0.2024

Hepatoblastoma Initial Staging:

- Ultrasound may be approved even after MRI or CT imaging in order to allow evaluation for tumor thrombus
- Once a primary liver mass is discovered, definitive imaging is indicated prior to histologic diagnosis, and may involve ANY of the following:
 - MRI Abdomen and Pelvis without and with contrast (CPT® 74183 and CPT® 72197) is preferred for evaluating tumor margins and vascular anatomy
 - Hepatobiliary-specific contrast agents (gadoxetate, gadobenate [MultiHance]) are preferred if available and should be approved if requested, whether or not a prior gadolinium-enhanced MRI has been previously performed
 - CT Abdomen and Pelvis with (CPT® 74177) is inferior to MRI for pediatric liver malignancies and should only be approved if MRI is not available, contraindicated, or sedation is required but not available, or to clarify specific inconclusive areas on MRI.
 - Noncontrast imaging is not indicated due to the increased radiation exposure and limited additive benefit
 - MRA Abdomen (CPT® 74185) or CTA Abdomen (CPT® 74175) to evaluate vascular invasion
- CT Chest with (CPT® 71260) **or** CT Chest without contrast (CPT® 71250) is indicated in the initial work-up of all pediatric liver tumors and should be completed prior to anesthesia exposure if possible
- Bone scan (See: **Modality General Considerations (PEDONC-1.3)**) for initial evaluation of bony metastases only with systemic symptoms or bone pain.
- MRI Brain without and with contrast (CPT® 70553) only for symptoms suggesting CNS metastases
- PET/CT only in very rare circumstances for preoperative planning when MRI and CT scans are insufficient for surgical decision-making.
 - Indications and coding for rare circumstances where PET/MRI may be approved are found in **PET Imaging in Pediatric Oncology (PEDONC-1.4)**

Hepatoblastoma Treatment Response:

- CT Chest with (CPT® 71260) **or** without contrast (CPT® 71250) every 2 cycles **and** at the end of planned therapy for individuals with incomplete resection at initial diagnosis
- MRI Abdomen and Pelvis without and with contrast (CPT® 74183 and CPT® 72197) every 2 cycles **and** at the end of planned therapy for individuals with incomplete resection at initial diagnosis

- CT Abdomen and Pelvis with contrast (CPT® 74177) or CT Abdomen and Pelvis with and without contrast (CPT® 74178) is inferior to MRI for pediatric liver malignancies and should only be approved if MRI is not available, contraindicated, or sedation is required but not available, or to clarify specific inconclusive areas on MRI.
 - Noncontrast imaging is not indicated due to the increased radiation exposure and limited additive benefit
- While the majority of individuals will require abdomen and pelvis imaging at all time points, the pelvis imaging may be omitted at the discretion of the ordering physician
- MRA Abdomen (CPT® 74185) or CTA Abdomen (CPT® 74175) to evaluate vascular invasion
- Imaging of any metastatic sites with the same modality used during initial staging every 2 cycles and at the end of planned therapy for individuals with incomplete resection at initial diagnosis
- Imaging more frequently to assess for surgical resectability in individuals who have received more than 4 cycles of chemotherapy.
- Abdominal ultrasound is indicated if tumor thrombus was detected at initial diagnosis
 - If no tumor thrombus was present, continued ultrasound evaluations are not indicated without a specific reason documented in the clinical records
- PET/CT should only be considered in very rare circumstances for preoperative planning when MRI and CT scans are insufficient for surgical decision making.

Hepatoblastoma Surveillance Imaging:

- For surveillance in individuals with an AFP of >100 ng/ml
 - CT Chest with contrast (CPT® 71260) and MRI Abdomen with and without contrast (CPT® 74183) for any clinically significant rise in tumor markers or symptoms suggesting recurrent disease
 - CT Abdomen and Pelvis with contrast (CPT® 74177) is inferior to MRI for pediatric liver malignancies and should only be approved if MRI is not available, contraindicated, or sedation is required but not available, or to clarify specific inconclusive areas on MRI.
 - Noncontrast imaging is not indicated due to the increased radiation exposure and limited additive benefit
- For individuals with AFP ≤100 ng/ml at diagnosis or recurrence, the following imaging is appropriate:
 - MRI Abdomen with and without contrast (CPT® 74183) every 3 months for 2 years, then every 4 months for 2 years after completion of all therapy
 - Chest x-ray or CT Chest with contrast (CPT® 71260) every 3 months for 2 years, then every 4 months for 2 years after completion of all therapy
 - Individuals with brain or bone metastases should have surveillance imaging on the same schedule as the primary site imaging with the same modality used during initial staging

Background and Supporting Information

- Pediatric liver tumors primarily include hepatoblastoma and hepatocellular carcinoma, but hepatic germ cell tumors and primary hepatic sarcomas occur with some frequency. Tumor markers are useful for initial evaluation as well as treatment response, particularly in hepatoblastoma. Early consideration of liver transplant may be undertaken in children and adolescents with unresectable localized disease, provided that the disease remains confined to the liver.
- Hepatoblastoma occurs most commonly in very young children (median diagnosis age of 19 months). Most cases of hepatoblastoma are sporadic, but some are associated with genetic abnormalities, including Beckwith-Wiedemann syndrome, familial adenomatous polyposis, and trisomy 18. Most suspected liver tumors will have ultrasound and tumor markers (AFP, β -HCG, CEA) as part of the initial evaluation.
- There has been no published evidence to date supporting the routine use of PET/CT imaging in the evaluation of pediatric Hepatoblastoma during initial imaging, treatment response, or surveillance.
- PET/CT should not be approved in lieu of biopsy of suspicious lesions
- Individuals with localized hepatoblastoma of pure fetal histology are often cured with surgery alone and do not receive adjuvant therapy. These individuals should be imaged using surveillance guidelines after surgery is completed.
- Individuals receiving adjuvant chemotherapy are usually treated with 2 to 8 cycles of combination chemotherapy. Tumor marker decrease is important in response assessment but does not eliminate the need for advanced imaging in individuals with unresected hepatoblastoma.
- The primary method of surveillance in hepatoblastoma is frequent assessment of serum tumor markers (primarily AFP).
- No specific imaging for surveillance in individuals with an AFP of >100 ng/mL at diagnosis or recurrence.

Pediatric Hepatocellular Carcinoma (HCC) (PEDONC-11.3)

ONCP.LT.0011.3.A

v2.0.2024

Pediatric HCC Initial Staging:

- Ultrasound may be approved even after MRI or CT imaging in order to allow evaluation for tumor thrombus
- Once a primary liver mass is discovered, definitive imaging prior to histologic diagnosis including ANY of the following:
 - MRI Abdomen and Pelvis without and with contrast (CPT® 74183 and CPT® 72197)
 - Hepatobiliary specific contrast agents (gadoxetate, gadobenate [MultiHance]) are preferred if available and should be approved if requested, whether or not a prior gadolinium-enhanced MRI has been previously performed
 - CT Abdomen and Pelvis with contrast (CPT® 74177) is inferior to MRI for pediatric liver malignancies and should only be approved if MRI is not available, contraindicated, or sedation is required but not available, or to clarify specific inconclusive areas on MRI.
 - Noncontrast imaging is not indicated due to the increased radiation exposure and limited additive benefit
 - MRA Abdomen (CPT® 74185) or CTA Abdomen (CPT® 74175) to evaluate vascular invasion
- CT Chest with (CPT® 71260) **or** without contrast (CPT® 71250) in the initial work-up of all pediatric liver tumors and should be completed prior to anesthesia exposure if possible
- MRI Brain without and with contrast (CPT® 70553) only for symptoms suggesting CNS metastases
- Nuclear bone scan (See **Modality General Considerations (PEDONC-1.3)**) should be used for initial evaluation of bony metastases only in individuals with systemic symptoms or bone pain
- PET/CT should only be considered in very rare circumstances for preoperative planning when MRI and CT are insufficient for surgical decision-making.
 - PET/CT should not be approved in lieu of biopsy of suspicious lesions
 - Indications and coding for rare circumstances where PET/MRI may be approved are found in **PET Imaging in Pediatric Oncology (PEDONC-1.4)**

Pediatric HCC Treatment Response:

- For individuals with disease not completely resected at initial diagnosis, the following every 2 cycles (~6 weeks) **and** at the end of planned therapy:

- CT Chest with (CPT® 71260) **or** CT Chest without contrast (CPT® 71250)
- MRI Abdomen and Pelvis without and with contrast (CPT® 74183 and CPT® 72197)
 - While the majority of individuals will require abdomen and pelvis imaging at all time points, the pelvis imaging may be omitted at the discretion of the ordering physician
 - CT Abdomen and Pelvis with contrast (CPT® 74177) is inferior to MRI for pediatric liver malignancies and should only be approved if MRI is not available, contraindicated, or sedation is required but not available, or to clarify specific inconclusive areas on MRI.
 - Noncontrast imaging is not indicated due to the increased radiation exposure and limited additive benefit
 - MRA Abdomen (CPT® 74185) or CTA Abdomen (CPT® 74175) to evaluate vascular invasion
- Imaging of any metastatic sites with the same modality used during initial staging
- Abdominal ultrasound if tumor thrombus was detected at initial diagnosis
 - If no tumor thrombus was present, continued ultrasound evaluations are not indicated without a specific reason documented in the clinical records
- PET/CT in very rare circumstances for preoperative planning when MRI and CT scans are insufficient for surgical decision-making.

Pediatric HCC Surveillance Imaging:

- MRI Abdomen and Pelvis without and with contrast (CPT® 74183 and CPT® 72197) every 3 months for 1 year, then every 6 months for 1 year, then annually for 3 years after completion of all therapy
- Chest x-ray or CT Chest with contrast (CPT® 71260) every 3 months for 1 year, then every 6 months for 1 year, then annually for 3 years after completion of all therapy

Background and Supporting Information

- Individuals with brain or bone metastases should have surveillance imaging on the same schedule as the primary site imaging with the same modality used during initial staging.
- HCC, including its rare histologically distinct variant fibrolamellar hepatocellular carcinoma (FL-HCC), occurs mostly in older children and adolescents. Despite recent advances in treatment, overall survival of pediatric HCC diagnosed in advanced stages remains exceedingly poor, with five-year survival of only 17% to 22% for all stages of pediatric HCC (and FL-HCC). Most suspected liver tumors will have ultrasound and tumor markers (AFP, β -HCG, CEA) as initial evaluation.
- PET/CT should not be approved in lieu of biopsy of suspicious lesions
- The majority of hepatocellular carcinoma individuals are treated with surgery alone and do not receive adjuvant therapy. Individuals with successful upfront gross total

resection should be imaged using surveillance guidelines after surgery is completed.

- PET/CT has no documented role in the surveillance evaluation of pediatric hepatocellular carcinoma.

Pediatric Pancreatic Carcinoma (PEDONC-11.4)

ONCP.LT.0011.4.A

v2.0.2024

- This guideline applies to suspected or diagnosed pancreatic neoplasms in children.
- Beckwith-Wiedemann syndrome increases pancreatoblastoma risk. MEN1, VHL, neurofibromatosis, and tuberous sclerosis are also risk factors for pancreatic endocrine neoplasms.
 - Screening studies in these conditions are found in **Screening Imaging in Cancer Predisposition Syndromes (PEDONC-2)**.

Indication	Imaging Study
Initial Staging	<ul style="list-style-type: none"> • CT Abdomen and Pelvis with or with and without contrast (CPT® 74177 or CPT® 74178) OR MRI Abdomen with and without contrast plus MRI Pelvis with and without contrast (CPT® 74183 and CPT® 72917) • CT Chest with (CPT® 71260) or without (CPT® 71250) contrast • ⁶⁸Ga-Dotatate PET/CT whole-body (CPT® 78816) <ul style="list-style-type: none"> • Exception: for pediatric pancreatic tumor of non neuroendocrine origin (SPN, pancreatoblastoma and other exocrine origin) with equivocal conventional imaging, FDG PET/CT whole-body or skull to thighs (CPT® 78816 or 78815)
Treatment response ~every 2 cycles during treatment and at the end of planned therapy	<ul style="list-style-type: none"> • CT or MRI as used at time of initial imaging
If conventional imaging for treatment response is equivocal	<ul style="list-style-type: none"> • Neuroendocrine tumors: ⁶⁸Ga Dotatate PET/CT skull to thighs or whole-body (CPT® 78815 or 78816) • Non-neuroendocrine tumors: FDG PET/CT skull to thighs or whole-body (CPT® 78815 or 78816)
Assess candidacy for PRRT therapy	<ul style="list-style-type: none"> • ⁶⁸Ga Dotatate PET/CT whole body CPT® 78816 may also be approved to assess candidacy for PRRT therapy
Surveillance	<ul style="list-style-type: none"> • MRI or CT, modality and contrast as used in initial imaging, every 3 months for 2 years, then every 4 months for 1 year, then every 6 months for 1 year, then in 12 months to complete 5 years surveillance.
Suspected recurrence	<ul style="list-style-type: none"> • Repeat all imaging as noted in initial staging section

Background and Supporting Information

- Pancreatic tumors in children are exceedingly rare. The most common are solid pseudopapillary neoplasm (SPN), a low-grade epithelial malignancy. Pancreatoblastoma is the second most common.

References (PEDONC-11)

v2.0.2024

1. Meyers RL, Trobaugh-Lotario AD, Malogolowkin MH, et al. Pediatric liver tumors. In: Pizzo PA, Poplack DG, eds. Principles and Practice of Pediatric Oncology. 7th edition. Philadelphia, PA: Wolters Kluwer; 2016:726-752.
2. Tomlinson GE. Hepatoblastoma and other liver tumors in children. In: Orkin SH, Fisher DE, Ginsburg D, Look AT, Lux SE, Nathan DG, eds. Nathan and Oski's Hematology and Oncology of Infancy and Childhood. 8th edition. Philadelphia, PA: Elsevier Saunders; 2015:1886-1905.
3. Pugmire BS, Towbin AJ. Magnetic resonance imaging of primary pediatric liver tumors. *Pediatr Radiol*. 2016;46:764-777. doi:10.1007/s00247-016-3612-0.
4. Chavhan GB, Shelmerdine S, Jhaveri K, Babyn PS. Liver MR Imaging in children: current concepts and technique. *RadioGraphics*. 2016;36(5):1517-1532. doi:10.1148/rg.2016160017.
5. Rai P, Feusner H. Cerebral metastasis of hepatoblastoma: a review. *J Pediatr Hematol Oncol*. 2016;38(4):279-282. doi:10.1097/MPH.0000000000000554.
6. Allen-Rhoades W, Whittle SB, Rainusso N. Pediatric solid tumors of infancy: an overview. *Pediatr Rev*. 2018;39:57-67. doi:10.1542/pir.2017-0057.
7. Allan BJ, Wang B, Davis JS, et al. A review of 218 pediatric cases of hepatocellular carcinoma. *J Pediatr Surg*. 2014;49(1):166-171. doi:10.1016/j.jpedsurg.2013.09.050.
8. Pappo AS, Furman WL, Schulz KA, Ferrari A, Helman L, Krailo MD. Rare tumors in children: progress through collaboration. *J Clin Oncol*. 2015;33(27):3047-3054. doi:10.1200/JCO.2014.59.3632.
9. Benson AB, D'Angelica MI, Abrams T, et al. National Comprehensive Cancer Network (NCCN) Guidelines Version 1.2023—March 10, 2023, Hepatocellular Carcinoma, available at: https://www.nccn.org/professionals/physician_gls/pdf/hcc.pdf, Referenced with permission from the NCCN Clinical Practice Guidelines in Oncology (NCCN Guidelines™) for Hepatocellular Carcinoma V1.2023 3/10/2023. ©2023 National Comprehensive Cancer Network, Inc. All rights reserved. The NCCN Guidelines™ and illustrations herein may not be reproduced in any form for any purpose without the express written permission of the NCCN. To view the most recent and complete version of the NCCN Guidelines™, go online to NCCN.org.
10. Benson AB, D'Angelica MI, Abrams T, et al. National Comprehensive Cancer Network (NCCN) Guidelines Version 2.2023—May 10, 2023, Biliary Tract Cancers, available at: https://www.nccn.org/professionals/physician_gls/pdf/btc.pdf, Referenced with permission from the NCCN Clinical Practice Guidelines in Oncology (NCCN Guidelines™) for Biliary Tract Cancers V2.2023 5/10/2023. ©2023 National Comprehensive Cancer Network, Inc. All rights reserved. The NCCN Guidelines™ and illustrations herein may not be reproduced in any form for any purpose without the express written permission of the NCCN. To view the most recent and complete version of the NCCN Guidelines™, go online to NCCN.org.
11. D'Souza AM, Shah R, Gupta A, et al, Surgical management of children and adolescents with upfront completely resected hepatocellular carcinoma, *Pediatr Blood Cancer*. 2019;65:e27293. doi:10.1002/pbc.27293.
12. Weeda VB, Aronson DC, Verheij J, and Lamers WH, Is hepatocellular carcinoma the same disease in children and adults? Comparison of histology, molecular background, and treatment in pediatric and adult patients, *Pediatr Blood Cancer*. 2019;66:e27475. doi:10.1002/pbc.27475.
13. Eklund MJ, States LJ, Acord MR, et. al. Imaging of pediatric pancreas tumors: A COG Diagnostic Imaging Committee/SPR Oncology Committee White Paper. *Pediatr Blood Cancer*. 2022;e29975. doi:10.1002/pbc.29975.
14. Schooler GR, Infante JC, Acord M, et. al. Imaging of pediatric liver tumors: A COG Diagnostic Imaging Committee/SPR Oncology Committee white paper. *Pediatr Blood Cancer*. 2023;70 Suppl 4:e29965. doi:10.1002/pbc.29965. .

Retinoblastoma (PEDONC-12)

Guideline

Retinoblastoma – General Considerations (PEDONC-12.1)

Retinoblastoma – Imaging (PEDONC-12.2)

References (PEDONC-12)

Retinoblastoma – General Considerations (PEDONC-12.1)

ONCP.EC.0012.1.A

v2.0.2024

- Retinoblastoma (RB) is primarily a disease of the infant and young child, and presents with leukocoria (loss of red reflex).
- About 75% of individuals are diagnosed before the age of two years (bilateral RB presents at 12 months of age).
- Retinoblastoma can occur as heritable (25% of cases) or nonheritable (75%) disease.
 - Heritable RB is associated with a germline mutation in the RB1 gene often resulting typically in bilateral disease.
 - Individuals who carry the RB1 mutation also have increased risk of developing other cancers, such as osteosarcoma, soft tissue sarcomas, or melanoma. For more information on heritable retinoblastoma, see: **Familial Retinoblastoma Syndrome (PEDONC-2.12)**.
 - Whole-body MRI has shown poor sensitivity and specificity in individuals with predisposition to systemic malignancy due to germline RB1 mutations, and is not supported.
- Detailed evaluation by a physician with significant training and/or experience in retinoblastoma (most commonly a pediatric ophthalmologist or pediatric oncologist) is indicated prior to considering advanced imaging.
- Retinoblastoma can be unilateral, bilateral, or trilateral (involving the pineal gland). Extraocular spread of retinoblastoma is rare and generally confined to the brain.

Retinoblastoma – Imaging (PEDONC-12.2)

ONCP.EC.0012.2.A

v2.0.2024

Retinoblastoma Initial Staging:

- Tumor biopsy is NOT required prior to imaging
- MRI Orbits (CPT® 70543) and Brain (CPT® 70553) without and with contrast in the initial work-up
 - Brain imaging may be omitted or deferred at the discretion of the treating ophthalmologist or oncologist
- MRI Spine without and with contrast (Cervical-CPT® 72156, Thoracic-CPT® 72157, Lumbar-CPT® 72158) if there is evidence of CNS metastasis on:
 - Ophthalmologic exam
 - MRI Brain
 - Lumbar CSF cytology
- CT Chest (CPT® 71260) and MRI Abdomen and Pelvis without and with contrast (CPT® 74183 and CPT® 72197) with clinical symptoms to suggest metastatic disease
- CT Orbital (contrast as requested) and orbital ultrasound can be approved if ordered by the treating ophthalmologist for a specified indication
- Nuclear bone scan (See: **Modality General Considerations (PEDONC-1.3)**) is the preferred imaging modality for individuals with systemic bone pain suggestive of bony metastases
- PET has no documented role in the evaluation of retinoblastoma

Retinoblastoma Treatment Response:

- MRI Orbits (CPT® 70543) and/or Brain (CPT® 70553) can be approved every 2 cycles (~ every 6 weeks) and at the end of planned therapy
- For individuals with metastatic disease, imaging of known positive areas using the same modality at initial staging can be approved every 2 cycles (~6 to 8 weeks) and at the end of planned therapy

Retinoblastoma Surveillance:

- Surveillance using advanced imaging for unilateral retinoblastoma after enucleation or exenteration only for evaluation of specific clinical concerns.
- MRI Orbits (CPT® 70543) and Brain (CPT® 70553) for individuals undergoing ocular salvage treatment approaches every 6 months for 2 years following completion of therapy
- MRI Brain without and with contrast (CPT® 70553) can be approved every 6 months for 5 years from the time of diagnosis with retinoblastoma

Background and Supporting Information

- CT should generally be avoided in retinoblastoma individuals under one year of age or with family history of retinoblastoma (heritable) due to substantially increased risks for secondary malignancy
- The primary method of surveillance in retinoblastoma is examination under anesthesia (EUA), although some older children can be sufficiently evaluated by exam without anesthesia (EWA).
- Surveillance using advanced imaging is generally not indicated for unilateral retinoblastoma after enucleation or exenteration but can be approved for evaluation of specific clinical concerns.
- Individuals with bilateral retinoblastoma or germline mutation in RB1 are at increased risk for subsequent pineoblastoma
- Routine MRI follow up for pineal disease is not currently supported by evidence in unilateral retinoblastoma individuals without germline RB1 mutations

References (PEDONC-12)

v2.0.2024

1. Hurwitz RL, Shields CL, Shields JA, et al. Retinoblastoma. In: Pizzo PA, Poplack DG, eds. Principles and Practice of Pediatric Oncology. 7th ed. Philadelphia, PA: Wolters Kluwer; 2016:700-725.
2. Rodriguez-Galindo C, Wilson MW, and Dyer M. Retinoblastoma. In: Orkin SH, Fisher DE, Ginsburg D, Look AT, Lux SE, Nathan DG, eds. Nathan and Oski's Hematology and Oncology of Infancy and Childhood. 8th edition. Philadelphia, PA: Elsevier Saunders; 2015:1747-1778.
3. de Jong MC, Kors WA, de Graaf P, Castelijns JA, Kivelä T, Moll AC. Trilateral retinoblastoma: a systematic review and meta-analysis. *Lancet Oncol.* 2014;15(10):1157-1167. doi:10.1016/S1470-2045(14)70336-5.
4. De Graaf P, Göricke S, Rodjan F, et al. Guidelines for imaging retinoblastoma: imaging principles and MRI standardization. *Pediatr Radiol.* 2012;42(1):2-14. doi:10.1007/s00247-011-2201-5.
5. Allen-Rhoades W, Whittle SB, Rainusso N. Pediatric Solid Tumors of Infancy: An Overview, *Pediatr Rev.* 2018;39:57-67. doi:10.1542/pir.2017-0057.
6. Lohmann DR, Gallie BL. Retinoblastoma. In: Pagon RA, Adam MP, Ardinger HH et al, eds. *GeneReviews™ [Internet]*. Seattle, WA: University of Washington, Seattle; 1993-2019. version November 21, 2018. <https://www.ncbi.nlm.nih.gov/books/NBK1452/>.
7. Freidman DN, Lis E, Sklar CA, et al. Whole-body magnetic resonance imaging (WB-MRI) as surveillance for subsequent malignancies in survivors of hereditary retinoblastoma: a pilot study. *Pediatr Blood Cancer.* 2014;61(8):1440-4. doi:10.1002/pbc.24835.

Pediatric Nasopharyngeal Carcinoma (PEDONC-13)

Guideline

Pediatric Nasopharyngeal Carcinoma – General Considerations
(PEDONC-13.1)

Pediatric NPC – Imaging (PEDONC-13.2)

References (PEDONC-13)

Pediatric Nasopharyngeal Carcinoma – General Considerations (PEDONC- 13.1)

ONCP.NC.0013.1.A
v2.0.2024

- Pediatric nasopharyngeal carcinoma (NPC) is rare in comparison to adult NPC but is responsible for up to 50% of nasopharyngeal cancers in children and has higher rates of aggressive type III EBV-associated histology than adult NPC.
- Standard upfront treatment in pediatric NPC consists of 3 to 4 cycles of neoadjuvant chemotherapy followed by definitive chemoradiotherapy. Rare individuals with lower stage disease may be treated with radiotherapy alone.

Pediatric NPC – Imaging (PEDONC-13.2)

ONCP.NC.0013.2.A

v2.0.2024

Pediatric NPC Initial Staging:

- MRI Brain without and with contrast (CPT® 70553) **and** MRI Neck without and with contrast (CPT® 70543)
 - CT Head without and with contrast (CPT® 70470), CT Maxillofacial without and with contrast (CPT® 70488), **and/or** CT Neck with contrast (CPT® 70491) for individuals with documented contraindication to MRI imaging (avoidance of sedation should not be the sole reason)
- CT Chest with contrast (CPT® 71260) in initial staging
- Whole-body PET/CT (CPT® 78816) after histologic confirmation of NPC to evaluate for distant metastases
 - Bone scan when PET/CT is unavailable (See: **Modality General Considerations (PEDONC-1.3)**)
 - Indications and coding for rare circumstances where PET/MRI may be approved are found in **PET Imaging in Pediatric Oncology (PEDONC-1.4)**
 - CT Abdomen with contrast (CPT® 74160) for ANY of the following if PET/CT unavailable:
 - Initial EBV DNA load ≥ 4000 copies/mL
 - Signs and symptoms of liver disease (including abdominal pain and elevated LFTs)

Pediatric NPC Treatment Response:

- MRI Brain without and with contrast (CPT® 70553) **and** MRI Neck without and with contrast (CPT® 70543) for response assessment at the following time points:
 - Following completion of neoadjuvant chemotherapy
 - Following completion of chemoradiotherapy
- CT Chest with contrast (CPT® 71260) **and** Whole-Body PET/CT (CPT® 78816) **or** bone scan (See: **Modality General Considerations (PEDONC-1.3)**) at the following time points:
 - Following completion of neoadjuvant chemotherapy only if positive at initial diagnosis
 - Following completion of chemoradiotherapy
- PET during active treatment for recurrent pediatric cancer in rare circumstances when results are likely to result in a treatment change, including a change from active treatment to surveillance.

Pediatric NPC Surveillance:

- MRI Brain without and with contrast (CPT® 70553) **and** MRI Neck without and with contrast (CPT® 70543) every 3 months for 1 year, then every 6 months for 2 years after completion of all planned therapy
- CT Chest with contrast (CPT® 71260) is indicated every 3 months for 1 year, then every 6 months for 2 years after completion of all planned therapy

Pediatric NPC Suspected Recurrence:

- MRI Brain without and with contrast (CPT® 70553) and MRI Neck without and with contrast (CPT® 70543)
 - CT Head without and with contrast (CPT® 70470), CT Maxillofacial without and with contrast (CPT® 70488), and/or CT Neck with contrast (CPT® 70491) can be approved for individuals with documented contraindication to MRI imaging
- CT Chest with contrast (CPT® 71260)
- Whole-body PET/CT (CPT® 78816) or bone scan (See: **Modality General Considerations (PEDONC-1.3)**) for histologically confirmed recurrence of NPC. These studies may also be approved for:
 - Clarification of specified inconclusive findings seen on conventional imaging
 - Restaging to identify sites of disease when EBV PCR levels are abnormally high and conventional imaging is negative

Background and Supporting Information

- Metastasis frequently occurs in cervical lymph nodes and retropharyngeal space. Distal metastasis usually appears in bones, lungs, mediastinum, and rarely, in the liver. In many individuals, the initial presentation is a cervical adenopathy, and diagnosis is made with a lymph node biopsy.
- Quantitative EBV DNA PCR measured at initial diagnosis, as it can serve as an effective tumor marker if elevated at initial diagnosis.
- Skull base invasion is common in pediatric NPC and has a dramatic impact on prognosis, and is more easily recognized on MRI imaging
- PET is generally not indicated during active treatment for recurrent pediatric cancer
 - Whole-body PET/CT (CPT® 78816) or bone scan (See: **Modality General Considerations (PEDONC-1.3)**) are not indicated for routine surveillance in asymptomatic individuals

References (PEDONC-13)

v2.0.2024

1. Pappo AS, Rodriguez-Galindo C, and Furman WL. Management of infrequent cancers of childhood. In: Pizzo PA, Poplack DG, eds. *Principles and Practice of Pediatric Oncology*. 7th edition. Philadelphia, PA: Wolters Kluwer; 2016:1098-1123.
2. Goldberg JM, Pappo AS, and Bishop M. Rare tumors of childhood. In: Orkin SH, Fisher DE, Ginsburg D, Look AT, Lux SE, Nathan DG, eds. *Nathan and Oski's Hematology and Oncology of Infancy and Childhood*. 8th edition. Philadelphia, PA: Elsevier Saunders; 2015:2123-2145.
3. Cheuk DKL, Sabin ND, Hossain M, et al. Positron emission tomography-computed tomography for staging and follow-up of pediatric nasopharyngeal carcinoma. *Eur J Nucl Med Mol Imaging*. 2012;39(7):1097-1106. doi:10.1007/s00259-012-2091-2.
4. Stambuk HE, Patel SG, Mosier KM, Wolder SL, Holodny AI. Nasopharyngeal carcinoma: recognizing the radiographic features in children. *Am J Neuroradiol*. 2005;26(6):1575-1579.
5. Sahai P, Mohanti BK, Sharma A, et al. Clinical outcome and morbidity in pediatric patients with nasopharyngeal cancer treated with chemotherapy. *Pediatr Blood Cancer*. 2017;64(2):259-266. doi:10.1002/pbc.26240.
6. PDQ® Pediatric Treatment Editorial Board. PDQ Childhood Nasopharyngeal Cancer Treatment – Health Professional Version. Bethesda, MD: National Cancer Institute. Updated 03/30/2023. Available at: <https://www.cancer.gov/types/head-and-neck/hp/child/nasopharyngeal-treatment-pdq> Accessed 8/4/2021.
7. Zhang, Lu et al. Plasma Epstein-Barr viral DNA complements TNM classification of nasopharyngeal carcinoma in the era of intensity-modulated radiotherapy. *ONcotarget*. 2015;7(5):6221-6231.

Pediatric Adrenocortical Carcinoma (PEDONC-14)

Guideline

Pediatric Adrenocortical Carcinoma – General Considerations
(PEDONC-14.1)

Pediatric ACC – Imaging (PEDONC-14.2)

References (PEDONC-14)

Pediatric Adrenocortical Carcinoma – General Considerations (PEDONC- 14.1)

ONCP.AC.0014.1.A

v2.0.2024

- Pediatric Adrenocortical Carcinoma (ACC) is a rare but aggressive tumor, with fewer than 25 cases diagnosed each year.
- Most individuals are diagnosed because of virilizing symptoms, Cushing syndrome, and rarely with feminization and hyperaldosteronism or detection on screening imaging recommended for specified cancer predisposition syndromes.
- See: **Li-Fraumeni Syndrome (LFS) (PEDONC-2.2)** and **Beckwith-Wiedemann Syndrome (BWS) (PEDONC-2.4)** for screening recommendations for individuals known to have these syndromes.

Pediatric ACC – Imaging (PEDONC-14.2)

ONCP.AC.0014.2.A

v2.0.2024

- CT Abdomen without and with contrast increases radiation exposure and should not be routinely performed in a child with an adrenal lesion as washout criteria have not been validated in children

Indication	Imaging Study
Initial staging	<ul style="list-style-type: none"> • CT Chest without contrast (CPT® 71250) or with (CPT® 71260) contrast • CT Abdomen with contrast (CPT® 74160) or MRI Abdomen without and with contrast (CPT® 74183) • Nuclear bone scan (see: (PEDONC-1.3) for coding)
After complete resection, with no plans for chemotherapy or radiotherapy	<ul style="list-style-type: none"> • See surveillance below
Restaging, for all unresected primary or metastatic disease on chemotherapy	<ul style="list-style-type: none"> • Every 2 cycles (~6 weeks) during chemotherapy, and following completion of all planned chemotherapy: <ul style="list-style-type: none"> • CT Chest without contrast (CPT® 71250) or with (CPT® 71260) contrast • CT Abdomen with contrast (CPT® 74160) or MRI Abdomen without and with contrast (CPT® 74183) • If positive for distant metastases at initial diagnosis: <ul style="list-style-type: none"> • Nuclear bone scan (see: (PEDONC-1.3) for coding) every 2 cycles (~6 weeks) during chemotherapy and following completion of all planned chemotherapy
Response assessment at the completion of radiotherapy	<ul style="list-style-type: none"> • CT Abdomen with contrast (CPT® 74160) or MRI Abdomen without and with contrast (CPT® 74183)

Indication	Imaging Study
Surveillance, individuals with only localized disease at diagnosis	<ul style="list-style-type: none"> • Every 3 months for 2 years, then every 6 months for 3 years: <ul style="list-style-type: none"> • CT Abdomen with contrast (CPT® 74160) or MRI Abdomen without and with contrast (CPT® 74183)
Surveillance, individuals with metastatic ACC	<ul style="list-style-type: none"> • Every 3 months for 2 years, then every 6 months for 3 years: <ul style="list-style-type: none"> • CT Chest without contrast (CPT® 71250) or with (CPT® 71260) contrast • CT Abdomen with contrast (CPT® 74160) or MRI Abdomen without and with contrast (CPT® 74183)
Recurrence	<ul style="list-style-type: none"> • CT Chest without contrast (CPT® 71250) or with (CPT® 71260) contrast • CT Abdomen with contrast (CPT® 74160) or MRI Abdomen without and with contrast (CPT® 74183)
Suspected bone recurrence	<ul style="list-style-type: none"> • Nuclear bone scan (see: (PEDONC-1.3) for coding)

Background and Supporting Information

- The mainstay of treatment is surgery.
 - Chemotherapy, adrenal suppression, and radiotherapy typically follow resection.
 - Many ACC individuals are treated with surgery alone and do not receive adjuvant therapy. These individuals should be imaged using surveillance guidelines after surgery is completed.

References (PEDONC-14)

v2.0.2024

1. Waguespack SG, Huh WW, and Bauer AJ. Endocrine tumors. In: Pizzo PA, Poplack DG, eds. Principles and Practice of Pediatric Oncology. 7th edition. Philadelphia, PA: Wolters Kluwer; 2016:919-945.
2. Michalkiewicz E, Sandrini R, Figueiredo B, et al. Clinical and outcome characteristics of children with adrenocortical tumors: a report from The International Pediatric Adrenocortical Tumor Registry. J Clin Oncol. 2004;22(5):838-845. doi:10.1200/JCO.2004.08.085.
3. Flynt KA, Dillman JR, Davenport MS, et al. Pediatric adrenocortical neoplasms: can imaging reliably discriminate adenomas from carcinomas? Pediatr Radiol. 2015;45(8):1160-1168. doi:10.1007/s00247-015-3308-x.
4. Gupta N, Rivera M, Novotny P, et al. Adrenocortical Carcinoma in Children: A Clinicopathological Analysis of 41 Patients at the Mayo Clinical from 1950 to 2017, Horm Res Paediatr. 2018;90:8-18. doi:10.1159/000488855.
5. PDQ® Pediatric Treatment Editorial Board. PDQ Childhood Adrenocortical Carcinoma Treatment. Bethesda, MD: National Cancer Institute. Updated 12/08/2022. Available at: <https://www.cancer.gov/types/adrenocortical/hp/child-adrenocortical-treatment-pdq>.
6. Wasserman JD, Novokmet A, Eichler-Jonsson C, et al. Prevalence and functional consequence of TP53 mutations in pediatric adrenocortical carcinoma: a children's oncology group study. J Clin Oncol. 2015;33(6):602-9. doi:10.1200/JCO.2013.52.6863.
7. Shah MH, Goldner WS, Benson III AB, et al. National Comprehensive Cancer Network (NCCN) Guidelines Version 2.2022 – 12/21/2022. Neuroendocrine tumors, available at: https://www.nccn.org/professionals/physician_gls/pdf/neuroendocrine.pdf Referenced with permission from the NCCN Clinical Practice Guidelines in Oncology (NCCN Guidelines™) for Neuroendocrine and Adrenal tumors V2.2022 – December 21, 2022. ©2022 National Comprehensive Cancer Network, Inc. All rights reserved. The NCCN Guidelines™ and illustrations herein may not be reproduced in any form for any purpose without the express written permission of the NCCN. To view the most recent and complete version of the NCCN Guidelines™, go online to NCCN.org
8. Rees MA, Morin CE, Behr GG, et. al. Imaging of pediatric adrenal tumors: A COG Diagnostic Imaging Committee/SPR Oncology Committee white paper. Pediatr Blood Cancer. 2022:e29973. doi:10.1002/pbc.29973. .

Pediatric Melanoma and Other Skin Cancers (PEDONC-15)

Guideline

Pediatric Melanoma and Other Skin Cancers (PEDONC-15)

References (PEDONC-15)

Pediatric Melanoma and Other Skin Cancers (PEDONC-15)

ONCP.SK.0015.A

v2.0.2024

- Pediatric melanoma is historically rare but has a steadily rising incidence, especially in adolescents and young adults (AYAs). Staging is assigned using the American Joint Committee on Cancer (AJCC) staging for adult melanoma. Most cases of melanoma arising in children and AYAs (~75%) are localized at diagnosis, and approximately 90% of individuals with pediatric melanoma are amenable to radical excision. The clinical management of adolescents and young adults with melanoma is still challenging and evolving because it is difficult to diagnose, and there is no standard treatment.
- Non-melanoma skin cancers (mostly basal cell carcinoma and squamous cell carcinoma) are extremely rare in pediatric individuals. In many cases, predisposing factors such as prolonged immunosuppression, radiation therapy, chemotherapy, voriconazole use, or a combination of the factors are present, and established age-specific guidelines for management of these skin tumors do not exist.
- Imaging guidelines and treatment approaches are consistent with those used for adults with melanoma and other skin cancers, and these individuals should follow the imaging guidelines in section **Melanomas and Other Skin Cancers (ONC-5)** in the Oncology Imaging Guidelines.

References (PEDONC-15)

v2.0.2024

1. Rodriguez-Galindo C, Furman WL, Pappo AS. Rare pediatric tumors. In: Pizzo PA, Poplack DG, eds. Principles and Practice of Pediatric Oncology. 7th edition. Philadelphia, PA: Wolters Kluwer; 2016:946-966.
2. Goldberg JM, Pappo AS, Bishop M. Rare tumors of childhood. In: Orkin SH, Fisher DE, Ginsburg D, Look AT, Lux SE, Nathan DG, eds. Nathan and Oski's Hematology and Oncology of Infancy and Childhood. 8th edition. Philadelphia, PA: Elsevier Saunders; 2015:2123-2145.
3. Swetter SM, Thompson JA, Coit DG, et al. National Comprehensive Cancer Network (NCCN) Guidelines Version 2.2023—March 10, 2023, Melanoma: Cutaneous, available at: https://www.nccn.org/professionals/physician_gls/pdf/cutaneous_melanoma.pdf, Referenced with permission from the NCCN Clinical Practice Guidelines in Oncology (NCCN Guidelines™) for Melanoma: Cutaneous V2.2023 3/10/2023. ©2023 National Comprehensive Cancer Network, Inc. All rights reserved. The NCCN Guidelines™ and illustrations herein may not be reproduced in any form for any purpose without the express written permission of the NCCN. To view the most recent and complete version of the NCCN Guidelines™, go online to NCCN.org
4. Senerchia AA, Ribiero KB, Rodriguez-Galindo C. Trends in incidence of primary cutaneous malignancies in children, adolescents, and young adults: a population-based study. *Pediatr Blood Cancer*. 2014;61(2):211-216. doi:10.1002/pbc.24639.
5. Kolandijan NA, Wei C, Burke A, Bedikian AY. Malignant melanoma in teenagers and young adults. *J Pediatr Hematol Oncol*. 2014;36(7):552-558. doi:10.1097/MPH.0000000000000231.
6. Brecht IB, De Paoli A, Bisogno G, et al. Pediatric patients with cutaneous melanoma: A European study. *Pediatr Blood Cancer*. 2018;65:e26974. doi:10.1002/pbc.26974.
7. Indini A, Brecht I, Del Vecchio M, et al. Cutaneous melanoma in adolescents and young adults. *Pediatr Blood Cancer*. 2018;65:e27292. doi:10.1002/pbc.27292.
8. Kohsravi H, Schmidt B, and Huang JT. Characteristics and outcomes of nonmelanoma skin cancer (NMSC) in children and young adults. *J Am Acad Dermatol*. 2015;73:785-790. doi:10.1016/j.aad.2015.08.007. .

Pediatric Salivary Gland Tumors and Thyroid Tumors (PEDONC-16)

Guideline

Pediatric Salivary Gland Tumors and Thyroid Tumors (PEDONC-16)
References (PEDONC-16)

Pediatric Salivary Gland Tumors and Thyroid Tumors (PEDONC-16)

ONCO.ST.0016.A

v2.0.2024

Pediatric Salivary Gland Tumors

- The majority of pediatric salivary gland tumors arise in the parotid gland. Approximately 10% to 15% of tumors arise in the submandibular, sublingual, or minor salivary glands.
- Roughly 75% of pediatric salivary gland tumors are benign, most commonly pleomorphic adenoma.
- The most common malignant tumors occurring in the salivary glands are mucoepidermoid carcinoma, adenoid cystic carcinoma, acinic cell carcinoma, undifferentiated carcinoma, and rarely adenocarcinoma.
- American Joint Committee on Cancer (AJCC) staging is used for pediatric as well as adult salivary gland tumors.
- Imaging and treatment guidelines for malignant pediatric salivary gland tumors are consistent with those used for adults with salivary gland tumors, and these individuals should follow the imaging guidelines in section **Salivary Gland Cancers (ONC-4)** in the Oncology Imaging Guidelines.

Pediatric Thyroid Tumors

- Differentiated thyroid cancers (DTC): Papillary, Follicular and Hürthle Cell are the most common childhood thyroid malignancy. Standard treatment is thyroidectomy and radioactive iodine (RAI).
- Imaging and treatment guidelines for malignant pediatric thyroid tumors are consistent with those used for adults with thyroid tumors, and these individuals should follow the imaging guidelines in section **Thyroid Cancers (ONC-6)** in the Oncology Imaging Guidelines.

References (PEDONC-16)

v2.0.2024

1. Rodriguez-Galindo C, Furman WL, and Pappo AS. Rare pediatric tumors. In: Pizzo PA, Poplack DG, eds. Principles and Practice of Pediatric Oncology. 7th edition. Philadelphia, PA: Wolters Kluwer; 2016:946-966.
2. Goldberg JM, Pappo AS, and Bishop M. Rare tumors of childhood. In: Orkin SH, Fisher DE, Ginsburg D, Look AT, Lux SE, Nathan DG, eds. Nathan and Oski's Hematology and Oncology of Infancy and Childhood. 8th edition. Philadelphia, PA: Elsevier Saunders; 2015:2123-2145.
3. Pfister DG, Spencer S, Adelstein D, et al. National Comprehensive Cancer Network (NCCN) Guidelines Version 2.2023—May 15, 2023, Head and Neck Cancers, available at: https://www.nccn.org/professionals/physician_gls/pdf/head-and-neck.pdf, referenced with permission from the NCCN Clinical Practice Guidelines in Oncology (NCCN Guidelines™) for Head and Neck Cancers V2.2023 5/15/2023. ©2023 National Comprehensive Cancer Network, Inc. All rights reserved. The NCCN Guidelines™ and illustrations herein may not be reproduced in any form for any purpose without the express written permission of the NCCN. To view the most recent and complete version of the NCCN Guidelines™, go online to NCCN.org
4. Chiaravalli S, Guzzo M, Bisogno G, et al. Salivary gland carcinomas in children and adolescents: The Italian TREP project experience. *Pediatr Blood Cancer*. 2014;61(11):1961-1968.
5. Rebours C, Couloigner V, Galmiche L, et al. Pediatric salivary gland carcinomas: diagnostic and therapeutic management. *Laryngoscope*. 2017;127:140-147.
6. Zamani M, Gronhoj C, Jensen JS, et al. Survival and characteristics of pediatric salivary gland cancer: A systematic review and meta-analysis. *Pediatr Blood Cancer*. 2019;66:e27543. doi:10.1002/pbc.27543.
7. Prasad PK, Mahajan P, Hawkins DS, Mostoufi-Moab S, Venkatramani R. Management of pediatric differentiated thyroid cancer: An overview for the pediatric oncologist. *Pediatr Blood Cancer*. 2020;67(6):e28141. doi:10.1002/pbc.28141.
8. Haddad RH, Bischoff L, Bernet V, et al. National Comprehensive Cancer Network (NCCN) Guidelines Version 2.2023 – May 18, 2023 Thyroid carcinoma, available at: https://www.nccn.org/professionals/physician_gls/pdf/thyroid.pdf. Referenced with permission from the NCCN Clinical Practice Guidelines in Oncology (NCCN Guidelines™) for Thyroid carcinoma V2.2023– May 18, 2023 ©2023 National Comprehensive Cancer Network, Inc. All rights reserved. The NCCN Guidelines™ and illustrations herein may not be reproduced in any form for any purpose without the express written permission of the NCCN. To view the most recent and complete version of the NCCN Guidelines™, go online to NCCN.org.
9. Squires JH, Martinez-Rios C, Davis JC, et. al. Imaging of pediatric thyroid tumors: A COG Diagnostic Imaging Committee/SPR Oncology Committee white paper. *Pediatr Blood Cancer*. 2023;70 Suppl 4:e29957. doi:10.1002/pbc.29957.

Pediatric Breast Masses (PEDONC-17)

Guideline

Pediatric Breast Masses (PEDONC-17)

References (PEDONC-17)

Pediatric Breast Masses (PEDONC-17)

ONCP.BC.0017.A
v2.0.2024

- Ultrasound (CPT® 76641 and CPT® 76642) is the primary and preferred modality used for evaluation of pediatric breast masses.
- MRI has very limited utility in evaluation of pediatric breast masses prior to biopsy but may be indicated in rare cases for surgical planning when ultrasound is non-diagnostic.
- Pediatric individuals with confirmed breast cancer should be imaged according to section **Breast Cancer (ONC-11)** in the Oncology Imaging Guidelines.

Background and Supporting Information

- Less than 1% of pediatric breast lesions are malignant, and advanced imaging is generally not recommended without histological confirmation of malignancy.
- Mammography has limited utility in pediatric breast mass evaluation due to the high mammographic breast density in this age group, and the risk of the radiation exposure outweighs the benefit of this modality. As a result, mammography is NOT recommended for evaluation of pediatric or adolescent breast masses.
 - BI-RADS classification may overstate the risk of malignancy or need for biopsy in pediatric individuals.

References (PEDONC-17)

v2.0.2024

1. Rodriguez-Galindo C, Furman WL, Pappo AS. Rare pediatric tumors. In: Pizzo PA, Poplack DG, eds. *Principles and Practice of Pediatric Oncology*. 7th edition. Philadelphia, PA: Wolters Kluwer; 2016:946-966.
2. Goldberg JM, Pappo AS, Bishop M. Rare Tumors of Childhood. In: Orkin SH, Fisher DE, Ginsburg D, Look AT, Lux SE, Nathan DG, eds. *Nathan and Oski's Hematology and Oncology of Infancy and Childhood*. 8th edition. Philadelphia, PA: Elsevier Saunders; 2015:2123-2145.
3. Kaneda HJ, Mack J, Kasales CJ, Schetter S. Pediatric and adolescent breast masses: a review of pathophysiology, imaging, diagnosis, and treatment. *AJR Am J Roentgenol*. 2013;200(2):W204-W212. doi:10.2214/AJR.12.9560.
4. Koning JL, Davenport KP, Poole PS, Kruk PG, Grabowski JE. Breast Imaging-Reporting and Data System (BI-RADS) classification in 51 excised palpable pediatric breast masses. *J Pediatr Surg*. 2015;50(10):1746-1750. doi:10.1016/j.jpedsurg.2015.02.062.
5. Siegel MJ, Chung EM. Breast. In: Siegel MJ, ed. *Pediatric Sonography*. 5th ed. Philadelphia, PA: Wolters Kluwer; 2019:196-210.
6. Siegel MJ, Chung EM. Breast masses in children and adolescents. *Applied Radiology*. 2017;46(9):12-17.
7. Johnson RH, Anders CK, Litton JK, Ruddy KJ, Bleyer A. Breast cancer in adolescents and young adults. *Pediatr Blood Cancer*. 2018;65:e27397. doi:10.1002/pmb.27397.
8. Sanders LM, Sharma P, El Madany M, et al. Clinical breast concerns in low-risk pediatric patients: practice review with proposed recommendations. *Pediatr Radiol*. 2018;48:186-195. doi:10.1007/s00247-017-4007-6.

Histiocytic Disorders (PEDONC-18)

Guideline

Histiocytic Disorders – General Considerations (PEDONC-18.1)

Langerhans Cell Histiocytosis (LCH) (PEDONC-18.2)

Hemophagocytic Lymphohistiocytosis (HLH) (PEDONC-18.3)

Non-Langerhans Cell Histiocytoses (PEDONC-18.4)

References (PEDONC-18)

Histiocytic Disorders – General Considerations (PEDONC-18.1)

ONCP.HC.0018.1.A

v2.0.2024

- The majority of histiocytic disorders occurring in the pediatric population are either Langerhans Cell Histiocytosis (LCH) or Hemophagocytic Lymphohistiocytosis (HLH).
- The Non-Langerhans cell histiocytoses encompass a variety of diseases, and have limited imaging considerations except as specified later in this section.
- Where there are indications for PET/CT in these guidelines, please note that indications and coding for rare circumstances where PET/MRI may be approved are found in **PET Imaging in Pediatric Oncology (PEDONC-1.4)**
- PEDONC-18 applies to individuals of all ages.
- The use of PET in this guideline refers to Fluorodeoxyglucose (fluorine-18-2-fluoro-2-deoxy-D-glucose [FDG]) radiotracer only.

Langerhans Cell Histiocytosis (LCH) (PEDONC-18.2)

ONCP.HC.0018.2.A

v2.0.2024

LCH Initial Imaging Studies:

- Whole-body PET/CT (CPT® 78816)
 - Whole-body Tc-99m bone scan (CPT® 78306) can be approved in lieu of PET if PET is unavailable
- CT Chest with contrast (CPT® 71260) **or** high-resolution CT Chest without contrast (CPT® 71250) in addition to PET/CT for suspected pulmonary LCH based on ANY of the following:
 - Abnormal CXR
 - Symptoms of pulmonary involvement and normal CXR
 - Clarification of pulmonary findings on PET/CT
- MRI Brain without and with contrast (CPT® 70553) for ANY of the following:
 - Headaches or visual or neurologic disturbances
 - Polyuria/polydipsia or other endocrine abnormalities
 - Skull or craniofacial (including jaw) bone involvement
 - Otorrhea or hearing loss (CT Temporal Bone may be substituted if requested)
 - Other signs or symptoms suggesting intracranial involvement, including neurodegeneration syndrome
- CTA/MRA Head (CPT® 70496/70544) may be approved as part of operative planning or image guidance
- CT Abdomen and/or Pelvis with contrast (CPT® 74177, 74160, or 72193) for ANY of the following:
 - Abdominal and/or pelvic signs and symptoms **if PET/CT has not been performed** or to clarify abnormal abdominal/pelvic findings on PET/CT
 - Abdominal and/or pelvic findings on ultrasound if PET/CT has not been performed
- MRI Abdomen without and with contrast (CPT® 74183) for any of the following:
 - Elevated liver function tests (usually >5X upper limit of normal)
 - Abnormalities seen on abdominal ultrasound or CT
- MRI Spine without and with contrast (Cervical-CPT® 72156, Thoracic-CPT® 72157, Lumbar-CPT® 72158) for ANY of the following **if PET/CT has not been performed**:
 - Vertebral lesions seen on skeletal survey
 - Clinical symptoms (including back pain) suggesting spinal involvement and negative skeletal survey

LCH Treatment Response:

- Both PET/CT and CT with contrast or MRI without and with contrast **only** for simultaneous treatment response evaluation with specific documentation showing that both are necessary (i.e. not for purpose of acquiring a PET/MRI)
- CT and/or MRI and/or PET/CT (if modality showed disease at initial diagnosis):
 - After 2-3 cycles of treatment
 - At completion of therapy (approximately 12 weeks) for individuals with persistent disease on cycle 2-3 imaging
 - After surgical curettage (CT or MRI of involved area, not repeat PET)
 - After radiation therapy
- Following the initial phase, treatment response evaluation of **involved sites** with CT with contrast or MRI with and without contrast, every ~3 months while receiving active treatment and at completion of therapy.
 - PET/CT may be approved for inconclusive conventional imaging, if disease was previously only measured/measurable on PET/CT, or for change from active treatment to surveillance
 - Shorter interval imaging can be approved for documented signs or symptoms concerning for disease progression

LCH Surveillance Imaging:

- Surveillance imaging is determined by areas of disease involvement.
 - Bone involvement
 - Single site bone disease
 - CT or MRI contrast as requested of involved bony areas at 6 and 12 months after completion of therapy
 - Multifocal bone disease
 - CT or MRI contrast as requested of involved bony areas every 6 months for 2 years
 - PET/CT (CPT® 78815 or CPT® 78816) may be approved for CT or MRI inconclusive for recurrence or if disease was previously only measurable on PET.
 - Skull or craniofacial (including jaw) bone involvement should be imaged according to CNS involvement section below.
 - Pulmonary involvement
 - CT Chest with (CPT® 71260) **or** without contrast (CPT® 71250) every 6 months for the first 2 years post completion of therapy for any of the following:
 - Individuals with a history of pulmonary involvement
 - Individuals with new respiratory or chest symptoms
 - New findings on CXR

- CNS involvement
 - MRI Brain without and with contrast (CPT® 70553) at 6 weeks, and then every 6 months for 2 years after completion of all therapy for previously documented measurable intracranial lesions
 - If negative at that time, continued surveillance is indicated at 4, 7, and 10 years after completion of all planned therapy
 - If residual measurable intracranial lesions are present at 6 months, imaging can be repeated every 3 months until negative or unchanged on two consecutive studies, at which time the schedule in the previous bullet should begin
 - MRI Brain without and with contrast (CPT® 70553) for documented hypothalamic-pituitary dysfunction every 6 months for 2 years and at 4, 7, and 10 years after completion of all planned therapy
 - MRI at any time for worsening neurologic symptoms
 - Intraspinal lesions should be imaged according to the same guidelines as brain imaging using MRI without and with contrast of all involved spine levels
- Liver involvement
 - Individuals with a history of liver involvement may have ONE of the following every 6 months for 2 years after completion of all therapy:
 - Ultrasound Abdomen (CPT® 76700)
 - CT Abdomen with contrast (CPT® 74160)
 - MRI Abdomen with and without contrast (CPT® 74183)
- Suspected recurrence or inconclusive findings on any surveillance imaging
 - All imaging studies supported for initial workup may be approved, including whole-body PET/CT (CPT® 78816)

Background and Supporting Information

- This guideline may be used for all ages of individuals.
- LCH includes a heterogeneous group of disorders formerly known by other names, including histiocytosis X, eosinophilic granuloma, Letterer-Siwe Disease, Hand-Schuller-Christian Disease, and diffuse reticuloendotheliosis. LCH has a widely variable clinical presentation, ranging from single indolent lesions to disseminated multisystem disease.
- Most common sites of involvement are skin, bones, liver, lung, and pituitary, though other sites are possible.
- Individuals with localized or single site disease are often treated only with local therapies or observed, and should be imaged according to surveillance guidelines
- Individuals receiving systemic therapy will usually undergo treatment for ~12 months. Treatment response is assessed using any modalities showing disease at initial diagnosis after ~6 weeks of treatment.
- Skull or craniofacial (including jaw) bone involvement at diagnosis are at higher risk for CNS recurrence

- CNS LCH has a particularly high rate of refractory and recurrent disease, and requires longer imaging surveillance
- Liver involvement
 - Persistent liver involvement is rare, and imaging after completion of LCH therapy will be highly individualized depending on degree of liver dysfunction and plans for supportive therapy or liver transplant

Hemophagocytic Lymphohistiocytosis (HLH) (PEDONC-18.3)

ONCP.HC.0018.3.A

v2.0.2024

- As imaging for this condition is usually done on an urgent basis, ANY or ALL of the following may be approved for the initial evaluation of HLH include:
 - Ultrasound Abdomen (CPT® 76700)
 - CT Abdomen and/or Pelvis (contrast as requested)
 - MRI Abdomen (CPT® 74183) and/or Pelvis (CPT® 72197) without and with contrast
 - Chest x-ray
 - CT Chest with contrast (CPT® 71260)
 - MRI Brain without and with contrast (CPT® 70553)
 - CTA/MRA Head (CPT® 70496/CPT® 70544) may be approved as part of operative planning or image guidance
 - CT Sinus without or with contrast (CPT® 70486 or CPT® 70487) if clinical suspicion for sinus disease
- Whole-body PET/CT (CPT® 78816) for the purpose of identifying a site for tissue diagnosis of a primary source of infection or malignancy if conventional imaging has been completed and is unrevealing
 - If a malignancy is identified as the inciting factor for HLH, additional imaging decisions for that malignancy should be based on the appropriate diagnosis-specific guidelines

Background and Supporting Information

- There are no standard imaging studies required for the diagnosis and initial evaluation of HLH. Most cases are diagnosed with a combination of physical findings, laboratory testing, and bone marrow evaluation. Advanced imaging studies may be necessary to assess organ dysfunction as HLH commonly affects the liver, spleen, and bone marrow, and less commonly the kidneys, lungs, and brain
- It is NOT required to perform ultrasound or plain film in a stepwise fashion if CT or MRI is planned as individuals with HLH can deteriorate rapidly
- There is no established standard role for PET in the diagnosis or treatment response evaluation of HLH
 - Secondary HLH is very difficult to treat if the primary cause is not concurrently treated

Non-Langerhans Cell Histiocytoses (PEDONC-18.4)

ONCP.HC.0018.4.A

v2.0.2024

Juvenile Xanthogranuloma (JXG):

- Skin and/or cervical nodes:
 - CT with contrast of appropriate area
- Systemic JXG with multi-organ involvement:
 - MRI Brain (CPT® 70553) **and/or** Orbits (CPT® 70543) without and with contrast
 - CT Neck (CPT® 70491), Chest (CPT® 71260), **and/or** Abdomen (CPT® 74160) with contrast
 - CTA/MRA Head (CPT® 70496/CPT® 70544) may be approved as part of operative planning or image guidance
- There is no established role for PET in the diagnosis or treatment of JXG

Rosai-Dorfman Disease (RDD):

- RDD Initial Imaging Studies:
 - MRI Brain (CPT® 70553) and/or Orbits (CPT® 70543) without and with contrast
 - CTA/MRA Head (CPT® 70496/CPT® 70544) may be approved as part of operative planning or image guidance
 - CT Neck (CPT® 70491), Chest (CPT® 71260) and/or Abdomen/Pelvis (CPT® 74177) with contrast **if PET/CT not performed** or to follow up unclear findings in said body areas on PET/CT
 - CT Sinus without or with contrast (CPT® 70486 or CPT® 70487) if clinical suspicion for sinus disease and **PET/CT not performed** or to follow up unclear sinus findings on PET/CT
 - Whole-body PET/CT (CPT® 78816) after histologic confirmation of diagnosis
- RDD Treatment Response:
 - Treatment response imaging can be approved after 2-3 cycles of systemic therapy during active treatment using any modalities showing disease at diagnosis, including PET/CT.
 - Once PET/CT is negative, conventional imaging with other modalities that revealed disease at presentation may be approved for subsequent restaging at completion of chemotherapy and/or radiation and/or after surgical resection.
- RDD Surveillance Imaging:
 - PET/CT is indicated every 6 months until stabilization of disease (two PET/CT with stable disease status).

- Further surveillance imaging can be approved every 3 months for the first year after completion of treatment, then every 6 months using any modalities showing disease at initial diagnosis excluding PET-CT.
 - PET/CT is not supported for routine surveillance of RDD but can be approved if conventional imaging is inconclusive for suspected recurrence.

Erdheim-Chester Disease (ECD):

- ECD Initial Imaging Studies:
 - PET/CT Whole Body (CPT® 78816)
 - Nuclear bone scan (See: **PEDONC-1.3: Modality General Considerations**) may be approved in lieu of PET if requested
 - MRI Brain (CPT® 70553) **and/or** Orbits (CPT® 70543) without and with contrast is indicated for CNS symptoms, including diabetes insipidus
 - CTA/MRA Head (CPT® 70496/70544) may be approved as part of operative planning or image guidance
 - CT Neck (CPT® 70491), Chest (CPT® 71260) **and/or** Abdomen/Pelvis (CPT® 74177) with contrast **if PET/CT not performed** or if inconclusive findings in said body area on PET/CT
 - Cardiac MRI without and with contrast (CPT® 75561) for clinically suspected cardiac involvement
 - CT Sinus without or with contrast (CPT® 70486 or CPT® 70487) if clinical suspicion for sinus disease **if PET/CT not performed** or inconclusive sinus findings on PET/CT
- ECD Treatment Response:
 - Treatment response imaging every 3 months during active treatment using any modalities showing disease at initial diagnosis, including PET/CT
 - Once PET/CT shows no remaining FDG-avid lesions, additional PET imaging is only indicated when conventional imaging studies are inconclusive and acute treatment decisions will be made based on PET results.
- ECD Surveillance Imaging:
 - CT **and/or** MRI **and/or** Nuclear bone scan **and/or** CTA **and/or** MRA **and/or** Cardiac MRI (if modality showed disease at initial diagnosis) every 3 months until the first year after completion of treatment and then every 6 months
 - PET/CT if conventional imaging is inconclusive for suspected recurrence.

Background and Supporting Information

- Non-Langerhans Cell histiocytoses includes diagnoses such as juvenile xanthogranuloma (JXG), sinus histiocytosis with lymphadenopathy (Rosai-Dorfman Disease, RDD), and Erdheim-Chester Disease (ECD)
- In general, these are localized cutaneous or nodal disease without need for regular advanced imaging, but important exceptions are listed in this section.
- Juvenile Xanthogranuloma (JXG):

- Generally involves only skin or cervical nodes, and involutes spontaneously
- Rosai-Dorfman Disease (RDD):
 - Characterized by bulky adenopathy (usually cervical) with frequent systemic involvement
 - There is no established role for PET in the diagnosis or treatment of RDD
 - Because of the paucity of evidence for PET, PET/CT should not be used to replace tissue confirmation for any clinical scenario in RDD
 - There is no established role for routine surveillance imaging of asymptomatic individuals after treatment for RDD
- Erdheim-Chester Disease (ECD):
 - An aggressive histiocytic disorder with overall poor prognosis that is characterized by long bone involvement with frequent spread to multiple organs
 - Most individuals will receive systemic therapy
 - Once PET/CT shows no remaining FDG-avid lesions, additional PET imaging is not indicated unless conventional imaging studies are inconclusive and acute treatment decisions will be made based on PET results.

References (PEDONC-18)

v2.0.2024

1. McClain KL, Allen CE, Hicks MJ. Histiocytic diseases. In: Pizzo PA, Poplack DG, eds. Principles and Practice of Pediatric Oncology. 7th ed. Philadelphia, PA: Wolters Kluwer; 2016:617-627.
2. Degar BA, Fleming MD, Rollins BJ, et al. Histiocytoses. In: Orkin SH, Fisher DE, Ginsburg D, Look AT, Lux SE, Nathan DG, eds. Nathan and Oski's Hematology and Oncology of Infancy and Childhood. 8th ed. Philadelphia, PA: Elsevier Saunders; 2015:2100-2122.
3. Haupt R, Minkov M, Astigarraga I, et al. Langerhans cell histiocytosis (LCH): guidelines for diagnosis, clinical work-up, and treatment for patients till the age of 18 years. *Pediatr Blood Cancer*. 2013;60(2):175-184. doi:10.1002/pbc.24367.
4. Chandrakasan S, Filipovich AH. Hemophagocytic Lymphohistiocytosis: advances in pathophysiology, diagnosis, and treatment. *J Pediatr*. 2013;163(5):1253-1259. doi:10.1016/j.jpeds.2013.06.053.
5. Phillips M, Allen C, Gerson P, et al. Comparison of FDG-PET scans to conventional radiography and bone scans in management of Langerhans cell histiocytosis. *Pediatr Blood Cancer*. 2009;52(1):97-101. doi:10.1002/pbc.21782.
6. Chellapandian D, Shaiki F, van den Bos C, et al. Management and outcome of patients with langerhans cell histiocytosis and single-bone CNS-risk lesions: a multi-institutional retrospective study. *Pediatr Blood Cancer*. 2015;62(12):2162-2166. doi:10.1002/pbc.25645.
7. Allen CE, Ladisch S, McClain KL. How I treat Langerhans cell histiocytosis. *Blood*. 2015;126(1):26-35. doi:10.1182/blood-2014-12-569301.
8. Schram AM, Berliner N. How I treat Hemophagocytic lymphohistiocytosis in the adult patient. *Blood*. 2015;125(19):2908-2914. doi:10.1182/blood-2015-01-551622.
9. Weitzman S, Jaffe R. Uncommon histiocytic disorders: the non-Langerhans cell histiocytoses. *Pediatr Blood Cancer*. 2005;45(3):256-264. doi:10.1002/pbc.20246.
10. Diamond EL, Dagna L, Hyman DM, et al. Consensus guidelines for the diagnosis and clinical management of Erdheim-Chester disease. *Blood*. 2014;124(4):483-492. doi:10.1182/blood-2014-03-561381.
11. Go RS, Jacobsen E, Baiocchi R, et al. National Comprehensive Cancer Network (NCCN) Guidelines Version 1.2023 – August 11, 2023. Histiocytic Neoplasms, available at: https://www.nccn.org/professionals/physician_gls/pdf/histiocytic_neoplasms.pdf Referenced with permission from the NCCN Clinical Practice Guidelines in Oncology (NCCN Guidelines™) for Histiocytic Neoplasms V1.2023 –August 11, 2023. ©2023 National Comprehensive Cancer Network, Inc. All rights reserved. The NCCN Guidelines™ and illustrations herein may not be reproduced in any form for any purpose without the express written permission of the NCCN. To view the most recent and complete version of the NCCN Guidelines™, go online to NCCN.org.
12. Salama HA, Jazieh AR, Alhejazi AY, et al. Highlights of the management of adult histiocytic disorders: Langerhans cell histiocytosis, Erdheim-Chester disease, Rosai-Dorfman disease, and hemophagocytic lymphohistiocytosis. *Clinical Lymphoma, Myeloma & Leukemia*. 2020;21(1):e66-75. doi:10.1016/j.dml.2020.08.007.
13. Goyal G, Young JR, Koster MJ, et al. The Mayo Clinical Histiocytosis Working Group consensus statement for the diagnosis and evaluation of adult patients with histiocytic neoplasms: Erdheim-Chester disease, Langerhans cell histiocytosis, and Rosai-Dorfman disease. *Mayo Clinical Proc*. 2019;94(10):2054-2071. doi:10.1016/j.mayocp.2019.02.023.
14. Allen CE, Merad M, McClain KL. Langerhans-Cell histiocytosis. *N Engl J Med*. 2018;379:856-68. doi:10.1056/NEJMra1607548.
15. Ablu O, Jacobsen E, Picarsic J, et al. consensus recommendations for the diagnosis and clinical management of Rosai-Dorfman-Destombes disease. *Blood*. 2018;131(26):2877-2890. doi:10.1182/blood-2018-03-839753.
16. Ferrell J, Sharp S, Kumar A, Jordan M, Picarsic J, Nelson A. Discrepancies between F-18-FDG PET/CT findings and conventional imaging in Langerhans cell histiocytosis. *Pediatr Blood Cancer*. 2021;68(4):e28891. doi:10.1002/pbc.28891.
17. Campbell KM, Shulman DS, Grier HE, DuBois SG. Role of bone marrow biopsy for staging new patients with Ewing sarcoma: A systematic review. *Pediatr Blood Cancer*. 2021 Feb;68(2):e28807. doi:10.1002/pbc.28807. Epub 2020 Nov 21. PMID: 33219750.

Long Term Pediatric Cancer Survivors (PEDONC-19)

Guideline

Long Term Pediatric Cancer Survivors – General Considerations
(PEDONC-19.1)

Cardiotoxicity and Echocardiography (PEDONC-19.2)

Second Malignant Neoplasms (SMN) (PEDONC-19.3)

Osteonecrosis in Long Term Cancer Survivors (PEDONC-19.4)

CNS vascular changes in pediatric cancer survivors following CNS
radiation (PEDONC-19.5)

References (PEDONC-19)

Long Term Pediatric Cancer Survivors – General Considerations (PEDONC-19.1)

ONCP.CS.0019.1.A
v2.0.2024

- This section applies to individuals who have passed the end of the surveillance imaging period for their specific cancer, or 5 years after completion of therapy, whichever occurs first
- As these are long-term survivors, many individuals falling under this guideline section will have reached adult age. However, these guidelines relate specifically to late effects of childhood cancer treatment and should be applied to all long term childhood cancer survivors regardless of current age
- The Children’s Oncology Group has published comprehensive guidelines for the management of long-term childhood cancer survivors, and these are available at: <http://www.survivorshipguidelines.org>
- A summary of cancer treatment should be available for all individuals in this category and should generally include, at minimum:
 - Type of cancer and stage
 - Dates of diagnosis, recurrence, cancer-related surgeries, beginning and end dates of chemotherapy, radiotherapy, and/or stem cell transplant
 - Protocol number used for treatment and cumulative chemotherapy drug dose exposures
 - Cumulative radiation dose, fraction number, modality, and field exposure
- Annual detailed history and complete physical examination is a critical component of cancer survivorship care and along with laboratory testing serves as the primary method of screening for the majority of late effects
- Advanced imaging for asymptomatic screening is not routinely indicated except as specified in this section
- Imaging requests related to new clinical signs or symptoms in a long term cancer survivor not explicitly covered in this section should be reviewed according to the guideline for the individual’s cancer type or the relevant non-malignant clinical problem

Cardiotoxicity and Echocardiography (PEDONC-19.2)

ONCP.CS.0019.2.A

v2.0.2024

- Screening echocardiography (CPT® 93306, CPT® 93307, or CPT® 93308) for life after exposure to anthracycline chemotherapy, cardiotoxic immunotherapy, or cardiac exposure to radiotherapy

SCREENING ECHOCARDIOGRAM INDICATIONS			
Age at time of Exposure	Cumulative Doxorubicin Equivalent Dose	Cumulative radiation dose to cardiac muscle	Echocardiogram frequency
All ages	None	None	None
0-0.99 years	≥250 mg/m ²	None	Annual
	0-249 mg/m ²	Any dose	Annual
	0-249 mg/m ²	None	Every 2 years
1-4.99 years	≥250 mg/m ²	Any dose	Annual
	0-249 mg/m ²	15+ Gy	Annual
		0-14.99 Gy	Every 2 years
	None	35+ Gy	Annual
		15-34.99 Gy	Every 2 years
		0-14.99 Gy	Every 5 years
5+ years	≥250 mg/m ²	Any dose	Every 2 years
	0-249 mg/m ²	15+ Gy	Every 2 years
		0-14.99 Gy	Every 5 years
	None	35+ Gy	Every 2 years
		15-34.99 Gy	Every 5 years
		0-14.99 Gy	None
All ages with known ventricular dysfunction			Annual

- Stress echocardiography is not indicated as a screening study for anthracyclines cardiotoxicity in the absence of coronary artery disease symptoms. See: **Stress Testing with Imaging – Indications (CD-1.4)** for imaging guidelines.
- Female cancer survivors who are pregnant or planning to become pregnant:
 - If any of the following are present, echocardiogram is recommended as a baseline exam and in the 3rd trimester, and as clinically indicated for symptoms

(see: **Pregnancy – Maternal Imaging (CD-11.4)** in the Cardiology Imaging Guidelines) if ANY of the following are present:

- Anthracycline or cardiotoxic chemotherapy/immunotherapy exposure
- Chest radiotherapy

Background and Supporting Information

- Exposure to cardiotoxic anthracycline chemotherapy agents is common in pediatric oncology due to the high success rate of this drug class in the treatment of pediatric cancers.
- Cardiac risk is assessed based on the age of the individual at the time of treatment initiation, the cumulative drug exposure expressed as doxorubicin equivalent mg/m², and the presence or absence of radiotherapy exposure to cardiac muscle.

Second Malignant Neoplasms (SMN) (PEDONC-19.3)

ONCP.CS.0019.3.A

v2.0.2024

SMN—Breast Cancer

Clinical breast exam every 6 months supplemented with:

- MRI Breast (CPT® 77049) annually and annual mammogram beginning at age 25 or 8 years after completion of radiotherapy (whichever occurs later- screening breast MRI is not supported prior to age 25) for individuals who received therapeutic radiation exposure in the following fields while they were under 30 years of age:
 - Chest (thorax)
 - Whole lung
 - Mediastinal
 - Axilla
 - Mini-mantle, mantle, or extended mantle
 - Total (TLI) or subtotal (SLTI) lymphoid irradiation
 - Total body irradiation (TBI)

SMN – CNS Tumors

- Routine surveillance of asymptomatic individuals with normal neurologic exams is not supported by evidence, with the exception of NF1 and NF2 below:
 - MRI Brain without and with contrast (CPT® 70553) can be approved every 2 years after completion of radiotherapy for individuals with NF1 or NF2
- MRI Brain without and with contrast (CPT® 70553) for any individual with history of brain radiotherapy and new neurologic symptoms, including simple headache
- MRI Cervical (CPT® 72156), Thoracic (CPT® 72157), and Lumbar Spine (CPT® 72158) without and with contrast for any individual with history of spine radiotherapy and new neurologic symptoms including change in quality of pain
 - MRI Spine can be performed with contrast only (Cervical-CPT® 72142, Thoracic-CPT® 72147, Lumbar-CPT® 72149) if being performed immediately following a contrast-enhanced MRI Brain
- MRI Brain without and with contrast (CPT® 70553) annually for individuals with history of brain radiotherapy and persistent neurologic symptoms
- MRI Cervical (CPT® 72156), Thoracic (CPT® 72157), and Lumbar Spine (CPT® 72158) without and with contrast annually for individuals with history of spine radiotherapy and persistent neurologic symptoms
 - MRI Spine can be performed with contrast only (Cervical-CPT® 72142, Thoracic-CPT® 72147, Lumbar-CPT® 72149) if being performed immediately following a contrast-enhanced MRI Brain

SMN—Colorectal Cancer

- No advanced imaging is currently recommended. See: **Background and Supporting Information** section for recommended surveillance

Background and Supporting Information

- SMN—Breast Cancer:
 - Clinical breast exam every 6 months supplemented with advanced imaging
- SMN-CNS Tumors:
 - These are associated with radiation exposure to the brain and with neurofibromatosis
 - Routine surveillance of asymptomatic individuals with normal neurologic exams is not supported by evidence, with the exception of NF1 and NF2 listed above
- SMN—Colorectal Cancer:
 - Colonoscopy is recommended every 5 years beginning at age 30 or 5 years after radiation exposure (whichever is later) for individuals with ≥ 30 Gy radiation exposure to the following fields:
 - Thoracic, Lumbar, Sacral, or Whole Spine
 - Abdomen
 - Pelvis
 - Total body irradiation (TBI)
 - Colonoscopy is also recommended every 5 years beginning at age 30 or 5 years after radiation exposure (whichever is later) for individuals with:
 - Personal history of ulcerative colitis, GI malignancy, adenomatous polyps, or hepatoblastoma
 - Familial polyposis
 - Family history of colorectal cancer or polyps in a first degree (parent or sibling) relative
 - While the American Cancer Society recently added computed tomographic colonography (CTC) (AKA “Virtual Colonoscopy”) as an acceptable option for colorectal cancer screening of average-risk adults, the National Comprehensive Cancer Network and United States Preventive Services Task Force concluded that data was too premature to warrant its use in screening. Colonoscopy remains the preferred screening modality for survivors at highest risk of colorectal cancer

Osteonecrosis in Long Term Cancer Survivors (PEDONC-19.4)

ONCP.CS.0019.4.A

v2.0.2024

Osteonecrosis is associated with corticosteroid, chemotherapy, and radiation exposure during treatment for ALL, NHL, and allogeneic HSCT in pediatrics. Osteonecrosis occurs primarily in hips, knees, and ankles and is frequently multifocal.

Osteoradionecrosis of the jaw can occur in individuals receiving radiotherapy to the mandible or maxilla; those receiving ≥ 40 Gy are at highest risk. Although unusual, it can also occur in any bone without symptoms. It is rare in other disease types.

- Plain films of symptomatic areas are indicated prior to advanced imaging.
- Routine bone density screening using DEXA or Quantitative CT screening has not been well normalized in the pediatric population, but imaging can be approved for those with symptoms to suggest bone density issues
 - DEXA or Quantitative CT screening is generally not recommended until age 18 unless a surgery, core decompression, or initiation of osteoporosis drugs will be planned based on the imaging results.
- Serial advanced imaging is not indicated in osteonecrosis without specific documentation regarding how the advanced imaging will change current individual management
 - When advanced imaging is necessary for acute management decisions, MRI without contrast of the affected area(s) can be approved.
 - Surveillance imaging of asymptomatic individuals to detect osteonecrosis has not been shown to impact individual outcomes, and it is not standard to alter treatment based on imaging findings alone without symptoms.
 - Follow up MRI of incidentally discovered osteonecrosis findings in asymptomatic individuals has not been shown to impact individual outcomes and is not necessary
 - For known osteonecrosis with articular collapse on other imaging, CT without contrast of area of interest is indicated for surgical planning
- See: **Acute Lymphoblastic Leukemia (ALL) (PEDONC-3.2)** for information on imaging osteonecrosis in ALL individuals during active treatment.

CNS vascular changes in pediatric cancer survivors following CNS radiation (PEDONC-19.5)

ONCP.CS.0019.5.A
v2.0.2024

Children receiving cranial radiation are at increased risk of cerebrovascular complications, including: hemorrhagic and ischemic stroke, moyamoya, occlusive vasculopathy, and cavernomas. These complications may occur months to years after radiation exposure.

- MRI Brain without and with contrast (CPT® 70553) and MRA Head (CPT® 70544, 70545, or 70546) for all individuals of any age with new neurologic symptoms or headache and a history of cranial irradiation.
- MRI Brain without and with contrast (CPT® 70553) and MRA Head (CPT® 70544, 70545, or 70546) may be approved annually for 10 years post treatment in individuals with a history of cranial irradiation and any of the following additional risk factors:
 - Down Syndrome, Sickle cell disease, or Neurofibromatosis 1 or 2
 - Parasellar or suprasellar tumors (i.e. craniopharyngioma)
 - Radiation dose >50 Gy
 - Radiation field involving Circle of Willis

References (PEDONC-19)

v2.0.2024

1. Landier W, Armenian SH, Meadows AT, et al. Late effects of childhood cancer and its treatment. In: Pizzo PA, Poplack DG, eds. *Principles and Practice of Pediatric Oncology*. 7th ed. Philadelphia, PA: Wolters Kluwer; 2016:1173-1196.
2. Vrooman L, Diller L, and Kenney LB. Childhood cancer survivorship. In: Orkin SH, Fisher DE, Ginsburg D, Look AT, Lux SE, Nathan DG, eds. *Nathan and Oski's Hematology and Oncology of Infancy and Childhood*. 8th ed. Philadelphia, PA: Elsevier Saunders; 2015:2397-2434.
3. Children's Oncology Group. Long-term follow up guidelines for survivors of childhood, adolescent and young adult cancers, version 5.0. Monrovia, CA: Children's Oncology Group; October 2018; Available online: www.survivorshipguidelines.org
4. Ryerson AB, Border WL, Wasilewski-Masker K, et al. Assessing anthracycline-treated childhood cancer survivors with advanced stress echocardiography. *Pediatr Blood Cancer*. 2015;62(3):502-508. doi:10.1002/pbc.25328.
5. Tieu MT, Cigsar C, Ahmed S, et al. Breast cancer detection among young survivors of pediatric Hodgkin lymphoma with screening magnetic resonance imaging. *Cancer*. 2014;120(16):2507-2513. doi:10.1002/cncr.28747.
6. Lange JM, Takashima JR, Peterson SM, Kalapurakal JA, Green DM, Breslow NE. Breast cancer in female survivors of Wilms tumor: a report from the national Wilms tumor late effects study. *Cancer*. 2014;120(23):3722-3730. doi:10.1002/cncr.28908.
7. Bevers TB, Helvie M, Bonaccio E, et al. National Comprehensive Cancer Network (NCCN) Guidelines Version 1.2023—June 19, 2023, Breast Cancer Screening and Diagnosis, available at: https://www.nccn.org/professionals/physician_gls/pdf/breast-screening.pdf, Referenced with permission from the NCCN Clinical Practice Guidelines in Oncology (NCCN Guidelines™) for Breast Cancer Screening and Diagnosis V1.2023 06/19/2023. ©2023 National Comprehensive Cancer Network, Inc. All rights reserved. The NCCN Guidelines™ and illustrations herein may not be reproduced in any form for any purpose without the express written permission of the NCCN. To view the most recent and complete version of the NCCN Guidelines™, go online to NCCN.org.
8. Recht M, Mostoufi-Moab S, McFadden J, et al. Bone health in pediatric hematology-oncology. In: American Society of Pediatric Hematology/Oncology Annual Meeting. Chicago; 2014.
9. Bhatia S, Armenian SH, Armstrong GT, et al. Collaborative research in childhood cancer survivorship: the current landscape. *J Clin Oncol*. 2015;33(27):3055-3064. doi:10.1200/JCO.2014.59.8052.
10. Chavhan GB, Babyn PS, Nathan PC, Kaste SC. Imaging of acute and subacute toxicities of cancer therapy in children. *Pediatr Radiol*. 2016;46(1):9-20. doi:10.1007/s00247-015-3454-1.
11. Karol SE, Mattano LA, Yang W, et al. Genetic risk factors for the development of osteonecrosis in children under age 10 treated for acute lymphoblastic leukemia. *Blood Journal*. 2016;127(5):558-564. doi:10.1182/blood-2015-10-673848.
12. Marcucci G, Beltrami G, Tamburini A, et al. Bone health in childhood cancer: review of the literature and recommendations for the management of bone health in childhood cancer survivors. *Ann Oncol*. 2019;30:908-920. doi:10.1093/annonc/mdz120.
13. Sanders LM, Sharma S, El Madany M, King AB, Goodman KS, Sanders AE. Clinical breast concerns in low-risk pediatric patients: practice review with proposed recommendations. *Pediatr Radiol*. 2018(48):186-195. doi:10.1007/s00247-017-4007-6.
14. Murphy ES, Xie H, Merchant TE, Yu JS, Chao ST, Suh JH. Review of cranial radiotherapy-induced vasculopathy. *J Neurooncol*. 2015;122(3):421-9. doi:10.1007/s11060-015-1732-2. Epub 2015 Feb 12.
15. Baumgartner JE, Ater JL, Ha CS, et al. Pathologically proven cavernous angiomas of the brain following radiation therapy for pediatric brain tumors. *Pediatr Neurosurg*. 2003;39(4):201-7. doi:10.1159/000072472.
16. Di Giannatale A, Morana G, Rossi A, et al. Natural history of cavernous malformations in children with brain tumors treated with radiotherapy and chemotherapy. *J Neurooncol*. 2014;117(2):311-20. doi:10.1007/s11060-014-1390-9. Epub 2014 Feb 11.
17. Bowers DC, Liu Y, Leisenring W, et al. Late-occurring stroke among long-term survivors of childhood leukemia and brain tumors: a report from the Childhood Cancer Survivor Study. *J Clin Oncol*. 2006;24:5277-5282.
18. Morris B, Partap S, Yeom K, Gibbs IC, Fisher PG, King AA. Cerebrovascular disease in childhood cancer survivors: a Children's Oncology Group report. *Neurology*. 2009;73:1906-1913
19. Laitt RD, Chambers EJ, Goddard PR, Wakeley CJ, Duncan AW, Foreman NK. Magnetic resonance imaging and magnetic resonance angiography in long term survivors of acute lymphoblastic leukemia treated with cranial irradiation. *Cancer*. 1995;76:1846-1852

20. Gastelum E, Sear K, Hills N, et. al. Rates and characteristics of radiographically detected intracerebral cavernous malformations after cranial radiation therapy in pediatric cancer patients. *J Child Neurol.* 2015;30(7):842–849. doi:10.1177/0883073814544364.
21. ACR-ASNR-SPR Practice Parameter for the Performance and Interpretation of Cervicocerebral Computed Tomography (CTA). (Resolution 42). 2020.
22. Rao SS, El Abiad JM, Puvanesarajah V, Levin AS, Jones LC, Morris CD. Osteonecrosis in pediatric cancer survivors: epidemiology, risk factors, and treatment. *Surgical Oncology.* 2019;28:214-221. doi:10.1016/j.suronc.2019.02.001.
23. Nordstrom M, Felton E, Sear K, et. al. Large vessel arteriopathy after cranial radiation therapy in pediatric brain tumor survivors. *J Child Neurol.* 2018;33(5):359-366. doi:10.1177/0883073818756729.
24. Ha AS, Chang EY, Bartolotta RJ, et. al. Expert Panel on Musculoskeletal Imaging. ACR Appropriateness Criteria® Osteonecrosis. *Am Coll Radiol (ACR)*; Date of Origin: 2016. Revised: 2022. <https://acsearch.acr.org/docs/69402/Narrative/>.

Hematopoietic Stem Cell Transplantation (HSCT) (PEDONC-20)

Guideline

General Considerations (PEDONC-20.0)

Pre-Transplant Imaging (PEDONC-20.1)

Post-Transplant Imaging (PEDONC-20.2)

References (PEDONC-20)

General Considerations (PEDONC-20.0)

ONCP.HT.0020.0.A

v2.0.2024

Transplant Types:

- Allogeneic (“allo”): The donor and recipient are different people, and there are multiple types depending on the source of the stem cells and degree of match between donor and recipient. This is most commonly used in diseases originating in the hematopoietic system, such as leukemias and lymphomas, and bone marrow failure syndromes or metabolic disorders. **The goal is to replace the hematopoietic and immune system with healthy donor cells to treat the disease.** Common types are:
 - Matched sibling donor (MSD or MRD): Donor and recipient are full siblings and HLA-matched
 - Matched unrelated donor (MUD): Donor and recipient are HLA matched but not related to each other
 - Cord blood: Donor stem cells come from frozen umbilical cord blood not related to the recipient, sometimes from multiple different donors at once
 - Haploidentical transplant (haplo): Donor is a half-HLA match to the recipient, usually a parent
- Autologous (“auto”): The donor and recipient are the same person. The process involves delivery of high dose chemotherapy that is ablative to the bone marrow, followed by an infusion of one’s own harvested stem cells. This is primarily done in the context of solid tumors and the stem cells mainly rescue hematopoiesis to facilitate high-dose chemotherapy.
- Allogeneic HSCT results in a much greater degree of immunosuppression than autologous HSCT because of the need to allow the new immune system to chimerize with the recipient’s body. Immune reconstitution commonly takes more than a year for individuals who receive allogeneic HSCT, and individuals remain at high risk for invasive infections until that has occurred. In addition, patients may require prolonged immunosuppression for prevention and management of graft-vs-host disease.
- Recipients of autologous transplant are deeply immunosuppressed until complete count recovery, which may take several months. Graft-vs-host disease is not a consideration in auto transplants because the host is also the donor.

Pre-Transplant Imaging (PEDONC-20.1)

ONCP.HT.0020.1.A

v2.0.2024

- Disease status assessment may be approved per individual disease guidelines if it has been 6 weeks or more between end of treatment imaging and HSCT or if there are signs and symptoms of disease progression.

Indication	Imaging
Immediate pre-transplant period - screening for active or occult infection	<ul style="list-style-type: none"> • CT Chest with or without contrast (CPT® 71250 or CPT® 71260) • CT Abdomen with contrast (CPT® 74160) is supported for asymptomatic individuals if chest infection or disease is identified on CT Chest or for signs and symptoms of active abdominal infection including fever. • CT Pelvis is not routinely recommended for screening asymptomatic individuals, but may be approved for pelvic signs and symptoms with CPT® 74177 or CPT® 72193 if abdominal imaging has already been performed. • CT Sinus (CPT® 70486) is not recommended for screening prior to HSCT, but is indicated for signs or symptoms of infectious or disease involvement of the sinuses
Individuals at risk of developing VOD, for pre-transplant baseline	<ul style="list-style-type: none"> • Abdominal ultrasound +/- Doppler (CPT® 76700 or 76705 +/- 93975)
Individuals with history of multiple blood transfusions at risk of iron overload, for iron quantification baseline	<ul style="list-style-type: none"> • CPT® codes as listed in <u>Transfusion-Associated (Secondary) Hemochromatosis (PEDAB-18.2)</u> may be approved in the immediate pre-transplant period even if done in the previous 12 months.
Suspected renal tubular dysfunction	<ul style="list-style-type: none"> • Nuclear renal imaging (CPT® 78700, CPT® 78701, CPT® 78707, CPT® 78708, CPT® 78709)

Background and Supporting Information

- CT Sinus screening is not routinely recommended as two studies showed no utility and no effect on surgical consults.
- Changes from baseline abdominal ultrasound with regard to veno-occlusive disease (VOD) are more predictive than absolute measurements and thus baseline imaging is supported.
- Pre-transplant liver and cardiac iron levels are associated with adverse transplant outcomes and a baseline is supported for further management.

Post-Transplant Imaging (PEDONC-20.2)

ONCP.HT.0020.2.A

v2.0.2024

Early post-transplant complication (<100 days post HSCT):

Indication	Imaging
For signs and symptoms of pulmonary infection or pulmonary edema or new CXR abnormalities	<ul style="list-style-type: none"> CT Chest without or with contrast (CPT® 71250 or CPT® 71260) PET/CT requests to clarify infection vs malignancy, see disease-specific guidelines for equivocal conventional imaging
Suspected impending lung necrosis on other imaging	<ul style="list-style-type: none"> MRI Chest with and without contrast (CPT® 71552)
<ul style="list-style-type: none"> EITHER of the following: <ul style="list-style-type: none"> Suspected graft vs. host disease (GVHD) of chest Bronchiolitis Obliterans (BOOP/BOS) 	<ul style="list-style-type: none"> High-resolution CT Chest without contrast (CPT® 71250)
<ul style="list-style-type: none"> ANY of the following: <ul style="list-style-type: none"> Suspected intra-abdominal and or pelvic infection (including cystitis or typhlitis) Suspected small bowel GVHD 	<ul style="list-style-type: none"> Abdominal Ultrasound (CPT® 76700 or CPT® 76705) +/- Pelvic Ultrasound (CPT® 76856 or CPT® 76857) CT Abdomen and Pelvis with contrast (CPT® 74177) may be approved for unclear findings on ultrasound
High clinical suspicion for intra-abdominal fungal infection	<ul style="list-style-type: none"> CT Abdomen and Pelvis with contrast (CPT® 74177)
Suspected hepatic veno-occlusive disease (VOD)	<ul style="list-style-type: none"> Ultrasound elastography (CPT® 91200) or Abdominal Ultrasound with Doppler (CPT® 76700 or CPT® 76705)

Indication	Imaging
Suspected CNS complication including infection, hemorrhage, thrombosis, or encephalopathy	<ul style="list-style-type: none"> • MRI Brain without or with and without contrast (CPT® 70551 or CPT® 70553) • CT Head without contrast (CPT® 70450) may be approved in the emergent setting or for suspected acute hemorrhage <ul style="list-style-type: none"> • Acute CT should not preclude subsequent MRI imaging • For additional imaging for suspected stroke, see: <u>Pediatric Stroke Initial Imaging (PEDHD-12.2)</u> in the Pediatric Head Imaging guidelines
Suspected musculoskeletal abscess or necrotizing fasciitis	<ul style="list-style-type: none"> • See: <u>Pediatric Infection/Osteomyelitis (PEDMS-8)</u> in the Pediatric Musculoskeletal Imaging guidelines
Fever of unknown origin (8 or more days of temperature 38.0 C/100.4 F or higher)	<ul style="list-style-type: none"> • PET/CT skull to thigh (CPT® 78815) is indicated if site-specific conventional imaging, microbiologic serologic studies, echocardiogram, urinalysis, and urine culture are all non-diagnostic

Late post-transplant complication imaging (100 or more days post HSCT):

Indication	Imaging
CNS complications	Same imaging as for early post-transplant
Chest complications	Same imaging as for early post-transplant
Hepatic VOD	Same imaging as for early post-transplant
Chronic GI GVHD	<ul style="list-style-type: none"> • CT Abdomen and Pelvis (CPT® 74177) • MR Enterography (CPT® 74183 and CPT® 72197) may be approved for suspected small bowel GVHD
Suspected renal tubular dysfunction	<ul style="list-style-type: none"> • Nuclear renal imaging (CPT® 78700, CPT® 78701, CPT® 78707, CPT® 78708, CPT® 78709)

Indication	Imaging
Suspected poor bone mineral density or osteonecrosis	See: <u>Osteonecrosis in Long Term Cancer Survivors (PEDONC-19.4)</u>
Suspected PTLD	See: <u>Post-Transplant Lymphoproliferative Disorder (PTLD) (PEDONC 5.3)</u>

References (PEDONC-20)

v2.0.2024

1. Chan SS, Coblenz A, Bhatia A, et. al. Imaging of pediatric hematopoietic stem cell transplant recipients: A COG Diagnostic Imaging Committee/SPR Oncology Committee white paper. *Pediatr Blood Cancer*. 2023;70 Suppl 4:e30013. doi: 10.1002/pbc.30013.
2. Kaste SC, Kaufman RA, Sunkara A, et. al. Routine pre- and post-hematopoietic stem cell transplant computed tomography of the abdomen for detecting invasive fungal infection has limited value. *Biol Blood Marrow Transplant*. 2015;21(6):1132-5. doi: 10.1016/j.bbmt.2015.02.023.
3. PDQ® Pediatric Treatment Editorial Board. PDQ Pediatric Hematopoietic Stem Cell Transplantation and Cellular Therapy for Cancer. Bethesda, MD: National Cancer Institute. Updated 02/04/2022. Available at: <https://www.cancer.gov/types/childhood-cancers/hp-stem-cell-transplant>.

Table of Contents

Guideline

- General Guidelines (PEDPV-1)
- Abnormal Uterine Bleeding (PEDPV-2)
- Pelvic Inflammatory Disease (PID) (PEDPV-3)
- Amenorrhea (PEDPV-4)
- Endometriosis (PEDPV-5)
- Suspected Adnexal Mass (PEDPV-6)
- Pelvic Pain/Dyspareunia, and Ovarian Torsion (PEDPV-7)
- Polycystic Ovary Syndrome (PEDPV-8)
- Periurethral Cysts and Urethral Diverticula (PEDPV-9)
- Fetal MRI (PEDPV-10)
- Undescended Testis (PEDPV-11)
- Scrotal Pathology (PEDPV-12)
- Penis-Soft Tissue Mass (PEDPV-13)
- Incontinence (PEDPV-14)
- Patent Urachus (PEDPV-15)

General Guidelines (PEDPV-1)

Guideline

Procedure Codes Associated with Pelvis Imaging

General Guidelines (PEDPV-1.0)

Pediatric Pelvis Imaging Age Considerations (PEDPV-1.1)

Pediatric Pelvis Imaging Modality General Considerations (PEDPV-1.3)

References (PEDPV-1)

Procedure Codes Associated with Pelvis Imaging

PVP.GG.ProcedureCodes.A
v1.0.2024

MRI	CPT®
MRI Pelvis without contrast	72195
MRI Pelvis with contrast (rarely used)	72196
MRI Pelvis without and with contrast	72197
Unlisted MRI procedure (for radiation planning or surgical software)	76498

MRA	CPT®
MRA Pelvis	72198

CT	CPT®
CT Abdomen and Pelvis without contrast	74176
CT Abdomen and Pelvis with contrast	74177
CT Abdomen and Pelvis without and with contrast	74178
CT Pelvis without contrast	72192
CT Pelvis with contrast	72193
CT Pelvis without and with contrast	72194
CT Guidance for Needle Placement (Biopsy, Aspiration, Injection, etc.)	77012
CT Guidance for and monitoring of Visceral Tissue Ablation	77013
CT Guidance for Placement of Radiation Therapy Fields	77014
Unlisted CT procedure (for radiation planning or surgical software)	76497

CTA	CPT®
CTA Abdomen and Pelvis	74174
CTA Pelvis	72191

Nuclear Medicine	CPT®
PET Imaging; limited area (this code not used in pediatrics)	78811
PET Imaging: skull base to mid-thigh (this code not used in pediatrics)	78812
PET Imaging: whole body (this code not used in pediatrics)	78813

Nuclear Medicine	CPT®
PET with concurrently acquired CT; limited area (this code rarely used in pediatrics)	78814
PET with concurrently acquired CT; skull base to mid-thigh	78815
PET with concurrently acquired CT; whole body	78816
Urinary Bladder Residual Study	78730
Ureteral Reflux Study (Radiopharmaceutical Voiding Cystogram)	78740
Testicular Scan – Vascular Flow and Delayed Images	78761
Radiopharmaceutical Imaging of Lymphatic System	78195
Radiopharmaceutical Localization Imaging Limited area	78800
Radiopharmaceutical Localization Imaging Whole Body	78802
Radiopharmaceutical Localization Imaging SPECT	78803

Ultrasound	CPT®
Ultrasound, pelvic (nonobstetric), complete	76856
Ultrasound, pelvic transvaginal	76830
Ultrasound, pelvic (nonobstetric), limited or follow-up	76857
Ultrasound, scrotum and contents	76870
Duplex scan of arterial inflow and venous outflow of abdominal, pelvic, scrotal contents and/or retroperitoneal organs; complete study	93975
Duplex scan of arterial inflow and venous outflow of abdominal, pelvic, scrotal contents and/or retroperitoneal organs; limited study	93976
Duplex scan of aorta, inferior vena cava, iliac vasculature, or bypass grafts; complete	93978
Duplex scan of aorta, inferior vena cava, iliac vasculature, or bypass grafts; limited	93979
Duplex scan of arterial inflow and venous outflow of penile vessels; complete	93980
Duplex scan of arterial inflow and venous outflow of penile vessels; limited study	93981

General Guidelines (PEDPV-1.0)

PVP.GG.0001.0.A

v1.0.2024

- A pertinent clinical evaluation since the onset or change in symptoms, including a detailed history, physical examination, appropriate laboratory studies, and basic imaging such as plain radiography or ultrasound should be performed prior to considering advanced imaging (CT, MRI, Nuclear Medicine), unless the individual is undergoing guideline-supported scheduled imaging evaluation. A meaningful technological contact (telehealth visit, telephone call, electronic mail or messaging) since the onset or change in symptoms can serve as a pertinent clinical evaluation.
- Unless otherwise stated in a specific guideline section, the use of advanced imaging to screen asymptomatic individuals for disorders involving the pelvis is not supported. Advanced imaging of the pelvis is only indicated in individuals who have documented active clinical signs or symptoms of disease involving the pelvis.
- Unless otherwise stated in a specific guideline section, repeat imaging studies of the pelvis are not necessary unless there is evidence for progression of disease, new onset of disease, and/or documentation of how repeat imaging will affect individual management or treatment decisions.
- Ultrasound
 - Ultrasound should be the initial imaging in most pelvic conditions to rule out those situations that do not require additional advanced imaging.
 - For those individuals who do require advanced imaging after ultrasound, ultrasound can be very beneficial in selecting the proper modality, body area, image sequences, and contrast level that will provide the most definitive information for the individual.
 - CPT[®] codes vary by body area and presence or absence of Doppler imaging and are included in the table at the beginning of this guideline.
 - Transabdominal ultrasound is appropriate in all pediatric individuals.
 - Transvaginal (TV) ultrasound is appropriate in pediatric individuals who are sexually active or use a tampon and consent to the study. Ultrasound (complete CPT[®] 76856 or, limited CPT[®] 76857) should substitute for TV in pediatric individuals or non-sexually active adult females

Pediatric Pelvis Imaging Age Considerations (PEDPV-1.1)

PVP.GG.0001.1.A

v1.0.2024

Many conditions affecting the pelvis in the pediatric population are different diagnoses than those occurring in the adult population. For those diseases which occur in both pediatric and adult populations, minor differences may exist in management due to individual age, comorbidities, and differences in disease natural history between children and adults.

- Individuals who are 18 years old and younger⁹ should be imaged according to the Pediatric Pelvis Imaging Guidelines if discussed. Any conditions not specifically discussed in the Pediatric Pelvis Imaging Guidelines should be imaged according to the General Pelvis Imaging Guidelines. Individuals who are >18 years should be imaged according to the General Pelvis Imaging Guidelines, except where directed otherwise by a specific guideline section.

Pediatric Pelvis Imaging Modality General Considerations (PEDPV-1.3)

PVP.GG.0001.3.A

v1.0.2024

- Ultrasound
 - See **General Guidelines (PEDPV-1.0)**
- MRI
 - MRI Pelvis is generally performed without and with contrast (CPT® 72197) unless the individual has a documented contraindication to gadolinium or otherwise stated in a specific guideline section.
 - Due to the length of time required for MRI acquisition and the need to minimize individual movement, anesthesia is usually required for almost all infants (except neonates) and young children (age <7 years) as well as older children with delays in development or maturity. This anesthesia may be administered via oral or intravenous routes. In this individual population, MRI sessions should be planned with a goal of minimizing anesthesia exposure by adhering to the following considerations:
 - MRI procedures can be performed without and/or with contrast use as supported by these condition-based guidelines. If intravenous access will already be present for anesthesia administration and there is no contraindication for using contrast, imaging without and with contrast may be appropriate if requested. By doing so, the requesting provider may avoid repetitive anesthesia administration to perform an MRI with contrast if the initial study without contrast is inconclusive.
 - Recent evidence-based literature demonstrates the potential for gadolinium deposition in various organs including the brain, after the use of MRI contrast.
 - The U.S. Food and Drug Administration (FDA) has noted that there is currently no evidence to suggest that gadolinium retention in the brain is harmful and restricting gadolinium-based contrast agents (GBCAs) use is not warranted at this time. It has been recommended that GBCA use should be limited to circumstances in which additional information provided by the contrast agent is necessary and the necessity of repetitive MRIs with GBCAs should be assessed.
 - If multiple body areas are supported by eviCore guidelines for the clinical condition being evaluated, MRI of all necessary body areas should be obtained concurrently in the same anesthesia session.
 - The presence of surgical hardware or implanted devices may preclude MRI.
 - The selection of best examination may require coordination between the provider and the imaging service.

- CT
 - CT Pelvis typically extends from the iliac crest to the ischial tuberosities, and CT Abdomen and Pelvis extends from the dome of the diaphragm through the ischial tuberosities.
 - In general, CT Pelvis is appropriate when evaluating solid pelvic organs.
 - In general, CT Abdomen and Pelvis is appropriate when evaluating inflammatory or infections processes, hematuria, or conditions which appear to involve both the abdomen and the pelvis.
 - In some cases, especially in follow-up of a known finding, it may be appropriate to limit the exam to the region of concern to reduce radiation exposure.
 - The contrast level in pediatric CT imaging is specific to the clinical indication, as listed in the specific guideline sections.
 - CT Pelvis or Abdomen and Pelvis may be indicated for further evaluation of abnormalities suggested on prior US or MRI Procedures.
 - CT may be appropriate without prior MRI or US, as indicated in specific sections of these guidelines.
 - CT should not be used to replace MRI in an attempt to avoid sedation unless listed as a recommended study in a specific guideline section.
 - The selection of best examination may require coordination between the provider and the imaging service.
- Nuclear Medicine
 - Nuclear medicine studies are rarely used in imaging of the pediatric pelvis but are indicated in rare circumstances, including the following:
 - Lymph system mapping (CPT[®] 78195) is indicated for lower extremity lymphedema with recent negative Doppler ultrasound, or a history of Milroy's disease or prior pelvic lymph node dissection.
- 3D Rendering
 - 3D Rendering indications in pediatric pelvis imaging are identical to those in the general imaging guidelines. See **3D Rendering (Preface-4.1)** in the Preface Imaging Guidelines

The guidelines listed in this section for certain specific indications are not intended to be all-inclusive; clinical judgment remains paramount and variance from these guidelines may be appropriate and warranted for specific clinical situations.

References (PEDPV-1)

v1.0.2024

1. Berland LL, Cernigliaro JG, Ho VB, et al. ACR Practice parameter for performing and interpreting magnetic resonance imaging (MRI). *American College of Radiology*. Revised 2017
2. Faerber EN, Abramson SJ, Benator RM, et al. ACR–ASER–SCBT–MR–SPR Practice parameter for the performance of pediatric computed tomography (CT). *American College of Radiology*. Revised 2014
3. Reighard C, Junaid S, Jackson WM, et al. Anesthetic Exposure During Childhood and Neurodevelopmental Outcomes: A Systematic Review and Meta-analysis. *JAMA Netw Open*. 2022;5(6):e2217427. Published 2022 Jun 1. doi:10.1001/jamanetworkopen.2022.17427
4. Macdonald A, Burrell S. Infrequently Performed Studies in Nuclear Medicine: Part 2. *Journal of Nuclear Medicine Technology*. 2009;37(1):1-13. doi:10.2967/jnmt.108.057851
5. FDA Drug Safety Communication: FDA identifies no harmful effects to date with brain retention of gadolinium-based contrast agents for MRIs; review to continue. FDA Drug Safety Communication. May 22, 2017
6. Siegel MJ. *Pediatric Sonography*. 5th ed. Philadelphia: Wolters Kluwer/Lippincott Williams & Wilkins; 2018:513-556.
7. Fraum TJ, Ludwig DR, Bashir MR, Fowler KJ. Gadolinium-based contrast agents: A comprehensive risk assessment. *Journal of Magnetic Resonance Imaging*. 2017;46(2):338-353. doi:10.1002/jmri.25625
8. Update on FDA approach to safety issue of gadolinium retention after administration of gadolinium-based contrast agents available at <https://www.fda.gov/media/116492/download>
9. Implementation Guide: Medicaid State Plan Eligibility Eligibility Groups Mandatory Coverage Infants and Children under Age 19 Guidance Portal. <https://www.hhs.gov/guidance/document/implementation-guide-medicaid-state-plan-eligibility-eligibility-groups-aeu-mandatory-2>

Abnormal Uterine Bleeding (PEDPV-2)

Guideline

Abnormal Uterine Bleeding (PEDPV-2.1)

References (PEDPV-2)

Abnormal Uterine Bleeding (PEDPV-2.1)

PVP.UB.0002.1.A

v1.0.2024

- Abnormal uterine bleeding imaging indications in pediatric individuals are very similar to those for adult individuals. See **Abnormal Uterine Bleeding (AUB) (PV-2.1)** in the Pelvis Imaging Guidelines.
- The causes of vaginal bleeding in children differ from those in adolescents. Vaginal bleeding after the first week or so of life but before menarche is always abnormal and warrants evaluation. Common conditions before normal menarche include vaginal foreign bodies, infections, precocious puberty, and estrogen exposure. After menarche, pregnancy and excessive menstrual bleeding (dysfunction) must be considered.
- Pediatric-specific imaging considerations include the following:
 - Transabdominal ultrasound is appropriate in all pediatric individuals.
 - Transvaginal (TV) ultrasound is appropriate in pediatric individuals who are sexually active or use a tampon and consent to the study. Transvaginal ultrasound is generally not appropriate in pediatric individuals or in individuals who have never been sexually active.
 - MRI Pelvis without contrast or without and with contrast (CPT® 72195 or CPT® 72197) is indicated if ultrasound is inconclusive.

References (PEDPV-2)

v1.0.2024

1. Emans SJ, Laufer MR. Precocious Puberty. In: *Emans, Laufer, Goldstein's Pediatric and Adolescent Gynecology*. 7th ed. Wolters Kluwer Health; 2019:114-124.
2. Upadhyia KK, Sucato GS. Abnormal Uterine Bleeding. In: Kliegman RM, St. Geme JW III, Blum NJ, Shah SS, Tasker RC, Wilson KM, eds. *Nelson Textbook of Pediatrics*, 21st ed. 2020:1060-1062.

Pelvic Inflammatory Disease (PID) (PEDPV-3)

Guideline

Pelvic Inflammatory Disease (PID) (PEDPV-3.1)

References (PEDPV-3)

Pelvic Inflammatory Disease (PID) (PEDPV-3.1)

PVP.ID.0003.1.A

v1.0.2024

- Pelvic inflammatory disease imaging indications in pediatric individuals are very similar to those for adult individuals. See **Pelvic Inflammatory Disease (PV-7.1)** in the Pelvis Imaging Guidelines.
- Pediatric-specific imaging considerations include the following:
 - Transabdominal ultrasound is appropriate in all pediatric individuals.
 - Transvaginal (TV) ultrasound is appropriate in pediatric individuals who are sexually active or use a tampon and consent to the study. Transvaginal ultrasound is generally not appropriate in individuals who are pre-pubescent or victims of abuse.
 - MRI Pelvis without contrast (CPT® 72195) or without and with contrast (CPT® 72197) is indicated if ultrasound is inconclusive.
 - CT Pelvis with contrast (CPT® 72193) is indicated if MRI is not readily available.

References (PEDPV-3)

v1.0.2024

1. Burstein GR. Sexually transmitted infections. In: Kliegman RM, St. Geme JW III, Blum NJ, Shah SS, Tasker RC, Wilson KM, eds. *Nelson Textbook of Pediatrics*. 21st ed. 2020:1081-1091
2. Cohen HL, Raju AD. Abnormalities of the female genital tract. In: Coley B, Saunders E, eds. *Caffey's Pediatric Diagnostic Imaging*. Philadelphia PA, 2019:1201-1211
3. Caprio MG, Serafino MD, Feo AD, et al. Ultrasonographic and multimodal imaging of pediatric genital female diseases. *Journal of Ultrasound*. 2019;22(3):273-289. doi:10.1007/s40477-019-00358-5

Amenorrhea (PEDPV-4)

Guideline

Amenorrhea (PEDPV-4.1)

References (PEDPV-4)

Amenorrhea (PEDPV-4.1)

PVP.AA.0004.1.A

v1.0.2024

- Females with primary amenorrhea and any of the following should be evaluated initially with pelvic ultrasound (CPT® 76856 or CPT® 76857):
 - Amenorrhea is usually primary and refers to absence of menstrual periods by age 16.
 - Normal pubertal development and negative pregnancy test.
 - Transabdominal ultrasound is appropriate in all pediatric individuals.
 - Transvaginal (TV) ultrasound is appropriate in pediatric individuals who are sexually active or use a tampon and consent to the study. Transvaginal ultrasound (CPT® 76830) is indicated for better view of genitourinary anomalies in sexually active females.
 - Delayed puberty with follicle-stimulating hormone (FSH) or luteinizing hormone (LH) that is elevated for the individual's age and Tanner stage.
 - MRI Pelvis without contrast or without and with contrast (CPT® 72195 or CPT® 72197) and/or MRI Abdomen without contrast or without and with contrast (CPT® 74181 or CPT® 74183) are indicated for congenital anomalies or for pre-operative planning.

References (PEDPV-4)

v1.0.2024

1. Langer JE, Oliver ER, Lev-Toaff AS, Coleman BG. Imaging of the Female Pelvis through the Life Cycle. *RadioGraphics*. 2012;32(6):1575-1597. doi:10.1148/rg.326125513
2. Upadhyia KK, Suscato GS. Amenorrhea. In: Kliegman RM, St. Geme JW III, Blum NJ, Shah SS, Tasker RC, Wilson KM, eds. *Nelson Textbook of Pediatrics*. 21st ed. Elsevier. 2019:1059-1060.
3. Cohen HL, Raju AD. Amenorrhea and abnormalities of puberty. In: Coley B, Saunders E, eds. *Caffey's Pediatric Diagnostic Imaging*. 13th ed. Elsevier. 2019:12.
4. Behr SC, Courtier JL, Qayyum A. Imaging of Müllerian Duct Anomalies. *RadioGraphics*. 2012;32(6). doi:10.1148/rg.326125515
5. Caprio MG, Serafino MD, Feo AD, et al. Ultrasonographic and multimodal imaging of pediatric genital female diseases. *Journal of Ultrasound*. 2019;22(3):273-289. doi:10.1007/s40477-019-00358-5

Endometriosis (PEDPV-5)

Guideline

Endometriosis (PEDPV-5.1)

Reference (PEDPV-5)

Endometriosis (PEDPV-5.1)

PVP.EM.0005.1.A

v1.0.2024

- Endometriosis imaging indications in pediatric individuals are very similar to those for adult individuals. See **Endometriosis (PV-6.1)** in the Pelvis Imaging Guidelines.
- Pediatric-specific imaging considerations include:
 - Transabdominal ultrasound is appropriate in all pediatric individuals.
 - Transvaginal (TV) ultrasound is appropriate in pediatric individuals who are sexually active or use a tampon and consent to the study. Transvaginal ultrasound is generally not appropriate in individuals who are pre-pubescent or have never been sexually active.

Reference (PEDPV-5)

v1.0.2024

1. Upadhyia KK, Suscato GS. Dysmenorrhea. In: Kliegman RM, St. Geme JW III, Blum NJ, Shah SS, Tasker RC, Wilson KM, eds. *Nelson Textbook of Pediatrics*, 21st ed. 2020:1062-1063.

Suspected Adnexal Mass (PEDPV-6)

Guideline

Suspected Adnexal Mass (PEDPV-6.1)

References (PEDPV-6)

Suspected Adnexal Mass (PEDPV-6.1)

PVP.AM.0006.1.A

v1.0.2024

- Suspected adnexal mass imaging indications in pediatric individuals are very similar to those for adult individuals. See **Adnexal Mass/Ovarian Cysts (PV-5)** in the Pelvis Imaging Guidelines. Ultrasound is the first study indicated for evaluation of a suspected adnexal mass.
- Pediatric-specific imaging considerations include the following:
 - Transabdominal ultrasound is appropriate in all pediatric individuals.
 - Transvaginal (TV) Ultrasound is appropriate in pediatric individuals who are sexually active or use a tampon and consent to the study. Transvaginal ultrasound is generally not appropriate in individuals who are pre-pubescent or have never been sexually active.
 - Adnexal masses with a solid component in individuals, age ≥ 15 years, should be imaged according to **Pediatric Germ Cell Tumors (PEDONC-10)** in the Pediatric Oncology Imaging Guidelines.

References (PEDPV-6)

v1.0.2024

1. Allen-Rhoades WA and Steuber CP. Clinical assessment and differential diagnosis of the child with suspected cancer. In: Pizzo PA and Poplack DG, eds. *Principles and Practice of Pediatric Oncology*. 2016;7:101-111
2. Kelleher CM, Goldstein AM. Adnexal Masses in Children and Adolescents. *Clinical Obstetrics and Gynecology*. 2015;58(1):76-92. doi:10.1097/grf.000000000000084
3. Caprio MG, Serafino MD, Feo AD, et al. Ultrasonographic and multimodal imaging of pediatric genital female diseases. *Journal of Ultrasound*. 2019;22(3):273-289. doi:10.1007/s40477-019-00358-5

Pelvic Pain/Dyspareunia, and Ovarian Torsion (PEDPV-7)

Guideline

Pelvic Pain/Dyspareunia, and Ovarian Torsion (PEDPV-7.1)

References (PEDPV-7)

Pelvic Pain/Dyspareunia, and Ovarian Torsion (PEDPV-7.1)

PVP.PP.0007.1.A

v1.0.2024

- Pelvic Pain/Dyspareunia imaging indications in pediatric individuals are identical to those for adult individuals. See **Pelvic Pain/Dyspareunia, Female (PV-11.1)** in the Pelvis Imaging Guidelines.
- Ovarian torsion in children is typically associated with a normal ovary. Spontaneous torsion of a normal ovary is more common than torsion caused by a lead mass, such as a cyst or tumor. Torsion involves both the ovary and fallopian tube and typically presents with acute onset of lower abdominal pain, often associated with nausea or vomiting.
 - Transabdominal ultrasound (CPT® 76856) with Doppler (CPT® 93975) is appropriate in all pediatric individuals.
 - Transvaginal (TV) ultrasound (CPT® 76830) with Doppler (CPT® 93975) is appropriate in pediatric individuals who are sexually active or use a tampon and consent to the study. Transvaginal ultrasound is generally not appropriate in individuals who are pre-pubescent or have never been sexually active.

References (PEDPV-7)

v1.0.2024

1. Naffaa L, Deshmukh T, Tumu S, Johnson C, Boyd KP, Meyers AB. Imaging of Acute Pelvic Pain in Girls: Ovarian Torsion and Beyond. *Current Problems in Diagnostic Radiology*. 2017;46(4):317-329. doi:10.1067/j.cpradiol.2016.12.010
2. Siegel MJ. *Pediatric Sonography*. 5th ed. Philadelphia: Wolters Kluwer/Lippincott Williams & Wilkins; 2018:513-556
3. Sintim-Damoa A, Majmudar AS, Cohen HL, Parvey LS. Pediatric Ovarian Torsion: Spectrum of Imaging Findings. *RadioGraphics*. 2017;37(6):1892-1908. doi:10.1148/rg.2017170026
4. Cohen HL, Raju AD. Abnormalities of the female genital tract. In: Coley B, Saunders E, eds. *Caffey's Pediatric Diagnostic Imaging*. Philadelphia PA, 2019:1201-1211
5. Caprio MG, Serafino MD, Feo AD, et al. Ultrasonographic and multimodal imaging of pediatric genital female diseases. *Journal of Ultrasound*. 2019;22(3):273-289. doi:10.1007/s40477-019-00358-5
6. Ssi-Yan-Kai G, Rivain A-L, Trichot C, et al. What every radiologist should know about adnexal torsion. *Emergency Radiology*. 2017;25(1):51-59. doi:10.1007/s10140-017-1549-8

Polycystic Ovary Syndrome (PEDPV-8)

Guideline

Polycystic Ovary Syndrome (PEDPV-8.1)

References (PEDPV-8)

Polycystic Ovary Syndrome (PEDPV-8.1)

PVP.OS.0008.1.A

v1.0.2024

- Polycystic ovary syndrome imaging indications in pediatric individuals are identical to those for adult individuals. See **Polycystic Ovary Syndrome (PCOS) (PV-8.1)** in the Pelvis Imaging Guidelines.

References (PEDPV-8)

v1.0.2024

1. Fondin M, Rachas A, Huynh V, et al. Polycystic Ovary Syndrome in Adolescents: Which MR Imaging–based Diagnostic Criteria? *Radiology*. 2017;285(3):961-970. doi:10.1148/radiol.2017161513
2. Cohen HL, Raju AD. Abnormalities of the female genital tract. In: Coley B, Saunders E, eds. *Caffey's Pediatric Diagnostic Imaging*. Philadelphia PA, 2019:1201-1211
3. Huddleston HG, Quinn M, Gibson M. Polycystic Ovary Syndrome and Hirsutism. In: Kliegman RM, St. Geme JW III, Blum NJ, Shah SS, Tasker RC, Wilson KM, eds. *Nelson Textbook of Pediatrics*, 21st ed. 2020:2857-2861
4. DiVall S, Merjaneh L. Adolescent Polycystic Ovary Syndrome: An Update. *Pediatric Annals*. 2019;48(8):e304-e310. doi:10.3928/19382359-20190729-01

Periurethral Cysts and Urethral Diverticula (PEDPV-9)

Guideline

Periurethral Cysts and Urethral Diverticula (PEDPV-9.1)

Periurethral Cysts and Urethral Diverticula (PEDPV-9.1)

PVP.CD.0009.1.A

v1.0.2024

- Periurethral cysts and urethral diverticula imaging indications in pediatric individuals are identical to those for adult individuals. See **Periurethral Cysts and Urethral Diverticula (PV-13)** in the Pelvis Imaging Guidelines.

Fetal MRI (PEDPV-10)

Guideline

Fetal MRI (PEDPV-10.1)

Fetal MRI (PEDPV-10.1)

PVP.MR.0010.1.A

v1.0.2024

- Fetal MRI indications in pediatric individuals are identical to those for adult individuals. See **Fetal MRI (PV-15.1)** in the Pelvis Imaging Guidelines.

Undescended Testis (PEDPV-11)

Guideline

Undescended Testis (PEDPV-11.1)

References (PEDPV-11)

Undescended Testis (PEDPV-11.1)

PVP.UT.0011.1.A

v1.0.2024

- Males with a history of cryptorchidism (undescended testis) have a several-fold risk increase of testicular cancer. It is important to diagnose and treat this condition either by bringing the undescended testis into the scrotum, or resecting the testis.
- Pediatric-specific imaging considerations include the following:
 - Suspected undescended testis is an indication for referral to a surgical subspecialist who should make the decision or be consulted on necessary imaging studies.
- After surgical evaluation or consultation, the following imaging is indicated for pre-operative evaluation⁸:
 - Scrotal ultrasound (CPT[®] 76870) if testis not palpable in the scrotal sac and there is concern for retractile or inguinal testis. In general CT and MRI are not indicated to localize non-palpable testes, as the findings would typically not alter the surgical procedure.
 - If after ultrasound there is concern for associated urogenital abnormalities, or the surgical consultant or any provider in consultation with the surgical consultant indicates that advanced imaging results would significantly alter the surgical procedure either of the studies below are indicated:
 - MRI Abdomen (CPT[®] 74183) and Pelvis (CPT[®] 72197) without and with contrast
 - CT Abdomen and Pelvis with contrast (CPT[®] 74177)

References (PEDPV-11)

v1.0.2024

1. Kolon TF, Herndon CDA, Baker LA, et al. Evaluation and treatment of cryptorchidism: AUA Guideline, Copyright © 2018 American Urological Association Education and Research, Inc.®
2. Inappropriate Use of Ultrasound in Management of Pediatric Cryptorchidism. *Pediatrics*. 2015;136(3). doi:10.1542/peds.2015-0222d
3. Elder JS. Disorders and anomalies of the scrotal contents. In: Kliegman RM, St. Geme JW III, Blum NJ, Shah SS, Tasker RC, Wilson KM, eds. *Nelson Textbook of Pediatrics*, 21st ed. 2020:2827-2833.
4. Poppas DP and Medina C. *Undescended testicle or cryptorchidism*. Cornell University Institute for Pediatric Urology
5. Krishnaswami S, Fonnesbeck C, Penson D, Mcpheeters ML. Magnetic Resonance Imaging for Locating Nonpalpable Undescended Testicles: A Meta-analysis. *Pediatrics*. 2013;131(6). doi:10.1542/peds.2013-0073
6. Aggarwal H, Rehfuss A, Hollowell J. Management of undescended testis may be improved with educational updates for referring providers. *Journal of Pediatric Urology*. 2014;10(4):707-711. doi:10.1016/j.jpuro.2013.10.025
7. Cohen HL, Miller SF. Abnormalities of the male genital tract. In: Coley B, Saunders E, eds. *Caffey's Pediatric Diagnostic Imaging*. Philadelphia, PA. 2019:1193-1200
8. Gates RL, Shelton J, et al. Management of the undescended testis in children: An American Pediatric Surgical Association Outcomes and Evidence Based Practice Committee Systematic Review. *J Pediatr Surg*. 2022 Jul;57(7):1293-1308. doi: 10.1016/j.jpedsurg.2022.01.003

Scrotal Pathology (PEDPV-12)

Guideline

Scrotal Pathology (PEDPV-12.1)

References (PEDPV-12)

Scrotal Pathology (PEDPV-12.1)

PVP.SP.0012.1.A

v1.0.2024

- Scrotal pathology imaging indications in pediatric individuals are very similar to those for adult individuals. See **Scrotal Pathology (PV-20.1)** in the Pelvis Imaging Guidelines.
- Pediatric-specific imaging considerations include the following:
 - Scrotal US (CPT® 76870) with Doppler (CPT® 93975 or CPT® 93976) is indicated for concerns of testicular torsion.
 - MRI Pelvis without contrast (CPT® 72195) or without and with contrast (CPT® 72197) is indicated if torsion is unlikely on ultrasound and no surgical exploration is planned. MRI is not typically used for the acute scrotum due to the limited availability of equipment and the long examination time involved.
 - Since the acceptance of Doppler US as the primary imaging for evaluation of acute scrotum, scintigraphy is not indicated. The unavailability of nuclear medicine imaging in many practices and its use of ionizing radiation, its poor anatomical details, and the time required for imaging are other limiting factors.

References (PEDPV-12)

v1.0.2024

1. Wang, CL, Aryal, B, et al ; ACR Appropriateness Criteria® Acute Onset of Scrotal Pain-Without Trauma, Without Antecedent Mass. *American College of Radiology*. 2018. <https://acsearch.acr.org/docs/69363/Narrative/>
2. Elder JS. Disorders and anomalies of the scrotal contents. In: Kliegman RM, Stanton BF, St. Geme JW III, et al., eds. *Nelson Textbook of Pediatrics*, 20th ed. 2016:2592-2598
3. Macdonald A, Burrell S. Infrequently Performed Studies in Nuclear Medicine: Part 2. *Journal of Nuclear Medicine Technology*. 2009;37(1):1-13. doi:10.2967/jnmt.108.057851
4. Tekgül S, Riedmiller H, Gerharz E, et al. Guidelines on paediatric urology. *European Association of Urology*. Revised March 2013
5. Alkhori NA, Barth RA. Pediatric scrotal ultrasound: review and update. *Pediatric Radiology*. 2017;47(9):1125-1133. doi:10.1007/s00247-017-3923-9
6. Cohen HL, Miller SF. Abnormalities of the male genital tract. In: Coley B, Saunders E, eds. *Caffey's Pediatric Diagnostic Imaging*. Philadelphia, PA. 2019:1193-1200
7. Lyshchik, A, Nikolaidis, P, et al. ACR Appropriateness Criteria® Newly Diagnosed Palpable Scrotal Abnormality. American College of Radiology, 2021. <https://acsearch.acr.org/docs/3158184/Narrative/>

Penis-Soft Tissue Mass (PEDPV-13)

Guideline

Penis-Soft Tissue Mass (PEDPV-13.1)

Penis-Soft Tissue Mass (PEDPV-13.1)

PVP.ST.0013.1.A

v1.0.2024

- Penile soft tissue masses are very rare in pediatric individuals, and imaging indications are identical to those for adult individuals. See **Penis-Soft Tissue Mass (PV-18.1)** in the Pelvis Imaging Guidelines.

Incontinence (PEDPV-14)

Guideline

Incontinence (PEDPV-14.1)

References (PEDPV-14)

Incontinence (PEDPV-14.1)

PVP.IN.0014.1.A

v1.0.2024

- Incontinence imaging indications in pediatric individuals are very similar to those for adult individuals. See **Urinary Incontinence/Pelvic Prolapse/Fecal Incontinence (PV-22)** in the Pelvis Imaging Guidelines.
- Most often incontinence in children is not due to a medical condition. Several uncommon disorders that can lead to urinary incontinence include a spinal cord defect such as spina bifida, ureteral duplication with ectopic insertion, and overactive bladder or dysfunctional voiding.
- No imaging is needed if primary enuresis is suspected; however, imaging evaluation may be warranted if ureteral duplication or overactive bladder or dysfunctional voiding is suspected. The physician should obtain a full medical history and urinalysis before imaging is done.
- Radiopharmaceutical urinary bladder residual study (CPT® 78730) is indicated for suspicion of urinary retention and a recent non-diagnostic ultrasound.
- Pediatric-specific imaging considerations include the following:
 - MRI Pelvis without and with contrast (CPT® 72197) is indicated if ultrasound is inconclusive or spinal abnormality is suspected.
 - CT Pelvis with contrast (CPT® 72193) is appropriate if MRI is not readily available.

References (PEDPV-14)

v1.0.2024

1. Elder JS. Enuresis and voiding dysfunction. In: Kliegman RM, St. Geme JW III, Blum NJ, Shah SS, Tasker RC, Wilson KM, eds. *Nelson Textbook of Pediatrics*, 21st ed. 2020:2816-2821
2. Mandell GA, Eggli DF, Gilday DL, et al. Procedure guideline for radionuclide cystography in children. *Society of Nuclear Medicine*. Version 3.0 approved January 2003.
3. Arlen AM, Cooper CS. New trends in voiding cystourethrography and vesicoureteral reflux: who, when and how?. *Int J Urol*. 2019;26(4):440-445. doi:10.1111/iju.13915
4. Fettich J, Colarinha P, Fischer S, et al. Guidelines for direct radionuclide cystography in children. *Paediatric Committee of the European Association of Nuclear Medicine*. Dec 2002.

Patent Urachus (PEDPV-15)

Guideline

Patent Urachus (PEDPV-15.1)

References (PEDPV-15)

Patent Urachus (PEDPV-15.1)

PVP.UR.0015.1.A
v1.0.2024

- Ultrasound pelvis (CPT® 76856) is indicated as the initial evaluation for patent urachus.
 - ANY of the following are indicated if the ultrasound is inconclusive or insufficient for preoperative planning:
 - MRI Pelvis without contrast (CPT® 72195)
 - MRI Pelvis without and with contrast (CPT® 72197)
 - CT Pelvis with contrast (CPT® 72193)
- Repeat imaging of asymptomatic individuals is not generally necessary, but is indicated for the following:
 - New or worsening symptoms
 - Preoperative planning

Background and Supporting Information

The urachus is a “tube” connecting the fetal bladder to the umbilical cord. It is usually obliterated during fetal growth, but if it remains patent, there can be a complete or partial connection between the bladder and the umbilicus.

Ultrasound has an accuracy greater than 90%.

References (PEDPV-15)

v1.0.2024

1. Villavicencio CP, Adam SZ, Nikolaidis P, Yaghmai V, Miller FH. Imaging of the Urachus: Anomalies, Complications, and Mimics. *RadioGraphics*. 2016;36(7):2049-2063. doi:10.1148/rg.2016160062
2. Berrocal T, López-Pereira P, Arjonilla A, Gutiérrez J. Anomalies of the Distal Ureter, Bladder, and Urethra in Children: Embryologic, Radiologic, and Pathologic Features. *RadioGraphics*. 2002;22(5):1139-1164. doi:10.1148/radiographics.22.5.g02se101139
3. Little DC, Shah SR, Peter SDS, et al. Urachal anomalies in children: the vanishing relevance of the preoperative voiding cystourethrogram. *Journal of Pediatric Surgery*. 2005;40(12):1874-1876. doi:10.1016/j.jpedsurg.2005.08.029
4. Buddha S, Menias CO, Katabathina VS. Imaging of urachal anomalies. *Abdom Radiol (NY)*. 2019;44(12):3978-3989. doi:10.1007/s00261-019-02205-x
5. Parada Villavicencio C, Adam SZ, Nikolaidis P, Yaghmai V, Miller FH. Imaging of the Urachus: Anomalies, Complications, and Mimics. *Radiographics*. 2016;36(7):2049-2063. doi:10.1148/rg.2016160062
6. West HC, Anton CG. Bladder and Urethra. In: Coley B, Saunders E, eds. *Caffey's Pediatric Diagnostic Imaging*. Philadelphia PA; 2019:1157-1166
7. Elder JS. Anomilies of the Bladder. In: Kliegman RM, St. Geme JW III, Blum NJ, Shah SS, Tasker RC, Wilson KM, eds. *Nelson Textbook of Pediatrics*, 21st ed. 2020:2810-2813

Table of Contents

Guideline

General Guidelines (PEDPN-1)

Procedure Codes Associated with Peripheral Nerve Disorders (PND)

Imaging

General Guidelines (PEDPN-1.0)

Age Considerations (PEDPN-1.1)

Modality General Considerations (PEDPN-1.3)

References (PEDPND-1)

Neurofibromatosis (PEDPN-2)

Neurofibromatosis – General Information (PEDPN-2.0)

Neurofibromatosis 1 (PEDPN-2.1)

Neurofibromatosis 2 (PEDPN-2.2)

Brachial Plexus (PEDPN-3)

Brachial Plexus (PEDPN-3.1)

References (PEDPND-3)

Gaucher Disease (PEDPN-4)

Gaucher Disease (PEDPN-4.1)

Spinal Muscular Atrophy (PEDPN -5)

Spinal Muscular Atrophy (PEDPN-5.1)

References (PEDPND-5)

General Guidelines (PEDPN-1)

Guideline

Procedure Codes Associated with Peripheral Nerve Disorders (PND)

Imaging

General Guidelines (PEDPN-1.0)

Age Considerations (PEDPN-1.1)

Modality General Considerations (PEDPN-1.3)

References (PEDPND-1)

Procedure Codes Associated with Peripheral Nerve Disorders (PND) Imaging

PNP.GG.ProcedureCodes.A
v1.0.2024

MRI	CPT®
MRI Neck without contrast	70540
MRI Neck without and with contrast	70543
MRI Cervical without contrast	72141
MRI Cervical without and with contrast	72156
MRI Brachial Plexus without contrast (unilateral)	73218
MRI Brachial Plexus without and with contrast (unilateral)	73220
MRI Brachial Plexus without contrast (bilateral)	71550
MRI Brachial Plexus without and with contrast (bilateral)	71552
MRI Chest without contrast	71550
MRI Chest without and with contrast	71552
MRI Thoracic without contrast	72146
MRI Thoracic without and with contrast	72157
MRI Lumbar without contrast	72148
MRI Lumbar without and with contrast	72158
MRI Abdomen without contrast	74181
MRI Abdomen without and with contrast	74183
MRI Pelvis without contrast	72195
MRI Pelvis without and with contrast	72197
MRI Upper Extremity Other Than Joint without contrast	73218
MRI Upper Extremity Other Than Joint with contrast (rarely used)	73219
MRI Upper Extremity Other Than Joint without and with contrast	73220
MRI Upper Extremity Joint without contrast	73221
MRI Upper Extremity Joint with contrast (rarely used)	73222
MRI Upper Extremity Joint without and with contrast	73223
MRI Lower Extremity Other Than Joint without contrast	73718
MRI Lower Extremity Other Than Joint with contrast (rarely used)	73719

MRI	CPT®
MRI Lower Extremity Other Than Joint without and with contrast	73720
MRI Lower Extremity Joint without contrast	73721
MRI Lower Extremity Joint with contrast (rarely used)	73722
MRI Lower Extremity Joint without and with contrast	73723
Unlisted MRI procedure (for radiation planning or surgical software)	76498

MRA	CPT®
MRA Upper Extremity	73225
MRA Lower Extremity	73725

Nuclear Medicine	
PET Imaging; limited area (this code not used in pediatrics)	78811
PET Imaging: skull base to mid-thigh (this code not used in pediatrics)	78812
PET Imaging: whole body (this code not used in pediatrics)	78813
PET with concurrently acquired CT; limited area (this code rarely used in pediatrics)	78814
PET with concurrently acquired CT; skull base to mid-thigh	78815
PET with concurrently acquired CT; whole body	78816
Bone Marrow Imaging Limited Areas	78102
Bone Marrow Imaging Multiple Areas	78103
Bone Marrow Imaging Whole Body	78104
Nuclear Bone Scan Limited	78300
Nuclear Bone Scan Multiple Areas	78305
Nuclear Bone Scan Whole Body	78306
Bone Scan Three Phase	78315
Radiopharmaceutical Localization Imaging Limited Area	78800
Radiopharmaceutical Localization Imaging Whole Body	78802

Nuclear Medicine

Radiopharmaceutical Localization Imaging SPECT	78803
---	-------

General Guidelines (PEDPN-1.0)

PNP.GG.0001.0.A

v1.0.2024

- A pertinent clinical evaluation including a detailed history, physical examination since the onset or change in symptoms with a thorough neurologic examination, appropriate laboratory studies, and basic imaging such as plain radiography or ultrasound should be performed prior to considering advanced imaging (CT, MRI, Nuclear Medicine), unless the individual is undergoing guideline-supported scheduled imaging evaluation. A meaningful technological contact (telehealth visit, telephone call, electronic mail or messaging) since the onset or change in symptoms can serve as a pertinent clinical evaluation.
 - EMG may not be of clinical utility or obtainable in infants or individuals with severe developmental delay
 - EMG/NCS results may not be abnormal until 10 days after injury.
- Unless otherwise stated in a specific guideline section, the use of advanced imaging to screen asymptomatic individuals for disorders involving the peripheral nervous system is not supported. Advanced imaging of the peripheral nervous system is only appropriate in individuals who have documented active clinical signs or symptoms of disease involving the peripheral nervous system.
- Unless otherwise stated in a specific guideline section, repeat imaging studies of the peripheral nervous system are not necessary unless there is evidence for progression of disease, new onset of disease, and/or documentation of how repeat imaging will affect individual management or treatment decisions.

Age Considerations (PEDPN-1.1)

PNP.GG.0001.1.A
v1.0.2024

- Many conditions affecting the peripheral nervous system in the pediatric population are different diagnoses than those occurring in the adult population. For those diseases that occur in both pediatric and adult populations, minor differences may exist in management due to individual age, comorbidities, and differences in disease natural history between children and adults.
- Individuals who are 18 years old or younger¹¹ should be imaged according to the Pediatric Peripheral Nerve Disorders Imaging Guidelines if discussed. Any conditions not specifically discussed in the Pediatric Peripheral Nerve Disorder Imaging Guidelines should be imaged according to the General Peripheral Nerve Disorder Imaging Guidelines. Individuals who are >18 years old should be imaged according to the General Peripheral Nerve Disorders Imaging Guidelines, except where directed otherwise by a specific guideline section.

Modality General Considerations (PEDPN-1.3)

PNP.GG.0001.3.A

v1.0.2024

- MRI
 - MRI without and with contrast is the preferred modality for pediatric peripheral nerve imaging unless otherwise stated in a specific guideline section.
 - Due to the length of time required for MRI acquisition and the need to minimize individual movement, anesthesia is usually required for almost all infants (except neonates) and young children (age <7 years) as well as older children with delays in development or maturity. This anesthesia may be administered via oral or intravenous routes. In this individual population, MRI sessions should be planned with a goal of minimizing anesthesia exposure by adhering to the following considerations:
 - MRI procedures can be performed without and/or with contrast as supported by these condition-based guidelines. If intravenous access will already be present for anesthesia administration and there is no contraindication for using contrast, imaging without and with contrast may be appropriate if requested. By doing so, the requesting provider may avoid repetitive anesthesia administration to perform an MRI with contrast if the initial study without contrast is inconclusive.
 - Recent evidence based literature demonstrates the potential for gadolinium deposition in various organs including the brain after the use of MRI contrast.
 - The U.S. Food and Drug Administration (FDA) has noted that there is currently no evidence to suggest that gadolinium retention in the brain is harmful and restricting gadolinium-based contrast agents (GBCAs) use is not warranted at this time. It has been recommended that GBCA use should be limited to circumstances in which additional information provided by the contrast agent is necessary and the necessity of repetitive MRIs with GBCAs should be assessed.
 - If multiple body areas are supported by the guidelines for the clinical condition being evaluated, MRI of all necessary body areas should be obtained concurrently in the same anesthesia session.
- CT
 - CT is rarely used in the evaluation of pediatric peripheral nerve disorders. See specific guideline sections for indications.
- Ultrasound
 - Ultrasound is rarely used in the evaluation of pediatric peripheral nerve disorders. See specific guideline sections for indications.

- Nuclear Medicine
 - Nuclear medicine studies are generally not indicated in the evaluation of peripheral nerve disorders. See **Neurofibromatosis (PEDPN-2)** for specific imaging guidelines regarding PET/CT in evaluation of peripheral nerve tumors.
- 3D Rendering
 - 3D Rendering indications in pediatric PND imaging are identical to those in the general imaging guidelines. See **3D Rendering (Preface-4.1)** in the Preface Imaging Guidelines.
- The guidelines listed in this section for certain specific indications are not intended to be all-inclusive; clinical judgment remains paramount and variance from these guidelines may be appropriate and warranted for specific clinical situations

References (PEDPND-1)

v1.0.2024

1. Bowen BC. Magnetic resonance imaging of the peripheral nervous system. In: Latchaw RE, Kucharczyk J, Moseley ME, et al., eds. *Imaging of the Nervous System*. Philadelphia, PA. Elsevier. 2005:1479-1497.
2. Reighard C, Junaid S, Jackson WM, et al. Anesthetic Exposure During Childhood and Neurodevelopmental Outcomes. *JAMA Netw Open*. 2022;5(6):e2217427. doi:10.1001/jamanetworkopen.2022.17427.
3. Fraum TJ, Ludwig DR, Bashir MR, Fowler KJ. Gadolinium-based contrast agents: A comprehensive risk assessment. *J Magn Reson Imaging*. 2017;46(2):338-353. doi: 10.1002/jmri.25625.
4. Update on FDA approach to safety issue of gadolinium retention after administration of gadolinium-based contrast agents. Available at: <https://www.fda.gov/media/116492/download>. September 20, 2018.
5. Blumfield E, Swenson DW, Iyer RS, Stanescu AL. Gadolinium-based contrast agents — review of recent literature on magnetic resonance imaging signal intensity changes and tissue deposits, with emphasis on pediatric patients. *Pediatr Radiol*. 2019;49(4):448-457. doi: 10.1007/s00247-018-4304-8.
6. Raybaud C and Barkovich AJ. Chapter 6: The Phakomatoses. In: *Pediatric Neuroimaging*. 5th ed. Philadelphia. Wolters Kluwer. 2012:569-636.
7. Soderlund KA, Smith AB, Rushing EJ, Smirniotopolous JG. Radiologic-Pathologic Correlation of Pediatric and Adolescent Spinal Neoplasms: Part 2, Intradural Extramedullary Spinal Neoplasms. *AJR Am J Roentgenol*. 2012;198(1):44-51. doi: 10.2214/ajr.11.7121.
8. Kang PB, McMillan HJ, Kuntz NL, et al. Utility and practice of electrodiagnostic testing in the pediatric population: An AANEM consensus statement. *Muscle Nerve*. 2020;61(2):143-155. doi: 10.1002/mus.26752.
9. Orozco V, et al. A Systematic Review of the Electrodiagnostic Assessment of Neonatal Brachial Plexus. *Neurol Neurobiol (Tallinn)*. 2020;3(2). doi: 10.31487/j.nnb.2020.02.12.
10. Artunduaga M, Liou CA, Morin CE, et al. Safety challenges related to the use of sedation and general anesthesia in pediatric patients undergoing magnetic resonance imaging examinations. *<Pediatr Radiol>*. 2021;51(5):724-735. doi: 10.1007/s00247-021-05044-5
11. Implementation Guide: Medicaid State Plan Eligibility Eligibility Groups Mandatory Coverage Infants and Children under Age 19. Available at: <https://www.hhs.gov/guidance/document/implementation-guide-medicaid-state-plan-eligibility-eligibility-groups-aeu-mandatory-2>. Issue date July 14, 2017.

Neurofibromatosis (PEDPN-2)

Guideline

Neurofibromatosis – General Information (PEDPN-2.0)

Neurofibromatosis 1 (PEDPN-2.1)

Neurofibromatosis 2 (PEDPN-2.2)

Neurofibromatosis – General Information (PEDPN-2.0)

PNP.NF.0002.0.A

v1.0.2024

- This guideline section includes imaging indications for individuals with neurofibromatosis and known benign lesions.
- For cancer screening guidelines, see **Neurofibromatosis 1 and 2 (NF1 and NF2) (PEDONC-2.3)** in the Pediatric Oncology Imaging Guidelines.
- For Peripheral Nerve Sheath Tumors, see **Peripheral Nerve Sheath Tumors (PNST) (PND-9.1)** in the Peripheral Nerve Disorders (PND) Imaging Guidelines.
- For guidelines related to known malignancies in individuals with NF1, see the appropriate imaging guideline for the specific cancer type.

Neurofibromatosis 1 (PEDPN-2.1)

PNP.NF.0002.1.A

v1.0.2024

- See **Neurofibromatosis 1 and 2 (NF1 and NF2) (PEDONC-2.3)** in the Pediatric Oncology Imaging Guidelines.
- For Peripheral Nerve Sheath Tumors, see **Peripheral Nerve Sheath Tumors (PNST) (PND-9.1)** in the Peripheral Nerve Disorders (PND) Imaging Guidelines.
- For guidelines related to known malignancies in individuals with NF1, see the appropriate imaging guideline for the specific cancer type.

Neurofibromatosis 2 (PEDPN-2.2)

PNP.NF.0002.2.A

v1.0.2024

- See **Neurofibromatosis 1 and 2 (NF1 and NF2) (PEDONC-2.3)** in the Pediatric Oncology Imaging Guidelines.
- Individuals with NF2 and known meningioma should be imaged according to guidelines in **Meningiomas (Intracranial and Intraspinal) (ONC-2.8)** in the Oncology Imaging Guidelines.
- Individuals with NF2 and known ependymoma should be imaged according to guidelines in **Ependymoma (PEDONC-4.8)** in the Pediatric Oncology Imaging Guidelines.

Brachial Plexus (PEDPN-3)

Guideline

Brachial Plexus (PEDPN-3.1)

References (PEDPND-3)

Brachial Plexus (PEDPN-3.1)

PNP.BP.0003.1.A

v1.0.2024

Disorders of the brachial plexus can generally be identified and distinguished from lesions in other locations by clinical and electromyography/nerve conduction (EMG/NCV) examination. If the diagnosis remains unclear, advanced imaging can be helpful as a pre-operative study to evaluate the anatomy of brachial plexus lesions that should have already been defined by clinical examination.

- MRI is the preferred modality for imaging the brachial plexus. The goal of imaging is to visualize the entire course of the neural network from the preganglionic to the postganglionic segments.
 - CT is not often useful and should not be used as a substitute for MRI.
 - MRI Upper Extremity Other Than Joint without contrast (CPT® 73218) or without and with contrast (CPT® 73220) is indicated for unilateral brachial plexus.
 - MRI Chest without contrast (CPT® 71550) or without and with contrast (CPT® 71552) is indicated for bilateral brachial plexus studies. MRI Neck without contrast (CPT® 70540) is indicated for upper trunk lesions.
 - It is rare for more than one CPT® code to be necessary to adequately image the brachial plexus area of interest.
 - MRI Shoulder without contrast (CPT® 73221) or without and with contrast (CPT® 73223) is indicated in infants with brachial plexopathy due to birth trauma if requested for preoperative planning. These individuals often have glenohumeral dysplasia and require shoulder surgery.
 - Ultrasound also may be indicated in infants with brachial plexus injury to show the glenoid dysplasia and associated shoulder subluxation
 - MRI Cervical Spine without contrast (CPT® 72141) is indicated if there is clinical suspicion for cervical nerve root avulsion.
 - PET/CT skull base to mid-thigh (CPT® 78815) is appropriate if there is a contraindication to MRI in individuals with a known malignancy or post-treatment syndrome.

References (PEDPND-3)

v1.0.2024

1. Expert Panel on Neurological and Musculoskeletal Imaging, Boulter DJ, Job J, et al. ACR Appropriateness Criteria® Plexopathy: 2021 Update. *J Am Coll Radiol*. 2021;18(11S):S423-S441. doi: 10.1016/j.jacr.2021.08.014.
2. Gunes A, Bulut E, Uzumcugil A, Oguz KK. Brachial Plexus Ultrasound and MRI in Children with Brachial Plexus Birth Injury. *AJNR Am J Neuroradiol*. 2018;39(9):1745-1750. doi: 10.3174/ajnr.A5749.
3. Menashe SJ, Tse R, Nixon JN, et al. Brachial Plexus Birth Palsy: Multimodality Imaging of Spine and Shoulder Abnormalities in Children. *AJR Am J Roentgenol*. 2015;204(2):W199-W206. doi: 10.2214/ajr.14.12862.
4. Somashekar DK, Di Pietro MA, Joseph JR, Yang LJS, Parmar HA. Utility of ultrasound in noninvasive preoperative workup of neonatal brachial plexus palsy. *Pediatr Radiol*. 2015;46(5):695-703. doi: 10.1007/s00247-015-3524-4.
5. Volpe JJ. Injuries of extracranial, cranial, intracranial, spinal cord and peripheral nervous system structures. In: *Volpe's Neurology of the Newborn*, 6th ed. Elsevier. Philadelphia 2018:1093-1123.

Gaucher Disease (PEDPN-4)

Guideline

Gaucher Disease (PEDPN-4.1)

Gaucher Disease (PEDPN-4.1)

PNP.GD.0004.1.A

v1.0.2024

- Gaucher Disease imaging indications in pediatric individuals are very similar to those for adult individuals. See **Gaucher Disease (Storage Disorders) (PN-6.3)** in the Peripheral Nerve Disorders (PND) Imaging Guidelines.

Spinal Muscular Atrophy (PEDPN -5)

Guideline

Spinal Muscular Atrophy (PEDPN-5.1)

References (PEDPND-5)

Spinal Muscular Atrophy (PEDPN-5.1)

PNP.SA.0005.1.A

v1.0.2024

- Spinal Muscular Atrophy
 - Molecular genetic testing is the standard tool for diagnosis for the early consideration in any infant with weakness or hypotonia
 - MRI is usually not indicated
 - See **Developmental Motor Delay (PEDHD-19.3)** in the Pediatric Head Imaging Guidelines for presentation of weakness or a loss of skills.

References (PEDPND-5)

v1.0.2024

1. Nance JR. Spinal Muscular Atrophy. *Continuum (Minneap Minn)*. 2020;26(5, Peripheral Nerve And Motor Neuron Disorders):1348–1368.
2. Glascock J, et al. Treatment Algorithm for Infants Diagnosed with Spinal Muscular Atrophy through Newborn Screening. Research Report 8. *J Neuromuscul Dis*. 2018;5(2):145–158. doi: 10.3233/JND-180304.
3. Prior TW, Leach ME and Finanger E. Spinal Muscular Atrophy. *GeneReviews*[®]. Created: February 24, 2000; Updated: 2020 Dec 3. Copyright © 1993-2020, University of Washington, Seattle. GeneReviews is a registered trademark of the University of Washington, Seattle. All rights reserved.

Table of Contents

Guideline

General Guidelines (PEDPVD-1)

Vascular Anomalies (PEDPVD-2)

Vasculitis (PEDPVD-3)

Disorders of the Aorta and Visceral Arteries (PEDPVD-4)

Infantile Hemangiomas (PEDPVD-5)

General Guidelines (PEDPVD-1)

Guideline

Procedure Codes Associated with PVD Imaging (PEDPVD)

General Guidelines (PEDPVD-1.0)

Age Considerations (PEDPVD-1.1)

Modality General Considerations (PEDPVD-1.3)

References (PEDPVD-1)

Procedure Codes Associated with PVD Imaging (PEDPVD)

PVDP.GG.0001.A

v1.0.2024

MRA	CPT®
Magnetic resonance angiography, head; without contrast material(s), followed by contrast material(s) and further sequence	70546
Magnetic resonance angiography, neck; without contrast material(s), followed by contrast material(s) and further sequences	70549
Magnetic resonance angiography, chest (excluding myocardium), with or without contrast material(s)	71555
Magnetic resonance angiography, pelvis, with or without contrast material(s)	72198
Magnetic resonance angiography, upper extremity, with or without contrast material(s)	73225
Magnetic resonance angiography, lower extremity, with or without contrast material(s)	73725
Magnetic resonance angiography, abdomen, with or without contrast material(s)	74185
CTA	CPT®
Computed tomographic angiography, head, with contrast material(s), including noncontrast images, if performed, and image postprocessing	70496
Computed tomographic angiography, neck, with contrast material(s), including noncontrast images, if performed, and image postprocessing	70498
Computed tomographic angiography, chest (noncoronary), with contrast material(s), including noncontrast images, if performed, and image postprocessing	71275
Computed tomographic angiography, upper extremity, with contrast material(s), including noncontrast images, if performed, and image postprocessing	73206
Computed tomographic angiography, lower extremity, with contrast material(s), including noncontrast images, if performed, and image postprocessing	73706
Computed tomographic angiography, abdomen and pelvis, with contrast material(s), including noncontrast images, if performed, and image postprocessing	74174

Computed tomographic angiography, abdomen, with contrast material(s), including noncontrast images, if performed, and image postprocessing	74175
CTA Abdominal Aorta with Bilateral Iliofemoral Runoff	75635
Nuclear Medicine	CPT®
PET Imaging; limited area (this code not used in pediatrics)	78811
PET Imaging: skull base to mid-thigh (this code not used in pediatrics)	78812
PET Imaging: whole body (this code not used in pediatrics)	78813
PET with concurrently acquired CT; limited area (this code rarely used in pediatrics)	78814
PET with concurrently acquired CT; skull base to mid-thigh	78815
PET with concurrently acquired CT; whole body	78816
Ultrasound	CPT®
Ultrasound, abdominal, real time with image documentation; complete	76700
Duplex scan of extracranial arteries; complete bilateral study	93880
Duplex scan of extracranial arteries; unilateral or limited study	93882
Non-invasive physiologic studies of extracranial arteries, complete bilateral study	93875
Limited bilateral noninvasive physiologic studies of upper or lower extremity arteries	93922
Complete bilateral noninvasive physiologic studies of upper or lower extremity arteries	93923
Duplex scan of upper extremity arteries or arterial bypass grafts; complete bilateral	93930
Duplex scan of upper extremity arteries or arterial bypass grafts; unilateral or limited	93931
Non-invasive physiologic studies of extremity veins, complete bilateral study	93965
Duplex scan of extremity veins including responses to compression and other maneuvers; complete bilateral study	93970
Duplex scan of extremity veins including responses to compression and other maneuvers; unilateral or limited study	93971
Duplex scan of hemodialysis access (including arterial inflow, body of access, and venous outflow)	93990

General Guidelines (PEDPVD-1.0)

PVDP.GG.0001.0.A

v1.0.2024

- A pertinent clinical evaluation since the onset or change in symptoms including a detailed history, physical examination, appropriate laboratory studies and basic imaging such as plain radiography or ultrasound should be performed prior to considering advanced imaging (CT, MR, Nuclear Medicine), unless the individual is undergoing guideline-supported scheduled imaging evaluation. A meaningful technological contact (telehealth visit, telephone call, electronic mail or messaging) can serve as a pertinent clinical evaluation.
- Unless otherwise stated in a specific guideline section, the use of advanced imaging to screen asymptomatic individuals for disorders involving the peripheral vascular system is not supported. Advanced imaging of the peripheral vascular system should only be approved in individuals who have documented active clinical signs or symptoms of disease involving the peripheral vascular system.
- Unless otherwise stated in a specific guideline section, repeat imaging studies of the peripheral vascular system are not necessary unless there is evidence for progression of disease, new onset of disease, and/or documentation of how repeat imaging will affect the individual's management or treatment decisions.

Age Considerations (PEDPVD-1.1)

PVDP.GG.0001.1.A

v1.0.2024

Many conditions affecting the peripheral vascular system in the pediatric population are different diagnoses than those occurring in the adult population. For those diseases which occur in both pediatric and adult populations, differences may exist in management due to the individual's age, comorbidities, and differences in disease natural history between children and adults.

- Individuals who are 18 years old and younger¹⁴ should be imaged according to the Pediatric Peripheral Vascular Disease imaging guidelines if discussed. Any conditions not specifically discussed in the pediatric peripheral vascular disease imaging guidelines should be imaged according to the general peripheral vascular disease imaging guidelines. Individuals who are >18 years old should be imaged according to the general Peripheral Vascular Disease imaging guidelines, except where directed otherwise by a specific guideline section.

Modality General Considerations (PEDPVD-1.3)

PVDP.GG.0001.3.A

v1.0.2024

- MRI
 - MRI is generally performed without and with contrast unless the individual has a documented contraindication to gadolinium or otherwise stated in a specific guideline section.
 - Due to the length of time required for MRI acquisition and the need to minimize the individual's movement, anesthesia is usually required for almost all infants (except neonates) and young children (age <7 years), as well as older children with delays in development or maturity. This anesthesia may be administered via oral or intravenous routes. In this population, MRI sessions should be planned with a goal of minimizing anesthesia exposure adhering to the following considerations:
 - MRI procedures can be performed without and/or with contrast use as supported by these condition-based guidelines. If intravenous access will already be present for anesthesia administration and there is no contraindication for using contrast, imaging without and with contrast may be indicated if requested. By doing so, the requesting provider may avoid repetitive anesthesia administration to perform an MRI with contrast if the initial study without contrast is inconclusive.
 - Recent evidence-based literature demonstrates the potential for gadolinium deposition in various organs including the brain after the use of MRI contrast.
 - The U.S. Food and Drug Administration (FDA) has noted that there is currently no evidence to suggest that gadolinium retention in the brain is harmful and restricting gadolinium-based contrast agents (GBCAs) use is not warranted at this time. It has been recommended that GBCA use should be limited to circumstances in which additional information provided by the contrast agent is necessary and the necessity of repetitive MRIs with GBCAs should be assessed.
 - If multiple body areas are supported for the clinical condition being evaluated, MRI of all necessary body areas should be obtained concurrently in the same anesthesia session.
 - The presence of surgical hardware or implanted devices may preclude MRI.
 - The selection of best examination may require coordination between the provider and the imaging service.
- CT
 - CT or CTA may be indicated for further evaluation of abnormalities suggested on prior US or MRI Procedures.

- CT may be indicated without prior MR or US, especially in the following (non-exhaustive list of) settings:
 - Lymphatic malformations
 - Vascular abnormalities including vasculitis, thrombosis, narrowing, aneurysm, dissection, and varices.
 - For pre-operative planning or assessment of post-operative complications.
- In some cases, especially in follow-up of a known finding, it may be appropriate to limit the exam to the region of concern to reduce radiation exposure.
- CT should not be used to replace MRI in an attempt to avoid sedation unless listed as a recommended study in a specific guideline section.
- The selection of best examination may require coordination between the provider and the imaging service.
- Ultrasound
 - Ultrasound can be helpful in evaluating arterial, venous, and lymphatic malformations.
 - Ultrasound can be limited by the imaging window and the individual's body type.
 - CPT® codes vary by body area and presence or absence of Doppler imaging and are included in the table at the beginning of this guideline.
- 3D Rendering
 - 3D Rendering indications in pediatric imaging are identical to those in the general imaging guidelines. See **3D Rendering (Preface-4.1)** in the Preface Imaging Guidelines
- Nuclear Medicine
 - Nuclear medicine studies are rarely used in the evaluation of peripheral vascular disorders but are indicated in the following circumstances:
 - Lymphoscintigraphy (CPT® 78195) is indicated for evaluation of lower extremity lymphedema when a recent Doppler ultrasound is negative for valvular insufficiency.
 - Vascular flow imaging (CPT® 78445) is an obsolete study that has been replaced by MRA, CTA, or Duplex ultrasonography, and is not supported for any indication at this time.
 - Venous thrombosis imaging (CPT® 78456, CPT® 78457, and CPT® 78458) are obsolete studies that have been replaced by MRA, CTA, or Duplex ultrasonography, and are not supported for any indication at this time.
 - Radiopharmaceutical nuclear medicine studies (CPT® 78800, CPT® 78801, CPT® 78802 or CPT® 78803) can be approved for evaluation of the following:
 - Mycotic aneurysms
 - Vascular graft infection
 - Infection of central venous catheter or other indwelling device
 - The guidelines listed in this section for certain specific indications are not intended to be all-inclusive; clinical judgment remains paramount and variance from these guidelines may be indicated and warranted for specific clinical situations.

References (PEDPVD-1)

v1.0.2024

1. Muratore F, Pipitone N, Salvarani C, Schmidt WA. Imaging of vasculitis: State of the art. *Best Practice & Research Clinical Rheumatology*. 2016;30(4):688-706. doi:10.1016/j.berh.2016.09.010.
2. American College of Radiology. Practice parameter for performing and interpreting magnetic resonance imaging (MRI): Amended 2022 (Resolution 8). ACR.org. Published October 1, 2018. <https://www.acr.org/-/media/ACR/Files/Practice-Parameters/mr-perf-interpret.pdf?la=en>.
3. Faerber EN, Abramson SJ, Benator RM, et al. Practice Parameters by Modality: ACR–ASER–SCBT–MR–SPR Practice parameter for the performance of pediatric computed tomography (CT). American College of Radiology | American College of Radiology. Published 2022 (Resolution 9).
4. Ing C, Dimaggio C, Whitehouse A, et al. Long-term Differences in Language and Cognitive Function After Childhood Exposure to Anesthesia. *Pediatrics*. 2012;130(3):e476-e485. doi:10.1542/peds.2011-3822.
5. Monteleone M, Khandji A, Cappell J, Lai WW, Biagas K, Schleien C. Anesthesia in Children. *Journal of Neurosurgical Anesthesiology*. 2014;26(4):396-398. doi:10.1097/ana.000000000000124.
6. Dimaggio C, Sun LS, Li G. Early Childhood Exposure to Anesthesia and Risk of Developmental and Behavioral Disorders in a Sibling Birth Cohort. *Anesthesia & Analgesia*. 2011;113(5):1143-1151. doi:10.1213/ane.0b013e3182147f42.
7. Macdonald A, Burrell S. Infrequently Performed Studies in Nuclear Medicine: Part 2. *Journal of Nuclear Medicine Technology*. 2009;37(1):1-13. doi:10.2967/jnmt.108.057851.
8. Mcneill GC, Witte MH, Witte CL, et al. Whole-body lymphangioscintigraphy: preferred method for initial assessment of the peripheral lymphatic system. *Radiology*. 1989;172(2):495-502. doi:10.1148/radiology.172.2.2748831.
9. Palestro CJ, Brown ML, Forstrom LA, et al. SNMMI Procedure Standard for 111In-Leukocyte Scintigraphy for Suspected Infection/Inflammation 3.0. SNMMI. <http://www.snmmi.org/ClinicalPractice/content.aspx?ItemNumber=6414>. Published June 2, 2004.
10. De Vries EFJ, Roca M, Jamar F, Israel O, Signore A. Guidelines for the labelling of leucocytes with 99mTc-HMPAO. *European Journal of Nuclear Medicine and Molecular Imaging*. 2010;37(4):842-848. doi:10.1007/s00259-010-1394-4.
11. Fraum TJ, Ludwig DR, Bashir MR, Fowler KJ. Gadolinium-based contrast agents: A comprehensive risk assessment. *Journal of Magnetic Resonance Imaging*. 2017;46(2):338-353. doi:10.1002/jmri.25625.
12. Center for Drug Evaluation and Research. Medical Imaging Drugs Advisory Committee. U.S. Food and Drug Administration. Published September 8, 2017. <https://www.fda.gov/advisory-committees/human-drug-advisory-committees/medical-imaging-drugs-advisory-committee>.
13. Center for Drug Evaluation and Research. New warnings for gadolinium-based contrast agents (GBCAs) for MRI. U.S. Food and Drug Administration. Published May 16, 2018. <https://www.fda.gov/drugs/drug-safety-and-availability/fda-drug-safety-communication-fda-warns-gadolinium-based-contrast-agents-gbcas-are-retained-body>.
14. Implementation Guide: Medicaid State Plan Eligibility Eligibility Groups Mandatory Coverage Infants and Children under Age 19 at <https://www.hhs.gov/guidance/document/implementation-guide-medicaid-state-plan-eligibility-eligibility-groups-aeu-mandatory-2>.

Vascular Anomalies (PEDPVD-2)

Guideline

General Information (PEDPVD-2.1)

Lymphatic Malformations (PEDPVD-2.2)

Venous Malformations (PEDPVD-2.3)

Capillary Malformations (PEDPVD-2.4)

Arteriovenous Malformations (AVMs) and Fistulas (PEDPVD-2.5)

Vascular Tumors (PEDPVD-2.6)

References (PEDPVD-2)

General Information (PEDPVD-2.1)

PVDP.AN.0002.1.A

v1.0.2024

- Individuals with aggressive lesions being treated with systemic therapy can have imaging (see specific sections for details regarding modality and contrast level) approved for treatment response every 3 months during active treatment.
- Annual surveillance imaging of known vascular or lymphatic malformations can be approved for body areas where growth could cause significant organ dysfunction or functional impairment.

Background and Supporting Information

Vascular and lymphatic malformations encompass a broad variety of conditions and have very heterogeneous natural history and treatment approaches. Lesions can be divided into low flow lesions (lymphatic, capillary and venous malformations), and high-flow lesions (arteriovenous malformations and fistulas).

Lymphatic Malformations (PEDPVD-2.2)

PVDP.AN.0002.2.A

v1.0.2024

- Ultrasound is indicated as an initial examination for superficial lesions.¹⁸
 - Large lesion characterization may be limited by ultrasound imaging window.
 - Ultrasound is also limited in evaluating malformation relationship to airway or bony structures.
- MRI without contrast or without and with contrast of the affected body part is indicated for:
 - Lymphatic malformations involving deep tissues
 - Malformations too large to be completely imaged with ultrasound¹⁷
 - Inconclusive ultrasound findings
 - Preoperative planning
 - Post treatment evaluation¹⁸
- CT is of limited value in evaluating lymphatic malformations
 - CT with contrast of the affected body part is indicated for lesions with acute enlargement and concerns for compression when MRI is contraindicated.

Background and Supporting Information

Lymphatic malformations are composed of dilated lymphatic channels filled with proteinaceous fluid and do not connect to normal lymphatic channels. They are typically soft, non-pulsatile masses with normal overlying skin.

Venous Malformations (PEDPVD-2.3)

PVDP.AN.0002.3.A

v1.0.2024

- Ultrasound with Doppler is indicated as an initial examination for superficial lesions.
 - Large lesion characterization may be limited by ultrasound imaging window.
 - Ultrasound is also limited in evaluating malformation relationship to airway or bony structures.
- MRI without contrast or without and with contrast of the affected body part is indicated for venous malformations for preoperative assessment to evaluate the extent of malformation and their relationship to normal structures.
- MRA or CTA has a limited role in evaluating most venous malformations but may be indicated (contrast as requested of the affected body part) if MRI or CT is equivocal and the results will impact acute management decisions.
- CT can also be used to characterize venous malformations and their relationship to normal structures but is generally not as accurate as MRI.
 - CT with contrast of the affected body part is indicated when MRI is inconclusive or contraindicated
 - Both Klippel-Trénaunay syndrome and CLOVES syndrome have been found to have increased risk of venous thrombosis and pulmonary embolism, particularly after surgery or sclerotherapy. When pulmonary embolism is suspected in such individuals, CT Chest with contrast with PE protocol (CPT® 71260) or CTA Chest (CPT® 71275) is indicated.

Background and Supporting Information

Venous malformations are slow-flow lesions characterized by dilated venous spaces and a normal arterial component. They are soft, compressible, non-pulsatile lesions that are usually blue to deep purple in color. Lesions can range from very small to large infiltrating ones. Some may change size with Valsalva.

Venous malformations are usually isolated, but they may be seen in multiple syndromes including Klippel-Trenaunay (KT) syndrome, Blue Rubber Bleb Nevus syndrome (BRBN), Maffucci syndrome, Proteus syndrome, Bannayan-Riley-Ruvalcaba syndrome, Parkes-Weber syndrome and congenital lipomatous overgrowth, vascular malformations, epidermal nevi and scoliosis/skeletal/spinal anomalies (CLOVES) syndrome.

Capillary Malformations (PEDPVD-2.4)

PVDP.AN.0002.4.A

v1.0.2024

- MRI (without contrast or without and with contrast) is indicated to evaluate occult underlying neurologic structures associated with encephalocele, spinal dysraphism, or Sturge-Weber syndrome.

Background and Supporting Information

Capillary malformations also known as port wine stains are characterized by a collection of small vascular channels in the dermis and generally do not require advanced imaging because the diagnosis is made clinically.

Arteriovenous Malformations (AVMs) and Fistulas (PEDPVD-2.5)

PVDP.AN.0002.5.A

v1.0.2024

- Ultrasound with Doppler is indicated as an initial examination for superficial lesions
 - Large lesion characterization may be limited by ultrasound imaging window.
 - Ultrasound is also limited in evaluating AVM relationship to airway or bony structures.
- MRI without contrast or without and with contrast of the affected body part is also indicated for evaluation of AVMs, and is useful in evaluating the extent of AVMs and their relationship to normal structures.
- MRA (contrast as requested) of the affected body part is indicated for evaluation and surveillance of known AVMs.
- It is unusual for both MRI and MRA to be necessary for routine treatment response or surveillance imaging of AVMs, but both may be indicated for preoperative planning.
- CT and CTA can also be used to characterize AVMs and their relationship to normal structures but is generally not better than MRI and has associated radiation risks.
 - CT with contrast and/or CTA (contrast as requested) of the affected body part is indicated when MRI and/or MRA is inconclusive or contraindicated.

Background and Supporting Information

Arteriovenous malformations are characterized by a network of multiple abnormal vascular channels interposed between enlarged feeding arteries and draining veins. The arteriovenous fistula has a single communication interposed between a feeding artery and a draining vein. The normal capillary bed is absent in both lesions. Both lesions may have an aggressive clinical course and are characterized by a reddish pulsatile mass which has a thrill or bruit. Though often recognized at birth, these lesions may grow and present near adolescence.

Vascular Tumors (PEDPVD-2.6)

PVDP.AN.0002.6.A

v1.0.2024

- Ultrasound with Doppler is indicated as an initial examination for vascular tumors.
 - Large lesion characterization may be limited by ultrasound imaging window.
 - Ultrasound is also limited in evaluating malformation relationship to airway or bony structures.
- MRI without contrast or without and with contrast of the affected body part is also indicated for evaluation of vascular tumors, and is useful in evaluating the extent of arteriovenous malformations and their relationship to normal structures, as well as response to therapy.
- MRA (contrast as requested) of the affected body part is indicated for evaluation and surveillance of known vascular tumors.
- It is unusual for both MRI and MRA to be necessary for routine treatment response or surveillance imaging of vascular tumors, but both may be indicated for preoperative planning.
- CT and CTA can also be used to characterize vascular tumors and their relationship to normal structures but is generally not better than MRI and has associated radiation risks.
 - CT with contrast and/or CTA (contrast as requested) of the affected body part is indicated when MRI and/or MRA is inconclusive or contraindicated.

Background and Supporting Information

Vascular tumors include a variety of benign, borderline, and malignant tumors, which have variable clinical courses, including but not limited to Infantile Hemangiomas see **Infantile Hemangiomas (PEDPVD-5)**, Epithelioid hemangioma, Kaposiform hemangioendothelioma, Kaposi sarcoma, Epithelioid hemangioendothelioma, and Angiosarcoma of soft tissue.

References (PEDPVD-2)

v1.0.2024

1. Pizzo PA, Poplack DG, Krishnamurthy R, Daldrop-Link HE, Jones JY, et. al. Imaging studies in the diagnosis and management of pediatric malignancies. In: Principles and Practice of Pediatric Oncology. Vol 7. Philadelphia: Wolters Kluwer; 2016:185-234.
2. Martin KL. Vascular disorders. *Nelson Textbook of Pediatrics*, Chapter 669. eds Kliegman R, St. Geme JW III, Blum NJ, et al. 21st ed. Philadelphia, PA: Elsevier; 2020:3461-3469.
3. Blei F, Guarini A. Current workup and therapy of infantile hemangiomas. *Clinics in Dermatology*. 2014;32(4):459-470. doi:10.1016/j.clindermatol.2014.02.001.
4. Bagrodia N, Defnet AM, Kandel JJ. Management of lymphatic malformations in children. *Current Opinion in Pediatrics*. 2015;27(3):356-363. doi:10.1097/mop.0000000000000209.
5. Wassef M, Blei F, Adams D, et al. Vascular Anomalies Classification: Recommendations From the International Society for the Study of Vascular Anomalies. *Pediatrics*. 2015;136(1):e203-e214. doi:10.1542/peds.2014-3673.
6. Kutz AM, Aranibar L, Lobos N, Wortsman X. Color Doppler Ultrasound Follow-Up of Infantile Hemangiomas and Peripheral Vascularity in Patients Treated with Propranolol. *Pediatric Dermatology*. 2015;32(4):468-475. doi:10.1111/pde.12596.
7. Adams DM, Trenor CC, Hammill AM, et al. Efficacy and Safety of Sirolimus in the Treatment of Complicated Vascular Anomalies. *Pediatrics*. 2016;137(2). doi:10.1542/peds.2015-3257.
8. Snyder E, Puttgen K, Mitchell S, Ahlawat S, Tekes A. Magnetic Resonance Imaging of the Soft Tissue Vascular Anomalies in Torso and Extremities in Children: An Update With 2014 International Society for the Study of Vascular Anomalies Classification. *Journal of Computer Assisted Tomography*. 2017;42(2):167-177. doi:10.1097/rct.0000000000000675.
9. Merrow AC, Gupta A, Patel MN, Adams DM. 2014 Revised Classification of Vascular Lesions from the International Society for the Study of Vascular Anomalies: Radiologic-Pathologic Update. *RadioGraphics*. 2016;36(5):1494-1516. doi:10.1148/rg.2016150197.
10. Johnson CM, Navarro OM. Clinical and sonographic features of pediatric soft-tissue vascular anomalies part 1: classification, sonographic approach and vascular tumors. *Pediatric Radiology*. 2017;47(9):1184-1195. doi:10.1007/s00247-017-3885-y.
11. Johnson CM, Navarro OM. Clinical and sonographic features of pediatric soft-tissue vascular anomalies part 2: vascular malformations. *Pediatric Radiology*. 2017;47(9):1196-1208. doi:10.1007/s00247-017-3906-x.
12. Sadick M, Müller-Wille R, Wildgruber M, Wohlgemuth W. Vascular Anomalies (Part I): Classification and Diagnostics of Vascular Anomalies. *RöFo - Fortschritte auf dem Gebiet der Röntgenstrahlen und der bildgebenden Verfahren*. 2018;190(09):825-835. doi:10.1055/a-0620-8925.
13. Olivieri B, White CL, Restrepo R, et. al. Low-Flow Vascular Malformation Pitfalls: From Clinical Examination to Practical Imaging Evaluation—Part 2, Venous Malformation Mimickers. *AJR Am J Roentgenol*. 2016;206(5):952-962. doi:10.2214/ajr.15.15794.
14. White CL, Olivieri B, Restrepo R, et.al. Low-Flow Vascular Malformation Pitfalls: From Clinical Examination to Practical Imaging Evaluation—Part 1, Lymphatic Malformation Mimickers. *AJR Am J Roentgenol*. 2016;206(5):940-951. doi:10.2214/ajr.15.15793.
15. Kulungowski AM, Patel M. Lymphatic malformations. *Semin Pediatr Surg*. 2020;29(5):150971. doi:10.1016/j.sempedsurg.2020.150971.
16. Lee E, Biko DM, Sherk W, Masch WR, Ladino-Torres M, Agarwal PP. Understanding Lymphatic Anatomy and Abnormalities at Imaging. *Radiographics*. 2022;42(2):487-505. doi:10.1148/rg.210104
17. Snyder EJ, Sarma A, Borst AJ, Tekes A. Lymphatic Anomalies in Children: Update on Imaging Diagnosis, Genetics, and Treatment. *AJR Am J Roentgenol*. 2022;218(6):1089-1101. doi:10.2214/AJR.21.27200.
18. Wang MX, Kamel S, Elsayes KM, et al. Vascular Anomaly Syndromes in the ISSVA Classification System: Imaging Findings and Role of Interventional Radiology in Management. *Radiographics*. 2022;42(6):1598-1620. doi:10.1148/rg.210234.

Vasculitis (PEDPVD-3)

Guideline

General Information (PEDPVD-3.1)

Large Vessel Vasculitis (PEDPVD-3.2)

Medium Vessel Vasculitis (PEDPVD-3.3)

Small Vessel Vasculitis (PEDPVD-3.4)

References (PEDPVD-3)

General Information (PEDPVD-3.1)

PVDP.VI.0003.1.A

v1.0.2024

- PET/CT is **not** medically necessary for management of pediatric vasculitis at this time.
 - There are limited data suggesting PET may have similar accuracy to MRA in the initial diagnosis of Takayasu arteritis but is not helpful in assessing treatment response and has not been shown to improve individual outcomes to date.

Background and Supporting Information

Systemic vasculitis is much less common in children than in adults, although the diagnostic pathways and treatment options are similar.

Large Vessel Vasculitis (PEDPVD-3.2)

PVDP.VI.0003.2.A

v1.0.2024

- ANY of the following modalities may be indicated for evaluation of Takayasu arteritis:
 - MRA of the affected body area(s) (contrast as requested)
 - CTA of the affected body area(s) (contrast as requested)
 - Ultrasound with Doppler of the affected body area(s)
- Imaging is indicated at the following intervals:
 - Every 3 months for treatment response during active treatment in individuals being treated with systemic therapy.
 - See specific sections for details regarding modality and contrast level.
 - Annually for surveillance of known involved body areas to detect progressive vascular damage that may require intervention.

Background and Supporting Information

Takayasu arteritis is the predominant large vessel vasculitis occurring in children.

Medium Vessel Vasculitis (PEDPVD-3.3)

PVDP.VI.0003.3.A

v1.0.2024

- Some children who have had COVID 19 develop a severe inflammatory disease that can present in a similar way to Kawasaki disease or toxic shock syndrome. This syndrome has been defined by the US Centers for Disease Control and Prevention as multisystem inflammatory syndrome in children (MIS-C). See **Multisystem inflammatory syndrome in children (MIS-C) (PEDCD-12)** in the pediatric cardiac imaging guidelines.
- Imaging guidelines for Kawasaki Disease- see **Kawasaki Disease (PEDCD-6)** in the pediatric cardiac imaging guideline.
- For evaluation of polyarteritis nodosa:
 - ANY of the following modalities may be indicated:
 - MRA of the affected body area(s) (contrast as requested)
 - CTA of the affected body area(s) (contrast as requested)
 - Ultrasound with Doppler of the affected body area(s)
 - Imaging is indicated at the following intervals:
 - Every 3 months during active treatment with systemic therapy for treatment response.
 - For details regarding modality and contrast level see **Modality General Considerations (PEDPVD-1.3)**
 - Annually for surveillance of known involved body areas to detect progressive vascular damage that may require intervention.

Background and Supporting Information

Polyarteritis nodosa and Kawasaki Disease are the primary medium vessel vasculitides occurring in children.

Small Vessel Vasculitis (PEDPVD-3.4)

PVDP.VI.0003.4.A

v1.0.2024

- Advanced imaging is not sensitive enough to detect changes in small vessels, and is not indicated for primary assessment of any small vessel vasculitis.
- End-organ damage occurs with several of the small vessel vasculitides. Advanced imaging is indicated for the following:
 - Henoch-Schönlein Purpura (HSP) is the most common vasculitis of childhood, mainly involving small blood vessels. Ultrasound abdomen (CPT® 76700) is commonly used to evaluate possible gastrointestinal complications (including bowel wall edema and hemorrhage, and intussusception) in known or suspected HSP, and should be approved when requested for that indication.
 - Granulomatosis with polyangiitis (GPA, formerly known as Wegener's granulomatosis):
 - CT Sinuses (CPT® 70486) and/or CT Chest without contrast (CPT® 71250) or with contrast (CPT® 71260) is indicated in the following circumstances:
 - New or worsening clinical symptoms affecting the body area requested
 - To assess response to medical therapy when a change in treatment regimen is being considered
 - Annually-to evaluate the extent of disease
 - Eosinophilic granulomatosis with polyangiitis (EGPA, formerly known as Churg-Strauss Syndrome):
 - CT Chest without contrast (CPT® 71250) or with contrast (CPT® 71260) is indicated in the following circumstances:
 - New or worsening clinical symptoms affecting the body area requested
 - To assess response to medical therapy when a change in treatment regimen is being considered
 - Annually-to evaluate the extent of disease
 - Immune complex associated small-vessel vasculitis [immunoglobulin A-associated vasculitis (IgAV)]:
 - Doppler ultrasound of the affected body part (most commonly abdomen) is indicated in the following circumstances:
 - New or worsening clinical symptoms affecting the body area requested
 - To assess response to medical therapy when a change in treatment regimen is being considered
 - Annually-to evaluate the extent of disease

References (PEDPVD-3)

v1.0.2024

1. Muratore F, Pipitone N, Salvarani C, Schmidt WA. Imaging of vasculitis: State of the art. *Best Practice Research Clinical Rheumatology*. 2016;30(4):688-706. doi:10.1016/j.berh.2016.09.010.
2. Lensen KDF, Comans EFI, Voskuyl AE, et al. Large-Vessel Vasculitis: Interobserver Agreement and Diagnostic Accuracy of 18F-FDG-PET/CT. *BioMed Research International*. 2015;2015:1-8. doi:10.1155/2015/914692. .
3. Soussan M, Nicolas P, Schramm C, et al. Management of Large-Vessel Vasculitis With FDG-PET. *Medicine*. 2015;94(14). doi:10.1097/md.0000000000000622.
4. Besson FL, Parienti J-J, Bienvenu B, et al. Diagnostic performance of 18F-fluorodeoxyglucose positron emission tomography in giant cell arteritis: a systematic review and meta-analysis. *European Journal of Nuclear Medicine and Molecular Imaging*. 2011;38(9):1764-1772. doi:10.1007/s00259-011-1830-0.
5. Sivaraman V, Fels EC, and Ardoin SP. Vasculitis syndromes. *Nelson Textbook of Pediatrics*, Chapter 192. eds Kliegman RM, St. Geme JW III, Blum NJ, et al. 21st ed. Philadelphia, PA: Elsevier; 2020:1317-1327.
6. Soliman M, Laxer R, Manson D, et. al. Imaging of systemic vasculitis in childhood. *Pediatric Radiology*. 2015;45(8):1110-1125. doi:10.1007/s00247-015-3339-3.
7. Zucker EJ, Chan FP. Pediatric cardiothoracic vasculitis: multimodality imaging review. *Pediatr Radiol*. 2022 Sep;52(10):1895-1909. doi: 10.1007/s00247-022-05431-6. Epub 2022 Jul 6. PMID: 35790558; PMCID: PMC925653.
8. Aeschlimann FA, Raimondi F, Leiner T, et al. Overview of Imaging in Adult- and Childhood-onset Takayasu Arteritis. *J Rheumatol*. 2022 Apr;49(4):346-357. doi: 10.3899/jrheum.210368.
9. Granata C, Damasio MB, Zaottini F, et al. Imaging of Childhood Vasculitis. *Radiologic Clinics of North America*. 2017;55(5):1131-1143. doi:10.1016/j.rcl.2017.05.001.
10. Broncano J, Vargas D, Bhalla S, Cummings KW, Raptis CA, Luna A. CT and MR Imaging of Cardiothoracic Vasculitis. *RadioGraphics*. 2018;38(4):997-1021. doi:10.1148/rg.2018170136.
11. Jennette JC, Falk RJ, Bacon PA, et al. 2012 Revised International Chapel Hill Consensus Conference Nomenclature of Vasculitides. *Arthritis & Rheumatism*. 2012;65(1):1-11. doi:10.1002/art.37715.
12. Ozen S, Pistorio A, Iusan SM, et al. EULAR/PRINTO/PRES criteria for Henoch-Schonlein purpura, childhood polyarteritis nodosa, childhood Wegener granulomatosis and childhood Takayasu arteritis: Ankara 2008. Part II: Final classification criteria. *Annals of the Rheumatic Diseases*. 2010;69(5):798-806. doi:10.1136/ard.2009.116657.

Disorders of the Aorta and Visceral Arteries (PEDPVD-4)

Guideline

Thoracic Aortic Disease (PEDPVD-4.1)

Aortic Congenital Vascular Malformations (PEDPVD-4.2)

Visceral Artery Aneurysms (PEDPVD-4.3)

References (PEDPVD-4)

Thoracic Aortic Disease (PEDPVD-4.1)

PVDP.AD.0004.1.A

v1.0.2024

Familial Aortopathies

- For Aortopathies such as the following:
 - Marfan
 - Ehlers-Danlos (EDS)- a genetic mutation known to predispose to aortic aneurysms/dissections (TGFB1, TGFB2, FBN1, ACTA2, or MYH11)
 - Loeys-Dietz
 - Familial thoracic aneurysm and dissections
- Screening: for Family history with first-degree relative of aortopathy
 - Asymptomatic Individuals with no signs or symptoms of disease, whose first-degree relative has no definitive gene defect, can have screening.
 - Echo (TTE) annually.
- Initial workup: Individuals with suspected aortopathies (gene positive, physical exam positive, or other findings) or definite disease associated with aortopathy
 - Echocardiogram (TTE) at the time of evaluation.
 - If the consideration is for Loeys-Dietz any of the following may be indicated in addition to the TTE at the time of work up:
 - MRA or CTA Head
 - MRA or CTA Neck
 - MRA or CTA Chest
 - MRA or CTA Abdomen and Pelvis
 - MRA or CTA of area of concern when there is an incidental finding on other imaging
- Surveillance: Suspected or known disease but **normal** aortic imaging:
 - Individuals with suspected genetic aortopathies but no disease can have an echocardiogram to assess for change:
 - At 6 months
 - Then annually
 - Individuals with Loeys-Dietz can be imaged with any of the following:
 - Echocardiogram
 - MRA or CTA of (any or all):
 - Head
 - Neck
 - Chest
 - Abdomen
 - Pelvis

- Individuals with Loyes-Dietz can be imaged with the above at the following intervals:
 - At 6 months
 - Then annually
- Surveillance: Suspected disease and **previous abnormal** imaging
 - Individuals with abnormal thoracic imaging can be imaged with (both):
 - Echocardiogram
 - CTA or MRA of (any):
 - Chest
 - Abdomen
 - Pelvis
 - Head (Loyes-Dietz)
 - Neck (Loyes-Dietz)
 - The above imaging is indicated as follows:
 - At the time of diagnosis
 - In 6 months after diagnosis (if older than 2 years)
 - Then as follows based on the individual's age:
 - Individual's age 0 to 2 years:
 - Every 3 months
 - Individual's age 3 to 12 years:
 - Every 6 months
 - Individual's age 13 years and older:
 - Every 12 months (if <4.5 or < 0.5 cm growth per year)
 - Every 6 months if ≥ 4.5 or ≥ 0.5 cm growth per year, or any Loyes-Dietz patient)
 - If the diameter z score is increased, then a repeat study can be done prior to the next allowed study, to assess for rate of change
 - If there are symptoms of dissection any or all of the following are indicated:
 - Echo
 - CTA or MRA of (any or all):
 - Chest
 - Abdomen
 - Pelvis
 - For pediatric individual with dissection, imaging per vascular surgery and cardiology or any provider in consultation with vascular surgery at **any** interval.
 - Miscellaneous syndromes with potential aortopathy as major feature of congenital heart disease
 - Individuals with Turner syndrome see section **Aortic disease in Turner Syndrome (CD-11.2.10)** in the Cardiac Imaging Guideline

- Williams syndrome See section **LVOT lesions (PEDCD-2.4.10)** in the Pediatric Cardiology Imaging Guideline
- Individuals with congenital heart disease would be managed based on **Imaging and Surveillance per Congenital lesion (PEDCD-2.4)** in the Pediatric Cardiology Imaging Guideline
- Miscellaneous disorders that can affect aorta, Osteogenesis imperfecta, Homocystinuria, polycystic kidney disease, Pseudo xanthoma elasticum, Hurler syndrome.
 - Screening echocardiogram yearly.
 - If positive findings, follow protocol for aortic root dilatation.
- Follow-up of thoracic aortic abnormalities for other conditions please see discussions indicated elsewhere in the guidelines:
 - Coarctation of the Aorta- See **Aortic Coarctation and IAA (interrupted aortic arch) (PEDCD-2.4.11)** in the Pediatric Cardiac Imaging Guidelines
 - Congenital rubella syndrome- See **Imaging and Surveillance per Congenital lesion (PEDCD-2.4)** in the Pediatric Cardiac Imaging Guidelines
 - Kawasaki Syndrome- See **Kawasaki Disease (PEDCD-6)**
 - Neurofibromatosis- See **General Guidelines (PEDCD-1.0)** in the Pediatric Cardiac Imaging Guidelines

Aortic Congenital Vascular Malformations (PEDPVD-4.2)

PVDP.PC.0004.2.A

v1.0.2024

- Cardiac MRI without contrast (CPT® 75557) or without and with contrast (CPT® 75561), MRA Chest (CPT® 71555), CT Chest with contrast (CPT® 71260), or CTA Chest (CPT® 71275) may be indicated for evaluation.
- Vascular rings may impact both the esophagus and trachea. See **Esophagus (PEDNECK-7)** and/or **Trachea (PEDNECK-8)** in the Pediatric Neck Imaging Guidelines for additional guidelines.

Visceral Artery Aneurysms (PEDPVD-4.3)

PVDP.AD.0004.3.A

v1.0.2024

- Visceral artery imaging indications in pediatric individuals are identical to those for adult individuals. See **Aortic Disorders and Renal Vascular Disorders and Visceral Artery Aneurysms (PVD-6)** in the Peripheral Vascular Disease Imaging Guidelines.

References (PEDPVD-4)

v1.0.2024

1. Byers PH, Belmont J, Black J, et al. Diagnosis, natural history, and management in vascular Ehlers-Danlos syndrome. *Am J Med Genet Part C Semin Med Genet.* 2017;175C:40-47. doi:10.1002/ajmg.c.31553.
2. Hanneman K, Newman B, Chan F. Congenital Variants and Anomalies of the Aortic Arch. *RadioGraphics.* 2017;37(1):32-51. doi:10.1148/rg.2017160033.
3. Erbel R, Aboyans V, Boileau C, et al. 2014 ESC Guidelines on the diagnosis and treatment of aortic diseases. *European Heart Journal.* 2014;35(41):2873-2926. doi:10.1093/eurheartj/ehu281.
4. Caglayan AO, Dundar M. Inherited diseases and syndromes leading to aortic aneurysms and dissections. *European Journal of Cardio-Thoracic Surgery.* 2009;35(6):931-940. doi:10.1016/j.ejcts.2009.01.006.
5. Coley BD, Chan FD. Acquired diseases of the great vessels. In: *Caffey's Pediatric Diagnostic Imaging.* Vol 1. 12th ed. Elsevier/Saunders; 2013:835.
6. Coley BD, Chan FD. Congenital diseases of the thoracic great arteries. In: *Caffey's Pediatric Diagnostic Imaging.* Vol 1. 12th ed. Elsevier/Saunders; 2013:772.
7. Collins RT. Cardiovascular Disease in Williams Syndrome. *Circulation.* 2013;127(21):2125-2134. doi:10.1161/circulationaha.112.000064.
8. D'hondt S, Damme TV, Malfait F. Vascular phenotypes in nonvascular subtypes of the Ehlers-Danlos syndrome: a systematic review. *Genetics in Medicine.* 2017;20(6):562-573. doi:10.1038/gim.2017.138.
9. Hiratzka LF, Creager MA, Isselbacher EM, et al. Surgery for Aortic Dilatation in Patients with Bicuspid Aortic Valves. *Journal of the American College of Cardiology.* 2016;67(6):724-731. doi:10.1016/j.jacc.2015.11.006.
10. Knadler JJ, Lemaire S, McKenzie ED, et al. Thoracic Aortic, Aortic Valve, and Mitral Valve Surgery in Pediatric and Young Adult Patients with Marfan Syndrome: Characteristics and Outcomes. *Seminars in Thoracic and Cardiovascular Surgery.* 2019;31(4):818-825. doi:10.1053/j.semtcvs.2019.06.005.
11. Landis BJ, Ware SM, James J, Shikany AR, Martin LJ, Hinton RB. Clinical Stratification of Pediatric Patients with Idiopathic Thoracic Aortic Aneurysm. *J Pediatr.* 2015;167(1):131-137. doi:10.1016/j.jpeds.2015.02.042.
12. Loughborough WW, Minhas KS, Rodrigues JCL, et al. Cardiovascular Manifestations and Complications of Loeys-Dietz Syndrome: CT and MR Imaging Findings. *RadioGraphics.* 2018;38(1):275-286. doi:10.1148/rg.2018170120.
13. Huang Y, Qu G. Faculty of 1000 evaluation for 2010 ACCF/AHA/AATS/ACR/ASA/SCA/SCAI/SIR/STS/SVM Guidelines for the diagnosis and management of patients with thoracic aortic disease. A Report of the American College of Cardiology Foundation/American Heart Association Task Force on Practice Guidelines, American Association for Thoracic Surgery, American College of Radiology, American Stroke Association, Society of Cardiovascular Anesthesiologists, Society for Cardiovascular Angiography and Interventions, Society of Interventional Radiology Society of Thoracic Surgeons, and Society for Vascular Medicine. F1000 - Post-publication peer review of the biomedical literature. 2010. doi:10.3410/f.4998963.4932064.
14. MacCarrick G, Black JH 3rd, Bowdin S, et al. Loeys-Dietz syndrome: a primer for diagnosis and management. *Genet Med.* 2014;16(8):576-587. doi:10.1038/gim.2014.11.
15. Maron BJ, Zipes DP, Kovacs RJ. Eligibility and Disqualification Recommendations for Competitive Athletes With Cardiovascular Abnormalities: Preamble, Principles, and General Considerations. *Journal of the American College of Cardiology.* 2015;66(21):2343-2349. doi:10.1016/j.jacc.2015.09.032.
16. Meester JAN, Verstraeten A, Schepers D, et al. Differences in manifestations of Marfan syndrome, Ehlers-Danlos syndrome, and Loeys-Dietz syndrome. *Annals of Cardiothoracic Surgery.* 2017;6(6):582-594. doi:10.21037/acs.2017.11.03.
17. Loeys BL, Dietz HC. Loeys-Dietz Syndrome. GeneReviews® [Internet]. <https://www.ncbi.nlm.nih.gov/books/NBK1133/>. Published March 1, 2018.
18. Oner T, Akgun G, Ergin SO, Karadag H, Yucel IK, Celebi A. Risk Factors Associated with Ascending Aortic Aneurysms and Aortic Elasticity Parameters in Children with a Bicuspid Aortic Valve. *Pediatric Cardiology.* 2019;40(5):980-986. doi:10.1007/s00246-019-02102-6.
19. Pierpont MEM, Lacro RV. Children with Thoracic Aortic Aneurysm: Challenges in Diagnosis and Therapy. *The Journal of Pediatrics.* 2015;167(1):14-16. doi:10.1016/j.jpeds.2015.03.056.
20. Sulli A, Talarico R, Scirè CA, et al. Ehlers-Danlos syndromes: state of the art on clinical practice guidelines. *RMD Open.* 2018;4(Suppl 1). doi:10.1136/rmdopen-2018-000790.
21. Williams JA, Loeys BL, Nwakanma LU, et al. Early Surgical Experience With Loeys-Dietz: A New Syndrome of Aggressive Thoracic Aortic Aneurysm Disease. *The Annals of Thoracic Surgery.* 2007;83(2):s757-63. doi:10.1016/j.athoracsur.2006.10.091.

22. Zanotti G, Vricella L, Cameron D. Thoracic Aortic Aneurysm Syndrome in Children. *Seminars in Thoracic and Cardiovascular Surgery: Pediatric Cardiac Surgery Annual*. 2008;11(1):11-21. doi:10.1053/j.pcsu.2008.01.005.

Infantile Hemangiomas (PEDPVD-5)

Guideline

Infantile Hemangiomas – General Considerations (PEDPVD-5.1)

Multiple Infantile Hemangiomas (PEDPVD-5.2)

PHACE(S) Syndrome (PEDPVD-5.3)

LUMBAR Syndrome (PEDPVD-5.4)

References (PEDPVD-5)

Infantile Hemangiomas – General Considerations (PEDPVD-5.1)

PVDP.IH.0005.1.A

v1.0.2024

Most infantile hemangiomas do not require any imaging. Ultrasound with Doppler can be used when the diagnosis is uncertain, or with high risk clinical considerations. Other general imaging considerations for other vascular neoplasms regarding MRI, MRA, CT, and CTA also apply to infantile hemangiomas. See **Vascular Tumors (PEDPVD-2.6)**.

- Multiple (5 or more) infantile hemangiomas can be associated with hepatic hemangiomas with risk potential for high-output cardiac failure and other risks see **Multiple Infantile Hemangiomas (PEDPVD 5.2)**.
- High-output cardiac failure can also be caused rarely by large cutaneous infantile hemangiomas. Affected infants may present with “failure-to-thrive”, a hyperdynamic precordium, tachycardia, bounding pulses with a widened pulse pressure, and a palpable thrill and/or audible bruit over the hemangioma. This is an indication for cardiac evaluation, including echocardiography (CPT® 93303 ordered with CPT® 93320 and CPT® 93325).
- Life threatening risk of airway obstruction is associated with infantile hemangiomas of the lower face (“beard distribution”), or of the anterior neck, or of the oral and/or pharyngeal mucosa.
- Location-associated functional impairment can be found with periocular infantile hemangiomas larger than 1 cm (impairing vision), or infantile hemangiomas involving lip(s) or oral cavity (impairing feeding)
- Ulceration can occur with profuse bleeding that can be life threatening.
- Disfigurement risk is increased with large (5 cm or larger) infantile hemangiomas, facial or scalp infantile hemangiomas, and breast infantile hemangiomas in female infants.
- An infantile hemangioma at least 2.5 cm in diameter overlying the lumbar spine or sacrum is an indication to do a spinal ultrasound (under 6 months of age) and/or MRI Lumbar Spine without contrast (CPT® 72148) or MRI Lumbar Spine without and with contrast (CPT® 72158).
- Infantile hemangiomas 5 cm or larger in size have an increased risk of extracutaneous structural abnormalities.
- Other high risk indications include Syndromes or Associations with extracutaneous structural changes: for “PHACE(S) syndrome” See **PHACE(S) Syndrome PEDPVD-5.3)**, and for “LUMBAR syndrome” See **LUMBAR Syndrome PEDPVD-5.4)**

Background and Supporting Information

Infantile Hemangiomas are the most common benign tumor of childhood, occurring in close to 5% of infants. Infantile Hemangiomas typically have a phase of rapid and significant growth between 1 month and 3 months of age; growth is usually completed by 5 months of age. Gradual involution then occurs, completed in 90% by age of 4 years but with residual skin changes frequently persisting. Though usually not needed for diagnosis, biopsy can be done when needed to identify unique markers not found on other vascular tumors.

When treatment is needed, imaging may be used to monitor response; consultation with a Hemangioma specialist may be useful in guiding evaluation, treatment, and follow up. The 2019 Clinical Practice Guideline of the American Academy of Pediatrics states "Unlike many diseases, management of IHs is not limited to 1 medical or surgical specialty. A hemangioma specialist may have expertise in dermatology, hematology-oncology, pediatrics, facial plastic and reconstructive surgery, ophthalmology, otolaryngology, pediatric surgery, and/or plastic surgery, and his or her practice is often focused primarily or exclusively on the pediatric age group."

Multiple Infantile Hemangiomas (PEDPVD-5.2)

PVDP.IH.0005.2.A

v1.0.2024

- Multiple (5 or more) hemangiomas is an indication for Ultrasound with Doppler exam of the liver (CPT® 76700):
 - Initial imaging to look for hepatic hemangiomas
 - Repeat doppler ultrasound abdomen:
 - Monitor hepatic hemangiomas for progression
 - Monitor response to treatment.

Background and Supporting Information

Multiple (5 or more) hemangiomas- though hepatic hemangiomas can be asymptomatic, they rarely can cause a high flow rate that can cause high-output cardiac failure and can be potentially fatal. "Diffuse" hepatic infantile hemangiomas are a rare subset of hepatic hemangiomas at high risk for morbidity and mortality; affected infants usually present before 4 months of age with severe hepatomegaly, which can lead to lethal abdominal compartment syndrome with compromised ventilation, renal failure caused by renal vein compression, or compromise of inferior vena cava blood flow to the heart. Hepatic hemangiomas can also inactivate (via deiodination) thyroid hormones, causing risk of severe hypothyroidism.

PHACE(S) Syndrome (PEDPVD-5.3)

PVDP.IH.0005.3.A

v1.0.2024

"PHACE" (Posterior fossa malformations, Hemangiomas, Arterial anomalies, Coarctation of the aorta and Cardiac defects, and Eye abnormalities) syndrome or association (or "PHACE(S)" syndrome when also associated with Sternal cleft and/or Supraumbilical raphe) is frequently suspected when an infant has a large (5 cm in diameter or larger) infantile hemangioma of the face, scalp, or neck (risk of PHACE(S) Syndrome is then approximately 30%).

In rare cases, the face or scalp is not involved, with a large infantile hemangioma located on the torso and/or upper extremity instead. Cerebrovascular anomalies, present in more than 90% of individuals with PHACE(S) syndrome, are the most common extracutaneous feature of the syndrome, followed by cardiac anomalies (67%) and structural brain anomalies (about 50%).

- Indications for imaging a young child for suspected PHACE(S) syndrome include the following:
 - Large (5 or more cm in diameter) infantile hemangioma of the face, scalp, and/or neck.
 - Infantile hemangioma on face, scalp, or neck that is smaller than 5 cm in diameter but with at least one major anomaly found in PHACE(S) syndrome, such as coarctation of the aorta or midline ventral defect.
 - Without any visible facial infantile hemangioma, PHACE(S) syndrome can also reasonably be suspected with the following:
 - Infantile hemangioma on upper chest or proximal upper extremity that is 5 cm or larger in size, with also major anomalies found in PHACE(S) syndrome
 - Large intraorbital infantile hemangioma.
- When PHACE(S) syndrome is reasonably suspected, initial imaging would include the following:
 - MRI Brain without contrast (CPT® 70551) or MRI Brain without and with contrast (CPT® 70553)
 - MRI Orbits without contrast (CPT® 70540) or MRI Orbits without and with contrast (CPT® 70543)
 - MRA Head without contrast (CPT® 70544) or MRA Head without and with contrast, (CPT® 70546)
 - MRA Neck may be done either without contrast (CPT® 70547), with contrast (CPT® 70548), or without and with contrast (CPT® 70549)
 - MRA Chest (CPT® 71555).
 - A screening transthoracic echocardiogram, CPT® 93303 (CPT® 93320 and CPT® 93325 are also indicated if ordered with CPT® 93303). If abnormalities are identified on echocardiogram, a cardiac MRI (CPT® 75557 or CPT® 75561) is then indicated.

- If other clinical information or imaging shows involvement of the aorta, then MRI Chest without contrast (CPT® 71550) or MRI Chest without and with contrast (CPT® 71552) is also indicated.
- Need for follow up or surveillance imaging is dictated by the results of the initial clinical and imaging assessment, and any subsequent clinical change. The most frequent follow up will be needed for those deemed at highest risk, including when the following has been found:
 - Evidence of past arterial stroke
 - Arterial stenosis or occlusions, with or without moyamoya-like vascular changes
 - Structural brain changes, with neurosurgical evaluation clarifying the need for follow up.
 - Changes in the aortic arch, coarctation of the aorta, and congenital cardiac anomalies, with pediatric cardiology evaluation clarifying the need for follow up see **Imaging and Surveillance per Congenital lesion (PEDCD-2.4)** in the Pediatric Cardiac Imaging Guidelines

LUMBAR Syndrome (PEDPVD-5.4)

PVDP.IH.0005.4.A

v1.0.2024

- “LUMBAR syndrome” is reasonably suspected in a child with a large (5 or more cm in diameter) infantile hemangioma of any lumbosacral or perineal region or lower extremity. The following imaging is then indicated:
 - Ultrasound spine (CPT® 76800) in infants up to 6 months of age, abdomen (CPT® 76700), and pelvis (CPT® 76856), with color Doppler.
 - MRI Lumbar Spine without contrast (CPT® 72148) or without and with contrast (CPT® 72158) at 3 to 6 months of age, or earlier when either findings on an Ultrasound exam are inadequate or when requested by a hemangioma specialist or any provider in consultation with a hemangioma specialist.
 - MRI of other relevant spinal level (relevance based on proximity of observed infantile hemangiomas larger than 5 cm) without contrast or MRI of the relevant spinal level without and with contrast.
 - When ultrasound findings are inadequate and/or when recommended by a hemangioma specialist or any provider in consultation with a hemangioma specialist:
 - MRI Pelvis without contrast (CPT® 72195) or without and with contrast (CPT® 72197) **and/or**
 - MRI Abdomen without contrast (CPT® 74181) or without and with contrast (CPT® 74183).
 - MRA Abdomen CPT® 74185 and/or Pelvis CPT® 72198, is indicated based on proximity of infantile hemangioma(s) at least 5 cm in diameter and/or other clinical evidence of vascular involvement, and/or when recommended by a hemangioma specialist or any provider in consultation with a hemangioma specialist.
 - Infantile hemangioma of the lower extremity that is at least 5 cm in diameter is an indication for MRI of the relevant portion of the lower extremity without contrast (CPT® 73718) or lower extremity without and with contrast (CPT® 73720) and/or lower extremity joint without contrast (CPT® 73721) or lower extremity joint without and with contrast (CPT® 73723).
 - When there is extensive lower extremity involvement with infantile hemangiomas the following are all indicated:
 - MRA (for both arterial and venous phase imaging) Abdomen
 - MRA Pelvis
 - MRA Lower extremities
 - Note: this should be reported as CPT® 74185 and CPT® 73725; the CPT® code for MRA Pelvis (CPT® 72198) should not be included in this circumstance.

Background and Supporting Information

The acronym "LUMBAR syndrome" refers to the association of Lower body infantile hemangiomas at least 5 cm in size (and other cutaneous defects), Urogenital anomalies and ulceration, "Myelopathy" (lipomyelocele/lipo-myelomeningocele and/or tethered spinal cord), Bony deformities, Anorectal malformations and Arterial anomalies, and Renal anomalies. Though not exclusively true, there is a general regional correlation between the location of the cutaneous large infantile hemangioma(s) with underlying structural anomalies.

References (PEDPVD-5)

v1.0.2024

1. Darrow DH, Greene AK, Mancini AJ, Nopper AJ. Diagnosis and Management of Infantile Hemangioma: Executive Summary. *Pediatrics*. 2015;136(4):786-791. doi:10.1542/peds.2015-2482.
2. Drolet BA, Chamlin SL, Garzon MC, et al. Prospective Study of Spinal Anomalies in Children with Infantile Hemangiomas of the Lumbosacral Skin. *The Journal of Pediatrics*. 2010;157(5):789-794. doi:10.1016/j.jpeds.2010.07.054.
3. Ferriero DM, Fullerton HJ, Bernard TJ, et al. Management of Stroke in Neonates and Children: A Scientific Statement from the American Heart Association/American Stroke Association. *Stroke*. 2019;50(3). doi:10.1161/str.000000000000183.
4. Holland KE, Drolet BA. Approach to the Patient with an Infantile Hemangioma. *Dermatologic Clinics*. 2013;31(2):289-301. doi:10.1016/j.det.2012.12.006.
5. Iacobas I, Burrows PE, Frieden IJ, et al. LUMBAR: Association between Cutaneous Infantile Hemangiomas of the Lower Body and Regional Congenital Anomalies. *The Journal of Pediatrics*. 2010;157(5). doi:10.1016/j.jpeds.2010.05.027
6. Krowchuk DP, Frieden IJ, Mancini AJ, et al. Clinical Practice Guideline for the Management of Infantile Hemangiomas. *Pediatrics*. 2019;143(1). doi:10.1542/peds.2018-3475.
7. Léauté-Labrèze C, Harper JL, Hoeger PH. Infantile haemangioma. *The Lancet*. 2017;390(10089):85-94. doi:10.1016/s0140-6736(16)00645-0.
8. Menapace D, Mitkov M, Towbin R, Hogeling M. The changing face of complicated infantile hemangioma treatment. *Pediatric Radiology*. 2016;46(11):1494-1506. doi:10.1007/s00247-016-3643-6
9. Nelson WE, Kliegman R, St. Geme JW, et al. Chapter 669 Vascular disorders . In: Nelson Textbook of Pediatrics. 21st ed. Philadelphia, PA: Elsevier; 2020:3461-3469.
10. Obara P, Mccool J, Kalva SP, et al. ACR Appropriateness Criteria® Clinically Suspected Vascular Malformation of the Extremities. *Journal of the American College of Radiology*. 2019;16(11). doi:10.1016/j.jacr.2019.05.013.
11. Restrepo R, Francavilla ML, Mas R, Lee EY. Up-To-Date Practical Imaging Evaluation of Neonatal Soft-Tissue Tumors: What Radiologists Need to Know. *American Journal of Roentgenology*. 2017;209(1):195-204. doi:10.2214/ajr.16.17576.
12. Steiner JE, Mccoy GN, Hess CP, et al. Structural malformations of the brain, eye, and pituitary gland in PHACE syndrome. *American Journal of Medical Genetics Part A*. 2017;176(1):48-55. doi:10.1002/ajmg.a.38523.
13. Tuite GF, Thompson DN, Austin PF, Bauer SB. Evaluation and management of tethered cord syndrome in occult spinal dysraphism: Recommendations from the international children's continence society. *Neurology and Urodynamics*. 2017;37(3):890-903. doi:10.1002/nau.23382.
14. Wang MX, Kamel S, Elsayes KM, et al. Vascular Anomaly Syndromes in the ISSVA Classification System: Imaging Findings and Role of Interventional Radiology in Management. *Radiographics*. 2022 Oct;42(6):1598-1620. doi: 10.1148/rg.210234.

Table of Contents

Guideline

General Guidelines (PEDSP-1.0)

Pediatric Back and Neck Pain and Trauma (PEDSP-2)

Kyphosis and Scoliosis (PEDSP-3)

Spinal Dysraphism and Tethered Spinal Cord (PEDSP-4)

Tethered Cord (PEDSP-5)

Myelopathy (PEDSP-6)

Other Congenital and Pediatric Spine Disorders (PEDSP-7)

General Guidelines (PEDSP-1.0)

Guideline

Procedure Codes Associated with Spine Imaging (PEDSPINE)

General Guidelines (PEDSP-1.0)

Pediatric Spine Imaging Age Considerations (PEDSP-1.1)

Pediatric Spine Imaging Appropriate Clinical Evaluation (PEDSP-1.2)

Pediatric Spine Imaging Modality General Considerations (PEDSP-1.3)

References (PEDSP-1)

Procedure Codes Associated with Spine Imaging (PEDSPINE)

SPP.GG.ProcedureCodes.A

v1.0.2024

Procedure Codes Associated with Spine Imaging	
MRI	CPT [®]
MRI Cervical without contrast	72141
MRI Cervical with contrast	72142
MRI Cervical without and with contrast	72156
MRI Thoracic without contrast	72146
MRI Thoracic with contrast	72147
MRI Thoracic without and with contrast	72157
MRI Lumbar without contrast	72148
MRI Lumbar with contrast	72149
MRI Lumbar without and with contrast	72158
MRI Unlisted procedure (for radiation planning or surgical software)	76498
MRA	CPT [®]
MRA Spinal Canal	72159
CT	CPT [®]
CT Cervical without contrast	72125
CT Cervical with contrast	72126
CT Cervical without and with contrast	72127
CT Thoracic without contrast	72128
CT Thoracic with contrast	72129
CT Thoracic without and with contrast	72130
CT Lumbar without contrast	72131
CT Lumbar with contrast	72132
CT Lumbar without and with contrast	72133
CT Pelvis without contrast	72192
CT Pelvis with contrast	72193
CT Pelvis without and with contrast	72194

Procedure Codes Associated with Spine Imaging	
CT Guidance for Placement of Radiation Therapy Fields	77014
CT Unlisted procedure (for radiation planning or surgical software)	76497
Nuclear Medicine	CPT®
PET Imaging; limited area (this code not used in pediatrics)	78811
PET Imaging: skull base to mid-thigh (this code not used in pediatrics)	78812
PET Imaging: whole body (this code not used in pediatrics)	78813
PET with concurrently acquired CT; limited area (this code rarely used in pediatrics)	78814
PET with concurrently acquired CT; skull base to mid-thigh	78815
PET with concurrently acquired CT; whole body	78816
Bone Marrow Imaging Limited Areas	78102
Bone Marrow Imaging Multiple Areas	78103
Bone Marrow Imaging Whole Body	78104
Nuclear Bone Scan Limited	78300
Nuclear Bone Scan Multiple Areas	78305
Nuclear Bone Scan Whole Body	78306
Bone Scan Three Phase	78315
Radiopharmaceutical localization of tumor, inflammatory process or distribution of radiopharmaceutical agent(s) (includes vascular flow and blood pool imaging, when performed); planar, single area (e.g., head, neck, chest, pelvis), single day imaging	78800

Procedure Codes Associated with Spine Imaging

Radiopharmaceutical localization of tumor, inflammatory process or distribution of radiopharmaceutical agent(s) (includes vascular flow and blood pool imaging, when performed); planar, 2 or more areas (e.g., abdomen and pelvis, head and chest), 1 or more days imaging or single area imaging over 2 or more days	78801
Radiopharmaceutical localization of tumor, inflammatory process or distribution of radiopharmaceutical agent(s) (includes vascular flow and blood pool imaging, when performed); planar, whole body, single day imaging	78802
Radiopharmaceutical localization of tumor, inflammatory process or distribution of radiopharmaceutical agent(s) (includes vascular flow and blood pool imaging, when performed); tomographic (SPECT), single area (e.g., head, neck, chest, pelvis), single day imaging	78803
Radiopharmaceutical localization of tumor, inflammatory process or distribution of radiopharmaceutical agent(s) (includes vascular flow and blood pool imaging, when performed); planar, whole body, requiring 2 or more days imaging	78804
Radiopharmaceutical localization of tumor, inflammatory process or distribution of radiopharmaceutical agent(s) (includes vascular flow and blood pool imaging, when performed); tomographic (SPECT) with concurrently acquired computed tomography (CT) transmission scan for anatomical review, localization and determination/detection of pathology, single area (e.g., head, neck, chest, pelvis), single day imaging	78830

Procedure Codes Associated with Spine Imaging

Radiopharmaceutical localization of tumor, inflammatory process or distribution of radiopharmaceutical agent(s) (includes vascular flow and blood pool imaging, when performed); tomographic (SPECT), minimum 2 areas (e.g., pelvis and knees, abdomen and pelvis), single day imaging, or single area imaging over 2 or more days	78831
Radiopharmaceutical localization of tumor, inflammatory process or distribution of radiopharmaceutical agent(s) (includes vascular flow and blood pool imaging, when performed); tomographic (SPECT) with concurrently acquired computed tomography (CT) transmission scan for anatomical review, localization and determination/detection of pathology, minimum 2 areas (e.g., pelvis and knees, abdomen and pelvis), single day imaging, or single area imaging over 2 or more days	78832
Ultrasound	CPT®
Ultrasound, spinal canal and contents	76800

General Guidelines (PEDSP-1.0)

SPP.GG.0001.0.A

v1.0.2024

- A pertinent clinical evaluation since the onset or change in symptoms, including a detailed history, physical examination with a thorough neurologic examination, appropriate laboratory studies and basic imaging such as plain radiography or ultrasound should be performed prior to considering advanced imaging (CT, MR, Nuclear Medicine), unless the individual is undergoing guideline-supported scheduled imaging evaluation. A meaningful technological contact (telehealth visit, telephone call, electronic mail or messaging) can serve as a pertinent clinical evaluation.
 - A thorough neurologic examination should include results of manual motor testing, specific dermatomal distribution of altered sensation, reflex examination, nerve root tension signs (e.g., straight leg raise test, slump test, femoral nerve tension test), and documentation of any specific radicular features.
- For those spinal conditions/disorders for which the Spine Imaging Guidelines require a plain x-ray of the spine prior to consideration of an advanced imaging study, the plain x-ray must be performed after the current episode of symptoms started or changed and results need to be available to the requesting provider of the advanced imaging study.
- Unless otherwise stated in a specific guideline section, the use of advanced imaging to screen asymptomatic individuals for disorders involving the spine is not supported. Advanced imaging of the spine should only be approved in individuals who have documented active clinical signs or symptoms of disease involving the spine.
- Unless otherwise stated in a specific guideline section, repeat imaging studies of the spine are not necessary unless there is evidence for progression of disease, new onset of disease, and/or documentation of how repeat imaging will affect patient management or treatment decisions.

Pediatric Spine Imaging Age Considerations (PEDSP-1.1)

SPP.GG.0001.1.A

v1.0.2024

- Many conditions affecting the spine in the pediatric population are different diagnoses than those occurring in the adult population. For those diseases which occur in both pediatric and adult populations, minor differences may exist in management due to patient age, comorbidities, and differences in disease natural history between children and adults.
- Patients who are ≤ 18 years old or younger¹⁴ should be imaged according to the Pediatric Spine Imaging Guidelines if discussed. Any conditions not specifically discussed in the Pediatric Spine Imaging Guidelines should be imaged according to the General Spine Imaging Guidelines. Individuals who are >18 years old should be imaged according to the General Spine Imaging Guidelines, except where directed otherwise by a specific guideline section.

Pediatric Spine Imaging Appropriate Clinical Evaluation (PEDSP-1.2)

SPP.GG.0001.2.A
v1.0.2024

- See: General Guidelines (PEDSP-1.0)

Pediatric Spine Imaging Modality General Considerations (PEDSP-1.3)

SPP.GG.0001.3.A

v1.0.2024

- MRI
 - MRI is the preferred modality for imaging the pediatric spine unless otherwise stated in a specific guideline section.
 - Due to the length of time required for MRI acquisition and the need to minimize individual movement, anesthesia is usually required for almost all infants (except neonates) and young children (age <7 years), as well as older children with delays in development or maturity. This anesthesia may be administered via oral or intravenous routes. In this individual population, MRI sessions should be planned with a goal of minimizing anesthesia exposure by adhering to the following considerations:
 - MRI procedures can be performed without and/or with contrast use as supported by these condition based guidelines. If intravenous access will already be present for anesthesia administration and there is no contraindication for using contrast, imaging without and with contrast may be appropriate if requested. By doing so, the requesting provider may avoid repetitive anesthesia administration to perform an MRI with contrast if the initial study without contrast is inconclusive.
 - Recent evidence based literature demonstrates the potential for gadolinium deposition in various organs including the brain, after the use of MRI contrast.
 - The U.S. Food and Drug Administration (FDA) has noted that there is currently no evidence to suggest that gadolinium retention in the brain is harmful and restricting gadolinium-based contrast agents (GBCAs) use is not warranted at this time. It has been recommended that GBCA use should be limited to circumstances in which additional information provided by the contrast agent is necessary and the necessity of repetitive MRIs with GBCAs should be assessed.
 - If multiple body areas are supported by eviCore guidelines for the clinical condition being evaluated, MRI of all necessary body areas should be obtained concurrently in the same anesthesia session.
- CT
 - CT is generally inferior to MRI for imaging the pediatric spine, but has specific indications in which it is the preferred modality listed in specific sections of these guidelines.
 - CT is the imaging study of choice in the setting of trauma
 - CT should not be used to replace MRI in an attempt to avoid sedation unless it is listed as a recommended study in a specific guideline section.

- Myelogram with post-myelogram CT imaging is rarely indicated in children except in certain limited indications (usually requested after specialist consultation), including:
 - Evaluation of spine in individuals with fixation hardware which limits utility of MRI.
 - Severe congenital scoliosis with inconclusive MRI.
 - Evaluation of nerve root avulsion in patients with a brachial plexus injury and inconclusive MRI.
 - Evaluation of paraspinal cyst to assess continuity with the subarachnoid space.
 - Coding note: CT of appropriate spinal level with or without contrast may be appropriate. If the radiologist performs the myelogram the exam should be coded with contrast. If a clinician performs the myelogram the exam should be coded without contrast.
- Ultrasound
 - Spinal canal ultrasound (CPT® 76800) describes the ultrasonic evaluation of the spinal cord (canal and contents) and should not be reported multiple times for imaging of different areas of the spinal canal.
 - Do not use CPT® 76800 for intraoperative spinal canal ultrasound as CPT® 76998 (intraoperative ultrasonic guidance) is the appropriate code in this circumstance.
 - Spinal canal ultrasound (CPT® 76800) is generally limited to infants up to 6 months of age because of the bone mass surrounding the spinal cord limits evaluation of the intraspinal contents in older infants.
 - **Exception:** the persisting acoustic window in children with posterior spinal defects of spinal dysraphism enables spinal canal ultrasound to be performed at any age (see: **Spinal Dysraphism (PEDSP-4)**).
 - In general, additional imaging studies of the spine are not indicated in asymptomatic individuals with normal spinal ultrasound findings.
- Nuclear Medicine
 - Nuclear medicine studies are rarely used in the evaluation of the spine, but are indicated in the following circumstances:
 - Evaluation of suspected loosening of orthopedic hardware when recent plain x-ray is nondiagnostic:
 - Bone scan (CPT® 78315) or
 - Distribution Of Radiopharmaceutical Agent SPECT (CPT® 78803, or 78831) or
 - SPECT/CT (CPT® 78830 or CPT® 78832)
 - For suspected spondylolysis, see **Spondylolysis (PEDSP-2.4)**
 - Evaluation of back pain when no cause is demonstrated on MRI, see **Back and Neck Pain in Children Age 5 and Under (PEDSP-2.2)** or **Back and Neck Pain in Children Age 6 and Older (PEDSP-2.3)**

- The guidelines listed in this section for certain specific indications are not intended to be all-inclusive; clinical judgment remains paramount and variance from these guidelines may be appropriate and warranted for specific clinical situations.

References (PEDSP-1)

v1.0.2024

1. Berland LL, Cernigliaro JG, Ho VB, et al. ACR Practice parameter for performing and interpreting magnetic resonance imaging (MRI). American College of Radiology. Revised 2017. <https://www.acr.org/-/media/ACR/Files/Practice-Parameters/mr-perf-interpret.pdf?la=en>.
2. Biassoni L, Easty M. Pediatric nuclear medicine imaging. *Br Med Bull*. 2017;123:127-48.
3. Newman B, Carmody TJ, Catanzano TM, et al. ACR-ASER-SCBT-MR-SPR Practice parameter for the performance of pediatric computed tomography (CT) Revised 2019 (Resolution 6). American College of Radiology. 2019. <https://www.acr.org/-/media/ACR/Files/Practice-Parameters/ct-ped.pdf?la=en>.
4. Ing C, DiMaggio C, Whitehouse A, et al. Long-term differences in language and cognitive function after childhood exposure to anesthesia. *Pediatrics*. 2012;130(3). doi:10.1542/peds.2011-3822.
5. Monteleone M, Khandji A, Cappell J, et al. Anesthesia in children: perspectives from nonsurgical pediatric specialists. *J Neurosurg Anesthesiol*. 2014;26(4):396-398. doi:10.1097/ana.000000000000124.
6. DiMaggio C, Sun LS, and Li G. Early childhood exposure to anesthesia and risk of developmental and behavioral disorders in a sibling birth cohort. *Anesth Analg*. 2011;113(5):1143-1151. doi:10.1213/ANE.0b013e3182147f42.
7. Donohoe KJ, Brown ML, Collier D, et al. Society of nuclear medicine procedure guideline for bone scintigraphy, version 3.0 approved June 20, 2003. *Society of Nuclear Medicine procedure guidelines manual*. 2003 Aug. http://snmmi.files.cms-plus.com/docs/pg_ch34_0403.pdf
8. Hochman MG, Melenevsky YV, Metter DF, et al. ACR Appropriateness Criteria®. Imaging after total knee arthroplasty. American College of Radiology. Date of origin: 1986. Last reviewed: 2017. <https://acsearch.acr.org/docs/69430/Narrative/>.
9. Cook GJR and I Fogelman. Bone single photon emission computed tomography. *The British Institute of Radiology*. 2001;13(3):149-154. doi: 10.1259/img.13.3.130149.
10. Fraum TJ, Ludwig DR, Bashir MR, et al. Gadolinium-based contrast agents: a comprehensive risk assessment. *J Magn Reson Imaging*. 2017;46(2):338–353. doi:10.1002/jmri.25625.
11. Fotenos, A. Update on FDA approach to safety issue of gadolinium retention after administration of gadolinium-based contrast agents. FDA. <https://www.fda.gov/media/116492/download>. Accessed April 22, 2020.
12. Blumfield E, Swenson DW, Iyer RS, Stanescu AL. Gadolinium-based contrast agents – review of recent literature on magnetic resonance imaging signal intensity changes and tissue deposits, with emphasis on pediatric patients. *Pediatric Radiology*. 2019;49(4):448-457. doi:10.1007/s00247-018-4304-8.
13. Siegel MJ. Spinal Ultrasonography. Pediatric sonography. 5th ed. Philadelphia. Wolters Kluwer. 2018;653-76.
14. Implementation Guide: Medicaid State Plan Eligibility Groups Mandatory Coverage Infants and Children under Age 19. <https://www.hhs.gov/guidance/document/implementation-guide-medicaid-state-plan-eligibility-eligibility-groups-aeu-mandatory-2>

Pediatric Back and Neck Pain and Trauma (PEDSP-2)

Guideline

Introduction (PEDSP-2.1)

Back and Neck Pain in Children Age 5 and Under (PEDSP-2.2)

Back and Neck Pain in Children Age 6 and Older (PEDSP-2.3)

Spondylolysis (PEDSP-2.4)

Spine Pain Due to Infectious Causes (PEDSP-2.5)

Spine Pain Related to Trauma and Painless Spine Trauma (PEDSP-2.6)

References (PEDSP-2)

Introduction (PEDSP-2.1)

SPP.TR.0002.1.A

v1.0.2024

- Currently, only about 20% of back pain in children over age 5 is from a discoverable cause. Scoliosis, spondylitic disorders, Scheuermann disease, tumor, and trauma are the most common causes.
- Back pain in children under age 5 is uncommon and often reflects underlying serious disease when present.
- Disc herniations are rare in children, but become more frequent as activity increases during adolescence.

Back and Neck Pain in Children Age 5 and Under (PEDSP-2.2)

SPP.TR.0002.2.A

v1.0.2024

- A pertinent clinical evaluation including a detailed history, physical examination with thorough neurologic examination and documentation of any specific radicular features, and plain radiography should be performed prior to considering advanced imaging.
- Advanced imaging is appropriate in all individuals in this age group except those with mild and transient back pain.
 - MRI of the symptomatic spinal region should be approved
 - Individuals in this age group will require sedation to complete MRI imaging. See: **Pediatric Spine Imaging Modality General Considerations (PEDSP-1.3)** for contrast and body area considerations.
 - CT without contrast of the symptomatic spinal region when:
 - Plain x-rays suggest an isolated vertebral bone abnormality without any concern for spinal canal or cord abnormalities (which is rare in this age group).
 - A recent MRI does not provide sufficient detail of the bony anatomy to allow for acute patient care decision making.
 - Bone scan is indicated for evaluation of suspected spinal fracture when x-ray is negative using any of the following CPT® code combinations:
 - CPT® 78300, CPT® 78305, or CPT® 78306 as a single study
 - CPT® 78315 or CPT® 78803 can be approved as a single study when stress fracture is suspected.
 - Bone scan is indicated for evaluation of suspected spondylolysis, or if recent spine MRI is inconclusive using any of the following CPT code combinations: SPECT bone scans are especially sensitive for detecting spondylolysis, revealing areas of bone turnover; and the findings are generally positive for a prolonged period.
 - CPT® codes: CPT® 78300, CPT® 78305, CPT® 78306, CPT® 78315, or CPT® 78803 as a single study
 - CPT® 78305 and CPT® 78803 concurrently
 - CPT® 78306 and CPT® 78803 concurrently

Back and Neck Pain in Children Age 6 and Older (PEDSP-2.3)

SPP.TR.0002.3.A

v1.0.2024

Radicular back and neck pain is common in adult patients but is uncommon in adolescents and rare in children.

- A pertinent clinical evaluation including a detailed history, physical examination with thorough neurologic examination including results of manual motor testing, the specific dermatomal distribution of altered sensation, reflex examination, and nerve root tension signs (e.g., straight leg raise test, slump test, femoral nerve tension test) and documentation of any specific radicular features, should be performed prior to considering advanced imaging.
- X-rays, while not required prior to conservative treatment, must be obtained before advanced imaging can be approved.
 - The results of plain x-rays performed after the current episode of symptoms started or changed need to be available to the requesting provider of the advanced imaging study
- Advanced imaging should be approved following a recent x-ray when one or more of the following pediatric “red flags” are present:
 - Accompanying systemic symptoms (fever, weight loss, etc.)
 - Functional disability (daily limitation in normal activities because of pain)
 - Pain which is extremely severe or worse at night
 - Constant or radicular pain lasting ≥ 4 weeks
 - Pain which worsens despite an attempt at symptomatic treatment
 - Neurological symptoms or abnormal neurological examination findings
 - An established diagnosis of cancer other than leukemia
 - Abnormal x-rays
 - Spinal imaging for patients having undergone spinal surgery
 - Associated bowel or bladder dysfunction
- In the absence of any “red flags”, a recent (within 3 months) 4-week trial of provider-supervised conservative treatment should be attempted before advanced imaging can be approved.
 - It can be assumed that children who are being evaluated by a pediatric spine surgeon have failed a reasonable trial of conservative treatment under the care of the primary care provider, as this is by far the most common reason for such referrals.
- X-rays of the involved regions should be obtained prior to advanced imaging in patients with “red flag” findings, or who remain symptomatic after a 4 week trial of provider-supervised conservative treatment.

- The results of plain x-rays performed after the current episode of symptoms started or changed need to be available to the requesting provider of the advanced imaging study
- MRI without contrast of the symptomatic spinal region is the preferred study for the evaluation of pediatric spine pain, and should be approved unless one of the following conditions applies, in which case MRI without and with contrast should be approved:
 - Fever ($\geq 100^{\circ}$ F)
 - Clinical suspicion of infection (discitis, osteomyelitis, paraspinous or epidural abscess)
 - Physical examination or plain x-ray suggests a mass lesion
 - New or worsening pain in a patient with an established diagnosis of cancer
- CT without contrast of the symptomatic spinal region when:
 - The request is for re-evaluation of a known vertebral bony disorder.
 - Plain x-rays show spondylotic changes or suggest an isolated vertebral bone abnormality without any concern for spinal canal or cord abnormalities (which is rare in this age group).
 - A recent MRI does not provide sufficient detail of the bony anatomy to allow for acute individual care decision making.
- Bone scan is indicated for evaluation of suspected spinal fracture when x-ray is negative, or if recent MRI is inconclusive using any of the following CPT[®] code combinations:
 - CPT[®] codes: CPT[®] 78300, CPT[®] 78305, or CPT[®] 78306 as a single study
 - CPT[®] 78315 or CPT[®] 78803 can be approved as a single study when stress fracture is suspected.

Spondylolysis (PEDSP-2.4)

SPP.TR.0002.4.A

v1.0.2024

Most cases of childhood spondylolysis are believed to be caused by repeated microtrauma, resulting in stress fracture of the pars interarticularis. Heredity is also believed to be a factor in some cases. It is the most common cause of low back pain in children older than age 10.

- Activity modification, NSAID treatment, physical therapy, and/or immobilization with various braces are the initial treatments for symptomatic patients.
- Surgical treatment is only recommended for patients with disabling symptoms that have not responded to non-surgical care.
- A pertinent clinical evaluation including a detailed history, physical examination with thorough neurologic examination and documentation of any specific radicular features, and plain radiography should be performed prior to considering advanced imaging.
- Spondylolysis is screened with plain x-rays
 - MRI without contrast of the symptomatic spinal level is indicated to evaluate for stress reaction in bone and visualizing nerve roots if symptoms have continued despite a recent (within 3 months) provider-directed 4 week course of conservative care, or if there is a documented need for preoperative planning.
 - If additional imaging is needed because of radiological uncertainty or associated spondylolisthesis, SPECT Radiopharmaceutical Localization Imaging (CPT[®] 78803) or SPECT/CT (CPT[®] 78830) is indicated to identify stress reaction in spondylolysis cases which are radiographically occult. Bone scan has been demonstrated to be superior to MRI in detecting active spondylolysis.
 - SPECT bone scans are especially sensitive for detecting spondylolysis, revealing areas of bone turnover; and the findings are generally positive for a prolonged period. CT without contrast of the symptomatic spinal level is indicated to provide detailed evaluation of bony anatomy, if there is a documented need for preoperative planning. CT scans have been considered the criterion standard for characterizing fractures and for detailing bone morphology and anatomy.

Spine Pain Due to Infectious Causes (PEDSP-2.5)

SPP.TR.0002.5.A

v1.0.2024

- Entities including, but not limited to, discitis and vertebral osteomyelitis, typically present with sudden onset of back pain, fever, and elevated white blood cell count, occurring most commonly in prepubescent children.
- A detailed history and physical examination with thorough neurologic examination should be performed initially.

Initial Imaging Studies

- Plain x-rays should be performed initially.
 - The results of plain x-rays performed after the current episode of symptoms started or changed need to be available to the requesting provider of the advanced imaging study
- MRI without and with contrast of the symptomatic spinal level is very sensitive at detecting early changes and can be approved when discitis or osteomyelitis is clinically suspected.
- Nuclear medicine imaging also can be positive as soon as 1 to 2 days after the onset of symptoms. Any of the following studies are indicated for initial evaluation of suspected osteomyelitis:
 - Bone scan (one of CPT® codes: CPT® 78300, 78305, 78306, or 78315)
 - Nuclear Bone Marrow imaging (one of CPT® codes: CPT® 78102, 78103, or 78104)
 - Radiopharmaceutical inflammatory imaging (one of CPT® codes: CPT® 78800, 78801, 78802, 78803, or 78804)
 - SPECT (CPT® 78831)
 - SPECT/CT (CPT® 78830, or CPT® 78832)

Follow-Up Imaging Studies

- Follow-up plain x-rays may show disc space narrowing and bony changes of osteomyelitis.
- MRI without and with contrast of the symptomatic spinal level or CT with contrast (including myelography) may be useful in follow-up for evaluating bony changes of osteomyelitis or concern for epidural abscess.
- Any of the following studies are indicated for evaluation of response to treatment in established osteomyelitis:
 - Bone scan (one of CPT® codes: CPT® 78300, 78305, 78306, or 78315)
 - Nuclear Bone Marrow imaging (one of CPT® codes: CPT® 78102, 78103, or 78104)
 - Radiopharmaceutical localization imaging (one of CPT® codes: CPT® 78800, 78801, 78803, 78830, 78831, or 78832)

Spine Pain Related to Trauma and Painless Spine Trauma (PEDSP-2.6)

SPP.TR.0002.6.A

v1.0.2024

- Imaging evaluation of traumatic spine injury in children is generally directed based on clinical examination. 60% to 80% of all spinal injuries in children involve the cervical spine as opposed to the thoracic spine and lumbar spine.
- A pertinent clinical evaluation including a detailed history, physical examination with thorough neurologic examination and documentation of any specific radicular features, should be performed prior to considering advanced imaging.
- When advanced imaging is appropriate, MRI without contrast or CT without contrast of the involved level is indicated as discussed in **Pediatric Spine Imaging Modality General Considerations (PEDSP-1.3)**
 - If the initial CT or MRI study is considered inconclusive, an exam of the other modality may be approved if needed to direct clinical management.

Cervical Spine

- The results of plain x-rays performed after the current episode of symptoms started or changed need to be available to the requesting provider of the advanced imaging study
- Children under 3 years of age should be approved for advanced imaging of the cervical spine following a relevant recent x-ray when one or more of the following “red flags” are present:
 - Glasgow Coma Scale <14
 - Individual does not open eyes regardless of stimulus
 - Motor Vehicle Collision
- Children ≥ 3 years of age should be approved for advanced imaging of the cervical spine following a recent (within 60 days) x-ray when one or more of the following “red flags” are present:
 - Altered Mental Status
 - Focal Neurologic Findings
 - Neck pain
 - Torticollis not present prior to trauma
 - Substantial torso injury
 - Diving or head-first injury
 - High speed motor vehicle collision
 - Predisposing conditions, e.g. Down Syndrome
- Children older than 2 years of age SHOULD NOT be approved for advanced imaging of the cervical spine if they meet ALL of the following criteria:
 - Absence of posterior midline cervical pain

- Absence of focal neurologic deficit
- Normal level of alertness
- No evidence of intoxication
- Absence of other clinically apparent pain which could distract patient from the pain of a cervical injury

Thoracolumbar Spine

- Children should be approved for advanced imaging of the thoracolumbar spine following a recent x-ray when x-rays are inconclusive, or there is an abnormal neurological examination.

Suspected Physical Child Abuse

- In children with suspected physical child abuse and documented findings suggesting abuse (e.g., fractures on skeletal survey or other clinical indicators), MRI Cervical (CPT® 72141), Thoracic (CPT® 72146), and Lumbar (CPT® 72148) Spine without contrast are indicated to search for associated abnormalities.
 - If intravenous access will already be present for anesthesia administration and there is no contraindication for using contrast, imaging without and with contrast can be approved. See: **Pediatric Spine Imaging Modality General Considerations (PEDSP-1.3)**

References (PEDSP-2)

v1.0.2024

1. Booth TN, Iyer RS, Falcone Jr RA, et al. ACR Appropriateness Criteria® Back pain-child. American College of Radiology; Updated: 2016. <https://acsearch.acr.org/docs/3099011/Narrative/>.
2. Calloni SF, Huisman TA, Poretti A, Soares BP. Back pain and scoliosis in children: when to image, what to consider. *The Neuroradiology Journal*. 2017;30(5):393-404.
3. Eckel T, Lehman R, and Paik H. Spondylolisthesis. Scoliosis Research Society. Scoliosis Research Society E-Text ©, 2022. <http://etext.srs.org/book/>.
4. Faingold R, Saigal G, Azouz EM, et al. Imaging of low back pain in children and adolescents. *Semin Ultrasound CT MR*. 2004;25(6):490-505. doi:10.1053/j.sult.2004.09.005.
5. Kjaer P, Leboeuf-Yde C, Sorensen JS, et al. An epidemiologic study of MRI and low back pain in 13-year-old children. *Spine*. 2005;30(7):798-806. doi:10.1097/01.brs.0000157424.72598.ec.
6. MacDonald J, Stuart E, Rodenberg R. Musculoskeletal low back pain in school-aged children: a review. *JAMA pediatrics*. 2017;171(3):280-7.
7. Matesan M, Behnia F, Bermo M, et al. SPECT/CT bone scintigraphy to evaluate low back pain in young athletes: common and uncommon etiologies. *J Ortho Surg*. 2016;11:76.
8. Mistovich RJ, Spiegel DA. The Spine. In: Kliegman RM, St. Geme JW III, Blum NJ, et al. Nelson Textbook of Pediatrics. 21st edition. Philadelphia, PA: Elsevier; 2020:3633-3646.
9. Ramirez N, Flynn JM, Hill BW, et al. Evaluation of a systematic approach to pediatric. *J Pediat Ortho*. 2015;35-28-32.
10. Rodriguez DP, Toussaint TY. Imaging of back pain in children. *AJNR Am J Neuroradiol*. 2010;31(5):787-802.
11. Taxter AH, Chauvin NA, Weiss PF. Diagnosis and treatment of low back pain in the pediatric population. *Phys Sportsmed*. 2014;42:94-104.
12. Trout AT, Sharp SE, Anton CG, et al. Spondylolysis and beyond: value of SPECT/CT in evaluation of low back pain in children and young adults. *Radiographic*. 2015;35:819-34.
13. Kadom N, Palasis S, Pruthi S, et al. ACR Appropriateness Criteria® Suspected Spine Trauma—Child. American College of Radiology; Date of Origin: 2018. <https://acsearch.acr.org/docs/3101274/Narrative/>.
14. Kim H, Crawford C, Ledonio C, et al. Current evidence regarding the diagnostic methods for pediatric lumbar spondylolisthesis: a report from the Scoliosis Research Society Evidence Based Medicine Committee. *Spine Deform*. 2018;6(2):185-188.
15. Oetgen ME. Current Use of Evidence-Based Medicine in Pediatric Spine Surgery. *Orthopedic Clinics*. 2018;49(2):191-4.
16. McAlister AS, Nagaraji U, Radhakrishnan R. Emergent imaging of pediatric cervical spine trauma. *Radiographic*. 2019;39:1126-1142.
17. Trout AT, Sharp SE, Anton CG, Gelfand MJ, Mehlman CT. Spondylolysis and beyond: value of SPECT/CT in evaluation of low back pain in children and young adults. *Radiographics*. 2015;35(3):819-34.
18. Born M, Schwier F, Stoeber B, Mentzel HJ, Freiberg J. The German evidence-based child protection guideline—imaging in suspected child abuse. *Rofo*. 2020;192(4):343-348. doi:10.1055/a-1019-8018.
19. Wooten-Gorges SL, Soares BP, Alazarki AL, et al. ACR Appropriateness Criteria®. Suspected Physical Abuse—Child. Date of origin: 1984. Last review: 2016.

Kyphosis and Scoliosis (PEDSP-3)

Guideline

Juvenile Thoracic Kyphosis (Scheuermann Disease) (PEDSP-3.1)

Scoliosis (PEDSP-3.2)

References (PEDSP-3)

Juvenile Thoracic Kyphosis (Scheuermann Disease) (PEDSP-3.1)

SPP.KS.0003.1.A

v1.0.2024

- This condition is also known as Scheuermann Kyphosis, and these individuals generally present with chronic and recurrent back pain.
- A pertinent clinical evaluation including a detailed history, physical examination with thorough neurologic examination and documentation of any specific radicular features, and plain radiography should be performed prior to considering advanced imaging.
- X-rays will typically show anterior wedging in three or more adjacent vertebral bodies.
 - Lower thoracic kyphosis from developmental vertebral wedging with thoracic kyphosis varying between 20° and 45° should be identified by plain x-rays before considering advanced imaging.
 - MRI is not an effective diagnostic modality for this condition since the incidence of false positive vertebral changes in normal individuals is high.
- MRI Thoracic Spine without contrast (CPT® 72146) preoperatively to rule out any associated spinal cord problems.
- MRI Lumbar Spine without contrast (CPT® 72148) preoperatively to rule out any associated spinal cord conditions when there is clinical or radiographic evidence of lumbar abnormalities.

Scoliosis (PEDSP-3.2)

SPP.KS.0003.2.A

v1.0.2024

- Scoliosis is an abnormal lateral curve of the thoracic or thoraco-lumbar spine in the frontal plane. A small lateral curve in a skeletally mature person is not uncommon and generally does not require further investigation.
- Using the Cobb technique for measuring these curves, a curve of under 10° is normal, a curve from 10 to 20° is mildly abnormal, a curve over 20° is significantly abnormal, and a curve > 40° is severely abnormal.
- Most patients with significant scoliosis have some element of kyphosis as well.
 - There are many ways of classifying scoliosis. These guidelines will classify scoliosis as congenital, idiopathic, and neuromuscular scoliosis.
- A pertinent clinical evaluation including a detailed history, physical examination with thorough neurologic examination and documentation of any specific radicular features, detailed examination of the spine in different body positions, and plain radiography should be performed prior to considering advanced imaging.
 - Standing posteroanterior (PA) and lateral x-rays of the spine are the initial imaging studies and are used for follow-up. If anteroposterior (AP) x-rays are to be performed, breast shields should be used to reduce breast radiation exposure.
 - Spine surgical specialists sometimes appropriately request both MRI and CT together for preoperative planning of scoliosis surgery.
 - In addition, MR and CT are useful to identify an underlying cause of scoliosis, such as congenital and developmental anomalies.
 - MR or CT Spine postoperative when recent postoperative x-rays are inconclusive for managing individual treatment.
 - Individuals with severe scoliosis may have compromised lung development. CT Chest with contrast (CPT® 71260) or without contrast (CPT® 71250) may be obtained in the perioperative period as well as 2 and 5 years post operatively to assess lung growth.

Congenital Scoliosis

Cases are recognized in infancy or early childhood. Most cases arise from anomalies of vertebral development, and many are associated with anomalies of the genitourinary system or of other organs.

- In infants, spinal ultrasound (CPT® 76800) can be approved after initial imaging with plain x-rays.
- MRI Cervical (CPT® 72141), Thoracic (CPT® 72146), and Lumbar (CPT® 72148) Spine without contrast are indicated to search for underlying anomalies.
 - If intravenous access will already be present for anesthesia administration and there is no contraindication for using contrast, imaging without and with contrast may, be approved. See: **Pediatric Spine Imaging Modality General Considerations (PEDSP-1.3)**

- MRI Brain without and with contrast if the clinical evaluation or preliminary imaging studies suggest an associated intracranial anomaly.
- Renal ultrasound (CPT® 76770 or CPT® 76775) should be performed, since nearly one-third of individuals also have genitourinary anomalies.
 - CT, MRI, or nuclear medicine studies of the genitourinary tract may be necessary if the ultrasound is abnormal.

Idiopathic Scoliosis

Idiopathic scoliosis is the most common form of pediatric scoliosis and is divided into infantile (0-3 years of age), juvenile (4-9 years of age), and adolescent (10-17 years of age). Idiopathic scoliosis is defined as having no underlying structural abnormality or accompanying syndrome.¹²

- The following clinical features are associated with an increased risk of underlying vertebral or spinal cord abnormality:
 - Associated back pain
 - Age younger than 10 years
 - Neurological abnormalities on examination or neurological symptoms
 - Left sided curve (concave to right)
 - Absence of apical segment lordosis/kyphosis
 - Rapid curve progression (>1 degree per month)
 - Pes Cavus (see: **Occult Spinal Dysraphism (PEDSP-4.3)**)
 - Double curves or high thoracic curves
 - Kyphosis
 - Spinal x-ray abnormalities other than the curve itself (widened spinal canal, dysplastic changes in spine or ribs, etc.)
 - Midline spinal cutaneous markers (esp. sacral) such as dermal tracts, tufts of hair, skin tags, etc.
 - Abnormal number or size of café au lait spots (neurofibromatosis)
- MRI Cervical (CPT® 72141), Thoracic (CPT® 72146), and Lumbar (CPT® 72148) Spine without contrast is the preferred study for the evaluation of scoliosis and should be approved when any of the above clinical features is present or if imaging is requested for individuals who are being actively evaluated for corrective surgery.

Neuromuscular Scoliosis

Scoliosis can result from many disorders of the nervous system. In some conditions, including (but not limited to) cerebral palsy, muscular dystrophy, and spinal muscular atrophy, associated scoliosis may develop over time.

The appropriate spinal level, modality, and contrast level of advanced imaging will depend on the nature of the underlying disease.

- MRI without contrast or without and with contrast or CT without contrast of the cervical, thoracic, and/or lumbar spine can be approved in these individuals with

painful neuromuscular scoliosis, or when they are actively being evaluated for spinal deformity corrective surgery.

- Bone scans (one of CPT® codes: CPT® 78300, CPT® 78305, CPT® 78306, or CPT® 78315) are useful to evaluate cases of painful scoliosis and to identify tumors or infections. They are more sensitive than plain radiography.

References (PEDSP-3)

v1.0.2024

1. ACR-SPR-SSR Practice parameter for the performance of radiography for scoliosis in children. Revised 2014.
2. Alsharief AN, El-Hawary R, Schmit P. Pediatric spine imaging post scoliosis surgery. *Pediatric radiology*. 2018;48(1):124-40.
3. Calloni SF, Huisman TA, Poretti A, Soares BP. Back pain and scoliosis in children: when to image, what to consider. *The Neuroradiology Journal*. 2017;30(5):393-404.
4. El-Hawary R, Chuckwunyerewa C. Update on evaluation and treatment of scoliosis. *Pediatr Clin N Am*. 2014;61:1223-41.
5. Kim H, Kim HS, Moon ES, et al. Scoliosis imaging: what radiologist should know. *Radiographics*. 2010;30:1823-42.
6. Mayfair D, Flemming AK, Dvorak MR, et al. Radiographic evaluation of scoliosis: review. *AJR*. 2010;194:S8-S22.
7. Mistovich RJ and Spiegel DA. The spine. In: Kliegman RM, St. Geme JW III, Blum NJ, et. al. *Nelson Textbook of Pediatrics*. 21st edition. Philadelphia, PA: Elsevier; 2020:3633-3646.
8. Shafa E, Shah SA. Scheuermann kyphosis. Scoliosis Research Society. E-Text. 2019.
9. Oetgen ME. Current use of evidence-based medicine in pediatric spine surgery. *Orthopedic Clinics*. 2018;49(2):191-4.
10. Gokce E, Beyhan M. Radiological imaging findings of Scheuermann disease. *World J Radiol*. 2016; 28:895-901.
11. NG S, Bettany-Saltikov J. Imaging in the diagnosis and monitoring of children with idiopathic scoliosis. *Open Orthop J*. 2017;11:1500-1520.
12. Jones JY, Saigal G, Palasis S, et al. ACR Appropriateness Criteria® Scoliosis-Child. American College of Radiology. Updated: 2018.

Spinal Dysraphism and Tethered Spinal Cord (PEDSP-4)

Guideline

Introduction (PEDSP-4.1)

Cutaneous Indications to Suspect Occult Spinal Dysraphism (PEDSP-4.2)

Non-Cutaneous Indications to Suspect Occult Spinal Dysraphism
(PEDSP-4.3)

Spinal Dysraphism (PEDSP-4.4)

References (PEDSP-4)

Introduction (PEDSP-4.1)

SPP.TC.0004.1.A

v1.0.2024

Spinal Dysraphism

- Spinal dysraphism includes a range of congenital and/or developmental anomalies of the spinal cord and associated spinal structures that can affect any level of the spine, but most commonly the lumbosacral region.
- Based on clinical classification, dysraphism is grouped into two categories:
 - Open dysraphism (spina bifida aperta) which are non-skin-covered, open neural tube defects (myelomeningocele)
 - Occult spinal dysraphism (also called closed spinal dysraphism), which includes skin-covered defects (either with or without an associated subcutaneous mass).

Normal position of spinal cord

- In newborns, the spinal cord should terminate (at the conus medullaris) at L2-3 or higher.
- By 3 months of age, the conus should lie at or above the L2 level.
- Afterwards, in normal infants and children, the conus medullaris should be positioned at L1-2.
- Of note, however, in premature infants, the conus medullaris may be located at the mid L3-level.
 - If such a finding on an initial spinal ultrasound results in uncertainty as to whether cord termination is low, repeat spinal ultrasound (CPT® 76800) can be performed in 4 to 6 weeks, since a normal cord will have “moved” higher within the spinal canal by this time.

Tethered cord

- Tethering is certain when the cord terminates at or below L4 and there is other supporting evidence of tethering such as limited spinal cord pulsatility, posterior positioning in the spinal canal, thick filum terminale, intraspinal mass, or lipoma.
- If the conus terminates at a normal position (at L2-3 under 3 months of age, at L2 by 3 months of age, at L1-2 in older infants and children), the cord may still be tethered by an abnormal structure. Such tethering of the spinal cord can be found in some (but not all) patients with Occult Spinal Dysraphism. Abnormalities can be found in both lumbosacral and thoracic regions and are often associated with spinal lipomas in either region.
- Open Spinal Dysraphism is frequently associated with tethering of the spinal cord; symptoms of or findings from that tethering may manifest initially or may increase after the newborn period and the initial imaging evaluation. See: **Open Dysraphism (PEDSP-4.4)**.

“Tethered cord Syndrome”

- “Tethered Cord Syndrome” refers to symptoms and abnormal physical findings (such as low back or leg pain, decreased or absent lower extremity reflexes, urinary

urgency, urinary incontinence, bowel incontinence, and constipation) that arise when a pathologic attachment causes abnormal spinal tension (increased by axial growth), with ensuing pathophysiologic effects. Some of these patients do have an abnormally low conus medullaris; other patients have other spinal abnormalities (such as spinal dysraphism) that causes the spinal cord to be abnormally tethered. Other patients with spinal dysraphism who may present with symptoms or findings suggestive of “Tethered Cord Syndrome” may have those clinical manifestations caused by primary dysplasia of neural tissue, instead of being caused by abnormal tethering. See: **Non-Cutaneous Indications to Suspect Occult Spinal Dysraphism (PEDSP-4.3)**.

- Not all anatomically tethered spinal cords result in symptoms of “Tethered Cord Syndrome”.

Imaging Studies to Evaluate Suspected Occult Spinal Dysraphism and/or Tethered Cord

- Plain x-rays are not indicated for suspected Occult Spinal Dysraphism and/or Tethered Cord.
- Spina Bifida Occulta, an incomplete fusion of the posterior lumbosacral bony elements (present in in about 25% of people), is often discovered as an incidental finding on x-rays and other imaging exams. In asymptomatic individuals it is of no consequence, and is not an indication for further imaging.
- A plain spine x-ray finding suggesting an absent or distorted pedicle (the “winking owl sign”) can be indicative of Occult Spinal Dysraphism, for which an initial MRI without contrast or MRI without and with contrast of the appropriate spinal level can be approved.
- When indicated (See: **Cutaneous Indications to Suspect Occult Spinal Dysraphism (PEDSP-4.2)**, **Non-Cutaneous Indications to Suspect Occult Spinal Dysraphism (PEDSP-4.3)**, and **Open Dysraphism (PEDSP-4.4)** for indications), the following imaging may be approved:
 - Spinal ultrasound (CPT® 76800) for initial evaluation in infants up to 6 months of age, in premature infants whose “corrected age” (subtracting the number of weeks of prematurity from the infant’s actual age) is less than or equal to 6 months, or in older individuals with open spinal dysraphism (see: **Open Dysraphism (PEDSP-4.4)**).
 - In a term infant, the diagnosis of tethered cord is likely if the conus terminates below the L2-L3 disc space. Of note, however, in premature infants, the conus medullaris may be located at the mid L3-level; if there is uncertainty as to whether cord termination is low in a premature infant, repeat spinal ultrasound (CPT® 76800) can be performed in 4 to 6 weeks, since a normal cord will have “moved” higher within the spinal canal by this time.
 - MRI Cervical, Thoracic, and Lumbar spine without contrast (CPT® 72141, 72146, and 72148) or without and with contrast (CPT® 72156, 72157, and 72158) may be approved for initial evaluation in individuals older than 6 months of age.

- MRI can be approved at a younger age when there are symptoms or physical findings or concerning findings on ultrasound showing the need for more prompt MRI imaging, or when MRI imaging prior to 6 months of age has been ordered by (or in consultation with) an appropriate specialist for an indication from **Cutaneous Indications to Suspect Occult Spinal Dysraphism (PEDSP-4.2)**, **Non-Cutaneous Indications to Suspect Occult Spinal Dysraphism (PEDSP-4.3)**, or **Open Dysraphism (PEDSP-4.4)**.
 - The appropriate spinal level, modality, and contrast level of follow-up advanced imaging will depend on the nature of the underlying disease, usually ordered by (or after consultation with) an appropriate specialist.
 - Postoperative MRI is not done routinely, but may be indicated if there are recurrent symptoms or findings suggesting recurrent tethering or other deterioration. Contrast level per ordering specialist.
 - A complete abdominal ultrasound (CPT® 76700) or retroperitoneal ultrasound (CPT® 76770) can be approved as an initial evaluation for patients with newly diagnosed neurogenic bladder, myelomeningocele (open spinal dysraphism), or occult spinal dysraphism.
 - A complete retroperitoneal ultrasound (CPT® 76770) can be approved every 6 to 12 months for follow-up/surveillance for any of the above conditions.
 - CT of the effected spinal level can be approved for surgical planning when a complex bony deformity of the spine is present, or when the Guidelines support doing MRI of the spine in a patient for whom MRI is contraindicated.

Cutaneous Indications to Suspect Occult Spinal Dysraphism (PEDSP-4.2)

SPP.TC.0004.2.A

v1.0.2024

- More than 80% of individuals with Occult Spinal Dysraphism and/or Tethered Spinal Cord will have a cutaneous lesion overlying the lower spine.
- Spine imaging is NOT indicated in the following situations:
 - Pilonidal cysts below the level of the intergluteal fold.
 - For discussion of imaging in pilonidal cysts, see: **Pilonidal Cyst (PV-21.4)** in the Pelvis Imaging Guidelines
 - Non-specific darkened areas of skin over the sacrum (such as dermal melanosis) unless there are other associated midline cutaneous abnormalities
 - Occult bony dysraphism incidentally noted on x-ray
- Screening with advanced imaging IS recommended in the following clinical conditions which are associated with an increased risk of underlying spinal dysraphism:
 - Spinal dimples (midline soft tissue depression over the spine); or deviated or split (bifid) gluteal cleft
 - Spinal ultrasound (CPT® 76800) may be approved for initial evaluation in infants up to 6 months of age (or in premature infants with a “corrected” age up to 6 months of age). Follow-up of a normal screening spinal ultrasound with ultrasound is not appropriate.
 - MRI of the involved spinal level without contrast or without and with contrast may be approved for initial evaluation in individuals older than 6 months of age. MRI can be approved at a younger age when there are symptoms or physical findings or concerning findings on ultrasound showing the need for more prompt MRI imaging, or if ordered by (or in consultation with) an appropriate specialist.
 - A screening MRI can be approved after a normal screening spinal ultrasound exam. Follow-up of a normal screening MRI imaging study is not appropriate.
 - Dermal sinuses overlying the lumbar, thoracic, or cervical spine, and sacral dermal sinuses, whether manifested by a dermal sinus tract (a small opening in the skin, which leads into a narrow duct; it may be associated with protruding hairs) or a dermal cyst. They may be associated with an overlying or nearby hairy patch or vascular nevus
 - Spinal ultrasound (CPT® 76800) may be approved for initial evaluation in infants up to 6 months of age (or in premature infants with a “corrected” age up to 6 months of age). Follow-up of a normal screening spinal ultrasound is not appropriate.
 - MRI of the involved spinal level without contrast or without and with contrast should be approved if an ultrasound shows abnormalities other than a

- cutaneous dermal cleft, if ordered after 6 months of age, or at a younger age if ordered by (or in consultation with) an appropriate specialist.
- A screening MRI can be approved after a normal screening spinal ultrasound exam. Follow-up of a normal screening MRI imaging study is not appropriate.
 - Subcutaneous midline masses (including cysts and lipomas) at any level.
 - Plain x-rays are not required to approve other imaging for midline masses overlying the spine when occult spinal dysraphism and/or tethered cord is suspected.
 - Spinal ultrasound (CPT® 76800) may be approved for initial evaluation in infants up to 6 months of age (or in premature infants with a “corrected” age up to 6 months of age), but MRI of the involved spinal level without contrast or without and with contrast is the preferred initial imaging for midline masses overlying the spine. Repeat ultrasound follow-up of a normal screening spinal ultrasound is not appropriate.
 - MRI of the involved spinal level without contrast or without and with contrast may be approved for initial evaluation in patients older than 6 months of age. MRI can be approved at a younger age when there are symptoms or physical findings or concerning findings on ultrasound showing the need for more prompt MRI imaging, or if ordered by (or in consultation with) an appropriate specialist.
 - A screening MRI can be approved after a normal screening spinal ultrasound exam. Follow-up of a normal screening MRI imaging study is not appropriate.
 - Caudal extensions (including tail-like appendages), midline skin tags, abnormal patches of hair over the spine at any level, infantile hemangiomas overlying any spinal level, and complex midline birthmarks above the upper sacral region.
 - Spinal ultrasound (CPT® 76800) may be approved for initial evaluation in infants up to 6 months of age (or in premature infants with a “corrected” age up to 6 months of age). Repeat ultrasound follow-up of a normal screening spinal ultrasound is not appropriate.
 - MRI of the involved spinal level without contrast or without and with contrast may be approved for initial evaluation in individuals older than 6 months of age. MRI can be approved at a younger age when there are symptoms or physical findings or concerning findings on ultrasound showing the need for more prompt MRI imaging, or if ordered by (or in consultation with) an appropriate specialist.
 - A screening MRI can be approved after a normal screening spinal ultrasound exam. Follow-up of a normal screening MRI imaging study is not appropriate.
 - Café au lait spots are a marker for type 1 neurofibromatosis
 - See imaging indications in **Neurofibromatosis 1 and 2 (NF1 and NF2) (PEDONC-2.3)** and/or **Neurofibromatosis (PEDPN-2)**.

Non-Cutaneous Indications to Suspect Occult Spinal Dysraphism (PEDSP-4.3)

SPP.TC.0004.3.A

v1.0.2024

- Imperforate Anus, and other congenital anorectal abnormalities are often associated with dysraphism. Also associated with spinal dysraphism are VACTERL (Vertebral malformations, Anal atresia, Cardiac anomalies, Tracheo-Esophageal fistula, Renal abnormalities, and Limb defects) Syndrome, Currarino triad (sacral dysgenesis, presacral mass, anorectal malformation), OEIS (omphalocele, exstrophy, imperforate anus, spinal defects) syndrome, Caudal regression Syndrome, and Sacral Agenesis (when 2 or more of the sacral vertebral bodies are absent; physical exam will show buttock flattening, short gluteal cleft, and palpable absence of coccygeal vertebrae; about 20% of children with sacral agenesis are not detected prior to age of 3 years).
 - Spinal ultrasound (CPT® 76800) may be approved for initial evaluation in infants up to 6 months of age (or in premature infants with a “corrected” age up to 6 months of age). Repeat ultrasound follow-up of a normal screening spinal ultrasound is not appropriate.
 - The following should be approved when requested: MRI Lumbar Spine without contrast (CPT® 72148) or without and with contrast (CPT® 72158); and/or MRI Pelvis without contrast (CPT® 72195) or MRI Pelvis without and with contrast (CPT® 72197).
 - Appropriate MRI (or other modality) imaging (including contrast level) of any other spinal level will depend on the nature of the underlying disease, usually ordered by (or in consultation with) an appropriate specialist.
 - Follow-up of a normal screening MRI imaging study is not appropriate, but an initial MRI can be approved if the first screening study was an ultrasound.
 - Postoperative MRI is not done routinely, but may be indicated if there are recurrent symptoms or findings suggesting recurrent tethering. Contrast level per ordering specialist.
- Rubinstein-Taybi syndrome (gait abnormalities, short stature, short limbs, characteristic facies, developmental delay, tethered spinal cord)
 - Spinal ultrasound (CPT® 76800) may be approved for initial evaluation in infants up to 6 months of age (or in premature infants with a “corrected” age up to 6 months of age). Repeat ultrasound follow-up of a normal screening spinal ultrasound is not appropriate.
 - MRI Lumbar spine without contrast (CPT® 72148) or without and with contrast (CPT® 72158) should be approved.
 - Appropriate MRI (or other modality) imaging (including contrast level) of any other spinal level will depend on the nature of the underlying disease, usually ordered by (or in consultation with) an appropriate specialist.

- Follow-up of a normal screening MRI imaging study is not appropriate, but an initial MRI can be approved if the first screening study was an ultrasound.
- Individuals with known DiGeorge Syndrome (22q11.2 deletion syndrome), when tethered cord syndrome or occult spinal dysraphism is suspected.
 - Spinal ultrasound (CPT® 76800) may be approved for initial evaluation in infants up to 6 months of age.
 - The following should be approved when requested: MRI Lumbar Spine without contrast (CPT® 72148) or without and with contrast (CPT® 72158)
 - Appropriate MRI (or other modality) imaging (including contrast level) of any other spinal level will depend on the nature of the underlying disease, usually ordered by (or in consultation with) an appropriate specialist.
 - Follow-up of a normal screening MRI imaging study is not appropriate, but an initial MRI can be approved if the first screening study was an ultrasound.
- Neurologic Related Symptoms and Physical Exam Findings suggestive of Occult Spinal Dysraphism or Tethered Cord Syndrome and/or low lying conus medullaris (see: **Myelopathy (SP-7.1)** and **Myelopathy (PEDSP-6)**, and **Developmental Motor Delay (PEDHD-19.3)** for spinal cord involvement suspected in individuals with developmental motor delay) for which MRI of the involved spinal level without contrast or without and with contrast may be approved when any of the following are present:
 - Asymmetry of the feet, with one smaller foot, a high arch, and/or clawing of the toes. This is sometimes called the “neuroorthopedic syndrome”, and is associated with lack of an ipsilateral ankle jerk deep tendon reflex and calf atrophy
 - Cavus foot (also called pes cavus or pes cavovarus)
 - Toe walking, when associated with upper motor neuron signs including hyperreflexia, spasticity, and positive Babinski sign
 - Ataxia (see: **Ataxia (PEDHD-20)**)
 - Absent perineal sensation
 - Lower urinary tract dysfunction, including urinary urgency or urinary incontinence. Though not a requirement for advanced imaging, some of these patients will have had abnormal urodynamic studies (such as cystometrography and/or sphincter electromyography).
 - Constipation, especially if there are abnormal physical exam findings related to the spine (such as lower extremity weakness, decreased lower extremity tone, abnormal lower extremity reflexes, a tuft of hair over the spine or covering a pilonidal dimple, a sacral dimple, gluteal cleft deviation, or absent anal or cremasteric reflex), failure of maximal laxative therapy (see: **Constipation, Diarrhea, and Irritable Bowel Syndrome (PEDAB-12)**) and/or bowel incontinence, when Tethered Cord Syndrome or Occult Spinal Dysraphism is suspected as the cause
 - Back or leg pain when Tethered Cord Syndrome or Occult Spinal Dysraphism is suspected as the cause. In this setting, neither a plain x-ray of the spine nor a

recent period of provider directed conservative treatment is required to approve an MRI spine).

Spinal Dysraphism (PEDSP-4.4)

SPP.TC.0004.4.A

v1.0.2024

- Clinically significant dysraphism includes findings ranging from complex vertebral anomalies to myelomeningocele.
- Dysraphism is categorized into 2 major groups:²⁶
 - Open Dysraphism - lack of skin covering with exposed neural elements
 - Closed Dysraphism - skin covered
- It is rare to perform MRI in neonates with open dysraphism as the diagnosis is usually made with obstetric ultrasound and confirmed with visual inspection
 - MRI of the entire spine may be approved for preoperative planning if ordered by a specialist.
- MRI Brain without contrast (CPT[®] 70551) or with and without contrast (CPT[®] 70553) is indicated in all cases of open dysraphism as Chiari II malformation will be present²⁶
- Closed Dysraphism
 - MRI of the entire spine without contrast or without and with contrast is appropriate at the time of initial diagnosis.
 - MRI Brain without contrast (CPT[®] 70551) or without and with contrast (CPT[®] 70553) or CT without contrast of the brain (CPT[®] 70450) may be approved in cases with associated hydrocephalus, signs of cerebral involvement, or the presence of multiple hydromyelia (which suggests hydrocephalus).
 - MRI Pelvis without contrast (CPT[®] 72195) or without and with contrast (CPT[®] 72196) may be approved once if there are clinical signs of pelvic malformation or anorectal anomaly
 - MRI Cervical, Thoracic, and Lumbar spine without contrast (CPT[®] 72141, 72146, 72148) or without and with contrast (CPT[®] 72156, 72157, 72158) when ordered for preoperative planning.
 - Spinal canal ultrasound (CPT[®] 76800) may be approved as an alternative to MRI, if requested, in individuals with open dysraphism as the posterior bony defect provides an acoustic window for ultrasound.
 - MRI of the appropriate spinal level without contrast or without and with contrast may be approved when there are new and/or worsened neurologic symptoms and/or physical exam findings suggestive of new or worsened tethering of the spinal cord, such as any of the following:
 - New or worsened cavus foot
 - New or worsened toe walking and/or upper motor neuron signs (including hyperreflexia, spasticity, and positive Babinski sign)
 - New or worsened leg weakness or numbness or difficulty in ambulation
 - New or worsened loss of perineal sensation

- New or worsened lower urinary tract dysfunction (including urinary urgency or urinary incontinence, or new or worse changes on diagnostic urodynamic studies)
- New or worsened constipation
- New or worsened pain in the back or legs suspected to have been caused by tethering of the spinal cord.
 - MRI Brain without contrast (CPT® 70551) or without and with contrast (CPT® 70553) or CT without contrast of the brain (CPT® 70450) may be approved in cases with associated hydrocephalus, signs of cerebral involvement, or the presence of multiple hydromyelia (which suggests hydrocephalus).
 - MRI Pelvis without contrast (CPT® 72195) or without and with contrast (CPT® 72196) may be approved once if there are clinical signs of pelvic malformation or anorectal anomaly
- The appropriate spinal level, modality, and contrast level of follow-up advanced imaging will depend on the nature of the underlying disease, usually requested after specialist consultation.

References (PEDSP-4)

v1.0.2024

1. Badve C, Phillips GS, Khanna PC, et al. MRI of closed spinal dysraphisms. *Pediatr Radiol*. 2011;41:1308-20.
2. Ellenbogen RG. Neural tube defects in the neonatal period. *Medscape*. Version December 18, 2019. <https://emedicine.medscape.com/article/1825866-overview>.
3. Haynes, KB, Wimberly RL, VanPelt JM, et al. Toe walking: a neurological perspective after referral from pediatric orthopaedic surgeons. *Journ of Ped Ortho*. 2018;38(3):152-6.
4. Kim SM, Chang HK, Lee MJ, et al. Spinal dysraphism with anorectal malformation: lumbosacral magnetic resonance imaging evaluation of 120 patients. *J PediatrSurg*. 2010 Apr;45(4):769-776 doi: 10.1016/j.jpedsurg.2009.10.094
5. Kinsman SL and Johnson MV. Congenital anomalies of the central nervous system. In: Kliegman RM, St. Geme JW III, Blum NJ, et. al. *Nelson Textbook of Pediatrics*. 21st edition. Philadelphia, PA: Elsevier; 2020:3063-3082.
6. Kucera JN, Coley I, O'Hara, et al. The simple sacral dimple: diagnostic yield of ultrasound in neonates. *Pediatr Radiol*. 2015;45:211-6.
7. Wang LL, Bierbrauer KS. Congenital and hereditary diseases of the spinal cord. *Semin Ultrasound CT, MRI*. 2017;38:105-25.
8. AIUM Practice Parameter for the Performance of an Ultrasound Examination of the Neonatal and Infant Spine. Revised 2016
9. Subiabre-Ferrer D, García-Rabasco A, Correa-González N, Ortiz-Salvador JM, Barreda-Solana M. Role of magnetic resonance image in children with lumbosacral and perineal hemangiomas: case reports and review of the literature. *Actas Dermo-Sifiliográficas (English Edition)*. 2019;110(9):728-33.
10. Farmakis SG and Siegel MJ. Spinal ultrasonography. In: Sanders RC and Hall-Terracciano B, et. al. *Clinical Sonography: A Practical Guide*. 5th edition. Philadelphia, PA: Wolters Kluwer. 2016;657-669.
11. Halevi PD, Udayakumaran S, Ben-Sira L, et al. The value of postoperative MR. *Childs Nerv Syst*. 2011;27:2159-62.
12. Hertzler DA, DePowell JJ, Stevenson CB, et al. Tethered cord syndrome: a review of the literature from embryology to adult presentation. *Neurosurg Focus*. 2010;29(1):E1. doi:10.3171/2010.3.FOCUS1079.
13. Hervey-Jumper SL, Garton HJL, Wetjen NM, et al. Neurosurgical management of congenital malformations and inherited disease of the spine. *Neuroimaging Clin N Am*. 2011;21(3):719-731. doi:10.1016/j.nic.2011.05.009.
14. Ladino Torres MF, DiPietro MA. Spine ultrasound imaging in the newborn. *Seminars in Ultrasound, CT, and MRI*. 2014;35(6):652-661. doi:10.1053/j.sult.2014.08.001.
15. Siegel MJ. Spinal ultrasonography. In: *Pediatric sonography*. 5th ed. Philadelphia, PA: Wolters Kluwer. 2018;653-76.
16. Proctor MR. Tethered Cord. In: Kliegman RM, St. Geme JW III, Blum NJ, et. al. *Nelson Textbook of Pediatrics*. 21st edition. Philadelphia, PA; 2020:3238-3239.
17. Moore, KR. Congenital Abnormalities of the Spine. In: Coley, ed. *Caffey's Pediatric Diagnostic Imaging*. 13th edition. Philadelphia, PA: Elsevier Saunders. 2019;408-418.
18. Tuite GF, Thompson DN, Austin PF, Bauer SB. Evaluation and management of tethered cord syndrome in occult spinal dysraphism: Recommendations from the International Children's Continence Society. *Neurology and urodynamics*. 2018;37(3):890-903.
19. Wang LL, Bierbrauer KS. Congenital and hereditary diseases of the spinal cord. *Semin Ultrasound CT, MRI*. 2017;38:105-25
20. G Tamura, N Morota, S Ihara. Impact of magnetic resonance imaging and urodynamic studies on the management of sacrococcygeal dimples. *Journal of Neurosurgery: Pediatrics*. 2017. Doi:10.3171/2017.5.PEDS16719.
21. Gomi, A., Oguma, H. & Furukawa, R. Sacrococcygeal dimple: new classification and relationship with spinal lesions. *Childs Nerv Syst*. 2013;29:1641–1645. doi:10.1007/s00381-013-2135-3 1231438.
22. Harada A, Nishiyama K, Yoshimura J, Sano M, Fujii Y. Intraspinous lesions associated with sacrococcygeal dimples. *J Neurosurg Pediatr*. 2014;14:81–86.
23. O'Neill BR, Gallegos D, Herron A, Palmer C, Stence NV, Hankinson TC, et al. Use of magnetic resonance imaging to detect occult spinal dysraphism in infants. *J Neurosurg Pediatr*. 2016;19:1---10.
24. Moore, KR. Congenital Abnormalities of the Spine. In: Brian Coley, ed. *Caffey's Pediatric Diagnostic Imaging*. 13th edition. Philadelphia, PA: 2019;408-418.
25. Greenan K, et. al. Imaging of Occult Spinal Dysraphism. In: Tubbs RS, et. al. *Occult Spinal Dysraphism*. doi.org/10.1007/978-3-030-10994-3_15.

26. Trapp B, Freddi TDL, Hans MDM, et. al. A practical approach to diagnosis of spinal dysraphism. *RadioGraphics*. 2021;41(2). doi:10.1148/rg.2021200103.

Tethered Cord (PEDSP-5)

Guideline

Tethered Cord (PEDSP-5)

Tethered Cord (PEDSP-5)

SPP.TetheredCord.PEDSP.5.A

v1.0.2024

- See: **Spinal Dysraphism and Tethered Spinal Cord (PEDSP-4)**

Myelopathy (PEDSP-6)

Guideline

Myelopathy (PEDSP-6)

Myelopathy (PEDSP-6)

SPP.Myelopathy.PEDSP.6.A

v1.0.2024

Myelopathy imaging indications in pediatric individuals are similar to those for adult individuals. See: **Myelopathy (SP-7)** in the Spine Imaging Guidelines and/or **Non-Cutaneous Indications to Suspect Occult Spinal Dysraphism (PEDSP-4.3)**

Other Congenital and Pediatric Spine Disorders (PEDSP-7)

Guideline

- Achondroplasia (PEDSP-7.1)
- Inflammatory Spondylitis (PEDSP-7.2)
- Atlantoaxial Instability in Trisomy 21 (Down Syndrome) (PEDSP-7.3)
- Basilar Impression (PEDSP-7.4)
- Chiari Malformation (PEDSP-7.5)
- Klippel-Feil Anomaly (Congenital Fusion of Cervical Vertebrae) (PEDSP-7.6)
- Marfan Syndrome (PEDSP-7.7)
- Neurofibromatosis (PEDSP-7.8)
- Von Hippel-Lindau Syndrome (VHL) (PEDSP-7.9)
- References (PEDSP-7)

Achondroplasia (PEDSP-7.1)

SPP.CD.0007.1.A

v1.0.2024

- The diagnosis of achondroplasia is made clinically. Achondroplasia patients are at risk for hydrocephalus as well as myelopathy from spinal stenosis with increasing age.
- A pertinent clinical evaluation including a detailed history, physical examination with thorough neurologic examination and documentation of any specific radicular features, and plain radiography should be performed prior to considering advanced imaging.
- MRI without contrast or without and with of the symptomatic spinal region can be approved when new or worsening clinical symptoms suggest achondroplasia-related spinal stenosis.
- MRI Brain without contrast (CPT® 70551) or CT Head without contrast (CPT® 70450) can be approved when new or worsening clinical symptoms suggest hydrocephalus.

Inflammatory Spondylitis (PEDSP-7.2)

SPP.CD.0007.2.A

v1.0.2024

- Except as listed below, imaging considerations in pediatric and adult patients are identical for this condition, and these patients should be imaged according to **Inflammatory Spondylitis (SP-10.2)**.

For pediatric patients with juvenile idiopathic arthritis:

- MRI without and with contrast or without contrast of the involved levels is appropriate.
- An initial x-ray is not necessary prior to MRI in these patients.
- For evaluation of facet arthropathy in patients with ankylosing spondylitis, osteoarthritis, or rheumatoid arthritis:
 - Whole body radiopharmaceutical localization imaging (CPT® 78802) and SPECT (CPT® 78803) OR
 - SPECT/CT (CPT® 78830)

Atlantoaxial Instability in Trisomy 21 (Down Syndrome) (PEDSP-7.3)

SPP.CD.0007.3.A

v1.0.2024

- The diagnosis of atlantoaxial instability is a recognized complication of trisomy 21, and patients are routinely screened with lateral x-rays of the cervical spine.
- MRI Cervical Spine without contrast (CPT[®] 72141) or without and with contrast (CPT[®] 72156) in individuals where the lateral cervical spine x-ray demonstrates an atlantodental (pre dens) interval of ≥ 4.5 mm, and/or a neural canal width of ≤ 14 mm.
- MRI Cervical Spine without contrast (CPT[®] 72141) or without and with contrast (CPT[®] 72156) when new or worsening clinical symptoms suggest myelopathy in a trisomy 21 individual.

Basilar Impression (PEDSP-7.4)

SPP.CD.0007.4.A

v1.0.2024

See: **Basilar Impression (PEDHD-9.4)** in the Pediatric Head Imaging Guidelines

Chiari Malformation (PEDSP-7.5)

SPP.CD.0007.5.A

v1.0.2024

See: **Chiari and Skull Base Malformations (PEDHD-9)** in the Pediatric Head Imaging Guidelines

Klippel-Feil Anomaly (Congenital Fusion of Cervical Vertebrae) (PEDSP-7.6)

SPP.CD.0007.6.A

v1.0.2024

This is generally an incidental finding. A detailed history and physical examination with thorough neurologic examination, and plain x-rays should be performed initially. Klippel-Feil can occur in conjunction with platybasia and/or Chiari malformation.

- Plain x-rays of the cervical spine are sufficient to establish the diagnosis. Advanced imaging is indicated if there are acute or worsening neurologic symptoms (including pain), or if multiple levels are involved.
 - MRI Cervical Spine without contrast (CPT® 72141) or CT Cervical Spine without contrast (CPT® 72125) for these indications.

Marfan Syndrome (PEDSP-7.7)

SPP.CD.0007.7.A

v1.0.2024

Marfan syndrome patients are at risk for scoliosis (see **Scoliosis (PEDSP-3.2)**) and dural ectasias. Dural ectasias are usually asymptomatic but can be associated with other spinal lesions.

- A pertinent clinical evaluation including a detailed history, physical examination with thorough neurologic examination and documentation of any specific radicular features, and plain radiography should be performed prior to considering advanced imaging.
- MRI without contrast of the symptomatic spinal region can be approved when:
 - New or worsening clinical symptoms suggest a complicated dural ectasia
 - The individual is under active consideration for surgery

Neurofibromatosis (PEDSP-7.8)

SPP.CD.0007.8.A

v1.0.2024

- See: **Neurofibromatosis 1 and 2 (NF1 and NF2) (PEDONC-2.3)** in the Pediatric Oncology Imaging Guidelines for screening recommendations in neurofibromatosis.
- See: **Neurofibromatosis (PEDPN-2)** in the Pediatric Peripheral Nerve Disorders Imaging Guidelines for imaging considerations in neurofibromatosis individuals with known plexiform neurofibromas.
- See: **Non-Rhabdomyosarcoma Soft Tissue Sarcomas (PEDONC-8.3)** in the Pediatric Oncology Imaging Guidelines for imaging in individuals with neurofibromatosis and malignant peripheral nerve sheath tumors.

Von Hippel-Lindau Syndrome (VHL) (PEDSP-7.9)

SPP.CD.0007.9.A

v1.0.2024

- See: **Von Hippel-Lindau Syndrome (VHL) (PEDONC-2.10)** in the Pediatric Oncology Imaging Guidelines for screening recommendations in VHL patients.
- MRI without and with contrast of the affected spinal level can be approved for patients with known spinal hemangioblastomas in the following conditions:
 - Annually for asymptomatic patients with unresected spinal hemangioblastoma(s)
 - Preoperative planning for resection of a hemangioblastoma
 - New or worsening symptoms suggesting progression of a known hemangioblastoma

References (PEDSP-7)

v1.0.2024

1. Child AH. Non-cardiac manifestations of marfan syndrome. *Ann Cardiothorac Surg.* 2017;6:599-609.
2. Frantzen C, Klasson TF, Links TP, et al. Von Hippel-lindau disease. *GeneReviews™*. [Internet] eds. Pagon RA, Adam MP, Bird TD et al. <https://www.ncbi.nlm.nih.gov/books/NBK1463/>
3. Jaremko JL, Liu L, Winn NJ, et al. Diagnostic utility of magnetic resonance imaging and radiography in juvenile spondyloarthritis: evaluation of the sacroiliac joints in controls and affected subjects. *J Rheumatol.* 2014;41:963-70. doi:10.3899/jrheum.131064.
4. Kao SC, Waziri MH, Smith WL, et al. MR imaging of the craniovertebral junction, cranium, and brain in children with achondroplasia. *American Journal of Roentgenology.* 1989;153(3):565-9. doi:10.2214/ajr.153.3.565.
5. Lambert RG, Bakker PA, van der Heijde D, et al. Defining active sacroiliitis on MRI for classification of axial spondyloarthritis: update by the ASAS MRI working group [epub ahead of print]. *Ann Rheum Dis.* 2016. doi:10.1136/annrheumdis-2015-208642.
6. Lin C, MacKenzie JD, Courtier JL, et al. Magnetic resonance imaging findings in juvenile spondyloarthropathy and effects of treatment observed on subsequent imaging. *Ped Rheumat.* 2014;12:25. doi:10.1186/1546-0096-12-25.
7. Rossi A. Pediatric spinal infection and inflammation. *Neuroimaging Clinics.* 2015;25(2):173-91.
8. Restropo R, Lee EY, Babyn PS. Juvenile idiopathic arthritis: Current practical imaging assessment with emphasis on magnetic resonance imaging. *Radiol Clin N Am.* 2013;51(4):703-719. doi:10.1016/j.rcl.2013.03.003.
9. Smoker WRK, Khanna G. Imaging the craniocervical junction. *Childs Nerv Syst.* 2008;24(10):1123-1145. doi:10.1007/s00381-008-0601-0.
10. Vezina G, Barkovich AJ. Neurocutaneous disorders. In: Barkovich AJ, Raybaud C, eds. *Pediatric Neuroimaging*, 6th ed. Philadelphia PA. Wolters Kluwer. 2015;633-702.
11. White KK, Bompadre V, Goldberg MJ, et al. Best practices in the evaluation and treatment of foramen magnum stenosis in achondroplasia during infancy. *Am J MedGenet A.* 2016;170A:42-51.
12. Dweck J, Lachman RS "Skeletal Dysplasias and Selected Chromosomal Disorders (Chapter 132)" in *Caffey's Pediatric Diagnostic Imaging*. 13th edition Brian Coley editor, Elsevier Saunders, Philadelphia PA, 2019. 1258-1295